

# UC Davis

## Dermatology Online Journal

### Title

Myxoid stroma and delicate vasculature of a superficial angiomyxoma give rise to the red planet sign

### Permalink

<https://escholarship.org/uc/item/5v18796n>

### Journal

Dermatology Online Journal, 20(9)

### Authors

Green, Margaret  
Logemann, Nichola  
Sulit, Daryl J

### Publication Date

2014

### DOI

10.5070/D3209023920

### Copyright Information

Copyright 2014 by the author(s). This work is made available under the terms of a Creative Commons Attribution-NonCommercial-NoDerivatives License, available at <https://creativecommons.org/licenses/by-nc-nd/4.0/>

Peer reviewed

**Photo Vignette**

**Myxoid stroma and delicate vasculature of a superficial angiomyxoma give rise to the red planet sign**

**Margaret Green DO MSc, Nicholas Logemann DO, Daryl J. Sulit MD**

**Dermatology Online Journal X (Z):**

**Walter Reed National Military Medical Center, Bethesda, MD**

**Correspondence:**

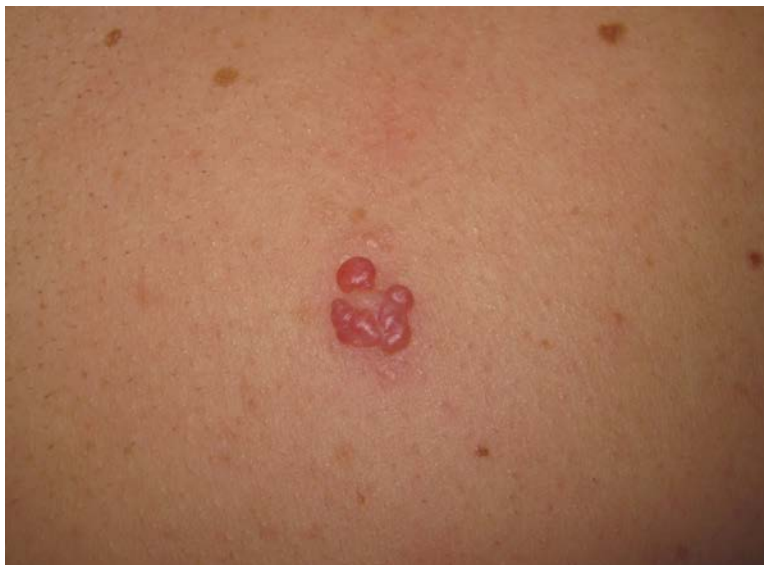Margaret Green DO, MSc  
Walter Reed National Military Medical Center  
8901 Rockville Pike  
Bethesda, MD 20889  
E-mail: Margaret.C.Green.mil@health.mil  
Telephone: (843) 343-6293

**Abstract**

Superficial angiomyxomas are uncommon benign mesenchymal tumors. They often recur locally if partially removed. This case report demonstrates not only the characteristic pathological findings of a superficial angiomyxoma in a 33- year-old man, but also shows a unique dermatoscopic image, which in our estimation resembles a celestial red planet such as the blood moon seen during a lunar eclipse. We propose to call this the “red planet” sign for a superficial angiomyxoma on dermoscopic examination.

**Keywords: dermoscopy, dermatoscopy, superficial angiomyxoma, dermatopathology**

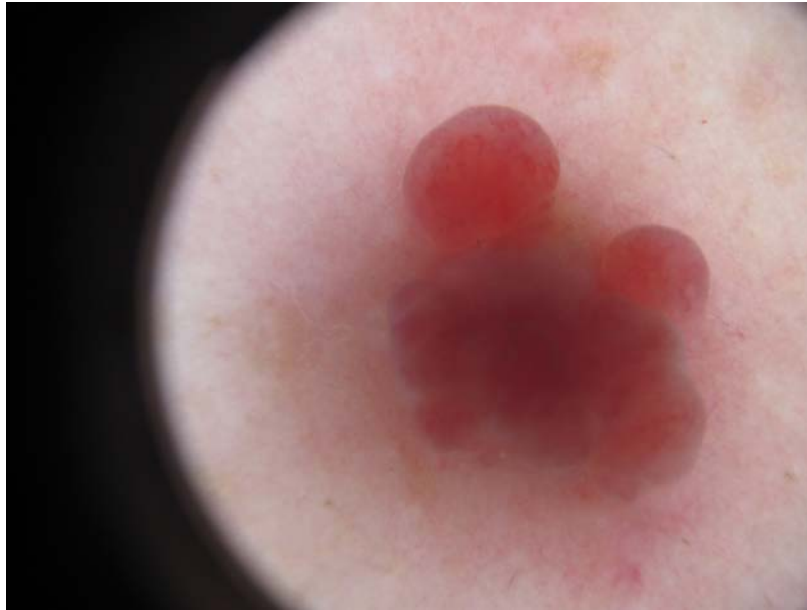
**Case synopsis**



**Figure 1.** Superficial angiomyxoma clinical photograph of posterior trunk

An otherwise healthy 33 year-old man presented in 2013 with a new lesion on his back that developed at the site of a shave biopsy previously performed in 2009. This prior biopsy was interpreted as cutaneous mucinosis on histopathology. On follow up physical exam in 2013, the patient was a Fitzpatrick skin type II with a polypoid, flesh to red, soft and non-tender papule with no erosion, measuring 1 cm in its greatest dimension (Figure 1). Dermoscopy demonstrated a red to maroon, translucent, globular, exophytic lesion with a faintly visible delicate vascular lattice network (Figure 2). In our observation, it is reminiscent of telescopic photographs of the blood moon during recent lunar eclipses (Figure 3).

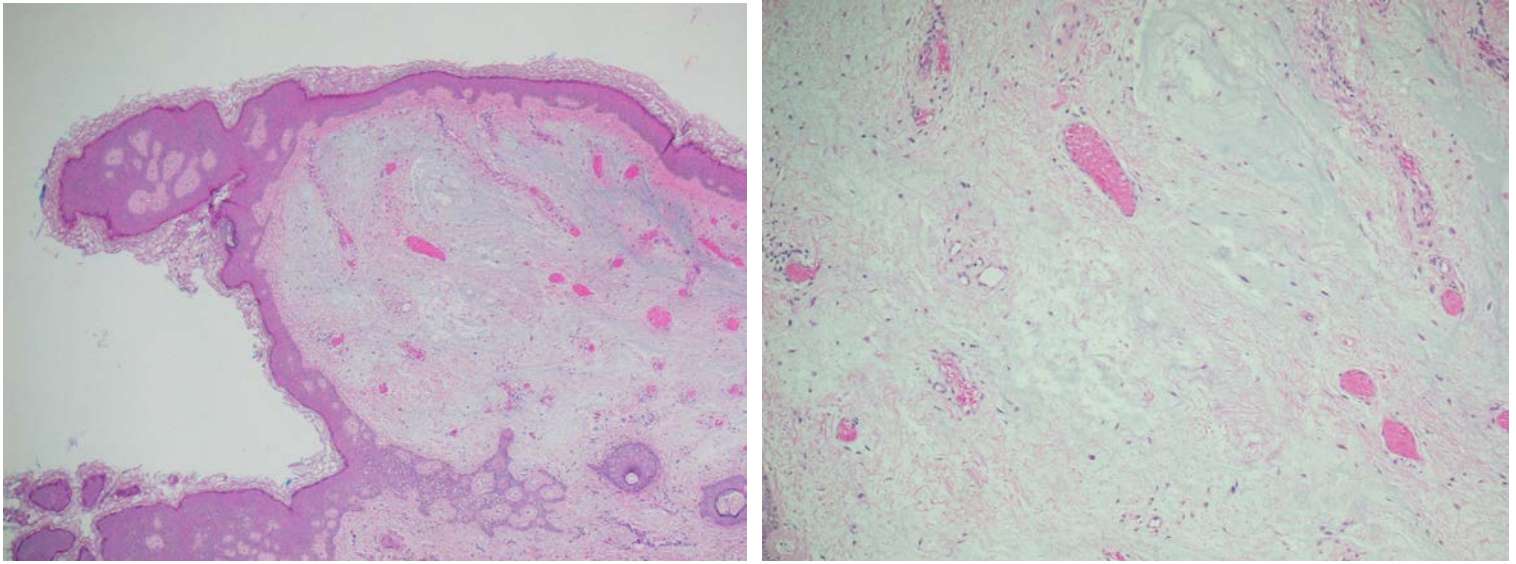
A shave biopsy was performed, which revealed copious amounts of basophilic myxoid stroma with associated stellate fibroblasts and a prominent intermingled vascular component. These histologic findings were consistent with a superficial angiomyxoma (Figures 4 and 5). Immunohistochemical staining was positive for CD34 and vimentin (Figure 6) and negative for S-100 (Figure 7), further supporting this diagnosis.



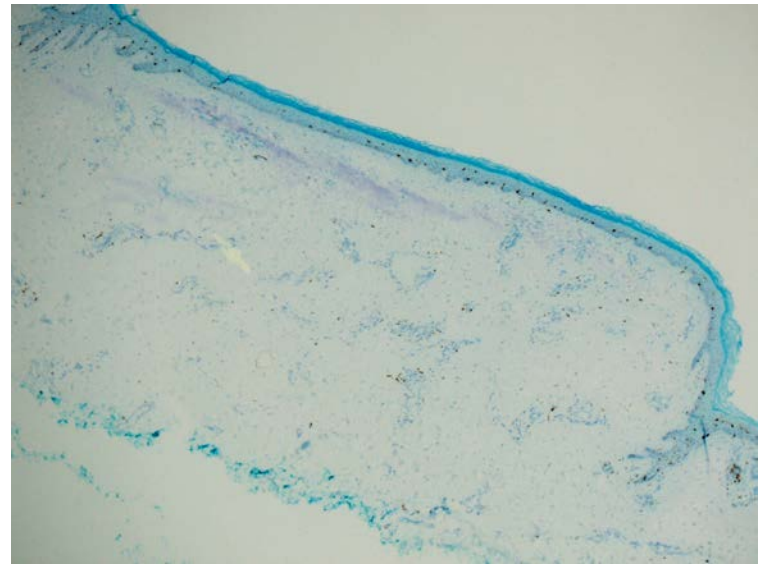
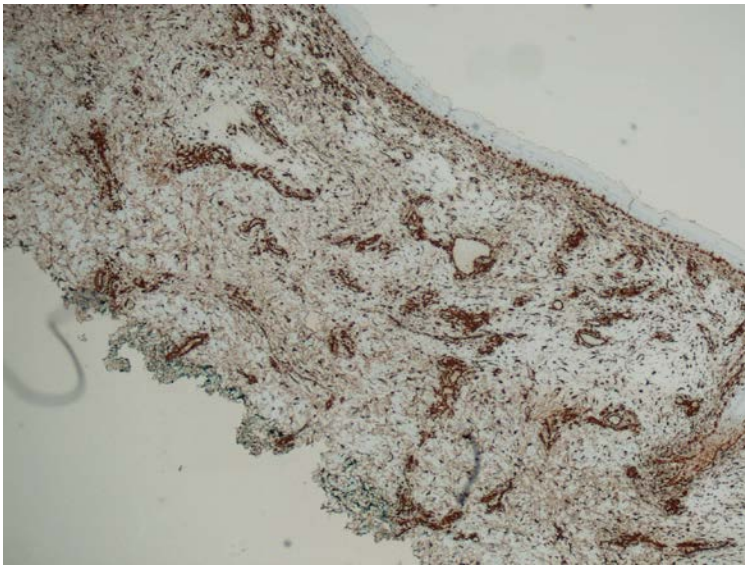
**Figure 2.** Superficial angiomyxoma dermoscopy demonstrates the red, globules with faint arborizing vasculature



**Figure 3.** Photograph of blood moon, demonstrates the “red planet” sign similarities with adjacent dermoscopy photograph. Used with permission from NASA, accessed on 13 May 2014 at [http://www.nasa.gov/vision/universe/watchtheskies/13oct\\_lunareclipse.html](http://www.nasa.gov/vision/universe/watchtheskies/13oct_lunareclipse.html).



**Figure 4.** Superficial angiomyxoma, hematoxylin and eosin, 4x involving the dermis, demonstrates spindle-shaped and stellate cells within a vascular, myxoid stroma. **Figure 5.** Superficial angiomyxoma, hematoxylin and eosin, 20x involving the dermis, demonstrates spindle-shaped and stellate cells within a vascular, myxoid stroma.



**Figure 6.** Superficial angiomyxoma with positive vimentin stain **Figure 7.** Superficial angiomyxoma with negative S100 stain

## Discussion

Superficial angiomyxomas are an uncommon, but are a distinctive type of mesenchymal tumor. They are benign cutaneous tumors that recur locally in 20 – 40% of cases after excision or biopsy, but they are not known to metastasize [1,2]. Cases have been reported of superficial angiomyxomas occurring on the head, neck, oral cavity mucosa, external genitalia, trunk, lower extremities, and subungual location [1,2,3]. Clinically, they usually present as red papules to nodules with multilobular projections. Superficial angiomyxomas have a peak incidence in the third and fourth decades of life with slight male predominance [1,2,3]. These tumors have been rarely associated with the Carney complex (skin and cardiac myxomas, lentiginos, endocrine overactivity, and endocrine tumors), which is also known as NAME syndrome (nevi, atrial myxoma, myxoid neurofibroma and ephelides) or LAMB syndrome (mucocutaneous lentiginos, atrial myxomas, mucocutaneous myxomas, and blue nevi) [3]. Our patient had no other clinical features suggestive of Carney complex.

The histologic diagnosis of a superficial angiomyxoma classically demonstrates a lesion that is well-circumscribed, rich in vascular structures, with a mucoid matrix containing an inflammatory cell infiltrate [3,4,5]. Immunohistochemical staining of

superficial angiomyxomas is typically positive for vimentin, may or may not be positive for CD 34, and is negative for S-100 [3,4,5]. The histopathologic differential diagnosis for superficial angiomyxoma includes myxoid neurofibroma, myxoid cyst, superficial fibromyxoma, sarcoma, and cutaneous mucinosis [3,4]. Distinguishing between these entities can be improved by the differences in characteristic immunohistochemical staining. Specific to this case, the first biopsy taken in 2009 was interpreted as cutaneous mucinosis, which characteristically has upper dermis focal mucin deposition and spindle-shaped fibroblasts but lacks the vascular structures, inflammatory cells, and lobular arrangement seen in superficial angiomyxomas [3]. Although the biopsy from 2013 was initially interpreted as cutaneous mucinosis, this pathology report was subsequently amended and the lesion depicted in this case was recognized as an angiomyxoma on departmental review. The prior biopsy specimen from 2009 was done at a different medical center and was not available for our review.

Although this case demonstrates classic clinical and histologic findings of an angiomyxoma, extensive review of the literature did not reveal any previously published dermatoscopic descriptions or photographs. Dermoscopic images demonstrated in this case will help facilitate the diagnosis of superficial angiomyxomas for other clinical dermatologists by providing them with a corollary memorable image of a celestial body. We propose to call this the “red planet sign” for a superficial angiomyxoma on dermoscopic examination.

## References

1. S V R, Raju MS, J D S, Taneja N, Chandra S, Mahajan S, Panwar E. Intraoral Superficial Angiomyxoma of the Upper Alveolus: Report of a Unique Case. *Case Rep Med.* 2012;Article ID 859021, 3 pages.
2. Ali N, Child CS, Michaelides M, Olver JM. Recurrence of a rare skin tumour: superficial angiomyxoma in the eyelid. *Can J Ophthalmol.* 2011;46:205-6.
3. Falidas E, Rallis E, Vlachos C, Konstantoudakis S, Villias C. Superficial Subungual Angiomyxoma: Case Report and Review of the Literature. *J Cutan Med Surg.* 2011 May-Jun;15(3):180-2.
4. Sibley CD, Brown HA, Harrop AR, Haber RM. Exophytic nodule on the scalp. Superficial Angiomyxoma. *JAMA Dermatol.* 2013 Jun; 149(6):751-6.
5. Weedon D, Strutton G, and Rubin A. *Weedon's Skin Pathology.* 3rd ed. London: Churchill Livingstone Elsevier, 2010.