

UC San Diego

UC San Diego Previously Published Works

Title

Alternative Access in Congenital Heart Disease

Permalink

<https://escholarship.org/uc/item/5th800hm>

Journal

JACC Case Reports, 2(11)

ISSN

2666-0849

Authors

Heyden, Caitlin M

Moore, John W

Ryan, Justin R

et al.

Publication Date

2020-09-01

DOI

10.1016/j.jaccas.2020.07.040

Peer reviewed



HHS Public Access

Author manuscript

JACC Case Rep. Author manuscript; available in PMC 2021 March 01.

Published in final edited form as:

JACC Case Rep. 2020 September ; 2(11): 1734–1735.

Alternative Access in Congenital Heart Disease

Caitlin M. Heyden, DO^a, John W. Moore, MD^a, Justin R. Ryan, PhD^a, Robert J. Lederman, MD^b, Howaida G. El-Said, MD^a, Kanishka Ratnayaka, MD^a

^aDepartment of Cardiology, Rady Children's Hospital, San Diego, California ^bCardiovascular and Pulmonary Branch, Division of Intramural Research, National Heart, Lung, and Blood Institute, Bethesda, Maryland.

Abstract

Limited arterial vascular access precluded necessary transcatheter intervention in a 22-year-old woman with repaired interrupted aortic arch type B. Alternative transcaval vascular access enabled percutaneous therapy. This practice evolution is likely to benefit the growing numbers of adults with congenital heart disease. (**Level of Difficulty: Advanced.**)

Keywords

adult congenital heart disease; congenital heart disease; endovascular; transcatheter electrosurgery; transcaval access

Caval-aortic or transcaval access is performed for adults with limited transfemoral artery vascular options (1,2), and it should be considered for comparable patients with adult congenital heart disease (ACHD). A 22-year-old woman with ACHD characterized by interrupted aortic arch type B was originally managed with a surgical 10-mm aortic isthmus jump graft and a subsequent surgical 16-mm Gore-Tex (W.L. Gore and Associates, Newark, Delaware) ascending-to-descending aorta bypass graft. She developed a compressive seroma around the 16-mm graft that prompted consideration for transcatheter management. Femoral artery access for transcatheter endograft was aborted because the required 16-F sheath could not traverse 3.9-mm and 1.5-mm vessels; the subclavian arteries were occluded. Patients with ACHD who present again decades after initial palliation may require unique management solutions, including establishment of sufficient vascular access to permit transcatheter therapy.

This is an open access article under the CC BY-NC-ND license (<http://creativecommons.org/licenses/by-nc-nd/4.0/>).

ADDRESS FOR CORRESPONDENCE: Dr. Kanishka Ratnayaka, Department of Cardiology, Rady Children's Hospital, 3020 Children's Way, MC 5004, San Diego, California 92123. kratnayaka@rchsd.org.

The authors have reported that they have no relationships relevant to the contents of this paper to disclose.

The authors attest they are in compliance with human studies committees and animal welfare regulations of the authors' institutions and Food and Drug Administration guidelines, including patient consent where appropriate. For more information, visit the *JACC: Case Reports* author instructions page.

APPENDIX For supplemental videos, please see the online version of this paper.

We pursued alternative transcaval vascular access (Figures 1A to 1F). Pre-procedural comprehensive advanced imaging (including peripheral access vessels) for pediatric patients with congenital heart disease is not systematic. As our case illustrates, it should be common practice in patients with ACHD and was performed before the subsequent transcaval procedure.

As previously described, transcatheter electrosurgery with an electrified 0.014-inch guidewire (Astato XS 20, Asahi, Tustin, California) supported in a NaviCross catheter (Terumo, Somerset, New Jersey) and a 6-F IM guide catheter (Cordis, Santa Clara California) was performed to cross from the vena cava to the aorta (2). Subsequent standard transcaval access enabled introduction of a 20-F aortic sheath (Gore DrySeal Flex, Gore) (1,2). Although pre-procedure cardiac computed tomography (CT) overlay is not required, we find it helpful for intraprocedural transcaval access. A thoracic endovascular graft (24 mm × 105 mm; Zenith Alpha Thoracic Endovascular Graft, Cook Medical, Bloomington, Indiana) followed by a bare-metal stent (36 mm; IntraStent Max LD, Covidien, Plymouth, Minnesota) excluded the extravascular communication and eliminated compressive obstruction. A ductal occluder (Amplatzer Duct Occluder 8 to 6 mm, Abbott, Abbott Park, Illinois) closed the tract post-intervention. Post-tract closure angiography demonstrated hemodynamically insignificant type 1 (tubular aortocaval fistula) closure (1). Balloon tamponade and covered stent options were available if required. In our initial experience, conservative follow-up imaging was performed the following day, at 1 month, and then at 6 months post-procedure. The fistula was occluded at 6 months by contrast-enhanced CT (Video 1).

Supplementary Material

Refer to Web version on PubMed Central for supplementary material.

ABBREVIATIONS AND ACRONYMS

ACHD	adult congenital heart disease
CT	computed tomography

REFERENCES

1. Greenbaum AB, Babaliaros VC, Chen MY, et al. Transcaval access and closure for transcatheter aortic valve replacement: a prospective investigation. *J Am Coll Cardiol* 2017;69:511–21. [PubMed: 27989885]
2. Lederman RJ, Babaliaros VC, Greenbaum AB. How to perform transcaval access and closure for transcatheter aortic valve implantation. *Catheter Cardiovasc Interv* 2015;86:1242–54. [PubMed: 26356244]

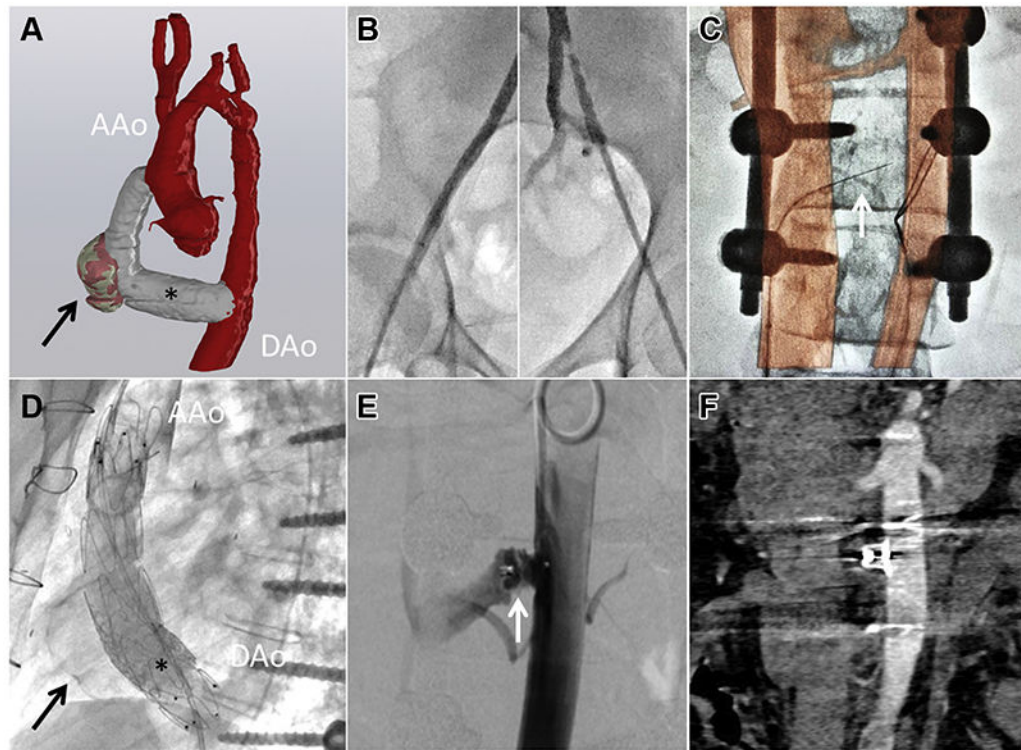


FIGURE 1. Transcaval Access for Transcatheter Congenital Heart Disease Intervention
(A) Pre-procedure cardiac computed tomography reconstruction demonstrates a compressive seroma (**arrow**) around a previous surgical Gore-Tex (W.L. Gore and Associates, Newark, Delaware) aortic arch bypass graft (**asterisk**) from the ascending aorta (AAo) to the descending aorta (DAo). **(B)** Limited femoral artery vascular access prompted **(C)** transcaval access with the snare in the descending aorta and wire crossing (**arrow**), including computed tomography overlay. **(D)** Post-endograft exclusion (**arrow**) and bypass graft dilation (**asterisk**) and **(E)** standard transcaval closure were performed (arrow). **(F)** At 6-month follow-up abdominal computed tomography (no residual fistula) is shown.