

# UC Davis

## Dermatology Online Journal

### Title

Milia-like calcinosis cutis in Down syndrome: a new case with a review of the literature

### Permalink

<https://escholarship.org/uc/item/5s61z4v2>

### Journal

Dermatology Online Journal, 27(8)

### Authors

Moar, Agata  
Maurelli, Martina  
Colato, Chiara  
et al.

### Publication Date

2021

### DOI

10.5070/D327854695

### Copyright Information

Copyright 2021 by the author(s). This work is made available under the terms of a Creative Commons Attribution-NonCommercial-NoDerivatives License, available at <https://creativecommons.org/licenses/by-nc-nd/4.0/>

Peer reviewed

# Milia-like calcinosis cutis in Down syndrome: a new case with a review of the literature

Agata Moar<sup>1</sup>, Martina Maurelli<sup>1</sup>, Chiara Colato<sup>2</sup>, Donatella Schena<sup>1</sup>, Giampiero Girolomoni<sup>1</sup>

Affiliations: <sup>1</sup>Section of Dermatology and Venereology, Department of Medicine, University of Verona, Verona, Italy, <sup>2</sup>Section of Pathology, Department of Diagnostics and Public Health, University of Verona, Verona, Italy

Corresponding Author: Agata Moar, Section of Dermatology and Venereology, Department of Medicine, University of Verona, Piazzale A Stefani 1, 37126 Verona, Italy, E-mail: [agata.moar@hotmail.it](mailto:agata.moar@hotmail.it)

## Abstract

We report an 11-year-old girl who presented with white papules on the dorsal and palmar region of the hands bilaterally. The parents reported that the lesions had appeared four months before and some had resolved spontaneously. The girl was suffering from celiac disease, Down syndrome, and alopecia areata treated with topical corticosteroids. At the first visit, the girl presented with alopecia areata, corticosteroid acne, and a dozen white papules located on the hands. On dermoscopy, a whitish structureless area was seen. Histological examination showed the presence of calcium deposits without tissue damage, thus confirming the diagnosis of milia-like idiopathic calcinosis cutis. At 6-month follow up, the lesions had completely disappeared. Milia-like idiopathic calcinosis cutis is a benign cutaneous disorder consisting of calcium deposits in an apparently undamaged dermis and is typically associated with Down syndrome. Up to a quarter of patients have coexisting syringomas. The milia-like papules tend to self-resolve as patients reach adulthood, so a wait-and-see approach is recommended.

*Keywords: calcinosis, cutis, milia-like, Down syndrome*

## Introduction

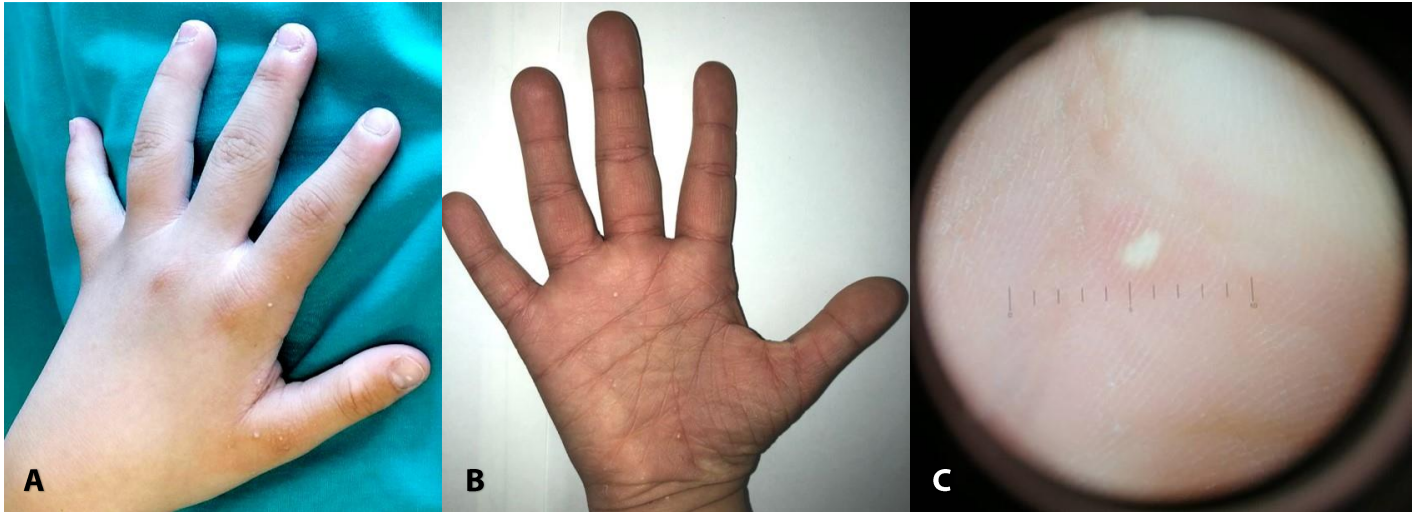
Patients with Down syndrome may present with various dermatologic manifestations, including alopecia areata, atopic dermatitis, single transverse palmar crease, scrotal tongue or macroglossia, and xerosis. A much more uncommon finding is milia-like

calcinosis cutis, [1,2]. Milia-like idiopathic calcinosis cutis is a benign disorder characterized by the presence of multiple, small, white papules usually localized to the hands and feet. It was first described by Sano et al. in 1978 in a patient affected by Down syndrome [3] and termed milia-like calcinosis cutis by Smith in 1989 [4]. Herein, we report an additional patient with milia-like calcinosis cutis and Down syndrome and review all the published cases.

## Case Synopsis

An 11-year-old girl presented because of the appearance of a dozen white papules localized on the dorsal and palmar surface of the hands of four months duration (**Figure 1A, B**). The mother reported the spontaneous resolution of some of the papules after the application of emollients. The girl was suffering from Down syndrome, alopecia areata, and celiac disease. She underwent adeno-tonsillectomy at the age of eight years. She had no cardiopathy or other major comorbidities of Down syndrome. Routine laboratory investigations, including blood cell count, kidney and liver function tests, glucose, and calcium and phosphate serum levels were within the normal range. No morphological alterations were found in thyroid ultrasound.

At the initial visit the patient also presented with corticosteroid-induced acne on the forehead, caused by the topical corticosteroid treatment of alopecia areata, palpebral milia on the upper eyelids, and 13 painful white papules not surrounded by erythema,



**Figure 1.** **A)** Dorsal and **B)** palmar white papules on the hands in a 11-year-old girl; **C)** homogeneous, round, smooth, symmetric white papule on dermoscopy.

1-3mm in size bilaterally distributed on the hands on both the dorsal and palmar aspects. Dermoscopy revealed homogeneous, round, smooth, symmetric white lesions (**Figure 1C**).

Histological examination of one papule showed a subepidermal well-circumscribed, oval calcified nodule, surrounded by a strip of fibrous tissue and a focal collection of CD68+ macrophages (**Figure 2**). Epidermis and dermis were otherwise unremarkable.

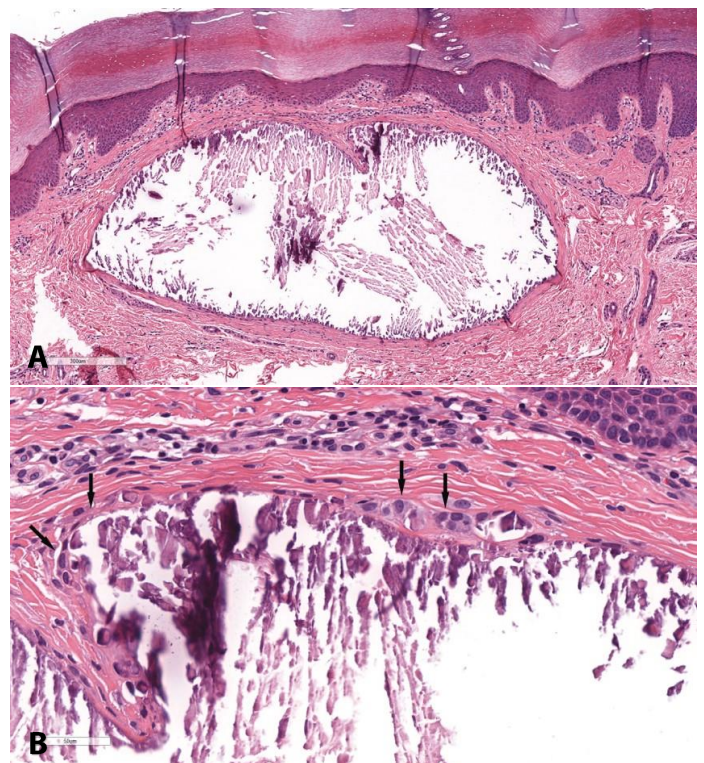
Daily application of emollients was recommended. At a 6-month follow-up, the previous lesions had spontaneously self-healed, while some new ones had appeared.

## Case Discussion

Cutaneous calcinosis is classified into dystrophic, metastatic, idiopathic, iatrogenic and calciphylactic forms [5]. Unlike dystrophic and metastatic calcification or calciphylaxis, milia-like calcinosis cutis is characterized by a deposition of calcium without tissue damage and by normal serum values of calcium and phosphates [5-7]. The etiopathogenesis is not known but it seems that repeated trauma may be a trigger for the appearance of calcinosis. Moreover, it has been speculated that an excessive concentration of calcium in the sweat glands may be one of the causes, but it has never been demonstrated [7]. Although cases of healthy

children with milia-like calcinosis cutis have been described [8-14], many cases of milia-like calcinosis cutis have been reported in association with Down syndrome [15-20].

A total of 33 reports were screened and included, using the terms "milia," "milia-like," "calcinosis,"



**Figure 2.** H&E histopathology; **A)** subepidermal well-circumscribed, oval calcified nodule, surrounded by a strip of fibrous tissue, 80 $\times$ ; **B)** with a focal collection of CD68+ macrophages indicated by arrows, 400 $\times$ .

“calcinosis cutis,” and/or “Down’s syndrome.” Since the first description in 1978, milia-like calcinosis cutis has been described in 15 healthy patients and 20 patients with Down syndrome (**Table 1**). The disease occurred in both sexes equally and mainly during childhood. Thus far, at least four cases have been described in adult patients [21-23]. Disease duration ranges from one month to nine years, with a median of 18 months.

Different skin areas may be affected, but most cases involve the hands and feet, both on the dorsal and palmo-plantar surfaces. Milia-like idiopathic calcinosis cutis clinically presents with white papules that may or may not be surrounded by an erythematous halo; some may even perforate by trans-epidemic calcium elimination [24-27]. Dermoscopically, the lesions appear as homogeneous white pattern in non-polarized light

**Table 1.** Milia-like calcinosis cutis: published cases 1978-2021.

| Case | Gender/age | Down syndrome | Localization                                  | Presence of Syringomas | Reference |
|------|------------|---------------|---|------------------------|-----------|
| 1    | M/0.5      | -             | Arms, legs                                    | -                      | [31]      |
| 2    | M/1.6      | -             | Feet  | -                      | [12]      |
| 3    | M/2        | -             | Sole  | -                      | [9]       |
| 4    | M/5        | -             | Forearms, knees, lower extremities            | -                      | [6]       |
| 5    | M/6        | +             | Hand, elbows, knees, legs, feet, face, wrists | -                      | [4]       |
| 6    | M/7        | +             | Face, trunk, buttocks, pubic area             | -                      | [29]      |
| 7    | M/8        | +             | Hands   | -                      | [28]      |
| 8    | M/10       | -             | Thighs, scrotum, foreskin                     | -                      | [8]       |
| 9    | M/10       | +             | Hand, feet                                    | PLS                    | [34]      |
| 10   | M/11       | +             | Hands, toe                                    | PLS                    | [34]      |
| 11   | M/11       | +             | Hands   | -                      | [17]      |
| 12   | M/12       | +             | Palms, soles                                  | -                      | [15]      |
| 13   | M/12       | +             | Hands, forearms, thighs, neck, face           | PS/PLS                 | [24]      |
| 14   | M/14       | -             | Hands, elbows, lips, knees                    | -                      | [10]      |
| 15   | M/19       | +             | Hands   | PS                     | [3]       |
| 16   | M/48       | -             | Forehead                                      | -                      | [23]      |
| 17   | F/0.5      | -             | Hands, feet, knees                            | -                      | [11]      |
| 18   | F/4        | +             | Hands, wrists                                 | PS                     | [20]      |
| 19   | F/5        | -             | Chin, neck, trunk, extremities                | *                      | [36]      |
| 20   | F/5        | -             | Thigh   | -                      | [13]      |
| 21   | F/5        | +             | Face, extremities                             | -                      | [19]      |
| 22   | F/6        | +             | Hand, feet, face                              | -                      | [7]       |
| 23   | F/6        | +             | Hands, feet                                   | PS                     | [33]      |
| 24   | F/6        | +             | Hands   | -                      | [26]      |
| 25   | F/7        | +             | Hands, feet                                   | -                      | [16]      |
| 26   | F/7        | -             | -   | -                      | [32]      |
| 27   | F/7        | +             | Hands   | -                      | [18]      |
| 28   | F/8        | +             | Hands, toe                                    | -                      | [22]      |
| 29   | F/8        | -             | Eyelids, hands                                | -                      | [37]      |
| 30   | F/11       | -             | Pubis   | -                      | [8]       |
| 31   | F/11       | +             | Hands, feet                                   | PS                     | [25]      |
| 32   | F/11       | +             | Face, neck, hands, knees                      | S*                     | [30]      |
| 33   | F/15       | +             | Hands, wrist                                  | -                      | [27]      |
| 34   | F/21       | -             | Hands   | -                      | [14]      |
| 35   | F/69       | -             | Face  | -                      | [21]      |
| 36   | F/11       | +             | Hands   | -                      | Our case  |

F, female; M, male; PLS, perilesional syringomas; PS, palpebral syringomas; S\*, plaque-type jaw syringoma; \*subsequently developed multiple diffuse syringomas on legs, chest and abdomen.



and as a petaloid pattern in polarized light [22,28,29]. Histology shows a well-defined accumulation of dense, basophilic, Von Kossa positive material in the papillary dermis, surrounded by thick collagen fibers and sometimes histiocytes [10,30]. The differential diagnosis may include molluscum contagiosum, warts, milia, xanthomas, and epidermal inclusion cysts.

Milia-like idiopathic calcinosis cutis tends to disappear spontaneously in adulthood [7,22]. A wait and see approach is recommended given the benignity of milia-like calcinosis cutis, the tendency for spontaneous self-resolution in many cases, and the absence of painful or itchy symptoms. Furthermore, it is unnecessary to perform invasive or aggressive treatments that may lead to side effects, require anesthesia, or promote scarring [28,31]. Some authors have described cases of calcinosis cutis treated with topical tretinoin with some benefit [32]. Aristizabal et al. have successfully treated an adult patient affected by forehead milia-like calcinosis cutis with the CO<sub>2</sub> laser [23].

In eight out of thirty-six cases, syringomas have also been described. In particular, four patients had palpebral syringomas, two perilesional syringomas, one both palpebral and perilesional syringomas, and one plaque-type jaw syringoma [3,20,24,25,30,33,34]. To date, the association between milia-like calcinosis cutis and syringomas is still unclear, and syringomas concomitant with milia-like calcinosis cutis have only been described in Down syndrome patients.

Only one case of multiple syringomas developing eight years after milia-like calcinosis cutis has been

described in a non-Down syndrome child [35]. Given the high frequency of syringomas in Down syndrome patients, it is difficult to establish whether there is a causal link between milia-like calcinosis cutis and syringomas or whether they are two different manifestations that may frequently coexist in Down syndrome patients [10]. No cases of simultaneous celiac disease, Down syndrome, and alopecia areata, as in our case, have been previously described.

## Conclusion

Milia-like idiopathic calcinosis cutis might be more common than previously believed. The strong association with Down syndrome calls for an accurate skin examination, including hands and feet, in all children with Down syndrome. Milia-like idiopathic calcinosis cutis is a benign skin condition that is important to recognize as the appearance of the lesions may be of concern to the patient or parents. It is therefore important to be able to reassure them. Given its tendency to self-resolution, a wait-and-see approach is recommended to avoid unnecessary treatment that could lead to scarring.

## Potential conflicts of interest

The authors declare no conflicts of interest.

**Acknowledgements:** We thank Dr. Davide Geat for English revision of the manuscript.

## References

1. Madan V, Williams J, Lear JT. Dermatological manifestations of Down's syndrome. *Clin Exp Dermatol*. 2006;31:623-9. [PMID: 16901300].
2. Sureshbabu R, Kumari R, Ranugha S, et al. Phenotypic and dermatological manifestations in Down syndrome. *Dermatol Online J*. 2011;17:3. [PMID: 21382286].
3. Sano T, Tate S, Ishikawa C. A case of Down's syndrome associated with syringoma, milia, and subepidermal nodule. *Jpn J Dermatol*. 1978;88:740.
4. Smith ML, Golitz LE, Morelli JG, Weston WL. Milia like idiopathic calcinosis cutis in Down's syndrome. *Arch Dermatol*. 1989;125:1586-7. [PMID: 2530938].
5. Jiménez-Gallo D, Ossorio-García L, Linares-Barrios M. Calcinosis Cutis and Calciophylaxis. *Actas Dermosifiliogr*. 2015;106:785-94. [PMID: 26394755].
6. Niu DM, Lin SY, Li MJ, et al. Idiopathic calcinosis cutis in a child: chemical composition of the calcified deposits. *Dermatology*. 2011;222:201-5. [PMID: 21540566].
7. Solak B, Kara RO, Vargol E. Milia-like calcinosis cutis in a girl with Down's syndrome. *An Bras Dermatol*. 2016;91:655-7. [PMID: 27828644].
8. Eng AM, Mandrea E. Perforating calcinosis cutis presenting as milia. *J Cutan Pathol*. 1981; 8:247-50. [PMID: 7309938].
9. Kim DH, Kang H, Cho SH, Park YM. Solitary milialike idiopathic calcinosis cutis unassociated with Down's syndrome: two case reports. *Acta Derm Venereol*. 2000;80:151-2. [PMID: 10877144].
10. Bécuwe C, Roth B, Villedieu MH, et al. Milia-like idiopathic calcinosis cutis. *Pediatr Dermatol*. 2004;21:483-5. [PMID:

- 15283797].
11. Menni S, Gualandri L, Boccardi D. Youngest case of idiopathic calcinosis cutis not associated with Down syndrome. *Int J Dermatol*. 2008;47:870-1. [PMID: 18717878].
  12. Jang EJ, Lee JY, Yoon TY. Milia-like idiopathic calcinosis cutis occurring in a toddler born as a premature baby. *Ann Dermatol*. 2011;23:490-2. [PMID: 22148017].
  13. Conti R, Arunachalam M, Colucci R, et al. Milia-like idiopathic calcinosis cutis in the absence of Down's syndrome. *G Ital Dermatol Venereol*. 2014;149:276-8. [PMID: 24819651].
  14. Lee DW, Yoon DH, Lee YS, Shim SI, Cho BK. Solitary milialike idiopathic calcinosis cutis: a case unassociated with Down's syndrome. *J Dermatol*. 1996;23:53-5. [PMID: 8720259].
  15. Shibuya M, Lizuka H, Ohkawara A, Kishiyama K. A case of calcinosis cutis in Down's syndrome. *Hifurinsho*. 1985;27:1218-9.
  16. Sais G, Jucglà A, Moreno A, Peyrí J. Milia-like idiopathic calcinosis cutis and multiple connective tissue nevi in a patient with Down's syndrome. *J Am Acad Dermatol*. 1995;32:129-30. [PMID: 7822505].
  17. Schepis C, Siragusa M, Alberti A. Milia-like idiopathic calcinosis cutis. *Eur J Dermatol*. 2000;10:637-8. [PMID: 11125332].
  18. Kotsuji T, Imakado S, Iwasaki N, Fujisawa H, Otsuka F. Milia-like idiopathic calcinosis cutis in a patient with translocation Down's syndrome. *J Am Acad Dermatol*. 2001;45:152-3. [PMID: 11423857].
  19. Kumar P, Savant SS, Nimisha E, Das A, Debbarman P. Milia-like idiopathic calcinosis cutis in a child with Down syndrome. *Dermatol Online J*. 2016;22:13030/qt7080c5gs. [PMID: 27617523].
  20. Turan E, Yurt N, Yeşilova Y, Tanrıku O. A rare association in Down's syndrome: milialike idiopathic calcinosis cutis and palpebral syringoma. *Cutis*. 2016;98:E22-3. [PMID: 28099543].
  21. Houtappel M, Leguit R, Sigurdsson V. Milia-like idiopathic calcinosis cutis in an adult without Down's syndrome. *J Dermatol Case Rep*. 2007;1:16-9. [PMID: 21886700].
  22. Fox GN, Mehregan DA, Jablonowski MN. Acral milia-like idiopathic calcinosis cutis in a child with Down's syndrome: report of a case, review of the literature, and description of dermoscopic findings. *Pediatr Dermatol*. 2013;30:263-4. [PMID: 22276686].
  23. Aristizabal M, Aristizabal J, Giraldo D, Loboguerrero O, Gold MH. Milia-like idiopathic calcinosis cutis of the forehead in an adult without Down's syndrome successfully treated with a CO(2) laser. *J Cosmet Dermatol*. 2020;19:102-4. [PMID: 31782594].
  24. Maroon M, Tyler W, Marks VJ. Calcinosis cutis associated with syringomas: a transepidermal elimination disorder in a patient with Down's syndrome. *J Am Acad Dermatol*. 1990;23:372-5. [PMID: 2144304].
  25. Schepis C, Siragusa M, Palazzo R, Batolo D, Romano C. Perforating milia-like idiopathic calcinosis cutis and periorbital syringomas in a girl with Down's syndrome. *Pediatric Dermatol*. 1994;11:258-60. [PMID: 7971561].
  26. Patrizi A, Neri I, Raone B, Passarini B. Calcinose miliaire idiopathique perforante des extrémités chez une malade trisomique 21. *Ann Dermatol Venereol*. 1997;124:162-4. [PMID: 9740828].
  27. Delaporte E, Gosselin P, Catteau B, et al. Calcinose miliaire idiopathique perforante des extrémités chez une malade trisomique 21. *Ann Dermatol Venereol*. 1997;124:159-61. [PMID: 9740827].
  28. Kawaguchi M, Suzuki T. Dermoscopy is useful for the diagnosis of milia-like idiopathic calcinosis cutis. *Australas J Dermatol*. 2018;59:63-4. [PMID: 28726314].
  29. Ghiasi M, Ghanadan A, Kalantari Y, Mahmoudi H, Etesami I. Generalized milia-like calcinosis cutis in a child with Down syndrome: dermoscopic features. *Dermatol Online J*. 2021;27:13030. [PMID: 33818994].
  30. Motegi SI, Sekiguchi A, Fujiwara C, Yamazaki S, Ishikawa O. Milia-like idiopathic calcinosis cutis and plaque-type syringoma in a girl with Down's syndrome. *J Dermatol*. 2019;46:e136-7. [PMID: 30194873].
  31. Grazzini M, Bassi A, Mazzatenta C. Milia-like idiopathic calcinosis cutis: when waiting is the best option. *J Pediatr*. 2020;224:173-4. [PMID: 32437759].
  32. Choi WJ, Jung SJ, Seo YJ, Park EJ, Jo HJ, Kim Kyu Han, Kim KJ. A case of milia-like idiopathic calcinosis cutis that improved with tretinoin cream. *Korean J Dermatol*. 2008;46:1640-3.
  33. Kanzaki T, Nakajima M. Milia like idiopathic calcinosis cutis and syringoma in Down's syndrome. *J Dermatol*. 1991;18:616-8. [PMID: 1838753].
  34. Schepis C, Siragusa M, Palazzo R, Batolo D, Romano C. Milia-like idiopathic calcinosis cutis: an unusual dermatosis associated with Down's syndrome. *Br J Dermatol*. 1996;134:143-6. [PMID: 8745902].
  35. Berk DR, Lu D, Lind AC, Bayliss SJ. Subsequent development of syringomas in a patient with milialike idiopathic calcinosis and without down syndrome. *Arch Dermatol*. 2010;146:680-1. [PMID: 20566940].
  36. Mehta JN, Berk DR, Hanson SG, Lind AC, Mallory SB. Generalized milia-like idiopathic calcinosis cutis. *Arch Dermatol*. 2006;142:1238-9. [PMID: 16983022].
  37. Smets G, De Coninck A, Hillary T. White papules on the eyelids and dorsa of the hands in an 8-year-old Ethiopian girl. *J Dtsch Dermatol Ges*. 2019;17:340-341. [PMID: 30821408].