

UC Irvine

UC Irvine Previously Published Works

Title

Preoperative Transcatheter Closure of Congenital Muscular Ventricular Septal Defects

Permalink

<https://escholarship.org/uc/item/5rx3n2r2>

Journal

New England Journal of Medicine, 324(19)

ISSN

0028-4793

Authors

Bridges, Nancy D

Perry, Stanton B

Keane, John F

et al.

Publication Date

1991-05-09

DOI

10.1056/nejm199105093241903

Copyright Information

This work is made available under the terms of a Creative Commons Attribution License, available at <https://creativecommons.org/licenses/by/4.0/>

Peer reviewed

PREOPERATIVE TRANSCATHETER CLOSURE OF CONGENITAL MUSCULAR VENTRICULAR SEPTAL DEFECTS

NANCY D. BRIDGES, M.D., STANTON B. PERRY, M.D., JOHN F. KEANE, M.D.,
STEVEN A.N. GOLDSTEIN, M.D., PH.D., VALERIE MANDELL, M.D., JOHN E. MAYER, JR., M.D.,
RICHARD A. JONAS, M.D., ALDO R. CASTENEDA, M.D., AND JAMES E. LOCK, M.D.

Abstract Background. Surgical repair of muscular ventricular septal defects, particularly those associated with complex heart lesions, carries a higher risk of reoperation and death than the repair of membranous defects. Closing a muscular defect through an incision in the systemic ventricle may cause late ventricular dysfunction. In a collaborative approach to this problem, we undertook preoperative transcatheter closure of muscular ventricular septal defects remote from the atrioventricular and semilunar valves, followed by the surgical repair of associated conditions.

Methods. In 12 patients selected jointly by a cardiologist and a cardiac surgeon, we attempted preoperative transcatheter umbrella closure of 21 defects. Half the patients had associated complex heart lesions; the others had had pulmonary-artery banding to reduce the amount

of left-to-right shunting. Half had severe ventricular septal deficiency.

Results. All 21 defects were successfully closed without major complications. Subsequent cardiac surgery for associated conditions in 11 of the 12 patients resulted in a mean pulmonary-to-systemic flow ratio of 1.1, indicating minimal residual left-to-right shunting; 1 patient awaited surgical repair. No deaths, reoperations, or late complications have occurred after a follow-up of 7 to 20 months.

Conclusions. A collaborative approach using transcatheter closure followed by the surgical repair of associated cardiac lesions may decrease rates of operative mortality, reoperation, and left ventricular dysfunction in patients with muscular ventricular septal defects. (N Engl J Med 1991; 324:1312-7.)

THE identification and surgical closure of muscular ventricular septal defects, particularly those that involve the trabeculated portion of the ventricular septum, are known to be difficult.¹⁻⁸ Improved angiographic diagnosis and surgical exposure (often by left ventriculotomy) have contributed to increased survival. Still, rates of reoperation and mortality in the hospital, especially in the setting of complex congenital heart disease, remain higher than for ventricular septal defects that are nearer to the atrioventricular or semilunar valves.⁵⁻⁸ Death is most often attributed to ventricular dysfunction, possibly due to residual ventricular septal defects, the effects of an incision in the systemic ventricle, or both.^{9,10} Experience with transcatheter closure of postoperative or congenital ventricular septal defects, as well as those occurring after a myocardial infarction, has been reported elsewhere,¹¹ as has experience with analogous heart lesions.¹² On the basis of these considerations, we developed a collaborative approach to the treatment of patients with defects in the apical or anterior muscular ventricular septum, with or without associated complex heart lesions. This approach combines the preoperative closure, performed through the lumen of a catheter, of ventricular septal defects remote from the atrioventricular or semilunar valves,

using a recently described umbrella-like device,^{13,14} with the subsequent surgical repair of associated conditions.

METHODS

Terminology

We have used the terminology of Van Praagh^{15,16} to describe cardiac anatomy.

Population of Patients

This report includes all patients (none of whom have been previously described) who had preoperative transcatheter closure of congenital muscular ventricular septal defects with the Bard Clamshell septal umbrella between June 1989 and July 1990. In each case, preoperative evaluation suggested that surgical closure of one or more of the ventricular septal defects would require an incision in the systemic ventricle. The anticipated difficulty of operative visualization and closure of the ventricular septal defects was also considered in the selection of patients, as was the surgery required for the repair of the associated lesions. Of the 12 patients selected, 6 had a severe septal deficiency, with multiple fenestrations (Fig. 1). Additional complex congenital cardiac lesions were present in 6, and all 12 had had at least one previous cardiac operation. The decision to attempt a transcatheter closure was made jointly by the patients' cardiologists and cardiac surgeons. Not included in this report are patients who had a transcatheter closure of residual postoperative ventricular septal defects, ventricular septal defects after a myocardial infarction, or communications from the left ventricle to the right atrium.

Informed Consent

Informed consent was obtained in all cases, under a protocol approved by the Food and Drug Administration and the clinical-investigation committee of Children's Hospital. The Clamshell septal umbrella is an investigational device; its use is currently limited to centers designated by the FDA.

Transcatheter Closure

The technique of transcatheter closure of ventricular septal defects has been described elsewhere and is shown in Figure 2. An end-

From the Departments of Cardiology (N.D.B., S.B.P., J.F.K., S.A.N.G., J.E.L.), Radiology (V.M.), and Cardiovascular Surgery (J.E.M., R.A.J., A.R.C.), Children's Hospital; and the Departments of Pediatrics (N.D.B., S.B.P., J.F.K., S.A.N.G., J.E.L.), Radiology (V.M.), and Surgery (J.E.M., R.A.J., A.R.C.), Harvard Medical School; both in Boston. Address reprint requests to Dr. Lock at the Cardiology Department, Children's Hospital, 300 Longwood Ave., Boston, MA 02115.

Dr. Lock developed the Clamshell device used in this study in collaboration with the C.R. Bard Corporation and may receive royalties if and when it is approved for marketing.

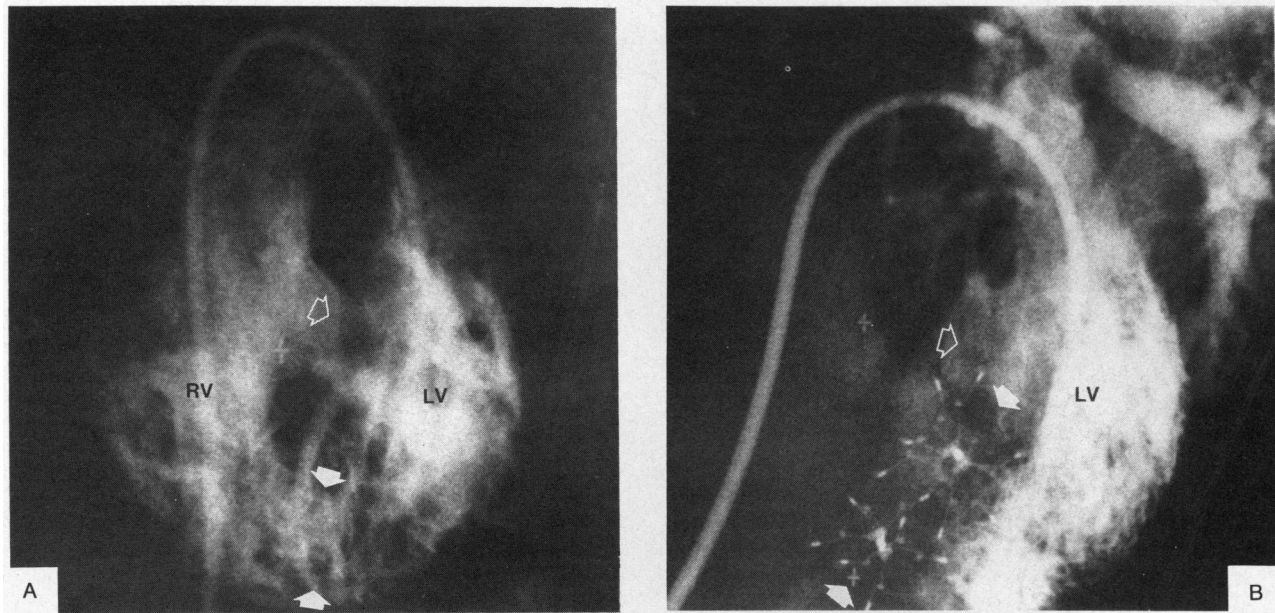


Figure 1. Left Ventricular Angiograms before and after Transcatheter Closure in a Patient with Transposition of the Great Arteries and Multiple Ventricular Septal Defects (Patient 3).

In Panel A, dye injected by a catheter crosses from the left ventricle (LV) to the right ventricle (RV) through a large paramembranous ventricular septal defect (open arrow) and several apical muscular defects (area between the solid arrows). In Panel B, the catheter again crosses an atrial septal defect to enter the left ventricle. The paramembranous defect remains open (open arrow), but the apical defects have been closed with two Clamshell devices (solid arrows). After a third transcatheter closure, this patient had a complete surgical repair involving an arterial-switch operation and closure of the paramembranous ventricular septal defect.

hole balloon catheter is advanced from the femoral vein into the heart, across the atrial septum (either through a naturally occurring atrial septal defect, or through an atrial septal puncture), through the mitral valve, and into the left ventricle. It is then passed through the ventricular septal defect from left to right (Fig. 2A). A guide wire is placed through the catheter and advanced into the right atrium or pulmonary artery; there, it is retrieved with a snare that has been advanced from either the right internal jugular vein or the left femoral vein. Thus, one end of the wire remains outside the body at the right femoral vein, and the other is retrieved and brought outside the body at the left femoral or right internal jugular vein (Fig. 2B). (The femoral venous approach was used for 12 of the defects we studied, most of which were in the anterior muscular septum; for apical defects, the right internal jugular vein was used. The approach that offered the straightest route to the defect was chosen.)

A long 11-French sheath is passed over the wire, across the defect; the guide wire is then removed, and the umbrella device and delivery system are passed through the sheath. Partial withdrawal of the sheath allows the distal umbrella to open in the left ventricle (Fig. 2C). After the position of the device has been adjusted, the sheath is withdrawn further to allow the right ventricular (proximal) umbrella to open (Fig. 2D). If its position is satisfactory, the device is released, and the sheath and delivery system are removed from the body. The size chosen for each umbrella was at least $2\frac{1}{2}$ times the stretched diameter of the ventricular septal defect, with consideration also given to the size of the ventricles and the distance to the atrioventricular and semilunar valves.

At least one ventriculogram and one echocardiogram were obtained for each patient after the placement of the device, to assess its position and the efficacy of closure. All the patients were given low-dose aspirin therapy for six months, and at the time of this writing they continue to receive prophylaxis for bacterial endocarditis during periods of increased risk. None received other forms of anticoagulant therapy.

RESULTS

Data on the patients, including the number and location of the defects closed and the approach used, are given in Table 1. The 12 patients underwent 21 catheterizations with transcatheter closure of ventricular septal defects. The time required for fluoroscopy ranged from 38 to 153 minutes (median, 104). Blood transfusions were given during 11 of the 21 catheterizations. A total of 21 devices were used to close cardiac defects (1 in each of six patients, 2 in each of four patients, 3 in one patient, and 4 in one patient), including 2 devices placed postoperatively to close residual defects (in Patients 10 and 11).

Position of the Device within the Heart

Of the 21 devices, 17 were positioned to straddle the ventricular septum, with four arms in the left ventricle and four arms in the right ventricle. The other four devices were intentionally placed mainly or entirely in the right ventricle, in muscle bundles overlying the defects. In three of the four patients involved, the placement of the device within the right ventricular muscle bundles closed the defect; in the remaining patient, the device straddled the right ventricular muscle bundles but was nonocclusive.

Adequate color flow mapping of the septum was possible in 9 of the 12 patients one to three days after

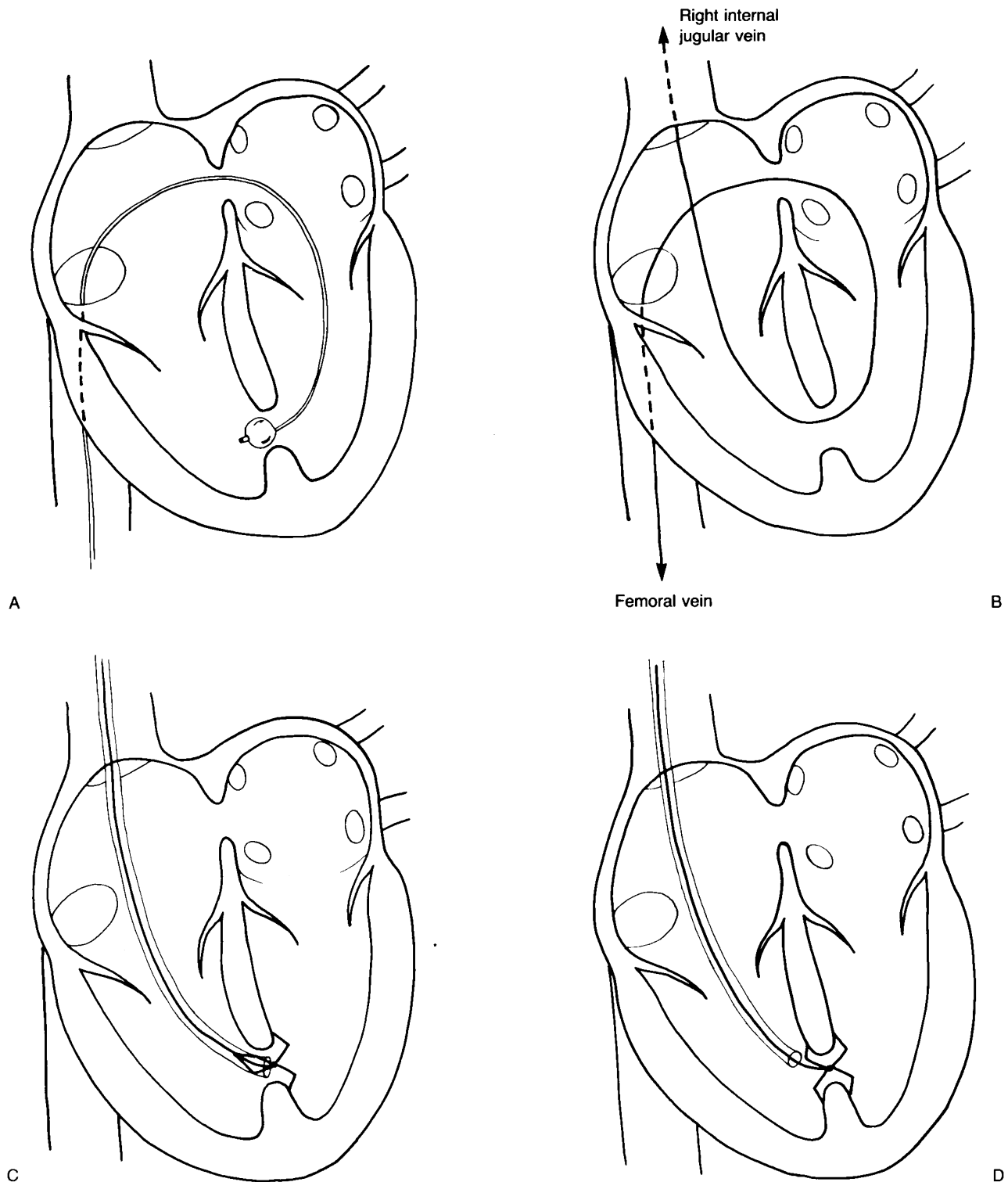


Figure 2. Technique of Transcatheter Closure of a Ventricular Septal Defect.

A venous catheter is advanced across the atrial septum (through either a naturally occurring atrial septal defect or an atrial septal puncture) and into the left ventricle; the ventricular septal defect is then crossed from left to right (Panel A). The end-hole catheter is then used to place a long guide wire (Panel B). In some patients, one end of the wire passes out the right internal jugular vein, as shown; in others, both ends pass out the femoral veins. This wire is used to guide the placement of a long sheath that is used to deliver the Clamshell device (Panel C). The device consists of two umbrellas, connected back to back, each with four arms; for simplicity, only four of the eight arms are shown (Panel D).

Table 1. Diagnosis, Age, and Treatment of the Patients.*

PATIENT NO.	DIAGNOSIS	AGE (YR) AT CATHETERIZATION	PREVIOUS SURGERY	TRANSCATHETER INTERVENTION	SUBSEQUENT SURGERY	FINAL QP:QS RATIO
1	Double-outlet right ventricle {S,D,A}; left juxtaposition of the atrial appendages; ASD secundum; pulmonic stenosis; paramembranous VSD; anterior muscular VSDs	3.1	Modified right Blalock-Taussig shunt (subclavian to pulmonary artery)	Two anterior muscular VSDs closed with 17-mm umbrellas, via the femoral vein	VSD closure; homograft from the right ventricle to the pulmonary artery; ligation and division of shunt	1.0
2	Multiple midmuscular, anterior, and posterior VSDs	3.9	Pulmonary-artery band	Midmuscular VSD closed with a 28-mm umbrella via the right internal jugular vein	Removal of the pulmonary-artery band; pulmonary-artery angioplasty	1.5
3	Transposition of the great arteries {S,D,D}; ASD secundum; multiple midmuscular, anterior, and posterior VSDs	0.9	Pulmonary-artery band	Midmuscular VSD closed with a 23-mm umbrella via the right internal jugular vein; apical VSD closed with a 17-mm umbrella via the right internal jugular vein; anterior VSD closed with a 17-mm umbrella via the femoral vein	Arterial-switch procedure; closure of ASD and posterior VSD	1.1
4	Transposition of the great arteries {S,D,A}; ASD secundum; paramembranous VSD; multiple posterior and anterior VSDs	0.8	Pulmonary-artery band	Posterior muscular VSD closed with a 17-mm umbrella via the femoral vein	Arterial-switch procedure; ASD closure; closure of paramembranous VSD	1.0
5	Double-outlet right ventricle {S,D,D}; malalignment VSD; multiple midmuscular, posterior, and apical VSDs	5.2	Pulmonary-artery band	Apical VSD closed with a 28-mm umbrella via the right internal jugular vein	Closure of the malalignment to the aorta; homograft from the right ventricle to the pulmonary artery	1.2
6	Truncus arteriosus type IA; bilateral-branch pulmonary-artery stenoses; malalignment VSD; apical VSD	6.7	Pulmonary-artery band, modified right Blalock-Taussig shunt	Apical VSD closed with a 23-mm umbrella via the right internal jugular vein	Closure of the malalignment VSD to the truncal valve; pulmonary-artery reconstruction; homograft from the right ventricle to the pulmonary arteries	1.0
7	Transposition of the great arteries {S,L,L}; malalignment VSD; apical VSD	20.4	Pulmonary-artery band, atrial septectomy	Apical VSD closed with a 23-mm umbrella via the right internal jugular vein	Removal of the pulmonary-artery band; pulmonary-artery angioplasty; closure of ASD and subaortic VSD	NA
8	Paramembranous VSD; multiple posterior, anterior, and apical VSDs	6.7	Pulmonary-artery band	Apical VSD closed with a 23-mm umbrella via the right internal jugular vein; anterior VSD closed with a 23-mm umbrella via the femoral vein	Awaiting surgery	0.7
9	Midmuscular VSD; coarctation of the aorta	1.8	Coarctation repair, pulmonary-artery band	Midmuscular VSD closed with a 23-mm umbrella via the femoral vein; balloon dilation of recurrent coarctation	Removal of the pulmonary-artery band	1.0
10	Multiple midmuscular and anterior VSDs; coarctation of the aorta	2.1	Coarctation repair, pulmonary-artery band	Midmuscular VSD closed with a 23-mm umbrella via the right internal jugular vein; after removal of pulmonary-artery band, anterior muscular VSD closed with a 28-mm umbrella via the femoral vein	Removal of the pulmonary-artery band	1.0
11	Multiple anterior VSDs; ASD secundum	4.5	Pulmonary-artery band	Anterior VSDs closed with a 28-mm umbrella via the femoral vein; after removal of pulmonary-artery band additional anterior defects closed with a 28-mm umbrella via the femoral vein	Removal of the pulmonary-artery band	1.2
12	Multiple anterior and apical VSDs	2.5	Pulmonary-artery band	Anterior apical VSDs closed with 23-mm, 28-mm, and 33-mm umbrellas via the femoral vein; inferior apical VSD closed with a 23-mm umbrella via the right internal jugular vein	Patch closure of anterior muscular VSD; removal of pulmonary-artery band	1.1

*Letters in brackets refer to the classification system for segmental anatomy developed by Van Praagh.^{15,16} QP:QS denotes pulmonary-to-systemic flow ratio, ASD atrial septal defect, VSD ventricular septal defect, and NA postoperative oxygen-saturation data not available.

the procedure. All the devices appeared stable. Defect closure was complete according to the results of color flow mapping in two patients, whereas in the remaining patients trivial or small residual flow jets were seen, either through additional muscular holes or along one side of the device or devices.

Clinical Outcome

Of the 12 patients, 1 awaits surgery at the time of this writing, and 11 have undergone successful biventricular surgical repair; in each case, the umbrella devices were left in the heart, and additional lesions were corrected surgically (Table 1). Postoperatively, two patients (Patients 10 and 11) were found to have residual ventricular septal defects remote from the site of the initial umbrella closure. Persistent symptoms of congestive heart failure resulted in the postoperative catheterization and transcatheter closure of these residual defects, which had been identified before surgery but judged insignificant. Catheterization data on these two patients are given in Table 2. After the closure of the residual defects, both patients had a decrease in pulmonary-artery pressure and had symptomatic improvement.

Oxygen-saturation data were available for the estimation of residual shunting in 10 of the 11 patients who underwent surgical repair, including those who had postoperative closure of additional defects, and in the 1 patient who awaits definitive surgery; final pulmonary-to-systemic flow ratios are given in Table 1. Only 1 of these 11 patients had a pulmonary-to-systemic flow ratio higher than 1.2. The remaining patient who underwent surgical repair, in whom oxygen-saturation data were not subsequently available, had no clinical or echocardiographic evidence of a substantial shunt.

The follow-up period after the first transcatheter closure ranged from 7 to 20 months. At this writing all 12 patients are at home and doing well. There have been no device-associated embolizations, strokes, or systemic or pulmonary emboli, and no episodes of endocarditis.

Complications of Transcatheter Closure

In one patient (Patient 5), the initial attempt at transcatheter closure of an apical defect was unsuccessful: six arms of the umbrella device opened in the left ventricle and two in the right ventricle. The device was therefore not released but was withdrawn into the delivery sheath and removed from the body. Transcatheter closure of the same defect was successful the next day. In one patient (Patient 4), one arm of the device entrapped the septal leaflet of the tricuspid valve, resulting in moderate, but well-tolerated, tricuspid insufficiency. In an arterial-switch operation two days later, the arm was lifted from the valve leaflet, leaving the umbrella device in place. Mild but persistent tricuspid insufficiency developed in one other patient after the placement of the device,

Table 2. Measures of Hemodynamics before and after Surgery for Removal of a Pulmonary-Artery Band, in Two Patients with Postoperative Defects Requiring Closure.*

PATIENT NO.	BEFORE FIRST CLOSURE		AFTER FIRST CLOSURE	AFTER BAND REMOVAL, BEFORE SECOND CLOSURE		AFTER SECOND CLOSURE	
	RVp/LVp	QP:QS	QP:QS	RVp/LVp	QP:QS	RVp/LVp	QP:QS
10	1.3	0.7	1.0	0.89	1.5	0.62	1.0
11	1.2	0.8	1.0	0.74	1.3	0.52	1.2

*RVp denotes right ventricular pressure, LVp left ventricular pressure, and QP:QS pulmonary-to-systemic flow ratio.

presumably as a result of manipulation of the catheter; echocardiographic assessment demonstrated that the device itself did not interfere with tricuspid-valve function. Other complications included a small, asymptomatic hemothorax associated with catheter access to the right internal jugular vein (in one patient), stridor after extubation (in one), and a transient palsy of the brachial plexus (in one).

DISCUSSION

Early reports of the treatment and outcome of patients with multiple muscular ventricular septal defects describe the importance of adequate preoperative diagnosis, the difficulty of adequate operative visualization, and the high surgical mortality associated with attempted repair. Before 1970, the reported operative mortality associated with the repair of these defects was 17 to 86 percent.^{1,2} In the decade that followed, improvements in angiocardiology¹⁷⁻¹⁹ and operative exposure^{3,20} contributed to better outcomes. In the current era, isolated ventricular septal defects that can be reached through the atrioventricular or semilunar valves can be repaired surgically with minimal risk of mortality.⁸ However, the reported operative mortality for patients similar to those described here remained as high as 43 percent as recently as 1983.⁷ A hospital mortality of 14 percent was reported from our institution, with one of four patients requiring reoperation,⁵ although current operative results in patients with muscular ventricular septal defects are no doubt somewhat better. Furthermore, patients with complex associated lesions, such as transposition of the great arteries or truncus arteriosus, are excluded from most reports; when they are included, complex disease is shown to contribute substantially to the surgical risk.^{3,7,8}

Surgical mortality in these patients is most frequently attributed to ventricular dysfunction. Studies in animals^{3,9} and follow-up of patients¹⁰ have led to concern about the effect of an incision in the systemic ventricle on ventricular function, although in these relatively small series of patients systemic ventriculotomy never emerged as an independent risk factor for operative death. In our experience, long-term adverse sequelae of this procedure appear to be common: after an average follow-up of five years, 12 of

24 such patients had one or more serious cardiac abnormalities, including a residual ventricular septal defect with a left-to-right shunt of more than 2:1 in 4 patients, a moderate-to-large apical ventricular aneurysm in 3, and moderate-to-severe global left ventricular dysfunction in 8.²¹

There were no serious complications in the patients described in this report. The follow-up period was short, however, and the long-term outcome of patients with intracardiac umbrella devices is unknown. In addition, there is clearly a potential for catheter-related morbidity in this high-risk group of patients; for example, we have seen one hemorrhagic stroke after the transcatheter closure of a postoperative residual shunt from the left ventricle to the right atrium, in a patient receiving streptokinase for loss of pulse.

This report confirms the complex nature of muscular ventricular septal defects. The clinical course in Patients 10 and 11 demonstrates that even when defects are identified accurately on preoperative catheterization, their importance can be difficult to assess. The presence of suprasystemic right ventricular pressure and the absence of detectable right-to-left shunting in these two patients before surgery seemed to indicate small residual defects; nevertheless, after the removal of the pulmonary-artery band, both had substantial left-to-right shunts and elevated pulmonary-artery pressures. Possibly, with the regression of right ventricular hypertrophy, the residual defects became larger and thus hemodynamically important.

Finally, this experience confirms the usefulness of a growing trend: the prospective, collaborative approach between pediatric interventional cardiologists and pediatric cardiac surgeons in the management of complex congenital heart disease.^{22,23} The value of transcatheter closure of ventricular septal defects is not that it allows the deferral or avoidance of surgery, but rather that it simplifies the subsequent surgical repair of complex or relatively inaccessible lesions. In the patients described in this report, preoperative transcatheter closure of ventricular septal defects allowed the subsequent surgical repair of other associated conditions (including other ventricular septal defects) without an incision in the systemic ventricle, and the procedure was not associated with deaths or major complications. Continued application of this approach may offer an improved outlook for patients with multiple ventricular septal defects, with or without associated complex cardiac disease, increasing the

number of such patients who are candidates for biven-tricular repair and reducing surgical mortality and the need for reoperation.

We are indebted to Stephen Roth, M.D., and Steven D. Colan, M.D., for reviewing the echocardiograms in these patients.

REFERENCES

- Friedman WF, Mehrizi A, Pusch AL. Multiple muscular ventricular septal defects. *Circulation* 1965; 32:35-42.
- Breckenridge IM, Stark J, Waterston DJ, Bonham-Carter RE. Multiple ventricular septal defects. *Ann Thorac Surg* 1972; 13:128-36.
- Zavarella C, Matsuda H, Jara F, Subramanian S. Left ventricular approach to multiple ventricular septal defects. *Ann Thorac Surg* 1977; 24:537-43.
- Fox KM, Patel RG, Graham GR, et al. Multiple and single ventricular septal defect: a clinical and haemodynamic comparison. *Br Heart J* 1978; 40:141-6.
- Kirklin JK, Castaneda AR, Keane JF, Fellows KE, Norwood WI. Surgical management of multiple ventricular septal defects. *J Thorac Cardiovasc Surg* 1980; 80:458-93.
- Rizzoli G, Blackstone EH, Kirklin JW, Pacifico AD, Barger LM Jr. Incremental risk factors in hospital mortality after repair of ventricular septal defect. *J Thorac Cardiovasc Surg* 1980; 80:494-505.
- Rizzoli G, Rubino M, Mazzucco A, et al. Progress in the surgical treatment of ventricular septal defect: an analysis of a twelve years' experience. *Thorac Cardiovasc Surg* 1983; 31:382-8.
- Kirklin JW, Barratt-Boyes BG. *Cardiac surgery: morphology, diagnostic criteria, natural history, techniques, results, and indications*. New York: Wiley, 1986:637-41.
- Waldhausen JA, Herendeen T, Taybi H. Left ventriculotomy: effects on ventricular function and coronary vessels. *Surgery* 1964; 56:868-73.
- Griffiths SP, Turi GK, Ellis K, et al. Muscular ventricular septal defects repaired with left ventriculotomy. *Am J Cardiol* 1981; 48:877-86.
- Lock JE, Block PC, McKay RG, Baim DS, Keane JF. Transcatheter closure of ventricular septal defects. *Circulation* 1988; 78:361-8.
- O'Laughlin MP, Mullins CE. Transcatheter occlusion of ventricular septal defect. *Cathet Cardiovasc Diagn* 1989; 17:175-9.
- Lock JE, Rome JJ, Davis R, et al. Transcatheter closure of atrial septal defects. *Circulation* 1989; 79:1091-9.
- Rome JJ, Keane JF, Perry SB, Spevak PJ, Lock JE. Double-umbrella closure of atrial defects: initial clinical applications. *Circulation* 1990; 82:751-8.
- Van Praagh R, Vlad P. Dextrocardia, mesocardia, and levocardia: the segmental approach in congenital heart disease. In: Keith JD, Rowe RD, Vlad P, eds. *Heart disease in infancy and childhood*. 3rd ed. New York: Macmillan, 1978:638-95.
- Van Praagh R. Terminology of congenital heart disease. *Circulation* 1977; 56:139-43.
- Taylor JFN, Crispin AR. Interventricular septal defect shown by left ventricular cine-angiography. *Br Heart J* 1971; 33:285-9.
- Elliott LP, Barger LM Jr, Bream PR, Soto B, Curry GC. Axial cineangiography in congenital heart disease. Section II. Specific lesions. *Circulation* 1977; 56:1048-93.
- Fellows KE, Keane JF, Freed MD. Angled view in cineangiography of congenital heart disease. *Circulation* 1977; 56:485-90.
- Singh AK, de Leval MF, Stark J. Left ventriculotomy for closure of muscular ventricular septal defects. *Ann Surg* 1977; 186:577-80.
- Hanna B, Colan SD, Bridges ND, Mayer JE, Castaneda A. Clinical and myocardial status after left ventriculotomy for ventricular septal defect closure. *J Am Coll Cardiol* 1991; 17:Suppl:110A. abstract.
- Rome JJ, Castaneda AR, Lock JE. Management in tetralogy of Fallot/atresia and diminutive pulmonary arteries. *Circulation* 1988; 78:Suppl II:II-291. abstract.
- Bridges ND, Lock JE, Castaneda AR. Baffle fenestration with subsequent transcatheter closure: modification of the Fontan operation for patients at increased risk. *Circulation* 1990; 82:1681-9.