

# UCLA

## UCLA Previously Published Works

### Title

Brain-behavior relationships in obsessive-compulsive disorder.

### Permalink

<https://escholarship.org/uc/item/5qb5n4n5>

### Journal

Seminars in Clinical Neuropsychiatry, 6(2)

### ISSN

1084-3612

### Authors

Saxena, S

Bota, RG

Brody, AL

### Publication Date

2001-04-01

### DOI

10.1053/scnp.2001.21833

Peer reviewed

# Brain-Behavior Relationships in Obsessive-Compulsive Disorder

*Sanjaya Saxena, Robert G. Bota, and Arthur L. Brody*

Advances in neuroimaging have led to a greater understanding of brain-behavior relationships in obsessive-compulsive disorder (OCD). This article provides an updated review and analysis of the structural and functional neuroimaging studies in OCD published to date and discusses how evidence from various types of neuroimaging studies has been synthesized to generate and test hypotheses regarding these relationships. We also review the basic science literature on the functional neuroanatomy of cortico-basal ganglia-thalamo-cortical circuits and integrate this information with neuroimaging data in OCD, to present a theoretic

cal model of brain mediation of OCD symptoms and response to treatment. Taken together, neuroimaging studies indicate that OCD symptoms are mediated by hyperactivity in orbitofrontal-subcortical circuits, which may be attributable to an imbalance of tone between direct and indirect striato-pallidal pathways. Serotonergic drugs may ameliorate OCD symptoms by changing the relative balance of tone through the indirect versus direct orbitofrontal-subcortical pathways, thereby decreasing activity in the overall circuit that exists in the symptomatic state.

Copyright 2001 © by W.B. Saunders Company

There have been many approaches to establishing brain-behavior relationships relevant to neuropsychiatric disorders. The two approaches generally considered most successful at localizing psychiatric dysfunctions in the brain are cognitive neuropsychology and neuroimaging. Neuropsychological studies attempt to correlate cognitive deficits with either known brain lesions or psychiatric syndromes. Although this approach has taught us much about the cognitive functions of discrete brain regions, especially in the cerebral cortex, it cannot always reveal which brain systems are directly involved in mediating psychiatric symptoms. Cognitive dysfunction does not always correlate well with psychiatric symptomatology, and most complex behavioral syndromes appear to be mediated by distributed neural circuits rather than discrete cortical regions.<sup>1</sup> Neuroimaging, however, allows for the direct measurement of both physical and functional

characteristics of brain structures in psychiatric populations. Several neuroimaging techniques can be used to delineate brain-behavior relationships. Structural brain imaging can reveal which brain regions may have gross abnormalities in size or shape that may be specific to a given disorder. Functional neuroimaging can reveal disease- or syndrome-specific patterns of brain activity, abnormal intercorrelations of regional brain function, and correlations between symptom ratings and regional brain activity. Functional neuroimaging studies that have isolated symptoms of interest by imaging them as they occur in real time have been the most successful at localizing neuropsychiatric symptoms to specific neural circuits.<sup>2</sup> Researchers have combined all these lines of evidence to generate brain-behavior models for neuropsychiatric disorders.

Obsessive-compulsive disorder (OCD) is a common neuropsychiatric illness characterized by intrusive, repetitive thoughts and ritualistic behaviors, which cause marked distress. Because OCD symptoms tend to be chronic, relatively consistent over time, and reliably reproducible, it has been possible to study them with a variety of neuroimaging techniques, in an effort to determine how the brain mediates their expression. Advances in neuroimaging have led to a greater understanding of the neurobiology of OCD, providing strong evidence that the pathophysiology of OCD involves abnormal functioning along specific, frontal-subcortical brain circuits. Both diagnosis-based and symptom-based neuroimaging approaches have been used to determine brain-behavior relationships in OCD. This article pro-

---

*From the UCLA Obsessive-Compulsive Disorder Research Program, Department of Psychiatry and Biobehavioral Sciences, UCLA School of Medicine; and the Psychiatry Service, West Los Angeles Veteran's Affairs Medical Center, Los Angeles, CA.*

*Supported in part by NIH Career Development Award no. 1 K23 MH01694-01 (S.S.) and Veteran's Affairs Research Career Development Award (A.L.B.).*

*Address reprint requests to Sanjaya Saxena, MD, UCLA Neuropsychiatric Institute, 300 UCLA Medical Plaza, Los Angeles, CA 90095. E-mail: ssaxena@mednet.ucla.edu*

*Copyright © 2001 by W.B. Saunders Company*

*1084-3612/01/0602-0002\$35.00/0*

*doi:10.1053/scnp.2001.21833*

vides an updated review and analysis of the neuroimaging studies in OCD published to date. We first review studies of brain structure using computerized tomography (CT) and magnetic resonance imaging (MRI), then move to studies of brain function using single photon emission computed tomography (SPECT), positron emission tomography (PET), functional MRI (fMRI), and magnetic resonance spectroscopy (MRS). As functional imaging studies have provided the most consistent and informative data about brain-behavior relationships in OCD, they are examined in greater detail. We then review the functional neuroanatomy of the frontal-subcortical circuits implicated by neuroimaging studies in OCD. Finally, we present a theoretical model of the pathophysiology of OCD that is supported both by neuroimaging findings and basic research. This model describes how frontal-subcortical brain circuitry may mediate OCD symptomatology and how successful treatments may ameliorate symptoms. Of necessity, this review repeats much from prior reviews by our groups and others.<sup>3-8</sup>

### Studies of Brain Structure in OCD Patients

#### *CT Studies of OCD*

CT studies were the first to suggest brain abnormalities in OCD but have not provided consistent findings. (For a summary of CT and MRI findings see Table 1). The first CT study<sup>9</sup> performed on OCD subjects and matched controls found no significant differences between groups in ventricle to brain matter ratio (VBR)—an index of brain atrophy. In contrast, a CT study of subjects with childhood-onset OCD<sup>10</sup> and one in adults with OCD<sup>11</sup> found ventricular volumes that were significantly larger than in controls. Luxenberg et al<sup>12</sup> found that caudate nucleus volume on CT was significantly smaller in male adolescents with childhood-onset OCD subjects than in male controls, a finding that would later be replicated by some, but not all, MRI studies of OCD.

#### *MRI Studies of OCD*

Compared with CT, MRI provides superior spatial resolution, distinction between gray and white matter, and visualization of neuroanatomic structures in multiple planes. It thereby allows the 3-dimensional reconstruction of neuroanatomic structures and calculation of their volumes. To

date there have been seven published series of OCD patients studied with MRI (see Table 1). As with CT, few consistent findings have emerged, although several studies have found abnormalities in the basal ganglia, whereas a few have focused on the orbitofrontal cortex (OFC), anterior cingulate gyrus (AC), and thalamus, structures also implicated in the pathophysiology of OCD by functional neuroimaging studies.

Scarone et al<sup>13</sup> found a significant increase in the volume of the right head of the caudate nucleus on MRI and a loss of the normal left > right caudate asymmetry in OCD patients compared with normal controls. However, Robinson and colleagues<sup>14</sup> reported smaller caudate nucleus volumes and enlarged ventricles in adult OCD patients compared to controls, and Rosenberg et al<sup>15</sup> found significantly smaller putamen volumes and larger third ventricles in treatment-naïve children with OCD compared to healthy control children. In the latter study, striatal volumes were inversely correlated with OCD symptom severity. Two quantitative MRI studies<sup>16,17</sup> found no differences in caudate volume between OCD subjects and controls.

Recent studies have provided clues that may explain the discrepant basal ganglia volume findings in the various structural imaging studies of OCD. Giedd et al<sup>18</sup> found larger caudate, putamen, and globus pallidus volume in children with streptococcus-related OCD than in healthy children, whereas Peterson et al<sup>19</sup> found that, in subjects with OCD and/or attention deficit/hyperactivity disorder (ADHD), higher antistreptolysin O antibody titers predicted larger volumes of putamen and globus pallidus. Giedd et al<sup>18</sup> suggest that there is a distinct subgroup of OCD patients who have pediatric autoimmune neuropsychiatric disorders associated with streptococcal infection (PANDAS), and that this subgroup has basal ganglia enlargement because of antibody-mediated inflammation.

Several MRI studies have examined cerebral cortical structures in OCD patients. Garber et al<sup>20</sup> found no structural abnormalities on the MRI scans of OCD patients by visual inspection. However, patients with a positive family history of OCD had more T1-mapping abnormalities in the AC than did patients with a negative family history or normals. There was also a significant positive correlation between right-left T1 asymmetry in the OFC and symptom severity in unmedicated

**Table 1.** Structural Imaging Studies in OCD

Authors	Technique	Subjects	Results
Insel et al, 1983 <sup>9</sup>	CT	10 OCD patients 10 normal controls	OCD = controls
Behar et al, 1984 <sup>10</sup>	CT	17 OCD patients 16 controls	VBRs larger in OCD subjects
Luxenberg et al, 1988 <sup>12</sup>	CT	10 male OCD adolescents 10 male control adolescents	Decreased caudate in OCD
Stein et al, 1993 <sup>11</sup>	CT	24 patients	Increased ventricular volume in OCD
Garber et al, 1989 <sup>20</sup>	MRI	32 treated OCD patients 14 normal controls	T <sub>1</sub> abnormalities in anterior cingulate gyrus
Kellner et al, 1991 <sup>16</sup>	MRI	12 OCD subjects 12 matched controls	caudate volume in OCD = controls
Scarone et al, 1992 <sup>13</sup>	MRI	20 treated OCD patients 16 normal controls	Increased right caudate volume in OCD
Robinson et al, 1995 <sup>14</sup>	MRI	26 OCD patients 26 healthy controls	Decreased caudate volume in OCD
Aylward et al, 1996 <sup>17</sup>	MRI	24 OCD patients 21 controls	OCD = controls
Jenike et al, 1996 <sup>21</sup> ; and Grachev et al, 1998 <sup>22</sup>	MRI-based morphometry	10 female OCD patients 10 female controls	Decreased total white matter and increased total cortex volume in OCD. Increased right frontal cortex volumes neg. correlated with nonverbal recall.
Rosenberg et al, 1997 <sup>15</sup>	MRI	19 never-treated children with OCD and 19 healthy controls	Decreased striatal volume and larger third ventricles in OCD
Rosenberg et al, 1997 <sup>25</sup> ; and Macmaster et al, 1999 <sup>26</sup>	MRI-based morphometry	21 never-treated children with OCD 21 healthy controls	Enlarged corpus callosum in OCD Decreased signal intensity in anterior corpus callosum
Szezeko et al, 1999 <sup>24</sup>	MRI	26 OCD patients 26 healthy controls	Decreased orbitofrontal cortex and right amygdala volumes in OCD
Giedd et al, 2000 <sup>18</sup>	MRI-based morphometry	34 children with streptococcus-related OCD and/or tics 82 healthy children	Larger caudate, putamen, and globus pallidus in strep.-related OCD/tics
Peterson et al, 2000 <sup>19</sup>	MRI	113 patients with OCD, ADHD, or Tic Disorder 34 controls	Antistreptococcal antibody titers predicted higher putamen and globus pallidus volumes in OCD and ADHD.
Gilbert et al, 2000 <sup>27</sup>	MRI	21 never-treated children with OCD; 10 after paroxetine; 21 healthy controls	Larger thalamic volume in OCD; decreased after paroxetine treatment

patients and those with a family history positive for OCD. More recent MRI studies have quantitatively measured cerebral cortical gray and white matter volumes and shape in OCD patients. Using MRI-based morphometry, Jenike et al<sup>21</sup> found that patients with OCD had significantly less total cerebral and cerebellar white matter but significantly greater total cerebral cortical volumes than matched normal controls. OCD patients also had longer corpus callosa, as well as a trend toward lower volume and less left-right asymmetry in caudate nuclei. They speculated that these abnormalities might indicate widespread alteration of the programmed neuronal death that normally oc-

curs during brain development, or reduced myelination in the brains of patients with OCD. This group also found that larger right frontal cortex regional volumes were negatively correlated with performance on visual recall tasks.<sup>22</sup> Rosenberg et al<sup>23</sup> found enlarged AC volumes in children with OCD, whereas Szezeko et al<sup>24</sup> found reduced OFC (including gray and white matter) and right amygdala volumes in OCD patients versus healthy controls, as well as a reduction in the normal right-left asymmetry in amygdala volume in OCD patients.

Recent MRI studies of children with OCD have found abnormalities in the thalamus and white

matter structures, as well. Rosenberg and colleagues examined the corpus callosum (CC) in treatment-naive children with OCD versus healthy controls and found both enlarged volume<sup>25</sup> and decreased signal intensity<sup>26</sup> indicating increased myelination and greater concentration of white matter in the CC of OCD patients. These abnormalities were localized to the anterior genu of the CC. Gilbert et al<sup>27</sup> measured thalamic volumes in children with OCD before and after treatment with paroxetine. Thalamic volumes were significantly greater in OCD patients than in normal controls, but declined significantly after 12 weeks of paroxetine treatment, suggesting that even short-term medication treatment could result in structural changes in the size of brain structures.

The heterogeneity of structural neuroimaging findings in OCD may reflect heterogeneity in the disorder itself. Localized abnormalities in prefrontal cortex, basal ganglia, and thalamus have been found in OCD patients, implying abnormal development or dysfunction of the frontal-subcortical circuits that mediate complex behavior. The fact that several structural imaging studies have found either abnormal volume or reduced asymmetry in the striatum suggests that at least a subgroup of patients with OCD may have abnormal basal ganglia development. Such subgroups may include patients with childhood-onset OCD, patients with comorbid Gilles de la Tourette's syndrome (TS) or other tic disorders (usually with childhood onset), or familial OCD. Some studies have found reduced caudate volumes in patients with TS.<sup>28,29</sup> Patients with TS or other tic disorders have not always been excluded from imaging studies of OCD and may have skewed their findings. Those structural imaging studies of OCD patients that found decreased caudate volumes might have included more patients with comorbid tics or TS or childhood-onset OCD, who may have more developmental brain abnormalities than other OCD patients. Conversely, subgroups of patients with OCD related to autoimmune responses to streptococcus infection may have basal ganglia enlargement.<sup>18,19</sup>

### Functional Imaging Techniques

Four different functional neuroimaging study designs have been used to elucidate brain-behavior relationships in OCD: (1) measuring cerebral activity in OCD patients versus normal controls with

functional brain imaging scans done in neutral or baseline states, (2) scanning OCD patients before and after treatment to measure cerebral activity changes that correspond to treatment response, (3) scanning patients while actively provoking their OCD symptoms, and (4) scanning OCD patients while they are performing a cognitive activation task. The different techniques have complemented each other, providing different pieces of information that, when synthesized and combined with basic neuroanatomical data, have helped us construct a cohesive model of the pathophysiology of OCD.

Most early functional neuroimaging studies of OCD used PET or SPECT, which use radioisotope-labeled tracers to measure glucose metabolism or blood flow. PET, which offers better spatial resolution than SPECT, employs the radiolabeled tracers <sup>18</sup>F-fluorodeoxyglucose (FDG) and <sup>11</sup>C-deoxyglucose to measure glucose uptake and metabolism, and <sup>15</sup>O-labeled-CO<sub>2</sub> or -H<sub>2</sub>O for regional cerebral blood flow (rCBF). In non-starvation conditions, glucose is by far the predominant energy substrate in the human brain, and its uptake has been shown to be a highly sensitive indicator of cerebral function. Under most circumstances, rCBF is highly correlated with glucose metabolism. SPECT uses 2 tracers to estimate rCBF, the inhaled gas <sup>133</sup>Xenon, and Technetium-99m-*d,l*-hexamethyl propyleneamine-oxime (HMPAO). Although HMPAO uptake usually is interpreted as a valid method of estimating the blood flow of one brain structure relative to that of another, variations in local rates of the metabolic conversion from the lipophilic to the hydrophilic form of HMPAO or localized dysfunction of the blood-brain barrier could produce spurious findings. HMPAO uptake is not consistently correlated with <sup>133</sup>Xenon-measured rCBF, especially in the basal ganglia.<sup>30</sup> Readers interested in more detail are referred elsewhere.<sup>31,32</sup>

Recent functional neuroimaging studies of OCD have employed magnetic resonance techniques such as MRS and functional MRI (fMRI). MRS measures concentrations of large molecules in brain tissue by acquiring proton spectra from these molecules after a magnetic resonance pulse.<sup>33</sup> The neurochemical markers measured by MRS include N-acetyl-aspartate (NAA), glutamate, myoinositol, choline, and creatinine. fMRI is a high-resolution imaging technique that measures correlates of regional brain activation by detecting

changes in blood oxygenation level in different clinical states or during various cognitive tasks.

### **Functional Neuroimaging Studies Comparing OCD Patients with Normal Controls at Baseline**

#### *Baseline PET Studies of OCD Patients Versus Normal Controls*

Seven PET studies to date have compared subjects with OCD to controls. Five of the seven found elevated metabolism or rCBF in the OFC, whereas 3 found elevated activity in the basal ganglia, and 2 found increased thalamic metabolism. Baxter et al<sup>54</sup> found significantly elevated absolute glucose metabolic rates for the cerebral hemispheres, caudate nuclei, and orbital gyri in 14 OCD patients (9 with concurrent major depression and 5 on medications), compared with control groups of normal subjects and patients with major depression alone. They then studied a new group of drug-free, non-depressed OCD patients<sup>55</sup> and again found significantly higher glucose metabolic rates for the whole cerebral hemispheres, bilateral caudate nuclei, and orbital gyri. Nordahl et al<sup>56</sup> found increased normalized metabolism in bilateral OFC and lower metabolism in the right parietal and left occipital-parietal regions in OCD patients than in normals. Swedo et al<sup>57</sup> examined adult patients with childhood-onset OCD and found increased metabolism in multiple cerebral cortical regions, (including OFC), right cerebellum, and right thalamus compared with controls. OCD severity was significantly correlated with right OFC metabolism. Sawle et al<sup>58</sup> found increased rCBF in the bilateral OFC, premotor, and midfrontal cortices of 6 patients with Obsessional Slowness, compared with normal controls. Perani et al<sup>59</sup> found higher glucose metabolic rates in the cingulate gyri, lenticular nuclei and thalamus of OCD patients than in normals, but no difference in OFC.

Martinot et al<sup>40</sup> found results at odds with those of the above PET studies, finding lower absolute metabolic rates in OCD subjects than in controls in all brain regions examined, including the lateral prefrontal cortex. These results resemble prior PET data on depressed OCD subjects<sup>41</sup> and may have been because of significant depressive comorbidity, given that Martinot et al<sup>42</sup> used much different thresholds of depression severity and recovery than used in the majority of studies done in the United States.

#### *Baseline SPECT Studies of OCD Patients Versus Normal Controls*

SPECT studies of OCD have also implicated the prefrontal cortex, striatum, and thalamus, but have been less consistent than PET studies in finding increased activity compared with normal controls perhaps because of technical problems with the SPECT technique (discussed later). Machlin et al<sup>43</sup> found a significantly higher ratio of medial-frontal cortex to whole cortex HMPAO concentration in OCD subjects compared to matched control subjects. Rubin et al<sup>30</sup> found significantly increased HMPAO uptake in bilateral dorsal parietal cortex, left postero-frontal cortex, and bilateral OFC, but decreased uptake in the head of the caudate bilaterally, in men with OCD. Adams et al<sup>44</sup> found asymmetric perfusion of the basal ganglia in medicated but symptomatic OCD patients compared with healthy controls. Lucey et al<sup>45</sup> however, found reduced region to cerebellum ratios of HMPAO uptake in several cerebral cortical regions, right caudate, and right thalamus. HMPAO uptake ratios in left inferior frontal cortex, medial frontal, and right parietal cortex were negatively correlated with OCD and depressive symptoms, whereas HMPAO uptake in thalamus, caudate nuclei, and superior frontal cortex was positively correlated with anxious/avoidant symptoms. Lucey and colleagues<sup>48</sup> also compared a group of patients with OCD to groups with Posttraumatic Stress Disorder (PTSD), Panic Disorder, and normal controls. The OCD and PTSD groups had significantly lower HMPAO uptake ratios in superior frontal cortex and right caudate than normals and panic disorder patients. However, both the OCD and PTSD groups had high depression scores, and depression severity was significantly negatively correlated with caudate rCBF. Crespo-Facorro et al<sup>47</sup> found reduced activity in right OFC in OCD patients without tics, but did not exclude patients with mood disorders. Some of the variability in these SPECT studies may then be because of differences in rates of comorbid depression between studies, which may have a significant impact on rCBF.

Caution must be exercised before equating HMPAO uptake with rCBF or abnormal glucose metabolism in a pathologic state such as OCD, in which the blood-brain barrier could be abnormal, causing dissociation of perfusion and metabolism.

Regional HMPAO uptake ratios could be decreased in OCD patients because of elevated uptake or rCBF in the cerebellum, often used as a reference region for normalized activity ratios in SPECT studies. HMPAO uptake could also be reduced by intrinsic neuroanatomic factors, even with increased rCBF or glucose metabolism in the same region. HMPAO uptake and rCBF were not consistently correlated in the basal ganglia and frontal cortex in one study of OCD patients and controls.<sup>30</sup> Another important factor contributing to findings of caudate hypoperfusion in SPECT studies may be the presence of TS, other tic disorders, or comorbid ADHD in OCD subjects, because ventral striatal hypometabolism, hypoperfusion, and low HMPAO uptake have been found in several studies of TS and ADHD.<sup>48-53</sup>

#### *Baseline MRS Studies of OCD Patients Versus Normal Controls*

Most MRS studies of OCD have measured NAA, thought to be a marker of neuronal density that is reduced in disease states that involve neuronal loss or dysfunction.<sup>54</sup> Ebert et al<sup>55</sup> found significantly lower relative levels of NAA in the right striatum of OCD patients compared with normal control subjects, as well as a NAA reduction in the AC that correlated with severity of illness. Bartha et al<sup>56</sup> also found lower NAA levels in the left striatum of OCD patients than in normal controls, but Ohara et al<sup>57</sup> found no differences between OCD patients and normal controls in NAA, creatinine, or choline concentrations in the lenticular nuclei, suggesting that the striatal reductions might be localized to the caudate nuclei. Fitzgerald et al<sup>58</sup> found reduced NAA levels in bilateral medial thalamus in OCD patients compared to controls. Thus, MRS studies have found neurochemical abnormalities in the very same brain structures found to have structural and functional alterations in OCD.

#### *Summary of Baseline Functional Neuroimaging Findings*

Baseline studies of OCD patients compared to normal controls (see Table 2 for summary) consistently indicate elevated activity in the OFC, with less consistent abnormalities in the caudate nuclei and thalamus, which also show neuro-

chemical alterations suggestive of neuronal dysfunction.

### **Cerebral Correlates of OCD Symptom Factors**

Studies that examine the neural substrates of specific symptoms that occur in a given disorder can use within-group variance in symptom profiles to identify patterns of brain activity that correlate with a predisposition to individual symptoms or symptom factors.<sup>2</sup> Although standard diagnostic classifications consider OCD to be a single diagnostic entity, it has become clear from factor analytic studies that several different OCD symptom factors exist.<sup>59,60</sup> One recent factor analysis of OCD symptoms by Leckman et al<sup>60</sup> yielded four principal symptom factors: (1) aggressive, sexual, and religious obsessions with checking compulsions; (2) symmetry obsessions with ordering, arranging, and repeating compulsions; (3) contamination obsessions with washing and cleaning compulsions; and (4) hoarding, saving, and collecting symptoms. These symptom factors appear to show different inheritance patterns. Despite this phenotypic heterogeneity, virtually all prior neurobiological and treatment studies of OCD have grouped patients with diverse symptom patterns together.

Only one neuroimaging study thus far has examined the neural correlates of specific OCD symptom factors. Rauch and colleagues<sup>61</sup> found that the severity of factor 1 symptoms correlated significantly with rCBF in bilateral striatum, whereas factor 2 symptoms had a trend toward negative correlation with rCBF in right striatum. Factor 3 symptoms correlated with rCBF in bilateral AC, left OFC, and other cortical areas. Although these were preliminary results, they suggest that different OCD symptom clusters are mediated by quite different patterns of brain activity, raising the question of whether the heterogeneity in the findings of previous functional imaging studies of OCD could be accounted for by phenotypic variations between their subject pools. Moreover, patients with primary hoarding/saving symptoms have been underrepresented in most studies of OCD,<sup>62</sup> potentially skewing their results. Our group at UCLA is now investigating the brain mediation of factor 4 symptoms (compulsive hoarding/saving) in a new sample of OCD patients.

**Table 2.** Baseline Functional Neuroimaging Studies of OCD Patients Versus Normal Controls

Authors	Subjects	Technique	Results in OCD
Baxter et al, 1987 <sup>34</sup>	14 OCD (9 with depression) 14 Depressed; 14 controls	FDG-PET	Increased orbital gyri and caudate in OCD
Baxter et al, 1988 <sup>35</sup>	10 OCD 10 controls	FDG-PET	Increased orbital gyri and caudate in OCD
Nordahl et al, 1989 <sup>36</sup>	8 OCD 30 controls	FDG-PET	Increased orbitofrontal, decreased parietal cortex
Swedo et al, 1989 <sup>37</sup>	18 OCD-childhood onset 18 controls	FDG-PET	Increased orbitofrontal, prefrontal, anterior cingulate, right thalamus, and cerebellum
Martinot et al, 1990 <sup>40</sup>	16 OCD 8 controls	FDG-PET	Decreased lateral prefrontal cortex in OCD
Sawle et al, 1991 <sup>38</sup>	6 with obsessional slowness 6 controls	<sup>15</sup> O-H <sub>2</sub> O-PET	Increased orbitofrontal, and midfrontal premotor cortex
Perani et al, 1995 <sup>39</sup>	11 OCD 15 controls	FDG-PET	Increased cingulate, lenticular nuclei, and thalamus in OCD
Machlin et al, 1991 <sup>43</sup>	10 OCD 8 controls	HMPAO-SPECT	Increased medial frontal cortex in OCD
Rubin et al, 1992 <sup>30</sup>	10 OCD 10 controls	<sup>133</sup> Xe- SPECT and HMPAO-SPECT	Xe: OCD = control HMPAO: increased parietal and frontal cortex, decreased caudate
Adams et al, 1993 <sup>44</sup>	11 OCD 11 controls	HMPAO-SPECT	Decreased left basal ganglia
Lucey et al, 1995 <sup>45</sup>	30 OCD 30 controls	HMPAO-SPECT	Decreased superior frontal, inferior frontal, temporal, and parietal cortex, right caudate, and right thalamus in OCD
Lucey et al, 1997 <sup>46</sup>	15 OCD, 16 PTSD 15 Panic, 15 controls	HMPAO-SPECT	Decreased right caudate and bilateral superior frontal cortex in OCD and PTSD vs controls
Crespo-Facorro et al, 1999 <sup>47</sup>	27 OCD (7 with tics) 16 controls	HMPAO-SPECT	Decreased right OFC in OCD without tics
Ebert et al, 1997 <sup>55</sup>	12 OCD 6 controls	MRS	Decreased NAA in right striatum and right anterior cingulate
Bartha et al, 1998 <sup>56</sup>	13 OCD 13 controls	MRS	Decreased NAA in left striatum
Ohara et al, 1999 <sup>57</sup>	12 OCD 12 controls	MRS	OCD = Control in lenticular nuclei NAA
Fitzgerald et al, 2000 <sup>58</sup>	11 OCD children 11 control children	MRS	Decreased NAA/Ch in bilateral medial thalamus in OCD

### Functional Neuroimaging Studies of OCD Patients Before and After Treatment

Functional neuroimaging studies done before and after treatment allow investigators to test hypotheses about the brain mediation of psychiatric symptoms by determining what changes in regional brain activity occur when patients respond to treatment, and what regional changes correlate best with symptomatic improvement. Such studies can also reveal differences in cerebral mechanisms of action between treatments. PET has been used to study OCD patients before and after treat-

ment with serotonin reuptake inhibitors (SRIs), cognitive-behavioral therapy (CBT), and neurosurgery. Of the seven published pre- and post-treatment PET studies of OCD, 6 found posttreatment decreases in the OFC in responders to treatment, 5 showed decreases in the caudate nuclei, and 2 found decreases in the AC after treatment.

Benkelfat et al<sup>63</sup> studied OCD subjects before and after treatment with clomipramine (CMI), finding significant decreases in glucose metabolism in the left caudate and several OFC subregions with treatment. The greatest decrease was in the right anterior OFC. Good responders to CMI



showed a significantly greater decrease in left caudate than partial or poor responders. Swedo and colleagues<sup>64</sup> found significant decreases in bilateral OFC metabolism in OCD patients after medication treatment, with greater decreases in left OFC metabolism in responders than nonresponders, whereas Perani et al<sup>39</sup> found that metabolic rates decreased significantly in the cingulate gyri of OCD patients after treatment with SRIs. Saxena et al<sup>65</sup> replicated the findings of decreased right caudate and OFC metabolism with treatment response in OCD patients treated with paroxetine, a different agent than those used in previous studies. Glucose metabolic decreases in the right caudate and right anterolateral subregion of the OFC were significantly greater in responders than in nonresponders to paroxetine. Another study<sup>66</sup> found that orbital and caudate glucose metabolic rates decreased significantly 1 year after bilateral anterior capsulotomy, a neurosurgical procedure found to effectively reduce symptoms in patients with treatment-refractory OCD.

Baxter et al<sup>67</sup> studied OCD patients before and after treatment with either fluoxetine or CBT. In both treatment groups, right caudate metabolic rates decreased significantly in responders but not in nonresponders, showing that both pharmacologic and nonpharmacologic treatments can have significant effects on brain activity patterns that mediate neuropsychiatric disorders. The percentage change in right caudate glucose metabolism correlated significantly with percentage change on the Yale-Brown Obsessive-Compulsive Scale (Y-BOCS)<sup>68</sup> for fluoxetine-treated patients, and there was a trend towards a correlation in subjects treated with CBT. When all responders to treatment were lumped together, significant correlations between metabolism in the right OFC, AC, caudate nucleus, and thalamus were found before, but not after treatment. These correlations were not found in patients with unipolar depression or normal control subjects, suggesting that treatment-responsive OCD is characterized by abnormal, disease-specific, functional relationships between these brain regions only in the symptomatic state. Successful treatment (fluoxetine or CBT) appeared to disrupt the linkage of regional activity that existed before treatment.<sup>67</sup> Benkelfat et al<sup>63</sup> examined their data in a similar way and also noted that some of the pretreatment correlations (between left OFC and left thalamus, and between right caudate and right thalamus) were disrupted after treatment with CMI. A second

study using CBT<sup>69</sup> replicated and extended earlier findings with that treatment modality. Significant decreases were found in bilateral caudate glucose metabolism in responders to CBT, compared with nonresponders. Again, strong pretreatment metabolic correlations between OFC and caudate, and between OFC and thalamus decreased significantly with successful CBT. Furthermore, change in Y-BOCS was positively correlated with change in left OFC metabolism.

Two SPECT studies have examined OCD patients before and after treatment. Hoehn-Saric et al<sup>70</sup> found that medial-frontal cortex HMPAO uptake, elevated in OCD patients before treatment, decreased significantly after treatment with fluoxetine. Rubin et al<sup>71</sup> found that HMPAO uptake decreased in cortical areas after treatment of males with OCD with CMI.

Recent MRS studies by Rosenberg and colleagues<sup>72,73</sup> found striking drops in glutamate resonance in the left caudate in 11 children with OCD after successful treatment with paroxetine. These changes were consistent with the glucose metabolic decreases seen with paroxetine treatment in FDG-PET studies of OCD<sup>65</sup> and suggest that glutamate-serotonin interactions in the caudate may play a role in the pathophysiology of OCD.

Thus, regardless of the type of imaging modality or the type of treatment used, pre- to post-treatment studies of OCD have consistently shown that OFC and caudate activity decreases with effective treatment. These findings are summarized in Table 3.

#### *Pretreatment PET Predictors of Response to Treatment*

Functional imaging data has also been examined to determine if pretreatment regional brain metabolism predicts treatment response. Swedo et al<sup>64</sup> found that responders to CMI had lower pretreatment metabolic rates in right OFC and right AC than did nonresponders. Using data from their previous studies,<sup>67,69</sup> the UCLA group found that pretreatment metabolism in left OFC differentially predicted response to CBT versus fluoxetine in patients with OCD.<sup>74</sup> Lower pretreatment left OFC metabolism was significantly correlated with response to fluoxetine, but higher pretreatment left OFC metabolism was correlated with response to CBT.<sup>74</sup> Recently, this group found that lower pretreatment bilateral OFC metabolic rates

**Table 3.** Pre- and Posttreatment Imaging Studies in OCD

Authors	Subjects/Treatment	Technique	Results With Treatment
Benkelfat et al, 1990 <sup>63</sup>	8 treated with clomipramine for mean 16 weeks	FDG-PET	Decreased L caudate and OCF areas
Mindus et al, 1991 <sup>66</sup>	5 treated with anterior capsulotomy	<sup>11</sup> C-Glc-PET	Decreased caudate and OFC
Swedo et al, 1992 <sup>64</sup>	13 subjects: 8 on clomipramine, 2 on fluoxetine, and 3 off meds for mean 20 months	FDG-PET	Decreased bilateral OFC
Baxter et al, 1992 <sup>67</sup>	9 with fluoxetine, 9 with behavior therapy for mean 10 weeks	FDG-PET	Decreased R caudate in responders to either treatment; loss of pathologic correlations between OFC, caudate and thalamus
Perani et al, 1995 <sup>39</sup>	4 with fluvoxamine, 2 with fluoxetine, and 3 with clomipramine	FDG-PET	Decreased cingulate
Schwartz et al, 1996 <sup>69</sup>	18 treated with behavior therapy for mean 10 weeks	FDG-PET	Decreased bilateral caudate in responders; loss of pathologic correlations among OFC, caudate, and thalamus
Saxena et al, 1999 <sup>65</sup>	20 with paroxetine for 8–12 weeks	FDG-PET	Decreased R caudate and R anterolateral OFC in responders
Hoehn-Saric et al, 1990 <sup>70</sup>	6 with fluoxetine for 3–4 months	HMPAO-SPECT	Decreased medial frontal to whole cortex ratio
Rubin et al, 1995 <sup>71</sup>	10 with clomipramine for mean 7 months	<sup>133</sup> Xe-SPECT and HMPAO-SPECT	Decreased cortical HMPAO uptake
Rosenberg et al, 1998 <sup>72</sup>	11 children on paroxetine for 12 weeks	MRS	Decreased glutamate in left caudate

were significantly correlated with better response to paroxetine, as well.<sup>65</sup> Taken together, these results suggest that OCD patients with particular patterns of brain metabolism may respond preferentially to specific types of treatment (CBT *v* medication), with lower pretreatment OFC activity predicting better response to SRI medications.

### Neuroimaging Studies of OCD Symptom Provocation

Perhaps the most direct information about brain-behavior relationships in OCD comes from symptom provocation studies that reveal patterns of brain activation occurring in real time, when patients are actively experiencing obsessions, anxiety, and urges to perform compulsive rituals. These studies have found strong correlations between OCD symptom expression and brain activation in the same regions found to be overactive at baseline.

Rauch et al<sup>75</sup> scanned OCD subjects with <sup>15</sup>O-CO<sub>2</sub>-PET during a resting state, while responding to an innocuous control stimulus, and when provoked by a stimulus tailored specifically

to induce each patient's symptoms. Patients had significant increases in rCBF in the right caudate nucleus, left AC, and bilateral OFC during the symptomatic state. Symptom severity correlated positively with activation of the left anterior OFC subregion but negatively with the posterior OFC subregion, suggesting that the different subregions might play opposing roles in mediating and suppressing OCD symptoms, respectively. This group repeated its symptom provocation method with fMRI, and observed activation in bilateral OFC, lateral frontal, anterior temporal, AC, and insular cortex, as well as in amygdala, lenticular nucleus, and right caudate.<sup>76</sup> McGuire et al<sup>77</sup> also reported positive correlations between provoked OCD symptoms and rCBF in the right inferior frontal cortex (including the right lateral OFC), striatum, globus pallidus, thalamus, left hippocampus, and posterior cingulate gyrus. Cottraux et al<sup>78</sup> measured rCBF changes in OCD patients and normal controls given obsessive versus neutral auditory stimulation. Obsessive stimulation was associated with higher rCBF in OFC regions in both controls and OCD patients, more on the right than left. Both neutral and obsessive stim-

ulation produced significantly greater rCBF increases in thalamus and putamen in controls than in OCD patients, whereas OCD patients had greater increases in superior temporal regions and a greater overall increase in rCBF. Zohar et al<sup>79</sup> performed <sup>133</sup>Xe-SPECT scans on OCD subjects with contamination obsessions and washing compulsions, first in a relaxation state, then during imaginal flooding, and finally during in vivo exposure to stimuli that induced their OCD symptoms. rCBF was increased nonsignificantly in the imaginal flooding, but decreased significantly in all superior cortical regions except temporal cortex during in vivo exposure, possibly because of shunting of blood flow to more ventral cortical and subcortical structures, which could not be visualized with this method.

Two studies have measured changes in brain activity after exacerbating OCD symptoms with pharmacologic challenges. Hollander et al<sup>80</sup> administered oral *m*-chlorophenylpiperazine (m-CPP), a serotonin receptor agonist that exacerbates OCD symptoms in some patients, and found a marked increase in global cortical perfusion in those patients whose symptoms worsened with m-CPP. Stein et al<sup>81</sup> administered sumatriptan, a serotonin 1D agonist, to OCD patients and observed significant increases in HMPAO uptake in right thalamus. OCD symptom exacerbation was correlated with increased activity in the right cerebellum, and with decreased activity in the left inferior frontal and midfrontal areas.

Taken together, the studies of OCD symptom provocation (see Table 4 for summary) strongly link the expression of OCD symptoms with activation of the OFC, basal ganglia, thalamus, limbic and paralimbic structures, predominately in the right hemisphere. These studies strengthen the hypothesis that OCD symptoms are mediated by increased activity in the frontal-subcortical circuits connecting these structures to one another.

### Neuroimaging Studies of Cognitive Activation in OCD

Cognitive activation studies attempt to delineate the pathophysiology of a disorder by finding abnormalities in regional brain activation during specific cognitive tasks. There have been 4 such studies in OCD, summarized in Table 5. All have shown abnormal brain activation patterns in subjects with OCD. Rauch et al<sup>82</sup> used <sup>15</sup>O-CO<sub>2</sub>-PET

to examine brain activation patterns of OCD patients versus control subjects while they performed an implicit (procedural) sequence learning task. Although patients and controls had comparable learning of the task, controls activated bilateral inferior striatum, whereas OCD patients did not activate inferior striatum but instead showed bilateral mesial temporal activation. These results suggest that OCD patients have cortico-striatal dysfunction and access brain systems involved in explicit memory<sup>83</sup> for tasks that normals would process implicitly, without conscious awareness. These findings have recently been replicated using the implicit learning paradigm and fMRI.<sup>84</sup> Lucey et al<sup>85</sup> used HMPAO-SPECT to measure relative rCBF changes during performance of the Wisconsin Card Sort Task (WCST), which tests the ability to shift cognitive set and executive functions, in OCD patients versus controls. OCD patients made more perseverative errors and null-sorts (responses that fail to match cards on any of the three possible dimensions) than controls, and the number of null-sorts was significantly correlated with rCBF in left inferior frontal cortex and left caudate. Using fMRI, Pujol et al<sup>86</sup> found significantly greater frontal cortical activation in OCD patients than in controls during a phonologically guided word generation task and a defective suppression of this activation during the following rest period. Both abnormal imaging findings in this study significantly correlated with OCD symptom severity. This area of investigation into OCD is in its infancy, and much more research will be required to reveal consistent links between symptoms, cognitive deficits, and brain activity abnormalities in OCD.

### Summary of Functional Neuroimaging Findings in OCD

Although not all studies agree, review of the OCD functional brain imaging literature reveals a remarkable amount of data suggesting abnormalities in OFC, AC, caudate, and thalamus, structures linked by well-described neuroanatomic circuits.<sup>87</sup> The great majority of studies provide evidence for elevated OFC activity in the untreated state that consistently decreases with response to treatment but is increased with symptom provocation. Several studies suggest a preferential role for the right anterolateral OFC in mediating OCD

**Table 4.** OCD Symptom Provocation Studies

<i>Authors</i>	<i>Subjects</i>	<i>Tracer</i>	<i>Results</i>
Zohar et al, 1989 <sup>79</sup>	10 OCD	<sup>133</sup> Xe-SPECT	Increased rCBF with imaginal flooding, and decreased rCBF to cortex with in vivo exposure
Rauch et al, 1994 <sup>75</sup>	8 OCD	<sup>15</sup> O-CO <sub>2</sub> -PET	Activation in R caudate, bilateral orbitofrontal, and L anterior cingulate
McGuire et al, 1994 <sup>77</sup>	4 OCD	<sup>15</sup> O-CO <sub>2</sub> -PET	Activation in inferior frontal, post. cingulate, striatum, GP, thalamus, and hippocampus; decreased dorsal prefrontal and parietal-temporal cortex
Hollander et al, 1995 <sup>80</sup>	14 OCD challenged with m-CPP	<sup>133</sup> Xe-SPECT	Increased global cortical perfusion
Cottraux et al, 1996 <sup>78</sup>	10 OCD 10 controls	<sup>15</sup> O-H <sub>2</sub> O-PET	Increased bilateral OFC Greater increases in thalamus and putamen in normals
Breiter et al, 1996 <sup>76</sup>	13 OCD 6 controls	fMRI	Activation in bilateral orbital, anterior cingulate, frontal, and temporal cortex, amygdala, insula, lenticular nuclei, and right caudate
Stein et al, 1999 <sup>81</sup>	14 OCD challenged with sumatriptan	HMPAO-SPECT	Increased right thalamus and putamen, decreased right caudate; symptom exacerbation associated with increased right cerebellum and decreased left inferior frontal and midfrontal areas

symptoms and/or the response to pharmacotherapy. The caudate nucleus has been found in several pretreatment studies to show abnormalities in OCD. Furthermore, 6 studies have shown decreases in caudate glucose metabolism after treatment with CMI, fluoxetine, paroxetine, CBT, or neurosurgery, whereas 3 studies have shown activation of the caudate with symptom provocation, and 2 have shown a failure of striatal activation during implicit sequence learning in OCD. Pathologic correlations among functional activity

rates in the OFC, caudate, and thalamus characterize the symptomatic state of OCD and are abolished by successful treatment. Although less consistently, functional neuroimaging data also support the involvement of AC, amygdala, and related limbic structures in OCD. Differences between studies may be attributable to symptomatic differences between subject pools, differences between the treatments used, different duration of treatment, different scanning conditions, and different methods of localizing brain regions.

**Table 5.** Cognitive Activation Studies in OCD

<i>Authors</i>	<i>Subjects/Task</i>	<i>Tracer</i>	<i>Results</i>
Rauch et al, 1997 <sup>82</sup> and in press <sup>84</sup>	9 females with OCD 9 females controls Implicit sequence learning	<sup>15</sup> O-CO <sub>2</sub> -PET and fMRI	Controls activated inferior striatum; but OCD patients activated medial temporal lobe
Lucey et al, 1997 <sup>85</sup>	19 OCD 19 controls	HMPAO-SPECT	null-sorts correlated with rCBF in left inferior frontal cortex and caudate
Pujol et al, 1999 <sup>86</sup>	20 OCD 20 controls	fMRI	Greater left inferior frontal cortex activation and defective suppression of activation in OCD
Rauch et al, in press <sup>84</sup>	6 females with OCD 10 female controls	fMRI	Controls activated inferior striatum; OCD patients activated medial temporal lobe

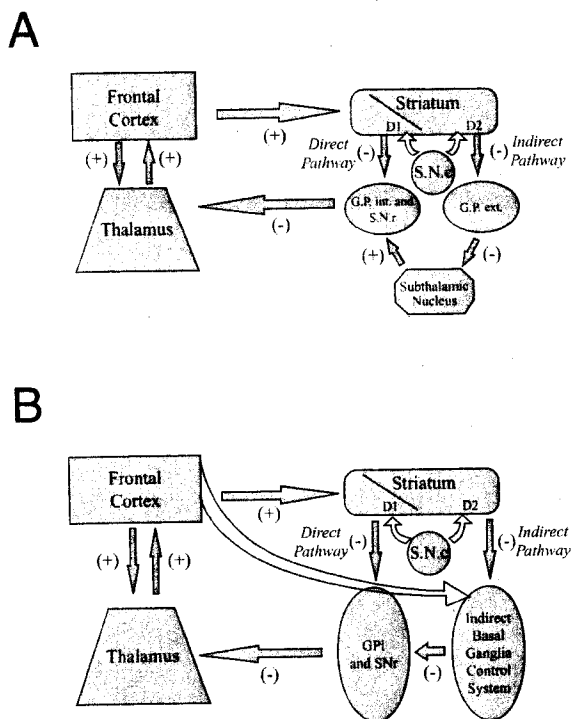
## A Theory of the Functional Neuroanatomy of OCD

Functional neuroimaging data clearly support pathophysiologic theories put forward by Rapoport and Wise,<sup>88</sup> Insel et al,<sup>89</sup> Modell et al,<sup>90</sup> and Baxter et al,<sup>3,91</sup> regarding the role of the OFC, basal ganglia, and frontal-subcortical circuits in OCD. Below, we present our present working model of OCD symptom mediation. It expands on earlier theories and incorporates newer data regarding the neuroanatomy and function of frontal-subcortical brain circuits, as well as a proposed mechanism for symptom reduction with treatment.

### Behavioral Regulation Through Frontal-Subcortical Circuits

Alexander, DeLong, and Strick<sup>87</sup> described a series of discrete, parallel, neuroanatomic circuits connecting the prefrontal cortex, basal ganglia, and thalamus. Many (probably thousands) of these frontal-subcortical circuits exist, originating in nearly every part of the cerebral cortex and projecting through different subcompartments of the basal ganglia and thalamus. The various frontal-subcortical circuits subserve different behavioral functions and appear to mediate the symptomatic expression of different psychiatric syndromes.<sup>3,4,90,92</sup> The lateral prefrontal-subcortical circuits have been implicated in Major Depression, whereas orbitofrontal-subcortical circuits appear to be involved in OCD, and sensori-motor circuits are thought to mediate the symptoms of movement disorders.<sup>4,91</sup>

Figure 1A presents a diagram of the classical conceptualization of frontal-subcortical circuitry. Classically, each of these circuits was described as having 2 loops: a direct pathway and an indirect pathway. In primates, the direct pathway projects from (1) cerebral cortex to (2) striatum to (3) the internal segment of the globus pallidus / substantia nigra, pars reticulata complex (GPI/SNr)—the main output station of the basal ganglia, then to (4) thalamus, and (5) back to cortex. The indirect pathway has a similar origin from (1) cortex to (2) striatum, but then projects from the striatum to (3) the external segment of the globus pallidus (GPe), and then to (4) subthalamic nucleus, before returning to (5) GPI/SNr, where it rejoins the common pathway to the (6) thalamus before returning to (7) cortex. Prefrontal cortex and thal-



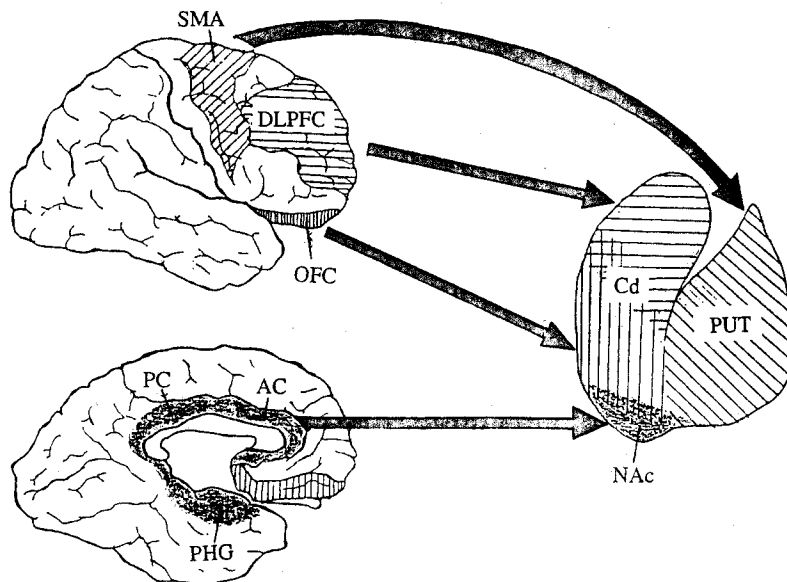
**Figure 1.** (A) Classic conception of direct and indirect frontal-basal ganglia-thalamo-cortical pathways. GPI and SNr, globus pallidus interna / substantia nigra, pars reticulata complex; GPe, globus pallidus externa. The frontal-subcortical circuit originates in the frontal cortex, which projects to striatum. The direct pathway projects from striatum to the GPI/SNr complex (the main output station of the basal ganglia), which projects to the thalamus, which has reciprocal, excitatory projections to and from the cortical site of origin. This pathway contains 2 excitatory and 2 inhibitory projections, making it a net positive feedback loop. The indirect pathway also originates in the frontal cortex and projects to the GPe, then to the striatum, but then projects to the GPe, then to the subthalamic nucleus, then back to GPI/SNr, before returning to the thalamus and finally, back to frontal cortex. This indirect circuit has 3 inhibitory connections, making it a net negative feedback loop. (B) Current conceptualization of prefrontal-basal ganglia-thalamo-cortical circuitry. GPI and SNr, globus pallidus interna / substantia nigra, pars reticulata complex; GPe, globus pallidus externa. Recent anatomic studies have called into question previous views of basal ganglia circuitry. Here, we refer to an indirect basal ganglia control system that consists of the GPe and the subthalamic nucleus. Connections within these structures are more complex than previously thought. The prefrontal cortex has excitatory projections to indirect pathway structures. In addition, the GPe directly projects to the GPI/SNr complex. Nevertheless, the net effect of activity in the indirect circuit still appears to be inhibition of the thalamus, thereby decreasing thalamo-cortical drive. The frontal-subcortical circuits originating in the lateral prefrontal cortex, orbitofrontal cortex, and anterior cingulate gyrus all pass through subcompartments of the medial dorsal nucleus of the thalamus.

amus also reciprocally activate each other. Impulses along the direct pathway (with 2 inhibitory connections) disinhibit the thalamus and activate the system in a positive feedback loop, whereas activity along the indirect pathway (with 3 inhibitory connections) would provide negative feedback, inhibiting the thalamus. Thus, the direct and indirect pathways appear to balance each other and allow for both facilitation and suppression of complex motor programs, via their opposite effects on thalamo-cortical activation.<sup>93</sup> Recent evidence suggests that the indirect pathway has interactions with the direct pathway that are much more complex than those envisioned in the classic model. Researchers agree, however, that, whatever the exact circuitry of the indirect pathway, activity through it results in increased activity in the GPi/SNr, thereby strengthening the inhibition of the thalamus. Our current conceptualization of frontal-subcortical circuitry (Fig 1B) acknowledges the present uncertainties by referring to the indirect pathway elements as the "indirect basal ganglia control system."

The connections between cortex and striatum have been described as "a common substrate for movement and thought."<sup>94</sup> The striatum, and the caudate nucleus in particular, is involved in processing cortical information for the initiation of behavioral responses and also plays an important role

in procedural learning, the acquisition of new habits and skills which require minimal conscious awareness.<sup>95</sup> Conventionally, the striatum is divided into the caudate nucleus, putamen, and nucleus accumbens (see Fig 2). Different regions of the striatum receive input from different cortical regions.<sup>87</sup> The OFC, a paralimbic isocortical area, projects to the ventromedial caudate nucleus, whereas the dorsolateral prefrontal cortex (an associative neocortical area) projects to the dorsolateral caudate, and the anterior cingulate gyrus and hippocampal formation (limbic areas) project to the nucleus accumbens (see Fig 2). Circuits involved in motor programming travel through the putamen. These topographical representations are maintained in a related, but distinct, topology through the GP, subthalamic nucleus, and thalamus, creating relatively segregated, closed loops.<sup>1,87</sup> Direct and indirect pathways are present in each of the loops—motor, associative, and limbic.<sup>96-98</sup> Several different thalamic nuclei are involved in these circuits, but those originating in limbic and association cortex all pass through subregions of the medial dorsal nucleus of thalamus.<sup>99</sup>

In these circuits, excitatory projections predominantly use glutamate as a neurotransmitter, whereas inhibitory ones mainly employ GABA. Several peptide transmitters also have important roles within these pathways.<sup>100</sup> Other neuro-



**Figure 2.** Frontal-striatal projections. Slanted lines, premotor and supplementary motor areas (SMA); horizontal lines, dorsolateral prefrontal cortex (DLPFC); vertical lines, orbitofrontal cortex (OFC); shaded area, anterior cingulate gyrus (AC), posterior cingulate gyrus (PC), and parahippocampal gyrus (PHG). Regional distribution of cortical projections to separate striatal subcompartments. The SMA projects to the putamen (PUT), the DLPFC projects to the dorsolateral head of the caudate nucleus (Cd), the OFC projects to the ventromedial head of the caudate, and the AC, PC, and PHG project to the nucleus accumbens (NAc). Although there may be slight overlap, cortical projection fields within the striatum are topographically distinct.

transmitters (dopamine, serotonin, acetylcholine, and so on) modify the activity of projections between these structures. Dopaminergic input from the substantia nigra pars compacta (SNc) exerts contrasting effects on the 2 pathways within each circuit.<sup>93</sup> Stimulation of the dopamine D1 receptor activates the direct pathway preferentially, whereas stimulation of the D2 receptor deactivates the indirect pathway.<sup>101,102</sup> Thus, the overall influence of dopamine appears to be to facilitate thalamo-cortical activation. However, there are marked differences in dopamine receptor distributions in the various regions of the striatum.<sup>103</sup> Therefore, dopamine acting in different regions of the striatum can have different effects on the direct/indirect pathway balance within a particular circuit, as well as the balance between parallel circuits involving different subcompartments of the striatum.

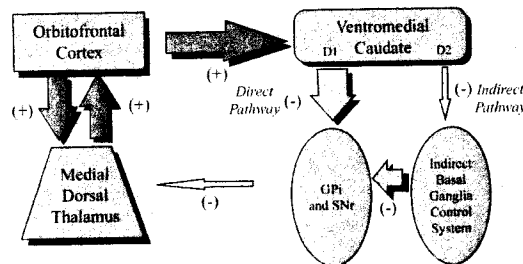
A function of the frontal-subcortical circuits passing through the striatum is the execution of prepackaged, complex, sequence-critical, response behaviors ("macros") that, to be adaptive, must be executed quickly in response to specific stimuli, to the exclusion of other responses dictated by interfering stimuli.<sup>4,5</sup> Naturally occurring activity along the direct pathway would tend to rivet behavior to the execution of the appropriate macros, until the need is judged passed. Conversely, activation of the indirect pathway may have as part of its function the suppression of direct pathway-driven behaviors when it is time to switch to another behavior—something OCD patients have difficulty doing.

#### *Model of OCD Pathophysiology: Imbalance of Direct > Indirect Pathway Tone in the Orbitofrontal-Subcortical Circuit*

Our present working model of the pathophysiology of OCD posits that in persons with OCD there is a response-bias toward stimuli relating to socioterritorial concerns about danger, violence, hygiene, order, sex, and so on—the themes of most obsessions in patients with OCD—mediated by orbitofrontal-subcortical circuits.<sup>4,5,7</sup> There is much experimental and clinical evidence that OFC is involved in the mediation of emotional responses to biologically significant stimuli, anticipatory anxiety, detection of errors, and social-affiliative behavior.<sup>104</sup> Patients with OCD have shown impaired performance on object alternation tasks,<sup>105</sup> consistent with dysfunction of the

OFC. Animal studies suggest that hoarding, another common OCD symptom, is mediated by the ventromedial striatum, GP, and medial dorsal thalamus,<sup>106</sup> structures connected with the OFC. Thus, the orbitofrontal-subcortical circuit appears to mediate voluntary, prospective control of behavior influenced by affectively charged memories and internal information. In normal individuals, socioterritorial concerns and responses to stimuli perceived as dangerous may be mediated by activity through the orbitofrontal-subcortical direct pathway, with appropriate inhibition from the indirect pathway. OCD patients, however, may have a low threshold for system capture by socioterritorial stimuli. This could be because of excess tone in the direct relative to the indirect orbitofrontal-subcortical pathway (Fig 3), allowing concerns about danger, violence, hygiene, order, sex, and so on to rivet attention to themselves, compelling patients to respond with ritualistic behavior, and resulting in an inability to switch to other behaviors. Such an imbalance of direct > indirect pathway tone would produce the hyperactive circuit seen in functional neuroimaging studies that mediates the repetitive, fixed behaviors relating to socioterritorial concerns in OCD.

It is unknown which brain structures may contain structural abnormalities that give rise to orbitofrontal-subcortical hyperactivity in OCD, but some evidence points to the striatum.<sup>55,56</sup> It is



**Figure 3.** Model of OCD pathophysiology. OCD symptomatology may be the result of a captured signal in the direct orbitofrontal-subcortical pathway, a positive feedback loop. This could be because of excess tone in the direct (large arrows) relative to the indirect (small arrows) orbitofrontal-subcortical pathway, resulting in increased activity in the orbitofrontal cortex, ventromedial caudate, and medial dorsal thalamus. This orbitofrontal-subcortical hyperactivity would allow concerns about danger, violence, hygiene, order, sex, and so on to rivet attention to themselves, compelling patients to respond with ritualistic behavior, and resulting in an inability to switch to other behaviors.

possible that there may be dysfunction involving the intrinsic structure of the striatum in patients with OCD. On a microstructural level, the striatum contains small, patchy compartments called striosomes, surrounded by a larger compartment called the matrix.<sup>100</sup> The striosomes are more concentrated in ventral and anterior part of the striatum,<sup>107</sup> are neurochemically specialized,<sup>108</sup> and receive preferential cortical input from the paralimbic posterior OFC and AC.<sup>109</sup> Striosomes exert a strong inhibitory influence on dopaminergic input from the SNc to the striatum and also send a small projection to the GPe, an important indirect pathway structure.<sup>110</sup> Thus, the striosomal compartment appears to provide negative feedback inhibition to the main frontal-subcortical circuits. Striosomes are selectively vulnerable to hypoxic-ischemic injury and, thus, could be preferentially damaged during brain development. Striosomal pathology has been implicated in Huntington's Disease (HD) a hyperkinetic movement disorder characterized by degeneration of the striatum. Neuropathologic studies have found selective degeneration of striosomes<sup>111</sup> and of the indirect pathway<sup>112</sup> early in the course of HD, resulting in excessive nigrostriatal dopaminergic input, creating an imbalance of direct versus indirect pathway activity. This imbalance is thought to mediate the choreiform movements, mood instability, and other early clinical manifestations of HD.<sup>112</sup> Abnormal development, loss, or dysfunction involving striosomes in the ventromedial caudate might result in an imbalance between direct and indirect pathways in the orbitofrontal-subcortical circuit, resulting in the symptoms of OCD, just as seen with other, parallel circuits in HD. Damage to striosomes or other areas of the striatum could potentially be produced by post-infectious anti-neuronal autoantibodies, thought to be implicated in at least a subset of patients with OCD.<sup>113,114</sup>

#### *Mechanism of Action of SRI's in OCD*

Currently, drugs that strongly inhibit serotonin reuptake are the only medications consistently proven effective in the treatment of OCD. We and others have previously hypothesized that SRI medications decrease activity in the orbitofrontal-subcortical circuit, possibly by changing the relative balance of activity through the indirect versus direct frontal-subcortical pathways,<sup>4,5,7,115</sup> thereby breaking the pathologic correlations along the circuit which existed in the sympto-

matic state.<sup>67,69</sup> Serotonin (5-HT), by virtue of its pattern of projections to cerebral cortex and basal ganglia structures, is in a position to influence the balance between direct versus indirect basal ganglia pathway activity, particularly for the associative and limbic frontal-subcortical circuits originating in the OFC and AC. The serotonergic innervation of the striatum is heavily concentrated in the ventromedial caudate and nucleus accumbens, precisely those subcompartments that receive input from the OFC and AC.<sup>116,117</sup> Serotonergic pathways from the midbrain also project strongly to subthalamic nucleus and globus pallidus,<sup>118</sup> key structures for the control of basal ganglia output.<sup>96</sup>

Serotonergic drugs may also exert their effect in the OFC. Recent work has shown differential effects of SRI drugs in OFC versus dorsal prefrontal cortex, in a time course that corresponds to the effects of these medications on OCD symptoms versus depressive symptoms. SRIs have been found both to enhance serotonin release and desensitize serotonin autoreceptors in the OFC after 8 weeks, but not 3 weeks, whereas effects in the dorsal prefrontal cortex occur after 3 weeks.<sup>119,120</sup> Given evidence by Baxter et al<sup>4</sup> showing in rodents that these 2 cortical regions have different effects on the direct and indirect basal ganglia pathways, the differential effects of serotonergic agents in the cerebral cortex alone could change the balance between direct versus indirect pathway tone, resulting in the decrease in overall activity in OFC, AC, and caudate seen in functional imaging studies of OCD responders to treatment.

The glucose metabolic decreases in OFC and caudate seen after successful treatment may reflect decreased release of excitatory neurotransmitters such as glutamate in these regions.<sup>75</sup> Studies have shown that 5-HT receptor activation can reduce the excitatory effect of glutamate on cellular activity.<sup>121</sup> This may be one mechanism by which SRI drugs decrease activity in the caudate, which receives much glutamatergic input from the cortex, as well as diminishing glutamatergic, thalamic excitation of the OFC.

#### *Possible Mechanisms of Action of CBT in OCD*

Very little is known about what brain mechanisms mediate the response to CBT in OCD or, for that matter, in any other psychiatric disorder. In pub-



lished reports to date, only 18 OCD patients have ever been studied with neuroimaging before and after CBT,<sup>67,69</sup> and only a few brain structures (caudate, thalamus, and OFC) were examined in those studies, precluding any firm conclusions about how CBT affects overall brain function. Nor is there adequate information from other psychiatric disorders or other investigative techniques in humans (eg, neuropsychological testing) about the brain mechanisms involved in response to CBT. Exposure and response prevention, the cognitive-behavioral technique most effective for OCD,<sup>122</sup> involves actively inhibiting urges to perform compulsions during exposure to stimuli that provoke obsessive fears. With time and repetition, patients habituate to the anxiety-provoking stimuli, their compulsive responses are extinguished, and their perception of danger is reduced. Schwartz<sup>123</sup> has speculated that tonically active neurons,<sup>124</sup> localized in the striatum at the borders of striosomes and matrix, might play a role in modifying striatal activity as the inhibition of habitual responses and the learning of new behavioral responses to fear-inducing stimuli take place. CBT might also activate associative, dorso-lateral prefrontal-subcortical circuits that stimulate the indirect basal ganglia control systems within the limbic frontal-subcortical circuits to mediate inhibition of compulsive responses. Clearly, much more investigation into the brain mechanisms of CBT and other effective psychotherapies is needed. Further studies of how psychotherapies affect neurochemistry, neuronal activity, and cognitive functioning will be of great importance in the future.

### Conclusions and Future Directions

Functional neuroimaging studies have advanced our understanding of brain-behavior relationships with respect to OCD greatly, but much is still unknown. Phenotypic heterogeneity could account for many of the inconsistencies among previous neuroimaging studies of OCD. Current studies are seeking to find the neurobiological substrates of specific OCD symptom factors, as well as predictors of treatment response. Future studies combining genetics and basic research with neuroimaging may further clarify the cause and pathophysiology of OCD. Although many lines of evidence point to dysfunction of orbitofrontal-subcortical circuitry in OCD, many questions re-

main unanswered. It has been suggested that orbitofrontal-subcortical hyperactivity in OCD may be the result of abnormal development of these structures or a failure of pruning of neuronal connections between them, as occurs in normal development.<sup>23</sup> However, no postmortem neuroanatomic studies of OCD exist to delineate its pathophysiology. Interventions that directly alter the indirect/direct pathway balance within frontal-subcortical circuits will allow for direct testing of the pathophysiologic hypotheses presented here. The roles of various neurochemical systems in OCD are similarly unclear. Although there is an abundance of indirect evidence suggesting serotonergic abnormalities in OCD, there is no direct evidence demonstrating what those abnormalities are, or whether they are primary or secondary phenomena in OCD. Currently ongoing studies of 5-HT synthesis in the brains of OCD patients<sup>125</sup> may shed light on this question.

### Acknowledgment

The authors thank several colleagues, especially Lewis R. Baxter, Jr., MD, who contributed greatly to the concepts and theories presented here.

### References

1. Cummings JL: Frontal-subcortical circuits and human behavior. *Arch Neurol* 50:873-880, 1993
2. Silbersweig DA, Stern E: Symptom localization in neuropsychiatry; A functional neuroimaging approach. *Ann NY Acad Sci* 835:410-20, 1997
3. Baxter LR: Neuroimaging studies of obsessive-compulsive disorder. *Psychiatric Clin N Am* 5:871-884, 1992
4. Baxter LR, Saxena S, Brody AL, et al: Brain mediation of obsessive-compulsive disorder symptoms: Evidence from functional brain imaging studies in the human and non-human primate. *Semin Clin Neuropsych* 1:32-47, 1996
5. Baxter LR, Ackermann RF, Swerdlow NR, et al: Specific brain system mediation of OCD responsive to either medication or behavior therapy, in Goodman W, Maser J (eds): NIMH-OC Foundation Monograph, Washington, NIMH-OC (in press)
6. Rauch SL, Baxter LR: Neuroimaging of OCD and related disorders, in Jenike MA, Baer L, Minichiello WE (eds): *Obsessive-Compulsive Disorders: Practical Management*. Boston, Mosby, 1998, pp 289-317
7. Saxena S, Brody AL, Schwartz JM, et al: Neuroimaging and frontal-subcortical circuitry in obsessive-compulsive disorder. *Br J Psychiatry* 173:26-38, 1998 (suppl 35)
8. Saxena S and Rauch SL: Functional neuroimaging and the neuroanatomy of obsessive-compulsive disorder. *Psychiatric Clin N Am* 23:1-21, 2000

9. Insel TR, Donnelly EF, Lalakea ML, et al: Neurological and neuropsychological studies of patients with obsessive-compulsive disorder. *Biol Psychiatry* 18:741-751, 1983
10. Behar D, Rapoport JL, Berg CJ, et al: Computerized tomography and neuropsychological test measures in adolescents with obsessive-compulsive disorder. *Am J Psychiatry* 141:363-369, 1984
11. Stein DJ, Hollander E, Chan S, et al: Computed tomography and neurological soft signs in obsessive-compulsive disorder. *Psychiatry Res* 50:143-150, 1993
12. Luxenberg JS, Swedo SE, Flamant MF, et al: Neuroanatomical abnormalities in obsessive-compulsive disorder determined with quantitative x-ray computed tomography. *Am J Psychiatry* 145:1089-1093, 1988
13. Scarone S, Colombo C, Livian S, et al: Increased right caudate nucleus size in obsessive-compulsive disorder: detection with magnetic resonance imaging. *Psychiatry Res* 45:115-121, 1992
14. Robinson D, Wu H, Munne RA, et al: Reduced caudate nucleus volume in obsessive-compulsive disorder. *Arch Gen Psychiatry* 52:393-398, 1995
15. Rosenberg DR, Keshavan MS, O'Hearn KM, et al: Frontostriatal measurement in treatment-naïve children with obsessive-compulsive disorder. *Arch Gen Psychiatry* 54:824-830, 1997
16. Kellner CH, Jolley RR, Holgate RC, et al: Brain MRI in obsessive-compulsive disorder. *Psychiatry Res* 36:45-49, 1991
17. Aylward EH, Harris GH, Hoehn-Saric R, et al: Normal caudate nucleus in obsessive-compulsive disorder assessed by quantitative neuroimaging. *Arch Gen Psychiatry* 53:577-584, 1996
18. Giedd JN, Rapoport JL, Garvey MA, et al: MRI assessment of children with obsessive-compulsive disorder or tics associated with streptococcal function. *Am J Psychiatry* 157:281-283, 2000
19. Peterson BS, Leckman JF, Tucker D, et al: Preliminary findings of antistreptococcal antibody titers and basal ganglia volumes in tic, obsessive-compulsive, and attention-deficit/hyperactivity disorders. *Arch Gen Psychiatry* 57:364-372, 2000
20. Garber HJ, Ananth JV, Chiu LC, et al: Nuclear magnetic resonance study of obsessive-compulsive disorder. *Am J Psychiatry* 146:1001-1005, 1989
21. Jenike MA, Breiter HC, Baer L, et al: Cerebral structural abnormalities in obsessive-compulsive disorder: A quantitative morphometric magnetic resonance imaging study. *Arch Gen Psychiatry* 53:625-632, 1996
22. Grachev I, Breiter HC, Rauch SL, et al: Structural abnormalities of frontal neocortex in obsessive-compulsive disorder. *Arch Gen Psychiatry* 55:181-182, 1998
23. Rosenberg DR, Keshavan MS: Toward a neurodevelopmental model of obsessive-compulsive disorder. A.E. Bennett Research Award. *Biol Psychiatry* 43:623-640, 1998
24. Szezeko PR, Robinson D, Ma J, et al: Orbital frontal and amygdala volume reductions in obsessive-compulsive disorder. *Arch Gen Psychiatry* 56:913-919, 2000
25. Rosenberg DR, Keshavan MS, Dick EL, et al: Corpus callosal morphology in treatment-naïve pediatric obsessive-compulsive disorder. *Prog Neuro-Psychopharmacol Biol Psychiatry* 21:1269-1283, 1997
26. MacMaster FP, Keshavan MS, Dick EL, et al: Corpus callosal signal intensity in treatment-naïve pediatric obsessive-compulsive disorders. *Prog Neuro-Psychopharmacol Biol Psychiatry* 23:601-612, 1999
27. Gilbert AR, Moore GJ, Keshavan MS, et al: Decrease in thalamic volumes of pediatric patients with obsessive-compulsive disorder who are taking paroxetine. *Arch Gen Psychiatry* 57:449-456, 2000
28. Peterson B, Riddle MA, Cohen DJ, et al: Reduced basal ganglia volumes in Tourette's syndrome using three-dimensional reconstruction techniques from magnetic resonance images. *Neurology* 43:941-949, 1993
29. Hyde TM, Stacey ME, Coppola RC, et al: Cerebral morphometric abnormalities in Tourette's syndrome: A quantitative MRI study in monozygotic twins. *Neurology* 45:1176-1185, 1995
30. Rubin RT, Villanueva-Meyer J, Ananth J, et al: Regional <sup>133</sup>Xe cerebral blood flow and cerebral <sup>99m</sup>-HMPAO uptake in unmedicated obsessive-compulsive disorder patients and matched normal control subjects: Determination by high-resolution single-photon emission computed tomography. *Arch Gen Psychiatry* 49:695-702, 1992
31. Sorenson JA, Phelps ME: *Physics in Nuclear Medicine*. Philadelphia, W.B. Saunders Co., 1987
32. Andreasen N: *Brain Imaging: Applications in Psychiatry*. Washington, DC, American Psychiatric Press, 1989
33. Maier M: In vivo magnetic resonance spectroscopy. *Br J Psychiatry* 167:299-306, 1995
34. Baxter LR, Phelps ME, Mazziotta JC, et al: Local cerebral glucose metabolic rates in obsessive-compulsive disorder—A comparison with rates in unipolar depression and in normal controls. *Arch Gen Psychiatry* 44:211-218, 1987
35. Baxter LR, Schwartz JM, Mazziotta JC, et al: Cerebral glucose metabolic rates in non-depressed obsessive-compulsives. *Am J Psychiatry* 145:1560-1563, 1988
36. Nordahl TE, Benkelfat C, Semple WE, et al: Cerebral glucose metabolic rates in obsessive-compulsive disorder. *Neuropsychopharmacol* 2:23-28, 1989
37. Swedo SE, Schapiro MG, Grady CL, et al: Cerebral glucose metabolism in childhood onset obsessive-compulsive disorder. *Arch Gen Psychiatry* 46:518-523, 1989
38. Sawle GV, Hymas NF, Lees AJ, et al: Obsessional slowness: Functional studies with positron emission tomography. *Brain* 114:191-2202, 1991
39. Perani D, Colombo C, Bressi S, et al: [<sup>18</sup>F]-FDG PET Study in obsessive-compulsive disorder: A clinical/metabolic correlation study after treatment. *Br J Psychiatry* 166:244-250, 1995
40. Martinot JL, Allilaire JF, Mazoyer BM, et al: Obsessive-compulsive disorder: A clinical, neuropsychological and positron emission tomography study. *Acta Psychiatrica Scandnav* 82:233-242, 1990
41. Baxter LR, Schwartz JM, Guze BH, et al: PET imaging in obsessive-compulsive disorder with and without depression. *J Clin Psychiatry* 51:61-69, 1990
42. Martinot JL, Allilaire JF, Mazoyer BM, et al: Left prefrontal glucose hypometabolism in the depressed state: A confirmation. *Am J Psychiatry* 147:1313-1317, 1990

43. Machlin SR, Harris GJ, Pearlson GD, et al: Elevated medial-frontal cerebral blood flow in obsessive-compulsive patients: A SPECT study. *Am J Psychiatry* 148:1240-1242, 1991
44. Adams BL, Warneke LB, McEwan AJB, et al: Single photon emission computerized tomography in obsessive-compulsive disorder: A preliminary study. *J Psychiatry Neurosci* 18:109-112, 1989
45. Lucey JV, Costa DC, Blanes T, et al: Regional cerebral blood flow in obsessive-compulsive disorder patients at rest: Differential correlates with obsessive-compulsive and anxious-avoidant dimensions. *Br J Psychiatry* 167:629-634, 1995
46. Lucey JV, Costa DC, Adshhead G, et al: Brain blood flow in anxiety disorders. OCD, panic disorder with agoraphobia, and post-traumatic stress disorder on 99mHMPAO single photon emission tomography (SPET). *Br J Psychiatry* 171:346-350, 1997
47. Crespo-Facorro B, Cabranes JA, Lopez-Ibor Alcocer MI, et al: Regional cerebral blood flow in obsessive-compulsive patients with and without chronic tic disorder. A SPECT study. *Eur Arch Psychiatry Clin Neurosci* 249:156-161, 1999
48. Riddle MA, Rasmussen AM, Woods SW, et al: SPECT imaging of cerebral blood flow in Tourette's syndrome, in Chase TN, Friedhoff AJ, Cohen DJ (eds): *Gilles de la Tourette Syndrome: Genetics, Neurobiology, and Treatment*. Advances in Neurology, vol. 58. New York, Raven Press, 1992, pp 207-211
49. Moriarty J, Eapen V, Costa DC, et al: HMPAO SPET does not distinguish obsessive-compulsive and tic syndromes in family multiply affected with Gilles de la Tourette's syndrome. *Psychol Medicine* 27:737-740, 1997
50. Braun AR, Stoetter B, Randolph C, et al: The functional neuroanatomy of Tourette's syndrome: An FDG-PET study. I. Regional changes in cerebral glucose metabolism differentiating patients and controls. *Neuropsychopharmacol* 9:277-291, 1993
51. Hall M, Costa DC, Shields J, et al: Brain perfusion patterns with 99mTc-HMPAO/SPET in patients with Gilles de la Tourette syndrome. Short report. *Nucl Med Suppl* 27:243-245, 1990
52. Heilman KM, Voeller KKS, & Nadeau SE: A possible pathophysiological substrate of attention deficit/hyperactivity disorder. *J Child Neurology* 6:S76-81, 1991 (suppl)
53. Zametkin AJ, Nordahl TE, Gross M, et al: Cerebral glucose metabolism in adults with hyperactivity of childhood onset. *N Engl J Med* 323:1361-1366, 1990
54. Birken D, Oldendorf WH: NAA: a literature review of a compound prominent in <sup>1</sup>H NMR spectroscopic studies of brain. *Neurosci Biobehav Rev* 13:23-31, 1989
55. Ebert D, Speck O, Konig A, et al: H-magnetic resonance spectroscopy in obsessive-compulsive disorder: Evidence for neuronal loss in the cingulate gyrus and the right striatum. *Psychiatry Res: Neuroimaging* 74:173-176, 1996
56. Bartha R, Stein MB, Williamson PC, et al: A short echo <sup>1</sup>H spectroscopy and volumetric MRI study of the corpus striatum in patients with obsessive-compulsive disorder and comparison subjects. *Am J Psychiatry* 155:1584-1591, 1998
57. Ohara K, Isoda H, Suzuki Y, et al: Proton magnetic resonance spectroscopy of lenticular nuclei in obsessive-compulsive disorder. *Psychiatry Res: Neuroimaging* 92:83-91, 1999
58. Fitzgerald KD, Moore GJ, Paulson LA, et al: Proton spectroscopic imaging of the thalamus in treatment-naive pediatric obsessive-compulsive disorder. *Biol Psychiatry* 47:174-182, 2000
59. Baer L: Factor analysis of symptom subtypes of obsessive-compulsive disorder and their relation to personality and tic disorders. *J Clin Psychiatry* 55:18-23, 1994 (suppl)
60. Leckman JF, Grice DE, Boardman J, et al: Symptoms of obsessive-compulsive disorder. *Am J Psychiatry* 154:911-917, 1997
61. Rauch SL, Dougherty DD, Shin LM, et al: Neural correlates of factor-analyzed OCD symptom dimensions: A PET study. *CNS Spectrums* 3:37-43, 1998
62. Ball SC, Baer L, Otto MW: Symptoms subtypes of obsessive-compulsive disorder in behavioral treatment studies: A quantitative review. *Behav Res Ther* 34:47-51, 1996
63. Benkelfat C, Nordahl TE, Semple WE, et al: Local cerebral glucose metabolic rates in obsessive-compulsive disorder: Patients treated with clomipramine. *Arch Gen Psychiatry* 47:840-848, 1990
64. Swedo SE, Pietrini P, Leonard HL, et al: Cerebral glucose metabolism in childhood-onset obsessive-compulsive disorder: Revisualization during pharmacotherapy. *Arch Gen Psychiatry* 49:690-694, 1992
65. Saxena S, Brody AL, Maidment KM, et al: Localized orbitofrontal and subcortical metabolic changes and predictors of response to paroxetine treatment in obsessive-compulsive disorder. *Neuropsychopharmacol* 21:683-693, 1999
66. Mindus P, Nyman H, Mogard J, et al: Orbital and caudate glucose metabolism studied by positron emission tomography (PET) in patients undergoing capsulotomy for obsessive-compulsive disorder, in Jenike MA, Asberg M (eds): *Understanding Obsessive-Compulsive Disorder (OCD)*. Toronto, Hogrefe and Huber Publishers, 1991, pp 52-57
67. Baxter LR, Schwartz JM, Bergman KS, et al: Caudate glucose metabolic rate changes with both drug and behavior therapy for obsessive-compulsive disorder. *Arch Gen Psychiatry* 49:681-689, 1992
68. Goodman WK, Price LH, Rasmussen SA, et al: The Yale-Brown Obsessive Compulsive Scale I. Development, use, and reliability. *Arch Gen Psychiatry* 46:1006-1011, 1989
69. Schwartz JM, Stoessel PW, Baxter LR, et al: Systematic changes in cerebral glucose metabolic rate after successful behavior modification treatment of obsessive-compulsive disorder. *Arch Gen Psychiatry* 53:109-113, 1996
70. Hoehn-Saric R, Pearlson GD, Harris GJ, et al: Effects of fluoxetine on regional cerebral blood flow in obsessive-compulsive patients. *Am J Psychiatry* 148:1243-1245, 1991
71. Rubin RT, Ananth J, Villanueva-Meyer J, et al: Regional <sup>133</sup>Xenon cerebral blood flow and cerebral Tc-HMPAO uptake in patients with obsessive-compulsive disorder

- before and after treatment. *Biol Psychiatry* 38:429-437, 1995
72. Rosenberg DR, MacMaster FP, Parrish JK, et al: Brain neurochemistry in pediatric obsessive-compulsive disorder. Presented at 3<sup>rd</sup> International OCD Conference, Madeira, Portugal, September 12, 1998
  73. Moore GJ, MacMaster FP, Stewart C, et al: Case study: Glutamatergic changes with paroxetine therapy for pediatric obsessive-compulsive disorder. *J Am Acad Child Adolesc Psychiatry* 37:663-667, 1998
  74. Brody AL, Saxena S, Schwartz JM, et al: FDG-PET predictors of response to behavioral therapy versus pharmacotherapy in obsessive-compulsive disorder. *Psychiatry Res: Neuroimaging* 84:1-6, 1998
  75. Rauch SL, Jenike MA, Alpert NM, et al: Regional cerebral blood flow measured during symptom provocation in obsessive-compulsive disorder using oxygen 15-labeled carbon dioxide and positron emission tomography. *Arch Gen Psychiatry* 51:62-70, 1994
  76. Breiter HC, Rauch SL, Kwong KK, et al: Functional magnetic resonance imaging of symptom provocation in obsessive-compulsive disorder. *Arch Gen Psychiatry* 49:595-606, 1996
  77. McGuire PK, Bench CJ, Frith CD, et al: Functional anatomy of obsessive-compulsive phenomena. *Br J Psychiatry* 164:459-468, 1994
  78. Cottraux J, Gerard D, Cinotti L, et al: A controlled positron emission tomography study of obsessive and neutral auditory stimulation in obsessive-compulsive disorder with checking rituals. *Psychiatry Res* 60:101-112, 1996
  79. Zohar J, Insel TR, Berman KF, et al: Anxiety and cerebral blood flow during behavioral challenge: Dissociation of central from peripheral and subjective measures. *Arch Gen Psychiatry* 46:505-510, 1989
  80. Hollander E, Prohovnik I, & Stein DJ: Increased cerebral blood flow during m-CPP exacerbation of obsessive-compulsive disorder. *J Neuropsychiatry Clin Neurosci* 7:485-490, 1995
  81. Stein DJ, Van Heerden B, Wessels C, et al: Single photon emission computed tomography with Tc-99 HMPAO during sumatriptan challenge in obsessive-compulsive disorder: Investigating the functional role of the serotonin autoreceptor. *Prog Neuro-Psychopharmacol Biol Psychiatry* 23:1079-1099, 1999
  82. Rauch SL, Savage CR, Alpert NM, et al: Probing striatal function in obsessive-compulsive disorder: A PET study of implicit sequence learning. *J Neuropsychiatry Clin Neurosci* 9:568-573, 1997
  83. Squire LR: Memory and the hippocampus: a synthesis of findings from rats, monkeys, and humans. *Psychol Rev* 99:195-231, 1992
  84. Rauch SL, Whalen PJ, Curran T, et al: Probing striato-thalamic function in OCD and TS using neuroimaging methods, in Cohen DJ, Goetz C, Jankovic J (eds): *Tourette Syndrome and Associated Disorders*. Philadelphia, Lippincott, Williams & Wilkins (in press)
  85. Lucey JV, Burness CE, Costa DC, et al: Wisconsin Card Sorting Task (WCST) errors and cerebral blood flow in obsessive-compulsive disorder (OCD). *Br J Medical Psychol* 70:403-411, 1997
  86. Pujol J, Torres L, Deus J, et al: Functional magnetic resonance imaging study of frontal lobe activation during word generation in obsessive-compulsive disorder. *Biol Psychiatry* 45:891-897, 1999
  87. Alexander GE, DeLong MR, & Strick PL: Parallel organization of functionally segregated circuits linking basal ganglia and cortex. *Ann Rev Neurosci* 9:357-381, 1986
  88. Rapoport JL & Wise SP: Obsessive-compulsive disorder: Is it a basal ganglia dysfunction? *Psychopharmacol Bull* 24:380-384, 1988
  89. Insel TR: Obsessive-compulsive disorder: A neuroethological perspective. *Psychopharmacol Bulletin* 24:365-369, 1988
  90. Modell JG, Mountz JM, Curtis GC, et al: Neurophysiologic dysfunction in basal ganglia/limbic striatal and thalamocortical circuits as a pathogenetic mechanism of obsessive-compulsive disorder. *J Neuropsychiatry Clin Neurosci* 1:27-36, 1989
  91. Baxter LR, Schwartz JM, Guze BH, et al: Neuroimaging in obsessive-compulsive disorder: Seeking the mediating neuroanatomy, in Jenike MA, Baer L, Minichiello W (eds): *Obsessive-Compulsive Disorders: Theory and Management*, Ed. 2. Chicago, Year Book Medical Publishers, 1990, pp 167-188
  92. Swerdlow NR, Koob GF: Dopamine, schizophrenia, mania and depression: Toward a unified hypothesis of cortico-striato-pallido-thalamic function. *Behav Brain Sci* 10:197-245, 1987
  93. Alexander GE, Crutcher MD: Functional architecture of basal ganglia circuits: Neural substrates of parallel processing. *TINS* 13:266-271, 1990
  94. Nauta WJH: Reciprocal links of the corpus striatum with cortex and limbic system: A common substrate for movement and thought?, in Muleller J (ed): *Neurology and Psychiatry: A Meeting of Minds*. New York, Karger, 1989, pp 3-9
  95. Saint-Cyr JA, Taylor AE: The mobilization of procedural learning: The "key signature" of the basal ganglia, in Squire LR, Butters N (eds): *Neuropsychology of Memory* (ed 2). New York, Guilford Press, 1992, pp 188-202
  96. Shink E, Bevan MD, Bolam JP, et al: The subthalamic nucleus and the external pallidum: Two tightly interconnected structures that control the output of the basal ganglia in the monkey. *Neuroscience* 73:335-357, 1996
  97. Smith Y, Hazrati L-N, Parent A: Efferent projections of the subthalamic nucleus in the squirrel monkey as studied by the PHA-L anterograde tracing method. *J Comp Neurol* 299:306-323, 1990
  98. Joel D & Weiner I: The connections of the primate subthalamic nucleus: Indirect pathways and the open-interconnected scheme of basal ganglia-thalamocortical circuitry. *Brain Res Rev* 23:63-78, 1997
  99. Mega M, Cummings JL: Frontal-subcortical circuits and neuropsychiatric disorders. *J Neuropsych Clin Neurosci* 6:358-370, 1994
  100. Graybiel AM: Neurotransmitters and neuromodulators in the basal ganglia. *TINS* 13:244-254, 1990
  101. Gerfen CR, Engber TM, Mahan LC, et al: D1 and D2 dopamine receptor-regulated gene expression of striatonigral and striatopallidal neurons. *Science* 250:1429-1432, 1990

102. O'Connor WT: Functional neuroanatomy of the basal ganglia as studied by dual-probe microdialysis. *Nuc Med Biol* 25:743-746, 1998
103. Hall H, Sedvall G, Magnusson O, et al: Distribution of D1 and D2 - dopamine receptors, and dopamine and its metabolites in the human brain. *Neuropsychopharmacol* 11:245-256, 1994
104. Zald DH, Kim SW: Anatomy and function of the orbital frontal cortex. I: Anatomy, neurocircuitry, and obsessive-compulsive disorder. *J Neuropsych Clin Neurosci* 8:125-138, 1996
105. Abbruzzese M, Bellodi L, Ferri S, et al: Frontal lobe dysfunction in schizophrenia and OCD: A neuropsychological study. *Brain Cognition* 27:202-212, 1995
106. Mogenson GJ, Wu M: Disruption of food hoarding by injections of procaine into mediodorsal thalamus, GABA into subpallidal regions, and haloperidol into accumbens. *Brain Res Bull* 20:247-251, 1988
107. Desban M, Kemel ML, Glowinski J, Gaucy C: Spatial organization of patch and matrix compartments in the rat striatum. *Neuroscience* 57:661-671, 1993
108. Besson MJ, Graybiel AM, Nastuk MA: [<sup>3</sup>H] SCH 23390 binding to D1 receptors in the basal ganglia of the cat and primate: Delineation of striosomal compartments and pallidal and nigral subdivisions. *Neuroscience* 26:101-119, 1988
109. Eblen F, Graybiel AM: Highly restricted origin of prefrontal cortical inputs to striosomes in the macaque monkey. *J Neurosci* 15:5999-6013, 1995
110. Gerfen CR: The neostriatal mosaic: Multiple levels of compartmental organization in the basal ganglia. *Ann Rev Neurosci* 115:285-320, 1992
111. Hedreen JC, Folstein SE: Early loss of neostriatal striosome neurons in Huntington's Disease. *J Neuropath Exper Neurol* 54:105-120, 1995
112. De Long MR: Primate models of movement disorders of basal ganglia origin. *TINS* 13:281-285, 1990
113. Murphy TK, Goodman WK, Fudge MW, et al: B lymphocyte antigen d8/17: A peripheral marker for Tourette's syndrome and childhood-onset obsessive-compulsive disorder? *Am J Psychiatry* 154:402-407, 1997
114. Swedo SE: Sydenham's chorea: A model for childhood autoimmune neuropsychiatric disorders. *JAMA* 272:1788-1791
115. Swerdlow NR: Serotonin, obsessive-compulsive disorder, and the basal ganglia. *Int Rev Psychiatry* 7:115-129, 1995
116. Insel TR: Toward a neuroanatomy of obsessive-compulsive disorder. *Arch Gen Psychiatry* 49:739-744, 1992
117. Parent A, Hazrati L-N: Functional anatomy of the basal ganglia I. The cortico-basal ganglia-thalamo-cortico loop. *Brain Res Rev* 20:91-127, 1995
118. Lavoie B, Parent A: Immunohistochemical study of the serotoninergic innervation of the basal ganglia in the squirrel monkey. *J Comp Neurol* 299:1-16, 1990
119. Mansari ME, Bouchard C, Blier P: Alteration of serotonin release in the guinea pig orbito-frontal cortex by selective serotonin reuptake inhibitors. *Neuropsychopharmacol* 13:117-127, 1995
120. Bergqvist PB, Bouchard C, Blier P: Effect of long-term administration of antidepressant treatments on serotonin release in brain regions involved in obsessive-compulsive disorder. *Biol Psychiatry* 45:164-74, 1999
121. Sizer AR, Kilpatrick GJ, Roberts MHT: A post-synaptic depressant modulatory action of 5-hydroxytryptamine on excitatory amino acid responses in rat entorhinal cortex in vitro. *Neuropharmacol* 31:5331-539, 1992
122. Marks IM: Review of behavioural psychotherapy. I: Obsessive-compulsive disorder. *Am J Psychiatry* 138:584-592, 1981
123. Schwartz JM: Neuroanatomical aspects of cognitive-behavioral therapy response in obsessive-compulsive disorder: An evolving perspective on brain and behavior. *Br J Psychiatry* 173:38-44, 1988 (suppl 35)
124. Aosaki T, Kimura M, Graybiel AM: Temporal and spatial characteristics of tonically active neurons of the primate striatum. *J Neurophys* 73:1234-1252, 1995
125. Benkelfat C, Leyton N, Okazawa H, et al: Brain regional rates of 5-HT synthesis in patients with obsessive-compulsive disorder. Presented at ACNP Annual Meeting, December 14, 1998, Las Croabas, Puerto Rico