

UCLA

UCLA Previously Published Works

Title

Orthognathic Consequences of Sphincter Pharyngoplasty in Cleft Patients

Permalink

<https://escholarship.org/uc/item/5q01t1t4>

Journal

Plastic & Reconstructive Surgery Global Open, 4(4)

ISSN

2169-7574

Authors

Yoshikane, Frances
Lai, Li Han
Hui, Brian K
[et al.](#)

Publication Date

2016-04-01

DOI

10.1097/gox.0000000000000656

Copyright Information

This work is made available under the terms of a Creative Commons Attribution-NonCommercial License, available at <https://creativecommons.org/licenses/by-nc/4.0/>

Peer reviewed



Orthognathic Consequences of Sphincter Pharyngoplasty in Cleft Patients: A 2-Institutional Study

Frances Yoshikane, BS*

Li Han Lai, DDS*

Brian K. Hui, DDS*

Deborah B. Martins, BS*

Gina Farias-Eisner, MD*

Rachel S. Mandelbaum, BS*

Han Hoang, MD*

James P. Bradley, MD†

Libby Wilson, MD‡

Justine C. Lee, MD, PhD*

Background: Understanding long-term sequelae of cleft treatment is paramount in the refinement of treatment algorithms to accomplish optimized immediate and long-term outcomes. In this study, we reviewed sphincter pharyngoplasties as a method of velopharyngeal insufficiency (VPI) treatment in relationship to orthognathic surgery.

Methods: Cleft lip/palate and cleft palate patients, 15 years of age and older, were reviewed for demographics, VPI surgery, revisions, and subsequent orthognathic surgery at 2 institutions. Chi-square test, Student's *t* test, and logistic regression analyses were performed.

Results: In 214 patients reviewed (mean age, 19.5 years), 61.7% were male, 18.2% had isolated cleft palate, 61.2% had unilateral cleft lip and palate, and 20.6% had bilateral cleft lip and palate. A total of 33.6% were diagnosed with VPI and received a sphincter pharyngoplasty (mean age, 11.9 years). When subsequent orthognathic surgery was examined, sphincter pharyngoplasty was not associated with maxillary advancement ($P = 0.59$) but did correlate with an increase in mandibular surgery from 2.8% to 11.1% ($P = 0.02$). The indications for mandibular surgery in the pharyngoplasty population were related to congenital micrognathia. When cephalometric analyses were evaluated, sphincter pharyngoplasty resulted in a decreased sella-to-nasion-to-B point angle (mean, 79.0–76.3 degrees, $P = 0.02$) and a higher incidence of normal to class II maxillomandibular relationships as defined by A point-to-nasion-to-B point angles >0.5 ($P = 0.02$).

Conclusions: Sphincter pharyngoplasty decreases anterior mandibular growth and the discrepancy between maxillomandibular skeletal relationships because of the frequent predisposition of cleft patients to maxillary hypoplasia. In patients with congenital mandibular micrognathia, a small increase in mandibular surgeries may occur. (*Plast Reconstr Surg Glob Open* 2016;4:e676; doi: 10.1097/GOX.0000000000000656; Published online 7 April 2016.)

Velopharyngeal insufficiency (VPI) is a significant speech dysfunction that occurs in 10% to 50% of cleft children secondary to deficiencies in palatal length and oropharyngeal dysmotility.^{1–5} The diagnostic criteria in most ma-

JOR cleft and craniofacial centers are hypernasal speech and nasoendoscopic confirmation of a gap on attempted oropharyngeal closure. After primary palatal reconstruction, a number of surgical and nonsurgical options have been well described to ad-

From the *Division of Plastic and Reconstructive Surgery, University of California Los Angeles David Geffen School of Medicine, Los Angeles, Calif.; †Division of Plastic and Reconstructive Surgery, Temple University, Philadelphia, Pa.; and ‡Craniofacial/Cleft Palate Program, Orthopaedic Hospital, Los Angeles, Calif.

Received for publication May 21, 2015; accepted February 2, 2016.

Presented at the 72nd Annual Meeting of the American Cleft Palate-Craniofacial Association, Palm Springs, Calif., April 20–25, 2015, and accepted for presentation at the

95th Annual Meeting of the American Association of Plastic Surgeons, New York City, N.Y., May 19–22, 2016.

Copyright © 2016 The Authors. Published by Wolters Kluwer Health, Inc. on behalf of The American Society of Plastic Surgeons. All rights reserved. This is an open-access article distributed under the terms of the Creative Commons Attribution-Non Commercial-No Derivatives License 4.0 (CCBY-NC-ND), where it is permissible to download and share the work provided it is properly cited. The work cannot be changed in any way or used commercially.

DOI: 10.1097/GOX.0000000000000656

dress VPI. Two of the most common methods are the pharyngeal flap and sphincter pharyngoplasty.⁴⁻¹¹

In the pharyngeal flap procedure, superiorly or inferiorly based posterior pharyngeal flaps are elevated and connected to the palate. This procedure thereby eliminates the anterior–posterior gap, tethers the palate to the posterior pharynx, and leaves 2 lateral openings of the oropharynx. For the sphincter pharyngoplasty procedure, the original 1950 description by Hynes included superiorly based musculomucosal flaps composed of the salpingopharyngeus muscle that was accessed within the nasopharynx after splitting the soft palate. These flaps were inset in an overlapping, double-breasted fashion into a transverse incision of the posterior pharynx. As the technique evolved, Hynes eventually included palatopharyngeus and superior constrictor muscles as part of the superiorly based flaps. These later modifications have largely stood the test of time and constitute the modern day sphincter pharyngoplasty.

The surgical indications for each procedure frequently depend on surgeon preference with variable consideration for differences in oropharyngeal wall motility.¹² Although the 2 techniques are generally matched in efficacy and safety with no statistically significant differences in outcome between them, historically, rare instances of mortality have been reported with pharyngeal flaps.^{3,13,14}

Maxillary hypoplasia in cleft patients results from a variety of intrinsic and extrinsic factors. Diminished intrinsic growth potential of the maxilla has been long suggested to exist in cleft children.¹⁵ As a readout of cleft severity, lateral incisor agenesis is now known to be an independent predictor of maxillary retrusion.¹⁶ Surgical and nonsurgical iatrogenic factors including lip repair, palate repair, alveolar bone grafting, and orthodontic maneuvers such as canine substitution have all been shown to also predict maxillary hypoplasia.^{17,18}

Despite the numerous outcomes studies on contributors to maxillary retrusion in cleft children, VPI surgery has received little attention. Orthognathic surgeons have observed that pharyngeal flaps may sometimes require division at the time of orthognathic procedures to allow for maxillary advancement.¹¹ Recently, the long-term effects of a variety of VPI surgery on maxillary growth in cleft patients have been examined in a single-institution retrospective study and suggested to increase LeFort I advancement.¹⁹

However, the strength of the correlation is limited by the small number of patients who needed maxillary advancement and variability in VPI correction. A previous study also came to a similar conclusion but looked at a much smaller cohort of 24 patients and was unable to make a definitive statement.²⁰

In this study, we investigate the effects of a modified Hynes sphincter pharyngoplasty correction of VPI in 2 cleft centers on subsequent orthognathic development and surgical correction.

METHODS

Patients

Patients with cleft lip and palate or isolated cleft palate at or near skeletal maturity (15 years of age or older) treated at the University of California Los Angeles Craniofacial Clinic and the Craniofacial/Cleft Palate Program at Orthopaedic Hospital were identified between the years of 2008 and 2014 (n = 214). Patients were retrospectively reviewed for demographics, VPI treatment, and pharyngoplasty revisions after lip/palate repair utilizing multidisciplinary team notes and operative reports. Patients who underwent orthognathic surgery or were recommended to have orthognathic surgery were recorded.

Correction of Velopharyngeal Insufficiency Using a Modified Hynes Sphincter Pharyngoplasty

At both institutions, VPI was diagnosed by 2 criteria: clinical evidence of hypernasality and nasendoscopy. Correction of VPI was performed using a modified Hynes technique. With retraction of the soft palate into the nasopharynx, the posterior pillars of the oropharynx including the mucosa, submucosa, palatopharyngeal, and the superior constrictor muscles were elevated down to the prevertebral fascia as superiorly based flaps. The pillars were then inset to Passavant's ridge in a double-breasted fashion narrowing the pharyngeal port. The donor sites were then closed in layers.

Lateral Cephalometric Analysis

Lateral cephalograms were obtained and traced by 2 or 3 independent evaluators. By using Steiner's analysis, skeletal relationships of the maxilla and mandible to the skull base were determined on lateral cephalograms using the A point-to-nasion-to-B point (ANB), sella-to-nasion-to-A point (SNA), and sella-to-nasion-to-B point (SNB) angles. Facial proportions and vertical relationships were estimated using upper facial height (nasion to A point)-to-lower facial height (A point to menton) ratio.

Disclosure: Supported by the Bernard G. Sarnat Endowment for Craniofacial Biology (J.C.L.). The Article Processing Charge was paid for by the authors.

Statistical Analysis

Statistical analyses were performed using STATA (StatCorp, College Station, Tex.). The primary outcome variable was orthognathic deficiencies, as determined by orthognathic surgery or the recommendation for correction and cephalometric analysis in patients who had previously been treated with sphincter pharyngoplasty. Chi-square analyses were used to compare groups based on the history of pharyngoplasty in relationship with Le Fort I advancement and bilateral sagittal split osteotomy. In addition, chi-square tests were used to compare those with pharyngoplasty revisions in relationship with Le Fort I advancement. Independent sample *t* tests were used to compare average cephalometric measurements between patients with and without previous sphincter pharyngoplasty. A $P < 0.05$ was considered significant for chi-square and *t* tests. Significant variables were subjected to univariate logistic regression analyses.

RESULTS

Patients and Descriptive Statistics

Two hundred fourteen patients from 2 institutions were evaluated at or near skeletal maturity with an average age of 19.5 years (range, 15–38 years; Table 1). Within this cohort, 61.7% were male, 18.2% had isolated cleft palate, 61.2% had unilateral cleft lip and palate, and 20.6% had bilateral cleft lip and palate.

Table 1. Demographics and Patient Characteristics

Age (y)	19.5 (15–38)
Male, n (%)	132 (61.7)
Cleft type, n (%)	
Isolated cleft palate	39 (18.2)
Cleft lip/palate	175
Unilateral	131 (61.2)
Right	47 (22.1)
Left	84 (39.4)
Bilateral	44 (20.6)
Velopharyngeal incompetence, n (%)	86 (40.1)
VPI before orthognathic surgery, n (%)	75 (35.0)
VPI after orthognathic surgery, n (%)	11 (5.1)
Age at pharyngoplasty (y)	11.9 (3.1–20.4)
Revision pharyngoplasties, n (%)	25 (29.1)
Maxillary Le Fort I advancement osteotomy, n (%)	104 (48.6)
Mandibular sagittal split osteotomy, n (%)	12 (5.6)

VPI, diagnosed by clinical hypernasality and nasoendoscopic evidence of incomplete oropharyngeal closure, was found in 40.1% of patients. Eleven patients (5.1%) were noted to have VPI after orthognathic surgery and were excluded. Sphincter pharyngoplasty was performed for all patients except 3 at an average age of 11.9 years (range, 3.1–20.4 years). Pharyngoplasty port revisions for either excessive airway obstruction or residual VPI after the first surgery were performed in 29.1% of patients. None of the patients experienced emergent airway complications.

Orthognathic Surgery after Sphincter Pharyngoplasty

Le Fort I advancement was required in 104 patients (48.6%) of the cohort because of maxillary retrusion (Table 1). A total of 5.6% received sagittal split osteotomies to address the mandible. The indications for mandibular surgery were evenly split between lateral deviation and mandibular retrusion.

To examine the relationship between sphincter pharyngoplasty and orthognathic surgery, chi-square analyses were performed (Table 2). In patients who received sphincter pharyngoplasties, Le Fort I advancement was required in 51.3%, whereas 47.5% of patients without VPI required Le Fort I advancement. This difference was not found to be statistically significant ($P = 0.59$). In contrast, 11.1% of patients who required sphincter pharyngoplasties went on to undergo mandibular surgery, whereas 2.8% of patients without VPI required sagittal split osteotomies ($P = 0.02$). Thus, sphincter pharyngoplasty did not demonstrate any relationships to maxillary advancement but did correlate to a small, statistically significant increase in mandibular surgery.

When we reviewed the indications for mandibular correction, all patients who required mandibular surgery had either lateral deviation of the mandible or congenital mandibular micrognathia that was noted even before sphincter pharyngoplasty. The characteristics of patients who underwent mandibular correction were not significantly different from the overall cohort in terms of cleft type. In addition, the types of clefts between patients who had mandibular surgery with and without sphincter pharyngoplasties did not differ significantly (Table 3). An increased number of patients were noted to have congenital mandibular

Table 2. Orthognathic Surgery after Sphincter Pharyngoplasty

Maxillary Surgery	No Maxillary Surgery	LeFort I	<i>P</i> Value
No pharyngoplasty, n (%)	74 (52.4)	67 (47.5)	0.59
Pharyngoplasty, n (%)	35 (48.6)	37 (51.3)	
Mandibular Surgery	No Mandibular Surgery	BSSO	<i>P</i> Value
No pharyngoplasty, n (%)	138 (97.2)	4 (2.8)	0.02
Pharyngoplasty, n (%)	64 (88.9)	8 (11.1)	

BSSO, bilateral sagittal split osteotomy.

micrognathia (5 of 8 patients; 62.5%) in patients who had pharyngoplasties versus patients who did not have pharyngoplasties (1 of 4 patients; 25%). Although the difference was not statistically significant, this may be partially reflective of the known increase in VPI seen in patients with Pierre Robin sequence.²¹

Maxillary and Mandibular Skeletal Relationships after Sphincter Pharyngoplasty

To determine the effects of sphincter pharyngoplasty on objective radiographic data, Steiner’s analysis was applied to 76 patients with lateral cephalograms at or near skeletal maturity (Table 4). In this analysis, the SNA angle was utilized to determine the anterior–posterior relationship of the maxilla to the skull base; the SNB was used to determine the anterior–posterior relationship of the mandible to the skull base; ANB was used to determine the anterior–posterior relationship between the maxilla and the mandible; and the upper facial height-to-lower facial height ratio (UFH:LFH) was used to determine the vertical growth relationships between the maxilla and the mandible.

For the entire cohort, SNA was found to be diminished with a mean of 76.1 degrees (range, 61.0–88.1 degrees; normal reference, 82±2). SNB was also found to be slightly diminished, albeit within normal reference ranges, at a mean of 78.2 degrees (range, 65.8–99.5 degrees; normal reference, 80±2). The ANB angle generally demonstrated a class III skeletal relationship between the maxilla and the mandible with a mean of –2.1 degrees (range, –20.5 to +9.5; normal reference, 2±1.5). The ratio of vertical growth as determined by UFH:LFH ratio also demonstrated a generally vertically foreshortened upper

face in comparison with the lower face with a mean of 0.78 (range, 0.42–1.07; normal reference, 0.95).

When comparing the differences in cephalometric analyses between patients who have undergone a sphincter pharyngoplasty versus those who have not, no statistically significant differences were noted in SNA ($P = 0.30$), ANB ($P = 0.20$), or UFH:LFH ratios ($P = 0.25$). Interestingly, SNB was found to be decreased to a mean of 76.3 degrees in patients who have had sphincter pharyngoplasties in contrast to 79.0 degrees in patients without pharyngoplasties ($P = 0.02$). Revision pharyngoplasties were not correlated to any statistically significant differences in cephalometric analyses.

To further stratify the anterior–posterior relationships of the mandible on skeletal analyses, patients were divided into groups with SNB < 79 indicative of a more posterior position of the mandible relative to the cranial base and ANB > 0.5 indicative of normal to class II skeletal relationships between the maxilla and the mandible (Table 5). A total of 45.2% of patients without pharyngoplasties were noted to have SNB < 79, whereas 73.9% of patients with pharyngoplasties were found to have SNB < 79 ($P = 0.02$). When patients were separated based on ANB > 0.5, 26.4% of patients without pharyngoplasties were found to have normal to class II relationships between the maxilla and the mandible, whereas 52.2% of patients with pharyngoplasties had these relationships ($P = 0.02$).

Logistic Regression Analyses with Dental Agenesis and Canine Substitution

To determine whether sphincter pharyngoplasty surgery is a predictor of mandibular surgery,

Table 3. Characteristics of Patients with Mandibular Surgery

	No Pharyngoplasty	Pharyngoplasty	P Value
Cleft palate, n (%)	1 (25)	2 (25)	1.00
Unilateral cleft lip and palate, n (%)	3 (75)	4 (50)	0.58
Bilateral cleft lip and palate, n (%)	0	2 (25)	0.52

Table 4. Cephalometric Analyses after Sphincter Pharyngoplasty

	Entire Cohort, Mean (Range)	No Pharyngoplasty, Mean (Range)	After Pharyngoplasty, Mean (Range)	P Value
SNA	76.1 (61.0 to 88.1)	76.5 (63.4 to 88.1)	75.1 (61 to 83.6)	0.30
SNB	78.2 (65.8 to 99.5)	79.0 (65.8 to 99.5)	76.3 (65.9 to 85)	0.02
ANB	–2.1 (–20.5 to +9.5)	–2.5 (–20.5 to +7.1)	–1.2 (–13.7 to +9.5)	0.20
UFH:LFH	0.78 (0.42 to 1.07)	0.77 (0.52 to 1.07)	0.79 (0.41 to 0.98)	0.25

Table 5. Stratified Anterior–Posterior Mandibular Relationships to the Skull Base and the Maxilla

	Entire Cohort, n (%)	No Pharyngoplasty, n (%)	After Pharyngoplasty, n (%)	P Value
SNB < 79	41 (53.9)	24 (45.2)	17 (73.9)	0.02
ANB > 0.5	26 (34.2)	14 (26.4)	12 (52.2)	0.02

Table 6. Sphincter Pharyngoplasty as a Predictor of Mandibular Surgery, Mild to Moderate Mandibular Retrusion, and Normal to Class II Maxillomandibular Discrepancy

	Odds Ratio	95% Confidence Interval	P Value
Mandibular surgery	4.31	1.25–14.85	0.02
SNB < 79	3.42	1.17–10.04	0.02
ANB > 0.5	3.83	1.28–11.47	0.02

mandibular retrusion as defined by SNB < 79, or ANB > 0.5, a logistic regression analysis was performed with all 3 outcomes (Table 6). Based on univariate analyses, sphincter pharyngoplasty surgery predicted mandibular surgery with an odds ratio of 4.31 [95% confidence interval (CI), 1.25–14.85, $P = 0.02$]. In addition, sphincter pharyngoplasty also predicted a more retrusive mandible as defined by SNB < 79 with an odds ratio of 3.42 (95% CI, 1.17–10.04, $P = 0.02$) and ANB > 0.5 with an odds ratio of 3.83 (95% CI, 1.28–11.47, $P = 0.02$).

DISCUSSION

In this study, the effects of sphincter pharyngoplasty on long-term orthognathic consequences were assessed at 2 cleft and craniofacial centers. In our 2 centers, the rate of VPI was 35% before orthognathic surgery. In the literature, the rate of VPI has been reported anywhere from 7% to 70%.^{22–25} This may be secondary to the types of clefts present in the cohort because severity is now known to be associated with a higher likelihood of VPI. Basta et al reported their long-term experience with a 15.8%

rate of VPI. However, their cohort had only 25% of patients with a Veau III or IV cleft, whereas our cohort had 81.8% with a Veau III or IV cleft.

Our data demonstrate no statistically significant association to maxillary development in terms of surgery or objective radiographic data. Surprisingly, we found a statistically significant decrease in the anterior–posterior relationship of the mandible to the skull base. Considering that cleft patients have a general tendency toward maxillary hypoplasia and class III occlusion, this effect actually improved the maxillomandibular discrepancies such that 52.2% of patients had ANB > 0.5. We detected a small but statistically significant increase in mandibular surgery, partially because of lateral deviation and partially because of preexisting mandibular pathology. However, it is important to note that the number of patients who require mandibular surgery, albeit significant, is ultimately small. Two questions arise from this study: (1) How does sphincter pharyngoplasty affect mandibular growth? (2) How can we use this information clinically?

On revisiting the anatomy of the oropharyngeal muscles, the superior constrictor muscles are notable in that they originate on the pterygoid hamulus, pterygomandibular raphe, and the mylohyoid line of the mandible and insert on the median raphe of the pharynx (Fig. 1). After elevation of the superiorly based flaps, parts of the superior constrictor muscles are elevated with the flaps. Closure of the donor site defects decreases the length of the superior constrictor muscles, thereby potentially adding an increased pull on the mandible because of the muscle attachments and scarring.

Although our results demonstrated an increased likelihood for a decreased anterior–posterior re-

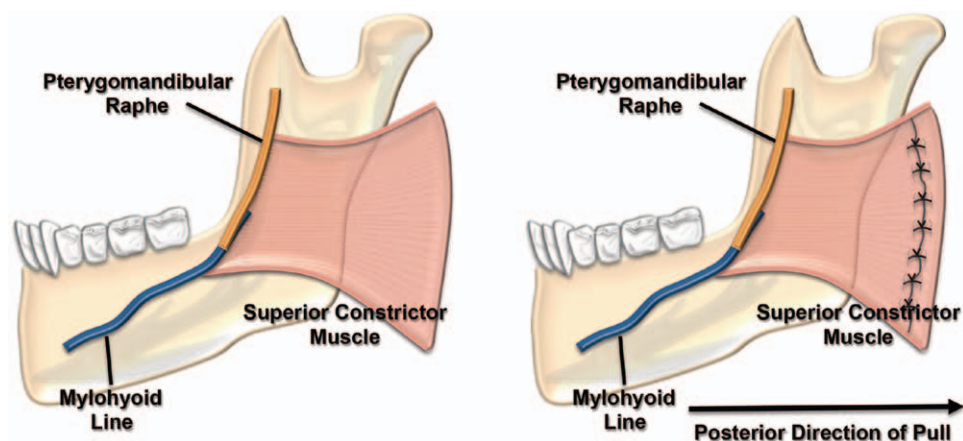


Fig. 1. Anatomy of the superior constrictor muscle before and after pharyngoplasty. The normal origin of the superior constrictor muscle on the pterygomandibular raphe and the mylohyoid line of the mandible is demonstrated on the lingual surface of the mandible (left). After pharyngoplasty, a portion of the superior constrictor muscle is elevated with the flaps. Closure of the donor site defects thereby exerts a posterior force on the mandible (right).

relationship of the mandible to the skull base as defined as an SNB < 79, one should note that maxillary hypoplasia exists frequently in cleft children, especially those who have undergone first world surgical corrections. Thus, decreases in mandibular prognathism may potentially improve facial harmony in such children. This is consistent with the radiographic data that found a higher prevalence of ANB > 0.5. However, the fact that sagittal split osteotomies are increased in this population suggests that the ultimate effects on the pharyngoplasty procedure on the mandible need to be carefully considered. Although the majority of sagittal split osteotomies in the nonpharyngoplasty population were secondary to lateral deviation, there was an increased number of patients in the pharyngoplasty group that had preexisting congenital mandibular pathology. The difference was not statistically significant because of the small number of patients who required mandibular surgery. However, it is likely that in children who have congenital mandibular hypoplasia, sphincter pharyngoplasty may exert an additive effect on retrognathia.

In recent years, many have advocated differential utilization of pharyngeal flaps or sphincter pharyngoplasties dependent on the results of nasendoscopy.³ In both of our centers, sphincter pharyngoplasties are utilized for VPI regardless of the oropharyngeal wall movement deficiencies noted. We have chosen this protocol because of 2 reasons: (1) the anatomic basis of the oropharyngeal muscle sphincter and (2) the known potential for airway emergencies after pharyngeal flap procedures. The oropharyngeal sphincter is a circular ring consisting of the palate anteriorly and the palatopharyngeal/superior constrictor muscles laterally and posteriorly. Thus, regardless of wall movement, decreases in the area of this circular ring automatically decrease the airflow and closure of the sphincter. However, admittedly, one weakness due to these practices is that we cannot compare our results to repair with pharyngeal flaps within our respective institutions. Secondly, the small but real potential for airway emergencies after pharyngeal flap procedures are important to note. Considering that speech surgery is an elective, nonemergent procedure, every effort should be made to avoid life-threatening complications, however rare they may be. To our knowledge, airway emergencies have not been reported for the sphincter pharyngoplasty in the literature.

Finally, our present data suggest a third argument for utilizing sphincter pharyngoplasties for VPI. In the report by the Erasmus group, pharyngeal flaps have been associated with maxillary hypoplasia.¹⁹ Although their group pooled data from at least 3

different techniques for VPI correction, their conclusions are consistent with the clinical observations made by our group and other surgeons of the tethering of the maxilla by pharyngeal flaps such that division is necessary for maxillary advancement. Although sphincter pharyngoplasties may have a mild effect on the mandible, the lack of association with maxillary growth is important specifically in the cleft population as they are already prone to maxillary hypoplasia.

Justine C. Lee, MD, PhD

Division of Plastic and Reconstructive Surgery
University of California Los Angeles
200 Medical Plaza, Suite 465
Los Angeles, CA 90095
E-mail: justine@ucla.edu

REFERENCES

1. Inman DS, Thomas P, Hodgkinson PD, et al. Oro-nasal fistula development and velopharyngeal insufficiency following primary cleft palate surgery—an audit of 148 children born between 1985 and 1997. *Br J Plast Surg*. 2005;58:1051–1054.
2. Bicknell S, McFadden LR, Curran JB. Frequency of pharyngoplasty after primary repair of cleft palate. *J Can Dent Assoc*. 2002;68:688–692.
3. Ysunza A, Pamplona C, Ramírez E, et al. Velopharyngeal surgery: a prospective randomized study of pharyngeal flaps and sphincter pharyngoplasties. *Plast Reconstr Surg*. 2002;110:1401–1407.
4. Hynes W. Observations on pharyngoplasty. *Br J Plast Surg*. 1967;20:244–256.
5. Hynes W. The results of pharyngoplasty by muscle transplantation in failed cleft palate cases, with special reference to the influence of the pharynx on voice production; Hunterian lecture, 1953. *Ann R Coll Surg Engl*. 1953;13:17–35.
6. Schoenborn K. Vorstellung eines Falles von Staphyloplastik. Vol. 15. *Verh dtsch Ges Chir*. 1886;57–62.
7. Padgett EC. The repair of cleft palates after unsuccessful operations. Vol. 20. *Arch Surg*. 1930:453–472.
8. Orticochea M. Construction of a dynamic muscle sphincter in cleft palates. *Plast Reconstr Surg*. 1968;41:323–327.
9. Orticochea M. A review of 236 cleft palate patients treated with dynamic muscle sphincter. *Plast Reconstr Surg*. 1983;71:180–188.
10. Hynes W. Pharyngoplasty by muscle transplantation. *Br J Plast Surg*. 1950;3:128–135.
11. Jackson IT, Silverton JS. The sphincter pharyngoplasty as a secondary procedure in cleft palates. *Plast Reconstr Surg*. 1977;59:518–524.
12. Moss AL, Pigott RW, Alberty EH. Hynes pharyngoplasty revisited. *Plast Reconstr Surg*. 1987;79:346–355.
13. Graham WP III, Hamilton R, Randall P, et al. Complications following posterior pharyngeal flap surgery. *Cleft Palate J*. 1973;10:176–180.
14. Jackson P, Whitaker LA, Randall P. Airway hazards associated with pharyngeal flaps in patients who have the Pierre Robin syndrome. *Plast Reconstr Surg*. 1976;58:184–186.
15. Good PM, Mulliken JB, Padwa BL. Frequency of Le Fort I osteotomy after repaired cleft lip and palate or cleft palate. *Cleft Palate Craniofac J*. 2007;44:396–401.

16. Lai LH, Hui BK, Nguyen PD, et al. Lateral incisor agenesis predicts maxillary hypoplasia and Le Fort I advancement surgery in cleft patients. *Plast Reconstr Surg*. 2015;135:142e–148e.
17. Ross RB. Treatment variables affecting facial growth in complete unilateral cleft lip and palate. *Cleft Palate J*. 1987;24:5–77.
18. Lee JC, Slack GC, Walker R, et al. Maxillary hypoplasia in the cleft patient: contribution of orthodontic dental space closure to orthognathic surgery. *Plast Reconstr Surg*. 2014;133:355–361.
19. Voshol IE, van Adrichem LN, van der Wal KG, et al. Influence of pharyngeal flap surgery on maxillary outgrowth in cleft patients. *Int J Oral Maxillofac Surg*. 2013;42:192–197.
20. Eskenazi LB, Schendel SA. An analysis of Le Fort I maxillary advancement in cleft lip and palate patients. *Plast Reconstr Surg*. 1992;90:779–786.
21. Filip C, Feragen KB, Lemvik JS, et al. Multidisciplinary aspects of 104 patients with Pierre Robin sequence. *Cleft Palate Craniofac J*. 2015;52:732–742.
22. Hosseinabad HH, Derakhshandeh F, Mostajeran F, et al. Incidence of velopharyngeal insufficiency and oronasal fistulae after cleft palate repair: a retrospective study of children referred to Isfahan Cleft Care Team between 2005 and 2009. *Int J Pediatr Otorhinolaryngol*. 2015;79:1722–1726.
23. Yuan N, Dorafshar AH, Follmar KE, et al. Effects of cleft width and Veau type on incidence of palatal fistula and velopharyngeal insufficiency after cleft palate repair. *Ann Plast Surg*. 2015.
24. Ha S, Koh KS, Moon H, et al. Clinical outcomes of primary palatal surgery in children with nonsyndromic cleft palate with and without lip. *Biomed Res Int*. 2015;2015:185459.
25. Basta MN, Silvestre J, Stransky C, et al. A 35-year experience with syndromic cleft palate repair: operative outcomes and long-term speech function. *Ann Plast Surg*. 2014;73(Suppl 2):S130–S135.