

UC Davis

UC Davis Previously Published Works

Title

Echocardiographic Features of Giant Right Atrial Diverticulum in a Dog

Permalink

<https://escholarship.org/uc/item/5pq5j434>

Journal

Journal of Veterinary Internal Medicine, 31(3)

ISSN

0891-6640

Authors

Park, S
Kittleson, MD
Yu, D
[et al.](#)

Publication Date

2017-05-01

DOI

10.1111/jvim.14712

Peer reviewed

Case Report

J Vet Intern Med 2017;31:879–883**Echocardiographic Features of Giant Right Atrial Diverticulum in a Dog**S. Park, M.D. Kittleson, D. Yu, and J. Choi 

A 12-year-old spayed female miniature Poodle presented for coughing, respiratory distress, and anorexia. After thoracocentesis for pleural effusion, radiography revealed an enlarged cardiac silhouette with a bulge in the area of the body of the right atrium. Echocardiography revealed an anechoic chamber-like cavity lateral to the right atrium that communicated with the right atrium through a 13 mm defect in the right atrial free wall. Contrast echocardiography and color flow Doppler were used to prove that the cavity communicated with the right atrium. The cavity was diagnosed as a giant right atrial diverticulum.

Key words: Atrium; Bubble; Canine; Diverticula.

A 12-year-old spayed female miniature Poodle presented for a nonproductive cough, respiratory distress, and anorexia for 2 weeks. There was no history of trauma. Upon physical examination, systolic blood pressure was 156 mmHg and heart rate was 150–160 beats/min. A heart murmur was not auscultated. CBC revealed mild anemia (hematocrit, 28.8%; reference range 37.3–61.7%). There was hyponatremia (135.6 mmol/L; reference range 140–150 mmol/L) and hypochloremia (103.8 mmol/L; reference range 109–120 mmol/L). Serum biochemical variables and D-dimer^a concentration (0.2 mg/L; reference range 0–0.3 mg/L) were within the reference range.

Thoracic radiographs revealed a large amount of pleural effusion. Approximately 200 mL of fluid obtained via thoracocentesis was consistent with a modified transudate with 720 nucleated cells/ μ L. After thoracocentesis, an enlarged cardiac silhouette with a bulge in the area of the body of the right atrium was detected on radiography (Fig 1). Abdominal radiographs showed hepatomegaly with a small amount of ascites. On echocardiography,^b the right atrial and ventricular chambers were approximately twice the size of the left atrial and ventricular chambers (Fig 2A). The

Abbreviations:

D	diverticulum
LA	left atrium
LV	left ventricle
RA	right atrium
RV	right ventricle

interventricular septum was flattened in diastole but not in systole and showed paradoxical septal motion (Fig 3). An anechoic cavity, which looked like a “third chamber”, was identified lateral to the right atrium (Fig 2). The cavity communicated with right atrium through a 13-mm defect in the right atrial free wall. There was also an approximately 2-cm-long linear hyperechoic structure attached to the edge of the defect that had a valve-like movement. In addition, there were hyperechoic structures (2–3 mm in diameter) attached to the internal wall of the cavity (Fig 2B). It was thought that both structures were most likely thrombi. The cavity was approximately 2.5×1.9 cm in size, twice the size of the right atrium. The wall was thin. The tricuspid valve leaflets were mildly thickened, and there was mild regurgitation. The peak velocity of the tricuspid regurgitant jet was within normal limits at 2.5 m/s (peak pressure gradient = 25 mmHg). The caudal vena cava did not collapse with respiration. On color flow Doppler, blood flow moved from the right atrium into the cavity and from the cavity into the right ventricle during the cardiac cycle (Fig 4). Bubble contrast echocardiography using agitated saline was performed after a 3-way stopcock was connected to a cephalic vein catheter. Two syringes, one containing 10 mL 0.9% NaCl solution and the other empty one, were connected to the 3-way stopcock. The saline was rapidly injected into between the 2 syringes several times, and the agitated saline was injected rapidly to document that blood flowed from the right atrium into this “third chamber” (Fig 5).

The microbubbles appeared first in the right atrium and then 1–2 seconds later in the cavity/chamber and the right ventricle (Video S1). The bubbles then were seen to swirl within the right atrium and cavity. The cavity was diagnosed as a giant right atrial diverticulum.

From the College of Veterinary Medicine and BK 21 Plus Project Team, College of Veterinary Medicine, Chonnam National University, Gwangju, Korea (Park, Yu, Choi); Department of Medicine and Epidemiology, School of Veterinary Medicine, University of California Davis, Davis, CA (Kittleson).

The work was done at the College of Veterinary Medicine, Chonnam National University, South Korea.

This case was presented at the 2016 Congress of the Korean Society of Veterinary Clinics, May 21–22, 2016, Seoul, South Korea.

Corresponding author: J. Choi, College of Veterinary Medicine, Chonnam National University, Yongbong-ro, Buk-gu, Gwangju 500-757, Korea; e-mail: imsono@jnu.ac.kr.

Submitted December 12, 2016; Revised February 3, 2017; Accepted March 9, 2017.

Copyright © 2017 The Authors. *Journal of Veterinary Internal Medicine* published by Wiley Periodicals, Inc. on behalf of the American College of Veterinary Internal Medicine.

This is an open access article under the terms of the Creative Commons Attribution-NonCommercial License, which permits use, distribution and reproduction in any medium, provided the original work is properly cited and is not used for commercial purposes.

DOI: 10.1111/jvim.14712

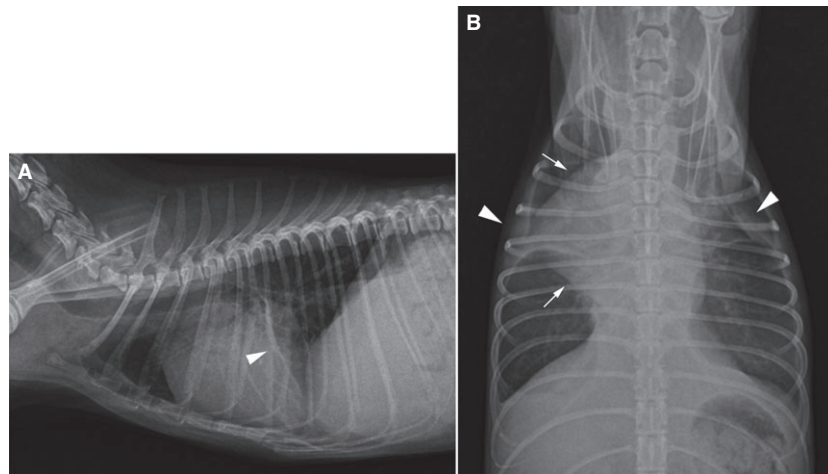


Fig 1. Right lateral (A) and ventrodorsal (B) thoracic radiographs of the dog after thoracocentesis. Note the enlarged cardiac silhouette with a bulge in the area of the right atrium (arrow). Vertebral heart scale is 11.6 vertebrae on right lateral view. A small amount of pleural effusion remained (arrow heads).

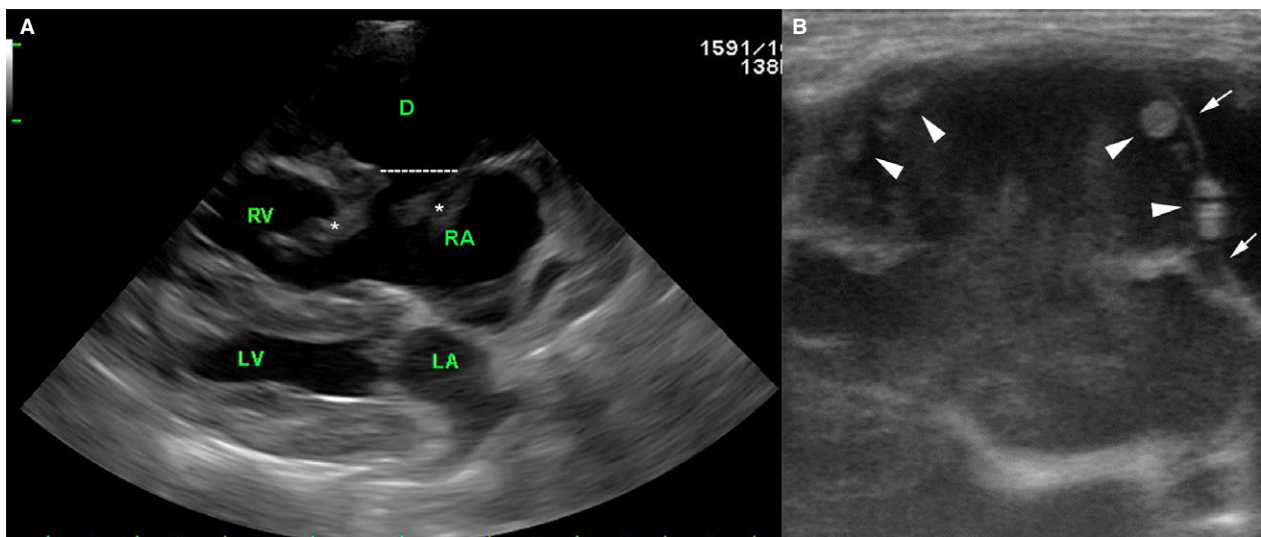


Fig 2. Echocardiogram (right parasternal long-axis 4-chamber view) showing an anechoic chamber-like cavity lateral to the right atrium (A) and a zoomed image of the cavity (B). The cavity communicates with right atrium through a 13-mm opening in the right atrial free wall (dotted line). Long (approximately 2 cm) linear hypoechoic structures attach to the edge of the defect. These structures moved throughout the cardiac cycle and resembled a valve moving (asterisks). The cavity is approximately 2.5×1.9 cm in size, twice that of the body of the right atrium, and is surrounded by a thin wall (arrow). In the cavity, 2–3 mm hyperechoic, round structures attach to the internal wall (arrow heads). The right atrium and ventricle were dilated to approximately twice the size of the left atrium and ventricle. D, diverticulum (chamber-like cavity); LA, left atrium; LV, left ventricle; RA, right atrium; RV, right ventricle.

The dog's respiratory distress resolved after thoracocentesis. The dog was treated with furosemide^e 2 mg/kg, PO, q12h; spironolactone^d 0.5 mg/kg, PO, q12h; pimobendan^e 0.5 mg/kg, PO, q12h. However, after 2 weeks, her condition deteriorated again with the recurrence of pleural effusion. After repeated thoracocenteses had been performed every week for 2 weeks, the treatment was withdrawn at the owner's request. The dog was then lost to follow-up.

Right atrial diverticulum is a saccular structure that protrudes from the right atrial free wall or right atrial

appendage.¹ It is thought to be a congenital malformation created by an aneurysmal outpouching of the endomyocardium of the right atrium or right atrial appendage. However, the exact etiology is unknown and controversial.^{2–4} Right atrial diverticula have been reported in both young and old humans. Despite it being seen in older humans, it is still assumed to be a congenital disease.³ Right atrial diverticulum is rare and data on the incidence or prevalence of this deformity is not available because only 18 cases have been reported in humans. The sizes of diverticula reported

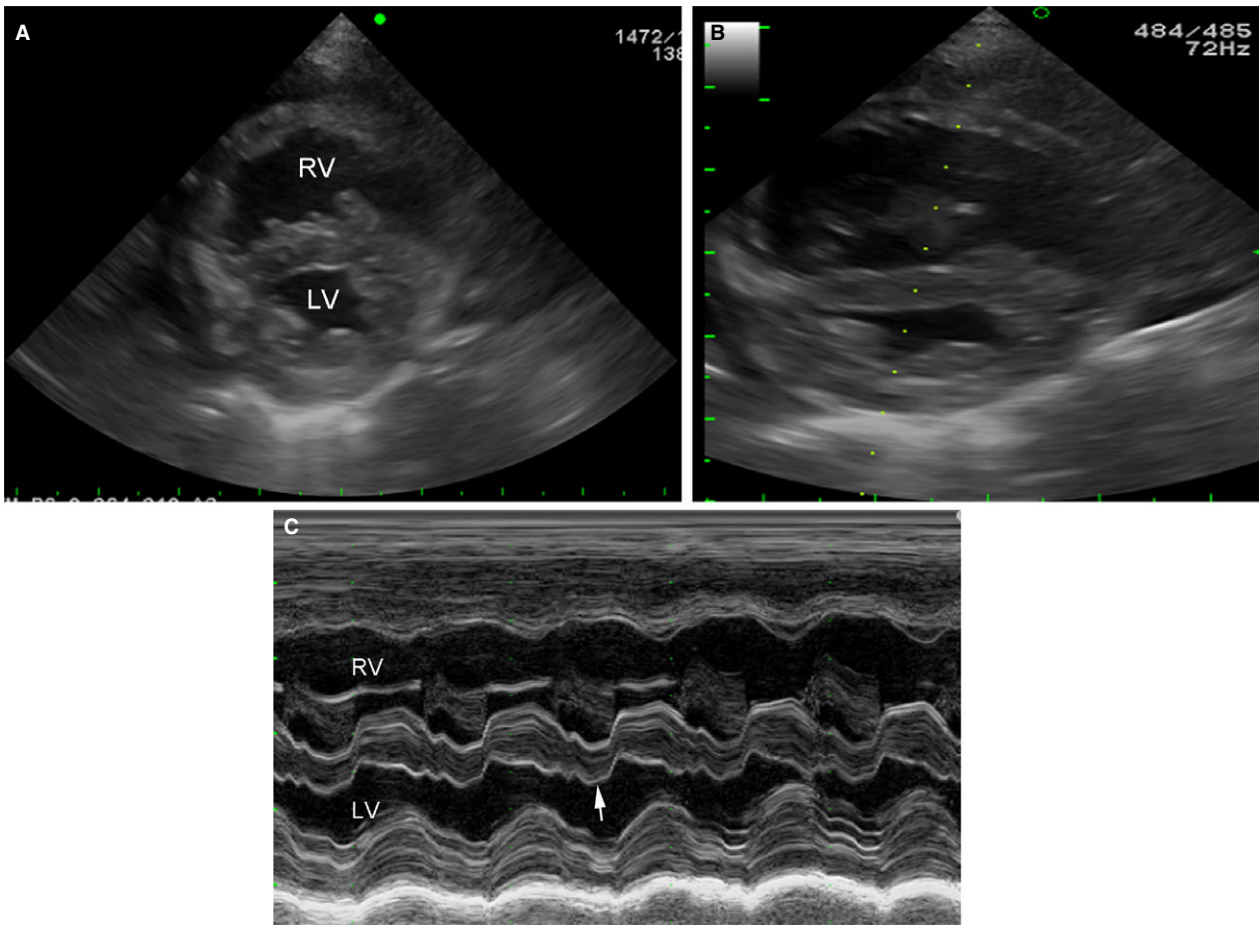


Fig 3. Echocardiogram (right parasternal short-axis transventricular view) showing the paradoxical septal motion on 2-dimensional (A, systolic phase; B, diastolic phase) and M-mode (C). Note the flattened interventricular septum, dilated right ventricular chamber, decreased left ventricular chamber size, and diastolic movement of the interventricular septum to the left ventricular free wall (arrow). LV, left ventricle; RV, right ventricle.

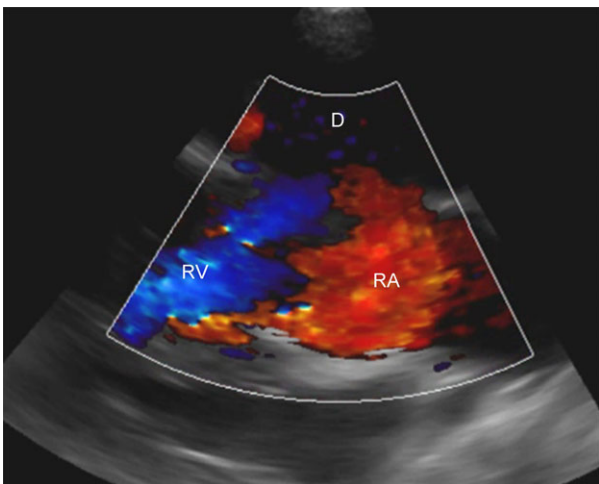


Fig 4. Echocardiogram (oblique right parasternal long-axis 4-chamber view) in color Doppler mode using the blue away and red toward map. Note the blood flow leaving the right atrium toward the cavity and leaving away from the cavity.

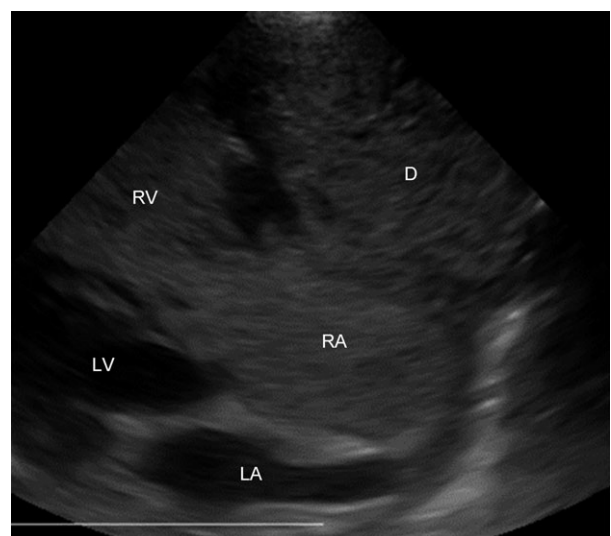


Fig 5. Contrast echocardiogram using agitated saline (oblique right parasternal long-axis 4-chamber view) showing the microbubbles appearing in the right atrial diverticulum, right atrium, and right ventricle. D, diverticulum (chamber-like cavity); LA, left atrium; LV, left ventricle; RA, right atrium; RV, right ventricle.

are variable and the largest one was $10 \times 6 \times 8$ cm.¹ Most of them originated from the atrial free wall and communicated with right atrial cavity through a neck-like structure.

In addition to diverticula, there are also aneurysms of the right auricle. An aneurysm is defined as a dilation that involves all layers of the atrial wall, while a diverticulum has an entry (orifice) from the atrium into the cavity.⁵ Right auricular aneurysm has been reported previously in 3 dogs.^{6,7}

A right atrial diverticulum has not been reported previously in dogs. This case had an orifice connecting the body of the right atrium to the diverticulum. The only right atrial diverticulum case in the veterinary literature is a 5-month-old foal that presented in respiratory distress. The right atrial diverticulum was diagnosed at necropsy.⁸

Radiographically a right auricular aneurysm shows up as a mass-like lesion in the cranial mediastinum.⁷ In theory, a right atrial diverticulum could show up the same way if the diverticulum originated from the auricle. In our case, the primary radiographic finding was a bulge in the area of the body right atrium at 9–10 o'clock on the cardiac clock face on a ventrodorsal thoracic radiograph.

In humans, the diagnosis of right atrial diverticulum is usually made by transthoracic or transesophageal echocardiography. In addition, angiography, computed tomography, and magnetic resonance imaging have been used.^{1,9–11} Echocardiographic features of right atrial diverticula are an echolucent cavity adjacent to the right atrium with an orifice between the 2 chambers/cavities.^{9,10} This cardiac deformity might be confused with a more familiar abnormality, such as cor triatriatum dexter, as both have 2 right atrial chambers. The core of the diagnosis of right atrial diverticulum is the communication of the cavity with the right atrium or auricle through a neck-like structure.¹ Flow between the 2 can be demonstrated by both color flow Doppler and contrast echocardiography.^{9,10} The communication of the cavity and right atrium could be ascertained on 2-dimensional and color Doppler ultrasonography in this case because the defect between 2 chambers was large enough to identify blood flow through it. The contrast echocardiogram confirmed that the blood flow initially entered the right atrium and then went into the cavity. After that, the blood flow returned into the right atrium and went into the right ventricle through tricuspid valve.

The size of the diverticulum in humans is variable.¹ In our case, the cavity extended over the surface of right ventricle similar with that of a giant atrial diverticulum in humans.^{2,10} The cavity in this case was too large to determine whether it contracted during the cardiac cycle, although right atrial diverticula can be seen to contract during atrial systole in some human patients.^{5,10} Hyperechoic linear structures were lodged at the walls of the orifice between the right atrial diverticulum and right atrium. They had a valve-like motion, but this was almost assuredly passive motion of thrombi by blood flow. Multiple round structures

attached to the internal surface of the cavity were also assumed to be thrombi created by the blood stasis within the diverticulum.

Mild tricuspid regurgitation may have developed due to incomplete coaptation of the tricuspid valve leaflets due to the dilated annulus of the valve. Right atrial pressure was assumed to be >15 mmHg because the caudal vena cava did not collapse at all during respiration. The estimated pressure gradient using the tricuspid regurgitant jet velocity was 25 mmHg, and pulmonary artery pressure was estimated to be at least 41 mmHg (mild pulmonary hypertension). This dog had pleural effusion, a small amount of ascites, and diastolic flattening of the interventricular septum, all suggestive of right heart failure. The origin of that failure cannot be easily explained. The presence of probable thrombi in the diverticulum should have made the dog prone to pulmonary thromboembolism. Pulmonary thromboembolism severe enough to result in right heart failure most commonly does so by creating severe pulmonary hypertension.¹² However, the velocity of the tricuspid regurgitant jet was normal, which should rule out severe pulmonary hypertension due to pulmonary thromboembolism. But it is possible that the measurement of the tricuspid regurgitant jet velocity was inaccurate. Another possible explanation revolves around the fact that the left ventricle was smaller than normal. This volume underload of the left ventricle can be caused by reduced right ventricular stroke volume and so cardiac output.¹³ If the right heart cardiac output was so compromised by the diverticulum and acute pulmonary thromboembolism, it is also possible that the pressure was artefactually low. This theory is supported by the low flow velocity in the right ventricular outflow tract/pulmonary artery.

In humans, a right atrial diverticulum is frequently silent. Some patients present with chest discomfort/pain, respiratory distress, atrial tachyarrhythmia, or atrial fibrillation. Congestive heart failure and sudden death occasionally occur.^{1,6,8} Tachycardia may be caused by abnormal impulses generated within the abnormal diverticular wall. Thrombus formation and resultant pulmonary thromboembolism can also occur.¹⁴ Several thrombi were suspected to lie within the diverticulum on echocardiography of this case although D-dimer level was in the reference range. The diverticulum can be so large that it compresses the right atrium and ventricle.¹⁵ This case showed serious clinical signs associated with congestive heart failure.

In conclusion, right atrial diverticulum is a rare cardiac deformity never before reported in a dog. It should be a diagnostic consideration if a “third chamber” is found adjacent to the body of the right atrium or right atrial appendage. Echocardiographic features of right atrial diverticulum were described in this case report and contrast echocardiogram was helpful to detect blood flowing between the right atrium and the diverticulum. Even color flow Doppler examination was able to identify blood flow between the diverticulum and the body of the right atrium in real time.

Footnotes

- ^a Alere Technologies AS, Oslo, Norway
^b Prosound Alpha 7, Hitachi-Aloka Medical, Tokyo, Japan
^c Lasix Tab, Handok, Chungbuk, Korea
^d Spirodactone guju Tab, Guju pharm, Hwaseong, Korea
^e Vetmedin, Meda Manufacturing GmbH, Germany
-

Acknowledgments

Grant support: This research was supported by Basic Science Research Program through the National Research Foundation of Korea (NRF) funded by the Ministry of Science, ICT and Future Planning (2015R1A2A2A01003313).

Conflict of Interest Declaration: Authors declare no conflict of interest.

Off-label Antimicrobial Declaration: Authors declare no off-label use of antimicrobials.

References

1. Binder TM, Rosenhek R, Frank H, et al. Congenital malformations of the right atrium and the coronary sinus: An analysis based on 103 cases reported in the literature and two additional cases. *Chest* 2000;117:1740–1748.
2. Babu T, Manohar SK, Bhat A, Singh MM. Case of right atrial diverticulum. *Indian J Thorac Cardiovasc Surg.* 1996;12:42–44.
3. Chatrath R, Turek O, Quivers ES, et al. Asymptomatic giant right atrial aneurysm. *Tex Heart Inst J* 2001;28:301–303.
4. Kurian KC, Nguyen M, Wilke N. Right atrial diverticulum—a rare cause of atrial fibrillation. *Clin Cardiol* 2007;30:631.
5. Patterson-Kane JC, Harrison LR. Giant right atrial diverticulum in a foal. *J Vet Diagn Invest* 2002;14:335–337.
6. Toaldo MB, Diana A, Morini M, Cipone M. Imaging diagnosis—intrapericardial right auricle aneurysm in a dog. *Vet Radiol Ultrasound* 2010;51:512–515.

7. Schwarz T, Willis R, Summerfield NJ, Doust R. Aneurysmal dilatation of the right auricle in two dogs. *J Am Vet Med Assoc* 2005;226:1512–1515.

8. Kobza R, Oechslin E, Prêtre R, et al. Enlargement of the right atrium—diverticulum or aneurysm? *Eur J Echocardiogr* 2003;4:223–225.

9. Sánchez-Brotons JA, López-Pardo FJ, López-Haldón JE, Rodríguez-Puras MJ. Giant right atrial diverticulum: Utility of contrast-enhanced ultrasound. *Rev Esp Cardiol (Engl Ed)*. 2013;66:222–223.

10. Sato Y, Satokawa H, Yamamoto A, et al. Giant right atrial diverticulum with thrombus formation. *Asian Cardiovasc Thorac Ann.* 2015;23:314–316.

11. Agematsu K, Okamura T, Ishihara K, Kurosawa H. Remarkable giant right atrial diverticulum in asymptomatic patient. *Interact Cardiovasc Thorac Surg* 2009;8:705–707.

12. Matthews JC, McLaughlin V. Acute right ventricular failure in the setting of acute pulmonary embolism or chronic pulmonary hypertension: A detailed review of the pathophysiology, diagnosis, and management. *Curr Cardiol Rev.* 2008;4:49–59.

13. Lumens J, Blanchard DG, Arts T, et al. Left ventricular underfilling and not septal bulging dominates abnormal left ventricular filling hemodynamics in chronic thromboembolic pulmonary hypertension. *Am J Physiol Heart Circ Physiol* 2010;299:1083–1091.

14. Yuan G, Yan BP, Hu J, et al. Compressive giant right atrial diverticulum. *Eur Heart J Cardiovasc Imaging* 2016;17:1065.

15. Shah K, Walsh K. Giant right atrial diverticulum: An unusual cause of Wolff-Parkinson-White syndrome. *Br Heart J* 1992;68:58–59.

Supporting Information

Additional Supporting Information may be found online in the supporting information tab for this article:

Video S1. Contrast echocardiogram using agitated saline (oblique right parasternal long-axis 4 chambers view). Note the microbubbles appearing first in the right atrium, immediately after in the diverticulum and right ventricle.