

# **UCLA**

## **Proceedings of UCLA Health**

### **Title**

An Atypical Cause of Chest Pain

### **Permalink**

<https://escholarship.org/uc/item/5nc0x4fq>

### **Journal**

Proceedings of UCLA Health, 24(1)

### **Authors**

Busuttil, Ashley

Macobian, Melkon

Gizaw, Eskidar

et al.

### **Publication Date**

2020-04-23

## CLINICAL VIGNETTE

---

# An Atypical Cause of Chest Pain

---

Ashley Busuttil, MD, Melkon Hacobian, MD, Eskidar Gizaw, NP and Peyman Benharash, MD

A 33-year-old male without known cardiac history presented to the emergency department with chest pain and shortness of breath for one day. He described the pain as left sided, constant, non-radiating, and five out of ten in severity. The pain worsened with deep inspiration, lateral movement of his torso, and being in the supine position. Despite feeling short of breath with exertion, he was able to ambulate distances that he considered normal. He noticed the onset of pain immediately when he woke up on the morning of presentation. He admitted using alcohol and intranasal methamphetamine and cocaine the night before but had no memory of the evening otherwise. He denied any fever, lower extremity swelling, orthopnea or prior episodes of chest pain. Social history was significant for consumption of up to 14 beers daily and frequent use of intranasal methamphetamines and cocaine.

On examination, the patient was afebrile, blood pressure was 153/90, heart rate 108, respirations 18, with oxygen saturation of 100% on room air. He appeared anxious, but otherwise in no acute distress. Precordial exam was significant for a two by two millimeter shallow appearing wound on the anterior chest without surrounding ecchymoses. Jugular venous pulsation was not elevated. The heart was tachycardic, with regular rhythm and no murmurs, rubs or gallops. Lungs were clear to auscultation bilaterally, abdomen was benign, and there was no lower extremity swelling. Skin was warm, dry and without rashes or lesions other than described above.

Initial laboratory testing revealed a normal CBC with hemoglobin of 14.6 (Ref 13.5-17.1 g/dL). Chemistry and coagulation panels were normal. D-dimer was elevated at 706 ng/mL (Ref < 500ng/mL). Troponin I was elevated at 2.9 ng/mL (Ref <0.1 ng/mL), increasing to 3.7 ng/mL four hours later, and then declining to 2.6 ng/mL six hours after. Brain natriuretic peptide was normal. Urine toxicology screen was positive for methamphetamines and cannabinoids. Admission electrocardiogram showed borderline tachycardia with non-specific T wave changes. Chest x-ray was normal. Echocardiogram completed in the emergency department showed a normal ejection fraction, normal wall motion and trace pericardial effusion. The patient received a single dose of aspirin 325mg. Cardiology consultation was obtained and the patient was admitted to the general medicine service for further workup and management.

Initial medical management included verapamil for heart rate control. Beta blockers were held due to concern for cocaine/methamphetamine use and heparin was held given concern for

bleeding with the finding of a small chest wound and trace pericardial effusion. A CT angiogram was ordered to evaluate for both pulmonary embolus as well as aortic injury. This revealed no embolus and no vascular injury, but did show a retained metallic radiopacity within the inferior right ventricle that was felt most consistent with a small caliber bullet (Figure 1). On re-review of the admission chest x-ray a small radiopaque density was visible overlaying the right ventricle (Figure 2).

The patient was immediately transferred to the cardiothoracic surgery service. The day after transfer, he underwent successful operative pericardial exploration through median sternotomy, cardiopulmonary bypass with removal of right ventricular bullet fragment and repair of right ventricular cardiac wound (Figure 3). The patient tolerated the procedure well and was discharged from the hospital on postoperative day five.

Chest pain is among the most common presenting complaints seen by hospital medicine providers. Despite its frequency, a methodological approach should be taken in every case to determine less common etiologies. There is frequent teaching about the three “not-to-miss,” life-threatening diagnoses of myocardial infarction, pulmonary embolism and aortic dissection. However, using a more mechanistic approach—rather than thinking of a list of diagnoses—avoids the pitfall of missing conditions that are very uncommon or rarely seen by the internist. In this case, with the patient’s age and history of methamphetamine/cocaine use, the leading diagnosis was stimulant induced vasospasm. However, with the small chest wall wound and unexplained trace pericardial effusion, trauma with resulting hemorrhagic pericardial fluid had to be a consideration despite the relatively unimpressive external findings and the remarkably stable hemodynamics. While the specific finding of an intra-cardiac bullet was certainly a surprise, the investigation with imaging to evaluate vascular or pericardial trauma was warranted.

The literature on surgical removal of cardiothoracic bullets dates back to the 1930’s and World War II, during which time Dr. Dwight Harken (1910-1993) gained a reputation as a pioneer in cardiothoracic surgical trauma.<sup>1</sup> He described a case series of the removal of foreign bodies from in and in relation to the heart and great vessels.<sup>2</sup> At that time of that report – the 1940’s – cardiopulmonary bypass or blood banking did not exist.

In the modern medical era, the presentation of penetrating cardiac injury remains dramatic with high immediate mortality. However, reported survival rates of penetrating cardiac injury vary widely, with differences related to the mechanism of injury, stability of patient on presentation to the hospital and the presence of complications such as tamponade.<sup>3-6</sup> Several studies describe excellent survival for the subset of patients presenting with hemodynamic stability. Kaljusto et al. describe 31 patients presenting to a Scandinavian hospital with 45% overall survival, however 18 of the patients included in the study had no signs of life on arrival. Of the 13 patients who did have signs of life on arrival, all survived.<sup>3</sup> Rapid recognition and appropriate treatment, even in rare and subtle clinical presentations, are imperative.

This patient's case was atypical in that he presented with relatively unimpressive evidence of external trauma and was hemodynamically stable. Nevertheless, his demographics – young, male—match the majority of patients described in the literature. Some reports describe conservative management for patients with hemodynamic stability, citing a case-by-case consideration of leaving bullet fragments in place within the thick-walled left ventricle.<sup>3</sup> Our patient had evidence of pericardial injury with hemopericardium requiring operative drainage. Furthermore, the bullet fragment was located within the right ventricle, which has increased risk of pseudoaneurysm formation as well as potentially devastating complications such as right ventricular rupture and embolization.

With this patient's young age and unexplained pericardial effusion, trauma was a key consideration despite his apparently stable presentation to a medical service with chest pain.

### Figures

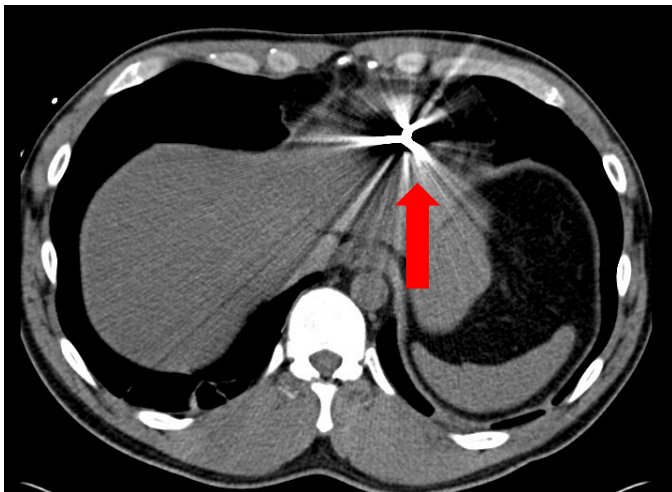


Figure 1: CT Angiogram displaying retained metallic radiopacity within the inferior right ventricle and/or inferior right ventricle myocardium

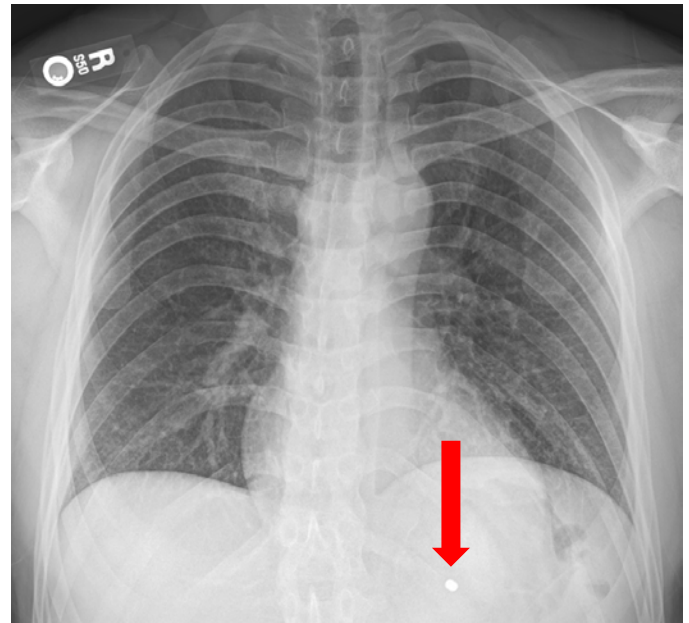


Figure 2. Admission Chest x-ray with radiopaque density

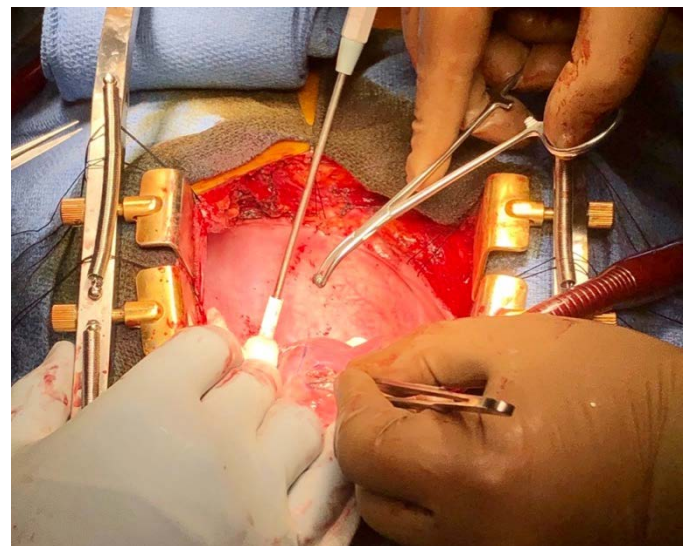


Figure 3. Intraoperative removal of right ventricular bullet

### REFERENCES

1. **Alivizatos PA.** Dwight Emary Harken, MD, an all-American surgical giant: Pioneer cardiac surgeon, teacher, mentor. *Proc (Bayl Univ Med Cent)*. 2018 Oct 29;31(4):554-557. doi: 10.1080/08998280.2018.1471896. eCollection 2018 Oct. PubMed PMID: 30949011; PubMed Central PMCID: PMC6413991.
2. **Harken DE, Williams AC.** Foreign bodies in and in relation to the thoracic blood vessels and heart; migratory foreign bodies within the blood vascular system. *Am J Surg*. 1946 Jul;72:80-90. PubMed PMID: 20987921.
3. **Kaljusto ML, Skaga NO, Pillgram-Larsen J, Tønnessen T.** Survival predictor for penetrating cardiac injury; a 10-year consecutive cohort from a Scandinavian trauma center. *Scand J Trauma Resusc Emerg Med*. 2015 Jun

3;23:41. doi: 10.1186/s13049-015-0125-z. PubMed PMID: 26032760; PubMed Central PMCID: PMC4451723.

4. **Velmahos GC, Degiannis E, Souter I, Saadia R.** Penetrating trauma to the heart: a relatively innocent injury. *Surgery*. 1994 Jun;115(6):694-7. PubMed PMID: 8197560.
5. **Mittal V, McAleese P, Young S, Cohen M.** Penetrating cardiac injuries. *Am Surg*. 1999 May;65(5):444-8. PubMed PMID: 10231214.
6. **Degiannis E, Loogna P, Doll D, Bonanno F, Bowley DM, Smith MD.** Penetrating cardiac injuries: recent experience in South Africa. *World J Surg*. 2006 Jul;30(7):1258-64. PubMed PMID: 16773259.