

UC Irvine

Clinical Practice and Cases in Emergency Medicine

Title

CPC-EM Full-Text Issue

Permalink

<https://escholarship.org/uc/item/5mn7d50j>

Journal

Clinical Practice and Cases in Emergency Medicine, 3(2)

Author

Saucedo, Cassandra

Publication Date

2019

Copyright Information

Copyright 2019 by the author(s). This work is made available under the terms of a Creative Commons Attribution License, available at <https://creativecommons.org/licenses/by/4.0/>

Peer reviewed

CPC Emergency Medicine

Volume III, Number 2, May 2019

Open Access at www.cpcem.org

ISSN: 2474-252X

Clinical Practice and Cases in Emergency Medicine

In Collaboration with the *Western Journal of Emergency Medicine*

Clinicopathological Cases from the University of Maryland

- 89** **Eight-year-old Boy with New-onset Seizure**
Rosenblatt L, Khoujah D, ZDW Dezman, Bontempo LJ

Case Series

- 95** **Code Blue: Life-threatening Methemoglobinemia**
JD Ponce Ríos, R Yong, P Calner

Case Reports

- 100** **Anterior Loculated Pericardial Effusion Misinterpreted as Right Heart Dilation Suggesting Pulmonary Embolism**
Lahham S, Frisch E, Langdorf MI
- 103** **Aortic Dissection with Subsequent Hemorrhagic Tamponade Diagnosed with Point-of-care Ultrasound in a Patient Presenting with STEMI**
Abrams E, Allen A, Lahham S
- 107** **Delayed Diagnosis of Spinal Tuberculosis in a 44-year-old Male with Acute on Chronic Low Back Pain**
Canine C, Medeck S, Hackett A
- 112** **A Desquamating Skin Rash in a Pediatric Patient**
Haggerty J, Grimaldo F
- 115** **Perilymphatic Fistula After Penetrating Ear Trauma**
Kita A, Kim I, Ishiyama G, Ishiyama A
- 119** **De Garengeot Hernia Diagnosed with Point-of-care Ultrasound**
Jennings L, Presley B, Jauch E
- 123** **Emergency Physician Reduction of Pediatric Hip Dislocation**
Capehart S, Balcik BJ, Sikora R, Sharon M, Minardi J

Contents continued on page iii



UC Irvine Health





— ACOEP's 2019 —

SCIENTIFIC ASSEMBLY

SAVE THE DATE

★ NOVEMBER 2 - 6, 2019 ★

JW MARRIOTT • AUSTIN, TX

Stay tuned at acoep.org for more information.

Clinical Practice and Cases in Emergency Medicine

Indexed in PubMed and full text in PubMed Central

In Collaboration with the *Western Journal of Emergency Medicine*

Rick A. McPheeters, DO, Editor-in-Chief
Kern Medical/UCLA- Bakersfield, California

Manish Amin, DO, Associate Editor
Kern Medical/UCLA- Bakersfield, California

Mark I. Langdorf, MD, MHPE, Associate Editor
University of California, Irvine School of Medicine- Irvine, California

Shadi Lahham, MD, MS, Associate Editor
University of California, Irvine School of Medicine- Irvine, California

Shahram Lotfipour, MD, MPH, Managing Associate Editor
University of California, Irvine School of Medicine- Irvine, California

Anna McFarlin, MD, Section Editor
Louisiana State University Health Science Center- New Orleans, Louisiana

Austin Smith, MD, Section Editor
Vanderbilt University Medical Center-Nashville, Tennessee

Christopher Sampson, MD, Section Editor
University of Missouri- Columbia, Missouri

Joel Moll, MD, Section Editor
Virginia Commonwealth University School of Medicine- Richmond, Virginia

Scott Goldstein, DO, Section Editor
Sidney Kimmel College of Medicine- Philadelphia, Pennsylvania

Steven Walsh, MD, Section Editor
Einstein Medical Center Philadelphia-Philadelphia, Pennsylvania

John Ashurst, DO, Section Editor
Kingman Regional Health Network, Arizona

Editorial Board

Amin A. Kazzi, MD, MAAEM
The American University of Beirut, Beirut,
Lebanon

Anwar Al-Awadhi, MD
Mubarak Al-Kabeer Hospital, Jabriya, Kuwait

Arif A. Cevik, MD
United Arab Emirates University
College of Medicine and Health Sciences, Al
Ain, United Arab Emirates

Abhinandan A. Desai, MD
University of Bombay Grant Medical College,
Bombay, India

Bandr Mzahim, MD
King Fahad Medical City, Riyadh, Saudi Arabia

Barry E. Brenner, MD, MPH
Case Western Reserve University

Brent King, MD, MMM
University of Texas, Houston

Daniel J. Dire, MD
University of Texas Health Sciences Center San
Antonio

David F.M. Brown, MD
Massachusetts General Hospital/Harvard
Medical School

Edward Michelson, MD
Texas Tech University

Edward Panacek, MD, MPH
University of South Alabama

Erik D. Barton, MD, MBA
Icahn School of Medicine, Mount Sinai,
New York

Francesco Dellacorte, MD
Azienda Ospedaliera Universitaria "Maggiore
della Carità," Novara, Italy

Francis Counselman, MD
Eastern Virginia Medical School

Gayle Galleta, MD
Sørlandet Sykehus HF, Akershus
Universitetssykehus, Lorenskog, Norway

Hjalte Björnsson, MD
Icelandic Society of Emergency Medicine

Jacob (Kobi) Peleg, PhD, MPH
Tel-Aviv University, Tel-Aviv, Israel

Jonathan Olshaker, MD
Boston University

Katsuhiko Kanemaru, MD
University of Miyazaki Hospital, Miyazaki, Japan

Khrongwong Musikatavorn, MD
King Chulalongkorn Memorial Hospital,
Chulalongkorn University, Bangkok, Thailand

Leslie Zun, MD, MBA
Chicago Medical School

Linda S. Murphy, MLIS
University of California, Irvine School of
Medicine Librarian

Nadeem Qureshi, MD
St. Louis University, USA
Emirates Society of Emergency Medicine,
United Arab Emirates

Niels K. Rathlev, MD
Tufts University School of Medicine

Pablo Aguilera Fuenzalida, MD
Pontificia Universidad Católica de Chile,
Región Metropolitana, Chile

Peter A. Bell, DO, MBA
Liberty University
College of Osteopathic Medicine

Peter Sokolove, MD
University of California, San Francisco

Robert M. Rodriguez, MD
University of California, San Francisco

Robert Suter, DO, MHA
UT Southwestern Medical Center

Robert W. Derlet, MD
University of California, Davis

Rosidah Ibrahim, MD
Hospital Serdang, Selangor, Malaysia

Samuel J. Stratton, MD, MPH
Orange County, CA, EMS Agency

Scott Rudkin, MD, MBA
University of California, Irvine

Scott Zeller, MD
University of California, Riverside

Steven Gabaeff, MD
Clinical Forensic Medicine

Steven H. Lim, MD
Changi General Hospital, Simei, Singapore

Terry Mulligan, DO, MPH, FIFEM
ACEP Ambassador to the Netherlands Society of
Emergency Physicians

Vijay Gautam, MBBS
University of London, London, England

Wirachin Hoonpongsimanont, MD, MSBATS
Siriraj Hospital, Mahidol University, Bangkok,
Thailand

Advisory Board

Amal Khalil, MBA
UC Irvine Health School of Medicine

Elena Lopez-Gusman, JD
California ACEP
American College of Emergency Physicians

Janice Wachtler, BAE, CBA
American College of Osteopathic Emergency
Physicians

John B. Christensen, MD
California Chapter Division of AAEM

Lori Winston, MD
California ACEP
American College of Emergency Physicians
Kaweah Delta Healthcare District

Mark I. Langdorf, MD, MHPE
UC Irvine Health School of Medicine

Nicholas T. Sawyer, MD, MBA
California ACEP
American College of Emergency Physicians
University of California, Davis

Peter A. Bell, DO, MBA
American College of Osteopathic
Emergency Physicians
Liberty University, College of Osteopathic
Medicine

Robert Suter, DO, MHA
American College of Osteopathic
Emergency Physicians
UT Southwestern Medical Center

Shahram Lotfipour, MD, MPH
UC Irvine Health School of Medicine

Trevor Mills, MD, MPH
California Chapter Division of AAEM
Northern California VA Health Care

Editorial Staff

Jimmy To, BS
Editorial Director

Leila Danishgar, BS
Associate Editorial Director

Tushank Chadha, BS
Marketing Director to Media and
Communications Director

Nancy G. Hernandez, BA
Executive Publishing Director

Dana Le, BS
WestJEM Publishing Director

Shashank Somasundaram, BS
CPC-EM Publishing Director

Cassandra Saucedo, BS
Associate Publishing Director

June Casey, BA
Copy Editor

Alissa Fiorentino, BA
WestJEM Staff Liaison

Official Journal of the California Chapter of the American College of Emergency Physicians, the American College of Osteopathic Emergency Physicians, and the California Chapter of the American Academy of Emergency Medicine



Available in MEDLINE, PubMed, PubMed Central, Google Scholar, eScholarship, DOAJ, and OASPA.

Editorial and Publishing Office: WestJEM/Department of Emergency Medicine, UC Irvine Health, 333 City Blvd, West, Rt 128-01, Orange, CA 92866, USA

Office: 1-714-456-6389; Email: Editor@westjem.org

Clinical Practice and Cases in Emergency Medicine

Indexed in PubMed and full text in PubMed Central

In Collaboration with the *Western Journal of Emergency Medicine*

This open access publication would not be possible without the generous and continual financial support of our society sponsors, department and chapter subscribers.

Professional Society Sponsors

AMERICAN COLLEGE OF OSTEOPATHIC EMERGENCY PHYSICIANS
CALIFORNIA ACEP

CALIFORNIA CHAPTER DIVISION OF
AMERICAN ACADEMY OF EMERGENCY MEDICINE

Academic Department of Emergency Medicine Subscriber

Albany Medical College Albany, NY	INTEGRIS Health Oklahoma City, OK	Robert Wood Johnson University Hospital New Brunswick, NJ	University of Florida, Jacksonville Jacksonville, FL
American University of Beirut Beirut, Lebanon	Kaweah Delta Health Care District Visalia, CA	Rush University Medical Center Chicago, IL	University of Illinois at Chicago Chicago, IL
Arrowhead Regional Medical Center Colton, CA	Kennedy University Hospitals Turnersville, NJ	Southern Illinois University Carbondale, IL	University of Illinois College of Medicine Peoria, IL
Augusta University Augusta GA	Kern Medical Bakersfield, CA	St. Luke's University Health Network Bethlehem, PA	University of Iowa Iowa City, IA
Baystate Medical Center Springfield, MA	Lakeland HealthCare St. Joseph, MI	Stanford/Kaiser Emergency Medicine Residency Program Stanford, CA	University of Louisville Louisville, KY
Beaumont Hospital Royal Oak, MI	Lehigh Valley Hospital and Health Network Allentown, PA	Staten Island University Hospital Staten Island, NY	University of Maryland Baltimore, MD
Beth Israel Deaconess Medical Center Boston, MA	Loma Linda University Medical Center Loma Linda, CA	SUNY Upstate Medical University Syracuse, NY	University of Michigan Ann Arbor, MI
Boston Medical Center Boston, MA	Louisiana State University Health Sciences Center New Orleans, LA	Temple University Philadelphia, PA	University of Missouri, Columbia Columbia, MO
Brigham and Women's Hospital Boston, MA	Madigan Army Medical Center Tacoma, WA	Texas Tech University Health Sciences Center El Paso, TX	University of Nebraska Medical Center Omaha, NE
Brown University Providence, RI	Maimonides Medical Center Brooklyn, NY	University of Alabama, Birmingham Birmingham, AL	University of South Alabama Mobile, AL
Carl R. Darnall Army Medical Center Fort Hood, TX	Maricopa Medical Center Phoenix, AZ	University of Arkansas for Medical Sciences Little Rock, AR	University of Southern California/Keck School of Medicine Los Angeles, CA
Conemaugh Memorial Medical Center Johnstown, PA	Massachusetts General Hospital Boston, MA	University of California, Davis Medical Center Sacramento, CA	University of Tennessee, Memphis Memphis, TN
Desert Regional Medical Center Palm Springs, CA	Mayo Clinic College of Medicine Rochester, MN	University of California Irvine Orange, CA	University of Texas, Houston Houston, TX
Doctors Hospital/Ohio Health Columbus, OH	Mt. Sinai Medical Center Miami Beach, FL	University of California, Los Angeles Los Angeles, CA	University of Texas Health San Antonio, TX
Eastern Virginia Medical School Norfolk, VA	North Shore University Hospital Manhasset, NY	University of California, San Diego La Jolla, CA	University of Warwick Library Coventry, United Kingdom
Einstein Healthcare Network Philadelphia, PA	Northwestern Medical Group Chicago, IL	University of California, San Francisco San Francisco, CA	University of Washington Seattle, WA
Emory University Atlanta, GA	Ohio State University Medical Center Columbus, OH	UCSF Fresno Center Fresno, CA	University of Wisconsin Hospitals and Clinics Madison, WI
Genesys Regional Medical Center Grand Blanc, Michigan	Ohio Valley Medical Center Wheeling, WV	University of Chicago, Chicago, IL	Wake Forest University Winston-Salem, NC
Hartford Hospital Hartford, CT	Oregon Health and Science University Portland, OR	University of Colorado, Denver Denver, CO	Wright State University Dayton, OH
Hennepin County Medical Center Minneapolis, MN	Penn State Milton S. Hershey Medical Center Hershey, PA	University of Florida Gainesville, FL	
Henry Ford Hospital Detroit, MI	Presence Resurrection Medical Center Chicago, IL		

State Chapter Subscriber

ARIZONA CHAPTER DIVISION OF THE
AMERICAN ACADEMY OF EMERGENCY MEDICINE
CALIFORNIA CHAPTER DIVISION OF THE
AMERICAN ACADEMY OF EMERGENCY MEDICINE
FLORIDA CHAPTER DIVISION OF THE
AMERICAN ACADEMY OF EMERGENCY MEDICINE

GREAT LAKES CHAPTER DIVISION OF THE
AMERICAN ACADEMY OF EMERGENCY MEDICINE
TENNESSEE CHAPTER DIVISION OF THE
AMERICAN ACADEMY OF EMERGENCY MEDICINE

UNIFORMED SERVICES CHAPTER DIVISION OF THE
AMERICAN ACADEMY OF EMERGENCY MEDICINE
VIRGINIA CHAPTER DIVISION OF THE
AMERICAN ACADEMY OF EMERGENCY MEDICINE

International Society Partners

EMERGENCY MEDICINE ASSOCIATION OF TURKEY
LEBANESE ACADEMY OF EMERGENCY MEDICINE
MEDITERRANEAN SOCIETY OF EMERGENCY MEDICINE

NORWEGIAN SOCIETY FOR EMERGENCY MEDICINE
SOCIEDAD ARGENTINA DE EMERGENCIAS

SOCIEDAD CHILENO MEDICINA URGENCIA
THAI ASSOCIATION FOR EMERGENCY MEDICINE

To become a *WestJEM* departmental sponsor, waive article processing fee, receive print and copies for all faculty and electronic for faculty/residents, and free CME and faculty/fellow position advertisement space, please go to <http://westjem.com/subscribe> or contact:

Alissa Fiorentino
WestJEM Staff Liaison
Phone: 1-800-884-2236
Email: sales@westjem.org

Clinical Practice and Cases in Emergency Medicine

Indexed in PubMed and full text in PubMed Central

In Collaboration with the *Western Journal of Emergency Medicine*

JOURNAL FOCUS

Clinical Practice and Cases in Emergency Medicine (CPC-EM) is a MEDLINE-indexed internationally recognized journal affiliated with the *Western Journal of Emergency Medicine* (WestJEM). It offers the latest in patient care case reports, images in the field of emergency medicine and state of the art clinicopathological and medicolegal cases. CPC-EM is fully open-access, peer reviewed, well indexed and available anywhere with an internet connection. CPC-EM encourages submissions from junior authors, established faculty, and residents of established and developing emergency medicine programs throughout the world.

Table of Contents *continued*

- 128 **Evans Syndrome**
Al Hazmi A, Winters ME
- 132 **Ruptured Visceral Artery Aneurysms: A Deadly Cause of Epigastric Pain**
Bradley S, Quenzer F, Wittler M
- 137 **Acute Angle-Closure Glaucoma Secondary to a Phakic Intraocular Lens, an Ophthalmic Emergency**
A Frost, DJ Ritter, A Trotter, MS Pulia
- 140 **Empagliflozin-induced Diabetic Ketoacidosis Unmasking a Type 1 Diabetes Diagnosis**
GM Ray, C Rodriguez, SM Schulman, P Sarangarm, M Bardack, MF Bouchonville
- 144 **Double Steal Phenomenon: Emergency Department Management of Recurrent Transient Ischemic Attack**
AR Rawal, C Bufano, O Saeed, AA Khan
- 149 **High Ascending Retrocecal Appendicitis in a Pediatric Patient Detected by Point-of-care Ultrasound**
T Mori, TS Shin, GYK Ong
- 153 **Symptomatic Vaginal Infection by *Neisseria meningitidis* Resulting in Meningitis with Septic Shock**
R Offman, E Boggs, A Gwizalda

Images in Emergency Medicine

- 156 **Pediatric Ingestion of Multiple Button Batteries**
J Fong, T Zitek
- 158 **Point-of-care Ultrasound Diagnosis of Cholecystitis vs. Adenomyomatosis**
E Kim, R Bashir, S Lahham
- 160 **Mucocutaneous Paraneoplastic Syndrome Secondary to Classical Hodgkin's Lymphoma**
J Jurkovic, M Cirone
- 162 **Early Diagnosis of Heterotopic Pregnancy in a Primigravid Without Risk Factors in the Emergency Department**
R O'Donnell, E Siacunco, D Quesada, K Barkataki, P Aguiñiga-Navarrete
- 164 **Apparent Pacer Spikes in a Patient with Back and Chest Pain**
A Lulla, RT Griffey
- 166 **Atypical Fungal Rash**
FWM Adel, V Bellamkonda

Policies for peer review, author instructions, conflicts of interest and human and animal subjects protections can be found online at www.cpcem.org.

Clinical Practice and Cases in Emergency Medicine

Indexed in PubMed and full text in PubMed Central

In Collaboration with the *Western Journal of Emergency Medicine*

Table of Contents *continued*

- 168 **A Man with Severe Right Knee Pain**
S Takeda, K Iwatsuki, Y Takeichi, T Kano, A Tabuchi, H Hirata
- 170 **Rare Cause of Inguinal Pain in 39-year-old Male**
K Barkataki, N Wang, D Quesada, R O'Donnell, JW Rosbrugh, P Aguiñiga-Navarrete
- 172 **The Aquarium Sign: Another Opportunity for Detection of Perforated Viscus**
M Gorgone, TP O'Connor, M Lu
- 174 **Identifying a Disc-shaped Foreign Body**
M Lee, M George, KE Dorney
- 176 **Adding Insult to Injury: Asymptomatic Fat Embolism Identified on Computed Tomography**
MJ Moore, SY Liu

Clinical Practice and Cases in Emergency Medicine (CPC-EM) is a open-access Medline-indexed internationally recognized journal affiliated with the *Western Journal of Emergency Medicine* (WestJEM). CPC-EM is distributed electronically to 19,000 emergency medicine scholars. This includes our sponsors California ACEP, the American College of Osteopathic Emergency Physicians, California Chapter of AAEM, and over 83 academic department of emergency medicine subscribers and 8 AAEM State Chapters.

CPC**EM** Clinical Practice & Cases

CALL FOR SUBMISSIONS

- Patient Care Case Reports
- Images in Emergency Medicine

Fully open-access, peer reviewed, well indexed: CPC-EM is available anywhere with an internet connection at **CPCEM.org**

Clinical Practice and Cases in Emergency Medicine is an internationally recognized journal affiliated with the MEDLINE-indexed ***Western Journal of Emergency Medicine***

CPC-EM encourages submissions from junior authors and countries with developing emergency medicine programs

CPC**EM** Clinical Practice & Cases

CALL FOR CPC-EM SECTION EDITORS!

- Medical-Legal Case Reports
- Case Reports/Images in Emergency Medicine

Send your CV and letter of interest to editor@cpcem.org

WestJEM Integrating Emergency Care
with Population Health

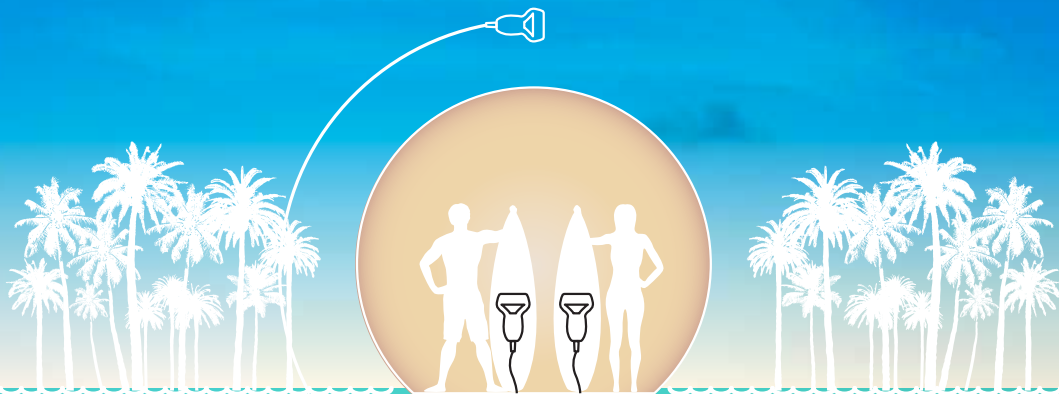
CPCEM Clinical
Practice
& Cases

Call for Reviewers!

Please send your CV and letter of interest to
editor@westjem.org

SEVENTH WORLD CONGRESS

ULTRASOUND IN MEDICAL EDUCATION



UCI School of Medicine
Department of Emergency Medicine

Irvine, California

SEPTEMBER 12 - 15, 2019

Western Journal of Emergency Medicine Call for Papers:

- **Social Emergency Medicine**
- **Systematic Reviews**



CALL FOR SECTION EDITORS

- Behavioral Health
- Cardiac Care
- Ultrasound
- Clinical Practice
- Pediatric Emergencies
- Public Health
- Trauma Care
- International Medicine
- ED Administration

**Send your CV and letter of interest to
editor@westjem.org**

Learn more at www.westjem.org

Eight-year-old Boy with New-onset Seizure

Lauren Rosenblatt, MD*

Danya Khoujah, MBBS[†]

Zachary D.W. Dezman, MD, MS, MS[†]

Laura J. Bontempo, MD, MEd[†]

*University of Maryland Medical Center, Department of Emergency Medicine, Baltimore, Maryland

[†]University of Maryland School of Medicine, Department of Emergency Medicine, Baltimore, Maryland

Section Editor: Joel Moll, MD

Submission history: Submitted January 28, 2019; Revision received March 29, 2019; Accepted April 1, 2019

Electronically published April 12, 2019

Full text available through open access at http://escholarship.org/uc/uciem_cpccm

DOI: 10.5811/cpcem.2019.4.42547

An eight-year-old boy presented to the emergency department for a first-time seizure. The patient had only signs of mild dehydration on physical exam and had an uneventful postictal recovery. First-time seizures in pediatric patients are often benign and require only an outpatient workup; some are dangerous. This case takes the reader through the differential diagnosis and systematic work-up of new-onset pediatric seizures, leading to an unanticipated diagnosis. [Clin Pract Cases Emerg Med. 2019;3(2):89-94.]

CASE PRESENTATION

An eight-year-old African-American male was brought to the emergency department (ED) by ambulance after a first-time, witnessed seizure at home. The patient arrived approximately 15 minutes after the seizure and was somnolent but arousable and confused, consistent with a postictal state. The remainder of the history was taken from the patient's mother, who was at his bedside. She stated that the patient had been feeling unwell for the past two to three days. He had been complaining of upper respiratory infection symptoms, including cough and nasal congestion. The mother stated she heard a "thud" upstairs and ran up to find her son on the floor shaking and incontinent of his bladder and bowels. The shaking lasted about one to two minutes. She reported that her son had a decreased appetite recently, but even when well he was a very picky eater with a very limited diet. He had only eaten French fries since becoming sick. The patient's mother had been encouraging oral hydration with Gatorade and Pedialyte.

The patient had no significant past medical history. He had never had surgery or other hospitalizations. He had an allergy to amoxicillin which resulted in hives. He saw a pediatrician regularly and was up to date on vaccines. He did not take medications on a daily basis. There was a family history of hypertension but no family history of seizure disorders. They lived in a home, and mother stated they felt safe at home. No one else in the home had been ill.

Vital signs included an oral temperature of 38° Celsius, a heart rate of 108 beats per minute, blood pressure of 111/70

millimeters of mercury, breathing at a rate of 26 breaths per minute, and oxygenating 97% on room air. On initial physical exam, patient appeared drowsy, but overall was well developed, with a body mass index of 19 kg/m², and in no acute distress. His head was normocephalic and atraumatic. Extraocular movements were intact, pupils were three millimeters and equal, round, and reactive to light. His tympanic membranes were normal and nose was normal. He had dry mucous membranes and his oropharynx was clear without exudate or erythema. His neck was supple and without lymphadenopathy. His lungs were clear to auscultation bilaterally, with good air movement. There were no wheezes, rales, or rhonchi. Auscultation of the patient's heart revealed a normal rate and regular rhythm without murmurs, rubs, or gallops. Abdomen was soft, non-tender, and non-distended with normal bowel sounds. The extremities had no edema, 2+ distal pulses, no tenderness, and no deformity with normal range of motion. Neurological exam revealed that he was easily arousable without cranial nerve deficits, normal strength, normal sensation, normal coordination, and normal gait. His skin was warm and dry, without rashes, pallor, or jaundice. He had a capillary refill of three to five seconds in all extremities.

After approximately 30 minutes in the ED, the patient's mother reported that her son seemed to be more alert, interactive, and conversive, and was back to his baseline mentation.

Labs, electrocardiogram (ECG), and chest radiograph were obtained in the ED. Laboratory results are shown in the table. ECG and chest radiograph can be seen in Images 1 and 2, respectively.

Table. Laboratory results for an eight-year-old boy with a new-onset seizure.

Labratory Test	Value
Complete blood cell count	
White blood cells	5.3 K/mcl
Hemoglobin	12.9 g/dL
Hematocrit	39.3%
Platelets	199 K/mcl
Serum chemistry	
Sodium	142 mmol/L
Potassium	3.9 mmol/L
Chloride	106 mmol/L
Bicarbonate	21 mmol/L
Blood urea nitrogen	4 mg/dL
Creatinine	0.33 mg/dL
Glucose	95 mg/dL
Magnesium	1.6 mg/dL
Phosphorus	3.9 mg/dL
Calcium	5.1 mg/dL
Albumin	3.9 g/dL
Lactate	0.7 mmol/L
Thyroid stimulating hormone	0.26 mIU/L

K/mcl, thousands per microliter; *g/dL*, grams per deciliter; *mmol/L*, millimoles per liter; *mg/dL*, milligrams per deciliter; *mIU/L*, milli-international units per liter.

While in the ED, a test was ordered, and a diagnosis was made.

CASE DISCUSSION

When I first read this case, it was unclear to me why it was a diagnostic dilemma. This is a case of an eight-year-old boy presenting with a seizure. What am I missing? There must be more to this than meets the eye.

He presented after a witnessed seizure at home, accompanied by incontinence, and followed by a postictal period. The seizure was preceded by upper respiratory infection symptoms and decreased oral intake. His physical exam is significant for signs of dehydration, such as tachycardia, dry mucous membranes, delayed capillary refill and tachypnea. His neurological exam is consistent with the described postictal period (drowsy and easily arousable), with intact cranial nerves, power, and sensation. He returned to his baseline mental status within approximately 30 minutes of arrival, which is what would be expected.

While all these descriptors of the incident make it typical for a first-time seizure, an alternative explanation for “seizure-like” activity should also be considered. Most importantly, the clinician must consider arrhythmias. The ECG provided reveals sinus tachycardia with no evidence of arrhythmia or an arrhythmogenic disorder such as hypertrophic cardiomyopathy or Wolff-Parkinson-White syndrome. Arrhythmia, therefore, is less likely to be the etiology.

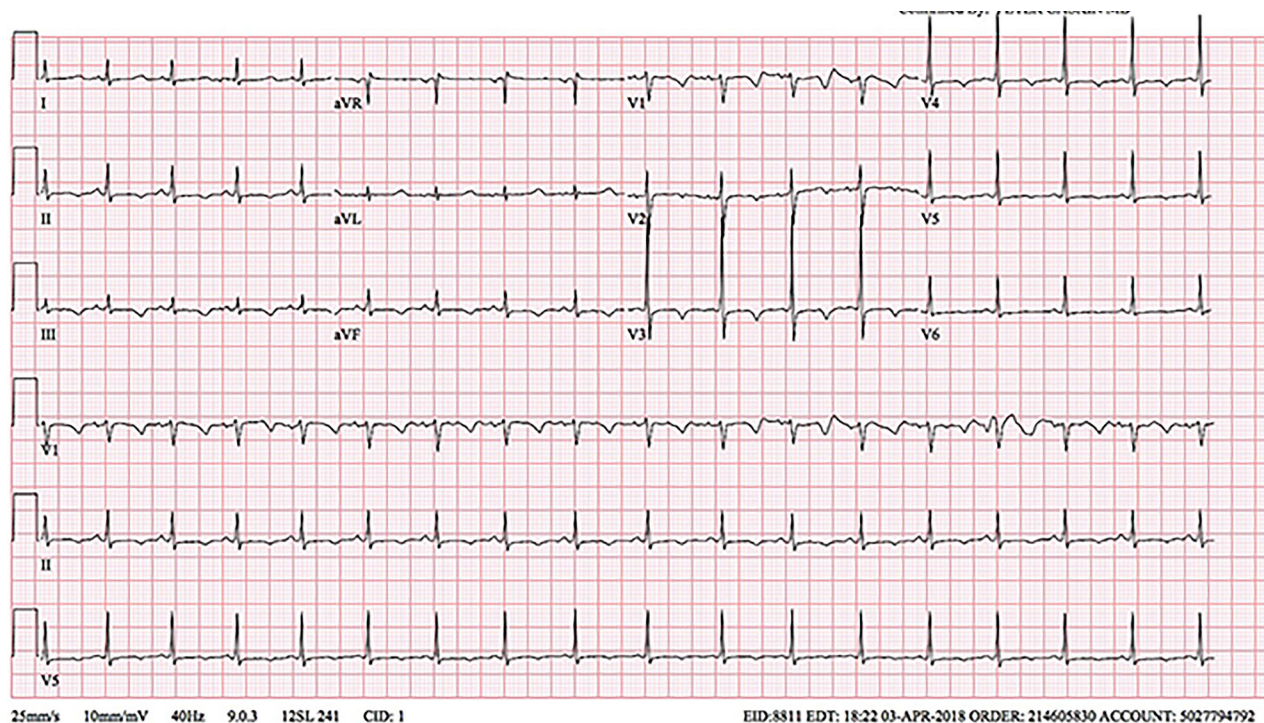


Image 1. Electrocardiogram of eight-year-old boy with new-onset seizure.

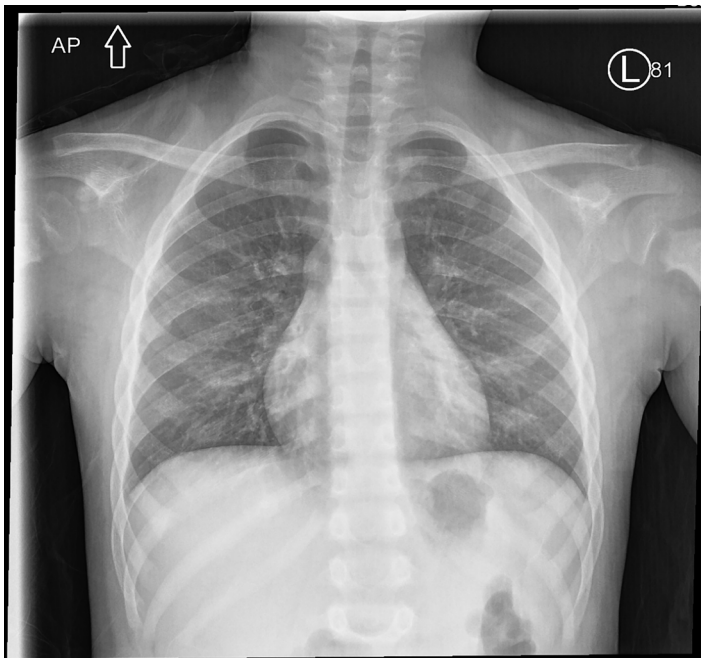

Image 2. Chest radiograph of eight-year-old boy with new-onset seizure.

In an attempt to understand what about this seizure makes it different, I went through my differential diagnosis for provoked seizures:

- Structural lesions
- Trauma
- Vascular
- Infection
- Toxic
- Metabolic
- Hypertensive
- Heat stroke
- Pregnancy (eclampsia)

The last three entities on this list (hypertensive encephalopathy, heat stroke and pregnancy) can be excluded right away, given the normal blood pressure, temperature and male gender.

A structural lesion, such as a tumor, is unlikely in the absence of signs of increased intracranial pressure or a focal neurological deficit. Less emergent lesions, such as congenital anomalies, can be safely addressed with an outpatient magnetic resonance imaging (MRI), excluding this entity from the differential. Trauma is unlikely to be the cause, as there is no reported trauma and no signs of head trauma on the patient's examination. A vascular catastrophe, such as an intracranial hemorrhage, would be accompanied by a headache, vomiting, and/or neurological findings, all of which are absent in this case. This, too, is therefore excluded. The remaining possibilities of

infectious, toxic and metabolic causes of the seizure must be looked at more closely.

Infectious

Here I have to consider meningitis/encephalitis, febrile seizures and a brain abscess. Although the patient has infectious symptoms, he does not have features suggestive of a more serious infection, such as neck stiffness, headache, vomiting, rash, or persistent altered mental status (AMS). I cannot exclude meningitis/encephalitis, but I will place them low on my differential diagnosis. Febrile seizures are excluded by the lack of fever on presentation as well as the child's age, which is outside the typical range for febrile seizures (three months to three years). An intracranial abscess could be considered if the patient were immunocompromised or had fever or focal neurological deficit. The patient is afebrile without focal neurological deficit and, as far as is known, is immunocompetent. An intracranial abscess is therefore excluded. The only diagnosis that remains from this category is meningitis/encephalitis.

Toxic

Here I have to consider several agents that can cause seizures, whether accidentally administered in large doses by the parent, or accidentally (or intentionally) ingested by the child. Many over-the-counter (OTC) cold medications contain anticholinergics, which in toxic quantities can cause seizures. Although some elements of the current presentation are consistent with an anticholinergic overdose, such as the AMS, tachycardia and dry mucous membranes, others are not, including the patient's pupillary exam. The patient's mother did not report any OTC medication use; however, children can surreptitiously ingest medications that are present at home and were inadvertently omitted from the initial history-taking, leaving anticholinergic overdose as a tempting explanation for the seizure. Other toxins that induce seizures include lithium, isoniazid and tricyclic antidepressants, which the child is not reported to have access to. Furthermore, there were no signs of tricyclic toxicity on the ECG, such as a rightward axis, wide QRS or terminal R wave in aVR. Finally, alcohol and benzodiazepine withdrawal can cause seizures, although these would present along with tachycardia, tremors, hypertension, diaphoresis, tongue fasciculations, and AMS. Outside of the mild tachycardia, none of these other signs are present. Neither is there past medical or social history suggesting regular ingestion of benzodiazepines or alcohol, effectively excluding these culprits as well. Other than anticholinergic overdose, toxin-induced seizures are off my list.

Metabolic

Several metabolic derangements can lead to seizures, including sodium abnormalities (hyper- or hyponatremia), glucose abnormalities (hyper- or hypoglycemia), hypocalcemia, hypomagnesemia, or every emergency physician's least favorite diagnosis to navigate in a child: inborn error of metabolism

(IEM). The answer may be as simple as obtaining an electrolyte panel, which should include magnesium and calcium. As for IEM, the child's age and lack of other medical history makes it much less likely. Combined with a lack of acidosis as evidenced by a normal serum bicarbonate level (21 millimoles per liter [mmol/L]) and normal lactate (0.7 mmol/L), and a normal glucose level, IEM is virtually excluded. Serum levels of sodium, glucose, and magnesium are all within normal limits. The calcium level, on the other hand, is 5.1 milligrams per deciliter (mg/dL), with a normal range of 8.5 – 10.2 mg/dL. Could it really be this low, or is it a lab error?

Additionally, I noted that the patient did not receive any neuroimaging. Although it is tempting to think that neuroimaging would reveal the etiology of his seizures, in truth, very rarely does neuroimaging of a pediatric patient with a first-time, non-febrile seizure affect the management of the patient.¹ My differential diagnosis is, therefore, unaffected by the absence of a computed tomography.

In review, my working differential diagnosis includes meningitis/encephalitis, anticholinergic overdose, and hypocalcemia. Taking another look at the ECG, the QTc is prolonged, which is consistent with hypocalcemia or an anticholinergic overdose. The patient's serum albumin level is 3.9 grams per deciliter, which is normal. Using the formula – corrected calcium = $[0.8 \times (\text{normal albumin} - \text{patient's albumin})] + \text{serum calcium level}$ – the patient's corrected calcium level is 5.2 mg/dL, which is still very low. The corrected calcium level and the patient's ECG suggest that his hypocalcemia is likely the culprit for the seizure. In addition, given that the question that ends the case is “a test was ordered, and a diagnosis was made,” and knowing that anticholinergic levels are not an accessible test from the ED, the diagnosis of anticholinergic overdose is excluded. I believe the diagnostic test of choice in this patient case is an ionized calcium level. However, what was the primary cause of the patient's hypocalcemia?

Hypocalcemia in children can be caused by hypoparathyroidism, low vitamin D levels (due to intake or synthesis), as a side effect of a medication/toxin, or secondary to another abnormality (alkalosis or hypomagnesemia) or a severe illness (such as pancreatitis or sepsis). The last three entities can be easily excluded, as the child is not on any daily medications, his serum bicarbonate and magnesium are normal, and he does not appear toxic. Hypoparathyroidism can be due to a genetic disorder or secondary to a thyroid surgery. It is unlikely that this is a first presentation of a genetic disorder at the age of eight, and the child has not had any surgeries. This leaves low vitamin D levels as a possible culprit for the hypocalcemia, whether due to decreased dietary intake, decreased absorption, or inadequate exposure to sunlight. Looking back over the case details, the mother did mention that the patient is a picky eater, making a dietary cause for the hypocalcemia most likely.

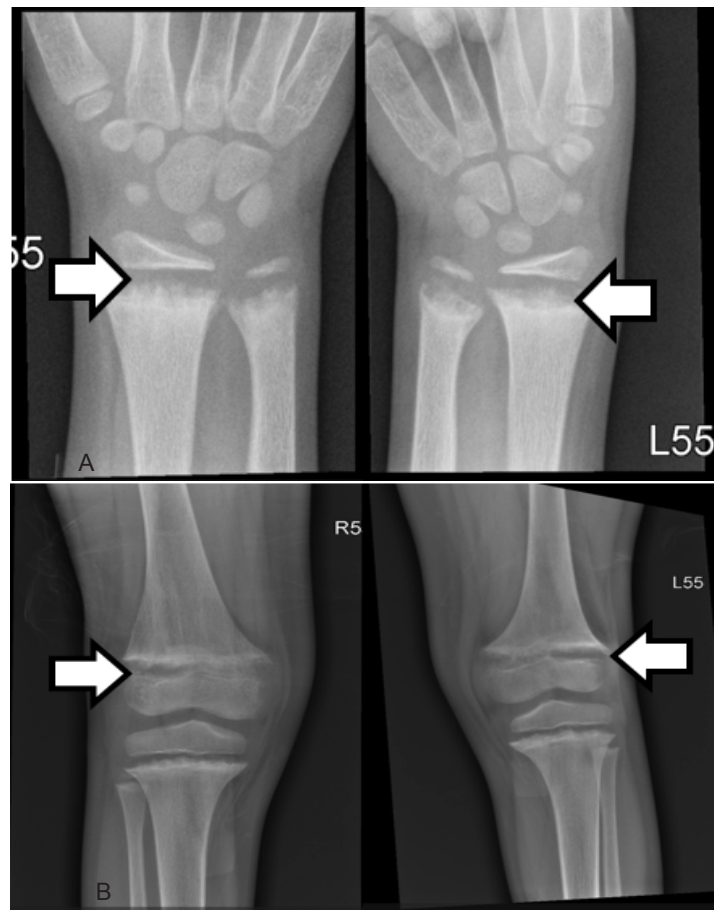


Image 3. Radiograph of bilateral wrists (A) and knees (B) of an eight-year-old boy with new-onset seizure. Arrows denote areas of poor bone mineralization.

CASE OUTCOME

The first thought once the labs started to result was that the calcium value must be wrong. A repeat calcium and an ionized calcium level were obtained, which were 5.0 mg/dL (range 8.8-10.8 mg/dL) and 0.77 mg/dL (range 1.15-1.29 mmol/L). This confirmed hypocalcemia without any other obvious electrolyte abnormalities, concluding that the patient had suffered a hypocalcemic seizure. This is consistent with the ECG, which showed QTc prolongation of 456 milliseconds, a common complication of hypocalcemia. The patient was given intravenous calcium gluconate in the ED. Endocrinology was consulted and they recommended obtaining radiographs of the wrists and knees (Image 3). These showed degradation and demineralization at the distal metaphases, revealing the diagnosis of rickets. Further investigation and conversation with the patient's mother regarding her child's picky eating habits revealed that her son only eats chicken nuggets and French fries, even when feeling well.

The patient was admitted to the pediatric hospitalist team. Inpatient workup included obtaining a parathyroid hormone

(PTH) level and vitamin D studies. The results of those studies were vitamin D 25-hydroxy of <4 nanograms (ng)/mL (range 20-80 ng/mL), vitamin D 1,25-hydroxy of 10.5 ng/mL (range 19.9-79.3 ng/mL), and parathyroid hormone (PTH) of 636 picograms (pg)/mL (range 8-54 pg/mL), proving that the etiology of the rickets was secondary to a vitamin D nutritional deficiency. The patient was started on aggressive calcium and vitamin D replacement. At six-month follow-up, repeat laboratory studies showed some improvement with a calcium of 8.5 mg/dL; however, vitamin D 25 hydroxy was still low at 4.2ng/mL.

RESIDENT DISCUSSION

Rickets is defined as a disease resulting from the failure to mineralize newly formed osteoid at the growth plates of long bones, causing an abundance of unossified cartilage.^{2,3} Rickets is specifically a pediatric disease and can only occur prior to fusion of the epiphyses of bones. After this time, the demineralization of bone results in osteomalacia in adults.

The presence of rickets in the literature has been documented as early as the 17th century by scientists Whistler and Glisson.^{2,4} Since then, there has been an abundance of literature documenting the role of vitamin D in the absorption and utilization of calcium through various organ systems within the human body. Public health efforts across the globe have included fortifying food with vitamin D; however, rickets remains prevalent, even in industrialized countries. The Centers for Disease Control and Prevention estimates that approximately five in 1,000,000 children between the ages of six months and five years in the U.S. has rickets.³ Rickets can be caused by renal, gastrointestinal, hepatic, or metabolic disease that prevent vitamin D absorption and metabolism. However, nutritional vitamin D deficiency is the leading cause of rickets globally.

The clinical symptoms of rickets tend to present in a bimodal fashion, with the majority of cases presenting during infancy, followed by a small resurgence during adolescence. This is thought to be associated with time periods of high bone turnover during normal growth and puberty.² During infancy, nutritional rickets is primarily caused by exclusive breastfeeding without formula or vitamin supplementation. It is thought that the increase in rickets cases documented in the U.S. is most likely secondary to the increase in popularity of breastfeeding over formula feeding. Breast milk only contains approximately 15-50 international units (IU)/L of vitamin D, which is well below the daily recommended requirement of 200-600 IU/L.^{5,6}

During adolescence, the cause of nutritional rickets is primarily the combination of poor sun exposure and dark pigmented skin. An overwhelming number of articles highlight that the majority of documented cases of rickets occurs in Black and dark-skinned children. Review articles reporting on the prevalence of rickets in the U.S. and Canada consistently report that 83% to 91% of cases are in

Black or dark-skinned patients.^{5,7,8}

Vitamin D plays an integral role in the regulation of intracellular and extracellular calcium concentrations within the human body. Vitamin D is either absorbed through photochemical synthesis of sunlight and ultraviolet light through the skin or by dietary consumption. Specifically, vitamin D₃ (cholecalciferol) is absorbed in the skin by 7-dehydrocholesterol. However, in darkly pigmented children, melanin competes with 7-dehydrocholesterol resulting in poor uptake of cholecalciferol.^{3,7} Vitamin D₂ is consumed by diet. Both forms are ultimately converted by the liver and kidney into the functional form of 1,25-dihydroxyvitamin D (calcitriol). Calcitriol functions with PTH to help balance concentrations of calcium in the serum. Calcitriol stimulates absorption of calcium by the gut or mobilizes calcium and phosphorus from the bone to maintain normal serum calcium levels.

Rickets has been classically defined by the obvious physical exam findings of frontal bossing (protrusion and widening of the forehead), bowed long bones, short stature, and rachitic rosary (beading of the costochondral junctions of the ribs). These, however, are late signs of rickets and uncommonly seen in the U.S or other developed countries. The literature more commonly documents cases with new-onset seizure, severe muscle spasms and tetany, cardiac arrhythmias, and new bone fractures.^{6,7,9} ED work-up for these presentations may reveal low serum concentration of calcium; however, diagnosis of rickets is ultimately made by radiographs of long bones showing cupping, fraying and demineralization at the metaphysis.² The etiology of the rickets requires further work up. Nutritional rickets is specifically diagnosed from lab work showing low serum levels of 25-hydroxyvitamin D (calcidiol)⁷. The patient described in this case was noted to have a calcidiol level of <4 ng/mL (range 20-80 ng/mL), confirming vitamin D-deficient nutritional rickets.

Treatment includes giving intravenous (IV) calcium gluconate for patients presenting with symptomatic hypocalcemia, including seizures, or those with notable ECG changes. For those who present with new-onset seizure or hypocalcemia seizures, there is no evidence for using antiepileptic drugs for seizure prevention. Most articles discuss treatment of the underlying condition and providing vitamin D and calcium supplementation. IV calcium gluconate should be dosed at 100-200 mg/kg/dose with a maximum dose of 1-2 grams. Aggressive oral supplementation should be initiated as well. Vitamin D treatment should be 50,000 IU/L weekly or 2000 IU daily, with a calcium-rich diet.^{6,9}

FINAL DIAGNOSIS

Nutritional vitamin D deficiency (rickets).

KEY TEACHING POINTS

1. Hypocalcemic seizures, tetany, and cardiac arrhythmias are common and concerning ED presentations of rickets.

2. Initial treatment, if presenting with concerning symptoms, is IV calcium gluconate.
3. Diagnosis can be made in the ED by radiographs of the long bones.

Documented patient informed consent and/or Institutional Review Board approval has been obtained and filed for publication of this case report.

Address for Correspondence: Laura J. Bontempo, MD, MEd, University of Maryland, Department of Emergency Medicine, 110 S Paca Street, 6th Floor, Suite 200, Baltimore, MD 21201. Email: Lbontempo@som.umaryland.edu.

Conflicts of Interest: By the *CPC-EM* article submission agreement, all authors are required to disclose all affiliations, funding sources and financial or management relationships that could be perceived as potential sources of bias. The authors disclosed none.

Copyright: © 2019 Rosenblatt et al. This is an open access article distributed in accordance with the terms of the Creative Commons Attribution ([CC BY 4.0](https://creativecommons.org/licenses/by/4.0/)) License. See: <http://creativecommons.org/licenses/by/4.0/>

REFERENCES

1. Hirtz D, Ashwal S, Berg A, et al. Practice parameter: evaluating a first nonfebrile seizure in children. *Neurology*. 2000;55(5):616-23.
2. Wharton B and Bishop N. Rickets. *Lancet Lond Engl*. 2003;362(9393):1389-400.
3. Nield LS, Mahajan P, Joshi A, et al. Rickets: not a disease of the past. *Am Fam Physician*. 2006;74(4):619-26.
4. Zhang M, Shen F, Petryk A, et al. "English disease": historical notes on rickets, the bone-lung link and child neglect issues. *Nutrients*. 2016;8(11):722.
5. Weisberg P, Scanlon KS, Li R, et al. Nutritional rickets among children in the United States: review of cases reported between 1986 and 2003. *Am J Clin Nutr*. 2004;80(6 Suppl):1697S-705S.
6. Bellazzini MA and Howes DS. Pediatric hypocalcemic seizures: a case of rickets. *J Emerg Med*. 2005;28(2):161-4.
7. Schnadower D, Agarwal C, Oberfield SE, et al. Hypocalcemic seizures and secondary bilateral femoral fractures in an adolescent with primary vitamin D deficiency. *Pediatrics*. 2006;118(5):2226-30.
8. Ward LM, Gaboury I, Ladhani M, et al. Vitamin D-deficiency rickets among children in Canada. *CMAJ Can Med Assoc J J Assoc Medicales Can*. 2007;177(2):161-6.
9. Bloom E, Klein EJ, Shushan D, et al. Variable presentations of rickets in children in the emergency department. *Pediatr Emerg Care*. 2004;20(2):126-30.

Code Blue: Life-threatening Methemoglobinemia

José D. Ponce Ríos, MD*
 Rothsovann Yong, MD, MA, MPH†
 Paul Calner, MB, Bch, BAO†

*Lowell General Hospital, Department of Pediatric Emergency Medicine, Lowell, Massachusetts
 †Lowell General Hospital, Department of Emergency Medicine, Lowell, Massachusetts

Section Editor: Steven Walsh, MD

Submission history: Submitted November 28, 2018; Revision received February 20, 2019; Accepted March 5, 2019

Electronically published March 27, 2019

Full text available through open access at http://escholarship.org/uc/uciem_cpccem

DOI: 10.5811/cpccem.2019.3.41794

Most cases of acquired methemoglobinemia result from exposure to certain drugs or toxins. One of the more common and well-described causes in the literature is exposure to topical benzocaine during medical procedures. We present a case series of acute acquired methemoglobinemia from a food source that has not been previously described in the literature: a dessert. Three patients, ages 5, 33, and 86 years, were brought to our emergency department by ambulance after becoming extremely ill from ingesting a dessert containing nitre powder at a family gathering. They all presented with hypotension, cyanosis, and hypoxia that was not responsive to oxygen administration. The adult patients had major improvement of symptoms after a single dose of methylene blue. In contrast, the 5-year-old child who had the worst symptoms minimally improved with administration of two doses of methylene blue requiring intensive care admission and transfer to a tertiary care center. [Clin Pract Cases Emerg Med. 2019;3(2):95-99.]

INTRODUCTION

Methemoglobinemia, which can be congenital or acquired, occurs when there is an elevated level of methemoglobin circulating in the blood. Methemoglobin is an oxidized form of hemoglobin;¹ it is produced when the iron in the hemoglobin molecule is in the ferric instead of the ferrous state. Methemoglobin, unlike its counterpart oxyhemoglobin, cannot carry oxygen or carbon dioxide and therefore leads to a state of hypoxia. Clinical manifestations include altered mental status, cyanosis, acidosis, impaired aerobic respiration, and in severe cases, coma and death.² We report our experience with three patients who presented to the emergency department (ED) with acquired methemoglobinemia after ingestion of a dessert at a family gathering. We will discuss diagnosis and management for methemoglobin toxicity.

CASE SERIES

Three patients, ages 5, 33 and 86 years, presented to the ED after becoming acutely ill at a family gathering. All three members ingested a pandan honeycomb cake, which contained “nitre powder” used as a thickening agent. While all three patients had significant symptoms, here we present in detail the case of the 5-year-old child who had the most profound symptoms.

CASE 1

A 5-year-old female who fell ill after eating dessert at a party presented to our ED via ambulance. The parents reported that the child had two large servings of cake and subsequently developed vomiting, loose stools, and syncope. They noted her to be “blue” (Image 1); 911 was called, and she was brought by ambulance to the hospital. During our encounter, the patient was very quiet and did not report any complaints. Vital signs upon arrival to the ED showed blood pressure 75/47 millimeters of mercury (mmHg), pulse oximetry 77% on 12 liters non-rebreather mask, respiratory rate 30 breaths per minute, and heart rate of 117 beats per minute. Her physical exam was significant for cyanosis, clear lungs to auscultation, and tachycardia on cardiovascular examination. The diagnosis of methemoglobinemia was quickly suspected given the clinical presentation of sudden onset cyanosis not improving with oxygen administration as well as low pulse oximetry.

Methemoglobinemia workup was initiated; upon collection, blood appeared very dark in the laboratory tubes. Co-oximetry confirmed an elevated methemoglobin level at 52%, venous blood gas showed a partial pressure of oxygen (pO₂) of 178 mmHg, and lactic acid was 3.3 millimoles per liter (mmol/L). Blood pressure improved after two 20

milliliters per kilogram (mL/kg) boluses of normal saline, but patient continued to have tachycardia and cyanosis. We administered one milligram per kilogram (mg/kg) of methylene blue intravenously over five minutes. When we re-checked her methemoglobin level at 30 minutes after methylene infusion, it was 38.6%; pulse oximetry remained in the 70%-80% range. The patient continued to appear cyanotic despite administration of the first dose of methylene blue; therefore, we administered the second dose of one mg/kg of methylene blue. While the patient had some improvement, she continued to be cyanotic throughout her course in the ED.

Due to a persistently elevated methemoglobin level, continued cyanosis, tachycardia, and signs of hypoxia (Table), despite the second dose of methylene blue, the decision was made to admit the child to a tertiary care center. She was transferred to the facility 60 minutes away by the tertiary care center's critical care ground transport team, which included a pediatric intensive care nurse and pediatric respiratory therapist, as well as two paramedics. Upon arrival, her methemoglobin level was 6.7% and lactate level was normal; supplemental oxygen was removed and remained off overnight. She tolerated oral intake and was discharged home the next day. No additional methemoglobin level was obtained.

CASE 2

A 33-year-old female with no significant past medical history presented to our ED from the same party after ingesting the same dessert. She reported feeling short of breath and had vomiting, loose stool, and a near-syncope event. She had no chronic conditions, took no medications on a daily basis, and had no allergies. Upon arrival, she appeared in mild distress and slightly anxious. Vital signs in the ED showed blood pressure 99/75 mmHg, pulse oximetry 81% on six liters nasal cannula, a respiratory rate of 16 breaths per minute, and heart rate of 87 beats per minute. Except for cyanosis on physical exam, the patient appeared in no acute distress. She had clear lungs, normal cardiovascular exam and an unremarkable abdominal exam. She had a methemoglobin level of 17.2%. After she was treated with one mg/kg methylene blue, vital signs normalized, and repeat methemoglobin level three hours after methylene blue infusion was 1.2%. She was discharged from the hospital after several hours of observation.

CASE 3

An 86-year-old female with a past medical history of hypertension and dyslipidemia was brought to our ED by ambulance from the same family gathering after ingesting the same honeycomb cake. She complained of feeling unwell with lightheadedness, headache, recurrent vomiting, shortness of breath, and chest pain followed by a syncopal episode. Paramedics reported that the patient was cyanotic with pulse oximetry 70% on 12 liters non-rebreather mask and

CPC-EM Capsule

What do we already know about this clinical entity?

In methemoglobinemia, high levels of methemoglobin circulate in the blood; if untreated, it can lead to death. Symptoms include cyanosis, tachycardia, shortness of breath, and lethargy.

What makes this presentation of disease reportable?

We represent a case series of acute acquired methemoglobinemia from a food source that has not been previously described in the literature: a dessert.

What is the major learning point?

Methemoglobinemia can be fatal. Prompt administration of methylene blue should be the first line treatment; ascorbic acid can be used as an adjuvant.

How might this improve emergency medicine practice?

Methemoglobinemia diagnosis requires high index of suspicion thorough history and physical exam. Prompt identification of patients is paramount to minimize morbidity and mortality.

hypotensive with systolic blood pressure 80 mmHg. On arrival to the ED, she was awake, alert and ill-appearing with the following vital signs: pulse oximetry 85% on non-rebreather mask, respiratory rate 25 breaths per minutes, pulse rate 98 beats per minutes, and blood pressure 115/72 mmHg after one liter normal saline bolus. Her physical exam was significant for severe cyanosis, tachypnea, clear lungs to auscultation, and tachycardia on cardiovascular examination. Given the concurrent presentation with the other two patients from the same party, we treated the patient with one dose of methylene blue prior to obtaining initial methemoglobin levels.

Her vital signs stabilized on reevaluation after 30 minutes of methylene blue administration. She reported complete resolution of symptoms including chest pain, shortness of breath, and headache. Her pulse oximetry improved to 92% on room air. Her comprehensive metabolic panel results were within normal limits except for a slight elevation of creatinine

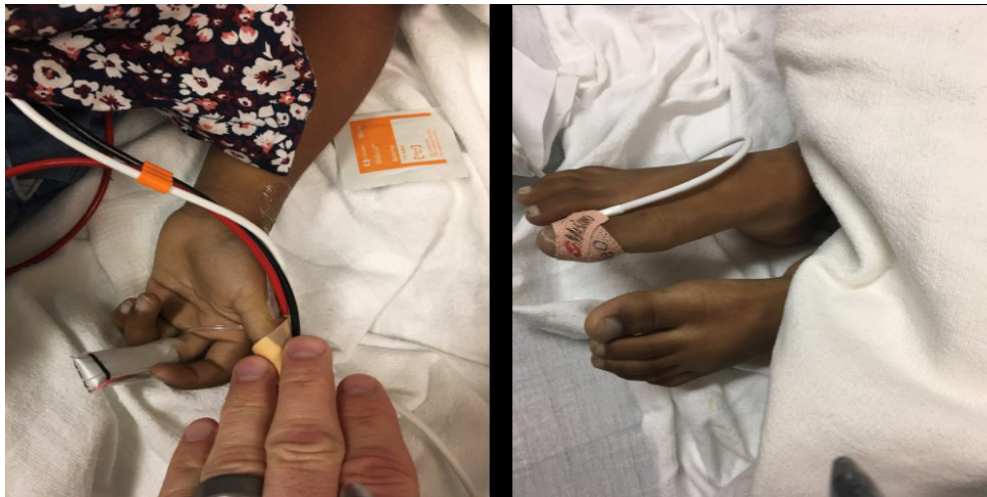

Image 1. Five-year-old patient's severely cyanotic hand and feet.

Table. Laboratory data and vital signs pre- and post-treatment with methylene blue.

Venous blood gas (100% FiO ₂)	Pretreatment	30 Minutes post treatment	Reference range
pCO ₂ (mmHg)	34.4	39.2	41.0-51.0
pO ₂ (mmHg)	178.0	41.4	
HCO ₃ (mmol/L)	*21.9	*19.4	22.0-26.0
pH	7.382	*7.317	7.320-7.420
Carboxyhemoglobin (%)	0.1	0.4	
Methemoglobin (%)	*52.0	*38.6	< 2
Lactic acid (mmol/L)	*3.3	Not obtained	0.4-2.0
Red blood cells 10 ⁹	3.82	Not obtained	3.7-5.30
Hemoglobin (g/dL)	10.9	Not obtained	11.0-14.0
Hematocrit(%)	32.8	Not obtained	33.0-42.0
Pulse rate (beats per minute)	117	*129	90-120
Respiratory rate (breaths per minute)	*30	26	20-28
Systolic blood pressure (mmHg)	*75	91	89-112
Diastolic blood pressure (mmHg)	47	*40	46-72
SpO ₂ on 100% supplemental oxygen (%)	*77	*82	> 90

pCO₂, carbon dioxide partial pressure; pO₂, oxygen partial pressure; HCO₃, bicarbonate; mmHg, millimeters of mercury; mmol/L, millimoles per liter; g/dL, grams per deciliter; SpO₂, saturation of peripheral oxygen; FiO₂, fraction of inspired oxygen.

*Abnormal findings.

from her baseline. Troponin I levels were negative. Initial methemoglobin levels pretreatment were unknown, but levels obtained at 30 minutes and 10 hours after methylene blue administration were 6.7% and 0.7%, respectively. The patient was admitted to telemetry for further observation, but once there she became hypotensive with blood pressure 90/50 mmHg despite administration of two additional liters of normal saline. She was then transferred to the intensive care unit (ICU) for

monitoring. She remained asymptomatic on room air with resolution of hypotension after receiving intravenous fluids at 100 mL per hour in the ICU overnight and was downgraded back to telemetry in the morning. She had a full recovery and was discharged home the following day.

DISCUSSION

Methemoglobinemia can be congenital or acquired. There

are four types of congenital methemoglobinemia.³ Type I (the most common) is cytochrome b5 reductase deficiency in the red blood cells, leading to mild cyanosis, headaches, and fatigue. In type II there is a global deficiency of cytochrome b5 reductase, and patients have severe symptoms as well as neurologic deficits.³⁻⁵ Type III is no longer considered an entity of its own as it presents like type I; type IV has only been described once.^{4,6,7}

Acquired methemoglobinemia can occur from a myriad of causes; medications and oxidation stress by illness have all been described in the literature. Some xenobiotics are commonly identified as culprits in cases of acquired methemoglobin. These agents include dapsone, lidocaine, nitrates, and sulfa-containing drugs.⁸⁻¹¹

Acquired methemoglobinemia presents with multiple symptoms secondary to a lack of oxygen delivery to tissues. These symptoms include cyanosis, tachycardia, shortness of breath and lethargy as we saw in our cases. As the patient's methemoglobin level increases, he or she will develop changes in mental status and increased respiratory rate, and potentially coma, seizures, and even death.^{12,13}

It is typically only after the methemoglobin level exceeds 10% of total hemoglobin that patients will become cyanotic. Levels greater than 30-40% are considered life-threatening, similar to what we found in our 5-year-old patient, and are associated with severe symptoms and profound hypoxia. Levels greater than 70% are often fatal.^{1,13-16}

Methemoglobinemia should be suspected in all patients with sudden onset of cyanosis that does not improve with the administration of oxygen or after ingestion or administration of a potential oxidative agent. It should also be suspected in patients who are clinically cyanotic but have a normal arterial pO₂. An additional clue in our 5-year-old patient that helped us diagnose methemoglobin toxicity was discoloration of the blood sample observed during phlebotomy. Blood with an elevated methemoglobin level has been described as chocolate, brownish-blue, or dark red in color.¹² Once suspected, a methemoglobin level should be obtained. It is important not to follow pulse oximetry on these patients as the value is often inaccurate.²

Once identified, methemoglobinemia should be treated aggressively, especially if methemoglobin levels are greater than 20% or if the patient is symptomatic.¹ There are two main treatments available: methylene blue and ascorbic acid.¹⁷ In patients with acute acquired methemoglobinemia who are symptomatic or have methemoglobin levels > 20 a single dose of one to two mg/kg of methylene blue should be given over five minutes, within 10-60 minutes of symptom onset. The response is typically very quick and a second dose is rarely required except in severe cases.¹⁸ In severe methemoglobinemia, patients should be managed in an ICU setting for close monitoring and stabilization of their airway, breathing, and circulation. If a patient has a methemoglobin level < 20 % and is asymptomatic, no therapy is recommended and close observation is reasonable.

Alternatively, ascorbic acid may be used to treat acquired methemoglobinemia, especially in those patients with glucose-6-phosphate dehydrogenase deficiency (G6PD) where methylene blue is contraindicated, or, if methylene blue is not available. Therapeutic doses of methylene blue may lead to severe hemolysis of erythrocytes especially in patients with G6PD; if ascorbic acid is used, multiple doses are often required over 24 hours or more.^{17,19,20}

Upon further investigation with the family we discovered that the dessert had “nitre powder,” which had been used as a thickening agent. “Nitre powder” is actually sodium nitrate (Image 2), a crystalline powder used for curing meats and preserving their color. The United States Food and Drug Administration allows its use for curing meats.²¹ In our literature review of acquired methemoglobinemia, we found cases of nitrate ingestions from ingesting cured meats at home²² and in intentional ingestions,¹⁵ but no cases related to ingesting a dessert. Obtaining a thorough medical history and physical exam was paramount in obtaining a diagnosis for these three patients. These cases were reported to the Department of Public Health since the product had been recently purchased at a local market despite it having been recalled years prior due to safety concerns.

CONCLUSION

Methemoglobinemia should be suspected in all patients with sudden onset of cyanosis that does not improve with the administration of oxygen. Prompt administration of methylene blue should be the first-line treatment. Ascorbic acid can be used as adjuvant therapy when there is a contraindication to methylene blue, or when methylene blue is not available.



Image 2. Package of nitre powder purchased from a local supermarket.

Documented patient informed consent and/or Institutional Review Board approval has been obtained and filed for publication of this case report.

Address for Correspondence: José D. Ponce Ríos, MD, Lowell General Hospital, Department of Emergency Medicine, 295 Varnum Avenue Lowell, MA 01854. Email: jose.ponce-rios@lowellgeneral.org.

Conflicts of Interest: By the CPC-EM article submission agreement, all authors are required to disclose all affiliations, funding sources and financial or management relationships that could be perceived as potential sources of bias. The authors disclosed none.

Copyright: © 2019 Ponce Ríos et al. This is an open access article distributed in accordance with the terms of the Creative Commons Attribution (CC BY 4.0) License. See: <http://creativecommons.org/licenses/by/4.0/>

REFERENCES

- Blanc PD (2012). Methemoglobinemia. In Olson KR (Ed.), *Poisoning & Drug Overdose* (261-3). New York, NY: The McGraw-Hill Companies.
- Wright RO, Lewander WJ, Woolf AD. Methemoglobinemia: etiology, pharmacology, and clinical management. *Ann Emerg Med.* 1999;34(5):646-56.
- DomBourian M, Ezhuthachan A, Kohn A, et al. A 5-hour-old male neonate with cyanosis. *Lab Med.* 2015;46(1):60-3.
- Percy MJ and Lappin TR. Recessive congenital methaemoglobinemia: cytochrome b5 reductase deficiency. *Br J Haematol.* 2008;141(3):298-308.
- Soliman DS and Yassin M. Congenital methemoglobinemia misdiagnosed as polycythemia vera: Case report and review of literature. *Hematol Rep.* 2018;10(1):7221.
- Da-Silva SS, Sajjan IS, Underwood JP. Congenital methemoglobinemia: a rare cause of cyanosis in the newborn—a case report. *Pediatrics.* 2003;112(2):e158-61.
- Tanishima K, Tanimoto K, Tomoda A, et al. Hereditary methemoglobinemia due to cytochrome b5 reductase deficiency in blood cells without associated neurologic and mental disorders. *Blood.* 1985;66(6):1288-91.
- Bohnhorst B, Hartmann H, Lange M. Severe methemoglobinemia caused by continuous lidocaine infusion in a term neonate. *Eur J Paediatr Neurol.* 2017;21(3):576-9.
- Günel E, Akkus Y, Cigsar G, et al. Methemoglobinemia incidence after the application of lidocaine for small surgical procedures. *Ağrı.* 2017;29(4):173-6.
- Canning J and Levine M. Case files of the medical toxicology fellowship at banner Good Samaritan Medical Center in Phoenix, AZ: methemoglobinemia following dapsone exposure. *J Med Toxicol.* 2011;7(2):139-46.
- Pollack ES and Pollack CV. Incidence of subclinical methemoglobinemia in infants with diarrhea. *Ann Emerg Med.* 1994;24(4):652-6.
- Cortazzo JA and Lichtman AD. Methemoglobinemia: a review and recommendations for management. *J Cardiothorac Vasc Anesth.* 2014;28(4):1043-7.
- Coleman MD and Coleman NA. Drug-induced methaemoglobinemia. Treatment issues. *Drug Saf.* 1996;14(6):394-405.
- Spiller HA, Revolinski DH, Winter ML, et al. Multi-center retrospective evaluation of oral benzocaine exposure in children. *Vet Hum Toxicol.* 2000;42(4):228-31.
- Cruz MD, Glick J, Merker SH, et al. Survival after severe methemoglobinemia secondary to sodium nitrate ingestion. *Toxicol Commun.* 2018;2(1):21-3.
- Zedan A, Omar S, Mahmoud F. Drug-induced methemoglobinemia: a case report and review of literature. *Southwest Respir Crit Care Chron.* 2014;2(5):34.
- Rino PB, Scolnik D, Fustiñana A, et al. Ascorbic acid for the treatment of methemoglobinemia: the experience of a large tertiary care pediatric hospital. *Am J Ther.* 2014;21(4):240-3.
- D'sa SR, Victor P, Jagannati M, et al. Severe methemoglobinemia due to ingestion of toxicants. *Clin Toxicol (Phila).* 2014;52(8):897-900.
- Guay J. Methemoglobinemia related to local anesthetics: a summary of 242 episodes. *Anesth Analg.* 2009;108(3):837-45.
- D'sa SR, Victor P, Jagannati M, et al. Severe methemoglobinemia due to ingestion of toxicants. *Clin Toxicol (Phila).* 2014;52(8):897-900.
- US Food and Drug Administration. CFR - Code of Federal Regulations Title 21. Available at: <https://www.accessdata.fda.gov/scripts/cdrh/cfdocs/cfrcfr/CFRSearch.cfm?fr=172.170&SearchTerm=nitrate>. Accessed June 27, 2018.
- Jain MD and Nikonova A. Methemoglobinemia from curing salt. *CMAJ.* 2013;185(16):E771.

Anterior Loculated Pericardial Effusion Misinterpreted as Right Heart Dilation Suggesting Pulmonary Embolism

Sari Lahham, MD, MBA*
Emily Frisch, BS†
Mark I. Langdorf, MD, MHPE*

*University of California, Irvine, Department of Emergency Medicine, Orange, California
†University of California, Irvine, School of Medicine, Irvine, California

Section Editor: Rick A. McPheeters, DO

Submission history: Submitted August 21, 2018; Revision received January 24, 2019; Accepted January 22, 2019

Electronically published February 26, 2019

Full text available through open access at http://escholarship.org/uc/uciem_cpem

DOI: 10.5811/cpcem.2019.1.40700

We report a case of anterior loculated pericardial effusion misinterpreted on point-of-care ultrasound as a dilated right ventricle, and suggesting diagnosis of pulmonary embolism (PE), in a patient with renal failure. The compressed right ventricle from tamponade physiology appeared to be a thickened intraventricular septum. Heparin was given empirically for presumed PE. Later the same day, computed tomography of the chest showed the effusion, as did formal echocardiogram. The patient had drainage of 630 milliliters of fluid and recovered from tamponade. Loculated effusions comprise 15% of all pericardial effusions, and misdiagnosis of PE with heparin therapy could be fatal. [Clin Pract Cases Emerg Med. 2019;3(2):100-102.]

INTRODUCTION

Pericardial effusion is abnormal fluid in the pericardial sac. Increased pressure impairs diastolic filling and hence cardiac output, progressing to cardiac tamponade.¹ Pericardial effusion clinically manifests as chest pain or pressure, weakness, near syncope and shortness of breath. Causes include pericarditis, infection, retrograde aortic dissection, post-myocardial infarction free wall rupture, renal failure, malignancy, and trauma. Loculated effusions are more common when scarring has supervened (e.g., postsurgical, post-trauma, post-purulent pericarditis),² and comprise 15% of effusions.³

Point-of-care ultrasound (POCUS) is typically readily diagnostic of pericardial effusion. The fluid appears anechoic, typically circumferential around the heart.^{1,2} Smaller effusions appear as a thin stripe, visible only posteriorly with gravity. The right side of the heart is most susceptible to compression by fluid since it is low pressure. Diastolic collapse of the right ventricle and right atrium defines tamponade physiology. A loculated anterior effusion has potential to cause tamponade. Although loculated pericardial effusion has been recently reported, POCUS simulating right heart strain and pulmonary embolism (PE) has not.⁴

CASE REPORT

A 46-year-old Asian man with history of hypertension, end-stage renal disease on dialysis, thrombotic stroke, and chronic

tobacco use presented to the emergency department (ED) with chief complaint of weakness, lightheadedness, and shortness of breath for two days. He had dialysis one day before, but did not feel better. He developed central chest pain at rest four to five hours prior to arrival, which was worse with deep inspiration. He was seen at an outside hospital and was told he had a pericardial effusion. He was then sent to our ED for higher level of care.

On arrival, blood pressure was 124/89 millimeters of mercury (mmHg), heart rate 120 beats per minute, respiratory rate 18 per minute, oral temperature 37.4° centigrade and oxygen saturation 93% on room air. His body mass index was 23 kg/m². His physical exam was notable for warm and dry skin, normal mentation, hyperdynamic precordium, normal S1 and S2, and no audible murmur, rub or gallop. There was jugular venous distention while sitting up at 90 degrees, but this was not specifically measured. There were no rales of pulmonary congestion and he had no leg edema or complaints of pain.

POCUS did not reveal circumferential or dependent effusion or tamponade physiology. The bedside image was interpreted as an enlarged right ventricle (RV), nearly twice the transverse dimension of the left ventricle, with a thickened intraventricular septum, suspicious for right heart strain (Video).

The patient had laboratory studies, electrocardiogram (Image 1), anterior-posterior portable chest radiograph (Image 2), and computed tomography angiography (CTA) to assess for PE (Image 3), among other diagnoses. He was given aspirin,

and unfractionated heparin bolus and drip per cardiology recommendations pending CTA, which was done upon admission a few hours after presentation to the ED. He was admitted to the coronary care unit. The CTA then revealed a loculated anterior pericardial effusion, and the thickened septum was determined to be the compressed RV, which had not been appreciated on POCUS.

His initial troponin was 0.23 nanograms per milliliter (ng/mL) (normal < .03 ng/mL) in the ED, and rose to 0.26 upon admission six hours later. This was thought to be due to renal failure and not acute coronary syndrome per the inpatient team. The patient had pericardiocentesis of 630 mL sterile serosanguinous fluid under ultrasound guidance in the cardiac catheterization lab. Initial intrapericardial pressure was 20 mmHg. The cause of the effusion was ultimately attributed to uremia. The patient had no history of infection or cardiac surgery to predispose to loculation. Fortunately, there was no complication of the unnecessary anticoagulation.

DISCUSSION

Pericardial effusion has traditionally been diagnosed via POCUS in the ED. Typical circumferential pericardial effusions are drained percutaneously with a small catheter.³ However, approximately 15% of the time, effusions become loculated from adhesions.² Common causes include scarring after trauma and purulent pericarditis.² Identifying loculated effusion is significant, as surgical pericardiectomy drainage is preferred.⁴ This report

CPC-EM Capsule

What do we already know about this clinical entity?

Pericardial effusions are consistently well and rapidly diagnosed through point-of-care ultrasound, given standard presentation.

What makes this presentation of disease reportable?

A loculated pericardial effusion can simulate an enlarged right ventricle and lead to misdiagnosis of pulmonary embolism (PE).

What is the major learning point?

Loculated pericardial effusions comprise 15% of all effusions, with 80% circumferential and 5% unspecified.

How might this improve emergency medicine practice?

Recognition of this entity can avoid anticoagulation for PE, which may worsen effusion and lead to tamponade.

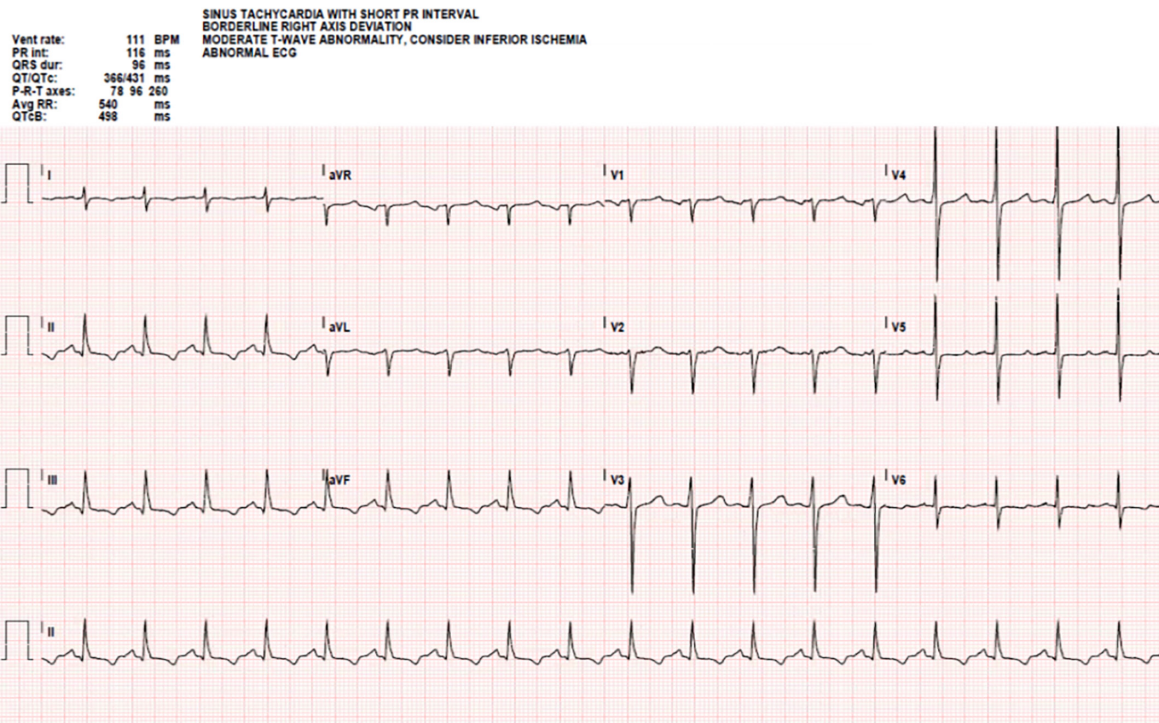


Image 1. Electrocardiogram showing sinus tachycardia rate 111, but no low voltage, electrical alternans or signs of hyperkalemia.

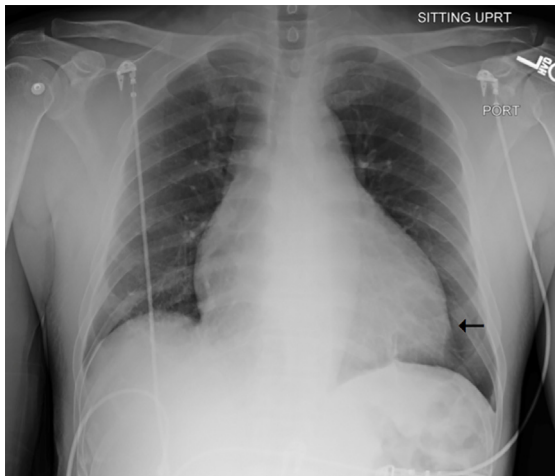


Image 2. Chest radiograph demonstrating cardiomegaly (arrow) but no vascular congestion.

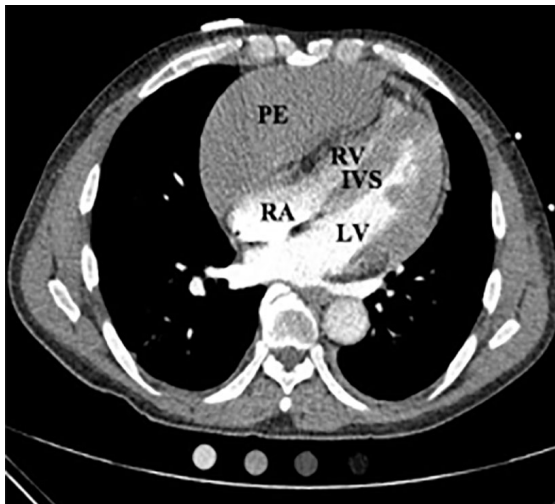


Image 3. Computed tomography angiography showing loculated anterior pericardial effusion (PE), right ventricle (RV), left ventricle (LV) and intraventricular septum (IVS). There was a 6.0 x 1.3 cm pericardial fluid collection, which extended predominantly along the right heart border and superiorly along the superior pericardial recess. There was severe compression of the RV and right atrium (RA).

highlights a pitfall of POCUS, but emphasizes the importance of the entire clinical presentation.

The patient's hypoxia, tachycardia, shortness of breath and chest pain were consistent with the working diagnosis of PE, but his relatively narrow pulse pressure, enlarged cardiac silhouette and history of dialysis-dependent renal failure suggested pericardial effusion. If POCUS is not convincing in a patient with suspicion for pericardial effusion, CT imaging or formal echocardiogram should be considered to help differentiate, as in this case. Early identification of pericardial effusion can be

critical in preventing and treating tamponade. We recommend POCUS, formal ultrasound or CTA of the chest to evaluate these two life threats.

CONCLUSION

Pericardial effusions are commonly diagnosed in the ED through POCUS. If clinical suspicion suggests pericardial effusion but circumferential fluid is not seen, loculated effusion should be considered. CTA or formal ultrasound will differentiate between these two life threats.

Video. Video clip of point-of-care ultrasound.

Documented patient informed consent and/or Institutional Review Board approval has been obtained and filed for publication of this case report.

Address for Correspondence: Mark I. Langdorf, MD, MHPE, University of California, Irvine, Department of Emergency Medicine, 333 City Blvd. West, Suite 640, Route 128, Orange CA 92868. Email: milangdo@uci.edu.

Conflicts of Interest: By the CPC-EM article submission agreement, all authors are required to disclose all affiliations, funding sources and financial or management relationships that could be perceived as potential sources of bias. The authors disclosed none.

Copyright: © 2019 Lahham et al. This is an open access article distributed in accordance with the terms of the Creative Commons Attribution (CC BY 4.0) License. See: <http://creativecommons.org/licenses/by/4.0/>

REFERENCES

1. Lee EK. Malignant pericardial effusion presenting as a wheeze-case report. *Crit Care Shock*. 2017;20(4):102-8.
2. Maisch B, Seferovic PM, Ristic AD, et al. Guidelines on the Diagnosis and Management of Pericardial Diseases, European Society of Cardiology. *Eur Heart J*. 2004;25(7):587-610.
3. Kopecky SL, Callahan JA, Tajik AJ, et al. Percutaneous pericardial catheter drainage: report of 42 consecutive cases. *Am J Cardiol*. 1986;58(7):633-5.
4. Tsang TS, Enriquez-Sarano M, Freeman WK, et al. Consecutive 1127 therapeutic echocardiographically guided pericardiocenteses: clinical profile, practice patterns, and outcomes spanning 21 years. *Mayo Clin Proc*. 2002;77(5):429-36.
5. Yang ZM, Pontius E, Motalib S, et al. Idiopathic loculated and septated pericardial effusion. *J Emerg Med*. 2018;55(2):e51-2.

Aortic Dissection with Subsequent Hemorrhagic Tamponade Diagnosed with Point-of-care Ultrasound in a Patient Presenting with STEMI

Eric Abrams, MD*
Angela Allen, BS†
Shadi Lahham, MD, MS*

*University of California, Irvine, Department of Emergency Medicine, Orange, California
†University of California, Irvine, School of Medicine, Irvine, California

Section Editor: Rick A. McPheeters, DO

Submission history: Submitted September 8, 2018; Revision received September 12, 2018; Accepted January 12, 2019

Electronically published February 26, 2019

Full text available through open access at http://escholarship.org/uc/uciem_cpem

DOI: 10.5811/cpcem.2019.1.40869

A 58-year-old male with no past medical history presented to the emergency department with sudden onset left lower extremity weakness and central chest pain with radiation to his back. Electrocardiogram revealed an acute inferior and posterior ST-segment elevation myocardial infarction (STEMI). Point-of-care ultrasound (POCUS) demonstrated right ventricular akinesis consistent with infarction, and an intimal defect consistent with an aortic dissection. We determined that cardiothoracic surgery was indicated rather than left-heart catheterization and anticoagulation. Using POCUS we were able to immediately diagnose a dissection of the aortic arch and considerably alter treatment in a patient presenting with STEMI. [Clin Pract Cases Emerg Med. 2019;3(2):103-106.]

INTRODUCTION

Aortic dissection (AD) is a life-threatening emergency with a mortality rate of up to 30%.¹ Due to either a tear in the aortic intima or hemorrhage within the media, an AD occurs when blood separates the intima from the media.² The dissection may extend either proximally to involve the aortic valve and coronary vessels and enter the pericardial space, or extend distally to involve the abdominal aorta.² All of these situations can lead to severe decompensation and death if not addressed immediately. Presented in this case is a male with AD recognized via point-of-care-ultrasound (POCUS).

CASE REPORT

A 58-year-old male who denied any past medical history presented to the emergency department (ED) with left lower extremity weakness for the prior 30 minutes. He stated that he had sudden onset paralysis, which prompted him to go to the ED for evaluation. On further inquiry, the patient also described having central chest pain radiating to the back that seemed to coincide with the paralysis. He denied shortness of breath or any other neurological deficits.

Upon arrival to the ED, the patient was diaphoretic, pale, and in acute distress. Vitals at the time included a pulse of

74 beats per minute, blood pressure of 166/97 millimeters of mercury in the right upper extremity, respirations of 20 breaths per minute, oxygen saturation of 97% on room air, and an oral temperature of 97.9 degrees Fahrenheit. His pertinent physical exam findings included bilateral diminished radial pulses and 0/5 strength in his left lower extremity. His lungs were clear to auscultation bilaterally and there was no appreciable murmur. No chest radiograph (CXR) was obtained.

An electrocardiogram (ECG) was performed (Image 1) that demonstrated an acute inferior and posterior ST-segment elevation myocardial infarction (STEMI), which prompted activation of a “code STEMI.” However, while he was still in the ED, we performed a POCUS. Ultrasound revealed right ventricle akinesis consistent with an acute MI and a dissection flap of the aortic arch, but was negative for pericardial effusion or tamponade at that time (Image 2). Based on these ultrasound findings and with cardiology at bedside, the code was cancelled as it was agreed that percutaneous coronary intervention should not be performed and instead cardiothoracic surgery be emergently paged. The patient was immediately brought to the radiology suite for an emergent computed tomography angiogram (CTA) of the chest and abdomen.

Unfortunately, while on the table prior to imaging acquisition, the patient became bradycardic, unresponsive, apneic, and was found to be in pulseless electrical activity arrest. CTA was aborted and cardiopulmonary resuscitation was initiated. He was brought to the resuscitation bay where repeat POCUS demonstrated a large, complex pericardial effusion with right and left ventricular collapse representing hemorrhagic tamponade (Image 3). An emergent pericardiocentesis was performed with ultrasound guidance without success. Given hemorrhagic tamponade from AD and failed pericardiocentesis, the resuscitation was deemed to be medically futile and time of death was called.

DISCUSSION

The incidence of AD in the general population is up to six cases per 100,000 per year and up to 30 in individuals over 65.² Common risk factors for this condition include longstanding arterial hypertension, connective tissue disorders, vascular inflammatory processes, deceleration trauma, and iatrogenic origins, with hypertension being the most common.² There are two methods to classify AD. The Stanford classification includes type A and type B where the former involves the ascending aorta and the latter does not. The DeBakey classification is divided into three types: I involves the ascending and descending aorta; II involves only the ascending aorta; and III spares the ascending aorta and arch.²

The classic symptoms associated with AD vary widely, complicating diagnosis and treatment plans. In a case-control study, it was found that the absence of abrupt-onset pain could

CPC-EM Capsule

What do we already know about this clinical entity?

Aortic dissection is a rare but life-threatening cause of ST-segment elevation myocardial infarction (STEMI).

What makes this presentation of disease reportable?

The use of point-of-care ultrasound (POCUS) to cancel catheterization laboratory activation based on the diagnosis of aortic dissection.

What is the major learning point?

POCUS should be used in patients who present with STEMI to evaluate for other life-threatening pathology.

How might this improve emergency medicine practice?

If aortic dissection can be readily diagnosed with ultrasound, the new standard of care for STEMI patients may be to perform POCUS.

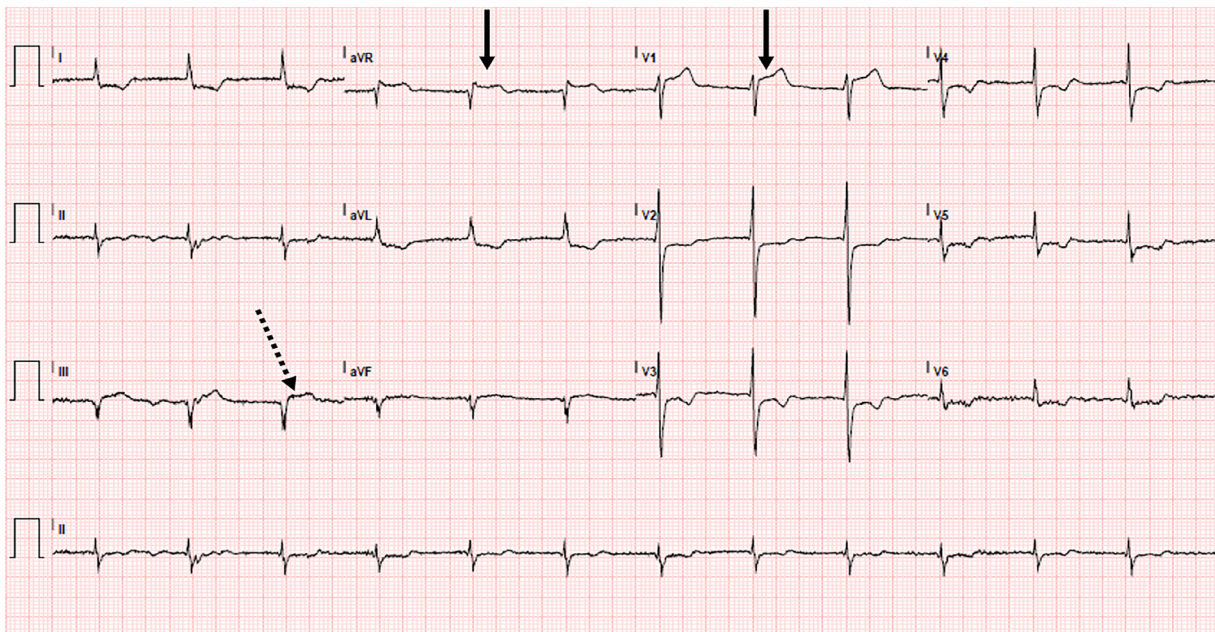


Image 1. Electrocardiogram performed demonstrating inferior ST-segment elevation myocardial infarction (dashed arrow) with additional ST-segment elevation in V1 and aVR (solid arrow) consistent with right coronary artery infarction with right ventricle involvement.

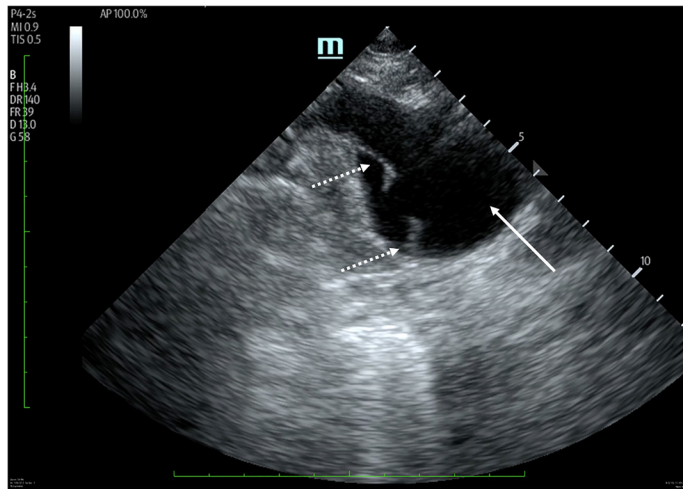


Image 2. Suprasternal ultrasound visualizing the aortic arch in transection (white arrow) with a non-contiguous dissection flap at the 8 and 10 o'clock positions (dashed arrow) representing the aortic mural defect causing dissection.

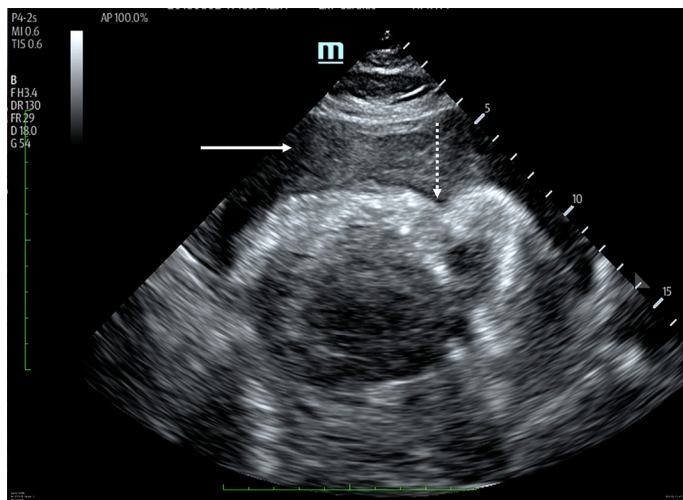


Image 3. Subxiphoid cardiac ultrasound demonstrating a large complex pericardial effusion (solid arrow) with complete right ventricular (RV) collapse and bowing of the RV free wall (dashed arrow).

help rule out dissection while the presence of tearing or ripping pain, hypotension, pulse deficit, neurologic deficits, and new murmur can help rule in the diagnosis; however, less than 50% of patients present with classic chest pain.³ Pulse deficits are present in only 20% of people, and 10-15% of patients deny pain altogether.¹⁻² Symptoms may even resemble associated conditions such as acute MI. Although an AD may extend into the coronary vessels leading to MI, treatment of a suspected MI with anticoagulation and antiplatelet therapy is detrimental in AD and can double mortality.⁴ One study found that multiple patients with

acute MI induced by AD were incorrectly treated with fibrinolysis and estimated that the mortality rate of such patients ranged from 69-100%, highlighting the importance of accurate diagnosis of the underlying cause of a patient's condition.⁵

The American College of Emergency Physicians (ACEP) evaluated a study that attempted to generate a standard guideline for the diagnosis and treatment of these patients. They concluded that the decision and methods to evaluate for acute AD ought to be decided by individual clinicians based on their judgment since it has been reported that AD is only initially suspected in the ED 43% of the time, especially in the absence of chest and abdominal symptoms.⁶⁻⁷ Diagnosis can be made using several imaging modalities. ACEP recommends CTA as one of the gold standards of diagnostic imaging modalities along with echocardiogram and magnetic resonance imaging (MRI), but the latter two modalities are used sparingly due to the lack of trained physicians and limited availability of these resources.⁶

The International Registry of Acute Aortic Dissection reported that echocardiography is used 33%, CT 61%, MRI in 2%, and angiography 4% of the time. As a secondary technique, echocardiogram was used 56%, CT 18%, MRI 9%, and angiography 17% of the time. CXR is abnormal in 60-90% of suspected ADs, but acute dissections can often have normal reads. ECG is also used but can be normal or very abnormal when an ascending dissection leads to coronary compromise.² Although ultrasound is not as widely used as CTA in the diagnosis of AD, it has been shown to be an effective tool in the rapid assessment of patients meeting certain criteria. In one such study, an AD POCUS protocol was developed that combined transthoracic and abdominal ultrasound. Pericardial effusion, intimal flap, and aortic outflow tract diameter data were gathered and successfully identified AD in 96.4% of patients with 100% sensitivity for Stanford type A dissections.⁸

As in this case, when a dissection extends into the coronary arteries it more commonly affects the right coronary artery and involves the inferior wall.² Given the mortality rate, the use of POCUS as an immediate means to diagnose AD can be life-saving.¹ Treatment for Stanford type A dissections is surgical, while type B patients are treated medically.² Type A dissection in our patient was immediately visualized with ultrasound, which prevented the use of anticoagulation and antiplatelet therapy and altered treatment plans to surgical intervention. Although the patient succumbed to hemorrhagic tamponade, receiving dual antiplatelet therapy, anticoagulation, and undergoing an emergent left heart catheterization solely based off his ECG would have exacerbated his dire situation. Despite our patient's outcome, the case we present adds to the evidence that POCUS is an integral component for management and treatment when evaluating a patient with chest pain in the ED.

CONCLUSION

POCUS may be useful in the initial evaluation of patients with suspected aortic dissection. When a dissection extends into

the coronary arteries leading to MI, overt presenting symptoms of MI may lead a practitioner to overlook dissection and instead treat for uncomplicated MI. This case presentation demonstrates how the use of POCUS allowed for the rapid diagnosis of aortic dissection. This diagnosis completely altered the treatment plan of the patient and prevented further interventions such as fibrinolytic therapy that would have worsened his condition.

Documented patient informed consent and/or Institutional Review Board approval has been obtained and filed for publication of this case report.

Address for Correspondence: Eric Abrams, MD, University of California, Irvine, Department of Emergency Medicine, 333 The City Boulevard West Suite 640, Orange, CA 92868. Email: erabrams@uci.edu.

Conflicts of Interest: By the CPC-EM article submission agreement, all authors are required to disclose all affiliations, funding sources and financial or management relationships that could be perceived as potential sources of bias. The authors disclosed none.

Copyright: © 2019 Abrams et al. This is an open access article distributed in accordance with the terms of the Creative Commons Attribution (CC BY 4.0) License. See: <http://creativecommons.org/licenses/by/4.0/>

REFERENCES

1. Hagan P, Nienaber C, Isselbacher E, et al. The International Registry of Acute Aortic Dissection (IRAD): new insights into an old disease. *JAMA*. 2000;283(7):897-903.
2. Gawinecka J, Schonrath F, von Eckardstein A. Acute aortic dissection: pathogenesis, risk factors and diagnosis. *Swiss Med Wkly*. 2017;147:w14489.
3. Ohel R, Um J, Anjum O, et al. High risk clinical features for acute aortic dissection: a case-control study. *Acad Emerg Med*. 2018;25(4):378-87.
4. Melchoir T, Hallman D, Johansen B. Aortic dissection in the thrombolytic era: early recognition and optimal management is a prerequisite for increased survival. *Int J Cardiol*. 1993;42(1):1-6.
5. Cannesson M, Burckard E, Lefevre M, et al. Predictors of in-hospital mortality in the surgical management of acute type A aortic dissections: Impact of anticoagulant therapies. *Ann Fr Anesth Reanim*. 2004;23(6):568-74.
6. Diercks D, Promes S, Schuur J, et al. Clinical policy: critical issues in the evaluation and management of adult patient with suspected acute nontraumatic aortic dissection. *Ann Emerg Med*. 2017;70(5):758.
7. Sullivan P, Wolfson A, Leckey R, et al. Diagnosis of acute thoracic aortic dissection in the emergency department. *Am J Emerg Med*. 2000;18(1):48-50.
8. Gibbons R, Smith D, Mulfur M, et al. Bedside point-of-care ultrasound for the detection of aortic dissections in the emergency department. *Ann Emerg Med*. 2017;70(4):S143.

Delayed Diagnosis of Spinal Tuberculosis in a 44-year-old Male with Acute on Chronic Low Back Pain

Curt Canine, DO
Sarah Medeck, DO
Anthony Hackett, DO

Carl R. Darnall Army Medical Center, Department of Emergency Medicine, Fort Hood, Texas

Section Editor: Joel Moll, MD

Submission history: Submitted April 6, 2018; Revision received November 17, 2018; Accepted November 26, 2018

Electronically published April 2, 2019

Full text available through open access at http://escholarship.org/uc/uciem_cpchem

DOI: 10.5811/cpcem.2018.11.38575

Spinal tuberculosis (STB), also known as tuberculous spondylitis, tuberculous vertebral osteomyelitis, or Pott's disease is a rare subset of extrapulmonary tuberculosis. Although rare in developed countries, STB is an important diagnosis for the emergency physician to consider. We report a case of a 44-year-old African-American male with STB presenting as an acute exacerbation of chronic low back pain complicated by urinary retention and difficulty ambulating. Our patient had no known predisposing risk factors for tuberculosis. This patient's STB was mistakenly diagnosed as nontuberculous vertebral osteomyelitis. This is not uncommon, as it is often difficult to distinguish the two clinically. This patient experienced advanced neurologic features at the time of initial presentation, which improved with surgical decompression. Ultimately, he re-presented to the emergency department 10 days after hospital discharge with recurrence of symptoms due to inaccurate antimicrobial selection. The diagnosis may hinge on the astute physician recognizing the characteristic, albeit subtle, imaging findings of STB. [Clin Pract Cases Emerg Med. 2019;3(2):107-111.]

INTRODUCTION

Spinal tuberculosis (STB), also known as tuberculous spondylitis, tuberculous vertebral osteomyelitis, or Pott's disease, is a rare subset of extrapulmonary tuberculosis (TB), which is itself a rare disease in immunocompetent patients. In the 10-year period from 2002 and 2011 there was an average of one case of STB per two million persons in the United States (U.S.).¹⁴ Despite ongoing efforts by the World Health Organization and the United Nations to eradicate TB, 10.4 million new cases were diagnosed worldwide in 2015. The U.S. alone saw 10,000 new TB cases in 2015, a 20% increase from 2014. TB remains among the top 10 causes of death worldwide with a global case fatality rate of 17% in 2015.¹¹

CASE REPORT

A 44-year-old African-American male with a history of chronic low back pain presented to the emergency department (ED) having difficulty walking and trouble urinating. He reported no classic TB risk factors and denied history of international travel or exposure to high-risk populations. He also denied a history of intravenous (IV) drug use. Nor did he report typical preceding symptoms of night sweats, fever, weight loss, cough, or hemoptysis. Initial vital signs included

blood pressure 123/85 millimeters of mercury (mmHg), pulse 127 beats per minute (bpm), respirations 28 per minute, oxygen saturation 99% on room air, and afebrile at 98.1° Fahrenheit (F). Due to concern for possible cauda equina syndrome, emergent magnetic resonance imaging (MRI) of the lumbar spine was done (Image 1). The patient was diagnosed with discitis, osteomyelitis and ventral epidural abscess at lumbar vertebrae 3 and 4 (L3, L4). Labs revealed leukocyte count 8.6×10^9 per liter (L), hemoglobin 12.4 grams per deciliter (g/dL), platelets $319 \times 10^9/L$, C-reactive protein (CRP) 1.15 milligrams (mg)/dL, erythrocyte sedimentation rate 56 millimeters per hour and lactic acid 0.8 millimoles/L. Urine drug screen, hepatitis panel, human immunodeficiency virus screen and rapid plasmin reagin test all returned negative.

He was promptly transferred to a hospital with neurosurgical capabilities and taken to the operating room for L3 laminectomy with partial facetectomy and evacuation of the ventral epidural abscess. Successful decompression of the L3 and L4 nerve roots was achieved, and abscess fluid was sent for culture. The patient was admitted and started on broad-spectrum IV antibiotics. Culture results from the epidural abscess returned *Propionibacterium acnes*, while the pathology report was negative for fungal elements. The

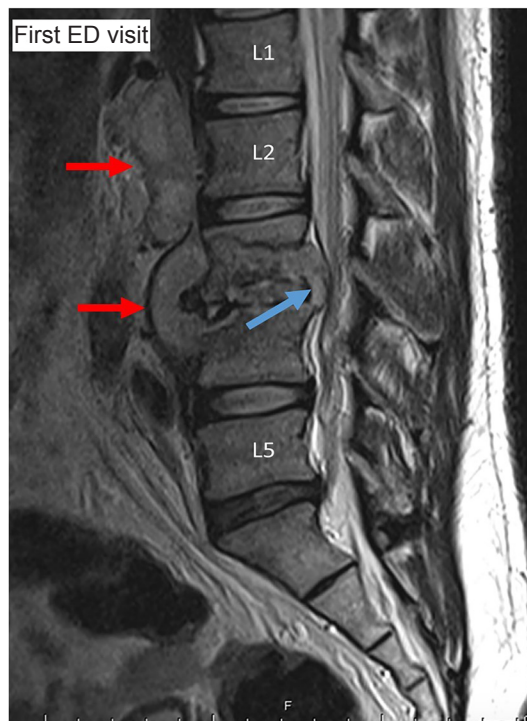


Image 1. Pre-operative sagittal magnetic resonance imaging from index visit demonstrates bony destruction of third and fourth lumbar vertebrae. A large epidural abscess extending from first to fourth lumbar vertebrae (red arrows) projects through third lumbar vertebral body and compresses the spinal nerve roots (blue arrow). Lumbar vertebrae 1 (L1), 2 (L2), and 5 (L5). ED, emergency department.

acid-fast bacilli (AFB) stain was also negative. Antibiotic coverage was narrowed to ceftriaxone only. After eight days in the hospital, the patient improved significantly, ambulating without difficulty, tolerating physical and occupational therapy. A peripherally inserted central line was placed before discharge to home, and arrangements were made for weekly lab monitoring and home IV ceftriaxone therapy. A prednisone taper was also prescribed for lingering radicular pain.

Ten days after discharge the patient presented once again to the ED for progressively worsening lumbar and thoracic back pain, lower extremity weakness and inability to pass a bowel movement. Initial vital signs were blood pressure 127/90 mmHg, pulse 102 bpm, respirations 21 per minute, oxygen saturation 98% on room air, and afebrile at 97.9° F. A second MRI was emergently ordered (Images 2 and 3), which demonstrated interval progression of infectious changes involving L3 and L4 with associated epidural and retroperitoneal spread of infection. Given the report of upper back pain on this second ED visit the MRI also imaged the thoracic spine, which identified extensive, abnormal epidural enhancement throughout the thoracic spinal canal suggestive of diffuse infection, with focal epidural thoracic spine abscess formation identified at vertebral levels 4-7.

Chart review revealed a positive QuantiFERON®-

CPC-EM Capsule

What do we already know about this clinical entity?
Spinal tuberculosis (STB) is a rare disease with a prevalence of one in two million in the west. With the rise in TB cases worldwide, STB may become more common.

What makes this presentation of disease reportable?
This case underscores the importance of expanding one's differential diagnosis for spinal epidural abscess (SEA) even in the immunocompetent host.

What is the major learning point?
STB can be present in an immunocompetent host. It should be considered especially if a patient returns with similar symptoms after effective treatment of SEA.

How might this improve emergency medicine practice?
Readers should be able to recognize the pearls and pitfalls of making this diagnosis and the possibility that STB may exist in an immunocompetent host.

TB Gold serum test, as well as a culture positive for *Mycobacterium tuberculosis* from the initial lumbar epidural abscess drained during decompressive neurosurgery. Vital signs were unremarkable with blood pressure 119/72 mmHg, pulse 94 bpm, respirations 18 per minute, oxygen saturation 98% on room air, and afebrile at 97.9° F. Physical examination was significant only for 4/5 strength to bilateral lower extremities. Significant lab abnormalities included critically low potassium 2.7 milliequivalents/L, leukocyte count $10.8 \times 10^9/L$, platelets $370 \times 10^9/L$ and CRP 10.36 mg/dL. The patient was admitted to a negative-pressure isolation bed and started on rifampin, isoniazid, pyridoxine, pyrazinamide and ethambutol for TB. The original neurosurgery team evaluated the patient again on the second hospital admission and determined no further operative intervention was necessary. The Department of Health was notified of the positive TB result and the patient was discharged home on hospital day eight on a monitored four-drug antibiotic regimen with a diagnosis of retroperitoneal abscess due to extension of Pott's disease of the spine.

DISCUSSION

The most common presenting symptoms in STB are back pain (70.4%), weight loss (30.3%), neurologic abnormalities

(30.1%), and night sweats (19.1%).³ A characteristic “aldermanic gait” describes patients taking short, deliberate steps to avoid jarring the spine. Among those presenting with neurologic symptoms, limb weakness was most common (33%), followed by complete limb paralysis (15%), and urinary or fecal incontinence (8%).¹ Time from initial symptoms to diagnosis is often quite protracted, with reports ranging from 78 days to over 1.5 years.^{2,3} Half of STB patients present with isolated back pain and no other symptoms at the time of diagnosis, contributing to an initial misdiagnosis rate of 41%.^{4,5} Further confounding the diagnosis, clinical judgment is shown to be insensitive and poorly specific.⁶

A panel of clinicians, laboratory scientists, and TB control experts from the Centers for Disease Control and Prevention and the Association for Public Health Laboratories, convened in 2008 and proposed a diagnostic algorithm for the diagnosis of TB, which pairs nucleic acid amplification testing (NAAT) results (positive or negative) with AFB smear results (positive or negative) to dictate treatment. A positive NAAT and positive AFB smear is presumed TB positive, antibiotics started and cultures followed. Unfortunately, all other combinations of results are indeterminate, and the recommendation is to use clinical judgment, repeat NAAT and AFB smear testing, and wait for culture results. While NAAT results are available within 48 hours and have a positive predictive value of 95%, this algorithm relies on AFB smear, which has been shown to be poorly sensitive, may require repeat sampling, and is dependent on the quality of the sample obtained.

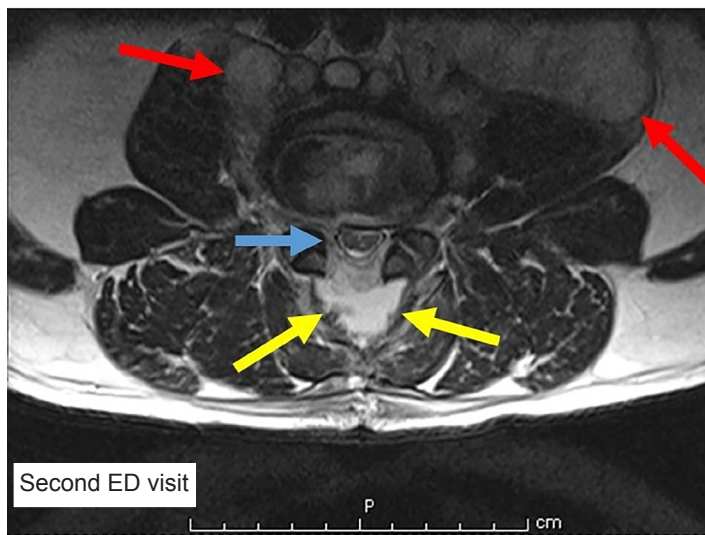


Image 2. Axial magnetic resonance image at the level of the third lumbar vertebrae taken on the second visit demonstrates progression of ventral epidural abscess now extending to completely surround the lumbar nerve roots (blue arrow), and extending into posterior vertebral space (yellow arrows). Again the left psoas muscle demonstrates inflammatory changes concerning for abscess with interval progression of right psoas muscle inflammation (red arrows). ED, emergency department.

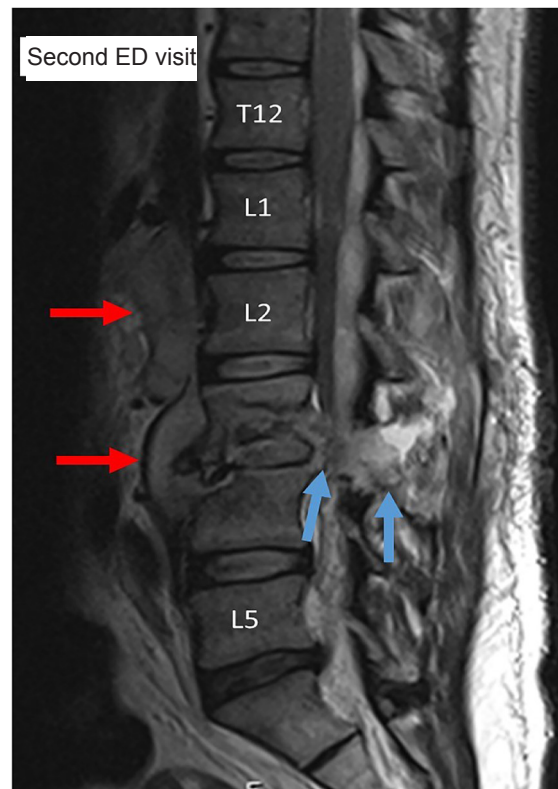


Image 3. Midline sagittal magnetic resonance image taken on second visit re-demonstrates epidural abscess (red arrows) that has spread to extensively involve posterior vertebral soft tissue elements (blue arrows). Lumbar vertebrae 1 (L1), 2 (L2), and 5 (L5). Thoracic vertebrae 12 (T12). ED, emergency department.

Further challenging its utility in the diagnosis of TB, NAAT performs poorly as a screening test in patients who have low clinical probability of TB.⁷ QuantiFERON-TB Gold serum test is an interferon-gamma release assay (IGRA) that measures T-cell release of interferon-gamma following stimulation by antigens unique to *M. tuberculosis* and a few other mycobacteria. IGRAs cannot distinguish between latent infection and active TB disease and should not be used for diagnosis of active TB, as a negative IGRA does not rule out active TB.⁸ Several newer, rapid, biomarker assays are currently under development, promising sensitivities nearing 100% with short turn-around times compared to traditional culture-based methods, but these assays require further evaluation before they are ready for clinical use.³

STB typically develops from hematogenous spread from lung to lumbar or lower thoracic vertebrae, via the venous plexus and then spreading to adjacent vertebrae under the anterior longitudinal ligament and destroying anterior vertebral elements while preserving intervertebral discs and posterior elements. When many vertebrae are affected, a characteristic, sharply-angulated thoracolumbar kyphosis develops. This finding is known as a gibbus deformity (not seen in this case). These features distinguish STB from nontuberculous vertebral

osteomyelitis, which affects the intervertebral discs early and vertebral elements more equally. In the case of STB, as opposed to nontuberculous osteomyelitis, paraspinal abscess is quite common at time of presentation.^{9,3} At the time of STB diagnosis the majority of patients were found to have MRI evidence of inflammatory paraspinal tissue changes (89.7%) or thecal compression (93.1%).¹⁰

Significant bone mineral loss (30%) is required before radiolucent lesions appear on plain films, a finding often delayed up to eight weeks.³⁻⁴ Chest radiograph (CXR) should be obtained when a diagnosis of STB is entertained, but it provides little help in diagnosing STB as approximately half will show no lesion. CXR revealed evidence of active or healed pulmonary disease in 30% of STB patients at time of diagnosis. Plain films of the spine may show endplate disruption and bone destruction but little else.⁴

Computed tomography is excellent at demonstrating bony lytic lesions, sclerosis, bone circumference disruption, disc space collapse, and paraspinal abscess with rim enhancement.⁴ However, MRI is the imaging modality of choice as it superiorly demonstrates soft tissue involvement, epidural extension, and involvement of neural structures, often before onset of clinical symptoms.^{3,2,11}

Untreated TB mortality is 70% at 10 years, and early diagnosis is paramount. STB should be treated for two months with quadruple therapy, usually rifampin, isoniazid, pyrazinamide and ethambutol, then rifampin and isoniazid continued for a total of six months. Children should be treated for one year.¹² For persistent symptoms, and lab or imaging signs of continued infection, options include extending medical therapy through nine months or operative management.¹¹ Surgical intervention is indicated in patients with compression of the spinal cord or nerve roots, spinal deformity leading to instability, extensive abscess formation, or medical treatment failure. One large study showed 37% of STB patients required operative management, and 10% of those required multiple surgeries.^{11,2}

CONCLUSION

This patient's STB was mistakenly diagnosed as nontuberculous vertebral osteomyelitis. This is not uncommon as it is often difficult to distinguish the two clinically. Both present with lumbar pain, have similar imaging findings and no proven diagnostic laboratory criteria with rapid results. It is not surprising then that STB diagnosis is often delayed months to years, increasing the chance of developing kyphotic deformities, neurologic deficits, and increased need for surgical management at the time of diagnosis.^{4,5,13} This patient experienced advanced neurologic features at the time of initial presentation, which improved with surgical decompression but ultimately returned due to inaccurate antimicrobial selection.

The diagnosis may hinge on the astute physician recognizing the characteristic, albeit subtle, imaging findings of STB. These include: 1) anterior vertebral body element destruction with

preservation of intervertebral discs and posterior vertebral elements of contiguous lumbar or lower thoracic vertebrae; 2) concomitant psoas-muscle abscess formation (often quite extensive); and later 3) gibbus and kyphotic deformities. Additionally, clues based on the clinical history as well as the presence of refractory spinal epidural symptoms despite culture-guided therapy should lend clues to the diagnosis.

Documented patient informed consent and/or Institutional Review Board approval has been obtained and filed for publication of this case report.

Address for Correspondence: Sarah Medeck, DO, Carl R. Darnall Army Medical Center, Department of Emergency Medicine, 36065 Santa Fe Drive, Fort Hood, TX 76544. Email: medecksarah@gmail.com.

Conflicts of Interest: By the CPC-EM article submission agreement, all authors are required to disclose all affiliations, funding sources and financial or management relationships that could be perceived as potential sources of bias. The authors disclosed none. This research did not receive any specific grant from funding agencies in the public, commercial, or not-for-profit sectors. The views expressed herein are solely those of the authors and do not represent the official views of the Department of Defense or Army Medical Department.

Copyright: © 2019 Canine et al. This is an open access article distributed in accordance with the terms of the Creative Commons Attribution (CC BY 4.0) License. See: <http://creativecommons.org/licenses/by/4.0/>

REFERENCES

1. Chen YH, Lin C-B, Hamod T, et al. Treatment modalities for tuberculosis of the spine: 22 years' experience in East Taiwan. *Formosan J Surg.* 2013;46(6):189-94.
2. Batirel A, Erdem H, Sengoz G, et al. The course of spinal tuberculosis (Pott disease): results of the multinational, multicentre Backbone-2 study. *Clin Microbiol Infect.* 2015;21(11):1008.e9-1008.e18.
3. Chen CH, Chen YM, Lee CW, et al. Early diagnosis of spinal tuberculosis. *J Formos Med Assoc.* 2016;115(10):825-36.
4. Nussbaum ES, Rockswold GL, Bergman TA, et al. Spinal tuberculosis: a diagnostic and management challenge. *J Neurosurg.* 1995;83(2):243-7.
5. Colmenero JD, Ruiz-Mesa JD, Sanjuan-Jimenez R, et al. Establishing the diagnosis of tuberculous vertebral osteomyelitis. *Eur Spine J.* 2013;22 Suppl 4:579-86.
6. Dinnes J, Deeks J, Kunst H, et al. A systematic review of rapid

- diagnostic tests for the detection of tuberculosis infection. *Health Technol Assess.* 2007;11(3):1-196.
7. Centers for Disease Control and Prevention. Updated guidelines for the use of nucleic acid amplification tests in the diagnosis of tuberculosis. *MMWR Morb Mortal Wkly Rep.* 2009;58(1):7-10.
 8. Sester M, Sotgiu G, Lange C, et al. Interferon- γ release assays for the diagnosis of active tuberculosis: a systematic review and meta-analysis. *Eur Respir J.* 2011;37(1):100-11.
 9. Weaver P and Lifeso RM. The radiological diagnosis of tuberculosis of the adult spine. *Skeletal Radiol.* 1984;12(3):178-86.
 10. Alvi AA, Raees A, Khan Rehmani MA, et al. Magnetic resonance image findings of spinal tuberculosis at first presentation. *Int Arch Med.* 2014;7(1):12.
 11. Varatharajah S, Charles YP, Buy X, et al. Update on the surgical management of Pott's disease. *Orthop Traumatol Surg Res.* 2014;100(2):229-35.
 12. World Health Organization. (2016, n.d.). *Global Tuberculosis Report 2016.* Available at: <http://apps.who.int/medicinedocs/documents/s23098en/s23098en.pdf>. Accessed on December 20, 2017.
 13. Kamara E, Mehta S, Brust JC, et al. Effect of delayed diagnosis on severity of Pott's disease. *Int Orthop.* 2012;36(2):245-54.
 14. De la Garza Ramos R, Goodwin C, Abu-Bonsrah, et al. The epidemiology of spinal tuberculosis in the United States: an analysis of 2002–2011 data. *J Neurosurg Spine.* 2017;26(4):507-12.

A Desquamating Skin Rash in a Pediatric Patient

John Haggerty, DO
Felipe Grimaldo, MD

Naval Medical Center San Diego, Department of Emergency Medicine, San Diego, California

Section Editor: Rick A. McPheeters, DO

Submission history: Submitted October 7, 2018; Revision received January 6, 2019; Accepted January 1, 2019

Electronically published February 26, 2019

Full text available through open access at http://escholarship.org/uc/uciem_cpccem

DOI: 10.5811/cpcem.2019.1.41162

Prompt identification and treatment of true dermatologic emergencies is essential in emergency medicine, especially in vulnerable populations such as pediatric patients. This is a case of a three-year-old female who presented with significant dehydration in the setting of a desquamating skin rash diagnosed in our emergency department as staphylococcal scalded skin syndrome. [Clin Pract Cases Emerg Med. 2019;3(2):112-114.]

INTRODUCTION

Dermatologic emergencies are rare. A five-year, multicenter review found that 3.3% of all emergency department (ED) visits were for general skin complaints, with only 4% of these requiring inpatient admission.¹ Some rashes are true emergencies, however, and thus require prompt diagnosis and treatment. Such rashes include necrotizing fasciitis, toxic epidermal necrolysis syndrome (TENS), and staphylococcal scalded skin syndrome (SSSS). SSSS will be discussed here.

CASE REPORT

A previously healthy and fully vaccinated three-year-old female was brought by her parents to the ED with a rash that had been worsening over a five-day period. The mother of the patient reported a fall from playground equipment with resulting abrasion just prior to the onset of the rash. In appearance, the rash was macular, mildly erythematous, and located over the child's trunk and face. Desquamation of skin surrounding the abrasion occurred after subsequent removal of an adhesive bandage applied to the area. The child had two healthcare visits before presenting to our ED. A few days after the fall, the patient's primary care physician diagnosed her with an allergic reaction and treated her with diphenhydramine. Further worsening of the rash prompted the parents of the patient to seek care at an outside ED, where she was again diagnosed with an allergic reaction, given diphenhydramine, and also treated with intravenous (IV) fluids. Of note, after this last visit to the ED, further desquamation occurred with removal of adhesives used to secure a peripheral IV on her arm.

In our department the parents denied fevers but reported decreased per os (PO) intake, with only one episode of

urination in the prior 24 hours, along with worsening fatigue. The child also reported some dysuria and odynophagia. She denied respiratory symptoms, vomiting or diarrhea. On physical examination, the child was mildly tachycardic with no other vital sign abnormalities. She appeared fatigued but was interactive during the examination. She had areas of slightly edematous erythema around her periorbital areas, cheeks, neck, upper back, and inguinal area with areas of surrounding desquamation (Images 1 and 2). The original abrasion was

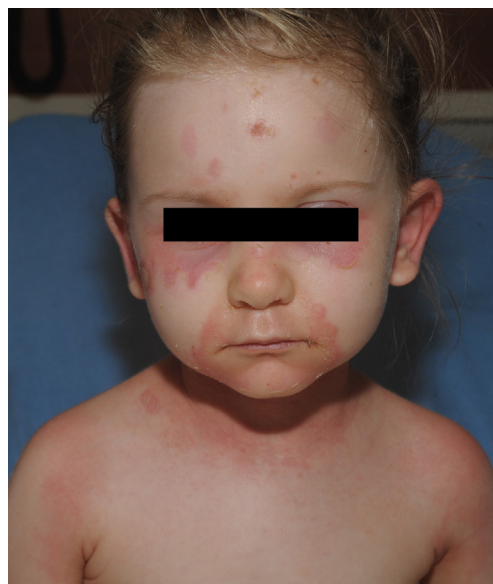

Image 1. Periorbital and perioral distribution of the edematous, erythematous, macular rash.

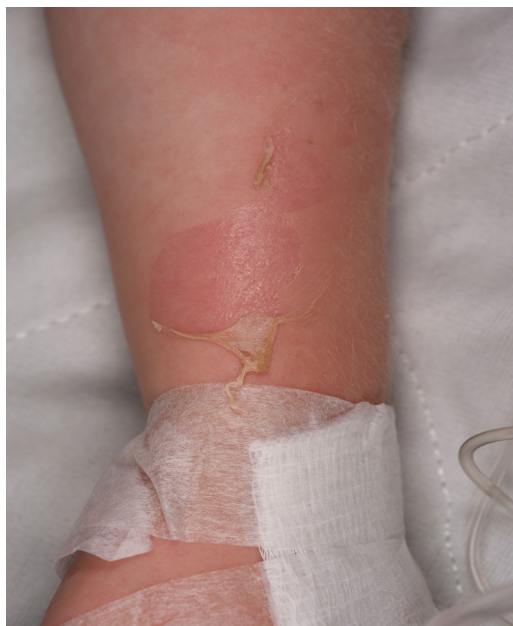

Image 2. Detail of the left forearm showing desquamation from removal of adhesive tape.

surrounded by more pronounced edema and erythema consistent with a small, localized cellulitis. There was no evidence of mucosal involvement on examination of the pharynx and vaginal introitus. The child received fluid resuscitation with a 20 milligram- per-kilogram bolus of IV normal saline, blood cultures were taken, and IV clindamycin initiated. Although there was no mucosal involvement on our examination, there was higher concern for Stevens-Johnson or TENS, since the child reported dysuria and odynophagia. The dermatology service was consulted and recommended admission to the pediatric intensive care unit (PICU) and the addition of ceftaroline to her IV clindamycin. The child was admitted to the PICU, where she received continued IV antibiotics, fluid resuscitation and wound care for the desquamating lesions. By hospital day three, she had no further wound desquamation and had improved urine output. She was discharged after a five-day hospital stay with a seven-day course of PO cephalexin.

DISCUSSION

SSSS occurs when exfoliative toxins produced by some species of *Staphylococcus aureus* bind and destroy proteins at the granulosum layer of the epidermis, resulting in the characteristic bullae of SSSS and a positive Nikolsky's sign. In SSSS, this separation of layers occurs within the epidermis as opposed to TENS, where the separation occurs at the dermal-epidermal layer. The more superficial split in the epidermis is one of the key factors in SSSS being a less serious condition than TENS. In bullous impetigo the toxins act locally, whereas in SSSS the toxins spread hematogenously, resulting in desquamation at sites distant to the infectious site. The toxins are excreted via the

CPC-EM Capsule

What do we already know about this clinical entity?

Staph scalded skin syndrome (SSSS) is a well- understood, but relatively rare disease which that is often overshadowed by other emergent rashes in clinical teaching.

What makes this presentation of disease reportable?

SSSS is a potentially life-threatening rash in vulnerable populations. We describe the classic appearance and distribution of this skin disease.

What is the major learning point?

SSSS is endemic to pediatric patients and patients with renal compromise. Prompt diagnosis and treatment can prevent significant morbidity and mortality.

How might this improve emergency medicine practice?

Given that hindsight is 20/20, it wasn't until our patient's third clinical interaction that SSSS was properly identified. It is essential that emergency physicians be astute diagnosticians.

kidneys, with almost complete clearance in normal renal function, resulting in few cases of SSSS in healthy adults. Children, especially neonates, with developing kidney function, and adults with kidney disease are thus unable to clear the toxins, resulting in higher incidence in these populations.²

The gold standard for diagnosis in SSSS is histology, but clinically the disease may be identified by history and physical. An important diagnostic step is differentiating between SSSS and the more dangerous TENS, which are similar in appearance but differ significantly in mortality. A key clinical differentiation lies in examination of the mucosal membranes. Significant mucosal involvement of the desquamating lesions is a hallmark of TENS, with sparing of the mucosa in SSSS. Of note, SSSS may induce dehydration and therefore dry, cracked lips, but will not induce mucosal desquamation itself. Another key clinical difference between SSSS and TENS is that the more superficial split in the epidermis seen in SSSS leads to a much thinner, more superficial desquamation of the skin, which is much less likely to lead to the fluid loss and risk of secondary infection

that is seen in TENS. However, this difference in the thickness of desquamation may be difficult to differentiate clinically for those not familiar with both conditions. Skin biopsy with frozen section analysis can provide definitive differentiation within minutes to hours for those cases where there is any doubt.

Treatment consists of either PO or parenteral IV antibiotics and supportive care. A patient with a small affected area, minimal desquamation, and good PO intake may be treated on an outpatient basis with a seven-day course of dicloxacillin or a cephalosporin.³ Patients with larger affected areas of desquamation will need fluid resuscitation and IV antibiotics with likely coverage for methicillin resistant *S. aureus* in the ED. Typical agents might include parenteral vancomycin or ceftaroline IV, but may depend on local resistance patterns. Antibiotic coverage may later be narrowed during hospitalization depending on culture results or clinical course. Clindamycin may be considered as an adjunctive agent due to its unique function as an inhibitor of bacterial toxin production in addition to bacteriostatic action but patterns of resistance have been observed when used alone.⁴ Lastly, burn care of desquamated areas is crucial to prevent secondary infections and for patient comfort.

CONCLUSION

In summary, this case demonstrates a relatively rare desquamating pediatric rash – staphylococcal scalded skin syndrome. Rapid identification and treatment of this disease is essential to avoid secondary infections, sepsis and renal failure.

Documented patient informed consent and/or Institutional Review Board approval has been obtained and filed for publication of this case report.

Address for Correspondence: John Haggerty, DO, Naval Medical Center San Diego, Department of Emergency Medicine, 34800 Bob Wilson DR, San Diego, CA 92134. Email: john.t.haggerty7.mil@mail.mil.

Conflicts of Interest: By the CPC-EM article submission agreement, all authors are required to disclose all affiliations, funding sources and financial or management relationships that could be perceived as potential sources of bias. No author has professional or financial relationships with any companies that are relevant to this study. The views expressed in this article are those of the authors and do not necessarily reflect the official policy or position of the Department of the Navy, Department of Defense, or the U.S. Government.

Copyright: © 2019 Haggerty et al. This is an open access article distributed in accordance with the terms of the Creative Commons Attribution (CC BY 4.0) License. See: <http://creativecommons.org/licenses/by/4.0/>

REFERENCES

1. Baibergenova A and Shear NH. Skin conditions that bring patients to emergency departments. *Arch Dermatol.* 2011;147(1):118-20.
2. Patel GK and Finlay AY. Staphylococcal scalded skin syndrome: diagnosis and management. *Am J Clin Dermatol.* 2003;4(3):165-75.
3. Habif TP. (2015). "Bacterial Infections." In: Habif TP (Ed.), *Clinical Dermatology, A Color Guide to Diagnosis and Therapy.* (6th ed.). Philadelphia, PA: Saunders.
4. Braunstein I, Wanat KA, Abuabara K, et al. Antibiotic sensitivity and resistance patterns in pediatric staphylococcal scalded skin syndrome. *Pediatr Dermatol.* 2014;31(3):305-8.

Perilymphatic Fistula After Penetrating Ear Trauma

Ashley E. Kita, MD*
Irene Kim, MD*
Gail Ishiyama, MD*†
Akira Ishiyama, MD*

*David Geffen School of Medicine at the University of California Los Angeles, Department of Head and Neck Surgery, Los Angeles, California
†David Geffen School of Medicine at the University of California Los Angeles, Department of Neurology, Los Angeles, California

Section Editor: Shadi Lahham, MD, MS

Submission history: Submitted December 27, 2018; Revision received December 1, 2018; Accepted January 1, 2019

Electronically published March 4, 2019

Full text available through open access at http://escholarship.org/uc/uciem_cpccem

DOI: 10.5811/cpcem.2019.1.37404

Pneumolabyrinth, defined as air within the labyrinth on high-resolution computed tomography, suggests that a perilymphatic fistula (PLF) is present. PLF describes an abnormal communication between the middle and inner ear, and can result in deafness, vertigo, and imbalance. In the setting of a penetrating injury to the temporal bone or inner ear, pneumolabyrinth should trigger prompt otolaryngology consultation and urgent surgical exploration. We describe a case in which a 49-year-old male presented with a traumatic PLF secondary to penetrating ear injury. Imaging demonstrated extensive pneumolabyrinth. Despite delay in diagnosis, expeditious surgical intervention resulted in successful preservation of inner ear function. [Clin Pract Cases Emerg Med.2019;3(2):115-118.]

INTRODUCTION

Perilymphatic fistula (PLF) refers to an abnormal communication of perilymph between the middle and inner ear through a defect in the otic capsule, and is associated with acute hearing loss, tinnitus, and vertigo. Some of the more common causes of PLF include penetrating injury (such as that of ear picks in Japan), barotrauma, middle ear surgery, and temporal bone fracture.^{1,2} Many reported cases of traumatic PLF deal with concurrent management of temporal bone fractures, in which case conservative strategies have been employed.³ As patients typically present first to the emergency department (ED), it is critical for emergency care providers to correctly identify the subgroup of patients who may require urgent surgical intervention to preserve hearing and balance. In the case of penetrating inner ear injury, high-resolution computed tomography (CT) should be carefully evaluated for air, since the presence of pneumolabyrinth confirms the diagnosis of PLF and requires urgent surgical intervention. We present the case of a man with a foreign body penetrating the inner ear who presented to the ED with spontaneous nystagmus and profound hearing loss who successfully maintained his inner ear function after immediate surgical exploration.

CASE REPORT

After falling off a mountain bike down an incline into some brush, a 49-year-old male mountain biker presented

to an outside ED with normal vitals, severe vertigo, nausea, intractable vomiting, profound hearing loss, and tinnitus. A CT was performed, which showed opacification of the ear canal, but did not comment on any abnormalities of the inner ear. The patient was transferred to our facility for further management. On examination, there was a spontaneous right-beating nystagmus and the facial nerve was intact. A tree twig was embedded in the left external auditory canal, obscuring visualization of the tympanic membrane.

Temporal bone CT demonstrated a linear foreign body projecting from the external auditory canal to the oval window, and an additional, separate small foreign body projecting into the vestibule. Presence of extensive intralabyrinthine air was detected radiographically (Image 1). On axial view, air bubbles were seen in the vestibule, posterior semicircular canal, and the scala vestibuli compartment of the cochlear basal turn, as well as in the lateral and superior semicircular canals (Image 2). Preoperative audiogram conducted at bedside revealed normal hearing on the right side and moderate-to-severe mixed hearing loss on the left.

The patient was diagnosed with a traumatic PLF with extensive pneumolabyrinth due to penetrating temporal bone injury and was taken urgently to the operating room less than one day after his inciting injury. A three-centimeter tree twig was lodged in the ear canal and found to be penetrating the tympanic membrane. Postauricular approach included

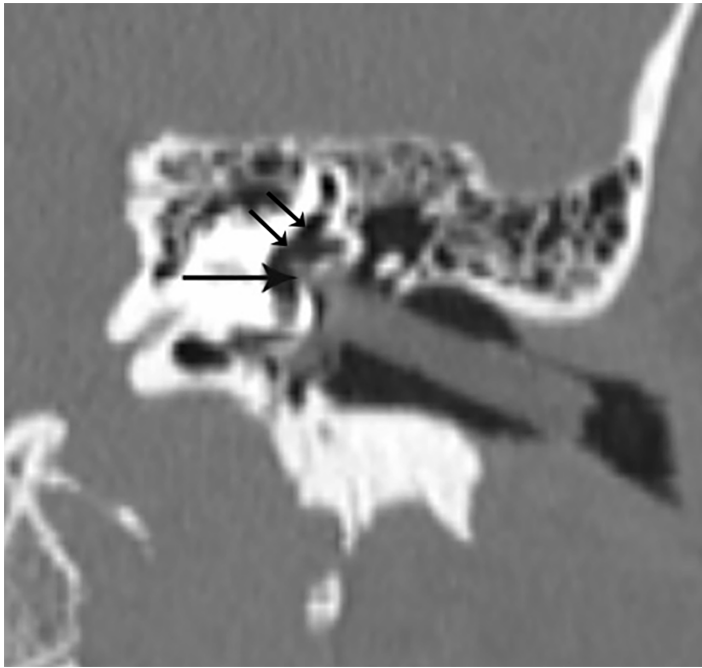


Image 1. Temporal bone computed tomography reconstructed in an oblique coronal view shows a linear foreign body projecting from the external auditory canal to the oval window, with a small projection into the vestibule (arrow). Extensive intralabyrinthine air is present (double arrows).

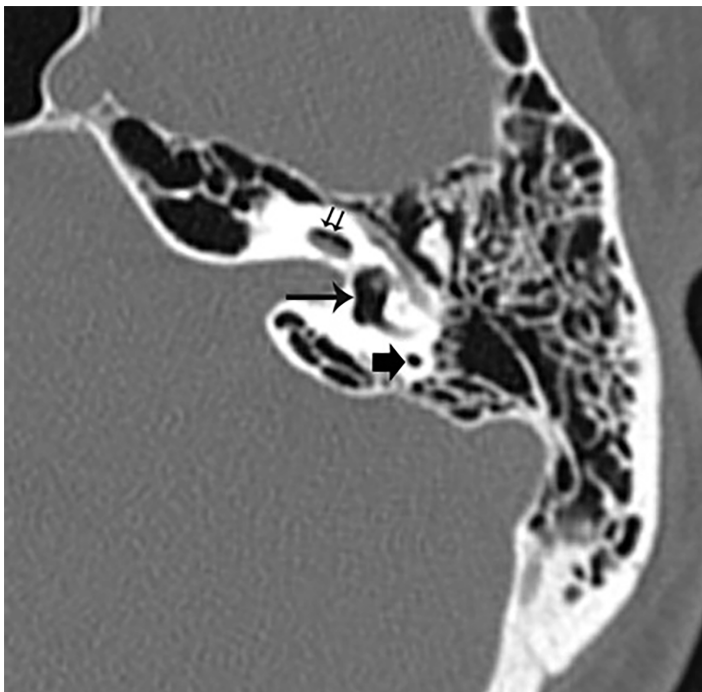


Image 2. An axial cut of temporal bone computed tomography shows air in the left vestibule (long arrow), the posterior semicircular canal (short arrow), and the scala vestibuli compartment of the cochlear basal turn (short double arrows). Air was also seen in the lateral and superior semicircular canals (not shown).

CPC-EM Capsule

What do we already know about this clinical entity?

Trauma to the inner ear may result in hearing loss and vertigo.

What makes this presentation of disease reportable?

Traumatic air within the inner ear is rare, but when related to penetrating trauma it suggests a perilymphatic fistula (PLF) requiring acute operative intervention.

What is the major learning point?

A computed tomography should be obtained in individuals presenting with penetrating ear trauma accompanied by vertigo and hearing changes to assess for PLF.

How might this improve emergency medicine practice?

Clinicians should have a heightened suspicion for PLF if air is seen within the cochlea or labyrinth in a patient with hearing and balance changes.

mastoidectomy and intraoperative assessment of the middle ear ossicles and extent of injury. The long process of the incus was dislocated but still attached to the malleus, the stapes was deeply embedded into the vestibule, and the oval window was completely open but covered by blood clot. All penetrating foreign bodies were extracted. Temporalis fascia was used to seal the oval window and a stapes prosthesis was placed. The tympanic membrane perforation was repaired.

Postoperatively, the patient had rapid and significant improvement of his vertigo. On physical examination, there was minimal spontaneous nystagmus. A four-week postoperative audiogram revealed a mild-to-moderate mixed hearing loss in the left ear with continued improvement at six months.

DISCUSSION

PLF describes an abnormal communication of fluid between the inner ear and the air-filled middle ear cavity.¹ Traumatic PLF due to temporal bone fracture and traumatic PLF due to penetrating trauma of the inner ear must be distinguished, as the first can be observed with bedrest and the second requires immediate surgery. Pneumolabyrinth, or

air displacing the fluid spaces of the otic capsule within the labyrinthine compartment, can confirm the presence of PLF.^{4,5} Physical exam findings consistent with this diagnosis include nystagmus with insufflation (positive fistula test) and dizziness induced by sound (Tullio's phenomenon). Because this hearing loss may be conductive, sensorineural, or mixed, a tuning fork examination may be of mixed utility. As demonstrated in this case, the diagnosis of pneumolabyrinth can be easily missed.

Pneumolabyrinth may be easy to detect when it is large, but small pneumolabyrinth can be challenging to visualize on a head CT or even on temporal bone CT. In such cases, it is important to obtain coronal views of the temporal bone as air rises to the most superior aspect of the superior semicircular canals. Although the effect of air within the inner ear labyrinth is not known, animal models suggest that air bubbles disturb the propagation of the traveling wave of the basilar membrane and produce profound sensorineural hearing loss.⁶ In addition, pneumolabyrinth may cause direct irritation of the membranous labyrinth resulting in severe rotational vertigo.⁴ Of note, pneumolabyrinth in the cochlea, or pneumocochlea, is related to more severe and potentially irreversible sensorineural hearing loss than those with air confined to the vestibule.^{3,7}

When pneumolabyrinth is present due to temporal bone fracture, conservative management with bed rest is usually recommended. Prisman et al. described three cases of pneumolabyrinth caused by temporal bone fracture in pediatric patients and reported resolution of vestibular symptoms with conservative management.³ The mechanism of vestibular-symptom resolution in these cases is likely due to central compensation rather than the restoration of peripheral vestibular function. In the setting of temporal bone fracture, these authors recommended surgical intervention only if the patient has cerebrospinal fluid otorrhea, progressive hearing loss, or unresolving vestibular problems.

On the contrary, pneumolabyrinth caused by penetrating temporal bone injury needs to be recognized and accurately diagnosed in the ED as best outcomes are obtained with urgent otologic consultation and immediate surgery.^{8,9} In this case, the presence of pneumolabyrinth was missed at an outside facility, causing a delay in diagnosis and surgical intervention. Despite this delay, the hearing and partial vestibular function were preserved. At the time of surgery, a blood clot found sealing the oval window may have prevented profound sensorineural hearing loss and permanent peripheral vestibulopathy. Given that the oval window was completely open due to subluxation of the stapes, this would have resulted in irreversible profound sensorineural hearing loss without surgery. As demonstrated in this case, the vestibular function was also partially preserved as the vestibule-ocular reflex is nearly symmetric. The diminished caloric response on the left is likely significantly overestimated secondary to tympanoplasty.

In the ED setting high-resolution CT of the temporal bone including coronal views should be obtained immediately to

evaluate for pneumolabyrinth when a patient with temporal bone injury is initially assessed. Early recognition of pneumolabyrinth in this setting is crucial since urgent referral to a facility where appropriate otologic procedures can be performed could save the inner ear function.

CONCLUSION

The long-term hearing outcomes of patients with PLF with pneumolabyrinth are generally poor, and early diagnosis and treatment are essential. Urgent physical examination, audiometry, imaging, and referral to appropriate specialists can help facilitate appropriate management. In the case of penetrating foreign body with pneumolabyrinth, urgent evaluation is critical and emergency physicians should have a high index of suspicion when patients present with findings similar to those described in this case. Our patient showed near-complete resolution of vertigo and long-term improvement in his hearing loss. These improvements in symptoms are likely attributable to the relatively brief interval to surgery and prompt repair of the PLF.

Documented patient informed consent and/or Institutional Review Board approval has been obtained and filed for publication of this case report.

Address for Correspondence: Ashley Kita, MD, University of California, Los Angeles, Department of Head and Neck Surgery, 10833 Le Conte Ave, CHS 62-132, Los Angeles, CA 90095. Email: akita@mednet.ucla.edu.

Conflicts of Interest: By the CPC-EM article submission agreement, all authors are required to disclose all affiliations, funding sources and financial or management relationships that could be perceived as potential sources of bias. The authors disclosed none.

Copyright: © 2019 Kita et al. This is an open access article distributed in accordance with the terms of the Creative Commons Attribution (CC BY 4.0) License. See: <http://creativecommons.org/licenses/by/4.0/>

REFERENCES

1. Alzahrani M, Fadous R, Dufour JJ, et al. Perilymphatic fistulas: can we predict the diagnosis? *Eur Arch Otorhinolaryngol*. 2015;272(8):1885-91.
2. Nakashima T, Matsuda K, Okuda T, et al. Late pneumolabyrinth may be induced by old penetrating injury: possibility of undiagnosed posttraumatic perilymphatic fistula. *Case Rep Otolaryngol*. 2015. DOI:

- 10.1155/2015/506484.
3. Prisman E, Ramsden JD, Blaser S, et al. Traumatic perilymphatic fistula with pneumolabyrinth: diagnosis and management. *Laryngoscope*. 2011;121(4):856-9.
 4. Ederies A, Yuen HW, Chen JM, et al. Traumatic stapes fracture with rotation and subluxation into the vestibule and pneumolabyrinth. *Laryngoscope*. 2009;119(6):1195-7.
 5. Tsubota M, Shojaku H, Watanabe Y. Prognosis of inner ear function in pneumolabyrinth: case report and literature review. *Am J Otolaryngol*. 2009;30(6):423-6.
 6. Gross M, Ben-Yaakov A, Goldfarb A, et al. Pneumolabyrinth: an unusual finding in a temporal bone fracture. *Int J Pediatr Otorhinolaryngol*. 2003;67(5):553-5.
 7. Woo HJ, Song SY, Kim YD, et al. Pneumolabyrinth without temporal bone fracture: different outcomes for hearing recovery. *Laryngoscope*. 2008;118(8):1464-6.
 8. Al Felasi M, Pierre G, Mondain M, et al. Perilymphatic fistula of the round window. *Eur Ann Otorhinolaryngol Head Neck Dis*. 2011;128(3):139-41.
 9. Hatano A, Rikitake M, Komori M, et al. Traumatic perilymphatic fistula with the luxation of the stapes into the vestibule. *Auris Nasus Larynx*. 2009;36(4):474-8.

De Garengot Hernia Diagnosed with Point-of-care Ultrasound

Lindsey Jennings, MD, MPH
Brad Presley, MD
Edward Jauch, MD, MS

Medical University of South Carolina, Department of Emergency Medicine, Charleston,
South Carolina

Section Editor: Rick A. McPheeters, DO

Submission history: Submitted October 12, 2018; Revision received January 2, 2019; Accepted January 12, 2019

Electronically published February 26, 2019

Full text available through open access at http://escholarship.org/uc/uciem_cpccem

DOI: 10.5811/cpcem.2019.1.41170

De Garengot hernias, defined as a femoral hernia containing the appendix, are rare. It is even uncommon to have an incarcerated de Garengot hernia with associated acute appendicitis. We report a case of a 76-year-old female presenting to the emergency department for a right lower quadrant abdominal mass for four days. Physical exam was consistent with an incarcerated hernia. A point-of-care ultrasound revealed a non-compressible, blind-ended loop of bowel within the hernia sac, concerning for acute appendicitis within the mass. Computed tomography of the abdomen and pelvis confirmed the diagnosis of acute appendicitis within a femoral hernia. [Clin Pract Cases Emerg Med. 2019;3(2):119-122.]

INTRODUCTION

Abdominal hernias and appendicitis are both common conditions evaluated in the emergency department (ED). However, encountering acute appendicitis within an incarcerated hernia is quite rare. Amyand hernias are inguinal hernias with the appendix contained within the hernia sac. De Garengot hernias are femoral hernias with the appendix contained within the hernia sac. Both of these hernias can be associated with acute appendicitis. This case report highlights the diagnostic difficulties in identifying patients with appendicitis within a hernia and is one of the few reported cases of making this diagnosis with point-of-care ultrasound (POCUS).^{1,2}

CASE REPORT

A 76-year-old female with a past medical history of nephrolithiasis, thyroid disease, and osteopenia presented to the ED for right lower quadrant abdominal pain for the prior four days. She stated that she had experienced pain after lifting several flowerpots. On the day of presentation the patient noticed a mass in the right lower quadrant. She went to her primary care physician for evaluation; an attempt to reduce the hernia in the office was unsuccessful, so the patient was transferred to the ED for concern of an incarcerated hernia.

In the ED, laboratory evaluation revealed an elevated white blood cell count at 13.02 millimeters (mm)³ (range

4.8-10.8 mm³), normal serum lactate of 0.57 millimoles per liter (mmol/L) (range 0.5-1.6 mmol/L), and a normal metabolic panel. A second attempt to reduce the mass after intravenous administration of hydromorphone was unsuccessful. Subsequent POCUS showed a blind-ended, non-compressible, dilated loop of bowel one centimeter in diameter within the right lower quadrant mass, concerning for acute appendicitis within the incarcerated hernia sac (Images 1, 2 and 3). Sonographic criteria for the diagnosis of acute appendicitis include a non-compressible, blind-ended loop of bowel that is greater than 6 mm in diameter without peristalsis.

Given the concern for acute appendicitis within the hernia sac, no further attempts at reduction were made and surgery was consulted. A computed tomography (CT) of the abdomen and pelvis performed per surgery's request confirmed the diagnosis of a right-sided femoral hernia containing an inflamed appendix, consistent with a de Garengot hernia with acute appendicitis (Image 4). The patient went to the operating room for appendectomy and hernia repair.

DISCUSSION

The presence of the appendix in a femoral hernia sac was first described in 1731 by the French surgeon de Garengot, giving this type of hernia its eponym.³ This is not to be confused with an Amyand hernia, in which the

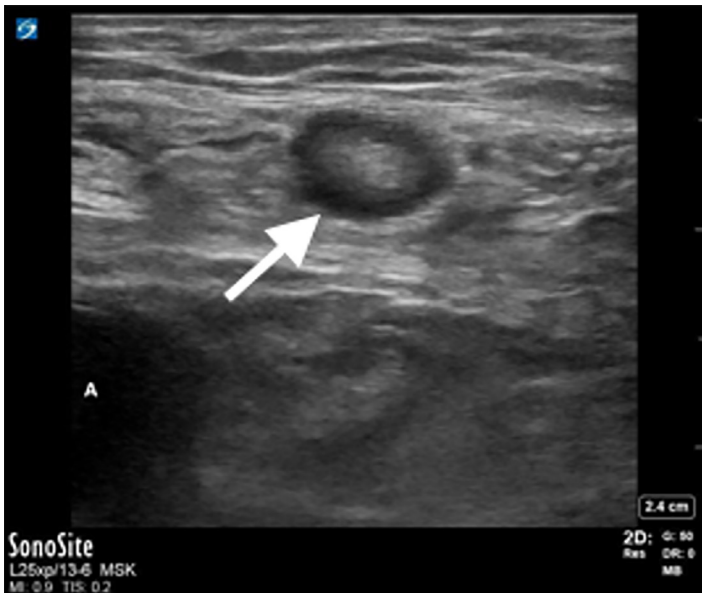

Image 1. Appendix within the hernia sac. Arrow pointing to the appendix with a diameter of approximately one centimeter. Pressure is being applied with the ultrasound probe, demonstrating that the appendix is non-compressible, while also compressing the femoral vein so it cannot be visualized. The femoral artery can be seen in the lower left (A).

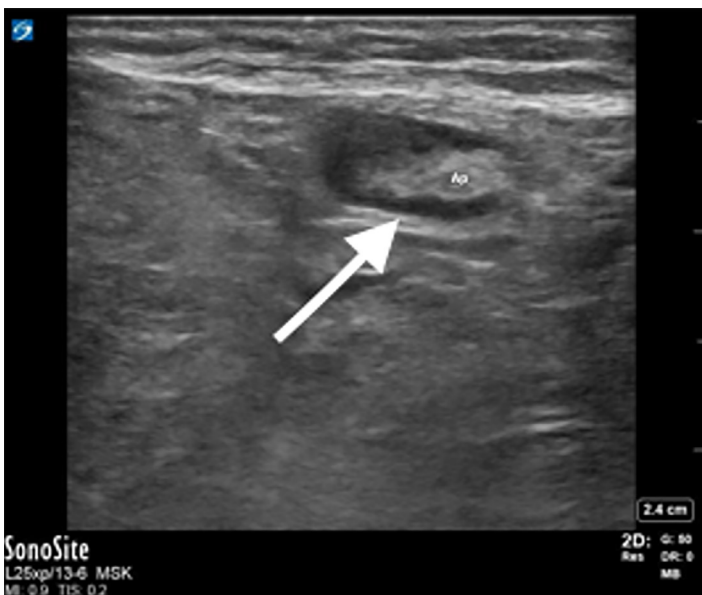

Image 2. Oblique view of appendix on ultrasound. Arrow pointing to fluid around the appendix. Ap, appendix.

appendix is contained within an inguinal hernia sac.⁴ De Garengeot hernias are rare, accounting for 0.5-3% of all femoral hernias.^{5,6} There are less than 100 known cases of de Garengeot hernias.⁷ It is even more uncommon to have

CPC-EM Capsule

What do we already know about this clinical entity?
De Garengeot hernias, femoral hernias containing the appendix, are rare and can be associated with acute appendicitis.

What makes this presentation of disease reportable?
The diagnosis was initially made with point-of-care ultrasound (POCUS). Diagnosis by POCUS is uncommon and has only been reported a few times in the literature.

What is the major learning point?
De Garengeot hernias can present indistinguishably from a femoral hernia. If the hernia is reducible, the diagnosis of appendicitis may be missed, leading to higher morbidity and mortality.

How might this improve emergency medicine practice?

This case demonstrates the utility of POCUS. Additionally, increased awareness of this disease may decrease the rate of delayed diagnosis.

acute appendicitis, which occurs in 0.08-0.13% of patients with de Garengeot hernias.⁸

De Garengeot hernias are often difficult to diagnose and may clinically present indistinguishably from an irreducible femoral hernia.⁹ While de Garengeot hernias have been diagnosed on CT, and in a few other case reports with ultrasound, they are often missed on imaging and almost never diagnosed preoperatively.¹⁰⁻¹³ Due to the uncommon nature of this condition, the best technique of operative management remains unclear and the laparoscopic approach remains controversial.^{3,7,14,15}

CONCLUSION

Our case of a de Garengeot hernia containing an acutely inflamed appendix shows that this diagnosis can be made with ultrasound. While the sensitivity and specificity of ultrasound in making the diagnosis of appendicitis within a hernia is still unknown, providers may consider ultrasound and CT in their initial evaluations. Emergency physicians should consider both Amyand and de Garengeot hernias in the differential diagnosis for patients with inguinal or femoral hernias, as these diagnoses can be difficult to make. In the setting of appendicitis within a hernia, reduction of the

hernia alone will not adequately treat the appendicitis, which can lead to significant complications. Additionally, the lack of symptoms of appendicitis can lead to a delayed diagnosis, resulting in a high frequency of perforated or gangrenous appendicitis, leading to increased morbidity and mortality.^{3,16} Maintaining a high level of suspicion may lead to earlier diagnosis and decreased complications.^{14,17}

Documented patient informed consent and/or Institutional Review Board approval has been obtained and filed for publication of this case report.

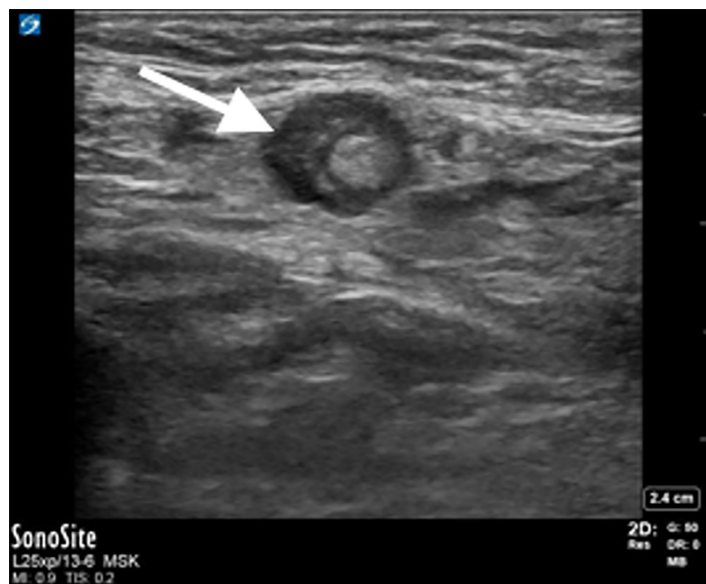

Image 3. Point-of-care ultrasound image of appendix with hypoechoic rim (arrow).

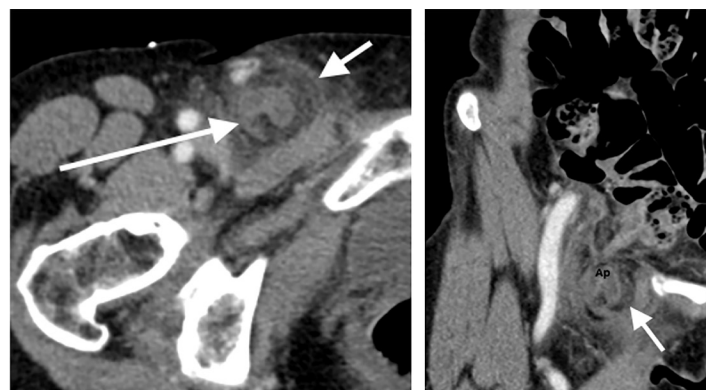

Image 4. (Left) Axial view of the inflamed appendix within the hernia sac on computed tomography. Long arrow pointing to the appendix, short arrow pointing to the hernia sac. (Right) Coronal view of appendicitis within the hernia sac on computed tomography (arrow).

Address for Correspondence: Lindsey Jennings, MD, MPH, Medical University of South Carolina, Department of Emergency Medicine, 169 Ashley Ave, MSC 300, Charleston, SC 29425. Email: jennil@musc.edu.

Conflicts of Interest: By the CPC-EM article submission agreement, all authors are required to disclose all affiliations, funding sources and financial or management relationships that could be perceived as potential sources of bias. The authors disclosed none.

Copyright: © 2019 Jennings et al. This is an open access article distributed in accordance with the terms of the Creative Commons Attribution (CC BY 4.0) License. See: <http://creativecommons.org/licenses/by/4.0/>

REFERENCES

1. Filatov J, Ilibitzki A, Davidovitch S, et al. Appendicitis within a femoral hernia: sonographic appearance. *J Ultrasound Med.* 2006;25(9):1233-5.
2. Kalles V, Mekras A, Mekras D, et al. De Garengot's hernia: a comprehensive review. *Hernia.* 2013;17(2):177-82.
3. Hussain A, Slessor AP, Monib S, et al. De Garengot hernia masquerading as a strangulated femoral hernia. *Int J Surg Case Rep.* 2014;5(10):656-8.
4. Luchs J, Halpern D, Katz D. Amyand's hernia: prospective CT diagnosis. *J Comput Assist Tomogr.* 2000;24(6):884-6.
5. Wise L. Strangulated femoral hernia appendix with perforated sigmoid diverticulitis. *Proc R Soc Med.* 1963;56:1105-6.
6. Konofaos P, Spartalis E, Smirnis A, et al. De Garengot hernia in a 60-year-old woman: a case report. *J Med Case Rep.* 2011;5:258.
7. Talini C, Oliveria LO, Araujo A, et al. De Garengot hernia: case report and review. *Int J Surg Case Rep.* 2015;8C:35-7.
8. Raja SS, Girn HR, Ainslie WG. Inflamed appendix in a femoral hernia sac: de Garengot's hernia. *Hernia.* 2009;13(5):551-3.
9. Ash L, Hatem S, Ramierz GA, et al. Amyand's hernia: a case report of prospective CT diagnosis in the emergency department. *Emerg Radiol.* 2005;11(4):231-2.
10. Zissin R, Brautbar O, Shapiro-Feinberg M. CT diagnosis of acute appendicitis in a femoral hernia. *Br J Radiol.* 2000;73(873):1013-4.
11. Ramsingh J, Ali A, Cameron C, et al. De Garengot's hernia: diagnosis and surgical management of a rare type of femoral hernia. *J Surg Case Rep.* 2014;2014(2):rju008.
12. Akopian G and Alexander M. De Garengot hernia: appendicitis within a femoral hernia. *Am Surg.* 2005;71(6):526-7.
13. Sharma H, Jha PK, Shekhawat B, et al. De Garengot hernia: an analysis of our experience. *Hernia.* 2007;11(3):235-8.
14. Ebisawa K, Yamazaki S, Kimura Y, et al. Acute appendicitis in an incarcerated femoral hernia: a case of de Garengot hernia. *Case*

Rep Gastroenterol. 2009;30(3):313-7.

15. Thomas B, Thomas M, McVay B, et al. De Garengeot hernia. *JLS.* 2009;13(3):455-7.
16. Meinke AK. Review article: appendicitis in groin hernias. *J*

Gastrointest Surg. 2007;11(10):1368-72.

17. Piperos T, Kalles V, Al Ahwal Y, et al. Clinical significance of de Garengeot's hernia: a case of acute appendicitis and review of the literature. *Int J Surg Case Rep.* 2012;3(3):116-7.

Emergency Physician Reduction of Pediatric Hip Dislocation

Seth Capehart, BA*
Brenden J. Balcik, MD†
Rosanna Sikora, MD†
Melinda Sharon, MPH‡
Joseph Minardi, MD†‡

*West Virginia University School of Medicine, Morgantown, West Virginia
†West Virginia University School of Medicine, Department of Emergency
Medicine, Morgantown, West Virginia
‡West Virginia University School of Medicine, Department of Medical
Education, Morgantown, West Virginia

Section Editor: Rick A. McPheeters, DO

Submission history: Submitted October 2, 2018; Revision received January 2, 2019; Accepted January 12, 2019

Electronically published February 26, 2019

Full text available through open access at http://escholarship.org/uc/uciem_cpccem

DOI: 10.5811/cpccem.2019.1.41131

Traumatic hip dislocation in children is relatively rare but presents a true emergency, as a delay in reduction can result in avascular necrosis of the femoral head and long-term morbidity. After sustaining a traumatic posterolateral hip dislocation, a seven-year-old boy presented to an outside facility where no attempt was made at reduction. The patient was transferred to our emergency department (ED) where he was promptly sedated and the dislocation was reduced in a timely manner. Emergency physicians have demonstrated high success rates with dislocation reduction. ED reduction should occur immediately to reduce the likelihood of long-term complications. While timely consultation with a pediatric orthopedist is recommended, that should not delay reduction. The reduction should ideally be performed before the patient leaves the department or is transferred to another facility. [Clin Pract Cases Emerg Med. 2019;3(2):123-127.]

INTRODUCTION

Traumatic hip dislocation in pediatric patients is relatively rare, with little literature to support specific treatment techniques and timelines. When compared to adults, pediatric hip reduction may be easier to perform and carries a more favorable prognosis.¹ A delayed reduction may result in avascular necrosis (AVN) of the femoral head. Early-stage AVN is usually painless but ultimately leads to painful degradation of the hip joint, restricted movement and eventual collapse, requiring arthroplasty.² In this report, we describe a seven-year-old boy with a traumatic posterolateral hip dislocation presenting to an emergency department (ED). In addition, we discuss the current literature and review the reduction procedures, so that subsequent cases may be treated as early as possible to decrease potential morbidity from this uncommon injury in the pediatric population.

CASE REPORT

A seven-year-old boy presented to an outside facility after sustaining a hip injury while playing organized football. He reported that he was struggling at the bottom of a pile when he developed severe hip pain. At the outside hospital, he was diagnosed with a posterolateral hip dislocation. No attempt at reduction was made at the referring hospital. After consultation

with a local orthopedist, the patient was transferred to our tertiary care facility via helicopter, and he arrived approximately 5.5 hours after initial injury. Prior to his arrival, preparations were made by ED staff for a rapid, comprehensive trauma evaluation and emergent sedation and reduction measures.

The patient complained of right leg pain and tingling upon arrival, with no reported pain elsewhere. Physical exam revealed that he was moderately distressed from pain and slightly tachycardic. The right lower extremity was internally rotated with flexion at the knee. He had normal distal pulses, good capillary refill, and was able to move his toes. Pelvic radiograph confirmed posterolateral right femoral head dislocation without evidence of fracture, as seen in Image 1. Point-of-care focused assessment with sonography for trauma exam and chest radiograph were also completed and both were negative.

A complete trauma evaluation confirmed an isolated right hip dislocation with no contraindications to procedural sedation to facilitate dislocation reduction. Given his stable hemodynamics, he was sedated with intravenous propofol. Once sedated, the pelvis was stabilized by providing posteriorly directed countertraction to the pelvic girdle preparing for reduction via Allis technique. The emergency physician (EP) stood on the bed, flexed the hip and knee to 90 degrees, placing the patient's right leg into a simulated seated

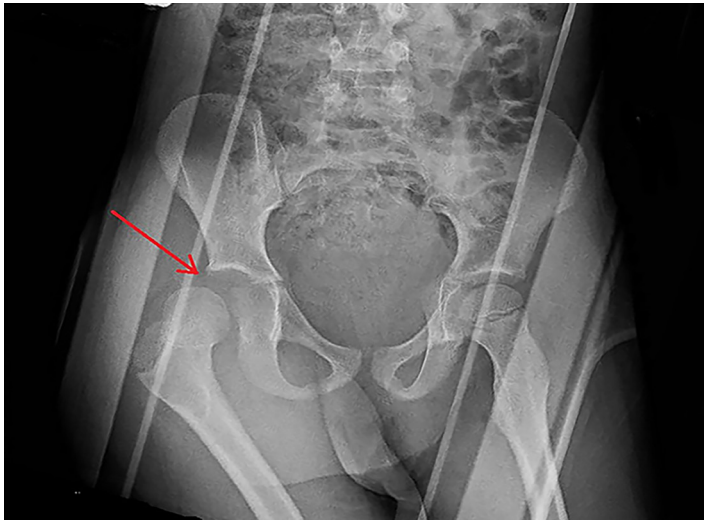


Image 1. Anteroposterior pelvic radiograph demonstrating superior and lateral displacement of the right femoral head relative to the acetabulum (arrow) and internal hip rotation consistent with posterior hip dislocation.

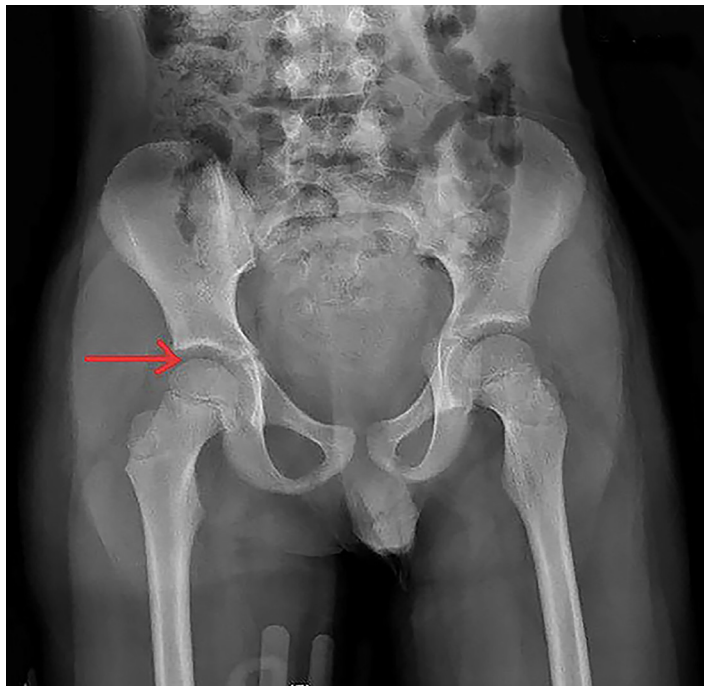


Image 2. Post-reduction anteroposterior view of the pelvis demonstrating normal alignment of the right femoral head within the acetabulum (arrow).

position, and provided steady anterior traction by pulling from behind the knee and slightly internally rotating. The right hip was easily reduced without complication and the patient remained hemodynamically stable. Post-reduction, radiographs were performed showing complete reduction of

CPC-EM Capsule

What do we already know about this clinical entity?

Posterolateral femoral head dislocations in the pediatric population are relatively rare and are often referred to surgery for reduction.

What makes this presentation of disease reportable?

While a relatively rare injury, pediatric hip dislocations are a true emergency due to risk of femoral head avascular necrosis resulting in increased morbidity.

What is the major learning point?

Reduction procedures should be performed by the initial treating emergency physician (EP), in a timely manner, to decrease the risk of avascular necrosis of the femoral head.

How might this improve emergency medicine practice?

Recognizing the risks of delayed reduction, the techniques, and safety of closed reduction should allow EPs to more rapidly treat these injuries leading to improved outcomes.

the femoral head, as seen in Image 2. The patient's pain was improved and his paresthesias were resolved.

Pediatric orthopedics was subsequently consulted, recommending a pelvic computed tomography (CT), which was negative for fracture. The patient was placed in a knee immobilizer and admitted for observation. He was discharged the next day with a walker, restricted to toe-touch weight-bearing of the right lower extremity with no hip flexion past 90 degrees or adduction past midline. He did well in follow-up, returning to full weight-bearing activity and exercise two months post-injury.

DISCUSSION

Although pediatric hip dislocation is relatively rare, it is a time-sensitive diagnosis. Delays in reduction result in increased risk of morbidity, namely AVN.³ EPs must be knowledgeable about and properly trained to diagnose and treat this condition. In children aged 6-10 years, the most common cause of injury is the result of a minor impact such as a fall from height or during an athletic event. Children 10 years of age and older mostly have hip dislocations due to a motor vehicle collision.¹ Approximately

80% of these types of pediatric injuries result in posterolateral dislocation as a result of minimal trauma. Dislocation in children is attributed to the ligamentous laxity and a soft, pliable acetabulum, which also accounts for a low incidence of associated acetabular and femur fractures compared to adults.⁴ The predominant mechanism of injury is posteriorly directed force along the femoral shaft while the hip is held in flexion, adduction, and internally rotated.⁵

Physical exam findings of posterior dislocation include prominent, elevated greater trochanter and a shortened, internally rotated, flexed, and adducted lower extremity. Conversely, anterior dislocation presents with a loss of greater trochanter prominence in an externally rotated, extended, and abducted lower extremity, with possible leg lengthening.⁵ Superior lateral displacement of the femoral head with respect to the acetabulum is consistent with posterior dislocation, while anteromedial displacement is consistent with anterior dislocation.⁶⁻⁸ Children who suffer minor trauma and refuse to weight bear should be carefully examined for findings suggestive of posterior hip dislocation, in addition to a full evaluation for other traumatic injuries as well as peripheral nerve injury.⁶

Diagnosis is confirmed radiographically and should be ordered immediately so that reduction can be performed within six hours from time of injury. In a longitudinal study, Mehlman et al. found a 20-fold increase in AVN of the femoral head for pediatric patients having reduction performed after six hours, while 95% of patients who underwent reduction in less than six hours had favorable outcomes.³ Additionally, a meta-analysis comparing AVN rates for early (< 6 hours) and late reductions (> 6 hours) from five eligible studies showed a significant, decreased risk of AVN to those undergoing early reduction.⁹ Other potential complications of pediatric hip dislocation include sciatic nerve injury, coxa magna (a usually asymptomatic rounding and shortening of the femoral head and neck), re-dislocation,

and post-injury arthritis. In adolescents, one must consider and evaluate for epiphysolysis (complete separation of the proximal femoral epiphysis), which leads to AVN in nearly all cases. CT or magnetic resonance imaging (MRI) may be necessary to establish this diagnosis post-reduction, but the optimal imaging modality has not been established.⁶

Management of injury includes prompt pain management, sedation or general anesthesia, emergent reduction of dislocated hip and post-reduction immobilization or traction. While the majority of the literature describes reductions that occur in the operating room (OR), reductions can safely be performed in the ED, allowing for a shorter interval between dislocation and reduction and reducing the risk of AVN. Existing literature suggests that all reductions for hip dislocations, including pediatric and even prosthetic hip dislocations, can be safely and effectively carried out in the ED.^{6,10} In a systematic review by Bressan et al., which included 25 case reports and case series, nearly half of reported acute cases were reduced in the ED with no reported adverse outcomes.⁶ All cases of reported AVN were associated with delayed reduction (> 6 hours) performed in the OR, which would suggest that early reduction in the ED by competent providers is protective against AVN.⁶ This review was unable to identify an optimal reduction technique.⁶ This case demonstrates an additional example of safe and successful closed pediatric hip reduction performed in the ED.

A variety of reduction techniques have been described and are summarized in the Table reproduced from Gottlieb, stating that the individual success rates vary from 60-90% across all age groups.¹¹ The best technique for pediatric reduction has not been identified and should be based on the experience of the providing physician.⁶ Therefore, EPs should be familiar with several different techniques to increase the odds of success.¹¹ Early consultation with pediatric orthopedic surgery is recommended and patients should be followed and examined for resulting AVN and/or growth disorders.^{6,12}

Table. Review of techniques for hip dislocation reduction by Gottlieb.¹¹

Name	Technique	Advantages	Disadvantages
Allis	Provider grasps affected leg with both knee and hip flexed to 90 degrees, applying traction toward the ceiling.	Well-established	Risk of falls and lower back injury to the provider.
Bigelow	Provider grasps affected leg with both knee and hip flexed to 90 degrees, applying in-line traction while abducting, externally rotating, and extending the leg.	This technique is no longer recommended.	Risk of falls and lower back injury to the provider. Increased risk of femoral neck fractures.
East Baltimore lift	Two providers place their arms underneath the affected knee with their knees bent and their hands on each other's shoulders. Providers slowly stand up while countertraction is applied to the patient's ankle.	Strong, controlled upward force and ability to internally and externally rotate the hip	Requires multiple providers.
Tulsa/ Rochester/ Whistler	Provider places the arm underneath the affected knee with the provider's palm on the flexed, unaffected knee. Using the forearm as a fulcrum, the provider applies downward pressure on the ankle, while internally and externally rotating the hip.	Requires only one provider	Less upward force is possible. Potential injury to the provider's forearm

Table. Continued.

Name	Technique	Advantages	Disadvantages
Flexion adduction	One provider flexes and maximally adducts the affected hip, while the second provider applies manual pressure on the femoral head.	Allows for a controlled, steady reduction attempt	Limited data on efficacy
Foot fulcrum	Provider places patient's foot against his or her inner ankle and places provider's outer foot against the patient's femoral head. Provider grasps patient's flexed knee and leans backward.	Requires only one provider and allows for a controlled, steady reduction attempt	Potential injury to provider's back and patient's sciatic nerve if incorrectly performed. Risk of fall injury.
Howard	Provider grasps affected leg with both knee and hip flexed to 90 degrees, applying in-line traction, while a second provider applies lateral traction.	Allows for a slow, controlled reduction attempt	Multiple providers are needed. Limited data on efficacy.
Lateral traction	Provider grasps affected leg in extension and applies in-line traction, while a second provider applies lateral traction.	Valuable technique when the patient is unable to flex the affected hip	Multiple providers are needed. Limited data on efficacy.
Lefkowitz	Provider places his or her knee underneath the affected leg with both knee and hip flexed to 90 degrees. Provider applies a downward force on the patient's lower leg, using the knee as a fulcrum.	Requires only one provider and allows for a controlled, steady reduction attempt	Potential to injure patient's knee ligaments. Difficult to provide significant force for the reduction.
Captain Morgan	Provider places his or her knee underneath the affected leg with both knee and hip flexed to 90 degrees. Provider plantarflexes ankle to facilitate the reduction.	Requires only one provider and allows for a controlled, steady reduction attempt	May be more difficult in patients with longer legs.
Postgraduate Institute (PGI)	Provider gradually flexes knee to 120 degrees of flexion, then abducts to 45 degrees, and finally externally rotates until the hip reduces.	Allows for a controlled, steady reduction attempt and does not require significant force	Limited data, but appears promising.
Piggyback/rocket launcher	Provider places patient's flexed knee over his or her shoulder and rises to a standing position	Requires only one provider and allows for a controlled, steady reduction attempt	Excess pressure on the lower leg can injure the knee ligaments.
Skoff	Patient is placed in left lateral decubitus with the leg in 100 degrees of hip flexion, 45 degrees of internal rotation, 45 degrees of adduction, and the knee bent to 90 degrees. In-line traction is applied to the leg, while another provider applies pressure to the greater tuberosity.	Allows for a controlled, steady reduction attempt	Multiple providers are needed. May be difficulty to palpate the greater tuberosity. Limited data on efficacy.
Stimson	Patient is placed prone with the affected leg 90 degrees past the end of the gurney. Downward traction is applied by the provider using either the provider's arm or the provider's bent knee.	Well-established. Uses gravity to facilitate the reduction	Multiple providers are needed. Difficulty to monitor the patient in the prone position. Potential for the patient to fall off the gurney.
Traction-countertraction	Patient is placed in left lateral decubitus with the leg in 100 degrees of hip flexion, 45 degrees of internal rotation, and 45 degrees of adduction. One provider applies posterior traction at the upper thigh, while a second provider applies anterior traction at the lower leg.	Allows for a controlled, steady reduction attempt. The use of bed sheets for traction allows the provider freedom to use his or her hands to facilitate the reduction.	Multiple providers are needed. Limited data on efficacy.

CONCLUSION

Although a relatively rare injury, pediatric hip dislocations do occur and the ED should be the primary location for closed reduction without evidence of fracture. In younger children these injuries are more often due to lower energy trauma, and associated fractures are less common than in older children and adults. EPs should be familiar with the diagnosis and

reduction procedures to reduce the risk of long-term complications, namely AVN, and financial cost to patients. Closed reduction should not be delayed pending transfer to an alternate facility, consultation with pediatric orthopedics, or availability of an OR. Reduction should be performed as soon as possible, preferably within six hours of dislocation to decrease the risk of AVN of the femoral head.

Documented patient informed consent and/or Institutional Review Board approval has been obtained and filed for publication of this case report.

Address for Correspondence: Joseph Minardi, MD, West Virginia University School of Medicine, Department of Emergency Medicine, 1 Medical Center Drive, Morgantown, WV 26506. Email: jminardi@hsc.wvu.edu.

Conflicts of Interest: By the CPC-EM article submission agreement, all authors are required to disclose all affiliations, funding sources and financial or management relationships that could be perceived as potential sources of bias. The authors disclosed none.

Copyright: © 2019 Capehart et al. This is an open access article distributed in accordance with the terms of the Creative Commons Attribution (CC BY 4.0) License. See: <http://creativecommons.org/licenses/by/4.0/>

REFERENCES

1. Bakkaly AE, Ettayebi F, Oubeja H, et al. Closed reduction of a traumatic hip dislocation in children: case report. *Pan Afr Med J.* 2017;26:231.
2. Sen RK. Management of avascular necrosis of femoral head at pre-collapse stage. *Indian J Orthop.* 2009;43(1):6-16.
3. Mehlman CT, Hubbard GW, Crawford AH, et al. Traumatic hip dislocation in children: Long-term follow-up of 42 patients. *Clin Orthop Relat Res.* 2000;376:68-79.
4. Thompson VP and Epstein HC. Traumatic dislocation of the hip: a survey of two hundred and four cases covering a period of twenty-one years. *J Bone Joint Surg Am.* 1951;33-A(3):746-78.
5. Masiewicz S and Johnson DE. Dislocation, Hip (Femur), Posterior. Available at: <https://www.ncbi.nlm.nih.gov/books/NBK459319/>. 2017. Accessed on September 1, 2018.
6. Bressan S, Steiner IP, Shavit I. Emergency department diagnosis and treatment of traumatic hip dislocations in children under the age of 7 years: a 10-year review. *Emerg Med J.* 2014;31(5):425-31.
7. Hughes MJ and D'Agostino J. Posterior hip dislocation in a five-year-old boy: a case report, review of the literature, and current recommendations. *J Emerg Med.* 1996;14(5):585-90.
8. Tannast M, Pleus F, Bonel H, et al. Magnetic resonance imaging in traumatic posterior hip dislocation. *J Orthop Trauma.* 2010;24(12):723-31.
9. Ahmed G, Shiraz S, Riaz M, et al. Late versus early reduction in traumatic hip dislocations: a meta-analysis. *Eur J Orthop Surg Traumatol.* 2017;27(8):1109-16.
10. Germann CA, Geyer DA, Perron AD. Closed reduction of prosthetic hip dislocation by emergency physicians. *Am J Emerg Med.* 2005;23(6):800-5.
11. Gottlieb M. Hip dislocations in the emergency department: a review of reduction techniques. *J Emerg Med.* 2018;54(3):339-47.
12. Mörsdorf P, Lauer A, Histing T, et al. Traumatic hip dislocation in a 6-year-old male child: seldom but demanding. *Unfallchirurg.* 2017;120(4):350-4.

Evans Syndrome

Ahmed Al Hazmi, MBBS*
Michael E. Winters, MD, MBA†

*University of Maryland Medical Center, Department of Emergency Medicine,
Baltimore, Maryland

†University of Maryland School of Medicine, Department of Emergency
Medicine, Baltimore, Maryland

Section Editor: Steven Walsh, MD

Submission history: Submitted September 22, 2018; Revision received December 31, 2019; Accepted January 23, 2019

Electronically published February 26, 2019

Full text available through open access at http://escholarship.org/uc/uciem_cpccem

DOI: 10.5811/cpcem.2019.1.41028

A 22-year-old man presented to the emergency department with facial swelling, rash, and fatigue. He had a past medical history of pericarditis and pericardial effusion. His evaluation showed anemia and thrombocytopenia. He was admitted for intravenous administration of steroids, plasmapheresis, and workup of his anemia and thrombocytopenia. He was ultimately diagnosed with Evans syndrome as a presenting feature of systemic lupus erythematosus. Plasmapheresis was stopped but administration of steroids continued. His blood counts improved, and the facial swelling and rash subsided. Evans syndrome is an immunologic conundrum that requires early recognition and treatment. [Clin Pract Cases Emerg Med. 2019;3(2):128-131.]

INTRODUCTION

Evans syndrome (ES) is a very rare autoimmune disease first described in 1951. It is the combination of Coombs-positive idiopathic autoimmune hemolytic anemia (IAHA) and immune thrombocytopenic purpura (ITP).¹⁻³ In addition, ES can be associated with the development of neutropenia due to autoimmune destruction. Though the degree of immunosuppression can be profound, there are no reported cases of ES patients with neutropenia experiencing life-threatening infections.^{2,4,5} Importantly, IAHA, ITP, and neutropenia can develop sequentially or can all be present at the time of diagnosis. Often, patients with ES have discordance between their clinical symptoms and the severity of their laboratory abnormalities.^{6,7} ES is a chronic autoimmune condition characterized by exacerbations and periods of remission.¹⁻³ Patients who are experiencing an exacerbation often present to the emergency department (ED) for evaluation and management. To minimize morbidity and the risk of death, it is important for the emergency physician to identify patients with ES and institute urgent therapy. In this case report, we describe an atypical presentation of ES in a young man who presented to our ED.

CASE REPORT

A 22-year-old male with a past medical history of pericarditis and pericardial effusion presented to the ED with

the chief complaint of facial swelling, which had been present for the prior three weeks. The swelling was predominantly on the right side of his face and upper lip. He had no history of angioedema, had not started any new medications, and was not aware of an environmental exposure that immediately preceded the onset of swelling. In addition to the facial and lip swelling, the patient reported a rash of the same duration on his chest and shoulders. Additional associated symptoms included decreased exercise tolerance, exertional dyspnea, and a single episode of dark, maroon-colored stool. He denied fever, chills, myalgia, arthralgia, chest pain, abdominal pain, nausea, vomiting, odynophagia, dysphagia, and confusion. He was not aware of any sick contacts and he had not traveled recently. He reported that his family did not have a history of chronic illnesses.

Physical examination was significant for a blood pressure of 104/58 millimeters of mercury, a pulse of 96 beats per minute, respiratory rate of 16 breaths per minute, a temperature of 36.8° Celsius, and a pulse oximetry reading of 100% on room air. He was a thin young man who did not appear to be in distress or acutely ill. Bilateral facial edema along with edema of the upper lip was noted (Image 1). In addition, his conjunctiva, palms, and soles were notable for pallor. A petechial rash was observed on his upper chest, bilateral shoulders, tongue, and soft palate (Image 2). A malar rash was also noted (Image 3). The remainder of his examination was normal.

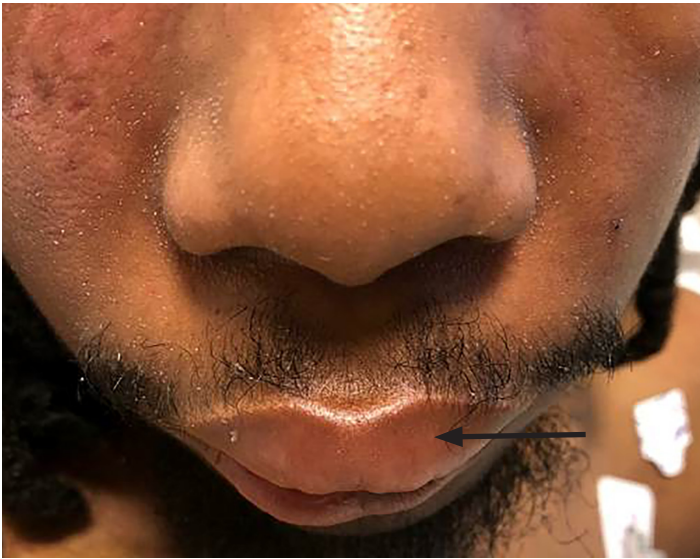

Image 1. Bilateral facial edema along with edema of the upper lip (arrow).

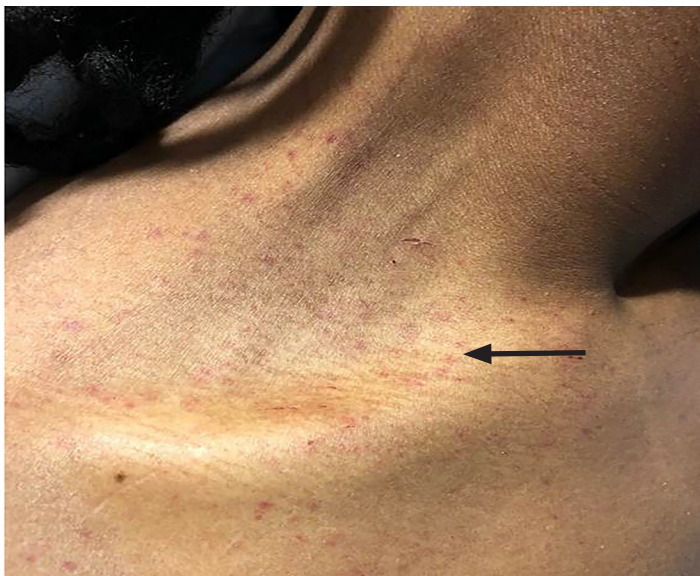

Image 2. Petechial rash (arrow) on upper chest and shoulders.

His initial ED evaluation included a chest radiograph, electrocardiogram, and laboratory studies. The results of pertinent laboratory studies are listed in the table. Given his severe thrombocytopenia and anemia, thrombotic thrombocytopenic purpura (TTP) was considered and an emergent hematology consultation was obtained. A peripheral blood smear demonstrated 1-2 schistocytes per high-power field, which initially raised concern for a microangiopathic hemolytic anemia. As a result, a hemodialysis catheter was inserted and plasmapheresis was initiated while the patient was in the ED. He received a unit of packed red blood cells

CPC-EM Capsule

What do we already know about this clinical entity?

Evans syndrome is a rare autoimmune disease characterized by autoimmune hemolytic anemia and immune thrombocytopenic purpura.

What makes this presentation of disease reportable?

To our knowledge, this is the first case report to detail the clinical presentation of a patient with Evans syndrome to the emergency department. The patient presented with angioedema, fatigue, and a petechial rash.

What is the major learning point?

Evans syndrome often presents with features of other autoimmune disorders and can frequently be misdiagnosed.

How might this improve emergency medicine practice?

In addition to thrombotic thrombocytopenic purpura, emergency physicians should consider the diagnosis of Evans syndrome in patients presenting with thrombocytopenia and a hemolytic anemia.

along with corticosteroids and was admitted to the medical intermediate care unit.

Workup revealed a positive immunoglobulin G (IgG) Coombs test. He also had a high titer of antinuclear acid antibody and low C3/C4 complements, indicative of an acute exacerbation of an autoimmune disease. The combination of his symptoms, ED workup, and history of pericarditis and pericardial effusion favored the diagnosis of systemic lupus erythematosus (SLE). Within 48 hours after admission, an A disintegrin and metalloproteinase with thrombospondin motifs 13 (ADAMTS13) level returned with 78% activity and less than 5% inhibitor. This result was not consistent with the diagnosis of TTP, and plasma exchange was stopped. Ultimately, the hematologist diagnosed Evans syndrome as a presenting feature of SLE.

DISCUSSION

ES is a rare autoimmune disorder characterized by profound immune dysregulation. To date, no cause has been identified and the pathophysiology remains uncertain.²

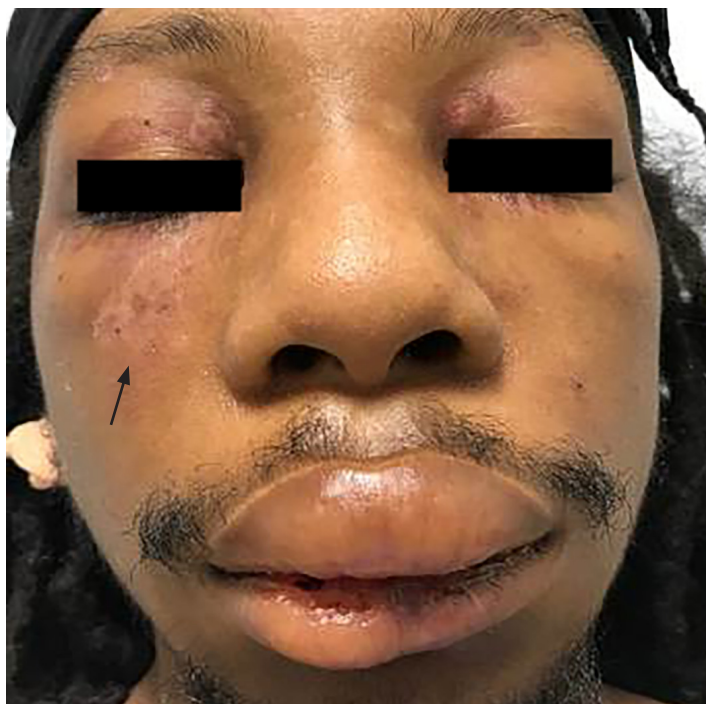

Image 3. Malar rash (arrow) in addition to facial and lip swelling.

Notwithstanding, ES has been associated with select infections and both the measles-mumps-rubella and influenza vaccines.^{4,8} It is hypothesized that immunization can trigger ES in susceptible individuals.^{4,8}

ES presents with signs and symptoms of both IAHA and ITP. Typical symptoms include fatigue, pallor, dyspnea, tachycardia, and fever. Jaundice, hematuria, hemoglobinuria, and hepatosplenomegaly might also be noticed. Patients with ES could have bruising, petechiae, and mucocutaneous bleeds secondary to thrombocytopenia. It is important to also note that patients may have neutropenia and may present with immunosuppression-related infections. The severity of the disease can vary from mild to life-threatening.⁹

Importantly, ES is a diagnosis of exclusion. Although the hallmark laboratory abnormalities point to IAHA and ITP, no single test can confirm the diagnosis of ES. In fact, many of its laboratory abnormalities are also seen in other conditions with similar clinical presentations (e.g., low level schistocytes). These include other autoimmune conditions (e.g., SLE), IgA deficiency, TTP, autoimmune myeloproliferative syndromes, and malignancy. Further complicating the diagnostic process is the fact that autoimmune destruction of circulating blood cells in autoimmune hemolytic anemia (AIHA) and ITP are also seen simultaneously in patients with paroxysmal nocturnal hematuria, hemolytic uremic syndrome, and hemangiomas with thrombocytopenia.¹⁰

Laboratory studies that are helpful in the management and workup are a complete blood count that shows

Table. Laboratory results relevant for Evans syndrome in the emergency department.

WBC	3.4 K/mcL
RBC	1.81 M/mcL
Hb	5.8 g/dL
HCT	17.2 %
PLT	4 K/mcL
LDH	389 units/L
AST	437 units/L
ALT	117 units/L
Total bilirubin	4.4 mg/dL
Indirect bilirubin	0.6 mg/dL
INR	1.2
PTT	42 seconds

WBC, white blood cells; K, thousands; mcL, microliter; RBC, red blood cells; M, moles; Hb, hemoglobin; g/dL, grams per deciliter; HCT, hematocrit; PLT, platelet; LDH, lactic dehydrogenase; L, liter; AST, aspartate aminotransferase; ALT, alanine aminotransferase; mg, milligrams; INR, international normalized ratio; PTT, partial thromboplastin time.

pancytopenia and a peripheral blood smear that shows features of AIHA (spherocytosis). These findings will differentiate AIHA from myelodysplastic syndromes, microangiopathic hemolytic anemias, congenital anemia, and thrombocytopenia. Other markers that can be used to identify hemolysis are an elevated reticulocyte count, the presence of unconjugated hyperbilirubinemia, and a decreased haptoglobin level. Additionally, the direct Coombs test is invariably positive in patients with ES.¹¹

Patients with an initial diagnosis of ES or an exacerbation of known disease should be treated with high-dose corticosteroids. In most cases, prednisone in a dose of 1-2 milligrams per kilogram is adequate to induce remission. Unfortunately, a subset of patients with ES is recalcitrant to this approach, and some have varied responses to the intravenous administration of immunoglobulin (IVIG). In addition, responses to the IVIG range from remission to no effect. Ultimately, patients who are refractory to corticosteroids and IVIG might require advanced therapies such as monoclonal antibodies (rituximab), cyclosporine, and splenectomy with stem cell transplant. It is imperative to avoid administering blood products to those patients unless they have profound anemia or life-threatening bleeding.¹²

CONCLUSION

Emergency physicians should consider ES in patients with features of a hemolytic anemia and thrombocytopenia. Early recognition and treatment can reduce the morbidity and mortality associated with this immunologic conundrum.

Documented patient informed consent and/or Institutional Review Board approval has been obtained and filed for publication of this case report.

Address for Correspondence: Michael E. Winters, MD, MBA, University of Maryland School of Medicine, Department of Emergency Medicine, 110 S Paca St, 6th Floor, Suite 200, Baltimore MD 21201. Email: mwinters@som.umaryland.edu.

Conflicts of Interest: By the CPC-EM article submission agreement, all authors are required to disclose all affiliations, funding sources and financial or management relationships that could be perceived as potential sources of bias. The authors disclosed none.

Copyright: © 2019 Hazmi et al. This is an open access article distributed in accordance with the terms of the Creative Commons Attribution (CC BY 4.0) License. See: <http://creativecommons.org/licenses/by/4.0/>

REFERENCES

1. Evans RS, Takahashi K, Duane RT, et al. Primary thrombocytopenic purpura and acquired hemolytic anemia; evidence for a common etiology. *AMA Arch Intern Med.* 1951;87(1):48-65.
2. Wang W, Herrod H, Pui CH, et al. Immunoregulatory abnormalities in Evans syndrome. *Am J Hematol.* 1983;15(4):381-90.
3. Evans RS and Duane RT. Acquired hemolytic anemia; the relation of erythrocyte antibody production to activity of the disease; the significance of thrombocytopenia and leukopenia. *Blood.* 1949;4(11):1196-213.
4. Shlamovitz GZ and Johar S. A case of Evans' syndrome following influenza vaccine. *J Emerg Med.* 2013;44(2):e149-51.
5. Savaşan S, Warriar I, Ravindranath Y. The spectrum of Evans' syndrome. *Arch Dis Child.* 1997;77(3):245-8.
6. Sarode R. Atypical presentations of thrombotic thrombocytopenic purpura: a review. *J Clin Apher.* 2009;24(1):47-52.
7. Zhang C, Chen XH, Zhang X. Quick development and sudden death: Evans syndrome followed by thrombotic thrombocytopenic purpura. *Am J Emerg Med.* 2014;32(9):1156.e3-e4.
8. Wucherpfennig KW. Mechanisms for the induction of autoimmunity by infectious agents. *J Clin Invest.* 2001;108(8):1097-104.
9. Miano M. How I manage Evans syndrome and AIHA cases in children. *Br J Haematol.* 2016;172(4):524-34.
10. Akbary S and Kannikeswaran N. Acute onset altered mental status in a previously healthy teenager. *Pediatr Emerg Care.* 2012;28(4):376-9.
11. Norton A and Roberts I. Management of Evans syndrome. *Br J Haematol.* 2006;132(2):125-37.
12. Hill QA, Stamps R, Massey E, et al. Guidelines on the management of drug-induced immune and secondary autoimmune, haemolytic anaemia. *Br J Haematol.* 2017;177(2):208-20.

Ruptured Visceral Artery Aneurysms: A Deadly Cause of Epigastric Pain

Sara Bradley, BS*
Faith Quenzer, DO†
Micah Wittler, DO†

*Western University of Health Sciences, College of Osteopathic Medicine of the Pacific, Pomona, California

†Desert Regional Medical Center, Department of Emergency Medicine, Palm Springs, California

Section Editor: Manish Amin, DO

Submission history: Submitted September 26 2018; Revision received December 21, 2018; Accepted January 23, 2019

Electronically published February 26, 2019

Full text available through open access at http://escholarship.org/uc/uciem_cpccem

DOI: 10.5811/cpccem.2019.1.41057

Visceral artery aneurysms (VAA) are rare, life-threatening disease processes that often affect the celiac, superior mesenteric, or inferior mesenteric arteries and their respective branches. The splenic, hepatic, superior mesenteric, and tripod celiac arteries are most commonly affected and have high rupture and mortality rates. This case describes splenic and celiac artery aneurysms in a patient that led to hemorrhagic shock and multisystem organ failure despite timely diagnosis and ligation. A brief review of the literature further elucidates the key risk factors in identifying patients with VAAs and their treatment course. [Clin Pract Cases Emerg Med. 2019;3(2):132-136.]

INTRODUCTION

Visceral artery aneurysms (VAA) are life-threatening and often require immediate intervention upon rupture. The arteries most commonly affected by VAAs are the following: hepatic, splenic, superior mesenteric, and the celiac. Each vessel has unique risk factors and epidemiologic characteristics that can help to narrow down which of the four may be involved. Risk of rupture and mortality rates of these vessels are high, especially in pregnancy. Computed tomographic angiography (CTA) is needed in conjunction with a thorough history and physical exam to help confirm the diagnosis. Operative management is done by open surgical repair, endovascular techniques, or laparoscopic surgery.

CASE REPORT

A 77-year-old, obese, Caucasian male presented to the emergency department (ED) with a sudden onset of lower chest and epigastric pain and sudden collapse after lifting a heavy object while working on his ranch. Per his wife, the patient was a previously healthy and active individual who had lost 50 pounds over the prior year on a diet and exercise regimen. The patient had a past medical history of gastroesophageal reflux disease, hyperlipidemia, diabetes, and hypertension. He was a former smoker from about age 15 to 60. The patient also had a history of daily alcohol use, which ended in his mid-forties.

Upon arrival to the ED, the initial vital signs revealed a blood pressure of 94/72 millimeters of mercury (mmHg), heart rate of 89 beats per minute (bpm), respiratory rate of 16 breaths per minute (BPM), and oxygen saturation of 100% on room air. On physical exam, the patient was somnolent but easily aroused, pale, and in severe distress. The cardiovascular exam revealed that the heart had regular rate and rhythm without murmurs. His lungs were clear and without wheezes, rhonchi, or rales. His abdominal exam was notable for a soft, distended, moderately tender epigastric region but without rebound or guarding. A pulsatile mass was not palpated and there were no abdominal bruits.

His initial complete blood count demonstrated a white count of $24.0 \times 10^9/L$, hemoglobin of 11,000 grams per liter, platelet count of $198 \times 10^9/L$, with 93% neutrophils. The comprehensive metabolic panel was unremarkable. The creatine phosphokinase and troponin were normal. Amylase and lipase were normal. An electrocardiogram (ECG) showed a sinus rhythm with no acute ST changes and a right bundle branch block, which was seen on a previous ECG.

The patient underwent a computed tomography (CT) angiogram of the chest and abdomen which showed 8.0 centimeter (cm) x 6.0 cm x 6.5 cm aneurysm in the expected location of the celiac artery and splenic artery with extensive

stranding of the surrounding fat, representing active hemorrhage as seen on the sagittal abdominal CT (Images 1 and 2).

Within 30 minutes of arrival to our ED, the patient was in hypovolemic shock with hypotension (59/34 mmHg), tachycardia

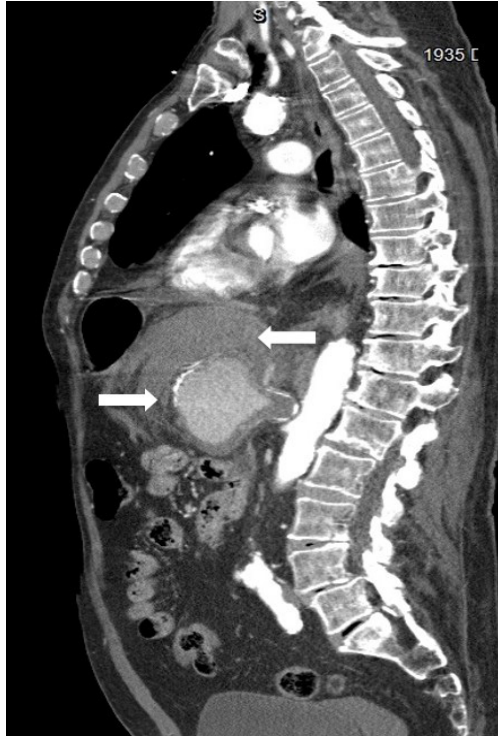

Image 1. Computed tomographic angiography of the chest and abdomen demonstrating active extravasation of the celiac artery and splenic artery aneurysm (rightward arrow) with extensive stranding (leftward arrow), representing active hemorrhage.

(142 bpm), and tachypnea (rate 26 BPM). The vascular surgeon was notified immediately and the patient was taken to the operating room within 45 minutes of arrival to undergo a ligation of the neck of the aneurysm. Upon arrival to the intensive care unit, the patient lost his pulses. He was unfortunately pronounced dead after unsuccessful heroic efforts.

DISCUSSION

VAA are those affecting the celiac, superior mesenteric, or inferior mesenteric arteries and their branches. These aneurysms are uncommon compared to aortic or iliac. Splenic (60%), hepatic (20%), superior mesenteric (5.9%) and tripod celiac (4%) are the most common arteries affected.¹ Visceral aneurysms have a low incidence rate between 0.1% and 0.2%, and a high rupture rate (25%) compared to aortic and iliac. Twenty-two percent of these aneurysms present as clinical emergencies, with a 70% mortality rate.² This is a rare case in which our patient had an aneurysm

CPC-EM Capsule

What do we already know about this clinical entity?

Visceral artery aneurysms (VAA) are rare and often affect the celiac, superior mesenteric, or inferior mesenteric arteries and their respective branches.

What makes this presentation of disease reportable?

Diagnosis of VAAs can be elusive due to the subtle presentation of symptoms that can mimic other diseases. However, when ruptured, they can be catastrophic.

What is the major learning point?

Ruptured VAA should be considered in the differential diagnosis in a patient with cardiovascular collapse and epigastric pain.

How might this improve emergency medicine practice?

An awareness and understanding of VAAs may potentially improve morbidity and mortality with early detection of the disease.

affecting both the celiac and splenic arteries. Incidence rates for celiac aneurysms are approximately 0.01%. There is no gender predilection, but some studies have indicated more frequent occurrence in males compared to females. Celiac aneurysms are commonly diagnosed in the fifth decade of life.³

These aneurysms are usually symptomatic at the time of diagnosis but can be asymptomatic as well, and are commonly found in association with other aneurysms, such as aortic, renal, popliteal, and femoral. The most common presenting symptoms are epigastric pain, back pain, nausea, abdominal distention, hematochezia, hematemesis, or a palpable pulsatile mass.⁴ The presentation can commonly mimic pancreatitis given the location of the vessel. The exact etiology of celiac aneurysms is unknown, but they are frequently associated with syphilis, tuberculosis, arteriosclerosis, medial degeneration, fibrous dysplasia, trauma, or mycotic lesions. Approximately 42% are idiopathic in nature.⁵

The risk of rupture for celiac aneurysms is about 13%.⁶ Ruptured celiac artery aneurysms have a mortality rate of approximately 80%, while the mortality rate of non-ruptured aneurysms ranges from 5-10%. Risk factors for rupture include pregnancy and increased diameter (>20 millimeters [mm]).^{4,5} Early diagnosis is crucial, as the emergency operative mortality rate is 40% vs elective (5%).⁵ Criteria for intervention in

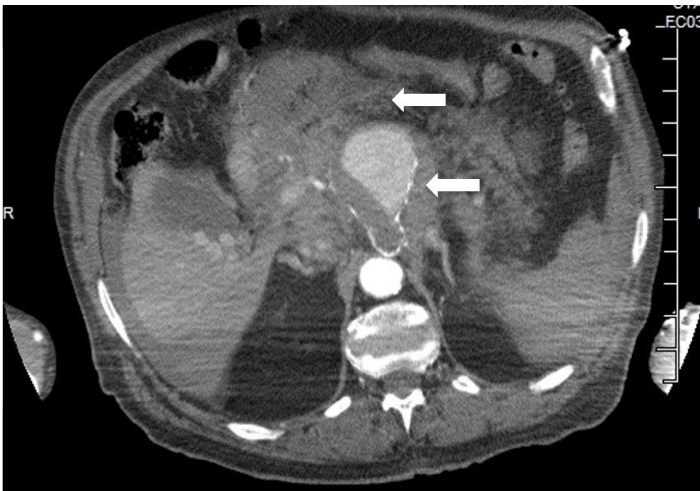


Image 2. Computed tomographic angiography of the abdomen in axial view demonstrating active extravasation (top arrow) of the celiac artery aneurysm (bottom arrow).

asymptomatic patients include the following: aneurysms greater than 2 cm in diameter with sensible operative risk; radiologic evidence of increasing aneurysm size; or a size greater than 3-4 times the original diameter of the vessel.⁶

Splenic artery aneurysms (SAA) are the most common true abdominal aneurysm behind aortic and iliac and are found four times more often in females than in males, occurring most commonly in patients in their fifth or sixth decade of life.⁷ Autopsy studies indicate an incidence of SAA between 0.1% and 10.4% and association with intra-abdominal aneurysms involving other visceral arteries. The reported rate of rupture is between 3% and 9.6%, with a mortality of 36% after rupture.⁸ The etiology of SAAs is unknown, but are frequently seen in association with portal hypertension, pregnancy, multiparity, arterial venous fistulas and malformations, atherosclerosis, hypertension, liver transplantation, and cirrhosis. Occurrence of SAA can be seen in 7%-17% of chronic liver disease patients with cirrhosis.⁹ Eighty percent of these aneurysms are found to have atherosclerotic changes and calcification.¹⁰ Incidence of rupture is seen most frequently in young, pregnant women, with an associated mortality of 75% and a fetal mortality of 95%. Patients with unruptured SAAs are commonly asymptomatic, and are diagnosed incidentally. The most common clinical complaint is epigastric abdominal pain, but patients can also present with splenomegaly, palpable pulsatile mass, hematochezia, melena, chest pain, or nausea.

Hepatic artery aneurysms (HAA) are the most commonly reported visceral pseudoaneurysm and have a mortality rate of 40%. They have an incidence rate of 0.02–4.0%, as well as a rupture rate of 80%.¹¹ HAAs are associated with atherosclerosis, cystic medial necrosis, trauma, mycotic embolization, trauma, Marfan syndrome, Klippel-Trenaunay syndrome, or giant cell arteritis.¹² Patients with aneurysms from nonatherosclerotic

etiologies are at higher risk of rupture. Fifty-five percent of these patients present with abdominal pain, and gastrointestinal hemorrhage occurs in up to 46%.¹³ Hemobilia, which is described by Quincke's triad (jaundice, biliary colic, and gastrointestinal bleeding) occurs in one-third of patients with HAA.¹¹ Surgical intervention is recommended when the aneurysm reaches greater than 20.0 mm.¹² Patients with superior mesenteric artery (SMA) aneurysms are usually symptomatic and can present with intermittent abdominal pain prior to rupture. These aneurysms commonly have mural thrombosis, which may ultimately result in acute mesenteric ischemia. SMAs can also invade into adjacent visceral organs, resulting in severe hemorrhage.¹³ SMAs are associated with higher dissection rates than the other visceral artery aneurysms, but only have a reported incidence of 0.06%.¹⁴ The rate of rupture for SMA aneurysms is 50%, where initial symptoms include hypovolemic shock, hemoperitoneum, or acute abdominal pain. These lesions are associated with high emergency surgery mortality rates (20-40%).¹⁵ Risk factors include arteriosclerosis, septic emboli, mycotic disease, pancreatitis, connective tissue disease, and trauma.¹⁶ It is important to quickly diagnose and treat these aneurysms to prevent serious complications including gastrointestinal or intraperitoneal hemorrhage, thrombosis, distal embolization, arterial spasm, arteriovenous fistula formation, secondary portal hypertension, bowel infarction, and death.¹⁵

An emergency physician's main role in the care of a patient with an acutely ruptured VAA is swift diagnosis and immediate surgical consultation. Prior to surgical intervention, standard resuscitative measures (insertion of two, large-bore intravenous catheters, cardiac monitoring, and supplemental oxygen) as well as preparation for administration of blood products should be done. Fluid resuscitation is needed if the patient is hemodynamically unstable; however, over-resuscitation has the potential to worsen active bleeding. Imaging modalities for diagnosis of VAA include ultrasound, CT with angiography, magnetic resonance imaging, and abdominal aortic arteriography being the gold standard. Point-of-care ultrasound can be useful to quickly visualize the aneurysm and associated free fluid inside the abdomen, especially for patients who are unstable and cannot undergo CT.¹⁷

Surgical intervention for VAAs varies and depends on the clinical presentation, etiology, the patient's comorbidities, and location of the aneurysm. The various techniques include open surgical repair, endovascular treatment, and laparoscopic surgery.¹¹ Indications for treatment of VAA include presence of pseudoaneurysm, symptomatic VAA, asymptomatic VAA greater than 2 cm, rapid expansion (greater than 0.5 cm per year), pregnancy, women of childbearing age, or liver transplantation.³ Notably, the threshold for intervention is significantly lower than that of aneurysms involving the aorta (greater than 5.5 cm). The summary table synthesizes the epidemiology associated with each type of VAA along with presenting symptoms, morbidity, and mortality (Table).

Table. Visceral artery aneurysms.

Vessel	Epidemiology	Risk factors	Presentation	Rate and risk for rupture	Mortality rate
Celiac artery	Males, 5th decade of life Incidence: 0.01%	Syphilis Tuberculosis Arteriosclerosis Medial degeneration Fibrous dysplasia Trauma Mycotic lesions	Epigastric abdominal pain Back pain Palpable pulsatile mass Hematochezia/ Melena Chest pain Nausea Mimics pancreatitis	Rate of rupture: 13% Risk increases with pregnancy and diameter >20mm	80%
Splenic artery	Females, 5th or 6th decade of life Incidence: 0.1% - 10.4%	Portal hypertension Pregnancy/ multiparity Atherosclerosis Arterial venous fistulas and malformation Hypertension Liver transplantation/ cirrhosis	Epigastric abdominal pain Splenomegaly Palpable pulsatile mass Hematochezia/ Melena Chest pain Nausea	Rate of rupture: 3-9.6% Most commonly ruptures in young pregnant women	36%
Hepatic artery	Males Incidence: 0.02– 4.0%	Arteriosclerosis Cystic medial necrosis Trauma Mycotic embolization Marfan syndrome Klippel-Trenaunay syndrome Giant cell arteritis	Abdominal pain Hematemesis Jaundice Portal hypertension	Rate of rupture: 80%	40%
Superior mesenteric artery	Males Incidence: 0.06%	Arteriosclerosis Septic emboli Mycotic disease Pancreatitis Connective tissue disease Trauma	Symptomatic prior to rupture - intermittent abdominal pain or acute mesenteric ischemia from thrombosis Once ruptured, hypovolemic shock, hemoperitoneum, and acute abdominal pain	Rate of rupture: 50% High emergency surgery	20-40%

Mm, millimeters.

CONCLUSION

Ruptured VAA is not often considered in the differential diagnosis of abdominal pain or, more importantly, in sudden collapse. When approaching a patient with signs of abdominal vascular catastrophe, differential diagnosis should include visceral as well as aortic aneurysms. VAAs are often not suspected initially in patients presenting with abdominal complaints, given their low prevalence, and this can delay diagnosis. However, in a patient with hypotension and epigastric abdominal pain, a life-threatening hemorrhage secondary to VAA should be suspected. One should be especially concerned for rupture in the pregnant or postpartum population. The patient in this case report had risk factors for VAA, including age, gender, past smoking and alcohol use, which may have predisposed him to atherosclerosis. Due to the high rate of rupture, the typical approach to VAA is early elective intervention, but in profound hypotension and suspected rupture, the patient will likely need emergent vascular surgery.

Documented patient informed consent and/or Institutional Review Board approval has been obtained and filed for publication of this case report.

Address for Correspondence: Sara Bradley, BS, Western University of Health Sciences, College of Osteopathic Medicine of the Pacific (COMP), 4961 Arrow Hwy #221, Montclair CA 91763. Email: sbradley2@westernu.edu.

Conflicts of Interest: By the CPC-EM article submission agreement, all authors are required to disclose all affiliations, funding sources and financial or management relationships that could be perceived as potential sources of bias. The authors disclosed none.

Copyright: © 2019 Bradley et al. This is an open access article distributed in accordance with the terms of the Creative Commons Attribution (CC BY 4.0) License. See: <http://creativecommons.org/licenses/by/4.0/>

REFERENCES

1. Arabia R, Pellicanò S, Siciliani R, et al. Splenic artery aneurysm and portal hypertension. Report of a case. *Minerva Med.* 1999;90(4):143-5.
2. Ferrero E, Ferri M, Viazzo A, et al. Visceral artery aneurysms, an experience on 32 cases in a single center: treatment from surgery to multilayer stent. *Ann Vasc Surg.* 2011;25(7):923-35.
3. Shanley CJ, Shah NL, Messina LM. Common splanchnic artery aneurysms: splenic, hepatic, and celiac. *Ann Vasc Surg.* 1996;10(3):315.
4. Saliou C, Kassab M, Duteille F. Aneurysm of the coeliac artery. *Cardiovasc Surg.* 1996;4(4):552-5.
5. Gupta R, Khanna SK, Chaudhary A, et al. Coeliac artery aneurysm: a case report. *Cardiovasc Surg.* 1996;4(4):550-2.
6. Syed M, Shaikh A, Neravetta S. Celiac artery aneurysm embolization by coil occlusion. *Ann Vasc Surg.* 2005;19(1):113-9.
7. Kenningham R, Hershman MJ, McWilliam F, et al. Incidental splenic artery aneurysm. *J R Soc Med.* 2002;95(9):460-1.
8. Stanley JC and Fry WC. Pathogenesis and clinical significance of splenic artery aneurysms. *Surgery.* 1974;76(6):898-909.
9. Moon DB, Lee SG, Hwang S, et al. Characteristics and management of splenic artery aneurysms in adult living donor liver transplant recipients. *Liver Transpl.* 2009;15(11):1535-41.
10. Dave S, Reis E, Hossain P, et al. Splenic artery aneurysm in 1990s. *Ann Vasc Surg.* 2000;14(3):223-9.
11. Gehlen J, Heeren P, Verhagen PF, et al. Visceral artery aneurysms. *Vasc Endovasc Surg.* 2012;45(8):681-7.
12. Bueschel P, Meyer F, Weber M, et al. Rare aneurysm of the hepatic artery with overlap to the gastroduodenal artery in very uncommon coincidence with occurrence of hepatomesenteric trunk. *Wien Klin Wochenschr.* 2013;125(3-4):111-4.
13. Schweigert M, Adamus R, Stadhuber RJ et al. Endovascular stent-graft repair of a symptomatic superior mesenteric artery aneurysm. *Ann Vasc Surg.* 2011;25(6):841.e5-8.
14. Luan JY and Li X. Computed tomography imaging features and classification of isolated dissection of the superior mesenteric artery. *Eur J Vasc Endovasc Surg.* 2013;46(2):232-5.
15. Olsen AB, Ralhan T, Harris JH, et al. Superior mesenteric artery pseudoaneurysm after blunt abdominal trauma. *Ann Vasc Surg.* 2013;27(5):674-8.
16. Choo C and Yen H. Unusual upper gastrointestinal bleeding: ruptured superior mesenteric artery aneurysm in rheumatoid arthritis. *World J Gastroenterol.* 2013;19(28):4630-2.
17. Lo WL and Mok KL. Ruptured splenic artery aneurysm detected by emergency ultrasound-a case report. *Crit Ultrasound J.* 2015;7(1):26.

Acute Angle-Closure Glaucoma Secondary to a Phakic Intraocular Lens, an Ophthalmic Emergency

Arian Frost, BA*

Daniel J. Ritter, MD†

Alana Trotter, MD‡

Michael S. Pulia, MD, MS†

*University of Wisconsin-Madison, School of Medicine and Public Health, Madison, Wisconsin

†University of Wisconsin-Madison, School of Medicine and Public Health, BerbeeWalsh Department of Emergency Medicine, Madison, Wisconsin

‡University of Wisconsin-Madison, School of Medicine and Public Health, Department of Ophthalmology and Visual Sciences, Madison, Wisconsin

Section Editor: Rick A. McPheeters, DO

Submission history: Submitted October 23, 2018; Revision received January 23, 2019; Accepted January 30, 2019

Electronically published March 5, 2019

Full text available through open access at http://escholarship.org/uc/uciem_cpem

DOI: 10.5811/cpcem.2019.1.41399

Implantable collamer lenses (ICL) are phakic (natural lens remains in place) lenses that were first developed in the 1990s for correction of high myopia. The effectiveness and safety of ICLs are making them an increasingly popular option for vision correction in the myopic patient, competing with traditional options like glasses, contacts, and procedures such as laser-assisted in situ keratomileusis. Although generally safe, due to the position of the phakic ICL in the eye, pupillary block remains a rare but vision-threatening complication of ICL implantation. Pupillary block caused by phakic ICL is a serious complication that requires urgent recognition and intervention and is poorly described in emergency medicine literature. We describe a case of pupillary block five years after ICL implantation that was refractory to standard medical therapy, highlighting the importance of early diagnosis and referral for more definitive therapy. [Clin Pract Cases Emerg Med. 2019;3(2):137-139.]

INTRODUCTION

Implantable collamer lenses (ICL) are specialized refractive intraocular lenses used to correct high myopia. Made of specialized collagen copolymer, phakic ICLs are surgically implanted inside the eye, sitting between the iris and the natural lens. These artificial lenses were first implanted in 1993 and approved by the United States (U.S.) Food and Drug Administration in 2005. They have since undergone multiple revisions to minimize complications and to increase utilization and potential indications.¹ When they were first released, ICLs were commonly used for high and extreme myopia. Low and moderate myopia were primarily treated with procedures such as laser-assisted in situ keratomileusis (LASIK), which is a permanent solution not available to patients with dry eye or thin cornea. Studies have compared the two treatments and made a case that ICLs are more effective and safer in the treatment of all cases of myopia.^{1,2}

Although relatively safe, ICLs are placed in the ciliary sulcus, and without adequate pre-operative measurements

they carry the risk of pupillary block, inflammation, cataract formation, and intraocular hypertension. Overall, less than 1% of patients with ICLs experience serious, vision-threatening complications.³ These complications, however, are most commonly observed in the immediate and subacute postoperative period. A remote increase in intraocular pressure and pupillary block secondary to ICL implantation is not well documented. We present a case of acute angle-closure glaucoma secondary to pupillary block due to mechanical obstruction from an ICL five years after implantation.

CASE REPORT

A 29-year-old woman with high myopia and a history of bilateral ICLs placed five years previously presented to the emergency department (ED) with a chief complaint of headache and blurry vision in her right eye. The patient stated that the night prior to presentation she noted that her right eye was dilated. She also complained of light sensitivity and mild blurry vision. When she woke up the morning of presentation she noted a dull headache behind

her right eye, which she rated a 2/10 on a numeric pain scale. She reported trouble focusing on close-up text but denied other vision decline or diplopia. She denied neck pain, nausea, vomiting, fever, chills, numbness, or tingling. She denied recent trauma, visits to the chiropractor, or use of mydriatic medications. She had been evaluated by ophthalmology six days prior to presentation for similar symptoms and was found to have mild mechanical anisocoria. Given her minor symptoms at that time, it was felt that there was no need for intervention.

Initial examination in the ED revealed a marked anisocoria, with the right pupil larger than the left. The right pupil was mid-dilated and fixed at six millimeters (mm). There was appropriate constriction of the left pupil. The right conjunctiva was injected. Visual acuity was 20/30 in the right eye and 20/20 in the left eye. Intraocular pressure of the right eye was markedly elevated at 44 mm of mercury (Hg). Her remaining neurologic exam revealed no focal deficits. Ophthalmology was consulted. After examining her, they found a right eye with a round, fixed pupil, +1 injection, diffuse microcysts, a shallow anterior chamber, fixed, minor iris bombe, and confirmation of intraocular hypertension. Examination of the left eye demonstrated two peripheral patent iridotomies at 12 o'clock and 3 o'clock and intraocular pressure of 11 mmHg. The patient was diagnosed with acute pupillary block and was administered timolol, acetazolamide, and brimonidine, but the intraocular pressure remained elevated at 35 mmHg. The patient was discharged from the ED directly to an outpatient ophthalmology clinic for urgent procedural treatment of pupillary block.

The patient presented to the ophthalmology clinic and underwent a yttrium-aluminum-garnet laser peripheral iridotomy. The right eye was anesthetized with topical proparacaine and a single peripheral iridotomy was created in the temporal iris. Aqueous humor was visualized to flow through the ostomy from the posterior to anterior chamber and the iris bombe significantly flattened. Immediately post-procedure, topical brimonidine was administered and the intraocular pressure was measured at 17 mmHg. One hour after the procedure, the intraocular pressure was 13 mmHg. The patient was prescribed difluprednate four times daily and brimonidine/timolol twice daily for five days and scheduled for follow-up with ophthalmology in one week.

At one-week follow-up, the patient noted marked improvement of her symptoms. She did not note any further headaches or difficulty with vision. She did, however, note continued mild anisocoria in the dark, and examination confirmed 0.5-1mm right greater than left anisocoria. Due to the persistent anisocoria, the patient was referred to neuro-ophthalmology for further investigation. A neurologic etiology was not identified and the persistent anisocoria was felt to be mechanical. The patient returned

CPC-EM Capsule

What do we already know about this clinical entity?

Acute angle-closure glaucoma is a vision-threatening process that must be rapidly identified by emergency care providers.

What makes this presentation of disease reportable?

This report highlights an unusual case of acute angle-closure glaucoma secondary to a phakic intraocular lens that could have been missed without awareness of this potential complication.

What is the major learning point?

Acute angle-closure glaucoma is a potential complication of phakic intraocular lens implantation, which is increasingly being used to correct myopia.

How might this improve emergency medicine practice?

This report seeks to provide a diagnostic and therapeutic approach to an unusual case of acute angle-closure glaucoma due to phakic intraocular lens implantation.

to ophthalmology clinic several months after her initial presentation with a subsequent increase in her intraocular pressure and required an additional peripheral iridotomy. She continues to be followed by ophthalmology.

DISCUSSION

No matter its cause, acute angle-closure glaucoma is an ophthalmological emergency that often requires a high degree of suspicion from the emergency physician. Patients with acute angle-closure glaucoma often have onset of symptoms in low-light conditions due to pupillary dilation resulting in apposition of the iris and lens. This contact is termed pupillary block and results in obstruction of aqueous flow from the posterior chamber. The restricted aqueous flow generates pressure that displaces the iris forward (bombe), narrowing the anterior chamber angle and restricting aqueous drainage through the trabecular meshwork and Schlemm's canal. The resulting elevation

of intraocular pressure causes symptoms that include blurry vision with halos around bright objects, headache, and nausea and vomiting. Physical findings are typically unilateral and include an injected eye with a non-reactive and dilated pupil, and corneal haziness.⁴ Any of these symptoms warrants at least consideration of acute angle-closure glaucoma in the ED.

Angle-closure glaucoma requires prompt diagnosis and treatment to prevent irreversible vision loss. Complete examination of ocular complaints should always include measurement of intraocular pressure. A generally accepted range for normal intraocular pressure is 8-21 mmHg, whereas acute angle-closure glaucoma will have intraocular pressure over 30 mmHg.⁵ Medical therapy is aimed at relieving pupillary block and reducing additional aqueous humor production. These aims are initially achieved with a combination of a systemic carbonic anhydrase inhibitor as well as topical agents including steroids, beta-blockers, and alpha agonists. After one hour of treatment, topical pilocarpine can be added to constrict the pupil (miotic) and relieve the block. Keeping the patient supine and aggressively managing symptoms (pain, nausea and vomiting) to avoid spikes in intraocular pressure are also critical management steps. Definitive management of acute angle-closure glaucoma includes emergent referral for ophthalmologic evaluation and consideration of surgical iridotomy.^{6,7}

Acute pupillary block is a rare but serious vision-threatening complication of ICLs and is not well reported in the emergency medicine literature. Additionally, much of what is reported in the literature focuses on cases in the immediate postoperative timeframe.^{3,8,9} Evidence suggests the rate of pupillary block two years after ICL implantation was found to be between 0.1-3.2%.^{10,11} Medical management of increased intraocular pressure serves as an attempted bridge to lower the intraocular pressure in preparation for an iridotomy or other definitive surgical management.

CONCLUSION

The case presented describes an unusual complication of an ICL, delayed pupillary block and acute glaucoma five years after implantation. Given the increasing utilization of ICLs, emergency physicians should become familiar with this known complication to enhance early detection and emergent ophthalmology consultation for definitive management.

Documented patient informed consent and/or Institutional Review Board approval has been obtained and filed for publication of this case report.

Address for Correspondence: Michael S. Pulia, MD, MS, University of Wisconsin School of Medicine and Public Health, BerbeeWalsh Department of Emergency Medicine, 800 University Bay Drive, Suite 310 Madison, WI 53705. Email: mspulia@medicine.wisc.edu.

Conflicts of Interest: By the CPC-EM article submission agreement, all authors are required to disclose all affiliations, funding sources and financial or management relationships that could be perceived as potential sources of bias. The authors disclosed none.

Copyright: © 2019 Frost et al. This is an open access article distributed in accordance with the terms of the Creative Commons Attribution (CC BY 4.0) License. See: <http://creativecommons.org/licenses/by/4.0/>

REFERENCES

1. Wang X and Zhou X. Update on treating high myopia with implantable collamer lenses. *Asia Pac J Ophthalmol*. 2016;5(6):445-9.
2. Kamiy K, Igarashi A, Shimizu K, et al. Visual performance after posterior chamber phakic intraocular lens implantation and wavefront-guided laser in situ keratomileusis for low to moderate myopia. *Am J Ophthalmol*. 2012;153(6):1178-86.
3. Huang D, Schallhorn SC, Sugar A, et al. Phakic intraocular lens implantation for the correction of myopia: a report by the American Academy of Ophthalmology. *Ophthalmology*. 2009;116(11):2244-58.
4. Leibowitz HM. The red eye. *N Engl J Med*. 2000;343(3):345-51.
5. Pokhrel PK and Loftus SA. Ocular emergencies. *Am Fam Physician*. 2007;76(6):829-36.
6. Shields SR. Managing eye disease in primary care. Part 3. When to refer for ophthalmologic care. *Postgrad Med*. 2000;108(5):99-106.
7. Tarff A and Behrens A. Ocular emergencies. *Med Clin North Am*. 2017;101(3):615-39.
8. McCaughey MV, Mifflin T, Fenzl CR, et al. Pseudophacomorphic glaucoma along with pupillary block after Visian™ implantable collamer lens implantation for high myopia. *Open J Ophthalmol*. 2014;4(4):107-11.
9. Chan KC, Birchall W, Gray TB, et al. Acute angle closure after implantable contact lens insertion unresponsive to surgical peripheral iridectomy. *J Cataract Refract Surg*. 2008;34(4):696-9.
10. Zhou TA, Shen Y, Wang Y, et al. Mid-long term follow-up results in correction of extreme myopia by posterior chamber phakic intraocular lens. *Chinese Journal of Ophthalmology*. 2012;48(4):307-11.
11. Kohnen T, Kook D, Morral M, et al. Phakic intraocular lens: part 2: results and complications. *J Cataract Refract Surg*. 2010;36(12):2164-94.

Empagliflozin-induced Diabetic Ketoacidosis Unmasking a Type 1 Diabetes Diagnosis

Gretchen M. Ray, PharmD*

Chelsea Rodriguez, BIS[†]

Samantha M. Schulman, BA[†]

Preeyaporn Sarangarm, PharmD[‡]

Michelle Bardack, MD[§]

Matthew F. Bouchonville, MD[¶]

*The University of New Mexico College of Pharmacy, Department of Pharmacy Practice and Administrative Sciences, Albuquerque, New Mexico

[†]The University of New Mexico College of Pharmacy, Albuquerque, New Mexico

[‡]The University of New Mexico Hospitals, Department of Pharmacy, Albuquerque, New Mexico

[§]The University of New Mexico School of Medicine, Department of Family and Community Medicine, Albuquerque, New Mexico

[¶]The University of New Mexico School of Medicine, Department of Internal Medicine, Division of Endocrinology, Diabetes, and Metabolism, Albuquerque, New Mexico

Section Editor: John Ashurst, DO

Submission history: Submitted November 28, 2018; Revision received January 31, 2019; Accepted February 8, 2019

Electronically published March 5, 2019

Full text available through open access at http://escholarship.org/uc/uciem_cpchem

DOI: 10.5811/cpchem.2019.2.41795

Empagliflozin is a sodium glucose cotransporter-2 inhibitor that inhibits renal glucose reabsorption through an insulin-independent mechanism. This class of drugs is used in the management of type 2 diabetes. A 49-year-old female with type 2 diabetes treated with empagliflozin presented to the emergency department in diabetic ketoacidosis (DKA). This case report details the series of events leading to the diagnosis of drug-induced DKA, which led to a change in the patient's diagnosis from type 2 diabetes to type 1 diabetes. [Clin Pract Cases Emerg Med. 2019;3(2):140-143.]

INTRODUCTION

The treatment of diabetes has rapidly evolved with the introduction of novel agents such as the sodium glucose cotransporter-2 (SGLT2) inhibitors. In 2013, the United States (U.S.) Food and Drug Administration (FDA) approved the first SGLT2 inhibitor, canagliflozin, for the treatment of non-insulin-dependent type 2 diabetes mellitus (T2DM). Since that time, three additional agents, empagliflozin, dapagliflozin, and ertugliflozin, have begun to be marketed in the U.S. These agents are now included into the American Diabetes Association (ADA) treatment guidelines as one of six possible add-on pharmacologic agents to metformin.¹ SGLT2 inhibitors are effective for the treatment of T2DM as they inhibit renal glucose reabsorption through an insulin-independent mechanism, which in turn lowers glucose levels through increased urinary glucose excretion.² This drug class is also associated with a reduction in body weight, as well as reduced blood pressure, which is largely due to their natriuretic effect.² Additionally, two SGLT2 inhibitors,

empagliflozin and canagliflozin, have been shown to reduce rates of major adverse cardiac events in high cardiovascular-risk patients in the Empagliflozin, Cardiovascular Outcomes, and Mortality in Type 2 Diabetes trial and Canagliflozin and Cardiovascular and Renal Events in Type 2 Diabetes (CANVAS) trials.^{3,4} Accordingly, prescriptions for SGLT2 inhibitors have been on the rise, resulting in this class of medications being commonly encountered in the primary care and emergency department (ED) settings.⁵

Common side effects of this drug class include increased risk of urinary tract infections, genital mycotic infections, and volume depletion.¹ Both diabetic ketoacidosis (DKA) and euglycemic diabetic ketoacidosis (euDKA) have since also been identified as rare but serious adverse effects of the SGLT2 inhibitors, and in 2015 the FDA released a safety alert to the public about this concern.⁶ In contrast to the low rates of DKA observed in SGLT2 inhibitor users with type 2 diabetes, the risks are remarkably higher in those with type 1 diabetes.⁷ This distinction has prompted

a consensus statement by the American Association of Clinical Endocrinologists urging caution with the off-label use of SGLT2 inhibitors in patients with type 1 diabetes.⁸ We describe the case of a patient initially diagnosed with type 2 diabetes presenting in DKA in association with the use of an SGLT2 inhibitor.

CASE REPORT

A 49-year-old female presented to the ED after waking up with nausea and abdominal pain followed by multiple episodes of vomiting. Her past medical history included T2DM, diagnosed four years earlier, and hypertension. Antihyperglycemic medications at the time of presentation included insulin glargine 25 units subcutaneous once a day, exenatide 10 micrograms (mcg) subcutaneous twice a day, empagliflozin 25 milligrams (mg) once a day (started four months prior to admission), and metformin 1000 mg twice a day.

Pertinent laboratory values upon presentation to the ED included the following: hemoglobin A1C 10.5% (4.4-5.6%), glucose 251 mg/deciliter (dL) (60-100 mg/dL), chloride 93 millimols per liter (mmol/L) (98-111 mmol/L), carbon dioxide 12 mmol/L (20-30 mmol/L), anion gap 29 (6-14), c-peptide 0.1 nanogram per milliliter (ng/mL) (0.9-6.9 ng/mL), ketone beta-hydroxybutyrate > 2.0 mmol/L (0.02-0.27 mmol/L), serum osmolality 322 milliosmoles per kilogram (mOsmol/kg) (280-295 mOsmol/kg), lactate 2.7 mmol/L (0.4-2.0 mmol/L) and a urine analysis with abnormal glucose of 500 mg/dL and ketones 80 mg/dL, but otherwise unremarkable. She was diagnosed with DKA and admitted to the intensive care unit on intravenous hydration and insulin drip per institution protocol.

DKA resolved two days following admission and the patient was discharged. At discharge, no precipitating factor leading to her DKA had been identified during the hospitalization. There had been no evidence of infection or pancreatitis, and she was discharged on all home medications with an increase in her insulin glargine to 30 units once a day.

She was seen in her primary care clinic six days post-discharge. Additional laboratory values were drawn including glutamic acid decarboxylase (GAD) antibody, which was elevated > 250 units/mL (< 0.5 units/mL). Given that the empagliflozin had been initiated four months prior to her hospital admission and that she had been admitted with euDKA with a glucose level of only 251 mg/dL at presentation, at the primary care follow-up, it was determined that this was a case of SGLT2 inhibitor-induced DKA. She had been managed as a type 2 diabetic for four years, but her low c-peptide level and elevated GAD antibody drawn at this post-discharge follow-up appointment resulted in a change in diagnosis to type 1 diabetes from type 2. All non-insulin antihyperglycemic agents including the empagliflozin that precipitated the DKA were discontinued and she was placed on a basal plus bolus insulin regimen.

CPC-EM Capsule

What do we already know about this clinical entity?
Sodium glucose cotransporter-2 (SGLT2) inhibitors are commonly used for the management of type 2 diabetes. This drug class has a known, rare side effect of diabetic ketoacidosis (DKA).

What makes this presentation of disease reportable?
The SGLT2 inhibitor-induced DKA led to the unmasking of type 1 diabetes in a patient previously diagnosed with type 2 diabetes.

What is the major learning point?
DKA is a rare risk of the SGLT2 inhibitor drug class, and there are certain factors that may predispose the patient to this adverse event. In this case, the underlying risk was type 1 diabetes.

How might this improve emergency medicine practice?
Improve identification of potential drug-induced DKA and underlying risk factors that may predispose the patient to this adverse effect.

DISCUSSION

The ADA diagnostic criteria for DKA include hyperglycemia (blood glucose > 250 mg/dL), metabolic acidosis (arterial pH < 7.3 and serum bicarbonate < 18 mEq/L) and ketosis.⁹ Euglycemic DKA was originally described in the literature as severe ketoacidosis with a blood glucose level less than 300 mg/dL, but currently a more common definition is a blood glucose < 200 mg/dL.^{10,11} SGLT2 inhibitors have been hypothesized to lead to this condition as a result of glucosuria leading to a rapid reduction in plasma glucose levels.^{12,13} This reduction in plasma glucose leads to decreased insulin release from the beta cells, which then leads to stimulation of alpha cells and the increase in plasma glucagon concentrations further stimulating hepatic ketogenesis.^{12,13} These mechanisms of ketogenesis in combination with continued glucosuria lowering plasma glucose levels results in the presence of ketone bodies in the setting of normal glucose levels.¹³ A total of 73 cases of SGLT2 inhibitor-related ketoacidosis were identified during a review of the FDA Adverse Event Reporting System database from March 2013 to May 2015. All patients required hospitalization or treatment in the ED, and many cases were complicated by a delayed diagnosis due to the low blood glucose levels on presentation.⁶

The SGLT2 inhibitors have also been studied for use in patients with type 1 diabetes.¹⁴⁻¹⁶ Their insulin-independent mechanisms offer an attractive and likely effective option as an add-on to insulin therapy. It has been hypothesized that patients with autoimmune type diabetes (latent autoimmune diabetes of adulthood, or type 1 diabetes) would be at greater risk of DKA in the setting of SGLT2 inhibitor therapy given their lack of endogenous insulin production leading to inability to overcome the SGLT2 inhibitor-induced increase in glucagon, thus leading to the setting of unsuppressed hepatic ketogenesis.¹⁷ A recent systematic review aimed to identify precipitating factors of SGLT2 inhibitor-induced DKA.¹³ In this review, two-thirds of all cases involved patients with T2DM; however, nine out of 25 of those individuals were later diagnosed with latent autoimmune diabetes of adulthood following resolution of their DKA.¹³ Additionally, an analysis of several cases of DKA in patients who were taking canagliflozin for type 2 diabetes in the CANVAS trial series found that six out of the 12 patients were diagnosed with autoimmune diabetes or tested positive for GAD65 antibodies after the development of DKA.¹⁷

Our case also describes a patient with presumed type 2 diabetes who, following her resolution of SGLT2 inhibitor-induced DKA, was further evaluated with antibody testing, and was revealed to have type 1 diabetes based on the presence of GAD antibodies. She had been treated as a type 2 diabetes patient for four years prior to her episode of DKA. Additionally, the causative agent, or precipitating factor, had not been identified at initial presentation to the hospital, or during the hospitalization. Although medications are not often identified as the precipitating factor for DKA, the SGLT2 inhibitors are being implicated with increased frequency in cases of DKA. In this case, the patient was discharged on the empagliflozin placing her at risk for a repeat event. The changes in diagnosis from type 2 to type 1 diabetes occurred after discharge at the primary care office.

CONCLUSION

We report a case of DKA secondary to the use of empagliflozin that resulted in a change in diagnosis from type 2 diabetes to type 1 diabetes. This case also highlights a situation in which the diagnosis of SGLT2 inhibitor-induced DKA was not made while the patient was in the hospital and she was discharged on the offending agent, thus placing her at risk for a repeat event. Such an event indicates the need for emergency and critical care providers to remain vigilant in identifying drug-induced causes of DKA.

Documented patient informed consent and/or Institutional Review Board approval has been obtained and filed for publication of this case report.

Address for Correspondence: Gretchen M. Ray, PharmD, The University of New Mexico College of Pharmacy, Department of Pharmacy Practice and Administrative Sciences, MSC09 5360, 1 University of New Mexico, Albuquerque, NM 87131. Email: gray@salud.unm.edu.

Conflicts of Interest: By the CPC-EM article submission agreement, all authors are required to disclose all affiliations, funding sources and financial or management relationships that could be perceived as potential sources of bias. The authors disclosed none.

Copyright: © 2019 Ray et al. This is an open access article distributed in accordance with the terms of the Creative Commons Attribution (CC BY 4.0) License. See: <http://creativecommons.org/licenses/by/4.0/>

REFERENCES

1. American Diabetes Association. 8. Pharmacologic approaches to glycemic treatment: *Standards of Medical Care in Diabetes—2018*. *Diabetes Care*. 2018;41(Supplement 1):S73-S85.
2. Vallon V and Thomson SC. Targeting renal glucose reabsorption to treat hyperglycaemia: the pleiotropic effects of SGLT2 inhibition. *Diabetologia*. 2017;60(2):215-25.
3. Zinman B, Wanner C, Lachin JM, et al. Empagliflozin, cardiovascular outcomes, and mortality in type 2 diabetes. *N Engl J Med*. 2015;373(22):2117-28.
4. Neal B, Perkovic V, Mahaffey KW, et al. Canagliflozin and cardiovascular and renal events in type 2 diabetes. *N Engl J Med*. 2017;377(7):644-57.
5. Hankins M, Tsai K, Kim J, et al. Early drug use of dapagliflozin prescribed by general practitioners and diabetologists in Germany. *Diabetes Res Clin Pract*. 2017;125:29-38.
6. Research C for DE. Drug Safety and Availability - FDA Drug Safety Communication: FDA revises labels of SGLT2 inhibitors for diabetes to include warnings about too much acid in the blood and serious urinary tract infections. Available at: <https://www.fda.gov/Drugs/DrugSafety/ucm475463.htm>. Accessed September 28, 2018.
7. Peters AL, Henry RR, Thakkar P, et al. Diabetic ketoacidosis with canagliflozin, a sodium-glucose cotransporter 2 inhibitor, in patients with type 1 diabetes. *Diabetes Care*. 2016;39(4):532-8.
8. Handelsman Y, Henry RR, Bloomgarden ZT, et al. American Association of Clinical Endocrinologists and American College of Endocrinology Position Statement on the Association of SGLT-2 Inhibitors and Diabetic Ketoacidosis. *Endocr Pract*. 2016;22(6):753-62.
9. Kitabchi AE, Umpierrez GE, Miles JM, et al. Hyperglycemic crises in adult patients with diabetes. *Diabetes Care*. 2009;32(7):1335-43.
10. Munro JF, Campbell IW, McCuish AC, et al. Euglycaemic diabetic ketoacidosis. *Br Med J*. 1973;2(5866):578-80.
11. Modi A, Agrawal A, Morgan F. Euglycemic diabetic ketoacidosis: a review. *Curr Diabetes Rev*. 2017;13(3):315-21.

12. Taylor SI, Blau JE, Rother KI. SGLT2 inhibitors may predispose to ketoacidosis. *J Clin Endocrinol Metab.* 2015;100(8):2849-52.
13. Burke KR, Schumacher CA, Harpe SE. SGLT2 inhibitors: a systematic review of diabetic ketoacidosis and related risk factors in the primary literature. *Pharmacotherapy.* 2017;37(2):187-94.
14. Henry RR, Rosenstock J, Edelman S, et al. Exploring the potential of the SGLT2 inhibitor dapagliflozin in type 1 diabetes: a randomized, double-blind, placebo-controlled pilot study. *Diabetes Care.* 2015;38(3):412-9.
15. Bell DSH. Case reports that illustrate the efficacy of SGLT2 inhibitors in the type 1 diabetic patient. *Case Rep Endocrinol.* 2015;2015:1-4.
16. Sands AT, Zambrowicz BP, Rosenstock J, et al. Sotagliflozin, a dual SGLT1 and SGLT2 inhibitor, as adjunct therapy to insulin in type 1 diabetes. *Diabetes Care.* 2015;38(7):1181-8.
17. Erondy N, Desai M, Ways K, et al. Diabetic ketoacidosis and related events in the canagliflozin type 2 diabetes clinical program. *Diabetes Care.* 2015;38(9):1680-6.

Double Steal Phenomenon: Emergency Department Management of Recurrent Transient Ischemic Attack

Amit R. Rawal, MD*
Collin Bufano, DO*
Omar Saeed, MD†
Asif A. Khan, MD‡

*North Florida Regional Medical Center, Department of Emergency Medicine, Gainesville, Florida

†University of Tennessee Health Science Center, Department of Internal Medicine, Memphis, Tennessee

‡North Florida Regional Medical Center, Department of Vascular and Interventional Neurology, Gainesville, Florida

Section Editor: Rick A. McPheeters, DO

Submission history: Submitted September 15, 2018; Revision received January 15, 2019; Accepted January 22, 2019

Electronically published February 13, 2019

Full text available through open access at http://escholarship.org/uc/uciem_cpccem

DOI: 10.5811/cpccem.2019.1.40960

Double steal phenomenon is a rare condition where occlusion of the innominate (brachiocephalic) artery leads to hemodynamic changes in which blood flow is shunted from the intracranial circulation down the right vertebral artery and subsequently up the right carotid and subclavian circulation. This is a case of a 67-year-old female presenting emergently with recurrent transient ischemic attacks due to double steal phenomenon. Emergency department recognition of the double steal phenomenon and large vessel occlusion by computed tomography angiogram of the head and neck allowed for early treatment, which was critical in avoiding irreversible cerebral infarction. [Clin Pract Cases Emerg Med. 2019;3(2):144-148.]

INTRODUCTION

Subclavian steal syndrome is a well-documented phenomenon in which right vertebral artery flow is reversed due to a prevertebral stenosis of the subclavian artery. This is contrasted by double subclavian steal phenomenon, which is considered even rarer and more critical, and occurs secondary to stenosis of the brachiocephalic (innominate) artery. This results in blood being “stolen” from the intracranial basilar artery circulation down the right vertebral artery, reconstituting in the right subclavian artery, and then the flow is subsequently again “stolen” from the right subclavian artery in a retrograde fashion up the right carotid artery. This is a case of a 67-year-old female who arrived to the emergency department (ED) with recurrent transient ischemic attacks (TIA) exacerbated by right arm exercise and change from supine positioning. The etiology was found to be innominate artery occlusion and resultant double steal phenomenon.

CASE REPORT

A 67-year-old female with history of chronic tobacco use, chronic obstructive pulmonary disease, hypertension, and hyperlipidemia, presented to the ED with symptoms of

TIA. The patient described the acute onset of left-sided facial weakness that waxed and waned, recurring several times throughout the day, and lasting 2-3 minutes at a time. The left facial weakness was also associated with mild, left-arm weakness and “clumsiness” involving fine motor function of her left hand. She noted lightheadedness but denied leg weakness, headache, visual changes, chest pain or shortness of breath. She also noted that symptoms were brought on by use of her upper extremities and when she changed her body position from lying to sitting. She denied any similar symptoms previously or stroke history. Of note, she noticed a rapid improvement in her symptoms to resolution just prior to ED presentation.

On examination, her blood pressure (BP) was 183/86 millimeters of mercury (mmHg). She was awake, alert, oriented, and able to describe a detailed history. Her cranial nerves were intact, motor strength was 5/5 bilaterally, and fine motor movements in both her hands were normal. There was no ataxia, extraocular muscle dysfunction, or indication of posterior circulation involvement.

Just after her initial asymptomatic presentation to the ED, her symptoms recurred when her systolic BP dropped by 20 mmHg upon standing from a supine position. Emergent

computed tomography angiogram (CTA) of the head and neck demonstrated a severe flow-limiting lesion of the innominate artery (Image 1). Further investigation with magnetic resonance imaging demonstrated decreased signal intensity within the right internal carotid artery at the cavernous sinus and petrous segments, a finding that potentially represented slow flow (Image 2).

The patient subsequently underwent emergent cerebral angiogram, which demonstrated occlusion of the proximal

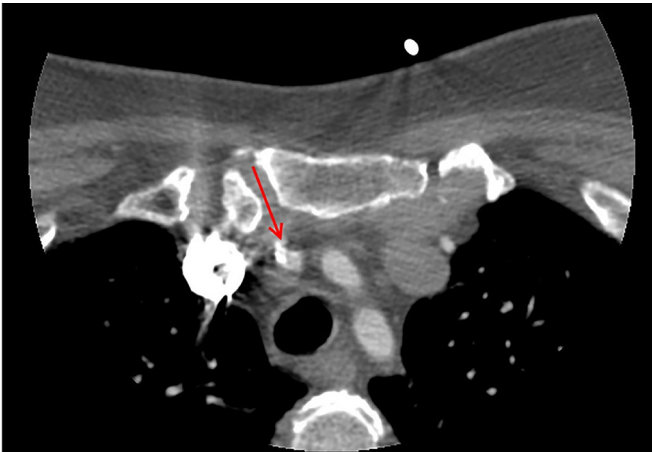


Image 1. Computed tomography angiography of the neck showing a calcified flow restricting lesion (red arrow) at the origin of the innominate artery.

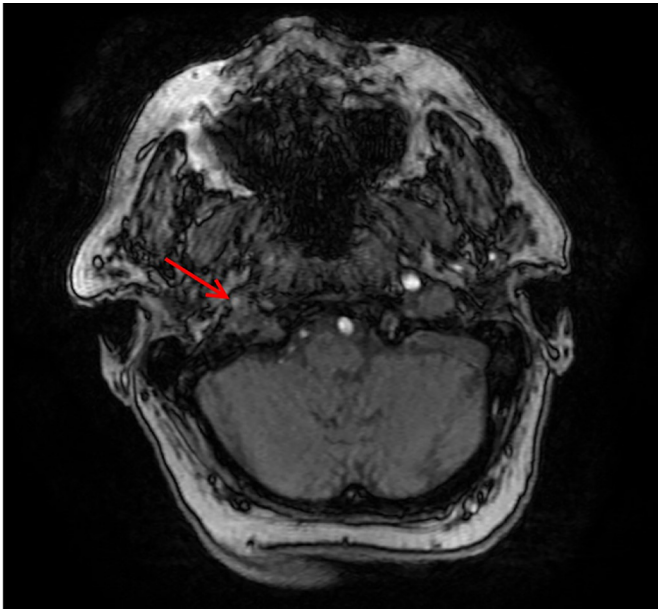


Image 2. Magnetic resonance angiography of the head showing decreased contrast intensity in the right carotid artery (red arrow) compared to the left.

CPC-EM Capsule

What do we already know about this clinical entity?

Double subclavian steal syndrome is a result of an occlusion in the innominate artery and causes hemodynamic flow changes in the right vertebral and carotid arteries, leading to neurologic deficits.

What makes this presentation of disease reportable?

This case was unique due to the recurrence of focal neurologic deficits that were precipitated by arm movement, blood pressure changes, and position changes.

What is the major learning point?

Computed tomography angiogram (CTA) of head and neck should be considered in the emergency department (ED) for evaluation of patients with neurologic symptoms that are recurrent, positional, or recur with labile pressures.

How might this improve emergency medicine practice?

This will hopefully encourage ED practitioners to have a low threshold for CTA on a subtype of neurologic patients to hasten diagnosis and prevent further ischemic events.

innominate artery (Image 3) at the aortic arch with resultant left to right vertebral artery steal phenomenon supplying the right subclavian artery (Image 4). The distal brachiocephalic artery flow was reconstituted via the subclavian artery and secondary steal phenomenon occurred into the right common carotid artery, causing delayed flow to the right cerebral hemisphere (Image 5).

The patient was maintained on a norepinephrine bitartrate infusion to increase BP, and her symptoms subsequently resolved. The symptoms recurred when she was positioned supine, but upon being placed in the Trendelenburg position her symptoms again resolved. The patient was therefore maintained with systolic BP goals between 160 and 210 mmHg. She remained asymptomatic during this period of elevated BP management. For definitive care, she underwent elective left carotid to right carotid “necklace” bypass surgery with complete and permanent resolution of her symptoms.

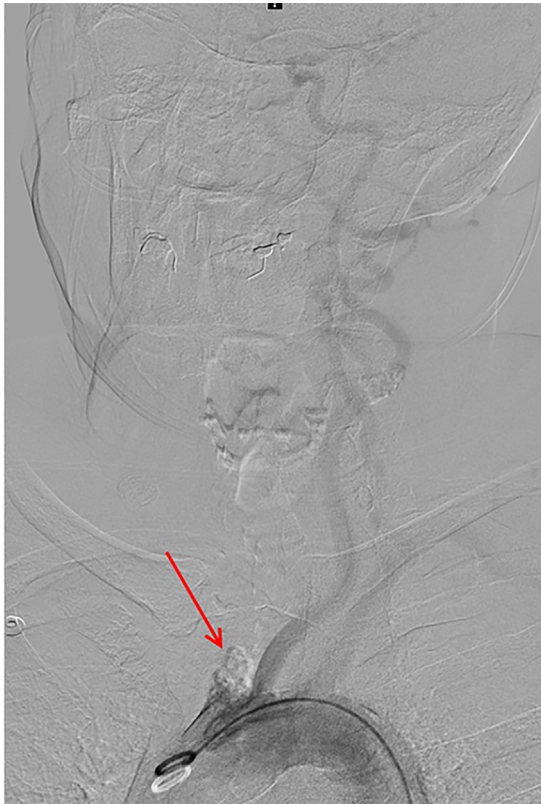

Image 3. Aortic arch angiography demonstrated occlusion of the brachiocephalic artery (red arrow).

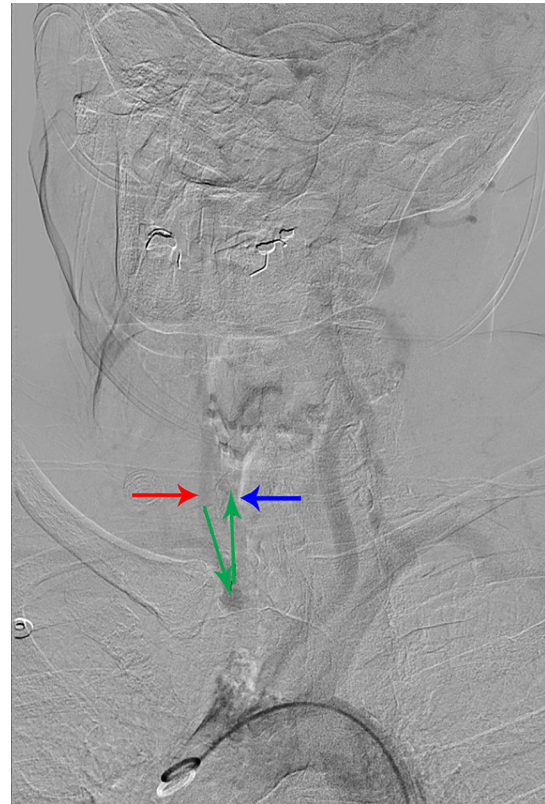


Image 5. Percutaneous angiography demonstrating reconstitution of the brachiocephalic artery distal to the occlusion with secondary steal of perfusion (green arrows) from the vertebral artery (red arrow) up the right common carotid (blue arrow).

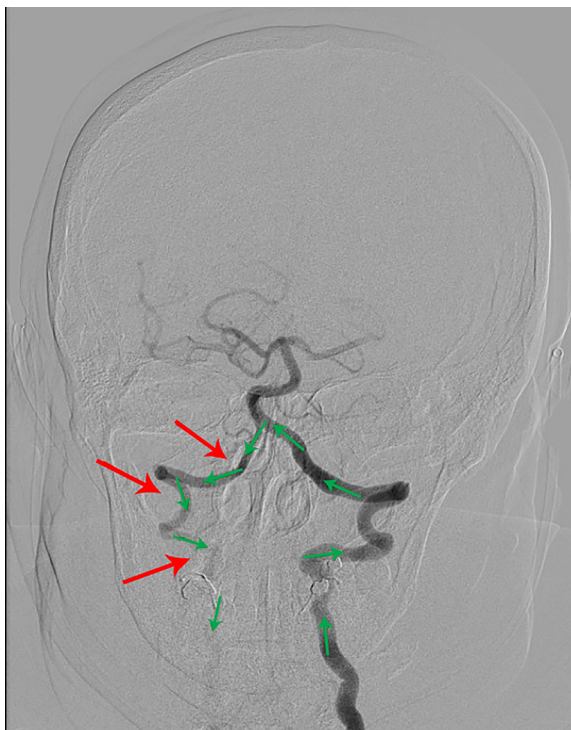


Image 4. Percutaneous angiography demonstrating contrast, and thus perfusion (green arrows), being stolen from the left vertebral artery to the right vertebral artery (red arrows).

DISCUSSION

Double steal phenomenon is caused by occlusion of the innominate artery. This results in hypoperfusion of the right carotid, subclavian and vertebral circulation, putting patients at risk of both posterior and anterior circulation ischemic events (Figure).^{1,2} Therefore, early diagnosis with CTA is critical. An ED evaluation of a subtype of TIAs (recurrent TIAs, positional TIAs, and TIAs that recur with labile blood pressures) to include CTA of the head and neck is warranted to identify lesions requiring emergent management.³ In this case, the double steal-inducing lesion at the origin of the brachiocephalic trunk resulted in weakness of the left face, hand and arm, as well as presyncope and dizziness.⁴

One of the more interesting aspects of the presentation was the positional nature of the symptoms, which resolved with induced hypertension. Additional signs and symptoms of innominate artery disease depend on degree of stenosis and acute changes in BP. Severe to near-total occlusion can cause additional symptoms that can originate from the vertebrobasilar circulation (vertigo, ataxia, drop attack, diplopia, and blurred vision), to symptoms that are hemispheric in origin (amaurosis fugax, transient paresis, and even upper extremity ischemia).⁵

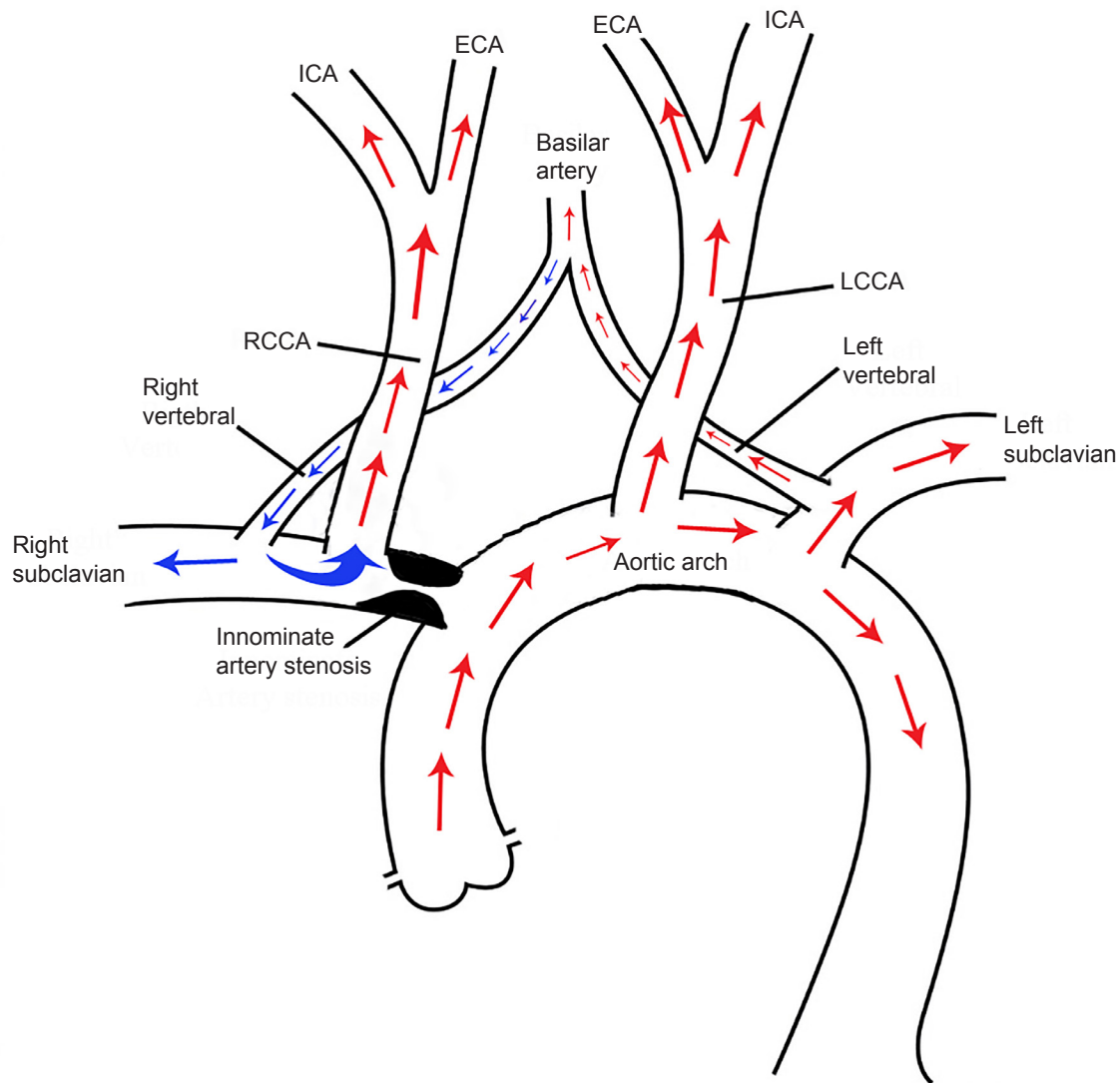


Figure. Schematic diagram demonstrating double steal phenomenon with retrograde blood flow from right vertebral artery to both right subclavian artery and the right common carotid artery (blue arrows).

RCCA, right common carotid artery; ICA, internal carotid artery; ECA, external carotid artery; LCCA, left common carotid artery.

CONCLUSION

Symptomatic patients with double steal phenomenon can present with persistent focal neurological deficits, TIAs, recurrent syncopal episodes, and dizziness. Definitive diagnosis occurs with CT and cerebral angiography. This case highlights the importance of early recognition in an ED setting with timely goals to include permissive hypertension or induced hypertension until definitive surgical repair can be performed.⁶

Documented patient informed consent and/or Institutional Review Board approval has been obtained and filed for publication of this case report.

Address for Correspondence: Amit R. Rawal, MD, North Florida Regional Medical Center, Department of Emergency Medicine, 1147 NW, 64th Terrace, Gainesville, FL 32605. Email: rawal.amit.r@gmail.com.

Conflicts of Interest: By the CPC-EM article submission agreement, all authors are required to disclose all affiliations, funding sources and financial or management relationships that could be perceived as potential sources of bias. The authors disclosed none.

Copyright: © 2019 Rawal et al. This is an open access article distributed in accordance with the terms of the Creative Commons Attribution (CC BY 4.0) License. See: <http://creativecommons.org/licenses/by/4.0/>

REFERENCES

1. Grant EG, El-Saden SM, Madrazo BL, et al. Innominate artery occlusive disease: sonographic findings. *AJR Am J Roentgenol.* 2006;186(2):394-400.
2. Esen K, Yilmaz C, Kaya O, et al. Double steal phenomenon secondary to innominate artery occlusion. *J Med Ultrason (2001).* 2016;43(3):435-8.
3. Menon BK and Demchuk AM. Computed tomography angiography in the assessment of patients with stroke/TIA. *Neurohospitalist.* 2011;1(4):187-99.
4. Filis K, Toufektzian L, Sigala F, et al. Right subclavian double steal syndrome: a case report. *J Med Case Rep.* 2008;2:392.
5. Grosveld WJ, Lawson JA, Eikelboom BC, et al. Clinical and hemodynamic significance of innominate artery lesions evaluated by ultrasonography and digital angiography. *Stroke.* 1988;19(8):958-62.
6. Latacz P, Simka M, Kazibudzki M, et al. Optimal interventional treatment in a patient with occlusion of the brachiocephalic trunk and left subclavian artery with "double" steal syndrome. *Postep Kardiol Inter.* 2015;11(4):341-3.

High Ascending Retrocecal Appendicitis in a Pediatric Patient Detected by Point-of-care Ultrasound

Takaaki Mori, MD
Teng S. Shin, MBBS
Gene Y.K. Ong, MBBS

KK Women's and Children's Hospital, Department of Emergency Medicine, Singapore

Section Editor: Rick A. McPheeters, DO

Submission history: Submitted November 18, 2018; Revision received January 31, 2019; Accepted February 8, 2019

Electronically published March 18, 2019

Full text available through open access at http://escholarship.org/uc/uciem_cpccem

DOI: 10.5811/cpcem.2019.2.41682

A 10-year-old male presented to our pediatric emergency department with progressive, colicky abdominal pain for one day, associated with fever and non-bilious vomiting. He had a guarded abdomen with sluggish bowel sounds. He was noted to have poor perfusion with tachycardia, which resolved with fluid resuscitation. Abdominal radiograph demonstrated the presence of a circular radiopaque structure at the right hypochondrial region. Point-of-care ultrasound revealed an ascending appendicitis with signs of perforation, which was unusually located just at the inferior edge of the liver, over the right hypochondrium. The patient was immediately admitted to the surgical intermediate care unit. Urgent laparoscopic appendectomy was successfully performed, and the child was discharged well. [Clin Pract Cases Emerg Med. 2019;3(2):149-152.]

INTRODUCTION

Abdominal pain in children is a common presentation to emergency departments (ED). The clinical approach to pediatric patients with abdominal pain in the ED requires a broad differential diagnosis. Pediatric patients with appendicitis often have a less-specific presentation, and perforation can occur rapidly.¹ Appendicitis occurring in less-typical anatomical positions, especially ascending retrocecal appendicitis, can be difficult to diagnose.² Missed or delayed diagnosis in perforated appendicitis can lead to serious morbidity and mortality.³ Pediatric appendicitis can present variably, but regardless of appendix location point-of-care ultrasonography (POCUS) can be useful.⁴

Published literature on the use of POCUS in the evaluation of pediatric abdominal pain and diagnosis of pediatric appendicitis is increasing.⁴ However, POCUS reports of ascending appendicitis in the pediatric population are uncommon. We present a case report of a pediatric patient with a high retrocecal appendicitis with perforation, which was detected by POCUS.

CASE REPORT

A previously healthy 10-year-old boy presented with an acute onset of periumbilical colicky abdominal pain of one day's

duration. It was rapidly progressive and became generalized. This was associated with tactile fever and two episodes of non-bilious vomiting. There was no associated diarrhea. The patient denied any recent sick contacts or overseas travel. At triage in the ED, he was febrile with a temperature of 38.2 degrees Celsius. He was tachycardic with a heart rate of 120 beats per minute and had a blood pressure of 90/61 millimeters (mm) of mercury. He had a respiratory rate of 20 breaths per minute and pulse oximetry was 99% on room air. His peripheral capillary refill time was delayed at three seconds. The triage nurses put him immediately in the resuscitation bay. Physical examination revealed an anicteric, lethargic child with a rigid abdomen and sluggish bowel sounds. Despite having generalized involuntary guarding of his abdomen, the child claimed the pain was "minimal." However, he was noted to be wincing maximally when his abdomen was palpated over his right hypochondrium. He was clinically in shock and was promptly given fluid resuscitation with a rapid bolus of 20 milliliters per kilogram of normal saline. He responded well to the fluids with improved peripheral perfusion. An upright chest radiograph did not reveal any free air under the diaphragm. A supine abdominal radiograph showed a circular radiopaque structure suggestive of calcification ("stone") over his right hypochondrium (Image 1).

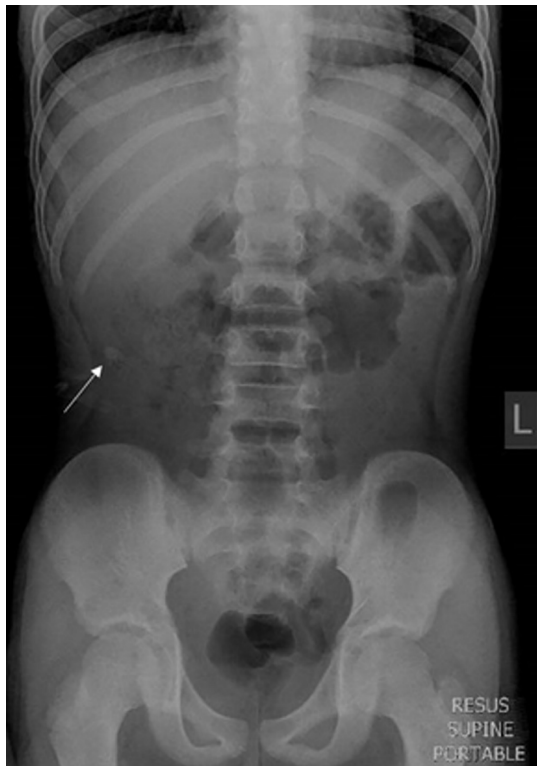

Image 1. Abdominal radiography showing a circular radiopaque structure (arrow) over the right hypochondrium.

POCUS was performed using Sonosite M-Turbo with a 2–5 megahertz curvilinear transducer. Visual cardiac contractility (parasternal long axis) showed a hyperkinetic left ventricle with good visual contractility. Initially, it was noted that his inferior vena cava was totally collapsed on spontaneous inspiration, which suggested that he was “volume depleted,” given his initial hemodynamic parameters. This improved post-fluid resuscitation. No gross abnormal hepatobiliary or renal abnormalities were noted. Unexpectedly, during the ultrasound examination of his right hypochondrium, a tubular structure measuring 14 mm in diameter with surrounding fluid at its end was noted just inferior to the liver’s surface (Image 2).

The tubular structure could be traced caudally to the cecum, suggesting a high ascending retrocecal appendicitis. The complex fluid and loss of the submucosal echogenic layer surrounding the appendix suggested perforation. Further interrogation showed a structure with acoustic shadowing posteriorly suggestive of an appendicolith (Image 3) in the clinical context.

Ultrasound also revealed features of ileus. Based on these findings, he was admitted to the surgical intermediate care unit with a diagnosis of perforated appendicitis even before any hematological and biochemical laboratory investigation

CPC-EM Capsule

What do we already know about this clinical entity?
The clinical approach to unwell pediatric patients with abdominal pain requires a broad differential diagnosis. Pediatric appendicitis may be rapidly progressive and present atypically.

What makes this presentation of disease reportable?
There is a paucity of literature on the use of emergency department (ED) point-of-care ultrasound (POCUS) in the diagnosis of ascending appendicitis in the pediatric population.

What is the major learning point?
ED POCUS may provide critical clinical information and facilitate the evaluation and expedite management of atypically located, perforated appendicitis in children.

How might this improve emergency medicine practice?
Ascending appendicitis is notoriously difficult to diagnose, especially in children. ED POCUS should be considered as part of the clinical evaluation, especially in unwell pediatric patients.

results were made available. After initiating intravenous antibiotics, the surgeons elected to obtain an urgent radiology abdominal ultrasound, which confirmed the findings of the initial POCUS. Soon after, he underwent an uneventful urgent laparoscopic appendectomy. Intraoperatively, surgical examination found that the cecum and appendix were unusually high, in close proximity to the liver’s inferior surface. The retrocecal appendix was noted to be inflamed with mid-shaft perforation. The base of the appendix was healthy. There was spillage of a fecolith into the paracolic gutter, with minimal fluid in the pelvis. Some adhesions were noted between the small bowel and abdominal wall. The rest of bowel, liver, and gallbladder were normal. Post-appendectomy, he was discharged well after a five-day hospitalization.

DISCUSSION

This case report demonstrates the clinical utility of POCUS to detect and expedite the management of a rapidly progressive appendicitis with an unusual anatomical location, in a stoic child with a potentially misleading abdominal

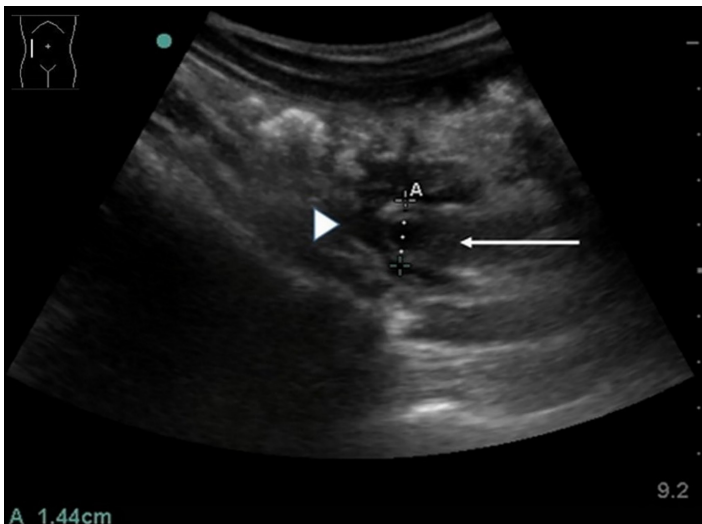


Image 2. Point-of-care ultrasonography of the abdomen over the right hypochondrium demonstrated a dilated appendix (arrow) measuring 14.4 millimeters (A) with a surrounding rim of complex hypoechoic fluid (arrowhead), suggesting perforation.

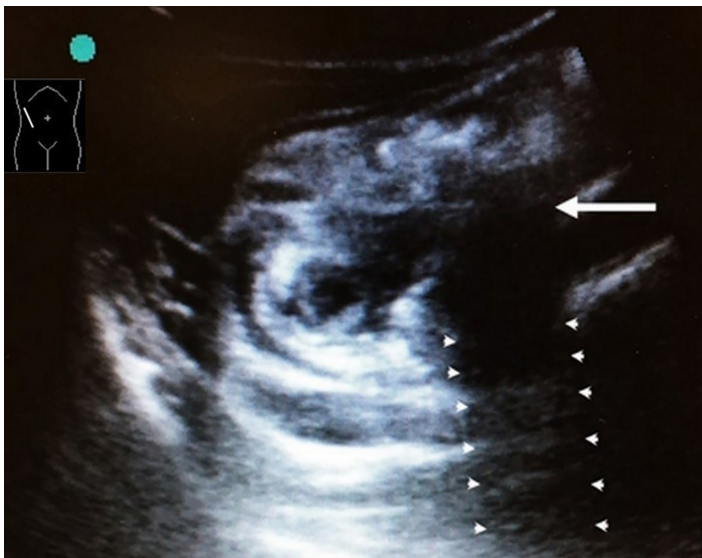


Image 3. An object (arrow) within the dilated appendix with acoustic shadowing posteriorly (arrowheads) suggestive of an appendicolith.

radiograph. His abdominal radiograph showed a “stone” over his right hypochondrium, which by location would usually indicate a gallbladder or renal stone. This “stone,” in retrospect, was a high appendicolith.

Unlike the ascending colon, the cecum and appendix are mobile and can vary in anatomical position. The appendix can be located in all directions in the pelvic cavity, with

the most prevalent anatomical site of the appendix being at the descending peritoneal and retrocecal area.⁵ Therefore, presenting symptoms and signs of acute appendicitis depend greatly on the location of the appendix. Approximately half of the observational studies and case reports of ascending retrocecal appendicitis had atypical presentations with the pain located in either the right flank or hypochondrium, which contributed to initial misdiagnosis and delays in management in this time-sensitive condition.⁶ Most patients required the need for abdominal computed tomography (CT) for diagnosis.

Some authors advocate a right lower quadrant ultrasound for screening of pediatric appendicitis.⁷ While this is a “higher-yield” initial approach, a more systematic abdominal ultrasound surveillance is recommended if the appendix is not visualized during the initial screen. The findings of periappendiceal fluid or abscess, an intraluminal appendicolith, and loss of the submucosal echogenic layer of the appendix were associated with perforation.⁷⁻⁹ Prompt diagnosis of perforation is essential for optimal patient outcome. This case report illustrates the clinical value of POCUS to promptly diagnose and expedite the patient’s management despite the unusual clinical presentation.

While abdominal CT with contrast remains the classic gold standard to diagnose acute appendicitis, the principle of minimizing radiation exposure in the pediatric population should be strongly advocated.¹⁰ Ultrasound is an important imaging tool with high diagnostic sensitivity and specificity of 98% to detect appendicitis when performed by radiologists.¹¹ With improved training for both adult and more recently pediatric emergency specialists, the clinical scope and utility of POCUS to diagnose and facilitate decision-making and management in pediatric appendicitis is also increasing.^{4,12} Benabbas et al., in a 2017 meta-analysis on the evaluation of pediatric appendicitis, reported ED POCUS to have a sensitivity of 86% and specificity of 91%.⁴

CONCLUSION

This was an uncommon case of a perforated appendicitis in a child whose appendix was located just inferior to the liver. Physicians should be aware of atypical presentations of appendicitis in view of the variable anatomical positions of the appendix. POCUS can be a useful clinical adjunct to help differentiate surgical causes of abdominal pain, especially those with atypical presentations of appendicitis in the pediatric population.

Documented patient informed consent and/or Institutional Review Board approval has been obtained and filed for publication of this case report.

Address for Correspondence: Gene Y.K. Ong, MBBS, KK Women's and Children's Hospital, Department of Emergency Medicine, 100 Bukit Timah Road, Singapore 229899. Email: geneong@yahoo.com.

Conflicts of Interest: By the CPC-EM article submission agreement, all authors are required to disclose all affiliations, funding sources and financial or management relationships that could be perceived as potential sources of bias. The authors disclosed none.

Copyright: © 2019 Mori et al. This is an open access article distributed in accordance with the terms of the Creative Commons Attribution (CC BY 4.0) License. See: <http://creativecommons.org/licenses/by/4.0/>

REFERENCES

1. Goldman RD, Carter S, Stephens D, et al. Prospective validation of the pediatric appendicitis score. *J Pediatr*. 2008;153(2):278-82.
2. Ong EM and Venkatesh SK. Ascending retrocecal appendicitis presenting with right upper abdominal pain: utility of computed tomography. *World J Gastroenterol*. 2009;15(28):3576-9.
3. Hall MJ, DeFrances CJ, Williams SN, et al. National Hospital Discharge Survey: 2007 summary. *Natl Health Stat Report*. 2010(29):1-20, 24.
4. Benabbas R, Hanna M, Shah J, et al. Diagnostic accuracy of history, physical examination, laboratory tests, and point-of-care ultrasound for pediatric acute appendicitis in the emergency department: a systematic review and meta-analysis. *Acad Emerg Med*. 2017;24(5):523-51.
5. Lee JH, Jeong YK, Park KB, et al. Operator-dependent techniques for graded compression sonography to detect the appendix and diagnose acute appendicitis. *AJR Am J Roentgenol*. 2005;184(1):91-7.
6. Meyers MA and Oliphant M. Ascending retrocecal appendicitis. *Radiology*. 1974;110(2):295-9.
7. Tseng P, Berdahl C, Kearl YL, et al. Does right lower quadrant abdominal ultrasound accurately identify perforation in pediatric acute appendicitis? *J Emerg Med*. 2016;50(4):638-42.
8. Xu Y, Jeffrey RB, Chang ST, et al. Sonographic differentiation of complicated from uncomplicated appendicitis: implications for antibiotics-first therapy. *J Ultrasound Med*. 2017;36(2):269-77.
9. Blumfield E, Yang D, Grossman J. Scoring system for differentiating perforated and non-perforated pediatric appendicitis. *Emerg Radiol*. 2017;24(5):547-54.
10. Pearce MS, Salotti JA, Little MP, et al. Radiation exposure from CT scans in childhood and subsequent risk of leukaemia and brain tumours: a retrospective cohort study. *Lancet*. 2012;380(9840):499-505.
11. Kessler N, Cyteval C, Gallix B, et al. Appendicitis: evaluation of sensitivity, specificity, and predictive values of US, Doppler US, and laboratory findings. *Radiology*. 2004;230(2):472-8.
12. Vieira RL, Hsu D, Nagler J, et al. Pediatric emergency medicine fellow training in ultrasound: consensus educational guidelines. *Acad Emerg Med*. 2013;20(3):300-6.

Symptomatic Vaginal Infection by *Neisseria meningitidis* Resulting in Meningitis with Septic Shock

Ryan Offman, DO*†
Elissa Boggs, DO*†
Adam Gwizdala, Pharm D*†

*Mercy Health-Muskegon, Department of Emergency Medicine, Muskegon, Michigan
†Michigan State University College of Osteopathic Medicine, Department of
Osteopathic Medical Specialties, East Lansing, Michigan
‡Mercy Health-Muskegon, Department of Pharmacy, Muskegon, Michigan

Section Editor: John Ashurst, DO

Submission history: Submitted November 24, 2018; Revision received February 11, 2019; Accepted March 4, 2019

Electronically published March 27, 2019

Full text available through open access at http://escholarship.org/uc/uciem_cpccem

DOI: 10.5811/cpcem.2019.3.41750

The most common infectious etiologies of vaginitis include Gardnerella bacterial vaginosis, candidiasis, and trichomoniasis. A few case reports describe symptomatic infection with *Neisseria (N) meningitidis*, an organism with potential for causing systemic disease with a high rate of morbidity and mortality. We describe a patient who presented with fulminant meningitis secondary to symptomatic vaginitis in which *N. meningitidis* was cultured. Due to the potential for significant morbidity and mortality as demonstrated by this case report, knowledge of this entity may prompt physicians to aggressively treat patients with vaginal cultures that are positive for *N. meningitidis*. [Clin Pract Cases Emerg Med. 2019;3(2):153-155.]

INTRODUCTION

Vaginitis is a common diagnosis among women, and in 40-50% of cases, *Gardnerella vaginalis* is isolated. This is followed by candidiasis, which causes 20-25% of cases, Trichomoniasis causes 15-20% of cases, and non-infectious causes account for 5-10% of cases.¹ *Neisseria (N) meningitidis* has been isolated from the urogenital region of women with symptomatic vaginitis previously, although no current treatment recommendations exist.² Although a very rare isolate from the urogenital region, *N. meningitidis* has been documented to cause both self-limiting vaginitis, arthritis, and meningococemia.^{3,4} However, a literature search revealed no case reports of symptomatic vaginitis secondary to *N. meningitidis* leading to fulminant meningitis with septic shock.

Meningococemia is a rapidly progressive infection mostly seen in young, healthy individuals who live in crowded environments.⁵ In the United States (U.S.), there are about 1,000-3,000 new cases diagnosed each year, with a prevalence between 0.5 and 1.1 cases per 100,000 people, with an associated mortality rate of up to 53%.⁶ We present a case in which *N. meningitidis* was isolated from vaginal cultures during work-up for symptomatic vaginitis followed by classic *N. meningitidis* meningitis presenting with septic shock. Recognition and treatment of *N. meningitidis* from uncommon sources may require more aggressive treatment than previously thought.

CASE REPORT

A 72-year-old female with a past medical history of hypertension presented to the emergency department (ED) with one day of generalized weakness, headache and rash. Review of her medical history revealed that she presented to her primary care physician with complaints of vaginal discharge two weeks prior to her presentation to the ED. Despite treatment with metronidazole, symptoms persisted prompting a speculum exam and vaginal cultures obtained by primary care physician five days prior to her ED encounter. These returned positive for *N. meningitidis*. At the time of presentation, she had not followed up for those results and therefore had no further treatment. The patient had been in her normal state of health until the previous evening when she described general malaise and fell asleep early. Her husband stated that she also slept much later than usual and when he tried to wake her, she seemed lethargic. Review of systems was otherwise negative.

Initial vital signs revealed a temperature of 101.7 degrees Fahrenheit, a pulse of 120 beats per minute, respiratory rate of 24 breaths per minute, and a blood pressure of 107/49 millimeters of mercury. The patient was found to be ill-appearing and obtunded. She had nuchal rigidity and a diffuse, non-blanching, purpuric rash. Other than atrial fibrillation with a rapid ventricular response, the remaining physical exam was unremarkable.

Immediate concern for meningococemia prompted empiric vancomycin (20 milligrams per kilogram, intravenous [mg/kg, IV]), ceftriaxone (2 grams [g], IV), ampicillin (2 g IV), dexamethasone (10 mg IV), and an initial 2-liter (L) normal saline bolus. After an unremarkable non-contrast computed tomography of her head, a lumbar puncture was performed revealing turbid cerebral spinal fluid with a white blood cell count of 262 cells per millimeter cubed (mm^3) (0-5 cells/ mm^3), glucose of 28 mg per deciliter (dL) (40-70 mg/dL), and a protein of 155 mg/dL (15-45mg/dL). Gram stain showed many gram-negative diplococci. Her initial serum white blood cell count was 7.4 thousand cells/ mL^3 (4.0-10.0 cells/ mL^3) and the initial lactic acid was 8.1 millimoles per liter (mmol/L) (0.5-1.6 mmol/L). Despite aggressive fluid resuscitation, the patient rapidly decompensated requiring central line placement, intubation, and norepinephrine infusion.

The patient was admitted to the intensive care unit where she had persistent septic shock that required corticosteroid administration and cardiovascular support with norepinephrine, epinephrine, and vasopressin. Her hospital stay was further complicated by disseminated intravascular coagulopathy and ischemic hepatitis. Cultures from blood and cerebral spinal fluid grew *N. meningitidis*, which was sensitive to ceftriaxone. She received a seven-day course upon recommendation of infectious disease specialists. On hospital day 10, she was discharged to a long-term acute care facility with ischemic necrosis of the digits of her hands and feet bilaterally, which would later require operative intervention.

DISCUSSION

We present a rare case in which a patient presented with a seemingly innocuous presentation of vaginitis two weeks prior to development of meningitis with septic shock secondary to *N. meningitidis*. Vaginitis is often encountered in the ED, and emergency physicians must know appropriate treatment plans as well as proper follow-up on culture results obtained on prior emergency visits, or from outpatient physicians.

The most common infectious etiologies of vaginitis include Gardnerella bacterial vaginosis, candidiasis, and trichomoniasis.¹ Bacterial vaginosis is a polymicrobial infection with a predominance of *Gardnerella vaginalis* occurring when dominance of the normal flora is disrupted.⁷ While not a sexually transmitted disease, sexual activity and other lifestyle choices do play a role as risk factors include multiple sexual partners, lack of condom usage, cigarette smoking, and douching.^{8,9} Candidiasis is a fungal infection that occurs with disturbances in vaginal flora, vaginal pH or glycogen stores of the vaginal epithelial cells. Risk factors include treatment with systemic antibiotics, presence of menstrual blood or semen, hormone therapy (including oral contraceptives), pregnancy, immunosuppression, and diabetes mellitus.¹⁰ Sexual transmission is also possible.¹¹

CPC-EM Capsule

What do we already know about this clinical entity?
It is known that Neisseria (N) meningitidis can cause localized genitourinary infections and occasionally mild systemic illness.

What makes this presentation of disease reportable?
Although there have been cases of mild systemic illness secondary to N. meningitidis reported, infection leading to septic shock has never been described.

What is the major learning point?
Treatment of genitourinary infections secondary to N. meningitidis requires aggressive therapy and prompt follow up.

How might this improve emergency medicine practice?
Knowledge of this entity could prevent significant morbidity and mortality as emergency physicians are often tasked with following up on cultures.

Trichomoniasis is a sexually transmitted disease caused by the protozoan *Trichomonas vaginalis*. Incidence increases with age. It is more prevalent in lower socioeconomic classes, those with increased number of lifetime sexual partners, and earlier age of onset of sexual activity.¹² Up to 75-80% of infections can be asymptomatic, aiding its transmission.¹³ Treatment is imperative as trichomoniasis is associated with multiple pregnancy complications, pelvic inflammatory disease, and increased transmission of other sexually transmitted diseases such as human immunodeficiency virus (HIV).

Treatment of infectious vaginitis varies by clinical scenario. Bacterial vaginitis can be treated with oral metronidazole, clindamycin, or tinidazole. Topical regimens include metronidazole or clindamycin. It is recommended that all symptomatic pregnant patients be treated with oral metronidazole or clindamycin. Candida vaginitis can be treated by all of the azole class of antifungals, including single-dose fluconazole. Treatment for trichomoniasis consists of oral metronidazole or tinidazole with a single-dose regimen recommended for most patients including pregnant patients. Those with HIV or failed initial treatment will require a longer course.¹⁴

Meningitis secondary to *N. meningitidis* is usually seen in young, previously healthy individuals who live in crowded environments.⁵ *N. meningitidis* is usually isolated in the nasopharynx of these individuals before becoming aerosolized and infecting close contacts.⁶ There have been case reports of

N. meningitidis causing self-limited vaginitis, bacteremia, and arthritis after isolation from the genitourinary region. Our case demonstrates another case of symptomatic vaginitis from this organism; however, significant subsequent meningitis and septic shock ensued.

Despite a few case reports of *N. meningitidis* isolation from the urogenital region of women previously, no current treatment recommendations exist.² Although some of these reports showed spontaneous clearance, others describe empiric treatment with penicillin and amoxicillin yielding clearance of symptoms and subsequent negative cultures.^{4,15} However, resistance patterns have since changed; in the U.S. standard therapy against *N. meningitidis* generally consists of third-generation cephalosporins (e.g., cefotaxime, ceftriaxone). Resistance does not seem to have developed.¹⁶ Therefore, it seems reasonable to initiate therapy with these agents as well as obtain infectious disease consultation to help discern duration of treatment and ensure proper follow-up.

CONCLUSION

Emergency physicians are often tasked with following up on culture results obtained previously in the ED or as an outpatient. This case of an uncommon isolate from a genitourinary culture highlights the possibility for subsequent invasive infection. While no true guidelines exist, we have outlined the available case reports of other patients presenting with varying degrees of symptomatology. We believe it is prudent for physicians to treat these findings aggressively and to stress the importance of follow-up for clearance of this organism in the otherwise systemically well patient.

Documented patient informed consent and/or Institutional Review Board approval has been obtained and filed for publication of this case report.

Address for Correspondence: Ryan Offman, DO, Mercy Health-Muskegon, Department of Emergency Medicine, 1675 Leahy St. Suite 315A Muskegon, MI 49442. Email: Ryan.offman@mercyhealth.com

Conflicts of Interest: By the CPC-EM article submission agreement, all authors are required to disclose all affiliations, funding sources and financial or management relationships that could be perceived as potential sources of bias. The authors disclosed none.

Copyright: © 2019 Offman et al. This is an open access article distributed in accordance with the terms of the Creative Commons Attribution (CC BY 4.0) License. See: <http://creativecommons.org/licenses/by/4.0/>

REFERENCES

1. Paladine HL. Vaginitis: Diagnosis and treatment. *Am Fam Physician*. 2018;97(5):321-9.
2. Thangkhiew I, Drake SM, Walzman M, et al. Genital infections due to *Neisseria meningitidis*. *Genitourin Med*. 1990;66(4):305-6.
3. Keys TF, Hecht RH, Chow AW. Endocervical *Neisseria meningitidis* with meningococemia. *N Engl J Med*. 1971;285(9):505-6.
4. Karunakaran R, Ngeow YF, Mashor M. Isolation of *Neisseria meningitidis* from an unusual site. *Malays J Pathol*. 2002;24(2):103-5.
5. Takada S, Fujiwara S, Inoue T, et al. Meningococemia in adults: a review of the literature. *Intern Med*. 2016;55(6):567-72.
6. Hershey JH and Hitchcock W. Epidemiology and meningococcal serogroup distribution in the United States. *Clin Pediatr (Phila)*. 2010;49(6):519-24.
7. Hill GB. The microbiology of bacterial vaginosis. *Am J Obstet Gynecol*. 1993;169(2 pt 2):450-4.
8. Smart S, Singal A, Mindel A. Social and sexual risk factors for bacterial vaginosis. *Sex Transm Infect*. 2004;80(1):58-62.
9. Brotman RM, Klebanaoff MA, Nansel TR, et al. A longitudinal study of vaginal douching and bacterial vaginosis—a marginal structural analysis. *Am J Epidemiol*. 2008;168(2):188-96.
10. Goncalves B, Ferreira C, Alves CT, et al. Vulvovaginal candidiasis: epidemiology, microbiology and risk factors. *Crit Rev Microbiol*. 2016;42(6):905-27.
11. Boatto HF, Girao MJ, de Moraes MS, et al. The role of symptomatic and asymptomatic sexual partners in the recurrent vulvovaginitis. *Rev Bras Ginecol Obstet*. 2015;37(7):314-8.
12. Ness RB, Smith KJ, Chang CC, et al. Prediction of pelvic inflammatory disease among young, single, sexually active women. *Sex Transm Dis*. 2006;33(3):137-42.
13. Van Der Pol B, Williams JA, Orr DP, et al. Prevalence, incidence, natural history, and response to treatment of *Trichomonas vaginalis* infection among adolescent women. *J Infect Dis*. 2005;192(12):2039-44.
14. Centers for Disease Control and Prevention. 2015 Sexually Transmitted Diseases Treatment Guidelines. Available at: <https://www.cdc.gov/std/tg2015/tg-2015-print.pdf>. Accessed February 7, 2019.
15. Hagman M, Forslin L, Moi H, et al. *Neisseria meningitidis* in specimens from urogenital sites. Is increased awareness necessary? *Sex Transm Dis*. 1991;18(4):228-32.
16. Jorgensen JH, Crawford SA, Fiebelkorn KR. Susceptibility of *Neisseria meningitidis* to 16 antimicrobial agents and characterization of resistance mechanisms affecting some agents. *J Clin Microbiol*. 2005;43(7):3162-71.

Pediatric Ingestion of Multiple Button Batteries

Johnny Fong, MD*
Tony Zitek, MD*†

*University of Nevada, Las Vegas School of Medicine, University Medical Center of Southern Nevada, Department of Emergency Medicine, Las Vegas, Nevada
†Kendall Regional Medical Center, Department of Emergency Medicine, Miami, Florida

Section Editor: Steven Walsh, MD

Submission history: Submitted July 1, 2018; Revision received October 21, 2018; Accepted November 7, 2018

Electronically published February 20, 2019

Full text available through open access at http://escholarship.org/uc/uciem_cpccem

DOI: 10.5811/cpcem.2018.11.39538

[Clin Pract Cases Emerg Med. 2019;3(2):156-157.]

CASE PRESENTATION

A two-year-old male presented to the pediatric emergency department for possible foreign body ingestion. Two hours prior to arrival, the child was found with the packaging for 10 button batteries, but his mother was only able to find one battery. The patient had no symptoms. Physical exam was within normal limits. Radiographs (Image 1) showed six foreign bodies within the stomach and one distally.

DISCUSSION

Button battery ingestions are increasing in both frequency as well as in major or fatal outcomes.¹ A low threshold for imaging is important as 54% of fatalities are from misdiagnosis due to non-specific presentations.¹ Possible complications include perforations, fistula, strictures, hemorrhage, and death.² The National Capital Poison Center Button Battery Ingestion Triage and Treatment Guideline (National Button Battery Guideline) specifically addresses patient age, battery size and location, and symptoms; however, it does not specifically address ingestion of multiple button batteries.³

The National Button Battery Guideline was recently changed to include the immediate administration of oral honey. This update was based on a recent study showing both in vitro and in vivo protective effects of honey in button battery ingestion.⁴ Imaging is not required if a specific set of criteria are met; otherwise, radiographs should be obtained of the entire length of the gastrointestinal tract to locate the battery.³ The main considerations are whether the battery is in the esophagus, if a magnet was co-ingested, or if the patient is having any symptoms.³ In these cases, endoscopic removal is preferred; however, surgical removal may be necessary if the battery is beyond reach.³ Important consideration should also be given to delayed injuries after battery removal.³

This patient was admitted for observation, serial abdominal exams, and polyethylene glycol whole-bowel irrigation. Radiograph the next morning showed progression of the batteries (Image 2). Whole-bowel irrigation continued and

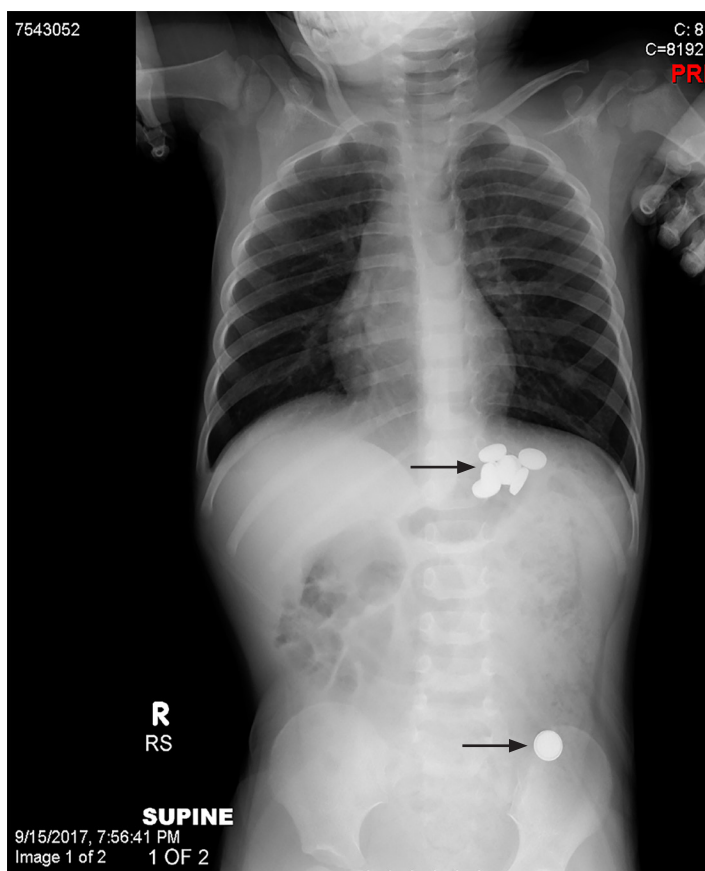


Image 1. Supine radiograph showing multiple button batteries (arrows) approximately four hours after ingestion.

eventually nine button batteries were passed rectally. Follow-up radiographs did not show any retained batteries.

Documented patient informed consent and/or Institutional Review Board approval has been obtained and filed for publication of this case report.

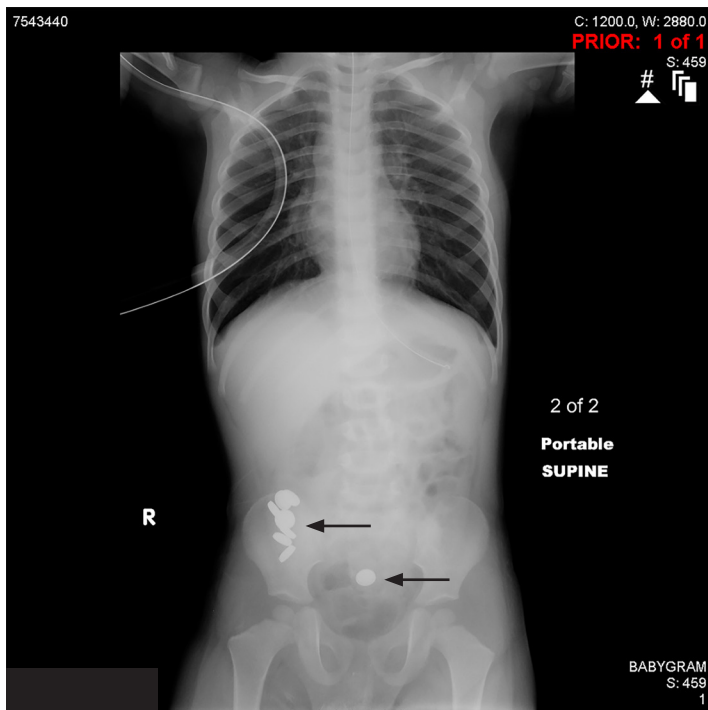


Image 2. Supine radiograph showing progression of multiple button batteries (arrows) after 14 hours of whole-bowel irrigation.

Address for Correspondence: Johnny Fong, MD, University of Nevada, Las Vegas School of Medicine, University Medical Center of Southern Nevada, Department of Emergency Medicine, 5298 Caprock Canyon Ave, Las Vegas, NV 89139. Email: johnny.fong.em@gmail.com.

Conflicts of Interest: By the *CPC-EM* article submission agreement, all authors are required to disclose all affiliations, funding sources and financial or management relationships that could be perceived as potential sources of bias. The authors disclosed none.

Copyright: © 2019 Fong et al. This is an open access article distributed in accordance with the terms of the Creative Commons Attribution (CC BY 4.0) License. See: <http://creativecommons.org/licenses/by/4.0/>

CPC-EM Capsule

What do we already know about this clinical entity?

The National Button Battery Guideline does not offer specific recommendations for multiple battery ingestions, an entity which is not well discussed in the existing literature.

What is the major impact of the image(s)?

Through providing initial and subsequent radiographs, this case aims to increase awareness of button battery ingestions, which is increasing in both frequency and major outcomes.

How might this improve emergency medicine practice?

This case offers a successful example of diagnosis and management of a multiple button battery ingestion through admission for whole-bowel irrigation with polyethylene glycol.

REFERENCES

1. Litovitz T, Whitaker N, Clark L, et al. Emerging battery-ingestion hazard: clinical implications. *Pediatrics*. 2010;125(6):1168-77.
2. Centers for Disease Control and Prevention (CDC). Injuries from batteries among children aged <13 years--United States, 1995-2010. *MMWR Morb Mortal Wkly Rep*. 2012;61(34):661-6.
3. National Capital Poison Center Button Battery Ingestion Triage and Treatment Guidelines. Available at: <https://www.poison.org/battery/guideline>. 2016. Accessed October 21, 2018.
4. Anfang RR, Jatana KR, Linn RL, et al. pH-neutralizing esophageal irrigations as a novel mitigation strategy for button battery injury. *Laryngoscope*. 2019;129(1):49-57.

Point-of-care Ultrasound Diagnosis of Cholecystitis vs. Adenomyomatosis

Esther Kim, BS
Rame Bashir, BS
Shadi Lahham, MD, MS

University of California-Irvine, Department of Emergency Medicine, Orange, California

Section Editor: Manish Amin, DO

Submission history: Submitted August 28, 2018; Revision received February 19, 2019; Accepted February 28, 2019

Electronically published March 27, 2019

Full text available through open access at http://escholarship.org/uc/uciem_cpce

DOI: 10.5811/cpcem.2019.2.40798

[Clin Pract Cases Emerg Med. 2019;3(2):158-159.]

CASE PRESENTATION

A previously healthy 26-year-old male presented with three days of right upper quadrant (RUQ) pain, worsened with food. Physical exam demonstrated a focal RUQ peritonitis, or positive Murphy's sign, with no rebound or guarding. Vital signs were stable, and labs showed no leukocytosis or metabolic derangements. Point-of-care ultrasound (POCUS) demonstrated a stone in the gallbladder neck, 4.6 millimeters anterior wall thickness, but no pericholecystic fluid (Video). Surgery was consulted and the patient was offered outpatient follow-up for biliary colic with adenomyomatosis. He returned to the emergency department (ED) the following day with persistent pain and underwent cholecystectomy for cholecystitis.

DISCUSSION

While gallstones are the most common cause of cholecystitis, 80% of patients with gallstones are asymptomatic and less than 3% develop acute cholecystitis.¹ While the presence of RUQ pain, fever, and leukocytosis are the clinical criteria for cholecystitis, the diagnosis requires imaging. A sonographic Murphy's sign is the most sensitive sign of cholecystitis (86%-88%); however, pericholecystic fluid and gallbladder wall thickening are nonspecific.²⁻³

Gallbladder wall thickening is associated with many conditions including adenomyomatosis. Adenomyomatosis is an idiopathic hyperproliferation of the gallbladder wall and is found in 9% of people.⁴ Characteristically, bile- or calcium-filled sinuses, or Rokitsansky-Aschoff sinuses (RAS), as well as "comet tail" artifacts are diagnostic.⁵ Adenomyomatosis has been associated with gallstones; however, this association was not significant.⁵ It is not associated with pericholecystic fluid. Although most patients with adenomyomatosis are asymptomatic and do not require intervention, caution should be taken to differentiate it from acute cholecystitis. Contrast-enhanced

ultrasound or magnetic resonance imaging should be used if initial ultrasound is equivocal.⁵

Adenomyomatosis and cholecystitis are not mutually exclusive and the patient's clinical picture is paramount. Absence of pericholecystic fluid, leukocytosis, and fever in the presence of RAS, and the presence of a gallstone (as in our patient) should not lower our threshold for emergent cholecystectomy, as symptomatic RAS, even in the absence of stone, is indication for surgery.⁶ Additionally, other differential diagnoses should be considered in the context of persistent RUQ pain and a thickened gallbladder wall. For instance, rare mucous-producing gallbladder neoplasms have been associated with cystic spaces resembling RAS.⁵

In summary, ED providers should maintain a low threshold for emergent cholecystectomy for patients with a positive Murphy's sign with ultrasonographic evidence of stone. In this way, POCUS can help minimize both unnecessary cholecystectomy and delays in patient care.

ACKNOWLEDGMENT

The authors would like to acknowledge the University of California (UC) Irvine Health Department of Emergency Medicine and UC Irvine School of Medicine.

Video. Right upper quadrant ultrasound demonstrating a stone in gallbladder neck, and anterior gallbladder wall measuring 4.6 millimeters with no pericholecystic fluid. Findings are also consistent with adenomyomatosis as evidenced by the Rokitsansky-Aschoff sinuses in wall and "comet tail" artifacts (red arrows).⁵

Documented patient informed consent and/or Institutional Review Board approval has been obtained and filed for publication of this case report.

Address for Correspondence: Shadi Lahham, MD, MS, University of California-Irvine, Department of Emergency Medicine, 333 The City Boulevard West, Suite 640, Orange, CA 92868. Email: slahham@uci.edu.

Conflicts of Interest: By the CPC-EM article submission agreement, all authors are required to disclose all affiliations, funding sources and financial or management relationships that could be perceived as potential sources of bias. The authors disclosed none.

Copyright: © 2019 Kim et al. This is an open access article distributed in accordance with the terms of the Creative Commons Attribution (CC BY 4.0) License. See: <http://creativecommons.org/licenses/by/4.0/>

REFERENCES

1. Bonatti M, Vezzali N, Lombardo F, et al. Gallbladder adenomyomatosis: imaging findings, tricks and pitfalls. *Insights Imaging*. 2017;8(2):243-53.
2. Indar AA and Beckingham IJ. Acute cholecystitis. *BMJ*. 2002;325(7365):639-43.
3. Bree RL. Further observations on the usefulness of the sonographic Murphy sign in the evaluation of suspected acute cholecystitis. *J Clin Ultrasound*. 1995;23(3):169-72.
4. Pinto A, Reginelli A, Cagini L, et al. Accuracy of ultrasonography in the diagnosis of acute calculous cholecystitis: review of the literature. *Crit Ultrasound J*. 2013;5(1):1-4.
5. Golse N, Lewin M, Rode A, et al. Gallbladder adenomyomatosis: diagnosis and management. *J Visc Surg*. 2017;154(5):345-53.
6. Bonatti M, Vezzali N, Lombardo F, et al. Gallbladder adenomyomatosis: imaging findings, tricks and pitfalls. *Insights Imaging*. 2017;8(2):243-53.

CPC-EM Capsule

What do we already know about this clinical entity?
Adenomyomatosis is an idiopathic hyperproliferation of the gallbladder wall. The presence of bile or calcium filled sinuses called Rokitansky-Aschoff sinuses are diagnostic.

What is the major impact of the image(s)?
Like cholecystitis, adenomyomatosis may present with gallbladder wall thickening on imaging but is often asymptomatic and does not require intervention. Gallbladder wall thickening in the absence of right upper quadrant pain, fever, leukocytosis and pericholecystic fluid should be further evaluated to avoid unnecessary cholecystectomy.

How might this improve emergency medicine practice?
Differentiating adenomyomatosis from acute cholecystitis using a thorough history, physical exam, and diagnostic imaging can minimize unnecessary intervention and morbidity.

Mucocutaneous Paraneoplastic Syndrome Secondary to Classical Hodgkin's Lymphoma

Jenna Jurkovic, DO*
Michael Cirone, MD†*

*Advocate Christ Medical Center, Department of Emergency Medicine, Oak Lawn, Illinois
†University of Illinois-Chicago, Department of Emergency Medicine, Chicago, Illinois

Section Editor: Rick A. McPheeters, DO

Submission history: Submitted November 28, 2018; Revision received February 10, 2019; Accepted March 4, 2019

Electronically published April 2, 2019

Full text available through open access at http://escholarship.org/uc/uciem_cpccm

DOI: 10.5811/cpcem.2019.3.41759

Paraneoplastic syndromes may be the only presenting manifestation of an otherwise occult malignancy. This case report highlights a patient presenting to the emergency department with an atypical, multi-system disease, ultimately leading to a diagnosis of mucocutaneous paraneoplastic syndrome secondary to classical Hodgkin's lymphoma. Emergency physicians should maintain a high clinical suspicion for paraneoplastic syndromes when patients present with multi-system manifestations. [Clin Pract Cases Emerg Med. 2019;3(2):160-161.]

CASE PRESENTATION

A 39-year-old Hispanic male with no past medical history presented to the emergency department (ED) with a chief complaint of "allergic reaction." Pertinent review of systems included several weeks of left facial and neck swelling, pharyngitis, non-productive cough, and rhinorrhea. He was evaluated multiple times in the urgent care setting and treated with several different antibiotic regimens for bacterial pharyngitis. He later developed bilateral conjunctivitis, oral ulcers, and a solitary penile lesion. Outpatient medications were broadened to include antivirals, antifungals, and steroids. Due to persistence of symptoms, along with the development of hematuria and rectal pain, the patient sought evaluation in the ED.

Physical examination revealed bilateral, non-purulent conjunctival injection, multiple non-painful ulcerative oral lesions (Image 1), tender left cervical lymphadenopathy with edema, and a single non-ulcerative penile lesion with purulent discharge at the glans (Image 2). Vitals were within normal limits. Laboratory studies revealed a slight leukocytosis, but the remainder of labs, including inflammatory markers, were unremarkable. Computed tomography of the neck demonstrated left-sided cervical adenopathy suspicious for neoplasm (Image 3).

DISCUSSION

The multisystem involvement of the patient's clinical presentation yielded a broad differential diagnosis including allergic, autoimmune, infectious, or neoplastic etiology.

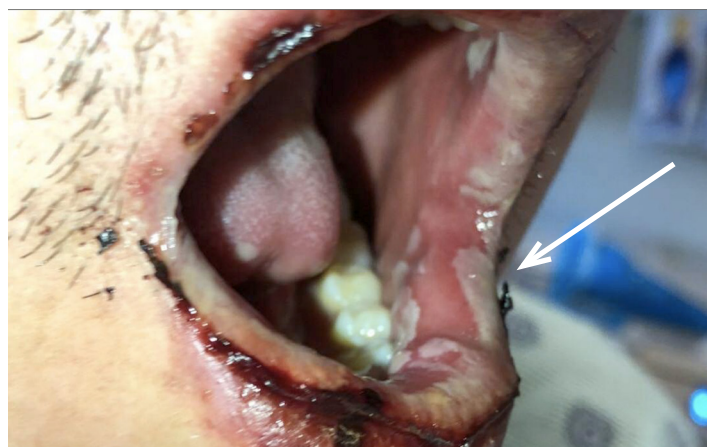

Image 1. Multiple ulcerative oral lesions.

Inpatient workup including lymph node, fine-needle aspirate and a biopsy of the lip established the diagnosis of a mucocutaneous paraneoplastic syndrome secondary to classical Hodgkin's lymphoma with mixed cellularity and Epstein-Barr virus positivity.

It is estimated that 8% of cancer patients are affected by paraneoplastic syndromes.¹ These syndromes often present with multisystem manifestations secondary to humoral substances produced by the tumor. In some cases, the paraneoplastic syndrome may be the only physical

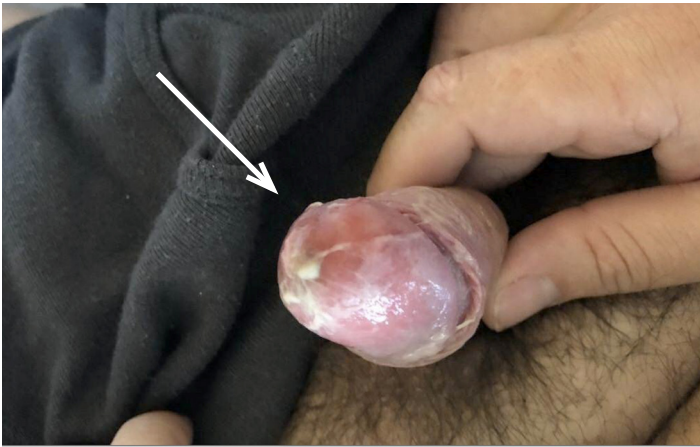

Image 2. Purulent penile discharge.

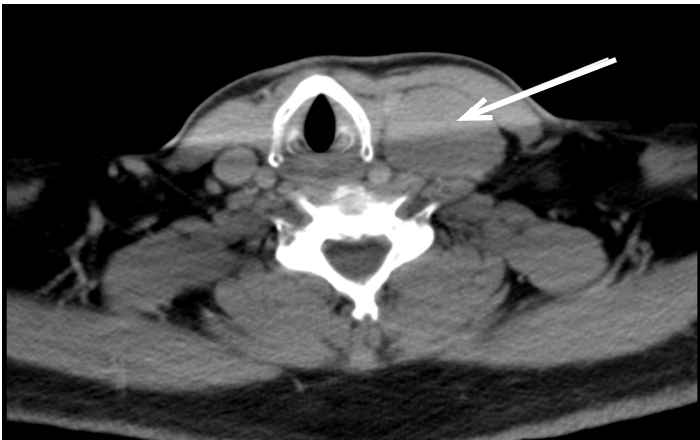


Image 3. Computed tomography, axial image, demonstrating left level 2-5b neck adenopathy.

manifestation of an otherwise occult malignancy.² Emergency physicians should maintain a high clinical suspicion for paraneoplastic syndromes when patients present with atypical multi-system endocrine, infectious, dermatologic, or rheumatologic disease. Timely detection, diagnosis and treatment of an otherwise occult malignancy, can significantly improve survival.²

Documented patient informed consent and/or Institutional Review Board approval has been obtained and filed for publication of this case report.

CPC-EM Capsule

What do we already know about this clinical entity?

Paraneoplastic syndromes may be the only presenting manifestation of an otherwise occult malignancy.

What is the major impact of the image(s)?

Multisystem abnormalities should raise suspicion for paraneoplastic syndrome.

How might this improve emergency medicine practice?

Emergency physicians should maintain a high clinical suspicion for paraneoplastic syndromes when patients present with atypical, multi-system manifestations, and this should warrant further diagnostic studies.

Address for Correspondence: Jenna Jurkovic, DO, Advocate Christ Medical Center, Department of Emergency Medicine, 4490 95th Street, Oak Lawn, IL 60453. Email: Jenna.jurkovic@advocatehealth.com.

Conflicts of Interest: By the CPC-EM article submission agreement, all authors are required to disclose all affiliations, funding sources and financial or management relationships that could be perceived as potential sources of bias. The authors disclosed none.

Copyright: © 2019 Jurkovic et al. This is an open access article distributed in accordance with the terms of the Creative Commons Attribution (CC BY 4.0) License. See: <http://creativecommons.org/licenses/by/4.0/>

REFERENCES

1. Darnell RB and Posner JB. (2010). Clinical findings, diagnosis, treatment, and prognosis. *Paraneoplastic Syndromes*. New York, New York: Oxford University Press.
2. Baijens LWJ and Manni JJ. Paraneoplastic syndromes in patients with primary malignancies of the head and neck. Four cases and a review of the literature. *Eur Arch Otorhinolaryngol*. 2005;263(1):32-6.

Early Diagnosis of Heterotopic Pregnancy in a Primigravid Without Risk Factors in the Emergency Department

Rachel O'Donnell, MD*

Elizabeth Siacunco, MD*

Daniel Quesada, MD†

Kieron Barkataki, DO*‡

Phillip Aguiñiga-Navarrete, RA*

*Kern Medical, Department of Emergency Medicine, Bakersfield, California

†LAC+USC Medical Center, Los Angeles, California

‡UCLA Health Sciences, Department of Emergency Medicine, Bakersfield, California

Section Editor: Rick A. McPheeters, DO

Submission history: Submitted October 17, 2018; Revision received December 12, 2018; Accepted January 4, 2019

Electronically published February 26, 2019

Full text available through open access at http://escholarship.org/uc/uciem_cpem

DOI: 10.5811/cpcem.2019.1.41312

[Clin Pract Cases Emerg Med. 2019;3(2):162-163.]

CASE PRESENTATION

A 19-year-old primigravida female presented with three weeks of intermittent suprapubic and left lower quadrant (LLQ) abdominal pain, worsening in the prior 24 hours, associated with nausea and vomiting at the time of presentation. Her last normal menstrual period was approximately 17 weeks prior to presentation, but she reported some vaginal spotting nine weeks ago. Abdominal exam revealed diffuse tenderness to palpation, worse in the LLQ, without peritoneal signs. A point-of-care ultrasound (POCUS) showed an intrauterine pregnancy (IUP). However, the patient's persistent unilateral pain was concerning. Therefore, a formal pelvic ultrasound was performed, which revealed an IUP at seven weeks gestation, including an anechoic region with free fluid in the pelvis (Image 1), and a left adnexal

complex mass suspicious for extrauterine pregnancy (Image 2). She subsequently underwent a laparoscopic left salpingectomy for a ruptured ectopic pregnancy. The IUP was unaffected.

DISCUSSION

While heterotopic pregnancy (HP) is rare, its frequency has increased with the advent of fertility treatment and reproductive technologies.¹ Other risk factors include history of ectopic pregnancy, pelvic inflammatory disease, and prior tubal surgery.² Our patient had no risk factors. While ectopic pregnancy is a leading cause of maternal death, HP has a good prognosis if diagnosed early.³ After treatment of an extrauterine pregnancy, more than half proceed with an otherwise-uneventful IUP to term.² However, its diagnosis is challenging,

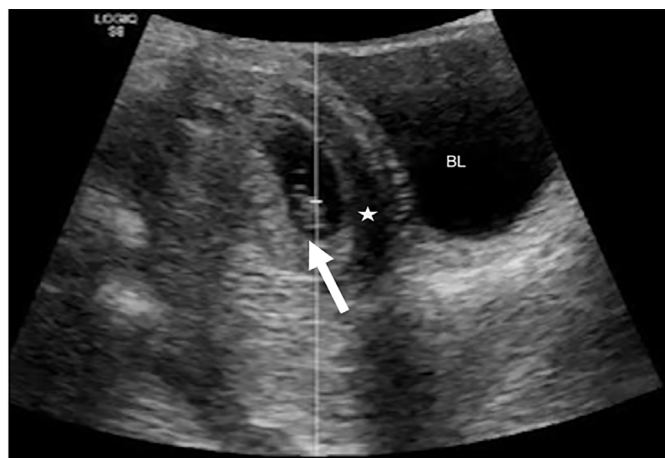


Image 1. Viable intrauterine pregnancy (arrow) with free fluid in the pelvis (star).
BL, bladder.

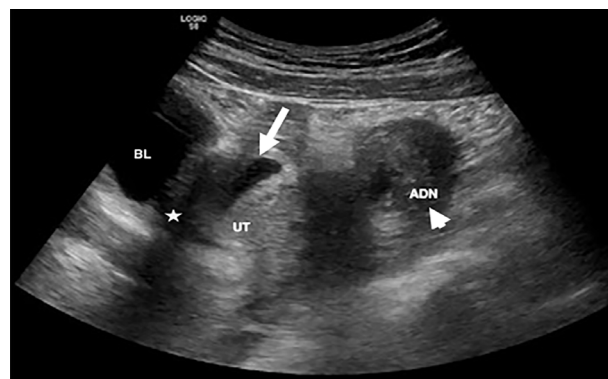


Image 2. Transabdominal ultrasonography revealing a gestational sac in the uterus (arrow) and a complex mass with central hypoechoogenicity in the left adnexa (arrowhead), suggestive of an extrauterine pregnancy.
UT, uterus; ADN, adnexa; BL, bladder.
Star = free fluid.

and many of these patients initially present to the emergency department with abdominal pain, vaginal bleeding, or both. With the emergence of POCUS, emergency physicians are trained to identify IUPs.⁴ A study concluded that emergency physicians were able to successfully use ultrasound to rule out ectopic pregnancy by locating an established IUP with embryonic structures.⁵ Thus, the presence of an IUP can mask a concomitant extrauterine pregnancy, delaying its diagnosis and potentially resulting in life-threatening hemorrhage. This case illustrates the need for emergency physicians to maintain a high index of suspicion for HP even in patients without risk factors, and the need to evaluate the entire pelvis despite an IUP.

Documented patient informed consent and/or Institutional Review Board approval has been obtained and filed for publication of this case report.

Address for Correspondence: Rachel O'Donnell, MD, Kern Medical, Department of Emergency Medicine, 1700 Mount Vernon Avenue, Bakersfield, CA 93306. Email: Rachel025@gmail.com.

Conflicts of Interest: By the CPC-EM article submission agreement, all authors are required to disclose all affiliations, funding sources and financial or management relationships that could be perceived as potential sources of bias. The authors disclosed none.

Copyright: © 2019 O'Donnell et al. This is an open access article distributed in accordance with the terms of the Creative Commons Attribution (CC BY 4.0) License. See: <http://creativecommons.org/licenses/by/4.0/>

REFERENCES

1. Tal J, Haddad S, Gordon N, et al. Heterotopic pregnancy after ovulation induction and assisted reproductive technologies: a literature review from 1971 to 1993. *Fertil Steril.* 1996;66(1):1-12.
2. Barrenetxea G, Barinaga-Rementería L, Lopez de Laruzzea A, et al. Heterotopic pregnancy: two cases and a comparative review. *Fertil Steril.* 2007;87(2):417.e9-15.
3. Schneider J, Berger CJ, Cattell C. Maternal mortality due to ectopic pregnancy. A review of 102 deaths. *Obstet Gynecol.* 1977;49(5):557-61.
4. Michalke J. An overview of emergency ultrasound in the United States. *World J Emerg Med.* 2012;3(2):85-90.
5. Durham B, Lane B, Burbridge L, et al. Pelvic ultrasound performed by emergency physicians for the detection of ectopic pregnancy in complicated first-trimester pregnancies. *Ann Emerg Med.* 1997;29(3):338-47.

CPC-EM Capsule

What do we already know about this clinical entity?

Heterotopic pregnancy is rare, and most cases are seen in patients undergoing infertility treatment. Additional risk factors are similar to those of an ectopic pregnancy.

What is the major impact of the image(s)?

Heterotopic pregnancy can be seen in those without obvious risk factors. A viable intrauterine pregnancy (IUP) does not completely rule out a concurrent ectopic pregnancy.

How might this improve emergency medicine practice?

Most EM physicians rule out an ectopic pregnancy if an IUP is seen on bedside ultrasound. This is a reminder to maintain a high index of suspicion for a heterotopic pregnancy despite a viable IUP.

Apparent Pacer Spikes in a Patient with Back and Chest Pain

Al Lulla, MD
Richard T. Griffey, MD, MPH

Washington University School of Medicine, Division of Emergency Medicine, St. Louis, Missouri

Section Editor: Rick A. McPheeters, DO

Submission history: Submitted September 30, 2018; Revision received November 24, 2018; Accepted January 1, 2019

Electronically published February 26, 2019

Full text available through open access at http://escholarship.org/uc/uciem_cpccem

DOI: 10.5811/cpcem.2019.1.41095

[Clin Pract Cases Emerg Med. 2019;3(2):164-165.]

CASE PRESENTATION

A 74-year-old female with a history of diabetes mellitus, hypertension, atrial fibrillation (on warfarin, diltiazem and metoprolol) presented with chest and back pain. A 12-lead electrocardiogram (ECG) was ordered at triage demonstrating possible aberrant pacemaker activity (Image 1).

DIAGNOSIS

Upon evaluation, the treatment team determined that the patient had no history of pacemaker placement. Physical examination revealed that the patient had an over-the-counter transcutaneous electrical nerve stimulation (TENS) unit adhered to her back to treat her back pain. Once the TENS device was removed, a repeat ECG demonstrated rate-controlled atrial fibrillation without any other electrical discharges (Image 2).

TENS units are external electrostimulators that produce electrical current with variable frequency, amplitude and duration, delivered through skin electrodes.¹ TENS units are sometimes used in the treatment of post-operative and chronic pain, and are theorized to work by altering electrical signals involved with the perception of pain.² Until recently, TENS units were only available through pain clinics or specialty providers. These units are now widely available over the counter, with an increasing likelihood of use by patients visiting the emergency department (ED). Although case reports from over 20 years ago report electrical spikes on ECG caused by earlier TENS units, this phenomenon has not been reported in the ED or in the emergency medicine literature and these electrical artifacts have not been described in newer, commercially available over-the-counter units in use today.³

Artifactual ECG changes inconsistent with a patient's presentation, particularly in patients with back pain, should prompt consideration by the emergency physician of the presence of a TENS unit causing artifacts.

Documented patient informed consent and/or Institutional Review Board approval has been obtained and filed for publication of this case report.

CPC-EM Capsule

What do we already know about this clinical entity? *Electrocardiogram (ECG) artifacts are well described phenomena attributable to various sources. While traditional Transcutaneous Electrical Nerve Stimulation (TENS) units have been known to cause ECG changes, ECG abnormalities due to over the counter TENS units in the emergency department (ED) setting have not been previously reported.*

What is the major impact of the image(s)? *TENS devices are a known pain treatment modality that are now increasingly available over the counter. These devices may induce artifactual changes on ECGs*

How might this improve emergency medicine practice? *Careful and thorough history and physical exam in the emergency department may prompt the emergency physician to the presence of a TENS device as the cause of electrocardiographic artifact.*

Address for Correspondence: Richard T. Griffey, MD, MPH, Washington University School of Medicine, Division of Emergency Medicine, 660 S. Euclid Ave, Campus Box 8072, Saint Louis, MO 63110. Email: griffeyr@wustl.edu.

Conflicts of Interest: By the CPC-EM article submission agreement, all authors are required to disclose all affiliations, funding sources and financial or management relationships that could be perceived as potential sources of bias. The authors disclosed none.

Copyright: © 2019 Lulla et al. This is an open access article distributed in accordance with the terms of the Creative Commons Attribution (CC BY 4.0) License. See: <http://creativecommons.org/licenses/by/4.0/>

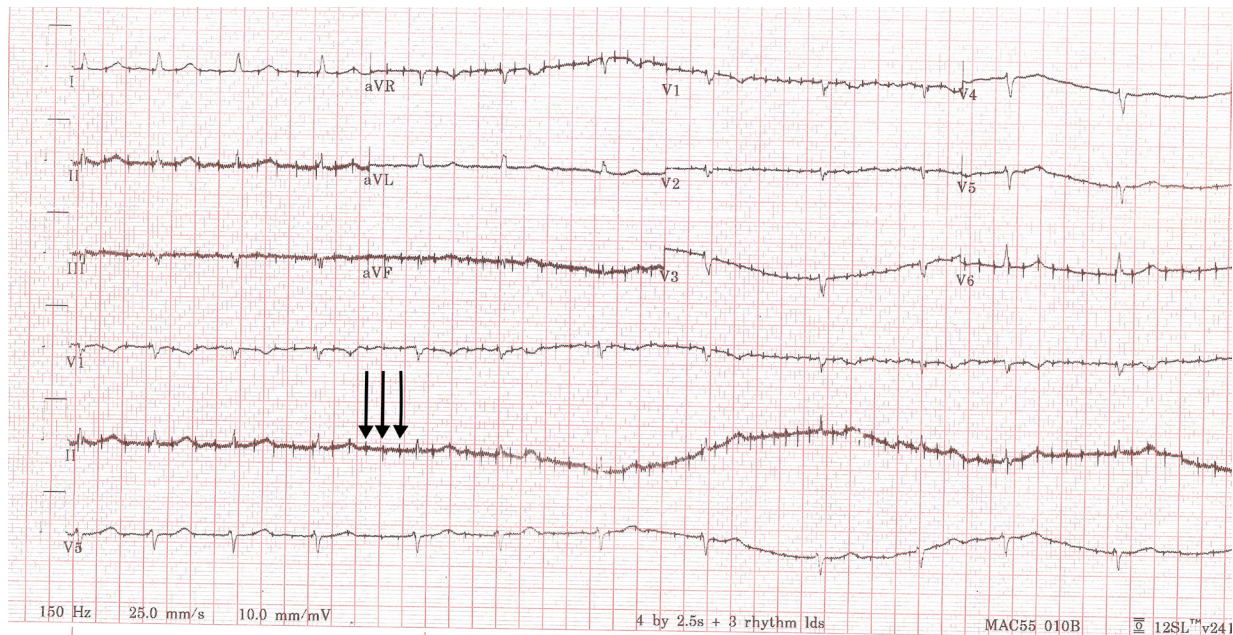


Image 1. 12-lead electrocardiogram demonstrates an irregular rhythm without p-wave morphologies and heart rate of 75, suggestive of rate-controlled atrial fibrillation. In addition, atypical, high-frequency electrical discharges (arrows) are seen irrespective of ventricular depolarization suggestive of aberrant pacemaker activity.

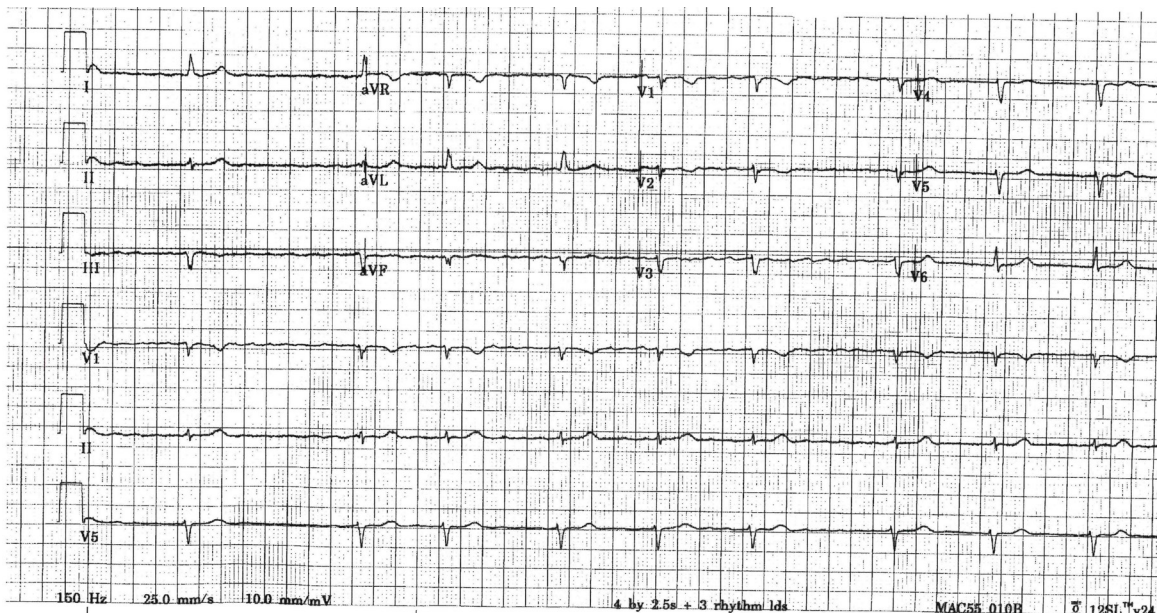


Image 2. Repeat 12-lead electrocardiogram after removal of transcutaneous electrical nerve stimulation device demonstrates atrial fibrillation with slow ventricular response and resolution of electrical discharges.

REFERENCES

1. Patel SI and Souter MJ. Equipment-related electrocardiographic artifacts: causes, characteristics, and correction. *Anesthesiology*. 2008;108(1):138-48.
2. Sliwa J and Marinko M. Transcutaneous electrical nerve stimulator-induced electrocardiogram artifact: a brief report. *Am J Physical Med Rehabil*. 1996;75(4):307-9.
3. Hauptman PJ and Raza M. Electrocardiographic artifact with a transcutaneous electrical nerve stimulation unit. *Int J Cardiol*. 1992;34:110-2.

Atypical Fungal Rash

Fadi W.M. Adel, MD*
Venkatesh Bellamkonda, MD†

*Mayo Clinic, Department of Internal Medicine, Rochester, Minnesota
†Mayo Clinic, Department of Emergency Medicine, Rochester, Minnesota

Section Editor: Rick A. McPheeters, DO

Submission history: Submitted October 19, 2018; Revision received January 6, 2019; Accepted January 12, 2019

Electronically published February 26, 2019

Full text available through open access at http://escholarship.org/uc/uciem_cpccem

DOI: 10.5811/cpcem.2019.1.41329

[Clin Pract Cases Emerg Med. 2019;3(2):166-167.]

CASE PRESENTATION

A 73-year-old man with rheumatoid arthritis on prednisone (10 milligrams [mg] daily routinely, and increased to 40 mg daily during frequent exacerbations) presented to the emergency department with chills and a leg rash. Two weeks prior, he noticed redness on his right thigh, with black spots developing later. His vital signs were normal, and his physical examination was significant for a 6 x 10 centimeter (cm) red, warm patch with 0.5 cm indurated black papules and ulcers (Image). His lab work-up was unremarkable. Periodic acid–Schiff–diastase and Gram stains of a punch biopsy sample of one papule demonstrated variably sized yeast and hyphal fungal elements. *Purpureocillium lilacinum* grew, thus clinching the diagnosis.

DISCUSSION

Although often dismissed as a contaminant, *P. lilacinum* is an emerging fungal agent implicated in cutaneous and

pulmonary diseases in immunocompetent and, more often, immunocompromised hosts. The fungus commonly grows on decaying organic material in soil.¹ We are aware of very few cases of cutaneous infection by this fungus reported in the literature and, to our knowledge, these are the only images with black papules. According to Saghrouni et al., successful cure has been achieved with griseofulvin, itraconazole, ketoconazole, and voriconazole in other cases.^{2,3} Voriconazole was initiated for this patient; however, he was lost to follow-up. This vignette demonstrates the importance of recognizing uncommon fungal infections, especially in immunocompromised patients.

Documented patient informed consent and/or Institutional Review Board approval has been obtained and filed for publication of this case report.

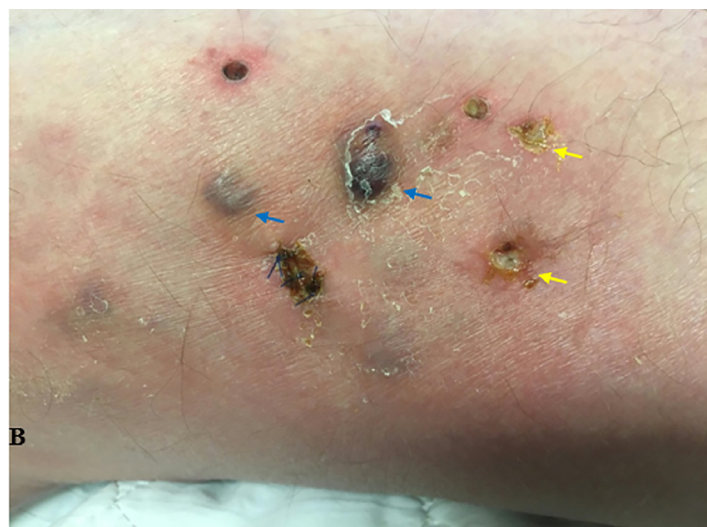
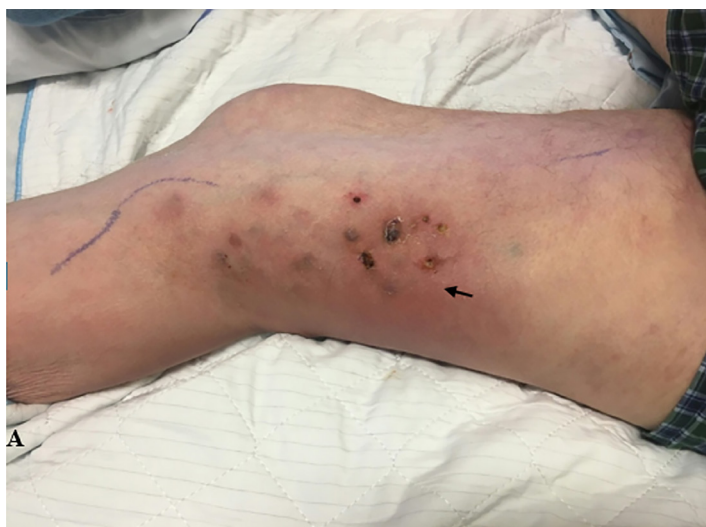
Image. *Purpureocillium lilacinum* in an immunocompromised host. A) The erythematous, warm base (black arrow) is on the medial surface of the patient's thigh. B) A close-up view of the lesion demonstrates black papules (blue arrows) and ulcers (yellow arrows).

Address for Correspondence: Fadi W.M. Adel, MD, Mayo Clinic, Department of Internal Medicine, 200 First Street SW, Rochester, MN, 55905. Email: adel.fadi@mayo.edu.

Conflicts of Interest: By the CPC-EM article submission agreement, all authors are required to disclose all affiliations, funding sources and financial or management relationships that could be perceived as potential sources of bias. The authors disclosed none.

Copyright: © 2019 Adel et al. This is an open access article distributed in accordance with the terms of the Creative Commons Attribution (CC BY 4.0) License. See: <http://creativecommons.org/licenses/by/4.0/>

REFERENCES

1. Luangsa-Ard J, Houbraken J, van Doorn T, et al. *Purpureocillium*, a new genus for the medically important *Paecilomyces lilacinus*. *FEMS Microbiol Lett.* 2011;321(2):141-9.
2. Trinh S and Angarone M. *Purpureocillium lilacinum* tattoo-related skin infection in a kidney transplant recipient. *Transpl Infect Dis.* 2017;19(3):e12689.
3. Saghrouni F, Saidi W, Said Z, et al. Cutaneous hyalohyphomycosis caused by *Purpureocillium lilacinum* in an immunocompetent patient: case report and review. *Med Mycol.* 2013;51(6):664-8.

CPC-EM Capsule

What do we already know about this clinical entity?

Purpureocillium lilacinum is a filamentous, soil-dwelling fungus and an emergent pathogen implicated in eye and skin infections, nasal septal perforations, and lung cavitation.

What is the major impact of the image(s)?

This is the first report of cutaneous P. lilacinum presenting as black papular lesions on an erythematous base. Previously, it was isolated from abscesses and tattoo-related red papules.

How might this improve emergency medicine practice?

This image will aid emergency providers to recognize similar-appearing lesions as potential cutaneous mycosis, and subsequently guide appropriate management and/or referral.

A Man with Severe Right Knee Pain

Shinsuke Takeda, MD*^{†‡}
 Katsuyuki Iwatsuki, MD, PhD[‡]
 Yosuke Takeichi, MD[†]
 Tomohiro Kano, MD[†]
 Akihiko Tabuchi, MD*
 Hitoshi Hirata, MD, PhD[‡]

*Anjo Kosei Hospital, Emergency and Critical Care Center, Anjo, Japan
[†]Anjo Kosei Hospital, Department of Orthopaedic Surgery, Anjo, Japan
[‡]Nagoya University Graduate School of Medicine, Department of Hand Surgery, Nagoya, Japan

Section Editor: Rick A. McPheeters, DO

Submission history: Submitted October 25, 2018; Revision received December 19, 2018; Accepted January 22, 2019

Electronically published February 26, 2019

Full text available through open access at http://escholarship.org/uc/uciem_cpem

DOI: 10.5811/cpcem.2019.1.41417

[Clin Pract Cases Emerg Med. 2019;3(2):168-169.]

CASE PRESENTATION

A 29-year-old man with no significant medical history presented to the emergency department with severe pain, swelling, and inability to move his right knee. He was injured when he extended his right knee to hit a tennis ball after running to the net. On examination, high-riding patellae were found on both the injured and non-injured sides. A lateral view radiograph showed patella alta in both knees (Image 1).

Magnetic resonance imaging (MRI) was performed to examine the right knee extensor apparatus (Image 2).

DISCUSSION

Patellar tendon rupture is an uncommon clinical presentation that generally affects patients younger than 40 years who actively engage in sporting activities.¹ Patellar tendon rupture from indirect injury in an athlete represents the end stage of jumper's knee and results from repetitive microtrauma.² It occurs most frequently in patients with predisposing factors such as rheumatoid arthritis, chronic renal failure, systemic lupus erythematosus, hyperparathyroidism, hereditary disorders of the connective tissue (e.g., Ehlers-

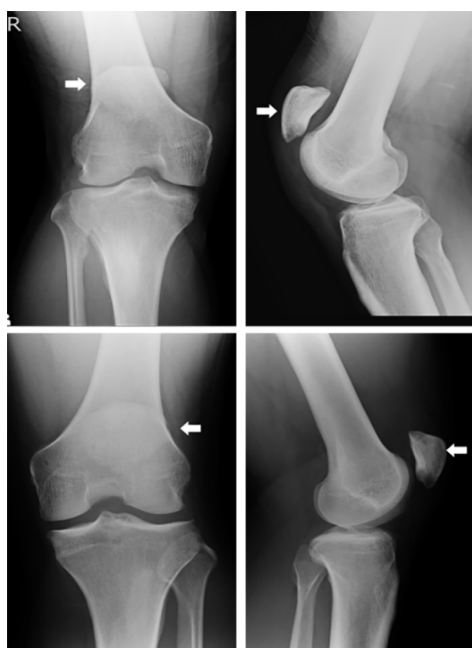


Image 1. High-riding patella (patella alta) (arrows): (upper) right knee and (lower) left knee. The Insall-Salvati ratio (length from the tibial tubercle to the inferior patellar pole divided by the length of the patella), as seen on the lateral view radiograph, is 1.86 in the right knee and 1.60 in the left knee. (Ratio >1.2 is defined as patella alta.)

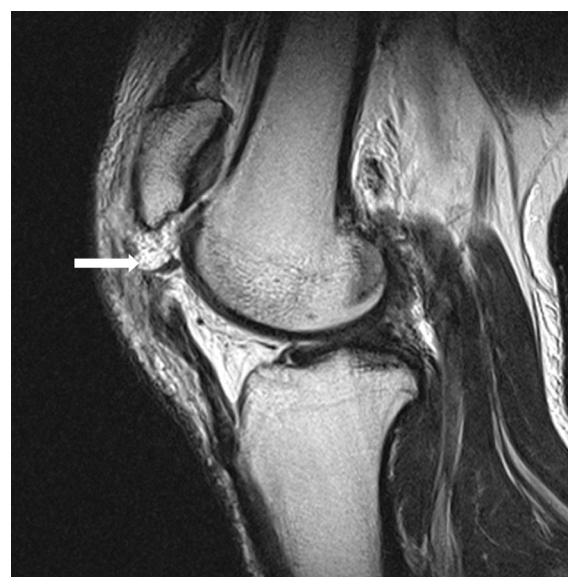

Image 2. Magnetic resonance sagittal T2-weighted image shows proximal patellar tendon rupture (enthesion of the patella) (arrow).

Danlos syndrome), or long-term medication such as corticosteroids or fluoroquinolones.^{1,3,4} Because MRI is not always immediately available, the emergency physician should confirm the disrupted extensor mechanism such as loss of active extension of the leg in addition to swelling in the anterior aspect of the knee and hemarthrosis. Patellar tendon rupture occurring in a patient with patella alta is quite rare.² In this case, diagnosis based on radiographs was difficult because the non-injured side also showed patella alta. Patella alta may contribute to or initiate chondromalacia.² After surgery, the patient returned to his baseline level of activity with no complaints.

Documented patient informed consent and/or Institutional Review Board approval has been obtained and filed for publication of this case report.

Address for Correspondence: Katsuyuki Iwatsuki, MD, PhD, Nagoya University Graduate School of Medicine, Department of Hand Surgery, 65 Tsurumai-cho, Shouwa-ku, Nagoya, Aichi 466-0065, Japan. Email: kiwatsuki@med.nagoya-u.ac.jp.

Conflicts of Interest: By the CPC-EM article submission agreement, all authors are required to disclose all affiliations, funding sources and financial or management relationships that could be perceived as potential sources of bias. The authors disclosed none.

Copyright: © 2019 Takeda et al. This is an open access article distributed in accordance with the terms of the Creative Commons Attribution (CC BY 4.0) License. See: <http://creativecommons.org/licenses/by/4.0/>

REFERENCES

1. Flanigan DC, Troyer J, Everhart JS, et al. (2017). Extensor mechanism injuries: quadriceps and patellar tendon ruptures. In: Eltorai A, Ebersson

CPC-EM Capsule

What do we already know about this clinical entity?

Patellar tendon rupture is an uncommon clinical presentation. Patellar tendon rupture occurring in a patient with patella alta is quite rare.

What is the major impact of the image(s)?

Diagnosis based on radiographs is difficult because the non-injured side also showed patella alta in this case.

How might this improve emergency medicine practice?

Emergency doctors should suspect patella tendon rupture from the clinical findings.

Considering our case such as non-injured side also showing patella alta, magnetic resonance imaging is essential for diagnosis.

C, Daniels A, (Eds.). Orthopedic Surgery Clerkship (309-313). Cham, Switzerland: Springer Publishing.

2. Kelly DW, Carter VS, Jobe FW, et al. Patellar and quadriceps tendon ruptures – jumper's knee. *Am J Sports Med.* 1984;12(5):375-80.
3. Siwek CW and Rao JP. Ruptures of the extensor mechanism of the knee joint. *J Bone Joint Surg Am.* 1981;63(6):932-7.
4. Kellersmann R, Blattert TR, Weckbach A. Bilateral patellar tendon rupture without predisposing systemic disease or steroid use: a case report and review of the literature. *Arch Orthop Trauma Surg.* 2005;125(2):127-33.

Rare Cause of Inguinal Pain in 39-year-old Male

Kieron Barkataki, DO*
 Nathan Wang, MD*
 Daniel Quesada, MD*†
 Rachell O'Donnell, MD*
 James W. Rosbrugh, MD*
 Phillip Aguiñiga-Navarrete, RA*

*Kern Medical, Department of Emergency Medicine, Bakersfield, California
 †LAC+USC Medical Center, Department of Emergency Medicine, Los Angeles, California

Section Editor: Rick A. McPheeters, DO

Submission history: Submitted October 10, 2018; Revision received January 4, 2019; Accepted January 12, 2019

Electronically published March 5, 2019

Full text available through open access at http://escholarship.org/uc/uciem_cpccm

DOI: 10.5811/cpcem.2019.1.41212

[Clin Pract Cases Emerg Med. 2019;3(2):170-171.]

CASE PRESENTATION

A 39-year-old male with no past history presented with three months of left inguinal pain and a left groin lump that became progressively larger and more painful. He was seen at another hospital over one month prior where they were unable to manually reduce the lump. He could not recall the computed tomography (CT) findings, and no surgery was performed. Since then, he has experienced persistent left inguinal pain and nausea. He denied fever, vomiting, dysuria, hematuria, penile discharge, testicular pain, or history of sexually transmitted diseases.

Physical exam revealed a firm, tender, and non-reducible mass in the left inguinal canal and along the spermatic cord. Remainder of examination was normal. Complete blood count, basic metabolic panel, lactate, urinalysis and urine culture were normal. CT of the abdomen and pelvis was suggestive of pampiniform plexus thrombosis (Image 1). Formal ultrasound images revealed diminished Doppler vascular flow (Image 2) within the left testicle and prominent, heterogeneous vascular structures seen in the left inguinal canal (Image 3) that correlated with the CT, indicating pampiniform plexus thrombosis as well.

DISCUSSION

Pampiniform plexus thrombosis is a rare cause of inguinal pain, which is often misdiagnosed as hernia or orchitis. Accurate diagnosis can prevent unnecessary treatment including surgical intervention. There are limited references in the literature to this condition, and there are no evidence-based approaches to management. The majority of reported cases involved the left venous plexus, and most were diagnosed intra-operatively for pre-operative diagnoses of incarcerated inguinal hernia or orchitis.¹ A work-up for hypercoagulability is recommended.² Management has ranged from conservative treatment with nonsteroidal anti-inflammatory drugs to surgical excision of the thrombosed vessels.³

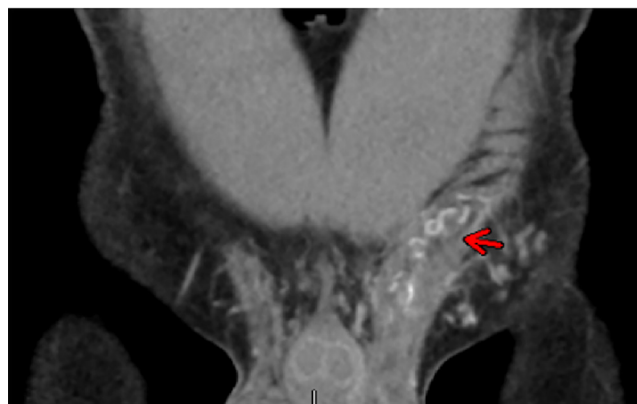


Image 1. Coronal contrast-enhanced computed tomography of the abdomen and pelvis showing fullness in the left inguinal canal with surrounding fat stranding (arrow).

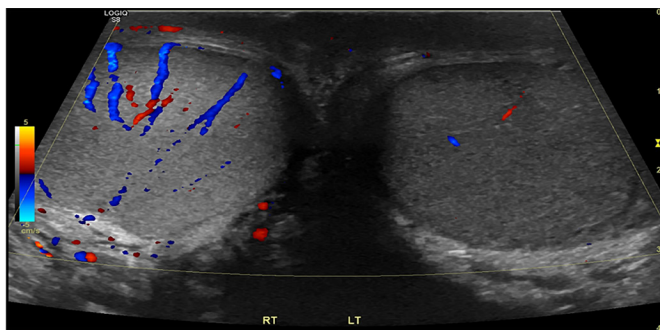


Image 2. Formal ultrasound of both testes with demonstration of decreased Doppler vascular flow on left testicle compared to right.

Documented patient informed consent and/or Institutional Review Board approval has been obtained and filed for publication of this case report.

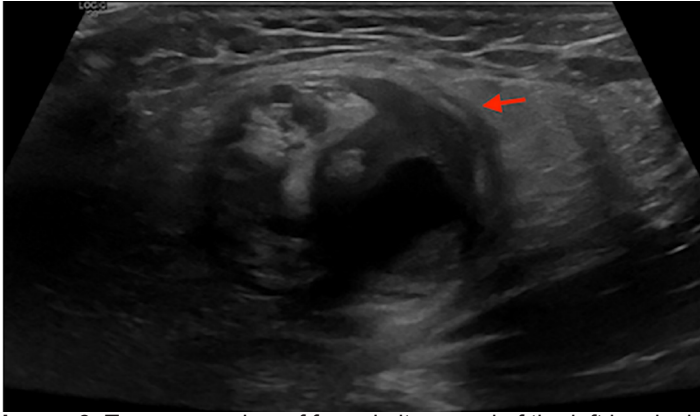


Image 3. Transverse view of formal ultrasound of the left inguinal canal displaying prominent heterogeneous structures (arrow).

Address for Correspondence: Kieron Barkataki, DO, Kern Medical, Department of Emergency Medicine, 1700 Mount Vernon Avenue, Bakersfield, CA 93306. Email: kieron20@gmail.com.

Conflicts of Interest: By the CPC-EM article submission agreement, all authors are required to disclose all affiliations, funding sources and financial or management relationships that could be perceived as potential sources of bias. The authors disclosed none.

Copyright: © 2019 Barkataki et al. This is an open access article distributed in accordance with the terms of the Creative Commons Attribution (CC BY 4.0) License. See: <http://creativecommons.org/licenses/by/4.0/>

CPC-EM Capsule

What do we already know about this clinical entity?

Pampiniform plexus thrombosis is a rare cause of inguinal pain. There is little consensus about the appropriate treatment at this time.

What is the major impact of the image(s)?

This disease process is often mistaken for incarcerated inguinal hernia. Multiple cases were not accurately diagnosed until the patient was on the operating table.

How might this improve emergency medicine practice?

This case reminds physicians of rare clinical entities and may help avoid unnecessary surgery.

REFERENCES

1. Kamel K, Gassen S, Mohamed M, et al. Bilateral spontaneous thrombosis of the pampiniform plexus; a rare etiology of acute scrotal pain: a case report and review of literature. *Afr J Urol.* 2018;24(1):14-8.
2. Tanner R, Twomey M, Maher MM, et al. A rare cause of testicular pain: thrombosis of the pampiniform plexus. *Ir Med J.* 2016;109(1):347-8.
3. Ouanes Y, Sellami A, Chaker K, et al. Thrombosis of the pampiniform plexus: About a case report. *Urol Case Rep.* 2018;20:28-9.

The Aquarium Sign: Another Opportunity for Detection of Perforated Viscus

Matthew Gorgone, DO
Timothy P. O'Connor, MD
Michael Lu, MD

University of Rochester Medical Center, Department of Emergency Medicine,
Rochester, New York

Section Editor: Rick A. McPheeters, DO

Submission history: Submitted November 8, 2019; Revision received January 21, 2019; Accepted January 30, 2019

Electronically published March 5, 2019

Full text available through open access at http://escholarship.org/uc/uciem_cpem

DOI: 10.5811/cpcem.2019.1.41582

[Clin Pract Cases Emerg Med. 2019;3(2):172-173.]

CASE PRESENTATION

A 61-year-old male with history of alcohol abuse and presumed cirrhosis presented to the emergency department with generalized weakness and right facial droop. He was found to be profoundly hypotensive and hypothermic with subsequent rapid decompensation requiring intubation and continuous norepinephrine infusion. Given the presence of ascites, we performed a diagnostic paracentesis that showed 9,787 nucleated cells per microliter with abundant intra- and extra-cellular bacteria. Intravenous vancomycin and piperacillin-tazobactam was started, but he was too hemodynamically unstable to travel to computed tomography to evaluate for perforation. A point-of-care ultrasound revealed air bubbles and debris actively bubbling (“aquarium sign”) through ascites and intraperitoneal A-lines indicative of pneumoperitoneum (Video). Portable abdominal radiograph was suspicious for free air, and eventually the patient was taken to the operating room where surgeons found a ruptured gastric ulcer and distal ileum and cecum ischemia without frank necrosis.

DISCUSSION

Any patient admitted to the hospital with ascites secondary to cirrhosis should undergo diagnostic paracentesis to rule out spontaneous bacterial peritonitis (SBP).¹ But distinguishing SBP from secondary causes such as viscus perforation can be difficult, as the classic symptoms of peritonitis do not often occur in patients with ascites because of the separation between visceral and parietal peritoneum.² Differentiating these etiologies is critical due to high mortality of secondary bacterial peritonitis without surgical intervention, and high mortality of SBP if patients undergo unnecessary exploratory laparotomy.^{2,3} Many ultrasound techniques to detect pneumoperitoneum have been described, including assessment of the perihepatic space, movable gas, and peritoneal line enhancement, but assessment of these can be challenging to inexperienced sonographers.⁴

While movable gas is more easily visualized in patients with ascites, free fluid also provides a unique opportunity to visualize active air seepage from perforated bowel, as seen in our case. To our knowledge, this has not been previously described.

Video. Ascites is visualized using a curvilinear transducer with the probe marker oriented toward the patient’s head. The image is obscured by what appears to be an “A” profile reverberation artifact, which is displaced superiorly as pressure is applied to the probe, suggesting movable air within the peritoneal cavity. Next, a phased array transducer is used with the probe marker oriented toward the patient’s head. Hyperechoic air bubbles are visualized rising to the top of the ascites.

Address for Correspondence: Matthew Gorgone, DO, University of Rochester School of Medicine and Dentistry, Department of Emergency Medicine, 601 Elmwood Ave P.O. Box MED-HMD, Rochester, NY 14642. Email: matthew.j.gorgone@gmail.com.

Conflicts of Interest: By the CPC-EM article submission agreement, all authors are required to disclose all affiliations, funding sources and financial or management relationships that could be perceived as potential sources of bias. The authors disclosed none.

Copyright: © 2019 Gorgone et al. This is an open access article distributed in accordance with the terms of the Creative Commons Attribution (CC BY 4.0) License. See: <http://creativecommons.org/licenses/by/4.0/>

REFERENCES

1. Runyon BA. Management of adult patients with ascites due to cirrhosis: Update 2012. Available at: https://www.aasld.org/sites/default/files/guideline_documents/adultascitesenhanced.pdf. Accessed

September 7, 2018.

2. Akriviadis EA and Runyon BA. Utility of an algorithm in differentiating spontaneous from secondary bacterial peritonitis. *Gastroenterology*. 1990;98(1):127-33.
3. Garrison RN, Cryer HM, Howard DA, et al. Clarification of risk factors for abdominal operations in patients with hepatic cirrhosis. *Ann Surg*. 1984;199(6):648-55.
4. Goudie A. Detection of intraperitoneal free gas by ultrasound. *Australas J Ultrasound Med*. 2013;16(2):56-61.

Documented patient informed consent and/or Institutional Review Board approval has been obtained and filed for publication of this case report.

CPC-EM Capsule

What do we already know about this clinical entity?

Multiple findings are associated with pneumoperitoneum that can be detected on ultrasound, but these findings can be subtle.

What is the major impact of the image(s)?

Visualizing air rising to the top of ascites on ultrasound is an easily seen finding and is indicative of perforation.

How might this improve emergency medicine practice?

Detection of free air on ultrasound as part of the assessment of critically ill cirrhotic patients can expedite surgical consultation.

Identifying a Disc-shaped Foreign Body

Michael Lee, Jr., MD, JD*
 Michael George, MD†
 Kate E. Dorney, MD*

*Boston Children's Hospital, Division of Emergency Medicine, Boston, Massachusetts
 †Boston Children's Hospital, Division of Radiology, Boston, Massachusetts

Section Editor: Rick A. McPheeters, DO

Submission history: Submitted November 30, 2018; Revision received January 24, 2019; Accepted January 30, 2019

Electronically published March 5, 2019

Full text available through open access at http://escholarship.org/uc/uciem_cpccem

DOI: 10.5811/cpcem.2019.1.41829

A four-year-old girl presented to the emergency department vomiting after a foreign body ingestion. An anteroposterior plain radiograph demonstrated a disc-shaped foreign body. Ordinarily, a plain radiograph cannot conclusively identify an object as a coin rather than a button battery that requires emergent removal. However, this high-voltage radiograph, windowed to increase contrast, showed the visible face of George Washington to confirm the diagnosis of an ingested quarter. [Clin Pract Cases Emerg Med. 2019;3(2):174-175.]

CASE PRESENTATION

A four-year-old girl presented to the emergency department with several episodes of vomiting; on questioning, she stated that she had swallowed something at daycare. Her parents were unsure whether she had access to button batteries. She had no respiratory distress on physical exam. The hospital obtained a single plain radiograph, an anteroposterior (AP) view of the chest (Image 1), and referred her to our tertiary center. The patient had no lateral film, but on high-contrast windowing of the film, which had been taken at a peak kilovoltage (kVp) of 100, the visible face of George Washington identified the object as a quarter (Images 2 and 3). The quarter was removed endoscopically without complication.

CASE DISCUSSION

In a disc-shaped foreign body ingestion, identifying the foreign body is critical but can be challenging. Esophageal button batteries must be removed emergently, given the high risk of injury, while an esophageal coin can be removed urgently unless the patient cannot manage her secretions.¹ On radiographs, a double halo on the AP view or a step-off seen on a lateral view suggests that a round object is likely to be a button battery.¹ Although the location cannot be definitively determined without a lateral film, an object seen en face in the AP view is more likely to be esophageal than tracheal.^{2,3} Additionally, our patient's symptoms – vomiting and dysphagia without respiratory

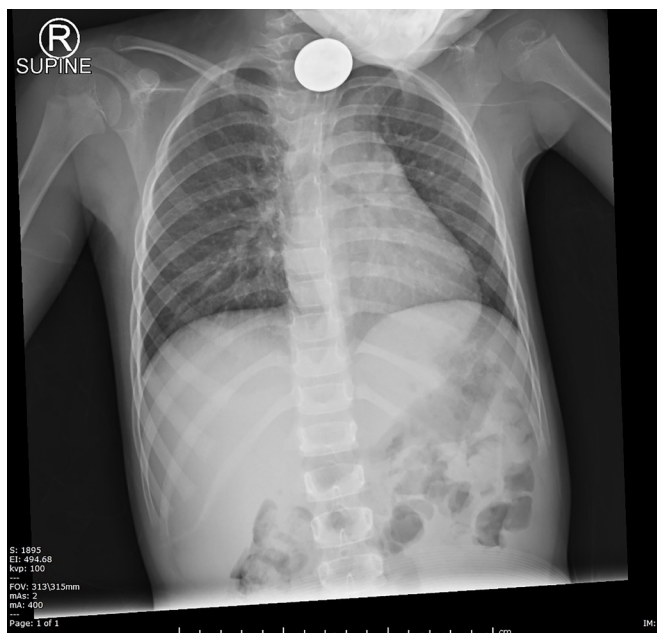


Image 1. Anteroposterior plain radiograph of the chest, demonstrating disc-shaped foreign body. The en face view suggests but does not prove likely esophageal location.

distress – suggested an esophageal location.

In our patient, the unusual visibility of George Washington's face was possible because the image was acquired at 100 kVp, at the higher end of the dose range for

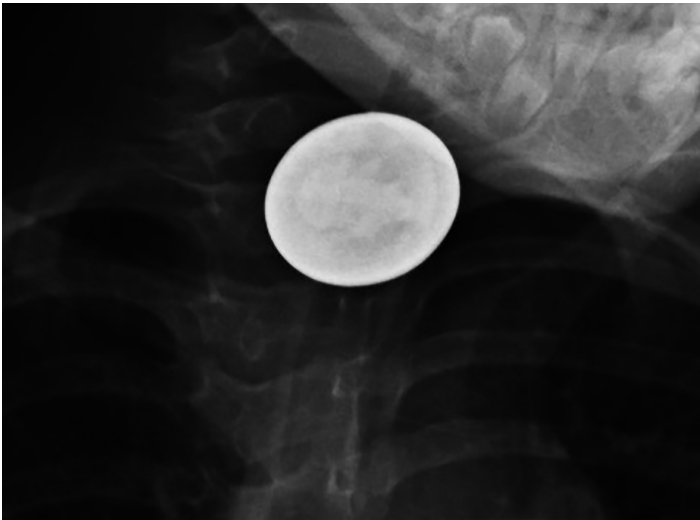

Image 2. Plain radiograph of the chest, windowed to increase contrast. The visible face of George Washington identifies this object as a quarter rather than a button battery.



Image 3. Photograph of a quarter, in a similar orientation to the quarter in Image 2.

patients of this age and size. While somewhat reducing subject contrast, this window allowed the beam to better penetrate metal and therefore enhanced the clarity of the quarter while delivering a lower radiation dose to the patient.⁴

Documented patient informed consent and/or Institutional Review Board approval has been obtained and filed for publication of this case report.

CPC-EM Capsule

What do we already know about this clinical entity?

When a disc-shaped foreign body is seen on a plain radiograph, differentiating between coins and button batteries is critical but can be challenging.

What is the major impact of the image(s)?

The attached radiograph, taken at a peak kilovoltage (kVp) of 100, demonstrated the visible face of George Washington, identifying the object as a quarter.

How might this improve emergency medicine practice?

kVp doses at the high end of the range for a patient's age and weight and high-contrast windowing, may help identify metallic foreign bodies.

Address for Correspondence: Michael Lee, Jr., MD, JD, Boston Children's Hospital, Division of Emergency Medicine, 300 Longwood Ave., Boston, MA 02215. Email: michael.lee@childrens.harvard.edu.

Conflicts of Interest: By the CPC-EM article submission agreement, all authors are required to disclose all affiliations, funding sources and financial or management relationships that could be perceived as potential sources of bias. The authors disclosed none.

Copyright: © 2019 Lee et al. This is an open access article distributed in accordance with the terms of the Creative Commons Attribution (CC BY 4.0) License. See: <http://creativecommons.org/licenses/by/4.0/>

REFERENCES

1. Kramer RE, Lerner DG, Lin T, et al. Management of ingested foreign bodies in children: a clinical report of the NASPGHAN Endoscopy Committee. *J Pediatr Gastroenterol Nutr.* 2015;60(4):562-74.
2. Raney LH and Losek JD. Esophageal coin and atypical radiograph. *Pediatr Emerg Care.* 2008;24(9):645-6.
3. Conners GP and Hadley JA. Esophageal coin with an unusual radiographic appearance. *Pediatr Emerg Care.* 2005;21(10):667-9.
4. Bushberg JT, Seibert JA, Leidholdt EM, et al. (2002). *The Essential Physics of Medical Imaging* (2nd ed.). Philadelphia, PA: Lippincott Williams & Wilkins.

Adding Insult to Injury: Asymptomatic Fat Embolism Identified on Computed Tomography

Malia J. Moore, MD
Sophia Y. Liu, MD

Carl R. Darnall Army Medical Center, Department of Emergency Medicine, Fort Hood, Texas

Section Editor: Anna McFarlin, MD

Submission history: Submitted December 3, 2018; Revision received February 5, 2019; Accepted February 8, 2019

Electronically published April 2, 2019

Full text available through open access at http://escholarship.org/uc/uciem_cpem

DOI: 10.5811/cpcem.2019.2.41888

Fat embolism (FE) is a classically taught complication of long bone fractures, with the potential to cause high morbidity and mortality; however, it is rarely apparent on emergency department (ED) presentation or imaging. If recognized by the ED clinician, development of symptoms of FE may be avoided by early surgical fixation and potentially by corticosteroid administration. [Clin Pract Cases Emerg Med. 2019;3(2):176-177.]

CASE PRESENTATION

The patient was an adult male involved in a high-speed motor vehicle collision into a tree, with prolonged extrication due to vehicle deformity. On initial trauma exam, he had obvious left femur and left wrist deformities. A radiograph of the left hip revealed a femur fracture (Image 1). Computed tomography (CT) of the head, spine, chest, abdomen, and

pelvis were performed. Imaging identified a fat embolism (FE) in the left common femoral vein (Images 2 and 3).

DISCUSSION

CT images showed a fat fluid level within the left common femoral vein as a direct complication of femur fracture. FE is a rare syndrome in which fat globules migrate into vasculature, most commonly from traumatized adipose tissue or marrow-containing bone. FE can complicate a wide variety of conditions, most commonly long bone or pelvic fractures. Symptomatic fat emboli present with a triad of

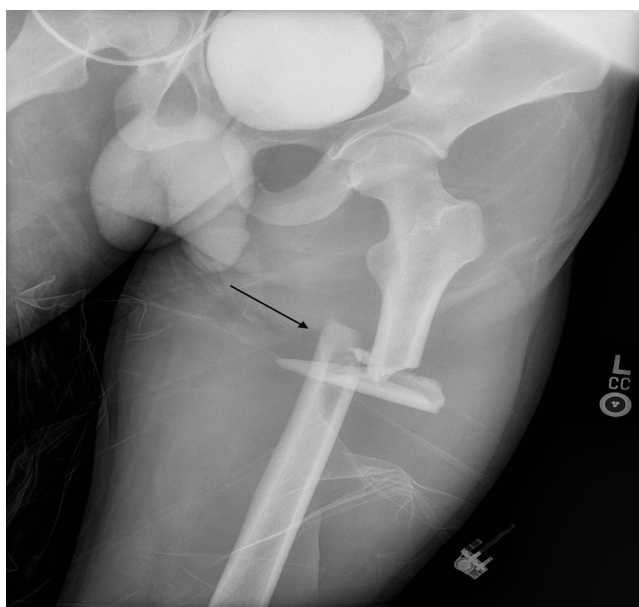


Image 1. Radiograph of the left hip demonstrating segmental, displaced, and shortened left femur fracture (arrow).

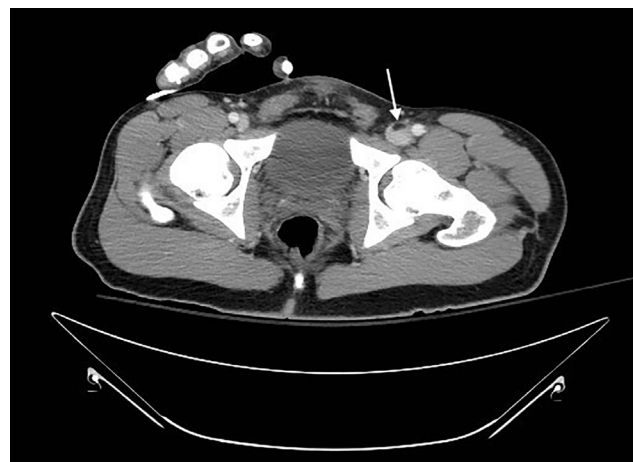


Image 2. Computed tomography of the pelvis in axial view showing fat fluid level within the left common femoral vein (arrow).

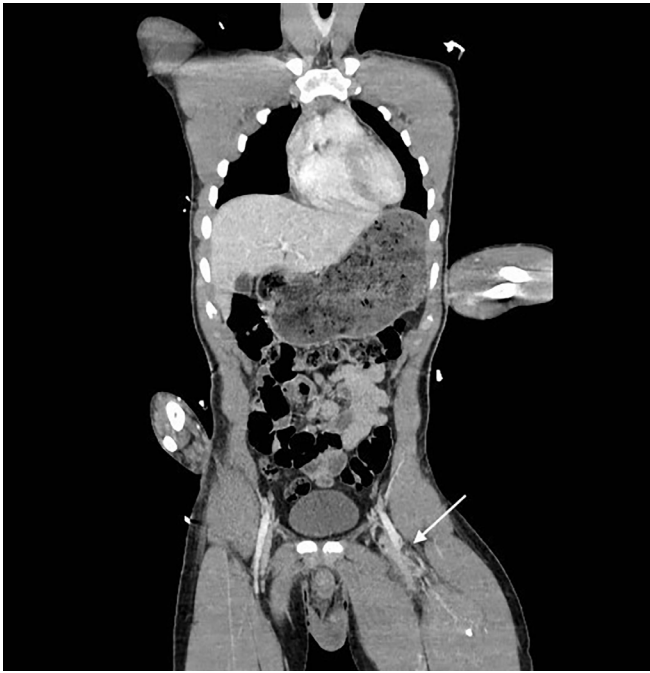

Image 3. Computed tomography image of the chest, abdomen, and pelvis in coronal view showing fat fluid level within the left common femoral vein (arrow).

hypoxemia, neurologic abnormality, and petechial rash. Although care is largely supportive, the patient should be carefully monitored with pulse oximetry, frequent neurologic checks, and re-examination to promptly identify and treat development of FE syndrome. All symptoms are transient if not fatal.^{1,2}

Early recognition of FE may prompt steps to avoid development of the clinical syndrome, such as early surgical fixation, which is preferred over traction, and corticosteroid administration. Corticosteroids have shown some benefit, especially in high-risk injuries with confirmed fat emboli; however, their routine empiric administration is controversial.³⁻⁵

Documented patient informed consent and/or Institutional Review Board approval has been obtained and filed for publication of this case report.

REFERENCES

1. Shaikh N. Emergency management of fat embolism syndrome. *J Emerg Trauma Shock*. 2009;2(1):29-33.
2. Kosova E, Bergmark B, Piazza G. Fat embolism syndrome. *Circulation*. 2015;131(3):317-20.
3. Schonfeld SA, Ploysongsang Y, DiLisio R, et al. Fat embolism prophylaxis with corticosteroids. A prospective study in high-risk patients. *Ann Intern Med*. 1983;99(4):438-43.
4. Bederman SS, Bhandari M, McKee MD, et al. Do corticosteroids reduce the risk of fat embolism syndrome in patients with long-bone fractures? A meta-analysis. *Can J Surg*. 2009;52(5):386-93.
5. Sen RK, Tripathy SK, Krishnan V. Role of corticosteroid as a prophylactic measure in fat embolism syndrome: a literature review. *Musculoskelet Surg*. 2012;96(1):1-8.

CPC-EM Capsule

What do we already know about this clinical entity?

Fat embolism (FE), a condition in which fat globules migrate into vasculature, is a known complication of long bone fractures that could lead to the development of FE syndrome.

What is the major impact of the image(s)?

The asymptomatic finding of FE in transit shown here is believed to be rare; however, its identification could help avoid the development of FE syndrome.

How might this improve emergency medicine practice?

Early identification of FE may prompt treatment and lessen the risk of morbidity and mortality associated with FE syndrome.

Address for Correspondence: Malia J. Moore, MD, Carl R. Darnall Army Medical Center, Department of Emergency Medicine, 36065 Santa Fe Drive, Fort Hood, TX 76544. Email: majmoore@gmail.com.

Conflicts of Interest: By the CPC-EM article submission agreement, all authors are required to disclose all affiliations, funding sources and financial or management relationships that could be perceived as potential sources of bias. The authors disclosed none. The views expressed here are those of the authors and do not reflect the official policy of the Department of the Army, the Department of Defense, or the US Government.

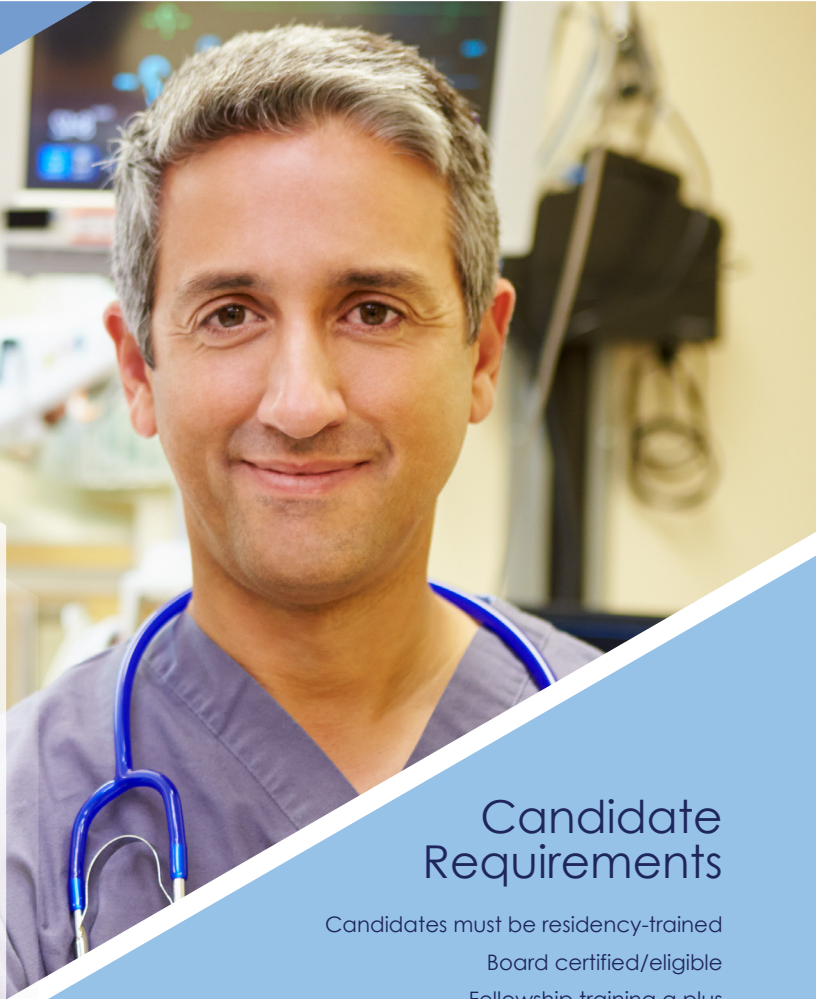Copyright: © 2019 Moore et al. This is an open access article distributed in accordance with the terms of the Creative Commons Attribution (CC BY 4.0) License. See: <http://creativecommons.org/licenses/by/4.0/>



WE'RE HIRING!

Emergency Medicine Faculty Position

Kern Medical is in search of an enthusiastic, academically minded, Emergency Medicine trained physician who is interested in a faculty position in our Emergency Medicine Residency Program. Our residency program maintains full accreditation by the RRC/ACGME and is affiliated with UCLA.



Candidate Requirements

- Candidates must be residency-trained
- Board certified/eligible
- Fellowship training a plus
- Strong interest in academic emergency medicine
- Eligible for license to practice medicine in California
- Pursue faculty appointment at UCLA

Benefits

- Competitive compensation package, commensurate with qualification and experience
- Full-time, employed position
- Salary, additional shifts, starting bonus, relocation bonus
- Vacation, Sick, Paid Education Leave and CME
- Reimbursement
- Health Benefits, Retirement
- Malpractice and tail coverage provided
- Loan Forgiveness Program Qualification

Kern Medical Overview

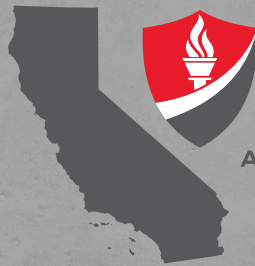We train over 200 medical students, residents and fellows with graduate medical education programs in many specialties including Emergency Medicine. The hospital is the only designated level II trauma center in Kern County and serves as a tertiary medical center. Our emergency department cares for approximately 49,000 patients a year and is an accredited stroke center. The emergency medicine residency is affiliated with UCLA and has been in operation since 1976. Our department has enjoyed strong, responsible and ongoing institutional support.

Located in California's San Joaquin Valley just 90 minutes north of Los Angeles, Kern County is within driving distance of beaches, mountains and several national parks, including Yosemite.

Qualified and interested individuals should contact:

Melanie Brassfield | Director of Physician Recruitment
Melanie.Brassfield@KernMedical.com
(661) 326.2610

**JOIN
CAL/AAEM!**



CALAAEM

CALIFORNIA CHAPTER DIVISION OF THE
AMERICAN ACADEMY OF EMERGENCY MEDICINE

*Championing
individual physician rights
and workplace fairness*

BENEFITS

- *Western Journal of Emergency Medicine* Subscription
- CAL/AAEM News Service email updates
- Discounted AAEM pre-conference fees
- And more!

CAL/AAEM NEWS SERVICE

- Healthcare industry news
- Public policy
- Government issues
- Legal cases and court decisions

In collaboration with our official journal

WestJEM Integrating Emergency Care
with Population Health



FACEBOOK.COM/CALAAEM



FOLLOW US @CALAAEM

[HTTP://WWW.CALAAEM.ORG](http://www.calaaem.org)



ADVANCED >

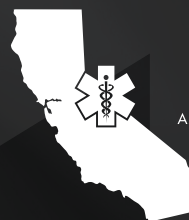YOUR LIFE IN EMERGENCY MEDICINE

> CALIFORNIA ACEP'S ANNUAL CONFERENCE 2019

Education is targeted to Medical Students and Residents, but all are welcome to attend.

Friday, September 20, 2019

Hyatt Regency, Orange County, CA



CALIFORNIA ACEP
AMERICAN COLLEGE OF EMERGENCY PHYSICIANS