

UC Davis

Dermatology Online Journal

Title

Lues maligna praecox: an important consideration in HIV-positive patients with ulceronodular skin lesions

Permalink

<https://escholarship.org/uc/item/5mj272nw>

Journal

Dermatology Online Journal, 21(3)

Authors

Hanson, Cody
Fischer, Ryan
Fraga, Garth
[et al.](#)

Publication Date

2015

DOI

10.5070/D3213023984

Supplemental Material

<https://escholarship.org/uc/item/5mj272nw#supplemental>

Copyright Information

Copyright 2015 by the author(s). This work is made available under the terms of a Creative Commons Attribution-NonCommercial-NoDerivatives License, available at <https://creativecommons.org/licenses/by-nc-nd/4.0/>

Peer reviewed

Case presentation

Lues maligna praecox: an important consideration in HIV-positive patients with ulcero-nodular skin lesions

Cody Hanson¹, Ryan Fischer¹, Garth Fraga², Anand Rajpara¹, Daniel Hinthorn³, Daniel Aires¹, Deede Liu¹

Dermatology Online Journal 21 (3): 8

¹Department of Dermatology, ²Department of Pathology, ³Department of Internal Medicine, University of Kansas Medical Center

Correspondence:

Cody Hanson
Department of Dermatology
The University of Kansas Medical Center
CHanson@kcumb.edu

Abstract

Syphilis is commonly known as “the great imitator” owing to its varied clinical manifestations. Secondary syphilis has a variety of presentations, with the most common manifesting as a diffuse papulosquamous eruption on the palms and soles. Lues maligna praecox is a rare form of secondary syphilis, with severe constitutional symptoms, seen primarily in HIV-positive individuals. We report an atypical case of suspected lues maligna in a 45-year-old male. The patient was HIV-positive with a CD4 count of 441. He presented to our clinic with large painful gummatous ulcers in the groin and lower back. He also reported daily fevers, night sweats, and weight loss consistent with secondary syphilis. Prior to this episode the patient had a history of acute active syphilis (RPR 1:128) in 2012 treated at that time with a single dose of 2.4 million units intramuscular benzathine penicillin; he had no reported exposures since that time. The patient was treated with three weekly doses of benzathine penicillin, 2.4 million units, given intramuscularly. This case demonstrates the importance of recognizing the varied clinical presentation of secondary syphilis and keeping lues maligna in consideration for ulcero-nodular skin lesions in patients who are HIV-positive.

Case synopsis

A 45-year-old man with known HIV diagnosed in 2008 presented to the outpatient clinic with a three-week history of painful ulcers on the back and groin. The patient reported that these ulcers began five weeks prior as small papules and quickly enlarged and ulcerated. The patient had no knowledge of a primary chancre. He was previously seen in the emergency department and internal medicine clinic during the papulopustular stage and was treated with both trimethoprim-sulfamethoxazole and doxycycline, with no improvement in symptoms. He had been experiencing fever, chills, night sweats, localized bone pain, and reported weight loss of 20-30 pounds over the five weeks that the skin lesions had been present. At the time of evaluation, he denied any neurologic or psychiatric symptoms, although he did admit to some visual changes (diplopia). His last RPR was negative four months prior, with his last positive RPR in 2012 at 1:128 during an acute episode of syphilis following initial exposure. He was treated with a single dose of 2.4 million units intramuscular benzathine penicillin at that time. Physical examination revealed well demarcated ulcers with surrounding erythema measuring 3 x 3 cm on the midline lower back (Figures 1, 2) and 3 x 1.5 cm on the right groin adjacent to the scrotum (Figure 3). The ulcers appeared gummatous and were tender, firm, and crusted on evaluation. There were also multiple small papules and pustules on the arms and thorax (Figure 4). Prominent lymphadenopathy was palpated in the groin bilaterally. Genital exam was negative for condyloma lata and examination of hands and feet did not reveal any skin lesions. A 4-mm punch biopsy was obtained from the edge of the lesion on the mid-back. Clinical differential diagnoses included tertiary syphilis, other infectious causes, and malignancy.

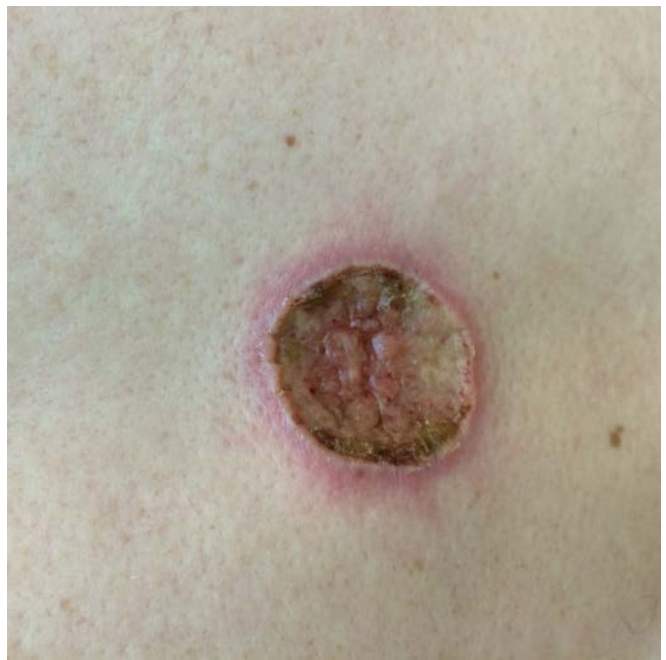
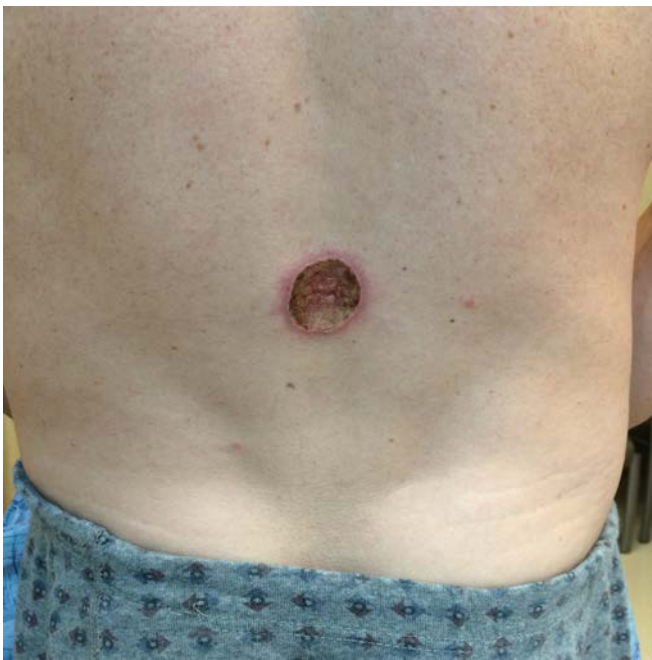
Figure 1 and 2. Well-demarcated gummatous ulcer with surrounding erythema on the lower back.

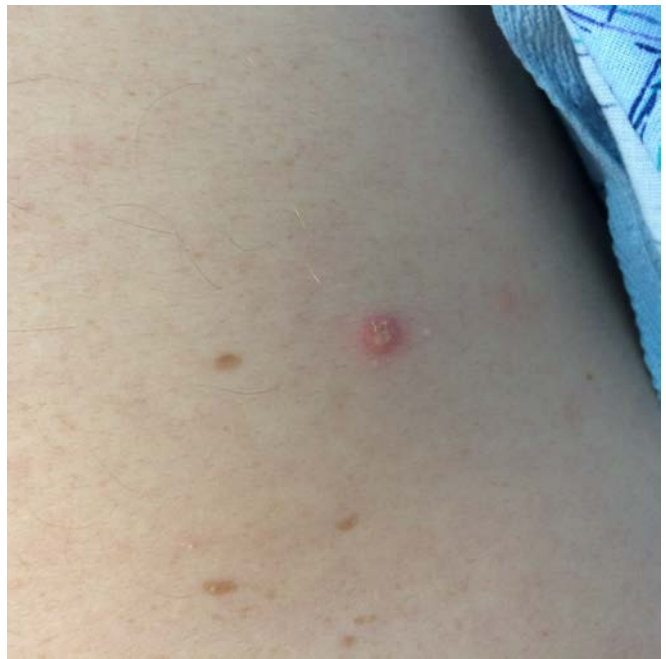
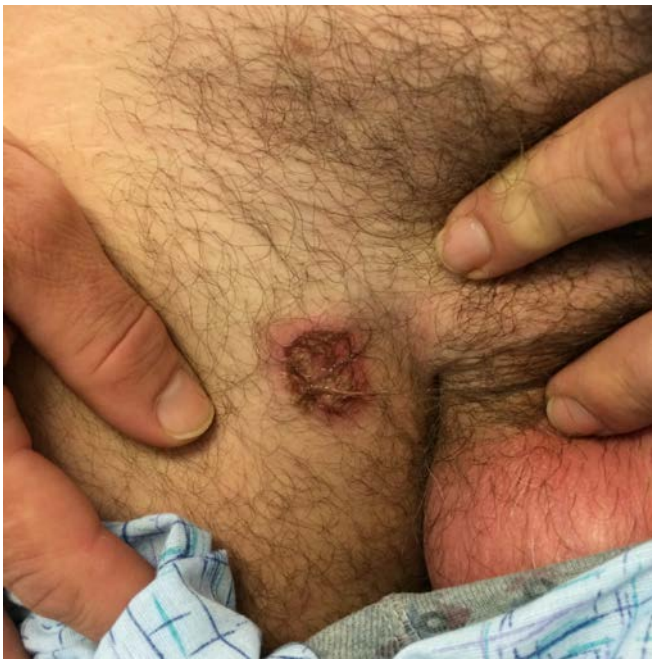
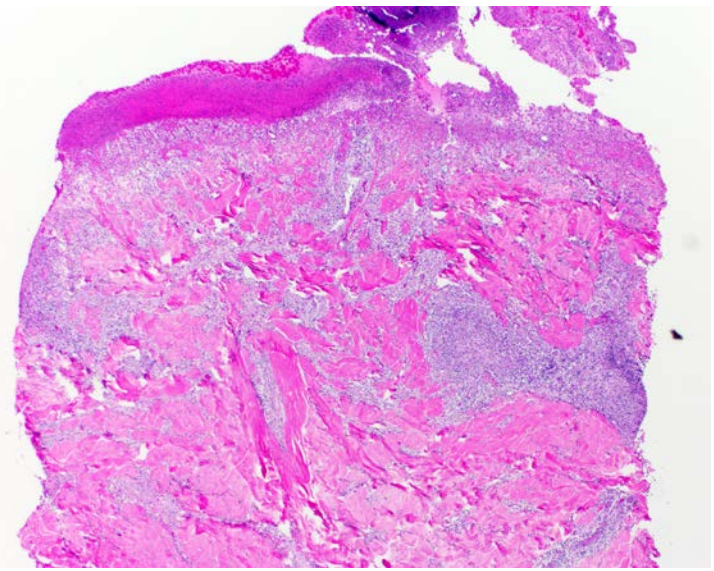
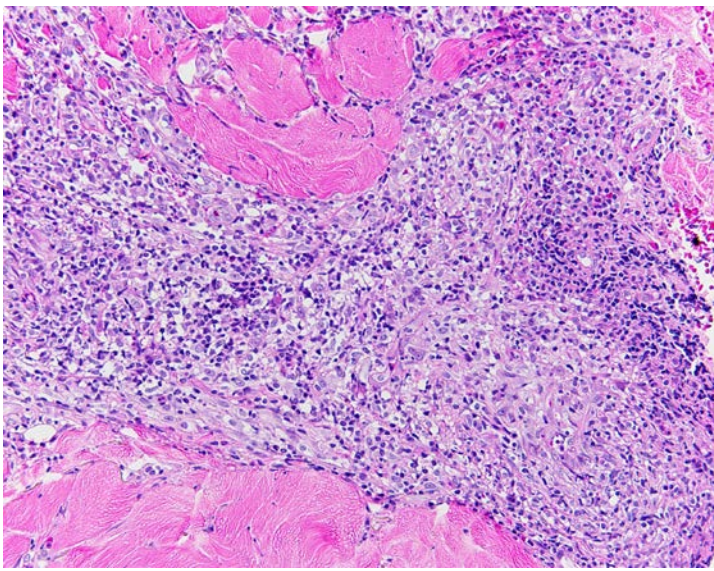
Figure 3 and 4. Gummatous ulcer on the right groin and pustule on the right upper arm.

Pertinent laboratory findings revealed an RPR of 1:256, negative TB spot, CD4 of 441, HIV viral load of 254, albumin decreased at 3.1, phosphorus elevated at 4.2, and alkaline phosphatase elevated at 241.

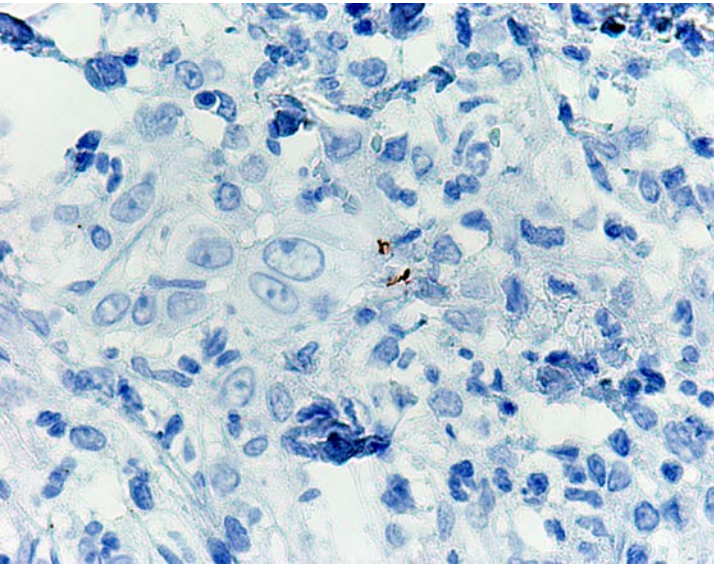
Lumbar puncture was performed owing to concerns of CNS involvement and the patient was found to have normal glucose, no xanthochromia, high-normal protein of 45, and a negative VDRL.

Bone flow imaging revealed intensity in the right navicular bone with associated sclerotic changes and extensive bony reparative change in the right distal tibia with heterogenous intense radiotracer uptake, both consistent with secondary syphilis. Abdominal ultrasound revealed mild hepatomegaly and splenomegaly.

Histopathology: Histologic examination of a punched out skin biopsy demonstrated ulceration and perivascular granulomatous dermatitis with rare plasma cells (Figures 5, 6). Immunostaining for *T. pallidum* highlighted rare spirochetes (Figure 7).



Figures 5, 6, and 7. Punch biopsy from the lesion on the lower back revealed ulceration and perivascular granulomatous inflammation with rare plasma cells present. Immunostaining for *Treponema pallidum* demonstrated rare spirochetes.



Following imaging, CSF examination, and histopathology results, the patient was determined to have secondary syphilis without CNS or ocular involvement. He was further admitted and administered the first of three weekly doses of intramuscular benzathine penicillin G, 2.4 million units. He was scheduled to return to the infectious disease clinic on an outpatient basis for two additional doses. The patient will remain on his current antiretroviral treatment for HIV.

Discussion

Syphilis is a sexually transmitted infection caused by the spirochete *Treponema pallidum*. This infection is most common in males and men who have sex with men. Infections are typically categorized into four phases: congenital, primary, secondary, latent, and tertiary. Secondary syphilis typically occurs three to ten weeks after appearance of a primary chancre, which has an average of a three-week incubation period from the time of initial infection. Common cutaneous lesions in secondary syphilis include macular, palmoplantar, mucosal, papulosquamous, and annular lesions. Alopecia may also occur as progressive hair loss on the scalp in a “moth-eaten” appearance. Although this type of hair loss may mimic alopecia areata, exclamation point hairs are rarely seen in syphilitic alopecia [1] and hair loss typically resolves within three months of treatment [2]. Uncommon presentations include hypopigmented plaques, granulomatous nodules and plaques, and malignant syphilis, which is seen with necrotic and crusted ulcers and typically presents with severe constitutional symptoms like those seen in our patient [3]. Ulceronodular syphilis or lues maligna praecox is a rare form of secondary syphilis seen with pustular lesions that rapidly progress to painful ulcerative lesions in patients with early HIV infection [4]. Our patient presented with similar skin lesions, although he had been diagnosed with HIV in 2008.

Once diagnosed with syphilis, a lumbar puncture is typically performed in the following situations: HIV-positivity, HIV-negativity with neurologic symptoms, latent syphilis, or multiple treatment failures [5]. Bone imaging may be performed for individuals with localized bone pain and documented syphilis, with lesions in the skull and long bones of the limb being the most common location of involvement for patients with secondary syphilis [6].

The standard treatment for HIV-positive patients with syphilis of unknown duration: one weekly dose of benzathine penicillin G, 2.4 million units, given intramuscularly for three weeks. Alternative treatments that have been used include doxycycline or ceftriaxone in penicillin-allergic patients [7], but our case demonstrates that these may not always be effective because our patient experienced progression of his infection despite treatment with doxycycline at the onset of the skin lesions. Penicillin has also been shown to induce a favorable outcome on patients with bone lesions, with similar outcomes seen in HIV-positive and HIV-

negative patients [6]. Patients with lues maligna often have a dramatic response to penicillin, rapidly improving shortly after onset of treatment [8].

Conclusion

The presentation of syphilis is highly variable, leading to possible confusion in patients with no reported risk factors. Our case report illustrates the importance of considering lues maligna praecox as a cause of ulcero-nodular lesions in any HIV-positive patient with suspected syphilis. Ulcero-nodular syphilis may mimic malignancy and all HIV-positive patients with ulcers should have a biopsy and rapid plasma reagin. The patient who presented to our clinic had a past history of primary syphilis, making the diagnosis of repeat infection more likely. With a rise in the number of cases of syphilis in recent years, it is important for physicians to recognize and treat syphilis early, because irreversible neurologic and cardiac damage may occur in the late stages of the infection.

References

1. Brown TJ, Yen-Moore A, Tying SK. An overview of sexually transmitted diseases: part I. *Journal of The American Academy of Dermatology* 1999; 41(4): 511- 532. [PMID: 10495370]
2. Bi MY, Cohen PR, Robinson FW, Gray JM. Alopecia syphilitica-report of a patient with secondary syphilis presenting as moth-eaten alopecia and a review of its common mimickers. *Dermatology Online Journal*. 2009; 15(10): 6. [PMID: 19951624]
3. Qiao J, Fang H. Moth-eaten alopecia: a sign of secondary syphilis. *Canadian Medical Association Journal*. 2013; 185 (1): 61–61. [PMCID: PMC3537782]
4. Kelly JD, LeLeux TM, Citron DR, Musher DM, Giordano TP. Ulcero-nodular syphilis (lues maligna praecox) in a person newly diagnosed with HIV infection. *British Medical Journal Case Report*. 2011. [PMID: 22689612]
5. Xavier EB, Diniz AS, Sasajima CC, Rochael M, Duraes S. Secondary syphilis with exuberant manifestations. *Journal of the American Academy of Dermatology*. 2013; 68(4): AB124.
6. Park KH, Lee MS, Hong IK, Sung JY, Choi SH, Park SO, Shin MJ, Chung HW, Lee SH. Bone involvement in secondary syphilis: a case report and systematic review of the literature. *Sexually Transmitted Diseases*; 2014; 41(9): 532-537. [PMID: 25118965]
7. Ghanem KG, Erbedding EJ, Cheng WW, Rompalo AM. Doxycycline compared with benzathine penicillin for the treatment of early syphilis. *Clinical Infectious Diseases* 2006; 42(6): e45-e49 [PMID: 16477545]
8. Wang H, Wang X, Li S. A case of lues maligna in an AIDS patient. *International Journal of STD & AIDS* 2012; 23(8): 599-600. [PMID: 22930302]