

# UCLA

## UCLA Previously Published Works

### Title

Magnetic resonance imaging of the posterior cruciate ligament

### Permalink

<https://escholarship.org/uc/item/5kr4v1c9>

### Journal

The American Journal of Sports Medicine, 20(6)

### ISSN

0363-5465

### Authors

Gross, Michael L  
Grover, Jaswinder S  
Bassett, Lawrence W  
et al.

### Publication Date

1992-11-01

### DOI

10.1177/036354659202000615

Peer reviewed

# Magnetic resonance imaging of the posterior cruciate ligament

## Clinical use to improve diagnostic accuracy

MICHAEL L. GROSS,\*† MD, JASWINDER S. GROVER,‡ MD,  
LAWRENCE W. BASSETT,‡ MD, LEANNE L. SEEGER,‡ MD, AND  
GERALD A. M. FINERMAN,\* MD

*From the \*Division of Orthopaedic Surgery and the ‡Department of Radiological Sciences, University of California, Los Angeles, California*

### ABSTRACT

This study was undertaken to determine the accuracy of magnetic resonance image scanning in detecting posterior cruciate ligament injury, and to determine those clinical situations where it can add the most useful information. A retrospective study was conducted on 201 patients who underwent surgery after magnetic resonance scanning of their knees. Two additional patients who did not have surgery but had clinical findings grossly positive for posterior cruciate ligament injury were included in the analysis of magnetic resonance imaging accuracy. In all, there were 190 intact and 13 torn posterior cruciate ligaments. In a review of the clinical findings in the 11 patients with surgically documented tears, we found that all 11 had positive magnetic resonance scans. In 4 of the 11, magnetic resonance imaging provided especially useful information regarding the status of the ligament. For the 190 normal ligaments, there were no false-positive scans; for the 13 torn ligaments, there were no false-negative scans. Therefore, specificity and sensitivity estimates for this group were both 100%.

Magnetic resonance imaging proved to be an accurate modality for evaluating the integrity of the posterior cruciate ligament. If used in the proper setting, it can provide useful information for diagnosing posterior cruciate ligament injuries.

The number of injuries to the PCL has increased over the past several years.<sup>6,7</sup> At the same time, the literature has

reflected a growing awareness of the role played by the PCL in knee stability.<sup>2</sup> Hughston et al.<sup>15</sup> stressed the importance of the PCL as the prime stabilizer of the knee joint and emphasized that it serves as the central axis about which normal and abnormal rotations occur. Butler et al.<sup>5</sup> reported that the PCL contributed 95% of the total restraint to displacement of the tibia.

While an accurate, early diagnosis is imperative for effective treatment of the PCL disruption, it is not easily arrived at soon after injury.<sup>1,3,6-10,14-16,19</sup> Pain, swelling, or protective muscle spasm may make physical examination difficult and delay diagnosis. Furthermore, no single finding on physical examination has been identified as 100% diagnostic for PCL tears.<sup>1,12,19,22,24</sup> Consequently, patients with PCL injury may present with a lack of convincing physical findings.

Although the treatment of acute isolated injuries of the PCL remains controversial, the recent trend toward early surgical intervention underscores the need for a reliable, reproducible method of evaluation.<sup>2,11</sup> In knees with multiple ligament injuries, failure to recognize acute disruptions of the PCL leads to inappropriate treatment and disappointing results.<sup>1,3,7,10,15,16</sup> Unless the surgeon is alerted to the possibility of a PCL injury, it may be overlooked intraoperatively since this ligament lies invested in synovium, which may need to be opened for adequate visualization. Thus, for patients with multiple ligament injuries who sometimes present with confusing physical findings, a diagnostic test with a high level of specificity would be useful.

Magnetic resonance imaging (MRI) is well established in the literature as an important adjunct to the proper diagnosis and treatment of soft tissue injuries in the knee.<sup>4,17,20,21,23</sup> While studies have indicated that the PCL can be visualized on MRI scans, none of them have included

† Address correspondence and reprint requests to: Michael L. Gross, MD, Orthopaedic and Sports Medicine Associates, 440 Old Hook Road, Emerson, NJ 07630.

enough positive and negative findings to estimate the accuracy of MRI scans in detecting injury to the PCL with much precision.

The purpose of this study was twofold: 1) to assess the accuracy of MRI in detecting injury to the PCL, and 2) to determine the appropriate role of MRI in the evaluation of a patient with a suspected PCL injury. In this report, we present a clinical grading scheme useful for evaluating the appearance of the PCL on MRI scans. We also describe the normal appearance of the PCL on MRI and identify anatomic factors that can produce variations in its appearance.

## MATERIALS AND METHODS

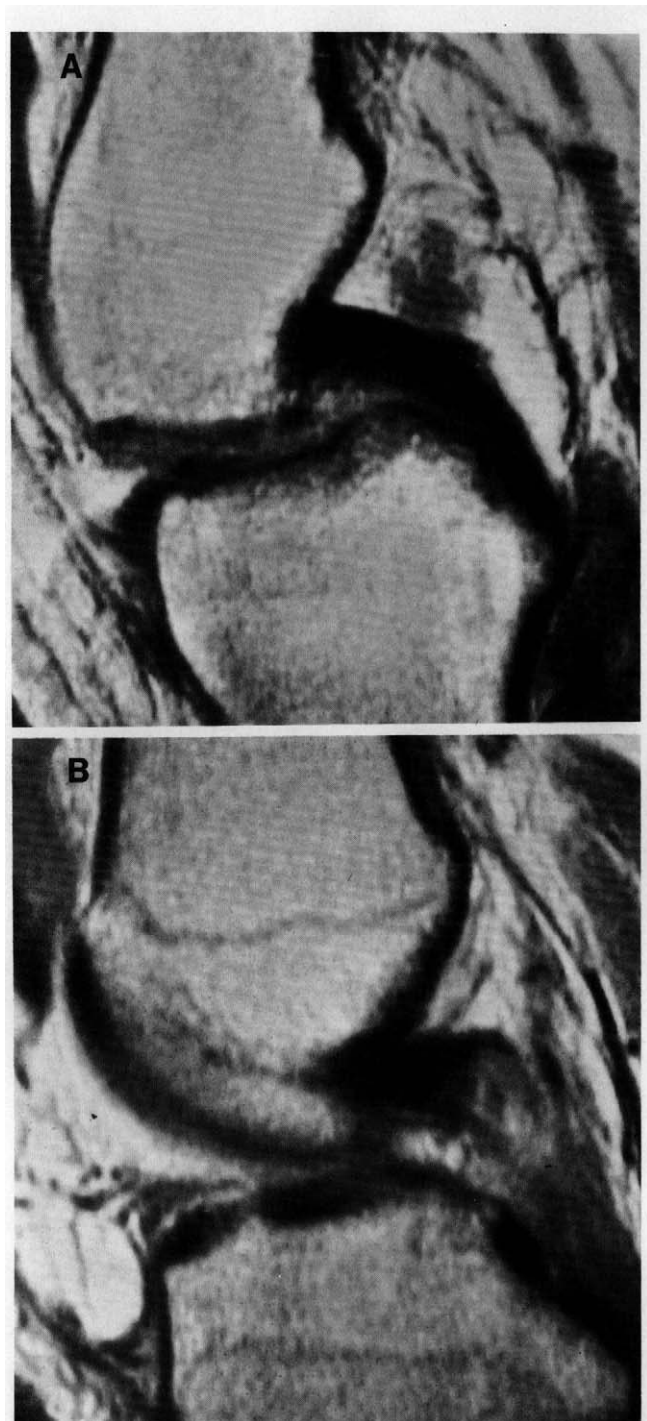
We conducted a retrospective review of the medical records, MRI scans, and surgical findings of 203 knees with regard to the PCL. The review included 201 consecutive patients who underwent MRI scanning and had subsequent arthroscopy or arthrotomy and 2 patients who had grossly positive physical findings, but who were not operated on because of other medical problems. We used consecutive patients, rather than only those with suspected PCL injury, to produce a more valid sample. In total, 190 intact and 13 torn ligaments were studied.

We recorded the following data from the medical records: 1) presenting history, including chief complaints and mechanism of injury; and 2) presence or absence of significant physical findings referable to the PCL. The latter included effusion, ecchymosis, AP instability, positive posterior drawer test, posterior sag, and varus/valgus instability in full extension. An assessment of the clinical impression before MRI scanning was recorded from the medical record when available, or by questioning the treating physician directly.

Examinations by MRI were performed with the patient in the supine position with the knee in 0° to 15° of flexion and 20° of external rotation. A 0.3 tesla magnet and a solenoid surface coil in the popliteal fossa were used to produce T1-weighted images in the sagittal plane with 5-mm slices at 5-mm intervals. The PCL was well visualized in all 203 cases.

One radiologist, who was unaware of the presenting diagnosis, reviewed all MRI scans and recorded the appearance of the PCL as either intact or torn. Magnetic resonance scans were considered positive for a tear in the PCL when the normally large, low-intensity band that represents this ligament was seen to be discontinuous (Fig. 1). Ligaments with internal areas of increased signal, but whose borders remained continuous, were judged as intact (Fig. 2). The presence of an abnormal signal was noted separately. Intact ligaments were further subdivided into three groups: arcuate, U-shaped, and kinked (Fig. 3).

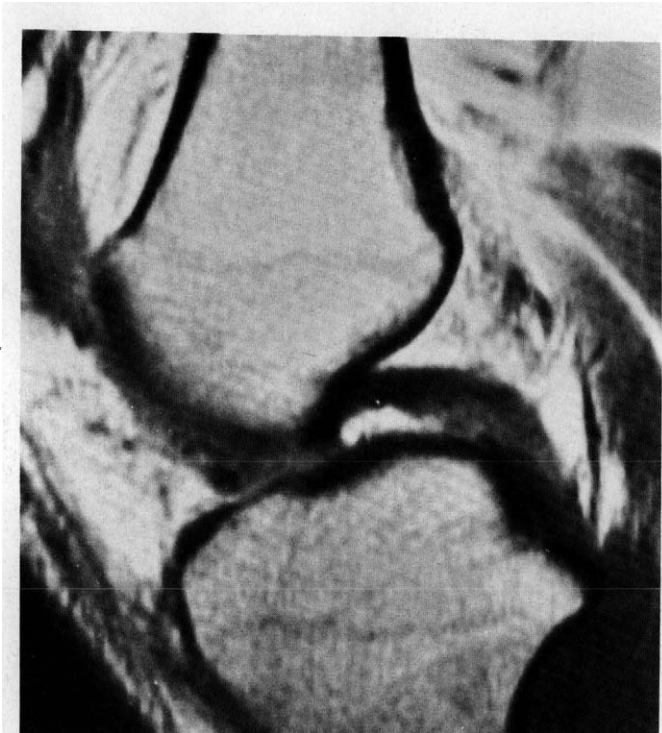Visualization of the PCL at surgery was used as the standard for comparison of findings. While surgery was usually performed for reasons unrelated to the PCL, in all cases the ligament was well visualized at surgery and probed when necessary to evaluate its integrity. In the two patients



**Figure 1.** A, MRI of intact PCL. B, MRI of torn PCL.

who did not undergo surgery, but whose MRI scans identified PCL disruptions, physical examination was used to confirm the MRI findings.

We defined sensitivity as the number of correct positive MRI results divided by the total number of positive results (torn ligaments) found at surgery. Specificity was defined as the number of correct negative MRI results divided by the



**Figure 2.** Area of increased signal within PCL, but ligament judged as intact.

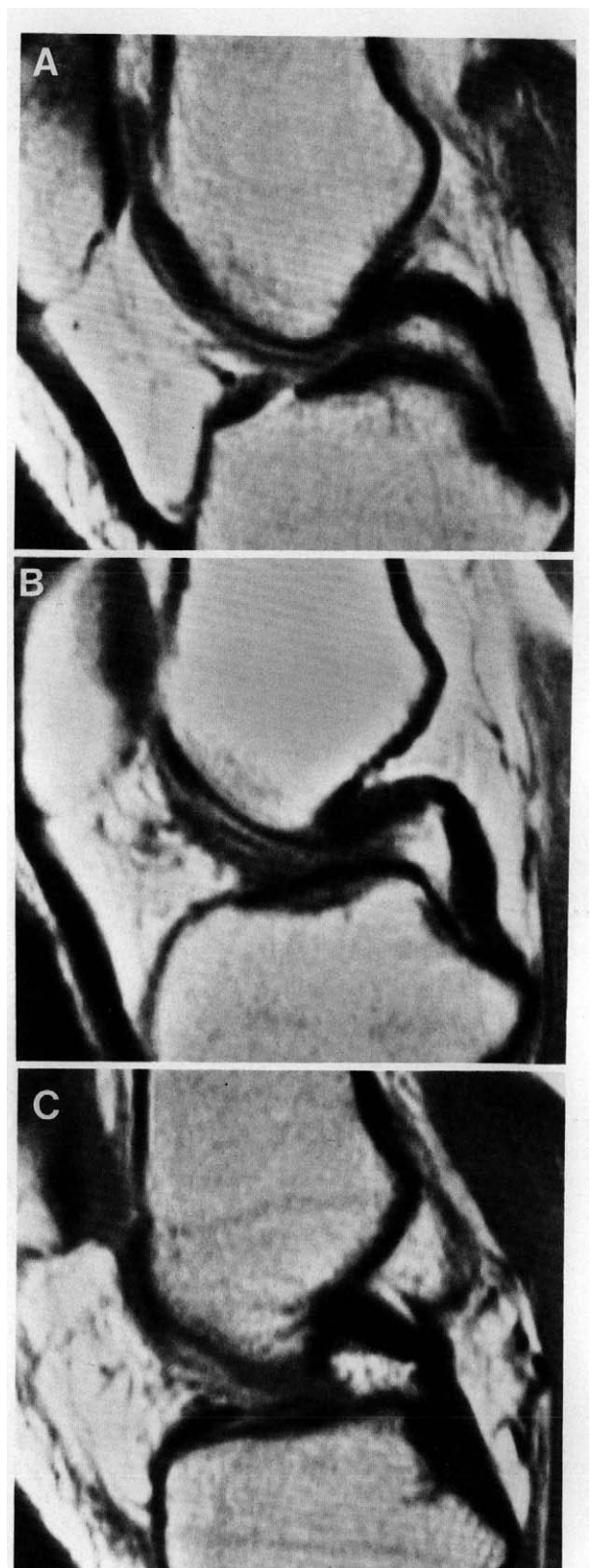
total number of negative results (intact ligaments) found at surgery. We used the sensitivity to calculate the positive predictive value and specificity to calculate the negative predictive value. We defined accuracy as the sum of correct positive MRI results and correct negative MRI results divided by the total number of MRI scans.

## RESULTS

Table 1 summarizes the results of MRI scanning and surgical observation of the PCL. An intact PCL was identified on 190 MRI scans. In two of the 190, the scan indicated an area of increased signal intensity within the ligament, but its borders were judged to be intact. In all 190 cases, the ligament was found to be undamaged at surgery. Thus, of the 190 intact ligaments scanned, all were correctly identified on MRI, resulting in both a specificity estimate and negative predictive value of 100%.

Normal ligaments were subdivided into three groups based on their appearance on MRI scans: arcuate (88.2%), kinked (7.8%), or U-shaped (4.0%). This classification of ligament appearance did not correlate with any morphologic characteristics of the ligament found at surgery or with injury found in other structures in the knee.

In 13 cases, MRI scans were interpreted as positive for a tear in the PCL. These findings, confirmed at surgery in 11 patients and on physical examination in the 2 who did not undergo surgery, yielded a sensitivity and positive predictive value of 100%. The accuracy of MRI scanning in this study, therefore, was 100%. The 95% confidence levels were cal-



**Figure 3.** Variations in the normal appearance of the PCL. A, arcuate; B, U-shaped; C, kinked.

**TABLE 1**  
Comparison of MRI and surgical results in evaluation of PCL tears

MRI results	Surgical evaluation		
	Torn	Intact	Total
Torn	13/11 <sup>a</sup>	0	13
Intact	0	190	190
Total	11	190	203
Sensitivity	100%		
Specificity	100%		

<sup>a</sup> Two cases confirmed by physical examination alone.

culated for specificity and sensitivity and found to be [0.98, 1.00] and [0.75, 1.00], respectively.

Table 2 presents the results of the clinical observations and MRI scanning of the 11 patients with surgically documented tears of the PCL. These patients are divided into three groups based on clinical suspicion: positive, equivocal, and negative. In 7 of the 11, history and physical examination alone were enough to correctly identify PCL tears; AP instability was detected and correctly attributed to PCL disruption. In the remaining 4 cases, the diagnosis based on clinical grounds alone was either equivocal or incorrect. Two of the 4 had multiple ligament injuries where PCL disruption was suspected. In both cases, AP instability was detected, but its source could not be identified, nor was posterior sag noted. The MRI scan, however, indicated a torn PCL, which was eventually confirmed at surgery. A third case presented with increased AP excursion and a hemarthrosis that was attributed to an acute ACL disruption. The MRI scan identified an intact ACL and a torn PCL, findings that were confirmed at surgery. A fourth case presented with a physical examination suggestive of a meniscal tear, with no findings related to the PCL. However, the MRI scan clearly identified a disruption in the PCL, a finding that was later documented at arthroscopy (Fig. 4). In summary, MRI was able to correctly identify PCL tears in the 4 patients with either equivocal or incorrect preliminary diagnoses.

**DISCUSSION**

Magnetic resonance imaging, used to evaluate injury to the ACL and lateral and medial menisci, holds promise as a diagnostic tool for tears of the PCL as well. In fact, evalua-

tion of the PCL should yield better results than the ACL since it is more consistently visualized and minor degrees of rotation have less of an effect. Indeed, previous studies that reported consistently high levels of accuracy for MRI of both the ACL and the menisci,<sup>4,17,20,21,23</sup> have also demonstrated that this technology has an excellent capacity to visualize the PCL.

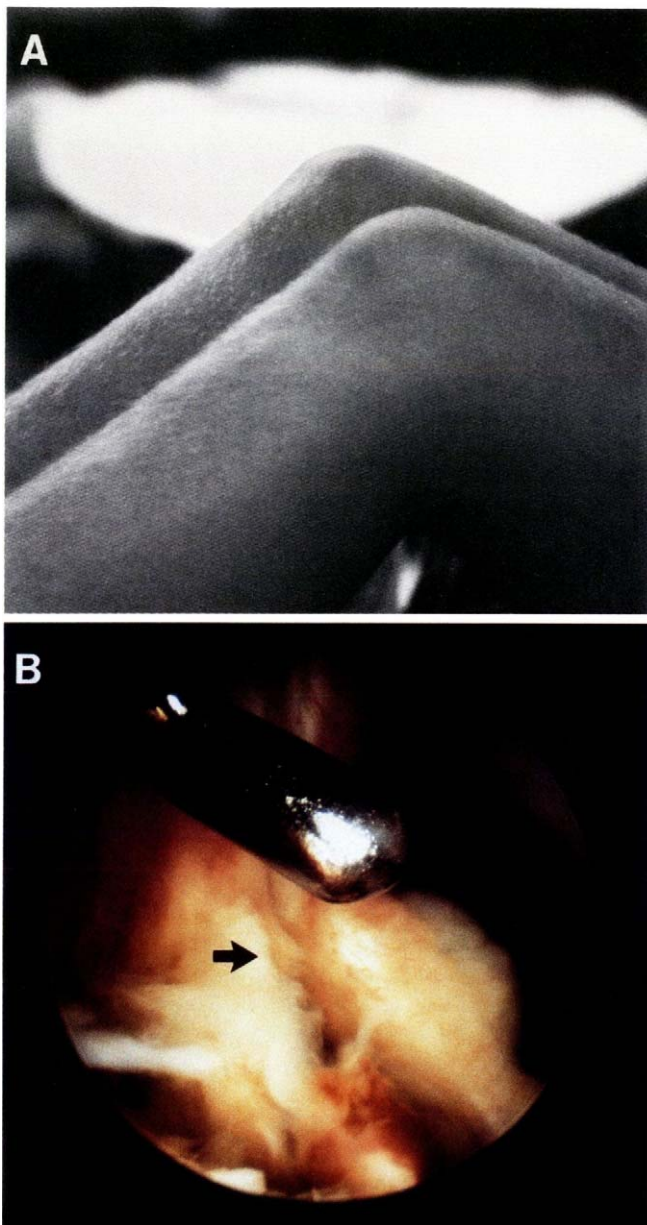
In the present study, values of 100% were estimated for sensitivity, specificity, positive and negative predictive values, and accuracy. We reported this previously in the radiology literature.<sup>13</sup> Here we have expanded our analysis to evaluate the implications of this data in the clinical setting. To evaluate the validity of these findings, 95% confidence intervals for sensitivity and specificity were calculated. The values calculated reflect the small number of surgically proven tears of the PCL in this study. What can be gathered from the data, however, is a high level of confidence when a positive result is reported from MRI. Although the data do not rule out the possibility of false-negative results, they show that a negative result will probably be correct in at least 75% of cases, and perhaps as high as 100%.

We attempted to eliminate as much of the selection bias as possible by using consecutively scanned patients who had surgery, rather than only those referred with suspected PCL tears. The study did not address the accuracy of clinical findings in those patients who did not have MRI scans because its sole purpose was to determine the accuracy of MRI in detecting injuries to the PCL and to ascertain the best use of this data in the clinical setting. The true value of a diagnostic test in the clinical setting is determined by how it contributes to the decision making process.

Indeed, it is important to realize that MRI will prove most useful in specific clinical situations. For the patient who has a strong positive history combined with positive physical findings, MRI evaluation is not likely to contribute significant information regarding the PCL. When the clinical impression concerning the PCL is equivocal, either due to a disparity between the presenting history and physical findings or because of an incomplete or confusing examination, MRI can provide useful and accurate additional information about the status of this ligament. In rare cases, MRI may prove useful when there is no suspicion that a PCL injury exists, but a scan is obtained for other reasons. If the scan

**TABLE 2**  
Results of clinical findings and MRI scans in surgically proven PCL tears (N = 11)

Correlation with clinical suspicion	Mechanism of injury	Swelling	Echymosis	Posterior sag	AP instability	Posterior drawer test	Varus/valgus in extension	MRI scan
Correct	Direct blow	2+	+	+	+	+	-	+
	Hyperflexion	2+	+	+	+	+	-	+
	Unknown	-	+	-	+	+	+	+
	Direct blow	-	+	-	+	+	N/A	+
	Fall on tibia	-	-	+	+	+	+	+
	Twisting	2+	-	+	+	+	N/A	+
	Direct blow	-	+	+	+	+	-	+
Equivocal	Skiing	2+	-	-	+	±	+	+
	Skiing	4+	-	-	+	±	N/A	+
Incorrect	Skiing	1+	+	-	+	-	N/A	+
	Direct blow	1+	-	-	-	-	-	+



**Figure 4.** Patient with negative history and physical findings but with MRI correctly identifying a tear in his PCL. A, note the lack of swelling or posterior sag in right knee. B, arthroscopic view of PCL showing complete disruption.

indicates an injury to the PCL, the patient should be reassessed in light of the new information supplied by the MRI, with its high degree of reliability. The exact significance of areas of increased intensity within the ligament remains unclear. No corresponding changes could be found in the ligament on direct visualization. The areas of increased intensity are probably caused by intraligamentous hemorrhage or edema. Studies by Kennedy et al.<sup>18</sup> have demonstrated that injury to the microstructure of the ligament will occur before there is any apparent damage of direct visuali-

zation. No classification system for PCL appearance on MRI currently exists. We suggest the following grading scale: 0, continuous low-intensity signal corresponding to the normal PCL; I, areas of increased signal within the ligament but with the borders intact; II, area of increased signal with one border intact; and III, complete disruption of the ligament. Grade I images probably correspond to ligaments with internal injury, Grade II to partial tears, and Grade III to complete tears. The clinical significance of Grade I and II injuries requires further study.

While the normal PCL most commonly appears as a smooth arc on MRI scans, variations in shape do not necessarily indicate injury. Both U-shaped and kinked variants have been identified. In this study, neither has been associated with tears or damage to the PCL or in other parts of the knee.

## REFERENCES

- Baker CL, Norwood LA, Hughston JC: Acute combined posterior cruciate and posterolateral instability of the knee. *Am J Sports Med* 12: 204-208, 1984
- Barton TM, Torg JS, Das M: Posterior cruciate ligament insufficiency. A review of the literature. *Sports Med* 1: 419-430, 1984
- Bianchi M: Acute tears of the posterior cruciate ligament. Clinical study and results of operative treatment in 27 cases. *Am J Sports Med* 11: 308-314, 1983
- Burstein DB, Fritts HM, Fischer DA: Diagnosis of meniscus and cruciate ligament tears using MRI. Evaluation of two scanning techniques. *Minn Med* 74: 29-32, 1991
- Butler DL, Noyes FR, Grood ES: Ligamentous restraints to anterior-posterior drawer in the human knee. A biomechanical study. *J Bone Joint Surg* 62A: 259-270, 1980
- Clancy WG, Shelbourne KD, Zoellner GB, et al: Treatment of knee joint instability secondary to rupture of the posterior cruciate ligament. Report of a new procedure. *J Bone Joint Surg* 65A: 310-322, 1983
- Gross MJ, Powell JF: Long-term followup of posterior cruciate ligament rupture: A study of 116 cases. *Am J Sports Med* 12: 292-297, 1984
- Dandy DJ, Pusey RJ: The long-term results of unrepaired tears of the posterior cruciate ligament. *J Bone Joint Surg* 64B: 92-94, 1982
- Daniel DM, Stone ML, Barnett P, et al: Use of the quadriceps active test to diagnose posterior cruciate-ligament disruption and measure posterior laxity of the knee. *J Bone Joint Surg* 70A: 386-391, 1988
- Fleming RE, Blatz DJ, McCarroll JR: Posterior problems in the knee. Posterior cruciate insufficiency and posterolateral rotatory insufficiency. *Am J Sports Med* 9: 107-113, 1981
- Fowler PJ, Messieh SS: Isolated posterior cruciate ligament injuries in athletes. *Am J Sports Med* 15: 553-557, 1987
- Grood ES, Stowers SF, Noyes FR: Limits of movement in the human knee. Effect of sectioning the posterior cruciate ligament and posterolateral structures. *J Bone Joint Surg* 70A: 88-97, 1988
- Grover JS, Bassett LW, Gross ML, et al: Posterior cruciate ligament MR imaging. *Radiology* 174: 527-530, 1990
- Hughston JC: The absent posterior drawer test in some acute posterior cruciate ligament tears of the knee. *Am J Sports Med* 16: 39-43, 1988
- Hughston JC, Bowden JA, Andrews JR, et al: Acute tears of the posterior cruciate ligament. Results of operative treatment. *J Bone Joint Surg* 62A: 438-450, 1980
- Hughston JC, Degenhardt TC: Reconstruction of the posterior cruciate ligament. *Clin Orthop* 164: 59-77, 1982
- Jackson DW, Jennings LD, Maywood RM, et al: Magnetic resonance imaging of the knee. *Am J Sports Med* 16: 29-38, 1988
- Kennedy JC, Hawkins RJ, Willis EB, et al: Tension studies of human knee ligaments. Yield point, ultimate failure, and disruption of the cruciate and tibial collateral ligaments. *J Bone Joint Surg* 58A: 350-355, 1976
- Loos WC, Fox JM, Blazina ME, et al: Acute posterior cruciate ligament injuries. *Am J Sports Med* 9: 86-92, 1981
- Mandelbaum BR, Finerman GAM, Reicher MA, et al: Magnetic resonance

- imaging as a tool for evaluation of traumatic knee injuries. Anatomical and pathoanatomical correlations. *Am J Sports Med* 14: 361-370, 1986
21. Mink JH, Levy T, Crues JV: Tears of the anterior cruciate ligament and menisci of the knee: MR imaging evaluation. *Radiology* 167: 769-774, 1988
  22. Moore HA, Larson RL: Posterior cruciate ligament injuries. Results of early surgical repair. *Am J Sports Med* 8: 68-78, 1980
  23. Polly DW, Callaghan JJ, Sikes RA, et al: The accuracy of selective magnetic resonance imaging compared with the findings of arthroscopy of the knee. *J Bone Joint Surg* 70A: 192-198, 1988
  24. Savatsky GJ, Marshall JL, Warren RF, et al: Posterior cruciate ligament injury. *Orthop Trans* 4: 293, 1980