

UC San Diego

Independent Study Projects

Title

Oral Health
A Study Guide
for Medical Students & Physicians

Permalink

<https://escholarship.org/uc/item/5hp4m9c5>

Author

Mendoza, Annette

Publication Date

2017

Oral Health

A Study Guide

for Medical Students & Physicians

TABLE OF CONTENTS

Introduction	3
Diseases of the Teeth and Periodontal Structures	4
Antibiotic Prophylaxis and Anticoagulation for Oral Procedures	20
Medical Disease and Oral Health.....	23
Oral Health Risks of Tobacco, Alcohol, and Illicit Drug Use.....	24
Diseases of the Oral Mucosa	25
Alterations of the Tongue	35
Salivary Gland Pathology	40
Oral and Dental Emergencies	46
Oral Anesthesia.....	59
Prenatal Oral Health.....	65
Infant and Child Oral Health.....	67
Adolescent and Young adult oral health.....	68
Geriatric Oral Health.....	70
The Oral Exam	74
References.....	76

INTRODUCTION

Oral disease continues to be an epidemic in the U.S., affecting people of all age groups. Dental Caries is the single most common chronic childhood disease- five times more chronic than asthma. Oral and pharyngeal cancers are diagnosed in about 30,000 Americans annually, mostly in the elderly and with poor prognosis. Studies have shown a link between periodontal diseases and a variety of other medical problems such as diabetes, cardiovascular disease, stroke, and adverse pregnancy outcomes. In addition, oral disease can greatly impact our quality of life given that it can affect our ability to eat, the types of foods we choose to eat, our facial appearance, and our ability to communicate. In the last decade, there has been recognition on the neglect of oral health in medical training and in medicine due to the separation of oral health from systemic health.

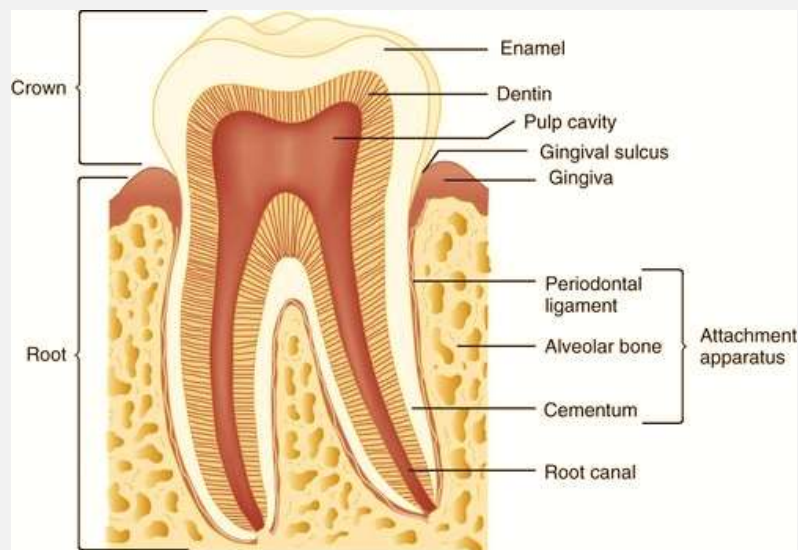
Some additional barriers to oral health include lack of access to care (due to limited income or lack of insurance), transportation, or the flexibility to take time off from work or leave other responsibilities. According to the CDC, it is found that people of color (particularly black and Hispanic), poverty, low income, modest education, and disability have higher oral disease rates than more socially advantaged populations. Often times these patients rely on their primary care provider for their oral health. That is why many initiatives have been developed to provide educational resources to enhance the role of the clinician's training in the promotion of oral health. With these initiatives including the development of this study guide, there is hope that we will begin to see better outcomes in our patients through better trained medical providers.

TEETH AND THE PERIODONTIUM

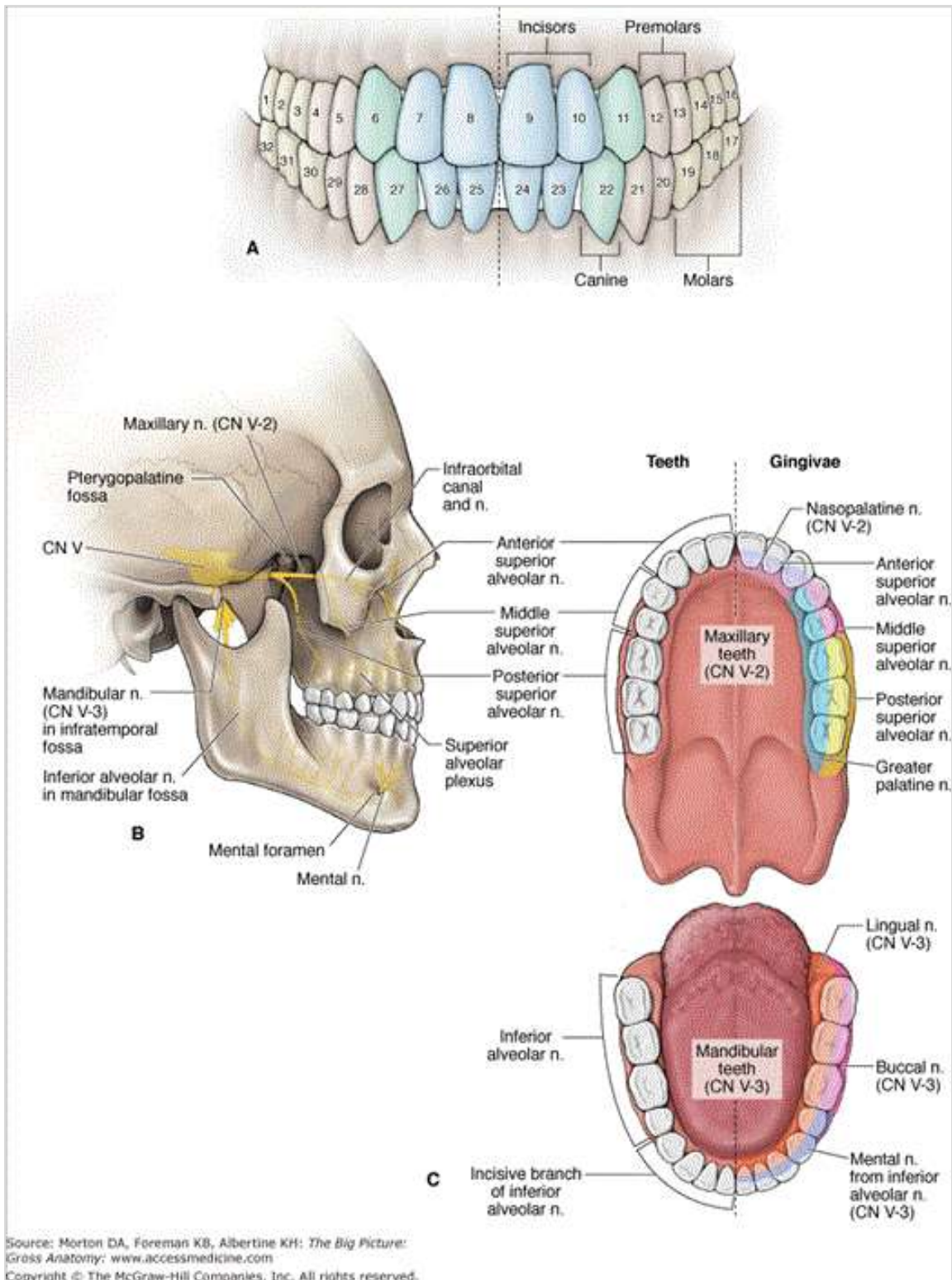
ANATOMY OF TEETH AND GINGIVAE

The Dental Anatomic Unit and Attachment Apparatus

- A tooth is made up largely of dentin, which surrounds the pulp (the neurovascular supply).
- **Dentin** (a homogeneous material) is produced by pulpal odontoblasts and is deposited as a system of microtubules filled with odontoblastic processes and extracellular fluid.
- The **crown** (visible portion of tooth) consists of dentin, covered by a thick layer of enamel.
- **Enamel** consists mostly of hydroxyapatite and is made by ameloblasts before eruption of the tooth into the mouth. It is the hardest substance in the human body.
- The root portion of the tooth extends into the alveolar bone and is covered with a thin layer of cementum.
- The **periodontium** (attachment apparatus) consists of a gingival component and a periodontal component.
 - The periodontal component includes the periodontal ligament, alveolar bone, and cementum of the root of the tooth. It forms the majority of the attachment apparatus.
 - The gingival component includes the junctional epithelium, gingival tissue, and gingival fibers. It helps maintain the integrity of the periodontal component.
- Gingival tissue is keratinized stratified squamous epithelium:
 - The free gingiva is the portion that forms the 2- to 3-mm-deep gingival sulcus in the disease-free state.
 - The attached gingiva adheres firmly to the underlying alveolar bone.
- Non-keratinized alveolar mucosa extends from the attached gingiva to the vestibule and floor of the mouth.

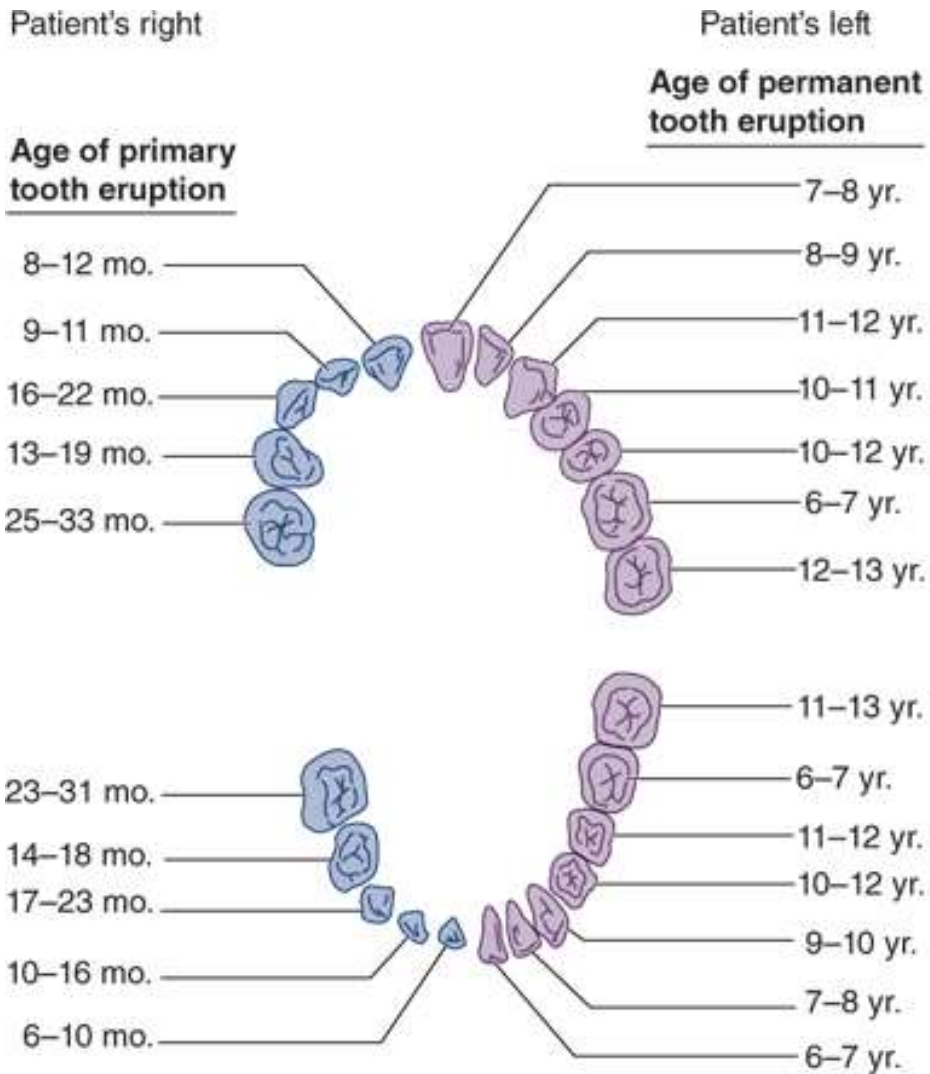


(A)Teeth. Lateral (B) and anterior (C) views of the innervation of the teeth and gingiva.



Normal Eruptive Patterns

Primary Dentition	Permanent Dentition
<p>20 Teeth</p> <ul style="list-style-type: none"> • 8 incisors • 4 canines • 8 molars 	<p>32 Teeth</p> <ul style="list-style-type: none"> • 8 incisors • 4 canines • 8 premolars • 12 molars



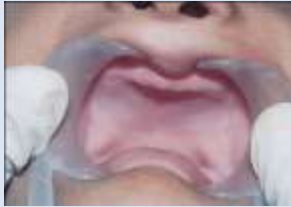Source: J.E. Tintinalli, J.S. Stapczynski, O.J. Ma, D.M. Yealy, G.D. Meckler, D.M. Cline: Tintinalli's Emergency Medicine: A Comprehensive Study Guide, 8th Edition www.accessmedicine.com Copyright © McGraw-Hill Education. All rights reserved.

ALTERATIONS OF TEETH

Developmental Alterations of the Teeth

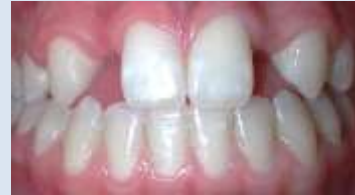Anodontia

Total lack of tooth development



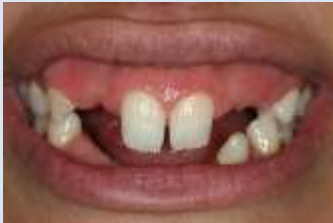Hypodontia

Lack of development of one or more teeth



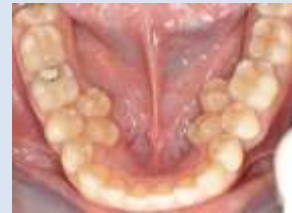Oligodontia

Lack of development of six or more teeth



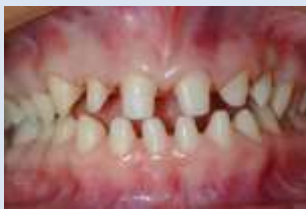Hyperdontia

Development of an increased number of teeth. The additional teeth are termed **supernumerary**.



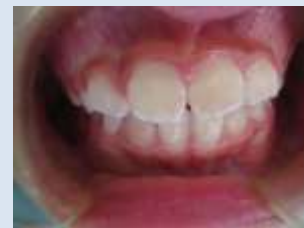Microdontia

The presence of unusually small teeth



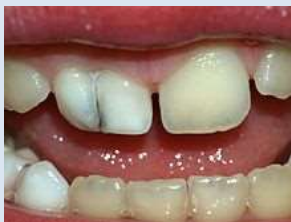Macrodontia

The presence of teeth larger than average



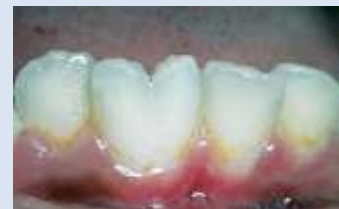Fusion

A single enlarged tooth or joined tooth, where tooth count reveals a missing tooth when anomalous tooth is counted as one



Gemination

A single enlarged tooth or joined tooth in which the tooth count is normal when the anomalous tooth is counted as one



Environmental Discoloration of Teeth

Extrinsic	Intrinsic
<ul style="list-style-type: none"> • Bacterial stains • Iron • Tobacco • Foods and beverages • Gingival hemorrhage • Restorative materials • Medications: <ul style="list-style-type: none"> -Stannous fluoride -Chlorhexidine 	<ul style="list-style-type: none"> • Amelogenesis imperfecta • Dentinogenesis imperfecta • Dental fluorosis • Erythropoietica porphyria • Hyperbilirubinemia • Ochronosis • Trauma • Localized red blood cell breakdown • Medications: <ul style="list-style-type: none"> -Tetracycline -Chlortetracycline -Oxytetracycline

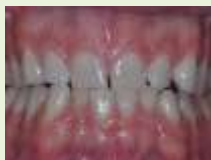Postdevelopmental Loss of Tooth Structure

In addition to dental caries and traumatic fractures, a variety of other influences can also contribute to the loss of tooth structure. Loss can begin from wear of the enamel (abrasion, attrition, erosion, or abfraction) or it can begin on the dentin or cemental surfaces by external or internal resorption.

Treatment is directed toward resolution of tooth sensitivity and pain, identifying the causes of tooth structure loss and protecting the remaining dentition:

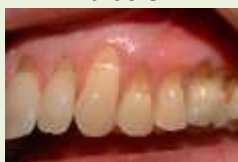- Dental sensitivity can be reduced through the use of varnishes, mouthwashes, or toothpastes containing strontium chloride, stannous fluoride, or monofluorophosphate.
- Patients should be educated about tooth exposure to acids.
- Mouth guards can be used to slow nocturnal attrition and to protect teeth from frequent exposure to acid from regurgitation or industrial sources.
- Advise those with erosion to limit tooth brushing to once a day (in the morning) because of increased vulnerability of acid etched enamel to abrasion and attrition.

Attrition







Loss of tooth structure caused by tooth to tooth contact during occlusion (contact between upper and lower teeth) and mastication.

Abrasion



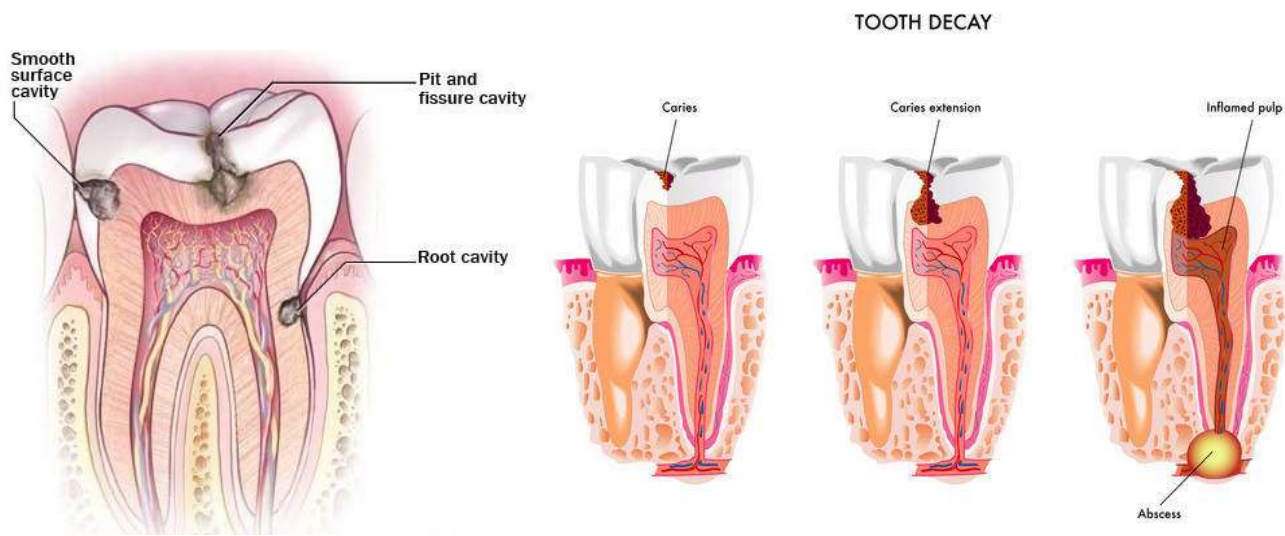
Pathologic loss of tooth structure or restoration, secondary to the action of an external agent. A common cause of abrasion is tooth brushing that combines abrasive toothpaste with heavy pressure and horizontal strokes.

<p>Demastication</p>	<p>Describes when tooth wear is accelerated by chewing an abrasive substance between opposing teeth.</p>
<p>Erosion</p> 	<p>The loss of tooth structure caused by a chemical process. Exposure to acid is the most common cause. Sources of acid include food, drinks, medications (chewable vitamin C, aspirin tablets), chronic involuntary or voluntary regurgitation and industrial environmental exposure. Chelating agents can also cause this. Saliva normally aids remineralization and contains bicarbonate with a significant buffering ability. However, this effect can be overwhelmed by excess acid or by the deficiency of quality and quantity of saliva leading to accelerated tooth loss.</p>
<p>Perimolysis</p> 	<p>Erosion from dental exposure to gastric secretions. Can result from:</p> <ul style="list-style-type: none"> • Hiatal hernia • Chronic alcoholism • Pregnancy • Bulimia • Psychologic problems
<p>Abfraction</p> 	<p>Tooth loss that occurs along the gingival margin. It is not clear what creates these specific lesions, but it is suggested that these lesions are caused by forces placed on the teeth during biting, eating, chewing and grinding.</p>
<p>Internal and external resorption</p> 	<p>Destruction of teeth can also be caused by resorption, accomplished by cells located in the dental pulp (internal resorption) or periodontal ligament (external resorption). Internal resorption is rare and is usually a result from injury to pulpal tissues such as physical trauma or caries related pulpitis. External resorption is extremely common.</p> <p>Treatment is directed at the removal of all soft tissue from the sites of dental destruction. Internal resorption can be stopped consistently if endodontic therapy successfully removes all vital pulp tissue before the process perforates into the periodontal ligament. The first step in treating external resorption is the identification and elimination of any accelerating factor.</p>

DENTAL AND PERIODONTAL DISEASE

Dental Caries

Dental caries (tooth decay) is the most prevalent infectious disease in humans, affecting 97% of the population worldwide during their lifetimes. Dental caries is a multifactorial, infectious, communicable disease caused by the demineralization of tooth enamel in the presence of a sugar substrate and of acid-forming cariogenic bacteria that are found in the soft gelatinous biofilm plaque. *Streptococcus mutans* is considered to be the primary strain causing decay. Development of caries is a dynamic process that involves an imbalance between demineralization and remineralization of enamel. When enamel is repeatedly exposed to the acid formed by the fermentation of sugars in plaque, demineralized areas develop on the tooth surfaces, between teeth, and on pits and fissures. This is also influenced by environmental factors such as low pH or inadequate formation of saliva. These areas of demineralization are painless and appear clinically as opaque or brown spots. If infection is allowed to progress, a cavity forms and can spread through the dentin and to the pulp causing pain, necrosis, and potentially an abscess.

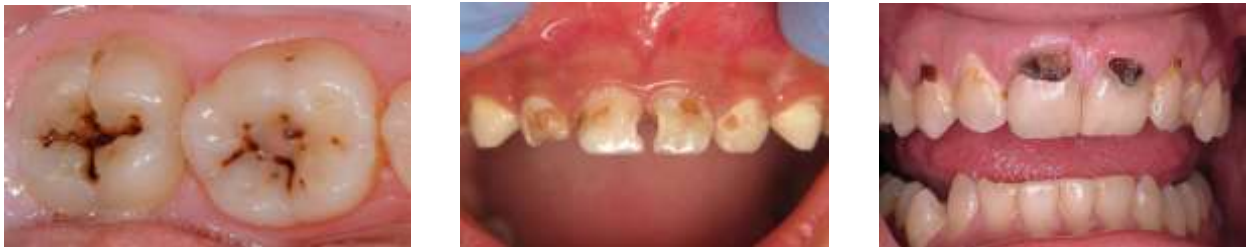

Caries Risk Factors:

- Presence of cavities or multiple fillings
- Gingival recession
- Xerostomia (medications, disease)
- Poor oral hygiene
- Poor access to dental care
- Low socio-economic and/or education status
- Inadequate fluoride
- High frequency foods/drinks/medications with sugar
- Special health care needs (oral health often overlooked)
- Presence of partial dentures or other appliances

DIAGNOSIS

Carious lesions progress at different rates and occur at many locations of the tooth, including the sites of previous restorations. Demineralized lesions generally occur at the margins of the gingiva and can be detected visually as white or brown spots. They may not be seen on radiographs. Advanced carious lesions (those spread through dentin), can be detected clinically. Using a sharp instrument, such as a dental explorer, is key in caries detection as carious tooth structure is detected as soft. If they occur between the teeth, they can be detected by radiographs. Root caries (more common in adults) may occur in areas of gingival recession. To diagnose secondary caries (caries formed at the site of restorations), dental professionals use digitally acquired and post-processed images. Other methods of detection such as spectrophotometry can also be utilized.



PREVENTION & TREATMENT

Fluoride treatment is widely accepted as a safe and effective practice for the primary prevention of dental caries. A proper mix of both forms of fluoride (topical and systemic) is key. Fluoride slows or reverses the progression of existing tooth decay by:

- Being incorporated into the enamel before tooth eruption
- Inhibiting demineralization
- Enhancing remineralization
- Inhibiting bacterial activity in plaque

Topical Fluorides

Self-applied

- Fluoride-containing toothpaste
 <3yrs = smear/size of grain of rice
 3-6yrs old = pea-size amount
 - Mouth- rinses (for 6yrs and older)
- Professionally-applied** (more concentrated)

- Gel
- Foam
- Rinse

Systemic Fluorides

Community water Fluoridation

- Recommended level is 0.7 parts fluoride per million parts water

Dietary fluoride supplements

(Tablets, drops, lozenges)

- Rx only
- Intended for children 6 mos-16 yrs old living in non-fluoridated areas and at high risk of developing tooth decay.

Fluoride Supplement Dosage Schedule—2010

Approved by the American Dental Association Council on Scientific Affairs

Age	Fluoride Ion Level in Drinking Water (ppm)*		
	<0.3	0.3-0.6	>0.6
Birth–6 months	None	None	None
6 months–3 years	0.25 mg/day**	None	None
3–6 years	0.50 mg/day	0.25 mg/day	None
6–16 years	1.0 mg/day	0.50 mg/day	None

*1.0 part per million (ppm) = 1 milligram per liter (mg/l)
 ** 2.2 mg sodium fluoride contains 1 mg fluoride ion.

What is dental enamel fluorosis?

Hypomineralization of tooth enamel caused by ingestion of excessive fluoride during enamel formation. In most cases, enamel fluorosis appears as barely noticeable faint white lines or streaks on tooth enamel and does not affect the function or health of the teeth.

Sealants may also help with the prevention and progression of initial or moderate dental decay. It is a protective coating (made of plastic and other dental materials) applied to the chewing surfaces of primary or permanent teeth. It can help decay from developing in pits and fissures. Dental professionals often use sealants in combination with topical fluorides.

Treatment of extensive lesions involves removal of the softened and infected hard tissue and restoration of the tooth structure with silver amalgam, glass ionomer, composite resin, or gold. Once irreversible pulpitis occurs, root canal therapy becomes necessary. This involves removal of the contents of the pulp chamber and root canals and is followed by thorough cleaning and filling with an inert material. Alternatively, the tooth may be extracted. Note that pulpal infection can lead to periapical abscess formation.

PERIODONTAL DISEASE

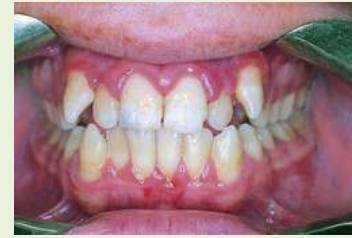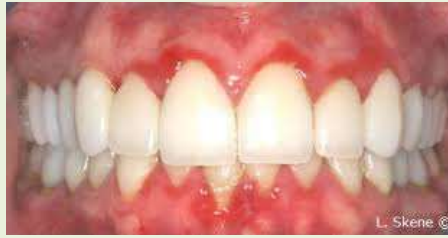According to the CDC, periodontal disease is the most common oral disease in adults affecting one of every two adults aged >30 years. Like dental caries, periodontal diseases are caused by bacteria in dental plaque that create an inflammatory response in gingival tissues (gingivitis) or in the soft tissue and bone supporting the teeth (periodontitis).

Gingivitis

Gingivitis refers to inflammation limited to the soft tissues that surround the teeth. Most cases of gingivitis occur from lack of proper oral hygiene, which leads to the accumulation of dental plaque and calculus (tartar). Gingivitis may also develop as a result of steroid hormones, which encourage the growth of certain bacteria in plaque during puberty and pregnancy and in women taking oral contraceptive pills. Other contributing factors include smoking, stress, poor nutrition, medications, diabetes mellitus, metal poisoning, trauma, tooth crowding with overlapping, and mouth breathing. The disease is diagnosed by clinical assessment. Healthy gingiva is normally coral pink, though with inflammation, it can appear as various shades of red. Early signs of gingivitis include a loss of stippling and bleeding on dental probing. With progression of disease, the areas can become bright red, with margins becoming blunted, receded, or hyperplastic. The inflammation worsens as mineralized plaque forms calculus at and below the gum surface (sulcus). Simple or marginal gingivitis may be painless and is treated by good oral hygiene practices such as tooth brushing and flossing. This type of gingivitis occurs in 50% of the population aged ≥ 4 years. In addition to improvements in oral hygiene, it is important that the patient receive periodic professional reinforcement. Gingivitis can be acute or chronic and it may persist for months or years without progressing to periodontitis. If the gingivitis does not resolve after improved plaque control and elimination of obvious contributing factors, the patient should be evaluated for underlying systemic disorders that could be contributing to the process.

Types of Gingivitis

- Plaque-related gingivitis
- Necrotizing ulcerative gingivitis (NUG)
- Medication-influenced gingivitis
- Allergic gingivitis
- Specific infection related gingivitis
- Dermatosis-related gingivitis

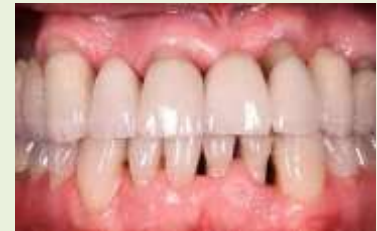
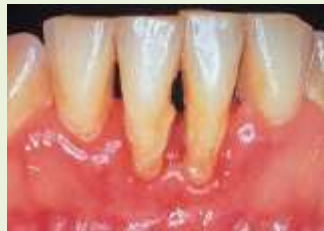
Periodontitis

Periodontitis refers to an inflammation of the gingival tissues in association with loss of both the attachment of the periodontal ligament and bony support. With progressive loss of attachment, significant destruction of the periodontal ligament and the adjacent alveolar bone can occur. Loosening and eventual loss of teeth are possible. For some time, the presence of disease has been correlated with the accumulation of dental plaque on the tooth and under the gingiva. However, many investigators now believe periodontitis occurs not from the mere presence of dental plaque, but as a result of shifts in the proportions of bacterial species in the plaque. Chronic periodontitis is associated predominantly with *Actinobacillus actinomycetemcomitans*, *Bacteroides forsythus*, *Porphyromonas gingivalis*, and *Prevotella intermedia*. In addition to the presence of pathogenic bacteria, other host factors include smoking, diabetes, and hereditary predisposition.

Classification of Periodontitis

- Chronic periodontitis
- Aggressive periodontitis
- Periodontitis as a manifestation of system diseases
- Necrotizing periodontal diseases
- Abscesses of the periodontium
- Periodontitis associated with endodontic lesion



Aggressive periodontitis occurs in otherwise healthy people. It appears to be correlated with one or more deficiencies in the immune system response (most commonly a neutrophil dysfunction), rather than with inappropriate accumulations of plaque and tartar. It is also classically defined by an observed aggregation of familial cases. Treatment typically involves a combination of antibiotics and the mechanical removal of subgingival plaque and inflamed periodontal tissues.

Periodontitis associated with systemic disease is not rare and may be attributed to diseases associated with premature loss of periodontal attachment. Several systemic diseases, including diabetes, HIV infection, Trisomy 21, and Papillon-Lefèvre syndrome, have been associated with this form of periodontitis.

Necrotizing ulcerative periodontitis (NUP) represents the loss of attachment that often occurs with necrotizing ulcerative gingivitis.

Chronic periodontitis (CP) has become the primary cause of tooth loss in patients older than 25 years of age. There is an increased prevalence associated with advanced aging, smoking, diabetes mellitus, and lower socioeconomic level. The presence of significant periodontitis may place patients at risk for an increased prevalence or greater severity of certain medical disorders. Some evidence links periodontitis with an increased risk for coronary artery disease (CAD), stroke, progressive diabetes mellitus, and delivery of low birth-weight babies. Patients with periodontitis present with gingivitis. Blunting and apical positioning of the gingival margins are typically present. Periodontal disease is present when a loss of attachment can be demonstrated through the use of a periodontal probe. A measurement of pockets greater than 3-4mm indicates destruction of the periodontal ligament and resorption of adjacent alveolar bone. Severe periodontitis is characterized by a 6-mm loss of tooth attachment. Treatment is directed at eliminating any existing risk factors. Removal of pathogenic bacterial plaque is crucial and this can be done through scaling, root planing, curettage, and debridement. Antibiotics are not generally used except in patients who do not respond to conventional therapy.

Periodontal Disease Risk Factors

- Poor oral hygiene including lack of flossing
- Tobacco use
- Diabetes and/or Osteoporosis
- Family history of periodontal disease
- Medications (anticonvulsants, methotrexate, Ca++ channel blockers may cause gingival hyperplasia)

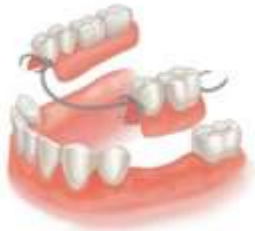Summary of PRIMARY CARE Prevention of Caries & Periodontal Disease:

- Eliminate sweet snacks/drinks between meals
- Brush twice daily with fluoridated toothpaste
- Children’s brushing should be supervised to ensure appropriate amount of toothpaste.
(discourage children aged <6 years from using fluoride-free toothpaste)
- Floss daily
- Regular dental visits every 6 months
- Regular oral exam at annual medical exam

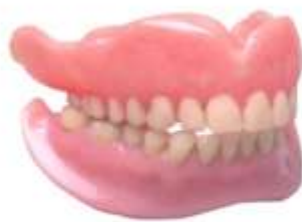DENTURES AND DENTAL IMPLANTS

Dentures

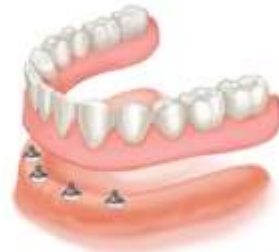Dentures are customized prosthetic devices constructed to replace missing teeth. They include removable dentures (either complete or partial, depending on the number of missing teeth) or implant-retained dentures. Overall, they can help patients with mastication, aesthetics, and pronunciation.



Partial Denture



Complete Dentures



Implant supported denture

PROPER DENTURE CARE

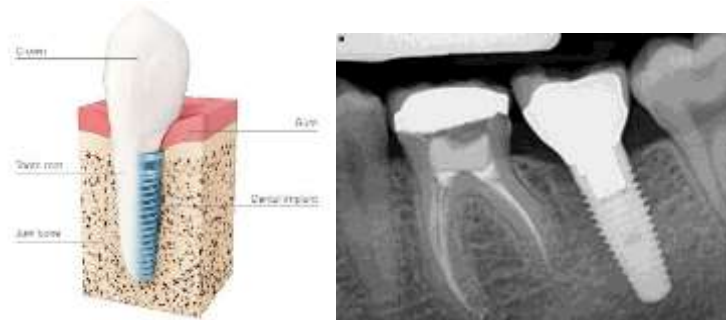
- Dentures should always be removed at night while patients are sleeping.
- Dentures should be placed in water or a denture cleanser solution, when they are not being worn. This helps the denture retain its shape, remain pliable and keeps it from drying out. Never place in hot water as it could cause them to warp.
- Must be cleaned daily to remove food particles and bacteria, and to help prevent dentures from becoming permanently stained. Removable dentures can be cleaned with commercial denture cleansers (tablets, creams, pastes, gels and solutions.) Denture cleansers should not be used while dentures are still in the mouth. Never use bleach or powdered household cleansers.
- In addition, they can also be cleaned with toothpaste or soap—mild hand soap or dishwashing liquid—warm water and a soft-bristle toothbrush.

PROBLEM CARE

- Accommodation to new dentures requires a period of adjustment.
- Loose dentures may produce pain as a result from friction or traumatic lesions.
- Poor fit and poor oral hygiene may permit the development of candidiasis. Clinical findings may include the presence of erythematous smooth or granular tissue conforming to an area covered by the appliance. The patient may be asymptomatic or present with pain. Treat with nystatin rinse 3x daily and ointment under the denture. Denture should also be soaked in chlorhexidine or nystatin.
- Problems with chewing, cheek biting, speech, or cracked corners of mouth may indicate poorly fitting dentures. Denture adhesives are not a remedy for ill-fitting dentures. Patient should see their dental provider for evaluation and adjustments.

Dental Implants

A dental implant is a surgical component that interfaces with the bone of the jaw or skull to support a dental prosthesis such as a crown. The development of osseous integrated dental implants has allowed patients to successfully enjoy the benefits of the fixed rather than removable dental prosthesis. Patients need to be evaluated preoperatively and assessed if they will be able to tolerate the procedure. Implant surgery is often performed in an ambulatory setting with the patient under local anesthesia or conscious sedation.



Indications for Implant Placement in the Partially Edentulous Patient

- 1) Inability to wear a removable partial dental prosthesis or complete denture
- 2) Need for long-span fixed dental prosthesis with questionable prognosis
- 3) Unfavorable number and location of potential natural tooth abutments
- 4) Single tooth loss that would necessitate preparation of minimally restored teeth for fixed prosthesis

Contraindications to Implant Placement (National Institutes of Health Consensus Conference)

- 1) Acute illness
- 2) Terminal illness
- 3) Uncontrolled metabolic disease
- 4) Tumoricidal irradiation of the implant site
- 5) Unrealistic patient expectation
- 6) Improper patient motivation
- 7) Lack of operator experience
- 8) Inability to restore with a prosthesis

Although the placement of dental implants does entail some risks, they are relatively minor. Absolute contraindications based on immediate surgical and anesthetic risks are limited to individuals who are acutely ill, individuals with uncontrolled metabolic disease, and pregnant women. Contraindications that threaten long-term implant retention include abnormal bone metabolism, poor oral hygiene, and previous irradiation of the implant site.

MEDICAL CLEARANCE FOR DENTAL PROCEDURES

Dental offices routinely send medical clearance forms to physicians before beginning treatment on medically compromised patients in order to gather additional relevant medical information and, sometimes, advice on how best to manage the patient's care. When it comes to medical clearance, the big issue is whether dental treatment could substantially affect a patient's physical condition or whether a physical condition could affect dental care. These requests should be approached with your standard preoperative evaluation.

- ▶ **When determining medical clearance for patients needing/requesting dental procedures, it is first important to consider the following:**
 - What dental procedure(s) will the patient be undergoing? What are the potential risks?
-Low risk procedures do not necessitate further evaluation given the low risk of complications.
 - What type of anesthesia will be used? *Who will be administering it?*
-Patients undergoing general anesthesia (GA) require additional considerations and will need preoperative anesthesia clearance as well.
 - What is the expected duration of the procedure?
 - Will it take place in an ambulatory/outpatient setting?

- ▶ **As with any pre-operative evaluation, it is first important to assess the patient for active heart conditions that could delay surgery. These include:**
 - Decompensated heart failure (CHF)
 - Significant arrhythmias
 - Severe valvular disease (severe aortic or mitral stenosis)
 - Unstable coronary syndromes :
 - Elective dental treatments should be postponed for at least 1 month and preferably for 6 months after myocardial infarction, after which the risk of reinfarction is low provided the patient is medically stable (e.g., stable rhythm, stable angina, and no heart failure).
 - Patients who have suffered a stroke should have elective dental care deferred for 6 months.
 - Effective stress reduction requires good pain control, including the use of the minimal amount of vasoconstrictor necessary to provide good hemostasis and local anesthesia.

- ▶ **If no "red flag" features are found, the patient's functional status should be assessed.**
 - Patients who have symptoms with activities of less than four metabolic equivalents (METs) have poor functional capacity and an increased risk for perioperative cardiovascular events.
 - One MET is defined as the energy expenditure for sitting quietly. Activities that correlate with 4 to 5 METs of activity include mopping floors, cleaning windows, painting walls, pushing a power lawnmower, raking leaves, weeding a garden, or walking up one flight of stairs.
 - If the patient cannot perform these activities, then it is important to determine if they are limited by dyspnea or cardiovascular disease which may require further workup.

► **Based on history, focus the assessment on specific areas of concern:**

Cardiovascular and Pulmonary Risk <ul style="list-style-type: none">• Ischemic heart disease• Heart failure• Dysrhythmias and cardiac devices• Valvular and congenital heart disease• Cerebrovascular disease• Pulmonary disease• Venous Thromboembolism	Bleeding Risk <ul style="list-style-type: none">• Personal and familial coagulation disorders• Platelet and vessel disorders• Transfusion history Social History <ul style="list-style-type: none">• Substance use and abuse• Tobacco
Metabolic Risk <ul style="list-style-type: none">• Glucose intolerance, hyperglycemia, diabetes• Kidney disease• Liver disease• Age	Medications <ul style="list-style-type: none">• Cardiovascular drugs• Drugs affecting hemostasis• Corticosteroids• Immunosuppressants• Bisphosphonates (risk of osteonecrosis of the jaw) Mechanical and Positioning Risks <ul style="list-style-type: none">• Musculoskeletal conditions

► **In addition to a performing focused physical exam, laboratory testing and imaging may also be helpful:**

- Electrocardiogram
- Myocardial perfusion imaging
- Chest X-Ray
- Pulmonary function tests
- Serum chemistries/ Blood count
- Hemoglobin and Hematocrit
- Coagulation studies



- **If there are any concerns about the patient's risk or safety, be sure to communicate that to the dental provider. Consider referrals to other medical specialists if expert consultation is needed. If the patient is at high risk but needs urgent dental treatment (such as an extraction) then consider alternate care options such as coordination with an oral surgeon to perform the procedure in an inpatient setting.**

ANTIBIOTIC PROPHYLACTIC REGIMENS FOR DENTAL PROCEDURES

PREVENTION OF INFECTIVE ENDOCARDITIS

Based on the latest recommendations by the American Heart Association (updated 2007)

Antibiotic prophylaxis with dental procedures* is reasonable only for patients with cardiac conditions associated with the highest risk of adverse outcomes from endocarditis, including:

- Prosthetic cardiac valve or prosthetic material used in valve repair
- Previous endocarditis
- Congenital heart disease (CHD) only in the following categories**:
 - Unrepaired cyanotic CHD, including those with palliative shunts and conduits
 - Completely repaired congenital heart defect with prosthetic material or device, whether placed by surgery or catheter intervention, during the first six months after the procedure†
 - Repaired CHD with residual defects at the site or adjacent to the site of a prosthetic patch or prosthetic device (which inhibit endothelialization)
- Cardiac transplantation recipients with cardiac valvular disease

* All dental procedures that involve manipulation of gingival tissue or the periapical region of teeth, or perforation of the oral mucosa.

**Except for the conditions listed above, antibiotic prophylaxis is not recommended for any other form of CHD.

†Prophylaxis is reasonable because endothelialization of prosthetic material occurs within six months after the procedure.

Antibiotic prophylaxis is NOT recommended for the following dental procedures or events:

- Routine anesthetic injections through non-infected tissue
- Taking dental radiographs
- Placement of removable prosthodontic or orthodontic appliances
- Adjustment of orthodontic appliances
- Placement of orthodontic brackets
- Shedding of primary teeth
- Bleeding from trauma to the lips or oral mucosa

STANDARD PROPHYLAXIS

Give 1 dose 30 – 60 minutes before procedure:

NOTE: If a patient has a penicillin allergy then clindamycin is the 2nd line drug immediately after penicillins. Approximately 10% of patients with penicillin allergies will have an allergy to cephalosporins as well.

Antibiotic Prophylactic Regimens for Dental Procedures

Situation	Agent	Regimen—Single Dose 30-60 minutes before procedure	
		Adults	Children
Oral	Amoxicillin	2 g	50 mg/kg
Unable to take oral medication	Ampicillin OR	2 g IM or IV*	50 mg/kg IM or IV
	Cefazolin or ceftriaxone	1 g IM or IV	50 mg/kg IM or IV
Allergic to penicillins or ampicillin— Oral regimen	Cephalexin**†	2 g	50 mg/kg
	OR		
	Clindamycin	600 mg	20 mg/kg
	OR		
Allergic to penicillins or ampicillin and unable to take oral medication	Cefazolin or ceftriaxone†	1 g IM or IV	50 mg/kg IM or IV
	OR Clindamycin	600 mg IM or IV	20 mg/kg IM or IV

*IM—intramuscular; IV—intravenous

**Or other first or second generation oral cephalosporin in equivalent adult or pediatric dosage.

†Cephalosporins should not be used in an individual with a history of anaphylaxis, angioedema or urticaria with penicillins or ampicillin.

PREVENTION OF PROSTHETIC JOINT INFECTION

Based on the latest recommendations by the American Academy of Orthopaedic Surgeons (2012)

Prevention of Orthopaedic Implant Infections in Patients Undergoing Dental Procedures:

- A new limited recommendation states, “The practitioner might consider discontinuing the practice of routinely prescribing prophylactic antibiotics for patients with hip and knee prosthetic joint implants undergoing dental procedures.”
- NOTE: Previous guidelines had recommended antibiotic prophylaxis for patients within the first 2 years after joint replacement who have inflammatory arthropathies, immunosuppression, type 1 diabetes mellitus, previous prosthetic-joint infection, hemophilia, or malnourishment.

Current ADA Guidelines:

In patients with prosthetic joint implants, a January 2015 ADA Clinical Practice Guideline, based on a 2014 systematic review states, “In general, for patients with prosthetic joint implants, prophylactic antibiotics are not recommended prior to dental procedures to prevent prosthetic joint infection.

ANTICOAGULATION GUIDELINES FOR ORAL PROCEDURES

- Cessation of anticoagulation or anti-platelet agents carries a risk of thromboembolic event
- It is safe to perform cleanings, fillings, and simple extractions without interrupting anticoagulation
- Bleeding can be controlled with local agents (*discuss with a dentist/oral surgeon*):
 - Surgical oxidized cellulose polymer
 - Tranexamic acid
 - Epsilon-aminocaproic acid (EACA) mouthwash
- Patients that are at high risk for thromboembolic events who need to undergo oral procedures that are high risk for bleeding, can be managed with “bridge therapy” using enoxaparin (Lovenox) and/or heparin days before the procedure
- Communication with the patient’s dentist or oral surgeon is crucial

Medical Disease and Oral Health

Oral Risks Associated With Medical Disease	
Disease	Oral Health Risks
Diabetes mellitus	The most common oral health problems associated with diabetes are tooth decay, periodontal disease, salivary gland dysfunction, fungal infections, lichen planus and lichenoid reactions. It can also increase risk of infection, delayed healing, and taste impairment.
Asthma	Asthma medication comprises of bronchodilators, corticosteroids and anticholinergic drugs. Patients taking these medications may experience dry mouth which may increase the risk of dental caries, dental erosion, and periodontal diseases. Inhaled steroids are associated with oral candidiasis.
Seizure disorders	Patients taking phenytoin are at risk of gingival hyperplasia, a condition which results in painful, swollen, red gums. This is more common among children who are on this medication.
Cardiovascular disease	Many studies have shown a connection between periodontitis and cardiovascular disease. However, there is no conclusive evidence that preventing periodontitis can prevent heart disease or that treating periodontal disease can lessen atherosclerosis.
Immunocompromised patients	The most common clinical manifestation of immunosuppression is chronic dry mouth. In patients with HIV, there is an increased incidence of candidiasis, xerostomia, oral hairy leukoplakia, melanotic hyperpigmentation, angular cheilitis and gingival erythema. Commonly reported neoplasms in HIV patients include Kaposi's sarcoma and nonHodgkin's lymphoma. Immunosuppressive drugs taken to prevent the reject of transplants can result in xerostomia, oral mucositis and gingival overgrowth. Topical fluoride treatments are key components to controlling the development of caries.
Cancer patients	Complications of cancer treatment include oral mucositis, stomatitis, xerostomia, salivary gland dysfunction, pain, infection, xerostomia-associated cavities, and taste alterations. Patients should see a dentist to prevent and control infections with appropriate treatment before, during, and after cancer therapy. Evaluation should be performed at least 1 month before cancer treatment starts to permit adequate healing from any required invasive procedures.
Attention deficit disorder (ADD)	Patients with ADD are more likely to have poor oral hygiene and therefore are at greater risk for caries. They are also at high risk for dental/oral trauma and bruxism.
Anxiety	Oral health problems associated with anxiety disorders include canker sores, dry mouth, lichen planus, red areas or mouth ulcers, burning mouth syndrome, and temporomandibular joint disorders. Some medications also cause dry mouth, which can increase the risk of developing tooth decay and periodontal disease.

Bulimia

Purging can result in rampant dental decay or enamel erosion. Other oral complications include dry mouth, dental caries, painful/bleeding gums, soft palate damage, salivary gland enlargement, reversal of previous dental work.

Effects of Alcohol, Tobacco, and Other Illicit Drugs

Tooth loss and periodontal disease

Tobacco can damage the gum tissue causing inflammation and periodontal disease. Use of tobacco, ecstasy, amphetamines, methamphetamines (particularly smoked methamphetamine) can also lead to tooth loss by constricting the capillaries in the gingival tissues.

Dry mouth

Use of alcohol, marijuana, ecstasy, amphetamines, methamphetamines, heroin and replacement therapies such as methadone limit saliva production causing dry mouth. This dramatically increases the risk of tooth decay, periodontal disease, and erosion.

Tooth decay and erosion

Dry mouth effects of these drugs contribute to tooth decay and erosion. Ecstasy raises body temperature, which can lead to an increase in the consumption of sugary drinks. Most alcoholic drinks are very sugary and acidic. Frequent consumption of these drinks can demineralize and weaken tooth enamel, which is the first step in tooth decay. Vomiting after drinking alcohol can cause erosion of the teeth as well.

Tooth grinding and jaw clenching

Tooth grinding (bruxism) and jaw clenching can occur with ecstasy, cocaine, amphetamine and methamphetamine use. Bruxism can lead to extreme wear, especially when combined with dry mouth. It can cause cracked and broken teeth and nerve damage.

Staining and bad breath

Smoking cigarettes contributes to bad breath and the buildup of tartar on teeth. It can also stain the teeth, tongue and gums. Staining may appear yellow or black.

Poor oral hygiene




Excessive alcohol consumption and drug use can result in neglected oral hygiene and self-care.


Oral cancer


Tobacco contains carcinogens, and is a major risk factor associated with oral cancer. Excessive consumption of alcohol significantly raises the risk of oral cancer, and when combined with smoking tobacco this risk is increased even more dramatically. Smoking marijuana also increases the risk of developing oral cancer.



DISEASES OF THE ORAL MUCOSA




INFECTION

Viral Diseases	Clinical Features	Clinical Course
<p>Primary acute herpetic gingivostomatitis (HSV type 1; rarely type 2)</p> 	<p><i>Lip and oral mucosa (buccal, gingival, lingual mucosa)</i></p> <ul style="list-style-type: none"> -Labial vesicles (rupture and crust) -Intraoral vesicles (ulcerate and are extremely painful) <ul style="list-style-type: none"> • Acute gingivitis, fever, malaise, foul odor, and cervical lymphadenopathy • Occurs primarily in infants, children, and young adults 	<ul style="list-style-type: none"> • Typically heals spontaneously in 10–14 days, unless secondarily infected • Any lesions lasting >3 weeks are not due to primary HSV infection
<p>Recurrent herpes labialis</p>	<p><i>Mucocutaneous junction of lip, perioral skin</i></p> <ul style="list-style-type: none"> • Eruption of groups of vesicles that may coalesce and then rupture and crust • painful to pressure or spicy foods 	<ul style="list-style-type: none"> • Lasts about 1 week, but may be prolonged if secondary infection present • If severe, topical or oral antiviral treatment may reduce healing time
<p>Recurrent intraoral herpes simplex</p>	<p><i>Palate and gingiva</i></p> <ul style="list-style-type: none"> • Small vesicles on keratinized epithelium that rupture and coalesce • Painful 	<ul style="list-style-type: none"> • Heals spontaneously in about 1 week • If severe, topical or oral antiviral treatment may reduce healing time
<p>Chickenpox (VZV)</p> 	<p><i>Gingiva and oral mucosa</i></p> <ul style="list-style-type: none"> • Skin lesions may be accompanied by small vesicles on the oral mucosa that rupture to form shallow ulcers • Vesicles may coalesce to form large bullous lesions that ulcerate • Mucosa may have generalized erythema 	<ul style="list-style-type: none"> • Lesions typically heal spontaneously within 2 weeks
<p>Herpes zoster (VZV reactivation)</p> 	<p><i>Cheek, tongue, gingiva, or palate</i></p> <ul style="list-style-type: none"> • Unilateral vesicular eruptions and ulceration in a linear pattern following sensory distribution of trigeminal nerve or one of its branches 	<ul style="list-style-type: none"> • Gradual healing without scarring unless secondarily infected • Postherpetic neuralgia is common • Treatment with oral acyclovir, famciclovir, or valacyclovir reduces healing time and postherpetic neuralgia


Infectious mononucleosis (Epstein-Barr virus)	<p><i>Oral mucosa</i></p> <ul style="list-style-type: none"> • Fatigue, sore throat, malaise, fever, and cervical lymphadenopathy • Numerous small ulcers usually appear several days before lymphadenopathy • May be gingival bleeding and multiple petechiae at junction of hard and soft palates 	<ul style="list-style-type: none"> • Oral lesions disappear during convalescence • No treatment is needed • Glucocorticoids are indicated if tonsillar swelling compromises the airway
Herpangina (coxsackievirus A; also possibly coxsackievirus B and echovirus)	<p><i>Oral mucosa, pharynx, tongue</i></p> <ul style="list-style-type: none"> • Sudden onset of fever, sore throat, and oropharyngeal vesicles, usually in children <4 years old, during summer months • Diffuse pharyngeal congestion and vesicles (1–2 mm), grayish-white surrounded by red areola • Vesicles enlarge and ulcerate 	<ul style="list-style-type: none"> • Incubation period of 2–9 days • Fever for 1–4 days • Recovery uneventful
Hand-foot-and-mouth disease (most commonly coxsackievirus A16) 	<p><i>Oral mucosa, pharynx, palms, and soles</i></p> <ul style="list-style-type: none"> • Fever, malaise, and headache with oropharyngeal vesicles that become painful, shallow ulcers • Highly infectious and usually affects children under age 10 	<ul style="list-style-type: none"> • Incubation period 2–18 days • Lesions heal spontaneously in 2–4 weeks
Primary HIV infection	<p><i>Gingiva, palate, and pharynx</i></p> <ul style="list-style-type: none"> • Acute gingivitis and oropharyngeal ulceration, associated with febrile illness resembling mononucleosis and including lymphadenopathy 	<ul style="list-style-type: none"> • Followed by HIV seroconversion, asymptomatic HIV infection, and usually ultimately by HIV disease



Bacterial & Fungal Diseases	Clinical Features	Course
Acute necrotizing ulcerative gingivitis “trench mouth” 	<p><i>Gingiva</i></p> <ul style="list-style-type: none"> • Painful, bleeding gingiva characterized by necrosis and ulceration of gingival papillae and margins • Associated with lymphadenopathy and foul breath 	<ul style="list-style-type: none"> • Treatment via debridement and diluted (1:3) peroxide lavage provide relief within 24 hrs • Antibiotics are indicated in acutely ill patients • Relapse may occur

<p>Prenatal (congenital) syphilis</p> 	<p><i>Palate, jaws, tongue, and teeth</i></p> <ul style="list-style-type: none"> • Gummatous involvement of palate, jaws, and facial bone • Hutchinson's incisors, mulberry molars, glossitis, mucous patches, and fissures at corners of mouth 	<ul style="list-style-type: none"> • Tooth deformities in permanent dentition irreversible
<p>Primary syphilis (chancre)</p> 	<p><i>Lesion appearing where organism enters body. May occur on lips, tongue, or tonsillar area</i></p> <ul style="list-style-type: none"> • Small papule developing rapidly into a large, painless ulcer with indurated border • Unilateral lymphadenopathy with chancre and lymph nodes containing spirochetes • Serologic tests positive by third to fourth weeks 	<ul style="list-style-type: none"> • Chancre heals in 1–2 months • Followed by secondary syphilis in 6–8 weeks
<p>Secondary syphilis</p>	<p><i>Oral mucosa frequently involved with mucous patches, which occur primarily on palate and also at commissures of mouth</i></p> <ul style="list-style-type: none"> • Maculopapular lesions of oral mucosa, 5–10 mm in diameter with central ulceration covered by grayish membrane • Eruptions occur on various mucosal surfaces and skin, accompanied by fever, malaise, and sore throat 	<ul style="list-style-type: none"> • Lesions may persist from several weeks to 1 year
<p>Tertiary syphilis</p>	<p><i>Palate and tongue</i></p> <ul style="list-style-type: none"> • Gummatous infiltration of palate or tongue followed by ulceration and fibrosis • Atrophy of tongue papillae produces characteristic bald tongue and glossitis 	<ul style="list-style-type: none"> • Gumma may destroy palate, causing complete perforation
<p>Gonorrhea</p>	<p><i>Lesions may occur in mouth at site of inoculation or secondarily by hematogenous spread from a primary focus</i></p> <ul style="list-style-type: none"> • Most pharyngeal infection is asymptomatic • May produce burning or itching sensation and oropharynx and tonsils may be ulcerated and erythematous • Saliva is viscous and foul-smelling 	<ul style="list-style-type: none"> • More difficult to eradicate than urogenital infection • Pharyngitis usually resolves with appropriate antimicrobial treatment
<p>Tuberculosis</p>	<p><i>Tongue, tonsillar area, soft palate</i></p> <ul style="list-style-type: none"> • Painless, solitary, 1- to 5-cm, irregular ulcer covered with persistent exudate • Ulcer has firm undermined border 	<ul style="list-style-type: none"> • Autoinoculation from pulmonary infection is typical • Lesions resolve with appropriate antimicrobial therapy




<p>Cervicofacial actinomycosis</p> 	<p><i>Swellings in region of face, neck, and floor of mouth</i></p> <ul style="list-style-type: none"> • Infection may be associated with extraction, jaw fracture, or eruption of molar tooth • In acute form, resembles acute pyogenic abscess, but contains yellow “sulfur granules” (gram-positive mycelia and their hyphae) 	<ul style="list-style-type: none"> • Typically, swelling is hard and grows painlessly • Multiple abscesses with draining tracts develop • Penicillin is first choice of antibiotic treatment • Surgery usually necessary
<p>Histoplasmosis</p> 	<p><i>Any area of the mouth, particularly tongue, gingiva, or palate</i></p> <ul style="list-style-type: none"> • Nodular, verrucous, or granulomatous lesions • Ulcers are indurated and painful • Usually hematogenous or pulmonary source, but can also be primary 	<ul style="list-style-type: none"> • Requires treatment with systemic antifungal therapy
<p>Candidiasis</p> 	<p><i>Any area in mouth</i></p> <ul style="list-style-type: none"> • Creamy white curd-like patches that reveal a raw, bleeding surface when scraped • Found in sick infants, debilitated elderly patients receiving high-dose glucocorticoids or broad-spectrum antibiotics, and patients with AIDS 	<ul style="list-style-type: none"> • Responds well to antifungal therapy and correction of the predisposing cause(s) when possible



OTHER CONDITIONS

	Clinical Features	Clinical Course
<p>Recurrent aphthous ulcers</p> 	<p><i>Usually on nonkeratinized oral mucosa (buccal and labial mucosa, floor of mouth, soft palate, lateral and ventral tongue)</i></p> <ul style="list-style-type: none"> • Single or clustered painful ulcers with surrounding erythematous borders • Lesions may be 1–2 mm in diameter in crops of multiple ulcers (herpetiform), 1–5 mm (minor), or 5–15 mm (major) 	<ul style="list-style-type: none"> • Lesions heal in 1–2 weeks but may recur monthly or several times a year • Use protective barrier with benzocaine and topical glucocorticoids relieve symptoms • Systemic glucocorticoids may be needed in severe cases
<p>Behcet’s syndrome</p>	<p><i>Oral mucosa, eyes, genitalia, gut, and CNS</i></p> <ul style="list-style-type: none"> • Multiple aphthous ulcers in mouth • Inflammatory ocular changes and ulcerative lesions on genitalia • Inflammatory bowel disease and CNS disease 	<ul style="list-style-type: none"> • Oral lesions often first manifestation • Persist several weeks and heal without scarring


<p>Traumatic ulcers</p>	<p><i>Anywhere on oral mucosa (dentures frequently responsible for ulcers in vestibule)</i></p> <ul style="list-style-type: none"> Localized, discrete ulcerated lesions with red border Produced by accidental biting of mucosa, penetration by foreign object, or chronic irritation by dentures 	<ul style="list-style-type: none"> Once irritant is removed, lesions usually heal in 7–10 days, unless secondarily infected
<p>Squamous cell carcinoma</p> 	<p><i>Any area of mouth, most commonly on lower lip, lateral borders of tongue, and floor of mouth</i></p> <ul style="list-style-type: none"> Red, white, or red and white ulcer with elevated or indurated border Continued growth with failure to heal Pain is not prominent in early lesions 	<ul style="list-style-type: none"> Invades and destroys underlying tissues Frequently metastasizes to regional lymph nodes
<p>Acute myeloid leukemia (usually monocytic)</p>	<p><i>Gingiva</i></p> <ul style="list-style-type: none"> Gingival swelling and superficial ulceration followed by hyperplasia of gingiva with extensive necrosis and hemorrhage Deep ulcers may occur elsewhere on mucosa Can be complicated by secondary infection 	<ul style="list-style-type: none"> Usually responds to systemic treatment of leukemia Occasionally requires local irradiation
<p>Lymphoma</p> 	<p><i>Gingiva, tongue, palate, and tonsillar area</i></p> <ul style="list-style-type: none"> Elevated, ulcerated area that may proliferate rapidly, giving appearance of traumatic inflammation 	<ul style="list-style-type: none"> Fatal if untreated May indicate underlying HIV infection
<p>Chemical or thermal burns</p>	<p><i>Any area in mouth</i></p> <ul style="list-style-type: none"> White slough due to contact with corrosive agents applied locally (e.g., aspirin, hot cheese) Removal of slough leaves raw, painful surface 	<ul style="list-style-type: none"> Lesions typically heal in several weeks if not secondarily infected

PIGMENTED LESIONS

Condition	Clinical Features	Clinical Course
Oral melanotic macule	<p><i>Any area of mouth</i></p> <ul style="list-style-type: none"> Discrete or diffuse, localized, brown to black macule 	<ul style="list-style-type: none"> Remains indefinitely No growth
Diffuse melanin pigmentation 	<p><i>Any area of mouth</i></p> <ul style="list-style-type: none"> Diffuse pale to dark-brown pigmentation May be physiologic (“racial”) or due to smoking 	Remains indefinitely
Nevi	<p><i>Any area of mouth</i></p> <ul style="list-style-type: none"> Discrete, localized, brown to black pigmentation 	Remains indefinitely
Malignant melanoma	<p><i>Any area of mouth</i></p> <ul style="list-style-type: none"> Can be flat and diffuse, painless, brown to black, or be raised and nodular 	<ul style="list-style-type: none"> Expands and invades early Metastasis leads to death
Addison’s disease 	<p><i>Any area of mouth, but mostly buccal mucosa</i></p> <ul style="list-style-type: none"> Blotches or spots of bluish-black to dark-brown pigmentation occurring early in disease, accompanied by diffuse pigmentation of skin Other symptoms of adrenal insufficiency 	Condition controlled by adrenal steroid replacement
Peutz-Jeghers syndrome	<p><i>Any area of mouth</i></p> <ul style="list-style-type: none"> Dark-brown spots on lips, buccal mucosa, with characteristic distribution of pigment around lips, nose, and eyes and on hands Accompanied by intestinal polyposis 	<ul style="list-style-type: none"> Oral pigmented lesions remain indefinitely Gastrointestinal polyps may become malignant
Drug ingestion (neuroleptics, oral contraceptives, minocycline, zidovudine, quinine derivatives)	<p><i>Any area of mouth</i></p> <ul style="list-style-type: none"> Brown, black, or gray areas of pigmentation 	Gradually disappears following cessation of drug intake
Amalgam tattoo 	<p><i>Gingiva and alveolar mucosa</i></p> <ul style="list-style-type: none"> Small blue-black pigmented areas associated with embedded amalgam particles in soft tissues May show up on radiographs as radiopaque particles in some cases 	Remains indefinitely

Heavy metal pigmentation (bismuth, mercury, lead)	<i>Gingival margin</i> <ul style="list-style-type: none"> Thin blue-black pigmented line along gingival margin Rarely seen except in children exposed to lead-based paint 	<ul style="list-style-type: none"> Indicative of systemic absorption No significance for oral health
Black hairy tongue	<i>Dorsum of tongue</i> <ul style="list-style-type: none"> Elongation of filiform papillae of tongue, which become stained by coffee, tea, tobacco, or pigmented bacteria 	Improves within 1–2 weeks with gentle brushing of tongue or if due to bacterial overgrowth, discontinuation of the offending antibiotic
Fordyce spots	<i>Buccal and labial mucosa</i> <ul style="list-style-type: none"> Numerous small yellowish spots just beneath mucosal surface No symptoms Due to hyperplasia of sebaceous glands 	Benign and remains without apparent change
Kaposi's sarcoma 	<i>Palate most common, but may occur at any other site</i> <ul style="list-style-type: none"> Red or blue plaques of variable size and shape; often enlarge, become nodular, and may ulcerate 	<ul style="list-style-type: none"> Usually indicative of HIV infection or nonHodgkin's lymphoma Rarely fatal, but may require treatment for comfort or cosmesis
Mucous retention cysts 	<i>Buccal and labial mucosa</i> <ul style="list-style-type: none"> Bluish, clear fluid-filled cyst due to extravasated mucus from injured minor salivary gland 	<ul style="list-style-type: none"> Benign and painless unless traumatized May be removed surgically

WHITE LESIONS OF THE ORAL MUCOSA

Condition	Clinical Features	Clinical Course
Lichen planus 	<i>Buccal mucosa, tongue, gingiva, and lips; skin</i> <ul style="list-style-type: none"> Striae, white plaques, red areas, ulcers in mouth purplish papules on skin May be asymptomatic, sore, or painful Lichenoid drug reactions may look similar 	<ul style="list-style-type: none"> White striae alone usually asymptomatic Responds to topical glucocorticoids

White sponge nevus	<p><i>Buccal mucosa, tongue, gingiva, and lips; skin</i></p> <ul style="list-style-type: none"> • Painless white thickening of epithelium • Adolescence/early adulthood onset; familial 	Benign and permanent
Smoker's leukoplakia and smokeless tobacco lesions	<p><i>Any area of oral mucosa, sometimes related to location of habit</i></p> <ul style="list-style-type: none"> • Floor of mouth commonly affected in men; tongue and buccal mucosa in women • White patch that may become firm, rough, or red-fissured and ulcerated; may become sore and painful but is usually painless 	<ul style="list-style-type: none"> • May or may not resolve with cessation of habit • 2% of patients develop squamous cell carcinoma • Early biopsy essential
Erythroplakia with or without white patches	<p><i>Floor of mouth commonly affected in men; tongue and buccal mucosa in women</i></p> <ul style="list-style-type: none"> • Velvety, reddish plaque • Occasionally mixed with white patches or smooth red areas 	<ul style="list-style-type: none"> • High risk of squamous cell cancer • Early biopsy essential
Candidiasis	<p><i>Any area in mouth</i></p> <p>Pseudomembranous type ("thrush"):</p> <ul style="list-style-type: none"> • creamy white cur-like patches that reveal a raw, bleeding surface when scraped • Found in sick infants, debilitated elderly patients receiving high-dose glucocorticoids or broad-spectrum antibiotics, and patients with AIDS 	Responds favorably to antifungal therapy and correction of predisposing causes where possible
	Erythematous type: flat, red, sometimes sore areas in same groups of patients	Course same as for pseudomembranous type
	Candidal leukoplakia: nonremovable white thickening of epithelium due to <i>Candida</i>	
	Angular cheilitis: sore fissures at corner of mouth	Responds to topical antifungal therapy
Hairy leukoplakia	<p><i>Usually on lateral tongue, rarely elsewhere on oral mucosa</i></p> <ul style="list-style-type: none"> • White areas ranging from small and flat to extensive accentuation of vertical folds • Found in HIV carriers (all risk groups for AIDS) 	<ul style="list-style-type: none"> • Due to Epstein-Barr virus • Responds to high-dose acyclovir but recurs • Rarely causes discomfort unless secondarily infected with <i>Candida</i>
Warts (Human papillomavirus)	<p><i>Anywhere on skin and oral mucosa</i></p> <ul style="list-style-type: none"> • Single or multiple papillary lesions with thick, white, keratinized surfaces containing many pointed projections • Cauliflower lesions covered with normal-colored mucosa or multiple pink or pale bumps (focal epithelial hyperplasia) 	<ul style="list-style-type: none"> • Lesions grow rapidly and spread • Squamous cell carcinoma must be ruled out with biopsy • Excision or laser therapy • May regress in HIV-infected patients receiving antiretroviral therapy

DERMATOLOGIC DISEASES

Dermatologic Diseases	Clinical Features	Clinical Course
<p>Mucous membrane pemphigoid</p>	<p><i>Typically produces marked gingival erythema and ulceration; other areas of oral cavity, esophagus, and vagina may be affected</i></p> <ul style="list-style-type: none"> • Painful, grayish-white collapsed vesicles or bullae of full-thickness epithelium with peripheral erythematous zone • Gingival lesions desquamate, leaving ulcerated area 	<ul style="list-style-type: none"> • Protracted course with remissions and exacerbation • Involvement of different sites develops slowly • Glucocorticoids may temporarily reduce symptoms but do not control disease
<p>EM minor and EM major (Stevens-Johnson syndrome)</p>	<p><i>Primarily oral mucosa and skin of hands and feet</i></p> <ul style="list-style-type: none"> • Intraoral ruptured bullae surrounded by inflammatory area • Lips may show hemorrhagic crust • “Iris” or “target” lesion on skin is pathognomonic • Patient may have severe signs of toxicity 	<ul style="list-style-type: none"> • Onset very rapid • Usually idiopathic, but may be associated with trigger such as drug reaction • Condition may last 3–6 weeks • Mortality rate for untreated EM major is 5–15%
<p>Pemphigus vulgaris</p>	<p><i>Oral mucosa and skin; sites of mechanical trauma (soft/hard palate, frenulum, lips, buccal mucosa)</i></p> <ul style="list-style-type: none"> • Usually (>70%) presents with oral lesions • Fragile, ruptured bullae and ulcerated oral areas • Mostly in older adults 	<ul style="list-style-type: none"> • With repeated occurrence of bullae, toxicity may lead to cachexia, infection, and death within 2 years • Often controllable with oral glucocorticoids

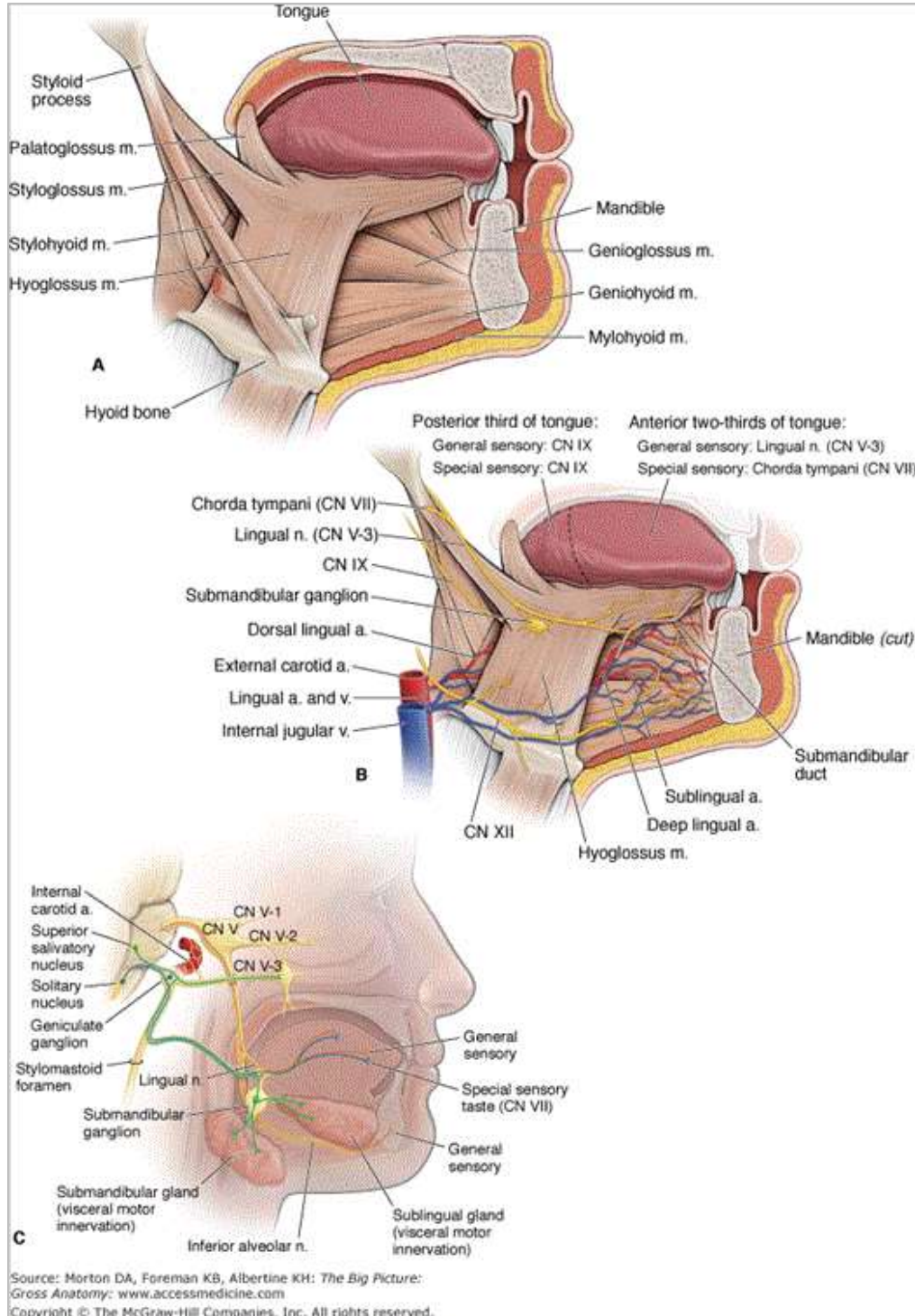
ORAL LESIONS ASSOCIATED WITH HIV INFECTION

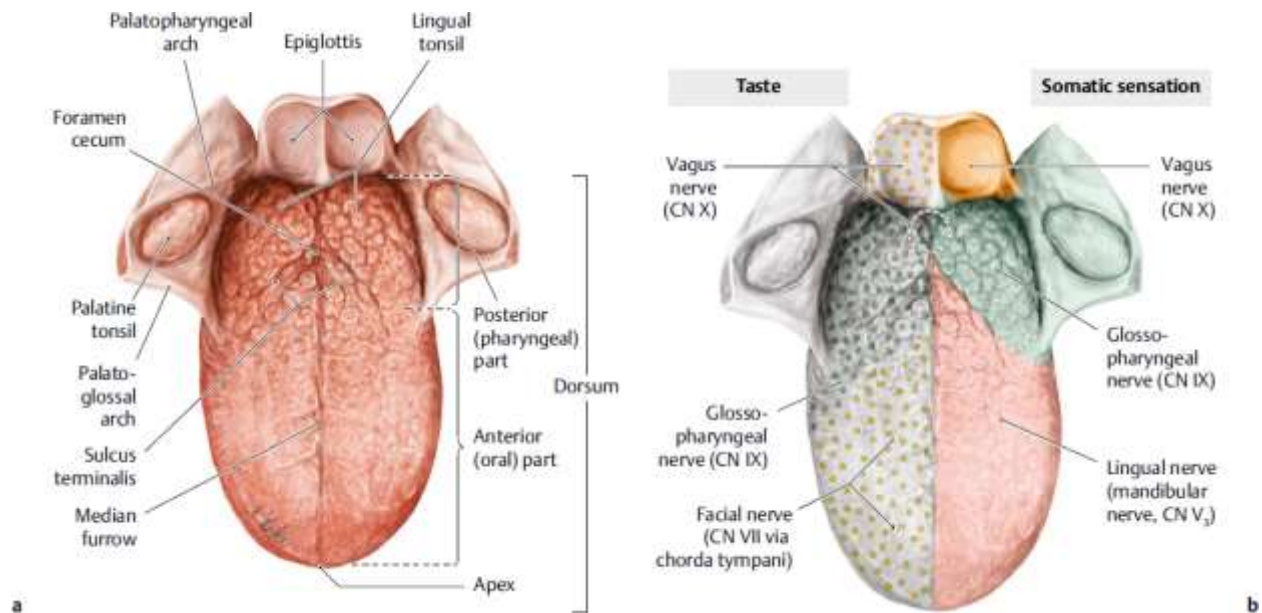
Lesion Morphology	Etiologies
Papules, nodules, plaques	<ul style="list-style-type: none"> • Candidiasis (hyperplastic and pseudomembranous) • Condyloma acuminatum (human papillomavirus infection) • Squamous cell carcinoma (preinvasive and invasive) • Non-Hodgkin's lymphoma • Hairy leukoplakia
Ulcers	<ul style="list-style-type: none"> • Recurrent aphthous ulcers • Angular cheilitis • Squamous cell carcinoma • Acute necrotizing ulcerative gingivitis • Necrotizing ulcerative periodontitis • Necrotizing ulcerative stomatitis • Non-Hodgkin's lymphoma • Viral infection (herpes simplex, herpes zoster, cytomegalovirus infection) • Infection caused by Mycobacterium tuberculosis or Mycobacterium avium-intracellulare • Fungal infection (histoplasmosis, cryptococcosis, candidiasis, geotrichosis, aspergillosis) • Bacterial infection (Escherichia coli, Enterobacter cloacae, Klebsiella pneumoniae, Pseudomonas aeruginosa) • Drug reactions (single or multiple ulcers)
Pigmented lesions	<ul style="list-style-type: none"> • Kaposi's sarcoma • Bacillary angiomatosis (skin and visceral lesions more common than oral) • Zidovudine pigmentation (skin, nails, and occasionally oral mucosa) • Addison's disease
Miscellaneous	<ul style="list-style-type: none"> • Linear gingival erythema

THE TONGUE


Anatomy

(A) Tongue muscles. (B) Neurovascular supply of the tongue. (C) Innervation of the tongue.

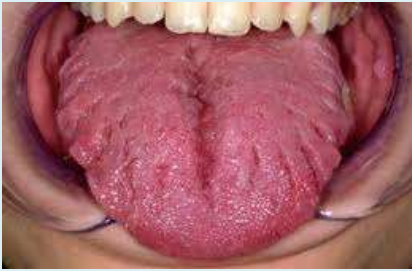



ALTERATIONS OF THE TONGUE

Size/Morphology/Color	Clinical Features
<p data-bbox="215 1287 418 1325">Macroglossia</p> 	<p data-bbox="578 1192 1468 1224">Diffuse enlargement of the tongue that may be symmetric or asymmetric</p> <ul data-bbox="630 1268 1533 1843" style="list-style-type: none"> • Mild symmetric enlargement is usually caused by loss of muscle tone such as in aging or with some systemic conditions such as amyloidosis. • May also be part of a syndrome found in developmental conditions such as Down syndrome, Simpson-Golabi-Behmel syndrome, or Beckwith-Wiedemann syndrome. • There is generally no treatment for symmetric lesions, unless the patient resorts to a surgical recontouring of the tongue. • Asymmetric enlargements are usually caused by a tumor. These include vascular malformations of either lymphatic (lymphangioma) or blood vascular origin (venous malformation). • In cases of amyloid deposits or a neoplasm, a biopsy is diagnostic. An MRI study is usually helpful for soft tissue tumors in the tongue that present with asymptomatic enlargement. • For patients with amyloidosis, a work-up for plasma cell dyscrasia is indicated. • For patients with other tumors, excision is the treatment of choice

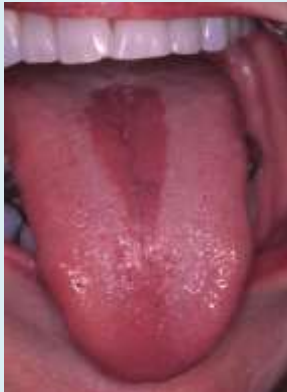Fissured tongue



Dorsal surface and sides of tongue covered by painless shallow or deep fissures that may collect debris and become irritated.

- Common condition that occurs in 1%–2% of the population, usually seen in adults
- There are two main patterns:
 - 1) A central fissure, either alone or with smaller fissures radiating from it at right angles.
 - 2) Short fissures distributed evenly throughout the tongue without the central fissure
- Condition is generally asymptomatic, though some patients report sensitivity of the tongue with spicy or acidic foods.
- In general, a fissured tongue is a permanent condition.

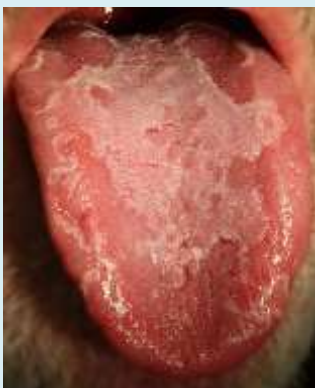Median rhomboid glossitis



Congenital abnormality with an ovoid, denuded area in median posterior portion of tongue

- May be associated with candidiasis and may respond to antifungal treatment

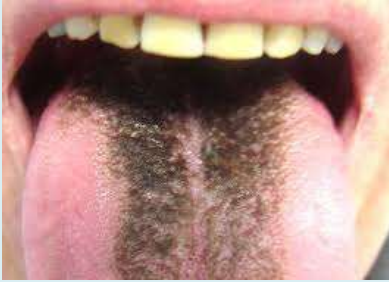Benign migratory glossitis (Geographic tongue)



Asymptomatic inflammatory condition of tongue, with rapid loss and regrowth of filiform papillae leading to appearance of denuded red patches “wandering” across surface

- Occurs in 1%–2% of the population (associated with a fissured tongue in about 30% of cases)
- Usually sensitive or painful, especially to acidic foods
- A history of atopy is often elicited
- Approximately 13% of patients with psoriasis develop this tongue condition.
- This is not infectious in etiology
- Symptomatic treatment may include diphenhydramine used as a swish and spit preparation or 2% viscous lidocaine.
- If severe, topical steroids such as dexamethasone may help

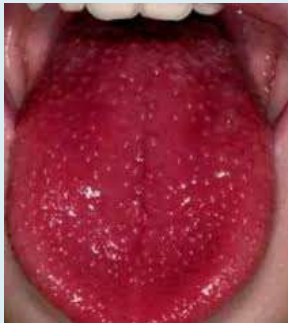Hairy tongue



Elongation of filiform papillae of medial dorsal surface area due to failure of keratin layer of papillae to desquamate normally. A brownish-black coloration may be due to staining by tobacco, food, or chromogenic organisms

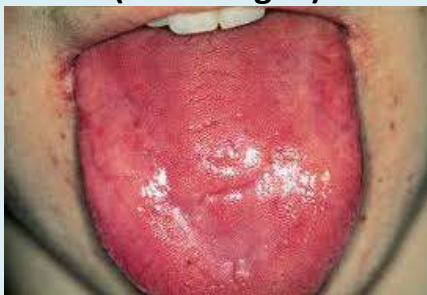- Caused by retention of keratinaceous debris on the tongue dorsum resulting from two factors acting alone or in combination:
 - (1) Dehydration (leading to more sticky and mucous rather than serous saliva).
 - (2) Poor oral intake (eating a soft diet or one low in fresh fruits and vegetables).
- Thickened matre of keratin on the tongue leads to increased bacterial colonization and their metabolic products (often sulfides) may lead to a foul or stale breath and may stain the tongue a variety of colors such as brown or black.
- Vigorous hydration and return to a normal diet with fresh fruits and vegetables generally resolve the lesions.
- The tongue may be brushed as part of the daily oral hygiene regimen to help to dislodge loose keratin squames and reduce discoloration.

“Strawberry” or “Raspberry” tongue





Appearance of tongue during scarlet fever due to hypertrophy of fungiform papillae as well as changes in filiform papillae

Atrophic Glossitis (Bald tongue)



Atrophy of the filiform and fungiform papillae of the tongue leads to a bald shiny, erythematous tongue dorsum

- Atrophy may be associated with xerostomia, pernicious anemia, iron-deficiency anemia, pellagra, or syphilis
- It may also be an expression of erythematous candidiasis and respond to antifungal treatment
- Patients often complain of a burning sensation and experience sensitivity when eating acidic, salty, or crunchy foods.
- Patient should have blood work to rule out hematinic deficiencies, in particular iron and vitamins B6 and B12 deficiency.
- Treatment consists of repletion of deficient elements or topical anesthetics help to control symptoms.

Condition	Clinical Features
<p>Hyperplastic Lingual Tonsil</p>  <p><small>Source: Goldman LA, Ruiz SL, Ockersin SA, Fisher AS, Laffel UJ, Wolff G, Fitzpatrick J (2016) <i>Oral Medicine: A General Medicine</i>, 2nd Edition. www.accessmedicine.com Copyright © The McGraw-Hill Companies, Inc. All rights reserved.</small></p>	<p>Hyperplastic lingual tonsil, when inflamed, protrudes as a fleshy, soft area with a slightly irregular surface (because of the crypts in the overlying foliate papillae), which then becomes more readily traumatized that then makes it even more inflamed and protuberant.</p> <ul style="list-style-type: none"> • Biopsy shows benign hyperplasia of lymphoid tissue. • Intralesional steroid injections may reduce the size of the lesion so that it is no longer traumatized. • Excision is curative.
<p>Papillitis of Tongue</p>  <p><small>Copyright © The McGraw-Hill Companies, Inc. All rights reserved.</small></p>	<p>Irritation of the tongue papillae either from local trauma, dryness, or a hypersensitivity reaction (possibly to a contactant).</p> <ul style="list-style-type: none"> • Dexamethasone mouth rinse reduces inflammation. • The provoking factor must be addressed to prevent recurrence.
<p>Tongue Nodules</p>	<ul style="list-style-type: none"> • Nodules on the lateral tongue tend to have a traumatic etiology and include fibromas (and its variant giant cell fibroma) and traumatic neuroma. • More common tumors of the tongue include benign nerve sheath tumors, granular cell tumors, oral lymphoepithelial cyst, vascular lesions such as pyogenic granulomas or venous malformations, and osseous and cartilaginous hamartomas. • All require excisional biopsy and have diagnostic histopathology

SALIVARY GLAND PATHOLOGY

Salivary glands consist of:

- Two parotid glands (and Stensen ducts)
- Two submandibular glands (and Wharton ducts)
- Two principal sublingual glands (and Ducts of Rivinus)
- Large number of minor salivary glands

Secretions: serous, mucous, or both

Components:

Water

Digestive enzymes

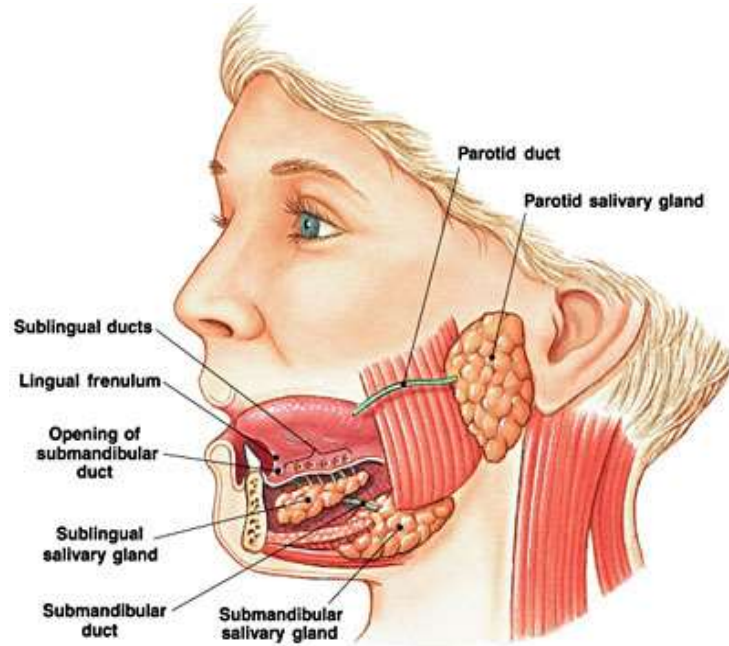
Mucin

Antimicrobial factors:

- *Lysozyme*
- *Lactoperoxidase*
- *Secretory IgA*

Epidermal growth factor

Minerals



- Major salivary glands (Parotid and submandibular) secrete intermittently in response to autonomic stimulation
- The lips and cheeks contain hundreds of minor glands that secrete mucus continuously throughout the day and night
- Saliva is produced by the clustered acinar cells and contains electrolytes, enzymes (e.g. ptyalin and maltase), carbohydrates, proteins, inorganic salts, and even some antimicrobial factors
- Approximately 500–1500 mL of saliva is produced by the acinar cells daily and transported through the ductal elements at an average rate of 1 mL per minute
- Abnormalities of saliva production can lead to dental caries, periodontal disease, and difficulties wearing dental prostheses, masticating, and speaking.

XEROSTOMIA

Refers to a subjective sensation of a dry mouth and is typically perceived when salivary flow is reduced by 50%. Xerostomia is a common problem that has been reported in 25% of older adults. Examination of the patient usually demonstrates a reduction in salivary secretions, and residual saliva appears foamy or thick. Patient may report difficulty with mastication and swallowing. There is increased oral candidiasis in patients with xerostomia because of the reduction in the cleansing and antimicrobial activity normally provided by saliva. These patients are also more prone to dental caries, especially cervical and root caries. This problem is particularly common with radiation therapy.

Causes of Xerostomia	Medications that may produce xerostomia
<p>Developmental Salivary gland aplasia</p> <p>Water/Metabolite Loss Impaired fluid intake Hemorrhage Vomiting/diarrhea</p> <p>Iatrogenic Medications Radiation therapy to the head and neck</p> <p>Systemic diseases Sjögren syndrome Diabetes mellitus Diabetes insipidus Sarcoidosis HIV infection Graft-versus-host disease Psychogenic disorders</p> <p>Local factors Decreased mastication Smoking Mouth breathing</p>	<p>Antihistamines Diphenhydramine Chlorpheniramine</p> <p>Decongestants Pseudoephedrine</p> <p>Antidepressants Amitriptyline</p> <p>Antipsychotics Phenothiazine derivatives Haloperidol</p> <p>Antihypertensives Reserpine Methyldopa Chlorothiazide Furosemide Metoprolol Calcium channel blockers</p> <p>Anticholinergics Atropine Scopolamine</p>

MANAGEMENT

- Elimination or limitation of drying medications
- Preventive dental care (more frequent dental visits, fluoride applications, chlorhexidine mouth rinses)
- Supplementation with commercial saliva substitutes or gel relieves dryness
- Sugarless mints or gum may stimulate salivary secretion if dysfunction is mild
- Pilocarpine or cevimeline has been shown to increase secretions if enough endocrine tissue remains
- Fluoride supplementation (critical to prevent caries)
- Hydration

Nonneoplastic Diseases of the Salivary Glands

Infectious	Noninfectious, Inflammatory	Noninflammatory
Mumps virus Coxsackie virus Influenza virus Echovirus Human immunodeficiency virus Bacteria Granulomatous infections	Sialolithiasis Chronic sialadenitis Sjögren syndrome Benign lymphoepithelial lesion Kimura disease Necrotizing sialometaplasia Adenomatoid hyperplasia Sarcoidosis	Sialadenosis Branchial cleft cysts Dermoid cysts Congenital cysts Mucoceles

Infection	
Acute Viral Inflammatory Disease	Acute, bilateral swelling of the parotid glands accompanied by pain, erythema, tenderness, malaise, fever, and occasionally trismus <ul style="list-style-type: none"> • Mumps (paramyxovirus) is the most common viral disorder • Peak incidence in young children aged 4–6 years • Incubation period is 14–21 days • Contagious • Confirm diagnosis with serologic testing: <ul style="list-style-type: none"> ○ (antibodies for mumps S, mumps V, hemagglutination) • Complications may involve other organs which can include meningitis, encephalitis, hearing loss, orchitis, pancreatitis, and nephritis • Disease is typically self-limiting and primarily symptomatic
Acute Suppurative Sialadenitis	Acute painful swelling of the salivary glands with fever <ul style="list-style-type: none"> • Can occur in postoperative patients and in elderly patients with chronic medical conditions • Risk factors include dehydration, trauma, immunosuppression, and debilitation • Skin overlying the parotid may be warm, tender, and edematous • Untreated acute suppurative sialadenitis may lead to an abscess • Saliva from the affected gland should be cultured • Common bacteria cultured: <i>Staphylococcus aureus</i>, <i>Streptococcus pneumoniae</i>, <i>Escherichia coli</i>, and <i>Haemophilus influenzae</i> • Other organisms obtained from chronically ill, hospitalized patients: Klebsiella, Enterobacter, Pseudomonas, and Candida • Treatment consists of rehydration, intravenous antibiotics with penicillinase-resistant gram-positive coverage, warm compresses, massage, sialogogues, improved oral hygiene

	<ul style="list-style-type: none"> • If an abscess is suspected, incision and drainage using a parotidectomy incision may be performed
Chronic Granulomatous Sialadenitis	<ul style="list-style-type: none"> • Chronic unilateral or bilateral salivary gland swelling • Minimal pain • Fine-needle aspiration biopsy of the gland can aid in diagnosis • Risk factors such as exposure to tuberculosis, animal exposure, trauma, and multiorgan system involvement should be considered • The differential diagnoses include: animal cat-scratch disease, sarcoidosis, actinomycosis, Wegener granulomatosis, and syphilis • Uveitis, facial palsy, and parotid enlargement are suggestive of sarcoidosis.

Noninfectious, Inflammatory Disease	
Sialolithiasis	<ul style="list-style-type: none"> • Condition where calcified mass or sialolith forms within a salivary gland • Acute, painful swelling of the major salivary gland, especially the submandibular gland, which may be recurrent • Aggravation of symptoms with eating; swelling may subside after approximately 1 hour • History of gout or xerostomia • A stone in the floor of the mouth may be palpated • Treatment depends on the location of the calculus • Calculus may be extracted intraorally, or if distal, then the submandibular gland may be indicated • Complications include acute suppurative sialadenitis, ductal ectasia, and stricture
Chronic Sialadenitis	<ul style="list-style-type: none"> • Results from decreased production of saliva or alterations in the salivary flow leading to salivary stasis, which creates an environment at risk for infection • Presenting symptoms consist of chronic, intermittent painful swelling of the salivary gland, especially with eating • As a reactive process to trauma or disease, chronic non-obstructive sialadenitis may progress to a fibrous mass formation or an inflammatory pseudotumor • Conservative therapy and surgical gland excision are the most successful treatment methods of chronic non-obstructive sialadenitis • If no treatable cause is identified, patients are encouraged to improve oral hygiene with increased hydration, massage of the affected gland, adequate nutrition, and use of sialagogues. Antibiotics are administered with acute exacerbations.

Sjögren Syndrome	<ul style="list-style-type: none"> • An autoimmune disorder characterized by parotid enlargement, xerostomia, and keratoconjunctivitis sicca • Often associated with another connective tissue disease • More commonly seen in postmenopausal women • Detection of autoantibodies SS-A and SS-B and others, along with minor salivary gland biopsy, may confirm the diagnosis • Slowly progressive disease • High risk for development of malignant lymphoma <p>Treatment</p> <ul style="list-style-type: none"> • Primarily symptomatic and supportive • Steroids and topical steroid eyedrops may be indicated for severe symptoms • Superficial parotidectomy may be required for severe recurrent parotid infections
-------------------------	--

Salivary Neoplasms

Benign Salivary Gland Tumors	<ul style="list-style-type: none"> • 64–80% of primary salivary tumors occur in the parotid gland, 7–15% occur in the submandibular gland, and <1% occur in the sublingual glands. • 54–80% of all tumors are benign. • Peak incidence of salivary tumors occurs in the 6th-7th decades. • Painless, slowly enlarging solitary mass in the salivary gland. • Deep parotid lobe tumors may present as a painless, asymmetric swelling of the soft palate. • Fine-needle aspiration cytology and imaging aid in the diagnosis. • Complete surgical excision is most often curative.
Papillary Cystadenoma Lymphomatosum (Warthin tumor)	<ul style="list-style-type: none"> • Histologically characterized by papillary structures composed of double layers of granular eosinophilic cells or oncocytes, cystic changes, and mature lymphocytic infiltration • Arises from the ectopic ductal epithelium, almost exclusively in the parotid gland • More commonly seen in males in the 5th-7th decades of life and there is an associated risk with smokers • The treatment requires complete excision of the affected portion of the gland with uninvolved margins
Monomorphic Adenomas	<ul style="list-style-type: none"> • Slow-growing tumors represent less than 5% of all salivary gland tumors • It is a group of mostly epithelial and myoepithelial neoplasms that include basal cell adenomas, canalicular adenomas, oncocytomas or oxyphilic adenomas, and myoepitheliomas.

<p>Pleomorphic Adenoma</p>	<ul style="list-style-type: none"> • Comprises of 2/3 of all salivary neoplasms. • Firm slow growing mass and considered benign. • Can recur if resection incomplete
<p>Malignant: Mucoepidermoid Carcinoma Adenoid Cystic Carcinoma Adenocarcinoma</p>	<ul style="list-style-type: none"> • Typically fast growth • May ulcerate and invade nerves, producing numbness and facial paralysis. • 5-year survival rate ~68%

ORAL AND DENTAL EMERGENCIES

Non-Traumatic Causes of Potential Oral Pain	
Odontogenic Origin	
<ul style="list-style-type: none"> • Tooth eruption • Pericoronitis • Dental caries • Dentinal sensitivity/cervical erosion • Reversible pulpitis • Irreversible pulpitis 	<ul style="list-style-type: none"> • Cracked tooth syndrome • Periradicular periodontitis • Periapical abscess/facial space infection • Postextraction discomfort • Postextraction alveolar osteitis • Post-restorative pain
Periodontal Pathology	
<ul style="list-style-type: none"> • Gingivitis • Periodontal disease • Gingival abscess 	<ul style="list-style-type: none"> • Periodontal abscess • Acute necrotizing gingivostomatitis • Peri-implantitis
Neurogenic/Neurophysiologic Syndromes	
<ul style="list-style-type: none"> • Trigeminal neuralgia • Other cranial neuralgias 	<ul style="list-style-type: none"> • Bell's Palsy • Temporomandibular disorder
Non-dental Infections	
<ul style="list-style-type: none"> • Oral candidiasis • Herpes simplex types 1 & 2 • Varicella-zoster, primary and secondary • Mumps • Sialadenitis 	<ul style="list-style-type: none"> • Hand-foot-and-mouth disease • Sexually transmitted infections • Sinusitis • Parotitis • Herpangina
Malignancies	
<ul style="list-style-type: none"> • Squamous cell carcinoma • Kaposi's sarcoma • Lymphoma 	<ul style="list-style-type: none"> • Leukemia • Melanoma • Graft-versus-host disease
Other Etiologies	
<ul style="list-style-type: none"> • Aphthous ulcers • Traumatic ulcers • Stomatitis and mucositis • Uremia • Vitamin deficiency • Radiation/chemotherapy relation • Benign migratory glossitis 	<ul style="list-style-type: none"> • Pyogenic granuloma • Lichen planus • Cicatricial pemphigoid • Pemphigous vulgaris • Erythema multiforme • Crohn's disease • Behcet's syndrome

Orofacial Trauma

- | | |
|---|---|
| <ul style="list-style-type: none">• Dental fractures• Subtle enamel cracks/infractures• Dental crown and/or root fractures• Dental luxations and avulsions | <ul style="list-style-type: none">• Alveolar ridge fractures• Facial bone fractures• Oral soft tissue lacerations |
|---|---|

PAIN OF ODONTOGENIC ORIGIN

Tooth Eruption

Eruption of primary or deciduous teeth in infants is often accompanied by irritability, drooling, and decreased intake. About 11-12% of teething infants will have a mildly elevated temperature. Eruption of permanent teeth (particularly third molars or wisdom teeth) may cause pain. Gingival irritation and inflammation may also be present.

Pericoronitis

Pericoronitis is inflammation of the operculum, which is the gingival tissue overlying the occlusal surface of an erupting tooth. Impaction of food and or debris underneath the operculum can result in a severe inflammatory response. If untreated, it may lead to localized infection. Trismus can result because of the close proximity of the masticator space to third molars. It can be life threatening if infection spreads to connecting parapharyngeal spaces.

Treatment: Antibiotics (penicillin VK, 500 mg PO four times a day, or clindamycin, 300 mg PO four times a day), irrigation of food and debris, saline mouth rinses, and analgesia with NSAIDs or opiates as appropriate.

Dental Caries

Dental caries is the loss of the integrity of the tooth enamel from hydroxyapatite dissolution by prolonged exposure to the acidic metabolic by-products of plaque bacteria. Common places for caries to occur are pits and fissures of the occlusal surface and near the gingival margins. Direct communication between oral environment and dental pulp can lead to sensitivity to cold or sweet stimulus. Patient must see a dentist for definitive treatment.

Pulpitis

Inflammation of the dental pulp is initially reversible, but after continued stimuli, the pulp's ability to respond and repair is compromised. In reversible pulpitis, pain is triggered by stimulus (heat, cold, sour or sweet) and lasts only seconds. In irreversible pulpitis, pain can last for minutes to hours. Spontaneous tooth pain usually represents pulpal necrosis and is treated with analgesia, antibiotics (penicillin VK, 500 mg PO four times a day, or clindamycin, 300 mg PO four times a day) and referral to a general dentist. Definitive treatment for irreversible pulpitis and pulpal necrosis is root canal therapy or dental extraction.

Cracked Tooth Syndrome

This syndrome occurs when there is an incomplete fracture of a tooth that may extend into the vital pulp. Molars are commonly affected. There may be pain with chewing that resolves when chewing ceases. Cold and sweet stimuli can also trigger pain.

Treatment: NSAIDs for temporary pain control and instruction to avoid chewing on the affected side. Patient must see a dentist for definitive treatment.

Periradicular Periodontitis

Acute periradicular periodontitis is the extension of pulp disease, inflammation, or necrosis into the tissues surrounding the root and apex of the tooth leading to widening of the periodontal ligament space and or a thinning of the lamina dura. In dental radiographs, these lesions are characterized by a radiolucent area associated with the root apex. Percussion of the suspected tooth with a light metal instrument can help identify the affected tooth. It is important to note that a periapical abscess is radiographically and clinically indistinguishable from periradicular periodontitis. There may be the presence of a parulis, a small swelling of gingiva with a draining fistula near the affected tooth. Treatment of dental abscesses or other periapical lesions includes antibiotics (penicillin VK, 500mg PO four times a day, or clindamycin, 300mg PO four times a day) and NSAIDs/opiates for pain. Refer to a dentist for definitive treatment.

Facial Space Infections

Infections can spread to various facial spaces:

- **Perforation of lingual cortical bone of mandibular molars (2nd or 3rd) → submandibular space**
- **Maxillary labial infection → infraorbital space**
Infection of the infraorbital space may involve the cavernous sinus through retrograde spread through the ophthalmic veins. Cavernous sinus thrombosis is characterized by infraorbital or periorbital cellulitis with meningeal signs, sepsis, and coma.
- **Periapical infections associated with mandibular teeth → lingual space**
Ludwigs's angina results from cellulitis of bilateral submandibular spaces and the lingual space. It is potentially life threatening because these spaces communicate directly with the parapharyngeal space, where if infected, could compromise the airway.

Postextraction Pain

Pain can be related to the trauma of dental surgery. Postoperative edema peaks within the first 24-48 hours of the extraction (such as with third molars). Trismus may result from normal perioperative inflammation or direct damage of TM joint and/or muscles of mastication during the surgery or the administration of a nerve block. Trismus peaks after 24 hours and decreases with time. Worsening trismus could indicate infection. Manage pain with ice packs, elevation of the head of the bed to 30 degrees, NSAIDs and oral narcotics.

Postextraction Alveolar Osteitis (Dry Socket)

After an extraction, total or partial displacement of the clot from the socket or fibrinolytic dissolution of the clot results in exposure of the alveolar bone and initiates a localized osteomyelitis of the exposed bone. It usually occurs on the second or third postoperative day and is accompanied with significant oral pain. Incidence is 1-5% of all extractions but up to 30% among impacted third molar extractions.

Treatment: Gentle irrigation with saline or chlorhexidine 0.12% oral rinse. Local or topical anesthesia may be needed. Manage pain with NSAIDs/opiates and refer for dental follow up. Antibiotics may be needed for severe cases.

Post Extraction Bleeding

After a tooth has been extracted, if the clot that forms in the socket is displaced, it may result in recurrent or continued bleeding. To control bleeding, it is best to apply firm pressure to the site for 20 minutes with a 2x2-inch gauze pad. If not successful, apply absorbable gelatin sponge (Gelfoam[®]), microfibrillar collagen (Avitene[®]), or regenerated cellulose (e.g. Surgicel[®]) into the socket to provide matrix for clot formation. Sutures may be used to hold the agents in place. If this still does not control bleeding, carefully inject the soft tissue surrounding the extraction with lidocaine or epinephrine. Another option is careful cautery with silver nitrate. If these methods fail, then an oral and maxillofacial surgical consultation is needed.

Postrestorative Pain

This may result from normal trauma from mechanical instrumentation of the tooth or direct exposure of the pulpal tissue during instrumentation. Pain occurs primarily with mastication, which may indicate improper occlusion of the new dental restoration or filling. After endodontic therapy, pressure build up in the pulpal chamber can cause severe pain.

Management: Control pain with NSAIDs/narcotics, and refer patient to a dentist. Temporary prolonged pain relief can also be obtained with an appropriate anesthetic block.

Orthodontic Appliances

A broken or bent wire may irritate or lacerate the cheek or lip. The wire needs to be bent away from soft tissue. If necessary, portions of the wire can be removed in its entirety by removing the rubber ligatures from each orthodontic bracket. These patients should follow up with their orthodontists as soon as possible.

PERIODONTAL PATHOLOGY

Periodontal disease

It is a continuum of disease that starts with gingivitis (gingival inflammation and bleeding) and can progress to the destruction of the periodontal attachment apparatus, deepening of the normal gingival sulcus, periodontal pocket formation, bone loss, tooth mobility, and ultimately tooth loss. Many factors including oral hygiene, hormonal variations, medications, and systemic disease can influence this. This disease is usually painless but may present with swollen gingival tissue or bleeding. Treatment is directed at slowing or stopping the progression of disease by the removal of plaque and its by-products. Refer to a dentist for definitive treatment, which may include extensive dental cleaning, education on better oral hygiene, and/or periodontal surgery for severe cases.

Gingival and Periodontal Abscess

A gingival abscess presents as a painful swelling confined to the margin of the gingiva or interdental papilla. It can rapidly enlarge over 24-48 hours and a purulent exudate can be expressed from the orifice. The most common cause is the entrapment of foreign matter (e.g. popcorn kernel, piece of meat, toothbrush bristle, or piece of food) in the gingiva.

Treatment: Must identify and remove the embedded foreign body and irrigate with normal saline.

Plaque and debris that becomes entrapped in the periodontal pocket may lead to a painful periodontal abscess. Small periodontal abscesses typically respond to warm saline rinses and antibiotics. Large abscesses need incision and drainage. Chlorhexidine 0.12% mouth rinses twice daily may help. Manage pain with NSAIDs or narcotics as appropriate.

Acute Necrotizing Ulcerative Gingivitis

This disease is also known as Vincent's disease or trench mouth. It may present as localized ulceration of the gingiva or as a more severe form, where localized ulceration and necrosis spread to the adjacent tissues of the cheeks, lips, and underlying facial bones. It appears to be an opportunistic infection with anaerobic bacteria such as *Treponema*, *Selenomonas*, *Fusobacterium*, and *Prevotella*. Infection with HIV is the most important predisposing factor. Other factors include poor oral hygiene, unusual emotional stress, poor diet, inadequate sleep, poor socioeconomic status, recent illness, alcohol use, tobacco use, acatalasia, and various infections such as malaria, measles, and intestinal parasites. The diagnostic triad includes pain, ulcerated or "punched out" interdental papillae, and gingival bleeding. Other signs include foul smelling breath, pseudomembrane formation, "wooden teeth" feeling, foul metallic taste, tooth mobility, lymphadenopathy, fever, and malaise. The differential diagnosis for this disease is extensive but herpes gingivostomatitis is the most difficult to differentiate. Herpes gingivostomatitis typically has smaller vesicular eruption, less bleeding, more systemic signs, and lack of interdental papilla involvement. Treatment focuses on bacterial control with chlorhexidine 0.12% oral rinses twice a day, professional debridement and scaling, and adjunctive antibiotic therapy with metronidazole, 500 mg PO three times daily.

Peri-Implantitis

Over the last 30 years, osseointegrated dental implants have been developed and used to allow a dental implant to replace tooth. Any pathologic changes around an implant are all given the general term, peri-implant disease. The clinical presentation of peri-implantitis is similar to that of a periodontal abscess. Treatment is also similar and focuses on the removal of plaque and debris from around the implant and irrigation with normal saline or 0.12% chlorhexidine solution. Antibiotics (metronidazole, 500mg PO three times a day for 10 days, or amoxicillin, 500mg PO three times a day for 10 days) are also indicated. Pain is managed with NSAIDs and opiates as needed, and the patient should be referred to a dentist for definitive care.

NEUROGENIC AND NEUROPHYSIOLOGIC SYNDROMES

Craniofacial Neuralgias

The most common is trigeminal neuralgia. Other less common neuralgias include glossopharyngeal neuralgia, vagal neuralgia, and superior laryngeal neuralgia. Post-herpes zoster-related neuralgia is also a cause of acute facial pain which can become chronic.

Bell's Palsy (Idiopathic Facial Nerve Palsy)

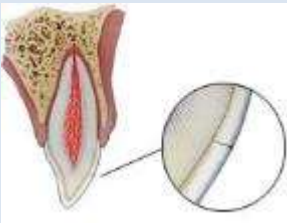
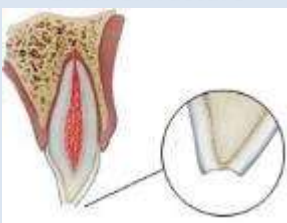
It presents as a peripheral unilateral weakness of the facial nerve of unknown etiology. Consider herpes zoster as it may present with a nonspecific pain prior to the onset of weakness or the onset of any visible vesicles.





Temporomandibular Disorder



A common cause of facial pain and headache due to symptoms involving the muscles of mastication or the temporomandibular joint.

DENTAL FRACTURES

A fracture of the tooth can involve any part of the enamel, dentin, and pulp. Emergency treatment of a fractured tooth is focused on maintaining pulpal viability and completion of the formation of the root and apex of the tooth. Therefore, treatment is aimed at sealing the dentinal tubules and creating barrier between the dental pulp and the oral environment. The International Association of Dental Traumatology (IADT) system divides dental trauma into eight categories:

	Clinical Findings	Management & Treatment
<p>Infraction</p> 	<ul style="list-style-type: none"> An incomplete fracture (crack) of the enamel without loss of tooth structure. Not tender. If tenderness is observed, it is necessary to evaluate the tooth for a possible luxation injury or a root fracture. 	<ul style="list-style-type: none"> Requires no emergency treatment In case of marked infractions, a dentist can etch and seal with resin to prevent discoloration of the infraction lines. Otherwise, no treatment is necessary.
<p>Enamel fracture</p> 	<ul style="list-style-type: none"> A complete fracture of the enamel. Loss of enamel. No visible sign of exposed dentin. Not tender. If tenderness is observed, tooth needs evaluation for a possible luxation or root fracture injury. Normal mobility. 	<ul style="list-style-type: none"> No emergency treatment is needed, except to smooth any sharp corners that may irritate or lacerate the tongue or mucosa. Refer patient to a general dentist for any cosmetic concerns and repairs. If the enamel fragment is recovered and kept moist, a dentist can bond it back in place. If the fragment is not recovered, soft tissue radiographs of any oral lacerations are needed to rule out foreign bodies.

<p>Enamel-dentin fracture</p> 	<ul style="list-style-type: none"> • A fracture confined to enamel and dentin with loss of tooth structure, but not exposing the pulp. • Account for 70% of all tooth fractures. • Dentin (creamy yellow color) can be visualized. • Percussion test: not tender. If tenderness is observed, the tooth needs to be evaluated for possible luxation or root fracture injury. • Normal mobility. 	<ul style="list-style-type: none"> • Needs immediate attention as delayed treatment (>24-48 hrs) can increase risk of pulpal necrosis. • If treatment cannot be done within 1-2 days, it is recommended that the exposed dentin be covered using glass ionomer dental cement. • If the exposed dentin is within 0.5 mm of the pulp (pink, no bleeding), place calcium hydroxide base and then cover with a glass ionomer dental cement. • Referral to a dentist for definitive treatment is important. • If a tooth fragment is available, it can be bonded to the tooth • Radiograph of lip or cheek lacerations to search for tooth fragments or foreign materials.
<p>Enamel-dentin-pulp fracture</p> 	<ul style="list-style-type: none"> • A fracture involving enamel and dentin with loss of tooth structure and exposure of the pulp. • When wiping the fractured surface with dry and sterile gauze, blood can be found originating from the pulp. • Normal mobility. • Percussion test: not tender. If tenderness is observed, needs evaluation for possible luxation or root fracture injury. • Exposed pulp is sensitive to stimuli. 	<ul style="list-style-type: none"> • After bleeding is controlled, the exposed pulp should be covered with a calcium hydroxide base. This area, along with the exposed dentin, should then be covered with glass ionomer cement. • Obtain radiograph of lip or cheek lacerations to search for tooth fragments or foreign materials. • Refer to a dentist as these fractures will need root canal therapy. • Oral analgesia may be needed.
<p>Crown-root fracture without pulp exposure</p> 	<ul style="list-style-type: none"> • A fracture involving enamel, dentin and cementum with loss of tooth structure, but not exposing the pulp (an uncommon result of dental trauma). • Crown fracture extending below gingival margin. • Percussion test: Tender. • Coronal fragment mobile or displaced. 	<p>Emergency treatment</p> <ul style="list-style-type: none"> • As an emergency treatment, a temporary stabilization of the loose segment to adjacent teeth can be performed until a definitive treatment plan is made. • There should be dental follow-up within 24-48 hours. • If the tooth is extremely mobile, extraction may be required to prevent possible aspiration. • If less than 1/3 of the root is involved, a dentist can perform root canal therapy with possible restoration of the tooth.
<p>Crown-root fracture with pulp exposure</p> 	<ul style="list-style-type: none"> • A fracture involving enamel, dentin and cementum and exposing the pulp (an uncommon result of dental trauma). • Percussion test: tender. • Coronal fragment displaced or mobile. 	<ul style="list-style-type: none"> • As an emergency treatment, a temporary stabilization of the loose segment to adjacent teeth can be performed until a definitive treatment plan is made. • There should be dental follow-up within 24-48 hours. • If the tooth is extremely mobile, extraction may be required to prevent possible aspiration. • If less than 1/3 of the root is involved, a dentist can perform root canal therapy with possible restoration of the tooth. • Oral analgesia may be needed.

<p>Root fracture</p> 	<ul style="list-style-type: none"> • The coronal segment may be mobile and may be displaced • Transient crown discoloration (red or gray) may occur • There is usually tenderness to percussion of the affected tooth. 	<ul style="list-style-type: none"> • Emergency treatment is directed at stabilizing the coronal segment and repositioning the coronal segment to its original position, until definitive treatment can be scheduled. • Obtain radiograph of lip or cheek to search for tooth fragments or foreign materials. • There should be dental follow-up within 24-48 hours. • If the tooth is extremely mobile, extraction may be required to prevent possible aspiration. If less than 1/3 of the root is involved, a dentist can perform root canal therapy with possible restoration of the tooth. • If the tooth fragment is available, it can be bonded to the tooth.
<p>Alveolar fracture</p> 	<ul style="list-style-type: none"> • The fracture involves the alveolar bone and may extend to the adjacent bone. • Segment mobility and dislocation with several teeth moving together are common findings. • An occlusal change due to misalignment of the fractured alveolar segment is often noted. 	<ul style="list-style-type: none"> • Reposition any displaced segment and then splint. • Suture gingival laceration, if present. • Stabilize the segment for 4 weeks.

LUXATION INJURIES





Forces that cause dental fractures are also capable of loosening a tooth from the attachment apparatus. Teeth should be evaluated for tenderness, malpositioning, or mobility. Luxations make up nearly 50% of injuries to teeth. There are six types of luxations: concussion, subluxation, extrusive luxation, lateral luxation, intrusive luxation, and avulsion. All patients with luxation injuries should be restricted to a soft diet for at least two weeks. Good oral hygiene is also important. Mouth rinsing with chlorhexidine 0.12% two times daily may also be helpful. Referral to a dentist for close-follow up is crucial.



Sequelae of Luxation Injuries

These injuries can include pulp canal obliteration, pulpal necrosis, internal and external resorption of the root, and ankylosis. Transient apical breakdown will occur with all types of luxations but is especially common with extrusive and lateral luxations and avulsions. More than 50% of extrusively luxated teeth undergo pulpal necrosis within 1.5 years of the traumatic event. Close dental follow-up is essential for detection of these sequelae. Forces that result in luxation injuries can commonly result in alveolar ridge fracture as well. For optimal results, stabilization of repositioned alveolar segments and associated teeth is essential for optimal results. Ideally with flexible fixation placed by a general dentist or oral surgeon. Stabilization is maintained for 4 weeks, up to 6 weeks, with significant fractures.

Luxation injuries of primary teeth

In patents 6-12 years old, dentition is mixed so it is important to distinguish primary from permanent teeth. Avulsed primary teeth are never replanted. Most luxation injuries in children require no treatment and heal spontaneously. Severe luxation usually requires extraction of the tooth. This is because repositioning or replanting primary teeth risks injuring the underlying permanent teeth. Intruded primary teeth are left alone to re-erupt into normal position. A dentist should manage most complicated luxation injuries of primary teeth to reduce risk of damage of permanent teeth. Referral to a general dentist is crucial to ensure optimal long-term outcome.

	Clinical Findings	Management & Treatment
<p>Concussion</p> 	<ul style="list-style-type: none"> • The tooth is tender to touch or tapping. • It has not been displaced and does not have increased mobility. • No radiographic abnormalities. 	<ul style="list-style-type: none"> • No treatment is needed. • Patient should eat a soft diet, manage pain with NSAIDs, and follow-up with a dentist to confirm diagnosis and rule-out more serious injury.
<p>Subluxation</p> 	<ul style="list-style-type: none"> • The tooth is tender to touch or tapping and has increased mobility. It has not been displaced. • This injury is associated with a higher incidence of subsequent pulpal necrosis. • Bleeding from gingival crevice may be noted. 	<ul style="list-style-type: none"> • Normally no treatment is needed • This does not usually require splinting, however, a flexible splint to stabilize the tooth for patient comfort can be used for up to 2 weeks.
<p>Extrusive luxation</p> 	<ul style="list-style-type: none"> • A partial or total disruption of the periodontal ligament resulting in a partial dislodgment of a tooth from the alveolar bone. • The tooth appears elongated and is excessively mobile. 	<ul style="list-style-type: none"> • This requires repositioning the tooth to its original position and splinting to stabilize the tooth during healing • A dentist can place a flexible wire stint, however in the ED setting, providing a temporary splint with non-eugenol zinc oxide periodontal dressing is acceptable. • Local anesthesia may be required. • Patient should see a dentist or maxillofacial surgeon within 24 hours.
<p>Lateral luxation</p> 	<ul style="list-style-type: none"> • The tooth is displaced, usually in a palatal/lingual or labial direction. • It will be immobile and percussion usually gives a high, metallic (ankylotic) sound. • Fracture of the alveolar process present. 	<ul style="list-style-type: none"> • Reposition the tooth digitally or with forceps to disengage it from its bony lock and gently reposition it into its original location. • Intra-arch stabilization is required for 4 weeks. • If there is minimal associated alveolar fracture, temporary splinting with a periodontal dressing is acceptable. Otherwise splinting by an oral and maxillofacial surgeon or general dentist is required in the ED.

<p>Intrusive luxation</p> 	<ul style="list-style-type: none"> • The tooth is displaced axially into the alveolar bone and is associated with periodontal ligament damage and alveolar bone contusion and fracture. • It is the most serious because there is significant damage to the periodontal ligament and alveolar socket. • It is immobile and percussion may give a high, metallic (ankylotic) sound. 	<ul style="list-style-type: none"> • It is recommended that the tooth be allowed to erupt on its own. Orthodontically extrude the tooth if no eruption is noted by three weeks. • Note: Root resorption is common as a result of damage to the periodontal ligament.
<p>Avulsion</p> 	<ul style="list-style-type: none"> • Avulsion is total displacement of a tooth from its socket. • It accounts for up to 16% of all dental injuries. 	<ul style="list-style-type: none"> • Best treatment is replantation at the scene as early improper replantation holds a higher success rate for tooth salvage than delayed replantation by a professional in the ED. • Only the crown portion of the tooth should be handled. • Rinse the tooth no more than 10 seconds with sterile normal saline or tap water in order to remove debris and place it immediately into the socket. • If the risk for aspiration is high (i.e. child, person with disability, or decreased level of consciousness) then transport the tooth with the patient to the ED. • Successful replantation relies on survival of the periodontal ligament fibers that remain attached to the avulsed tooth and so it is best to place the tooth in isotonic solutions such as Hank's balanced salt solution, sterile saline, milk, or saliva. • NOTE: Milk is an acceptable medium because of its osmolarity and concentration of calcium and magnesium ions. Hank's is the best transport solution as it maintains ligamental cell viability for up to 4-6 hours and even helps restore cell viability in a tooth that has been avulsed longer than 20 minutes. • If the avulsed tooth was not recovered, obtain radiographs to ensure the tooth was not aspirated. <p style="text-align: center;">SEE NEXT SECTION ON SPECIFIC RECOMMENDATIONS FOR REPLANTATION OF AVULSED TEETH</p>

Recommendations for Replantation of Avulsed Teeth

For all patients:

- Administer systemic antibiotics
 - Doxycycline, 100 mg PO twice a day (adults)
 - Penicillin VK (12.5 mg/kg/dose) PO four times a day (children <12yo)
- If the avulsed tooth has been in contact with soil, and if tetanus coverage is uncertain, provide a tetanus booster.
- Instruct the patient to brush teeth with a soft toothbrush after every meal and use chlorhexidine 0.12% mouth rinse two times daily.

Replantation of Avulsed Teeth	
<i>NOTE: Acceptable transport media from best to worse: Hank's balanced saline>> milk> water</i>	
Clinical Scenario	Treatment
Open apex Moist tooth stored in acceptable media, and/or <60 min extra oral dry time	1. Gently irrigate the tooth root clean with sterile saline. 2. If available, cover root with minocycline hydrochloride microspheres (Arestin™, OraPharma, Inc.) or soak for 5 min in doxycycline solution (doxycycline, 1 mg/20 mL saline). 3. Administer local anesthesia. 4. Irrigate the socket with saline. Examine the socket. If there is a fracture of the socket wall, reposition it with an appropriate instrument. 5. Firmly replant tooth and verify the tooth position clinically and radiographically, if possible. 6. Flexible splint for up to 2 weeks.
Open apex Extra oral dry time >60 min or other reason suggesting nonviable cells	1. Remove from tooth attached necrotic soft tissue carefully with gauze. 2. If available, immerse tooth in 2% stannous fluoride solution for 20 min. 3. Administer local anesthesia. 4. Irrigate the socket with saline. 5. Examine the socket. If there is a fracture of the socket wall, reposition it with an appropriate instrument. 5. Firmly replant tooth and verify the tooth's position clinically and radiographically, if possible. 6. Flexible splint for up to 4 weeks.
Closed apex Moist tooth stored in acceptable media, and/or <60 min extra oral dry time	1. Gently irrigate the tooth root clean with sterile saline. 2. Administer local anesthesia. 3. Irrigate the socket with Saline. 4. Examine the socket. If there is a fracture of the socket wall, reposition it with an appropriate instrument. 5. Firmly replant tooth and verify the tooth's position clinically and radiographically, if possible 6. Flexible splint for up to 2 weeks.
Closed apex Extra oral dry time >60 min or other reason suggesting nonviable cells	1. Remove from tooth attached necrotic soft tissue carefully with gauze. 2. If available, immerse tooth in 2% stannous fluoride solution for 20 min. 3. Administer local anesthesia. 4. Irrigate the socket with saline 5. Examine the socket. If there is a fracture of the socket wall, reposition it with an appropriate instrument. 6. Firmly replant tooth and verify the tooth's position clinically and radiographically, if possible. 7. Flexible splint for up to 4 weeks.

SOFT TISSUE TRAUMA

Laceration Location	Treatment
Oral Cavity Mucosa	<ul style="list-style-type: none"> • Small lacerations (<1 cm) typically do not need repair and can be allowed to heal naturally. • Suture closure of intraoral lacerations is usually indicated when wounds are large enough to trap food particles or have a tissue flap that interferes with chewing. • Use 4-0 absorbable suture to close the mucosa. • Lacerations of the cheek or buccal mucosa need to be examined carefully for involvement of Stensen's duct which drains the parotid salivary glands. • Lacerations of the floor of the mouth require careful evaluation for involvement of Wharton's duct of the submandibular salivary glands. • If a duct is compromised, repair by an oral or maxillofacial surgeon or otorhinolaryngologist is needed.
Lips	<ul style="list-style-type: none"> • May lead to potential cosmetic problems so careful closure is essential. It's best to consult plastic surgery if possible. • Intraoral mucosal lacerations may not need to be sutured if they are isolated and the wound edges spontaneously approximate, especially if <1 cm in length. Larger or gaping wounds should be closed with a rapidly absorbable 5-0 suture. • NOTE: Check if lacerations cross the vermilion-skin and/or the vermilion-mucosal borders. <ul style="list-style-type: none"> Does not cross vermilion border: <ul style="list-style-type: none"> Mucosa (6-0 Vicryl) Orbicularis oris muscle (4-0 or 5-0 absorbable suture) Skin (6-0 nylon) Crosses the vermilion border: <ul style="list-style-type: none"> Mucosa (6-0 Vicryl) vermilion border (6-0 nylon) skin (6-0 nylon)
Frenulum	<ul style="list-style-type: none"> • Lacerations of the maxillary labial frenulum or to the lingual frenulum of the tongue, unless large, do not require repair. But if they do, an absorbable suture such as 4-0 chromic gut or Vicryl® is appropriate. • They can be very painful and so adequate analgesia may be required.
Tongue	<ul style="list-style-type: none"> • NOTE: Bleeding and delayed swelling can compromise the airway. • Simple linear lacerations <1cm involving the central portion of the dorsal surface of the tongue and that do not gape open, heal well without repair. • All lacerations that bisect the tongue require repair. • Partial amputations can be successfully replanted with the appropriate microsurgical techniques.

**Tongue
(Continued)**

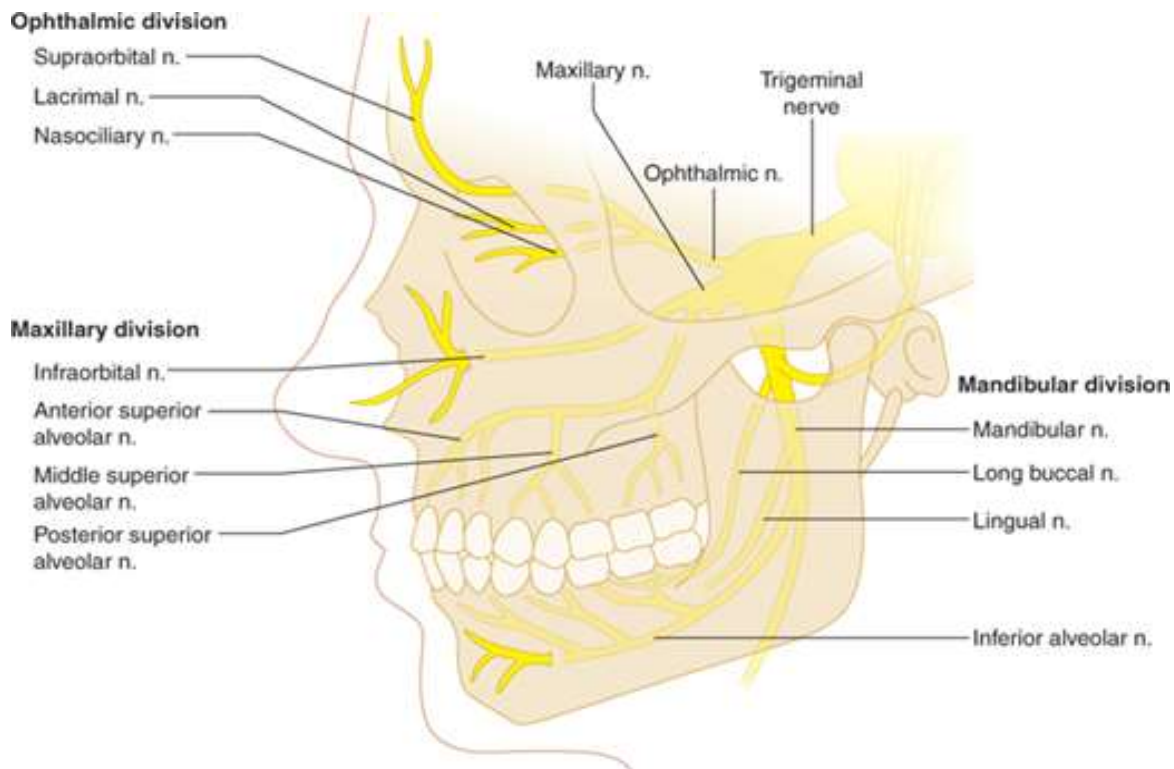
Recommendations:

- Anesthetize using local infiltration or by topically placing 4% lidocaine-soaked gauze for 5 minutes on the laceration. Bilateral lingual nerve blocks can be used for lacerations of the anterior two thirds of the tongue that cross the midline.
- Dental bite block or a Molt mouth prop can be helpful in keeping the mouth open during repair.
- Absorbable sutures such as 4-0 chromic gut or Vicryl should be used. Sutures should be placed so they include both the muscular layer and the superficial mucosal layers of the tongue.
- Wound edges should be approximated and closed very loosely to allow for swelling of the tongue, which can be significant. Sutures should be tied with at least four square knots.

DENTAL LOCAL ANESTHESIA

The trigeminal nerve is the largest nerve (motor/sensory) and it has three main branches:

- **Ophthalmic nerve**
- **Maxillary nerve** –provides sensory innervation to the maxilla and associated structures including maxillary teeth, gingiva, and oral mucous membranes
- **Mandibular nerve** has three main divisions:
 - *Buccal nerve*- provides sensory innervation to the mucosa of the cheek and buccal gingiva of the mandibular molars
 - *Lingual nerve*- innervates the anterior two thirds of the tongue, lingual gingiva, and floor of the mouth
 - *Inferior alveolar nerve*- innervates soft tissue of the lip, chin, teeth and gingiva



Source: J.E. Tintinalli, J.S. Stapczynski, O.J. Ma, D.M. Yealy, G.D. Meckler, D.M. Cline:
Tintinalli's Emergency Medicine: A Comprehensive Study Guide, 8th Edition
www.accessmedicine.com
Copyright © McGraw-Hill Education. All rights reserved.

STEPS TO AN ATRAUMATIC INJECTION

- 1) **Use a sterilized sharp needle, preferably an aspirating syringe (stainless steel disposable needles are currently used in dentistry)**
 - a. Use needles not larger than 25 gauge (preferably 25- or 27-gauge).
- 2) **Check the flow of local anesthetic solution by expelling a few drops of solution**
- 3) **Determine whether or not to warm the anesthetic cartridge or syringe**
 - a. If cartridge is stored at room temperature (approximately 72°F, 22°C), no need to warm.
- 4) **Position the patient**
 - a. Make sure patient is in physiologically sound position before and during the injection. Vasodepressor syncope (common faint) is the most commonly seen medical emergency in dentistry before, during, and sometimes immediately after local anesthetic administration.
 - b. To prevent syncope, especially in the presence of anxiety, it is recommended that the patient be placed in a supine position with the feet elevated slightly.
- 5) **Dry the tissue in and around the site of needle penetration with a 2x2 inch gauze to remove any gross debris**
- 6) **Apply topical anti-septic (optional)**
 - a. Use Betadine or Merthiolate and avoid alcohol-containing antiseptics as they can cause burning of the soft tissue
- 7) **Apply topical anesthetic and communicate with the patient**
 - a. Limit the anesthetic to the area of the injection site to avoid undesired wide areas of anesthesia.
 - b. Be especially cautious when using topical anesthetics such as lidocaine which can be rapidly absorbed into the cardiovascular system leading to increased risk of overdose.
 - c. Be sure to communicate to the patient, "I'm applying a topical anesthetic to the tissue so that the remainder of the procedure will be much more comfortable." Avoid using words such as *injection, shot, pain, or hurt*.
- 8) **Establish a firm hand rest**
- 9) **Make the tissue taut**
 - a. The tissues at the site of needle penetration should be stretched before insertion of the needle.
- 10) **Keep the syringe out of the patient's line of sight**
- 11) **Insert the needle into the mucosa. Watch and communication with the patient**
 - a. General rule: The bevel of the needle should be oriented toward bone.
 - b. Insert the needle gently into the tissue at the injection site to the depth of the bevel.
 - c. During this step, the operator should communicate to the patient "I don't expect you to feel this" and the patient should be watched for any signs of discomfort.
- 12) **Inject several drops of local anesthetic solution (optional)**
- 13) **Slowly advance the needle to the target**
- 14) **Deposit several drops of local anesthetic before touching the periosteum**
 - a. Note that the periosteum is richly innervated and contact with the needle tip produces pain.
- 15) **Aspirate**
 - a. Aspiration dramatically minimalizes the possibility of intravascular injection.
- 16) **Slowly deposit the local anesthetic solution and communicate with the patient**
 - a. Slow injection is defined as the deposition of 1ml in not less than 60 seconds.
 - b. Slow injection prevents the solution from tearing the tissue into which it is deposited.
- 17) **Slowly withdraw the syringe**
- 18) **Observe the patient**
 - a. Most drug reactions, especially those to intraorally administered local anesthetics develop either during or within 5-10 minutes of completion of the injection.
- 19) **Record the injection on the patient's chart**
 - a. Note the local anesthetic drug used, vasoconstrictor used (if any), dose (in milligrams) of the solution(s) used, the needle(s) used, the injection(s) given, and the patient's reaction
 - b. Example: *R-IANB, 25-long, 2% lido + 1:100,000 epi, 36mg. Tolerated procedure well.*

MAXILLARY INJECTIONS

Supraperiosteal Infiltration

Indications:

- 1) Pulpal anesthesia of the maxillary teeth when treatment is limited to one or two teeth
- 2) Soft-tissue anesthesia when indicated for surgical procedures in a circumscribed area

Contraindications:

- 1) Infection or acute inflammation in the area of the injection.
- 2) Dense bone covering the apices of teeth. This can be determined only by trial and error. It is most likely found over the permanent first molar in children as its apex lies beneath the zygomatic bone, which is relatively dense. The apex of an adults central incisor may also be located under denser bone.

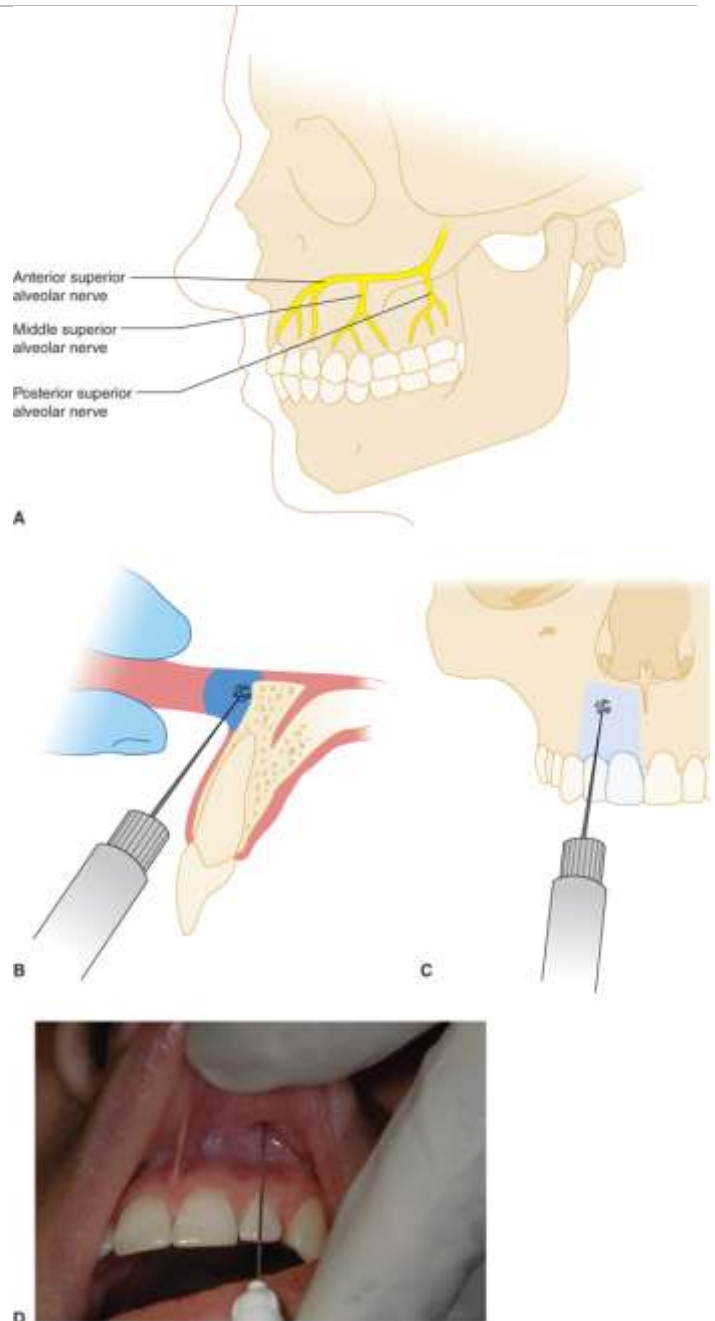
Diagram

A. The maxillary nerve and innervation of the maxillary teeth by the posterior superior alveolar nerve, the middle superior alveolar nerve, and the anterior superior alveolar nerve.

B. With the lip or cheek pulled taught, the needle is inserted at the height of the buccal fold. Note: the 2-3 concentric circles of dotted lines around the needle tip indicate the area where the anesthesia is deposited.

C. The needle is directed along the long axis of the tooth, and anesthesia is deposited just superior to the area of the root apex.

D. Clinical photograph depicting a supraperiosteal infiltration of the maxillary lateral incisor.



Source: J.E. Tintinalli, J.S. Stapczynski, O.J. Ma, D.M. Yealy, G.D. Meckler, D.M. Cline: Tintinalli's Emergency Medicine: A Comprehensive Study Guide, 8th Edition www.accessmedicine.com Copyright © McGraw-Hill Education. All rights reserved.

Palatal Infiltration

Potentially the most traumatic intraoral injection.

Indications:

Anesthesia of the hard palate is necessary for dental procedures involving manipulation of palatal soft or hard tissues.

Contraindications:

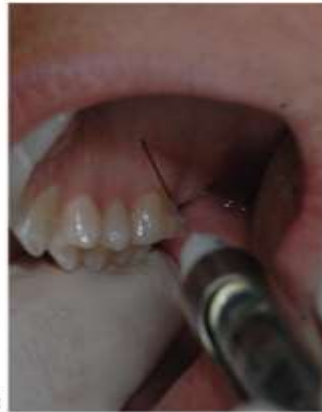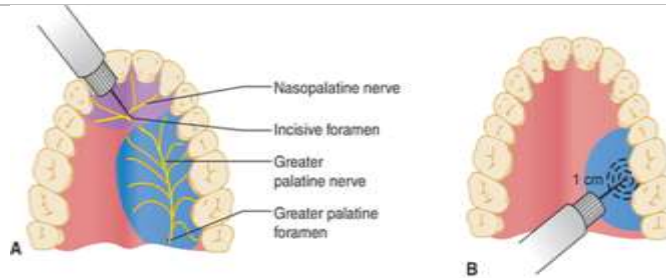
Infection or acute inflammation in the area of the injection.

Diagram

A. Illustrates the innervation to the soft tissue of the hard palate. The bilateral greater palatine nerves innervate the posterior portion of the palate after they each exit their respective greater palatine foramina (see blue shaded area). The anterior portion of the hard palate is innervated by the nasopalatine nerve after exiting the incisive foramen. Injection over the incisive foramen (shown) will result in anesthesia to the purple shaded area.

B. A fine-gauge needle is inserted into the palatal tissue about 1 cm below the gingival margin, and a small amount of anesthesia is injected. Blanching of the palatal tissue surrounding the injection site is noted. This will provide anesthesia to the tissue adjacent to area injected as shown. A similar injection over the area of the greater palatine foramen or the incisive foramen will provide anesthesia to their respective zones.

C. Clinical photograph depicting a palatal infiltration.



Source: J.E. Tintinalli, J.S. Stapczynski, O.J. Ma, D.M. Yealy, G.D. Meckler, D.M. Cline: Tintinalli's Emergency Medicine: A Comprehensive Study Guide, 8th Edition www.accessmedicine.com Copyright © McGraw-Hill Education. All rights reserved.

MANDIBULAR INJECTIONS

Inferior Alveolar Nerve Block (direct technique)

The most frequently used and one of the most important injection techniques in dentistry.

Indications:

- 1) Procedures on multiple mandibular teeth in one quadrant
- 2) When buccal soft-tissue anesthesia is necessary (anterior to first molar)
- 3) When lingual soft tissue anesthesia is necessary

Contraindications:

- 1) Infection or acute inflammation in the area of injection
- 2) Patients who may bite either the lip or tongue (E.g. a child or those with a disability)

Diagram

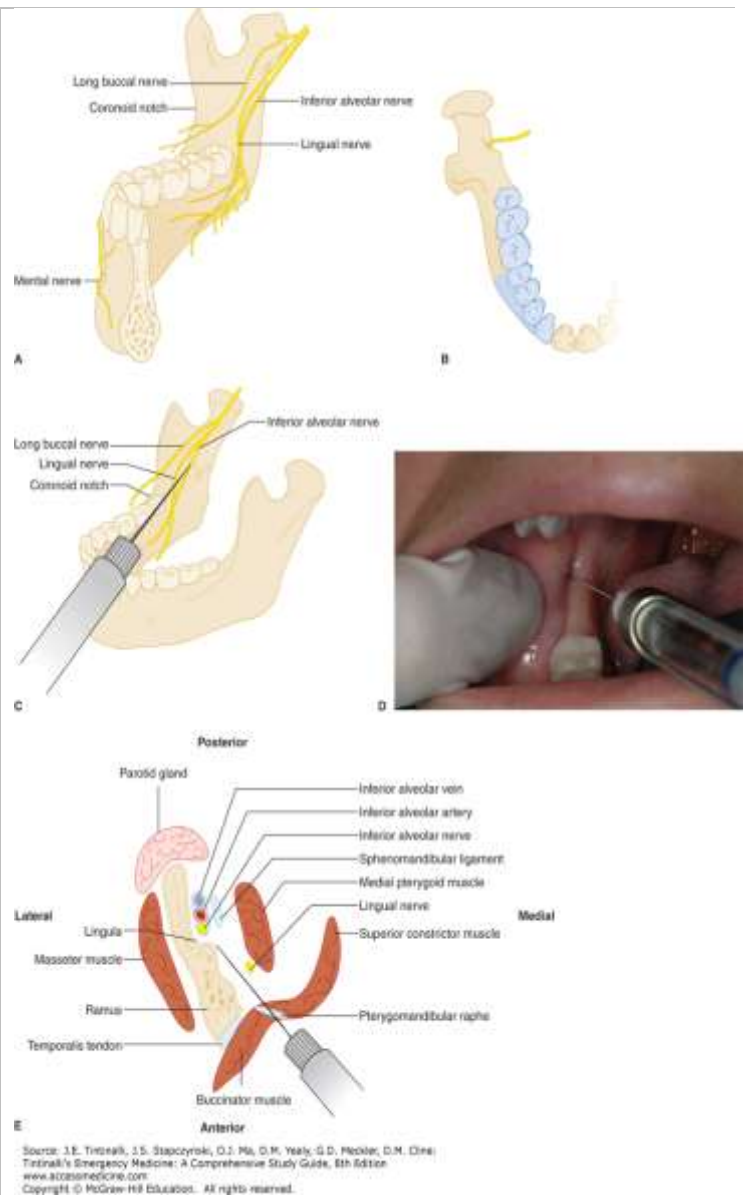
A. Illustrates the anatomy of the inferior alveolar nerve as it enters the mandibular foramen in the pterygomandibular space. The lingual nerve is located superficial and medial to the inferior alveolar nerve. Note the coronoid notch.

B. Shows the area of anesthesia obtained with a successful inferior alveolar nerve block. The lingual nerve is usually also blocked, which provides anesthesia to the floor of the mouth, lingual gingiva, and the anterior two thirds of the tongue.

C. The syringe should be directed from the contralateral premolar area about 1 to 1.5 cm above the mandibular plane. It is inserted about 20 to 25 mm until bone is touched in an area above the lingula. The needle should then be withdrawn 1 to 2 mm and aspirated for blood before injecting anesthesia. The sphenomandibular ligament attaches to the lingula and will prevent the anesthesia from reaching the inferior alveolar nerve if the injection is too low.

D. Clinical photograph of the direct technique. Note the point of injection in the pterygomandibular depression just lateral to the pterygomandibular raphe.

E. A diagram of a transverse section of the pterygomandibular fossa at the level of an inferior alveolar nerve injection. Notice the needle passes through the buccinator muscle to an area just superior to the lingula.



Lingual Nerve Block and the Long Buccal Nerve Block

Indications:

When buccal soft tissue anesthesia is necessary for dental procedures in the mandibular molar region.

Contraindications:

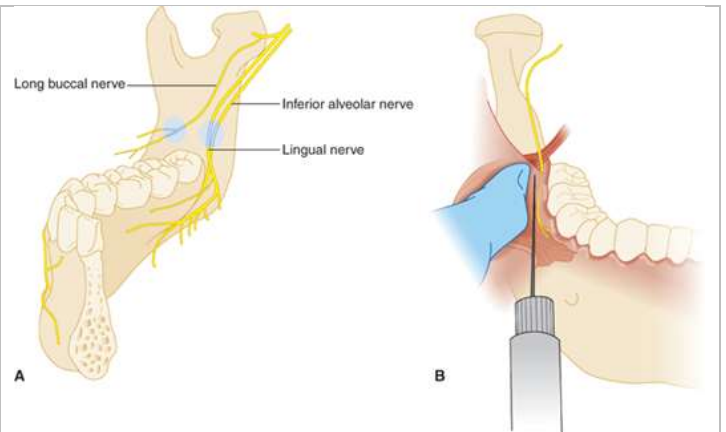
When there is infection or acute inflammation in the area of injection.

Diagram

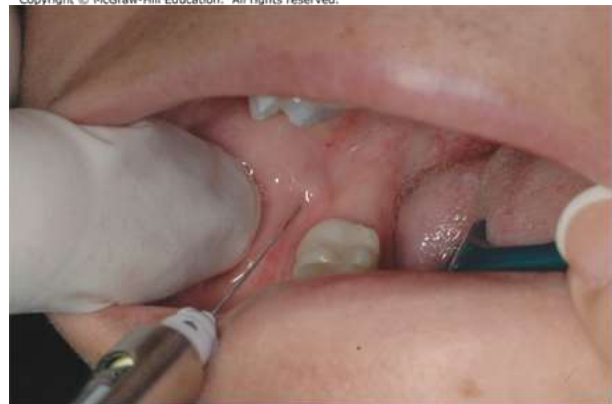A. The shaded areas represent the area in which anesthesia should be deposited for their respective blocks. The lingual nerve runs superficial and medial to the inferior alveolar nerve and can be easily anesthetized as part of the inferior alveolar nerve block. The lingual nerve block can be performed by depositing anesthesia about half the depth of the inferior alveolar nerve block.

B. A diagrammatic representation of the long buccal nerve block. The long buccal nerve requires a separate injection of a small quantity of anesthetic just lateral to the molars in the buccal mucosa.

C. Clinical photograph of the long buccal nerve block.



Source: J.E. Tintinalli, J.S. Stapczynski, O.J. Ma, D.M. Yealy, G.D. Meckler, D.M. Cline: Tintinalli's Emergency Medicine: A Comprehensive Study Guide, 8th Edition www.accessmedicine.com Copyright © McGraw-Hill Education. All rights reserved.



Source: J.E. Tintinalli, J.S. Stapczynski, O.J. Ma, D.M. Yealy, G.D. Meckler, D.M. Cline: Tintinalli's Emergency Medicine: A Comprehensive Study Guide, 8th Edition www.accessmedicine.com Copyright © McGraw-Hill Education. All rights reserved.

Prenatal Oral Health

Pregnancy is characterized by complex physiological changes that may affect oral health. Often health professionals do not provide oral care to pregnant women and some women with obvious signs of oral disease do not seek or receive care. It's important to know that preventative, diagnostic, and restorative dental treatment is safe throughout pregnancy and is effective in improving and maintaining oral health.

Periodontitis may be associated with several poor pregnancy outcomes, although the mechanism by which this occurs, remains unclear and controversy still exists. In a recent systematic review of mainly cross-sectional, case-control, and cohort studies conducted between 1996 and 2006 in 12 countries and three states, investigators identified 24 studies demonstrating a positive relationship between periodontitis and preterm birth, low birth weight, or both. These studies involved approximately 15,000 mothers. Three of the studies were randomized controlled trials (RCTs). However, 14 studies reported no relationship between periodontitis and poor pregnancy outcomes. A recent, large, U.S.-based RCT found no association between periodontitis and preterm birth and low birth weight.

<p>Gingivitis</p>	<ul style="list-style-type: none"> • Prevalence: 30-75% in pregnancy • Mild gum swelling, tenderness, erythema • Bleeds easily, reversible, hormonal cause • Treatment: brush bid, floss, regular dental visits
<p>Periodontitis</p>	<ul style="list-style-type: none"> • Prevalence: 30% of women of childbearing age • Inflammation of gum, ligaments, bone • Plaque+ bacteria + inflammation • May be associated with preterm labor/low birth weight • Treatment: Proper hygiene, deep root scaling
<p>Caries</p>	<ul style="list-style-type: none"> • Plaque, white spots, brown spots lead to cavities • Women can pass caries risks to infant postpartum • Treatment: Proper hygiene and regular dental visits • Prescription xylitol gum postpartum
<p>Pregnancy granuloma</p>	<ul style="list-style-type: none"> • Prevalence: 5 % of pregnant women • Erythematous, non-painful, smooth nodule • Usually on gingival tissue, bleeds easily • Treatment: Observation. May recur if excised
<p>Dental Erosion</p>	<ul style="list-style-type: none"> • Caused by hyperemesis and GERD • Treatment: Rinse after emesis/meals with 1 teaspoon baking soda in 1 cup water

Summary of Prenatal Oral Health Recommendations

- Encourage patient to practice good oral hygiene:
 - Brush teeth with fluoridated toothpaste twice a day.
 - Rinse every night with a fluoridated, alcohol-free mouthrinse.
- If the last dental visit took place more than 6 months ago, or if there are any oral health problems or concerns, patient should schedule a dental appointment as soon as possible.
- Oral health care, including use of X-rays, pain medication, and local anesthesia, is safe throughout pregnancy.
- Normal dental procedures such as prophylaxis (cleaning), cavity restoration (filling), and periodontal restoration may be performed under local anesthesia.
- Antibiotics may be given for dental abscesses.
- Women should get oral health treatment as recommended by an oral health professional, before delivery. Dental treatments can occur during all 3 trimesters.
 - First Trimester:** Care is safe, but elective treatment can be delayed if the patient or provider prefer to wait until the 2nd trimester. Urgent care should not be delayed.
 - Second Trimester:** Optimal time for treatment. The fetus is not large and organogenesis is complete.
 - Third Trimester:** Women can be uncomfortable late in term. Position women angled on left side.
- Postpartem patients should maintain good oral practices. They should also continue with getting dental health care and eating healthy foods.

<p style="text-align: center;">Dental X-Rays</p> <ul style="list-style-type: none"> • Only as needed • Radiation exposure extremely low • Use lead apron of abdomen/thyroid • Avoid retakes 	<p style="text-align: center;">Analgesics</p> <ul style="list-style-type: none"> • Acetaminophen (FDA Category B) • Ibuprofen (B/D*) • Oxycodone (B/D*) • Hydrocodone and Codeine *avoid in 3rd trimester
<p style="text-align: center;">Common Dental Medications Antibiotics</p> <ul style="list-style-type: none"> • Penicillin (FDA Category B) • Amoxicillin (B) • Cephalexin (B) • Erythromycin base (B) • Clindamycin (B) 	<p style="text-align: center;">Anesthetics</p> <ul style="list-style-type: none"> • Lidocaine (FDA Category B) • Procaine (C) • Nitrous Oxide (no rating; literature indicates safe)
<p style="text-align: center;">Antimicrobials (Safe to use)</p> <ul style="list-style-type: none"> • Chlorhexidine mouth rinse • Xylitol 	

Infant and Child Oral Health

Early childhood caries (ECC), also known as baby bottle tooth decay, is defined as a condition of demineralization of the enamel with different degrees of cavitation in the primary dentition of children younger than 6 years. According to the CDC, dental caries remain the most common chronic disease of children aged 6 to 11 years. Oral health for this population should focus on the development of the deciduous teeth and permanent teeth, caries, diet, fluoride varnish, and oral hygiene of the entire family to reduce the exposure to cariogenic bacteria.

<p>Oropharyngeal Candidiasis</p>	<ul style="list-style-type: none"> • Bottle feeding increases rates of thrush • Peak prevalence at 4 weeks of age • Treat with nystatin or one of the imidazoles
<p>Tooth Eruption (Teething)</p>	<ul style="list-style-type: none"> • Loose stools are associated with teething • May be accompanied by irritability, drooling, decreased intake, and elevated temperature • Use teething rings or cold wash cloths to suck/chew • Acetaminophen or Ibuprofen as needed • NOTE: Teething gels can be dangerous at high doses
<p>Caries</p>	<ul style="list-style-type: none"> • Cariogenic bacteria can be passed easily from mother (or other persons) to child by pre-chewing food, cleaning pacifier with mouth, or baby sticking fingers in someone else's mouth and putting them back in their own • Encourage breastfeeding by the mother • If bottle feeding, no bottle propping and no bottle to bed

Summary of Infant and Child Oral Health Recommendations

- **0 -2 months**
 - Diet: Encourage exclusive breastfeeding for at least the first 4-6 months.
 - If bottle feeding, hold infant during feeds. No bottle propping and no bottle to bed.
- **4 months**
 - Diet: Encourage exclusive breastfeeding for at least the first 4-6 months.
 - If bottle feeding, hold infant during feeds. No bottle propping and no bottle to bed.
 - Oral hygiene: Wipe gums clean with clean damp cloth.
- **6-9 months**
 - Diet: Introduce healthy age appropriate foods.
 - Introduce the cup and wean off the bottle by age 1. No bottles for sleeping.
 - Oral hygiene: Start brushing as teeth erupt. Use only a smear of fluoride toothpaste.
 - Dental screening: During 6 mos check-up, conduct an oral health risk assessment and refer to a dentist for urgent oral healthcare.
 - Fluoride: Prescribe systemic fluoride if needed (best if done by an oral healthcare provider)

► 12+ months

- The American Dental Association and the American Academy of Pediatrics both recommend that infants be seen by a dentist by age 1, or within 6 months of the eruption of the first tooth.
- Ensure regular dental visits from age one year
- Oral hygiene: Brush with fluoride tooth paste at least two times daily
 - <3yrs = smear/size of grain of rice
 - 3-6yrs old = pea-size amount
- Fluoride: Prescribe systemic fluoride for high risk until age 16. Provide fluoride varnish for moderate and high risk patients every 6 months (best if done by an oral healthcare provider)
- Diet:
 - Wean off the bottle (no bottles for sleeping)
 - Only water or milk in sippy cups
 - Limited number of snacks- no grazing
 - Encourage healthy snacks: Fresh fruit/vegetables, plain cheerios, cheese, crackers
 - No soda
 - Less or no juice
 - Only plain milk or water between meals (best if tap water)
 - Less or no junk food and candy (encourage low sugar or sugar free)
- Exam: Assess caries, defects, oral hygiene and refer to a dentist for urgent oral healthcare.

Adolescent/Young Adult Oral Health

Adolescence is a time of great developmental change. That includes a worsening of nutritional and self-care habits, and an increase in high-risk behaviors, including increased risk of trauma and exposure to negative substances such as alcohol, tobacco, or other illicit drugs, increased consumption of dietary sugars in their nutritional patterns, and possibly a decline in the consistency and effectiveness of oral hygiene routines. Moreover, adolescents are less likely to seek routine preventive care. According to the CDC, dental caries remain the most common chronic disease of adolescents aged 12 to 19 years.

Risk Factors for Poor Adolescent Oral Health

- High caries risk and rate
- High risk for trauma (lack of mouth guard used for sports)
- High risk for periodontal disease
- Developing poor nutritional habits, and eating disorders (bulimia)
- Need for orthodontic or restorative dental treatment
- Increasing esthetic awareness and demands
- Potential use of alcohol, tobacco, and other illicit drugs
- Pregnancy
- Unique social and psychological needs

<p>Caries</p>	<ul style="list-style-type: none"> • Prevalence is highest during adolescence • Plaque, white spots, brown spots lead to cavities • Treatment: Proper hygiene and regular dental visits
<p>Periodontal Disease</p>	<ul style="list-style-type: none"> • Adolescents have a higher prevalence of gingivitis than prepubertal children or adults due to effects of rise of sex hormones • Treatment: Proper hygiene and regular dental visits
<p>Wisdom Teeth (Third Molars)</p>	<ul style="list-style-type: none"> • Can present acute/chronic problems • Impaction or malposition can lead to pericoronitis, caries, cysts, or periodontal problems which can merit removal • Refer to a dentist if there are any problems or concerns • Evaluation of third molars can be done during routine dental visits
<p>Malocclusion</p>	<ul style="list-style-type: none"> • This can include single or multiple tooth malpositions, tooth/jaw size discrepancies, and craniofacial disfigurements • Congenitally missing teeth present complex problems for the adolescent and often require combined orthodontic and restorative care.
<p>Intraoral and Perioral Piercings</p>	<ul style="list-style-type: none"> • Infection is a common complication (10-20% of cases), especially with tongue piercings • Other complications include bleeding, tooth fractures, potential nerve damage, transmission of disease due to unsterile materials (hepatitis B and C, HIV), ulceration, gingivitis, gingival recession, metal hypersensitivity, and accidental choking from loose jewelry • Piercings produce radiopaque areas and must not be worn during X-ray examinations • Patients should be educated regarding the dangers that may follow piercing of the oral cavity • Individuals with oral/perioral piercing should visit their dentist regularly for a thorough oral examination
<p>Eating Disorders</p>	<ul style="list-style-type: none"> • Clinicians should suspect purging behavior if a patient is suffering from rampant decay or enamel erosion • Patients require a comprehensive approach including behavioral interventions as well as a dental referral • Dental recommendations may include rinses after vomiting to rid the mouth of acid, the use of high-concentration fluoride toothpastes, and more frequent visits to the dentist
<p>Alcohol, tobacco, illicit drug use</p>	<ul style="list-style-type: none"> • Significant oral, dental, and systemic health consequences and death are associated with all current forms of tobacco use, alcohol use, and illicit drug abuse • Practitioner should provide or refer the patient to appropriate educational and counseling services

Trauma

- Common injuries to permanent teeth occur secondary to falls, followed by traffic accidents, violence, and sports
- Dental and facial injuries due to sports can be reduced significantly by introducing mandatory protective equipment such as face guards and mouth guards
- Based patient history of sports and activities, recommend the appropriate protective equipment

Summary of Adolescent/Young Adult Oral Health Recommendations

- Refer all adolescents and young adults for dental check-ups every 6 months.
- Adolescents should brush twice daily with a fluoridated toothpaste and floss daily.
- Fluoride varnish should be applied in the medical setting twice per year for both children and adolescents.
- Fluoride supplements should be offered to adolescents (up to age 16 years) who do not have access to community fluoridated water. (Best if done by an oral healthcare provider)
- Screen for: Alcohol and drug use, oral piercings, tobacco use, sexual activity, eating disorders, and sports activities.
 - Recommend the use of mouth guards for sports
 - Educate on the risks of oral piercings and substance use
- Diet: Adolescents should be encouraged to drink water rather than sodas, sports drinks, energy drinks, or fruit juices. Nutritional counseling is beneficial to help teens make better choices. It may also be useful to educate teen athletes that simple sugars and junk food (i.e., donuts, cookies) are not enough to maintain energy for playing sports and can lead to weight gain as well.

Geriatric Oral Health

Elderly Americans are at significant risk for dental disease. They have had the longest cumulative opportunity to develop caries, periodontitis, or lose teeth. The elderly are more likely to have chronic disease, take medications, and be physically unable to care for their dentition. Salivary gland function naturally decreases with aging and results in drying of the oral cavity or the development of disease processes. In addition, dental insurance is typically not a retirement benefit and many older adults pay a significant portion out of pocket, limiting their choices and ability to receive dental care.

Periodontal disease

- About 70% of older adults have periodontal disease
- Almost a third are fully edentulous (missing all natural teeth)
- Having fewer than 20 teeth compromises masticatory function and nutritional status

<p>Caries</p>	<ul style="list-style-type: none"> • About 23% of older adults have untreated dental caries • Root caries is a major cause of tooth loss in older adults • Those with active or recurrent caries benefit from fluoride varnish applications and Rx high-fluoride toothpaste
<p>Artificial teeth</p>	<ul style="list-style-type: none"> • Properly made, well-fitting complete dentures restore only 10% to 15% of masticatory function • Poorly fitting dentures can disrupt the normal flora and result in oral candidiasis infection
<p>Oral candidiasis</p>	<ul style="list-style-type: none"> • Up to 65% of denture-wearers experience oral candidiasis • Results in burning sensation and irritation to the roof of the mouth, denture stomatitis or papillary hyperplasia • Treat with topical anti-fungal agents to both the oral tissues and denture (several weeks) • To prevent infection, dentures should be cleaned regularly and not be worn overnight
<p>Xerostomia</p>	<ul style="list-style-type: none"> • Affects approximately 25% of older adults • Increases the risk of caries and periodontal disease • Primary disease may include Sjogrens, rheumatoid arthritis, or salivary tumor • Can be the effect of medications – anticholinergics, antidepressants, antipsychotics, diuretics, antihypertensives, sedatives, antihistamines, and inhalers
<p>Oral cancer</p>	<ul style="list-style-type: none"> • Oral cancer is the eighth most common cancer in men and is seven times more likely to occur in older adults • Squamous cell carcinoma comprises 96% of oral and pharyngeal malignancies • Primary risk factors: age, tobacco, alcohol • Both leukoplakia (white patch) and erythroplakia (red patch) persisting for more than 2 weeks, particularly those that progress to raised plaques of mixed appearance and ulceration, should be referred for biopsy
<p>Aspiration Pneumonia</p>	<ul style="list-style-type: none"> • Patients with poor oral health have an increased risk for aspiration pneumonia (AP) • Improved oral hygiene can decrease the bacterial load and results in a 40% reduction in (AP) • Other practices that help reduce risk include postural adjustment, extra time for feeding assistance, smaller quantities per bite, and chewing longer before swallowing
<p>Osteonecrosis of the Jaw (ONJ)</p>	<ul style="list-style-type: none"> • Osteonecrosis of the alveolar bone can result from bone antiresorptive agents: IV/oral bisphosphonates, denosumab • Cancer patients receiving bone antiresorptive agents minimize risk of developing (ONJ) through dental evaluation/treatment

prior to initiating therapy

- During medication therapy, encourage daily oral care, no smoking, limited alcohol, no invasive dental procedures, and dental hygiene maintenance appointments every three months

Summary of Geriatric Oral Health Recommendations

- Prevention of Caries & Periodontal Disease
 - Eliminate sweet snacks/drinks between meals
 - Brush twice daily with fluoridated toothpaste
 - Floss daily
 - Regular dental visits every 6 months
 - Regular oral exam at annual medical exam
 - If in long-term care facilities: Label all dental supplies, separate individual patient's dental supplies, and don't store dental supplies near toilets.
- Oral Lesions
 - Any red or white patch or ulceration persisting longer than 2 weeks, should be referred for biopsy/immediate dental evaluation.
 - Encourage proper denture care (See section on denture care)
- Management of Xerostomia
 - Discontinue meds or move to morning dosing
 - Avoid sugar containing foods and drinks
 - Xylitol mints, sugar-free gum
 - Rx brush on topical fluoride gel
 - Rx saliva substitutes
 - Regular dental visits – higher risk for caries

Additional pharmacologic considerations

- Gastric reflux caused by progesterone, nitrates, beta blockers, and calcium channel blockers erodes the surfaces of teeth.
- Phenytoin, methotrexate and calcium channel blockers cause gingival hyperplasia.
- Periodontal disease is exacerbated in type 2 diabetics taking nifedipine.
- Patients taking steroids are more susceptible to candidiasis infections.
- Drug preparations and nutritional supplements containing sugar promote dental caries.
- Chemotherapy and radiation therapy cause oral mucositis and stomatitis.
- Noninvasive dental procedures such as cleanings, fillings, crown preparation, and simple extractions may be performed without interrupting anticoagulation or antiplatelet therapy.

Common Foods that Damage Teeth



Avoid chewing on **ice**. Hard substances can leave teeth vulnerable to a dental emergency and damage enamel.



Frequent exposures to **acidic foods** can erode enamel, making teeth more susceptible to decay over time. Its best to limit **citrus** exposure to teeth. Drink plenty of plain water (without any infused citrus.)



Sticky foods, including dried fruits, can damage teeth since they tend to stay on the teeth longer than other types of food. After eating foods like this, make sure to rinse with water after and to brush and floss carefully.



Avoid **sugary beverages** such as sodas and sports drinks. Most carbonated soft drinks, including diet soda, are also acidic and therefore should be avoided or limited. Caffeinated beverages can also dry out the mouth which increases risk of tooth decay and other oral infections.



Coffee and **tea** can be healthy beverage choices, but this changes when there are add-ins like sugar. Caffeinated coffee and tea can also dry out the mouth and stain teeth. If consuming these beverages, drink plenty of water and limit the add-ins.



Crunchy snack foods like potato chips are filled with starch, which tends to get trapped in teeth. If indulging in snacks like these, take extra care floss after to remove all the food particles that can lead to plaque build-up.

THE ORAL EXAM

INSPECTION (Before the exam, remove all dentures and appliances)

The lips

- Observe their color and moisture, and note any lumps, ulcers, cracking, or scaliness.

The Oral Mucosa

- Use a good light and the help of a tongue blade.
- Inspect the oral mucosa for color, ulcers, white patches, and nodules.

The Gums and Teeth

- Note the color of the gums (normally pink.) Patchy brownness may be present in certain ethnic groups.
- Inspect the gum margins and interdental papillae for swelling or ulceration.
- Inspect the teeth. Note if any of them are missing, discolored, misshapen, or abnormally positioned. You can check for looseness with your gloved thumb and index finger. Gently percuss the suspected teeth with a firm clean object to determine if a specific tooth is the source of pain. After trauma, test for mobility and tenderness with gentle pressure and percussion. Assure that all the teeth occlude as normal for the patient.
- Looks for signs of caries: White spots, brown spots, pits
- Looks for signs of poor oral hygiene: Presence of plaque and or erythematous/receded gums may indicate periodontal disease

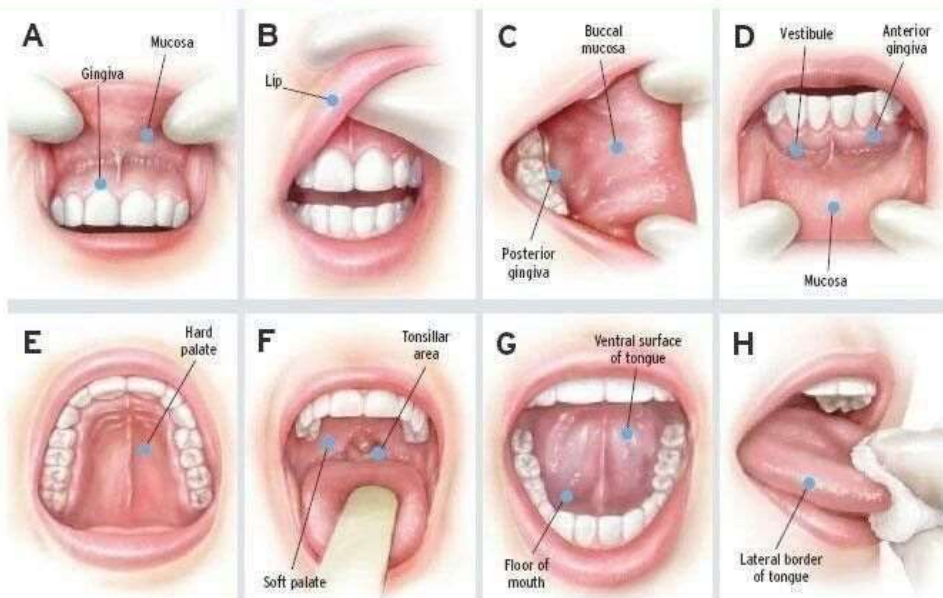
The Roof of the Mouth

- Inspect the color and architecture of the hard palate.

The Tongue and the Floor of the Mouth

- Ask the patient to put out his or her tongue. Inspect it for symmetry-a test of CNXII.
- Note the color and the texture of the dorsum of the tongue.
- Inspect the sides and undersurface of the tongue and the floor of the mouth. These are the areas where cancer most develops.
 - Note any white or reddened areas
 - Nodules
 - Ulcerations
- Ask the patient to protrude his tongue. Grasp the tip of the tongue with a gauze and pull it to the side. Inspect the side of the tongue and then palpate it, feeling for any induration (hardness). Repeat on the other side.
- Inspect the soft palate, anterior and posterior pillars, uvula, tonsils, and pharynx. Note their color and symmetry. Look for exudate, swelling, ulceration, or tonsillar enlargement. If possible palpate any suspicious area for induration or tenderness. Tonsils have crypts, or deep infoldings of the squamous epithelium. Whitish spots of normal exfoliating epithelium may sometimes be seen in these crypts.

The 8-Step Oral Cancer Screening



REFER TO A DENTIST

- All adults and children for 6 month check ups
- All adults and children with signs of caries, periodontal disease, or suspicious oral lesions

References

- Andersson, L., Andreasen, J. O., Day, P., Heithersay, G., Trope, M., DiAngelis, A. J., Kenny, D. J., Sigurdsson, A., Bourguignon, C., Flores, M. T., Hicks, M. L., Lenzi, A. R., Malmgren, B., Moule, A. J. and Tsukiboshi, M. (2012), International Association of Dental Traumatology guidelines for the management of traumatic dental injuries: 2. Avulsion of permanent teeth. *Dental Traumatology*, 28: 88–96. doi:10.1111/j.1600-9657.2012.01125.x
- Beaudreau, Ronald W.. "Oral and Dental Emergencies." *Tintinalli's Emergency Medicine: A Comprehensive Study Guide*, 8e. Eds. Judith E. Tintinalli, et al. New York, NY: McGraw-Hill, 2016, <http://accessmedicine.mhmedical.com/content.aspx?bookid=1658&Sectionid=109444613>.
- Butt, Fidelia Yuan-Shin.. "Chapter 18. Benign Diseases of the Salivary Glands." *CURRENT Diagnosis & Treatment in Otolaryngology—Head & Neck Surgery*, 3e. Ed. Anil K. Lalwani. New York, NY: McGraw-Hill, 2012, <http://accessmedicine.mhmedical.com/content.aspx?bookid=386&Sectionid=39944053>.
- DiAngelis, A. J., Andreasen, J. O., Ebeleseder, K. A., Kenny, D. J., Trope, M., Sigurdsson, A., Andersson, L., Bourguignon, C., Flores, M. T., Hicks, M. L., Lenzi, A. R., Malmgren, B., Moule, A. J., Pohl, Y. and Tsukiboshi, M. (2012), International Association of Dental Traumatology guidelines for the management of traumatic dental injuries: 1. Fractures and luxations of permanent teeth. *Dental Traumatology*, 28: 2–12. doi:10.1111/j.1600-9657.2011.01103.x
- Dick, Gregory, et al.. "Oral Diseases & Disorders." *Current Diagnosis & Treatment: Geriatrics*, Second Edition Eds. Brie A. Williams, et al. New York, NY: McGraw-Hill, 2014, <http://accessmedicine.mhmedical.com/content.aspx?bookid=953§ionid=53375675>
- Durso, Samuel C.. "Oral Manifestations of Disease." *Harrison's Principles of Internal Medicine*, 19e. Eds. Dennis Kasper, et al. New York, NY: McGraw-Hill, 2015, <http://accessmedicine.mhmedical.com/content.aspx?bookid=1130&Sectionid=79725733>.
- Iserson, Kenneth V.. "Dental: Fillings, Extractions, and Trauma." *Improvised Medicine: Providing Care in Extreme Environments*, 2e. Ed. Kenneth V. Iserson. New York, NY: McGraw-Hill, 2016, <http://accessmedicine.mhmedical.com/content.aspx?bookid=1728&Sectionid=115697338>.
- Iserson, Kenneth V.. "Dental: Diagnosis, Equipment, Blocks, and Treatment." *Improvised Medicine: Providing Care in Extreme Environments*, 2e. Ed. Kenneth V. Iserson. New York, NY: McGraw-Hill, 2016, <http://accessmedicine.mhmedical.com/content.aspx?bookid=1728&Sectionid=115697177>.
- LeBlond R.F., Brown D.D., Suneja M., Szot J.F.. "The Preoperative Evaluation." *DeGowin's Diagnostic Examination*, 10e Eds. Richard F. LeBlond, et al. New York, NY: McGraw-Hill 2014, <http://accessmedicine.mhmedical.com/content.aspx?bookid=1192§ionid=68671542>.
- Levin, L., Zadik, Y., Becker T. (2005), Oral and dental complications of intra-oral piercing. *Dent Traumatol*, 21: 341–343.
- Malamed, Stanley F. *Handbook of Local Anesthesia*. St. Louis, Mo: Elsevier/Mosby, 2004. Print.
- Malmgren, B., Andreasen, J. O., Flores, M. T., Robertson, A., DiAngelis, A. J., Andersson, L., Cavalleri, G., Cohenca, N., Day, P., Hicks, M. L., Malmgren, O., Moule, A. J., Onetto, J. and Tsukiboshi, M. (2012), International

Association of Dental Traumatology guidelines for the management of traumatic dental injuries: 3. Injuries in the primary dentition. *Dent Traumatol*, 28: 174–182. doi:10.1111/j.1600-9657.2012.01146.x

Morton, David A., et al.. "Chapter 24. Oral Cavity." *The Big Picture: Gross Anatomy*. Eds. David A. Morton, et al. New York, NY: McGraw-Hill, 2011, <http://accessmedicine.mhmedical.com/content.aspx?bookid=381&Sectionid=40140032>.

Neville, Brad W. *Oral & Maxillofacial Pathology*. Philadelphia [etc.]: W.B. Saunders, 2002. Print.

Oral Health Care During Pregnancy: A National Consensus Statement. 2012. Washington D.C. National Maternal and Child Oral Health Resource Center. www.mchoralhealth.org/PDFs/OralHealthPregnanc

Ramos-Gomez, Francisco, et al.. "Dental Care: The Forgotten Need." *Medical Management of Vulnerable and Underserved Patients: Principles, Practice, and Populations*, 2e. Eds. Talmadge E. King, and Margaret B. Wheeler. New York, NY: McGraw-Hill, 2016, <http://accessmedicine.mhmedical.com/content.aspx?bookid=1768&Sectionid=119152415>.

Ryan, Kenneth J., and C. George Ray.. "Dental and Periodontal Infections." *Sherris Medical Microbiology*, 6e. Eds. Kenneth J. Ryan, and C. George Ray. New York, NY: McGraw-Hill, 2014, <http://accessmedicine.mhmedical.com/content.aspx?bookid=1020&Sectionid=56968783>.

Woo, Sook-Bin.. "Chapter 76. Biology and Pathology of the Oral Cavity." *Fitzpatrick's Dermatology in General Medicine*, 8e. Eds. Lowell A. Goldsmith, et al. New York, NY: McGraw-Hill, 2012, <http://accessmedicine.mhmedical.com/content.aspx?bookid=392&Sectionid=41138779>.

American Dental Association
<http://www.ada.org/>

American Heart Association
<http://www.heart.org/HEARTORG>

Smiles for Life
<http://smilesforlifeoralhealth.org/>

Annette Mendoza (UCSD ISP)

Howard Taras, MD
Donna Kritz-Silverstein, PhD
Andrew Chapokas, DMD, MSD