

UC Irvine

UC Irvine Previously Published Works

Title

Laparoscopic Roux-en-Y gastric bypass for morbid obesity.

Permalink

<https://escholarship.org/uc/item/5hk493h7>

Journal

JSLJ Journal of the Society of Laparoscopic & Robotic Surgeons, 3(3)

ISSN

1086-8089

Authors

Nguyen, NT
Ho, HS
Mayer, KL
[et al.](#)

Publication Date

1999

Copyright Information

This work is made available under the terms of a Creative Commons Attribution License, available at <https://creativecommons.org/licenses/by/4.0/>

Peer reviewed

Laparoscopic Roux-en-Y Gastric Bypass for Morbid Obesity

Ninh T. Nguyen, MD, Hung S. Ho, MD, Kathrin L. Mayer, MD, Levi Palmer, BS, Bruce M. Wolfe, MD

ABSTRACT

Surgery is currently the only effective treatment for morbid obesity. The two most commonly accepted operations are the Roux-en-Y gastric bypass and vertical banded gastroplasty. Although multiple authors have reported on a laparoscopic approach to gastric banding, the Roux-en-Y gastric bypass is a complex operation to be replicated using laparoscopic techniques. In this article, we describe our technique of the Roux-en-Y gastric bypass using a laparoscopic approach in four cases.

Key Words: Laparoscopy, Obesity, Gastric bypass, Weight reduction.

INTRODUCTION

Morbid obesity is defined as being 100 pounds (45 kg) or more over the ideal body weight according to the Metropolitan Life Insurance Company height and weight tables. According to the National Institutes of Health Consensus Conference in 1996, surgery remains the only effective treatment for morbid obesity.¹ Indications for surgical treatment of morbid obesity are patients with a body mass index (BMI) greater than 40 kg/m² or, alternatively, a BMI between 35-40 kg/m² with weight-related serious comorbidity.²

There are a variety of operations for morbid obesity. These include jejunal-ileal bypass, biliopancreatic diversion, vertical banded gastroplasty, and Roux-en-Y gastric bypass. Payne and co-workers originally introduced jejunoileal bypass. This operation was abandoned due to severe long-term complications such as cirrhosis and liver failure. Biliopancreatic diversion is a malabsorptive procedure described by Scopinaro and co-workers in Genoa, Italy.³ In the United States, the two most frequently performed operations for morbid obesity are the vertical banded gastroplasty and the Roux-en-Y gastric bypass.⁴ The Roux-en-Y gastric bypass is a complex operation that can be associated with high morbidity, especially wound-related complications. Advances in laparoscopic optics, surgical techniques and instrumentation have made it possible to perform the gastric bypass operation using the laparoscopic approach. In this article, we present our technique of the laparoscopic Roux-en-Y gastric bypass for patients with morbid obesity.

METHODS

We performed a retrospective chart review of four initial cases of laparoscopic Roux-en-Y gastric bypass performed at the University of California Davis Medical Center. Charts were reviewed for demographic data, operative results, morbidity and mortality.

Operative Technique

Position of the Patient and Trocars

The patient is placed in a supine position. The surgeon stands on the patient's right side, and the assistant sur-

Division of Gastrointestinal Surgery, Department of Surgery, University of California Davis Medical Center, Sacramento, CA

Address reprint request to: Ninh T. Nguyen, MD, Department of Surgery, 4301 X Street, Rm. 2310, Sacramento, CA 95817-2214. Telephone: (916) 734-4596, Fax: (916) 734-3951, E-mail: ninh.nguyen@ucdmc.ucdavis.edu

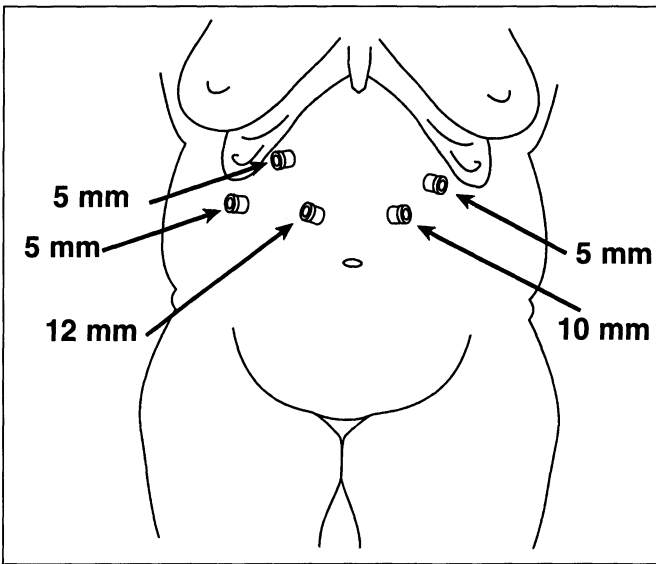


Figure 1. Laparoscopic trocar position for laparoscopic Roux-en-Y gastric bypass.

geon stands on the patient's left side. Carbon dioxide pneumoperitoneum is created using the Veress needle technique placed at the left midclavicular line slightly above the umbilicus. The intra-abdominal pressure is maintained at 15-17 mm Hg. Five abdominal ports are introduced on the anterior abdominal wall (**Figure 1**). A 45° angle telescope is used routinely to provide better visualization of the gastroesophageal junction. The patient is placed in a steep reverse Trendelenburg position with a foot plate at the end of the table to help secure the patient.

Creation of Gastric Pouch

The left lobe of the liver is retracted using a self-retaining liver retractor (Diamond-Flex retractor, Genzyme Surgical Product, Tucker, GA). Our initial dissection is on the hepatogastric ligament of the proximal stomach to enter the lesser sac. A 15-30 ml gastric pouch is created by dividing the gastric cardia approximately 1 cm below the gastroesophageal junction.

Creation of the Roux-en-Y Jejunal Limb

The greater omentum and transverse colon are retracted to the upper abdomen. The ligament of Treitz is identified, and a window in the transverse colon mesentery is created to the left of the middle colic vessels. A retro-

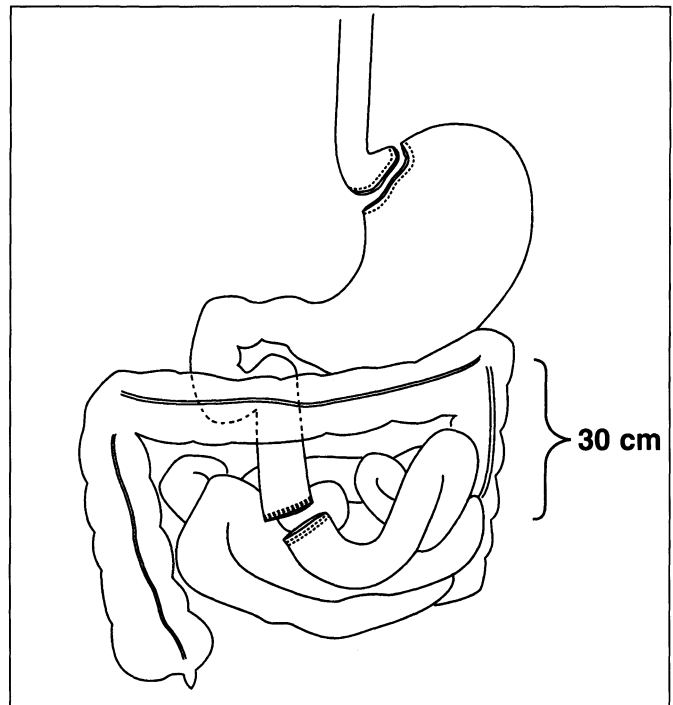


Figure 2. Laparoscopic division of proximal jejunum to create the Roux limb.

colic, retrogastric tunnel is made for the Roux-limb. The jejunum is transected 30 cm distal to the ligament of Treitz to create the Roux-limb (**Figure 2**). Two applications of the 2.5 mm Endo-GIA vascular stapler (USSC, Norwalk, CT) are applied to divide the jejunal mesentery. A Penrose drain is sutured to the stapled end of the Roux limb. The Roux-limb is measured 75 cm in length for patients with a BMI up to 50 kg/m² or 150 cm for patients with a BMI greater than 50 kg/m². A stapled, functional end-to-side jejunostomy is created using two applications of the Endo-GIA stapler. The remaining enterotomy site is stapled closed. Care must be taken to avoid narrowing the jejunal lumen when closing the enterotomy.

Endoscopic Placement of Anvil in the Gastric Pouch

The Penrose drain attached to the Roux limb is tunneled along the retrocolic and retrogastric path and positioned near the transected stomach. Flexible upper endoscopy is performed, and a snare grasper is passed through the gastric pouch into the peritoneal cavity (**Figure 3**). A loop wire is placed into the abdominal cavity, grasped by the snare, pulled into the gastric pouch and then pulled

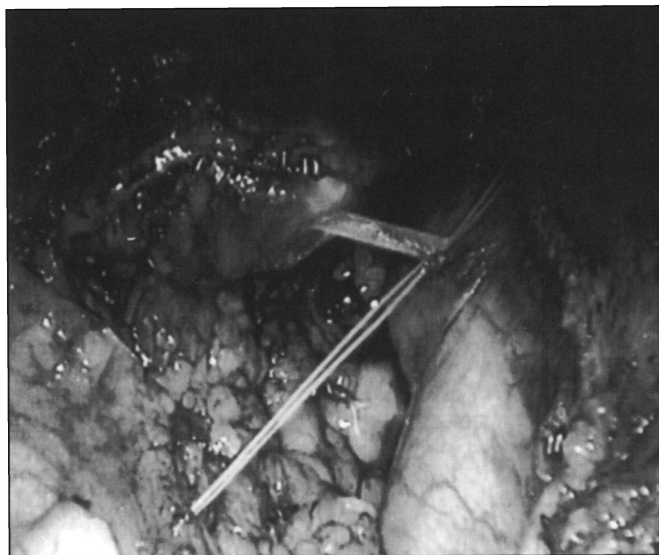


Figure 3. Endoscopic retrieval of guide wire for placement of 21 mm anvil.

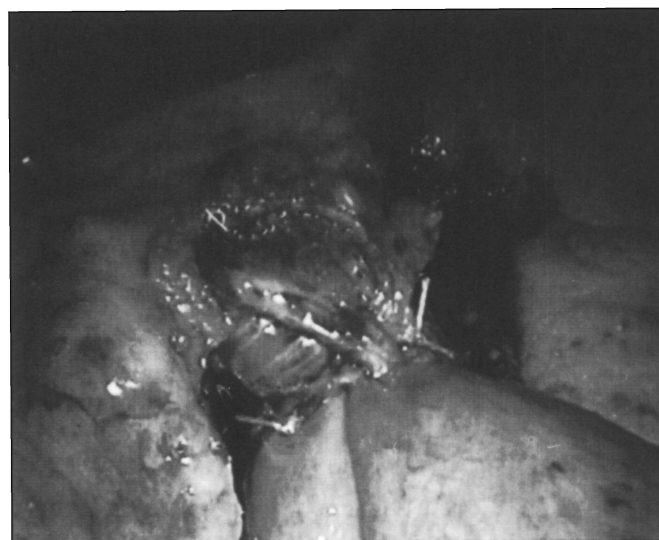

Figure 4. Laparoscopic functional end-to-side gastroenterostomy.

out through the mouth. The loop wire is attached to an anvil of the 21 mm CEEA Stapler (USSC). The anvil is pulled down through the stapled gastric pouch.

Gastroenterostomy Anastomosis

The CEEA stapler is placed through the end of the Roux limb to create a functional end-to-side gastrojejunostomy

anastomosis (**Figure 4**). The anastomosis is reinforced with interrupted sutures. The open end of the Roux limb is closed using the Endo GIA stapler (USSC). The gastrojejunostomy site is inspected endoscopically and tested for leaks. All ports larger than 5 mm are closed with 0-Vicryl suture using the Endoclose device (USSC). The patient is extubated in the operating suite prior to being transferred to the recovery room.

Postoperative Care

The patient is transferred to the floor from the recovery room. A gastrograffin swallow study is performed on postoperative day 2. Clear liquid is started on the evening of postoperative day 2 if there was no leak on the gastrograffin swallow. The patient is discharged on postoperative day 3 and scheduled for an office visit on postoperative day 7.

RESULTS

Four patients (3 females and 1 male) underwent laparoscopic Roux-en-Y gastric bypass from August 1998 to September 1998. The average age was 53 years. The mean BMI was 51.2 kg/m². There were no intraoperative emergencies or difficulties requiring conversion to laparotomy. The mean operative time was 381.3 + 119.7 minutes. The estimated blood loss was 275 + 64.5 ml. One of four patients was observed in the ICU for one night. The mean length of hospital stay was four days. There were no postoperative complications.

DISCUSSION

Mason and colleagues described the gastric bypass in 1969 based on observation that patients who underwent subtotal gastrectomy with Billroth II reconstruction lose a significant amount of weight after the operation. The original gastric bypass operation was later modified by Griffen and colleagues, who substituted the loop gastrojejunostomy for a Roux-en-Y gastrojejunostomy.

Gastric bypass can be associated with significant morbidity. Complications related to Roux-en-Y gastric bypass include intraoperative splenic injury, anastomotic leaks, deep venous thrombosis, pulmonary embolism, wound infection, incisional hernia, and respiratory complications.⁵ In an attempt to minimize the postoperative complications, decrease length of hospitalization, and enhance the recovery period, multiple authors have reported their initial results of laparoscopic approaches

to the treatment of morbid obesity. Belachew and colleagues reported on 350 patients who underwent an adjustable silicone gastric banding procedure.⁶ Short-term results of their first 75 patients undergoing laparoscopic gastric bypass (LGB) demonstrated that weight loss and reversal of comorbidities with laparoscopic Roux-en-Y gastric bypass were comparable to the open approach. Wittgrove was the first to report the laparoscopic Roux-en-Y gastric bypass.⁷ Our laparoscopic Roux-en-Y gastric bypass operation is a modification of the technique developed by Wittgrove and refined by Schauer and colleagues at the University of Pittsburgh. Important aspects of this operation include 1) the use of the Ultrasonic dissector for entering the lesser sac on the gastric lesser curvature; 2) creation of a 15-20 ml pouch by dividing the stomach 1 cm below the gastroesophageal junction; 3) the Roux limb must be routed retrocolic and retrogastric to adequately reach the transected gastric pouch; and 4) the end-to-side gastroenterostomy anastomosis is performed with the anvil placed transorally and pulled down to the gastric pouch.

Laparoscopic Roux-en-Y gastric bypass is a complex but feasible operation requiring appropriate instrumentation and advanced laparoscopic skills. This technique deserves further clinical evaluation to determine the long-term complication and weight loss potential as compared to the conventional open approach.

References:

1. Brolin RE. Update. NIH consensus conference. Gastrointestinal surgery for severe obesity. *Nutrition*. 1996;12(6):403-404.
2. NIH conference. Gastrointestinal surgery for severe obesity. Consensus development panel. *Ann Intern Med*. 1991;115:956-961
3. Scopinaro N, Adami GF, Marinari GM, et al. Biliopancreatic diversion. *World J Surg*. 1998;22:936-946.
4. Mason EE, Doherty C, Cullen JJ, Scott D, Rodriguez EM, Maher JW. Vertical gastropasty: evolution of vertical banded gastropasty. *World J Surg*. 1998;22:919-924.
5. Mason EE, Renquist KE, Jiang D. Perioperative risks and safety of surgery for severe obesity. *Am J Clin Nutr*. 1992;55:573S-576S.
6. Belachew M, Legrand M, Vincent V, Lismonde M, Le Docte N, Deschamps V. Laparoscopic adjustable gastric banding. *World J Surg*. 1998;22:955-963.
7. Wittgrove AC, Clark WG, Schubert KR. Laparoscopic gastric bypass, Roux en-Y: technique and results in 75 patients with 3-30 months follow-up. *Obesity Surg*. 1996;6:500-504.