

UCSF

UC San Francisco Previously Published Works

Title

Preexisting autoantibodies to type I IFNs underlie critical COVID-19 pneumonia in patients with APS-1

Permalink

<https://escholarship.org/uc/item/5h50j4cx>

Journal

Journal of Experimental Medicine, 218(7)

ISSN

0022-1007

Authors

Bastard, Paul
Orlova, Elizaveta
Sozaeva, Leila
[et al.](#)

Publication Date

2021-07-05









DOI

10.1084/jem.20210554

Peer reviewed

BRIEF DEFINITIVE REPORT

Preexisting autoantibodies to type I IFNs underlie critical COVID-19 pneumonia in patients with APS-1

Paul Bastard^{1,2,3} , Elizaveta Orlova⁴ , Leila Sozaeva⁴ , Romain Lévy^{1,2,5} , Alyssa James⁶ , Monica M. Schmitt⁶ , Sebastian Ochoa⁶ , Maria Kareva⁴ , Yulia Rodina⁷ , Adrian Gervais^{1,2} , Tom Le Voyer^{1,2} , Jérémie Rosain^{1,2} , Quentin Philippot^{1,2} , Anna-Lena Neehus^{1,2} , Elana Shaw⁶ , Mélanie Migaud¹ , Lucy Bizien¹ , Olov Ekwall^{8,9} , Stefan Berg⁸ , Guglielmo Beccuti¹⁰ , Lucia Ghizzoni¹⁰ , Gérard Thiriez¹¹ , Arthur Pavot¹² , Cécile Goujard¹³ , Marie-Louise Frémond^{5,14} , Edwin Carter¹⁵ , Anya Rothenbuhler¹⁶ , Agnès Lingart¹⁶ , Brigitte Mignot¹⁷ , Aurélie Comte¹⁷ , Nathalie Cheikh¹⁸ , Olivier Hermine^{2,19} , Lars Breivik²⁰ , Eystein S. Husebye^{20,21,22} , Sébastien Humbert²³ , Pierre Rohrllich²⁴ , Alain Coaquette²⁵ , Fanny Vuoto²⁶ , Karine Faure²⁶ , Nizar Mahlaoui^{5,27} , Primož Kotnik^{28,29} , Tadej Battelino^{28,29} , Katarina Trebušak Podkrajšek^{28,29} , Kai Kisand³⁰ , Elise M.N. Ferré⁶ , Thomas DiMaggio⁶ , Lindsey B. Rosen⁶ , Peter D. Burbelo³¹ , Martin McIntyre³² , Nelli Y. Kann⁷ , Anna Shcherbina⁷ , Maria Pavlova³³ , Anna Kolodkina⁴ , Steven M. Holland⁶ , Shen-Ying Zhang^{1,2,3} , Yanick J. Crow^{14,15} , Luigi D. Notarangelo⁶ , Helen C. Su⁶ , Laurent Abel^{1,2,3} , Mark S. Anderson³⁴ , Emmanuelle Jouanguy^{1,2,3} , Bénédicte Neven^{2,5} , Anne Puel^{1,2,3} , Jean-Laurent Casanova^{1,2,3,35} , and Michail S. Lionakis⁶

Patients with biallelic loss-of-function variants of *AIRE* suffer from autoimmune polyendocrine syndrome type-1 (APS-1) and produce a broad range of autoantibodies (auto-Abs), including circulating auto-Abs neutralizing most type I interferons (IFNs). These auto-Abs were recently reported to account for at least 10% of cases of life-threatening COVID-19 pneumonia in the general population. We report 22 APS-1 patients from 21 kindreds in seven countries, aged between 8 and 48 yr and infected with SARS-CoV-2 since February 2020. The 21 patients tested had auto-Abs neutralizing IFN- α subtypes and/or IFN- ω ; one had anti-IFN- β and another anti-IFN- ϵ , but none had anti-IFN- κ . Strikingly, 19 patients (86%) were hospitalized for COVID-19 pneumonia, including 15 (68%) admitted to an intensive care unit, 11 (50%) who required mechanical ventilation, and four (18%) who died. Ambulatory disease in three patients (14%) was possibly accounted for by prior or early specific interventions. Preexisting auto-Abs neutralizing type I IFNs in APS-1 patients confer a very high risk of life-threatening COVID-19 pneumonia at any age.

¹Laboratory of Human Genetics of Infectious Diseases, Necker Branch, Institut National de la Santé et de la Recherche Médicale U1163, Necker Hospital for Sick Children, Paris, France; ²University of Paris, Imagine Institute, Paris, France; ³St. Giles Laboratory of Human Genetics of Infectious Diseases, Rockefeller Branch, The Rockefeller University, New York, NY; ⁴Endocrinology Research Centre, Moscow, Russia; ⁵Pediatric Immunology, Hematology and Rheumatology Unit, Necker Hospital for Sick Children, Assistance Publique Hôpitaux de Paris, Paris, France; ⁶Laboratory of Clinical Immunology and Microbiology, Division of Intramural Research, National Institute of Allergy and Infectious Diseases, National Institutes of Health, Bethesda, MD; ⁷Dmitry Rogachev National Medical Research Center of Pediatric Hematology, Oncology and Immunology, Moscow, Russia; ⁸Department of Pediatrics, Institute of Clinical Sciences, The Sahlgrenska Academy, University of Gothenburg, Sweden; ⁹Department of Rheumatology and Inflammation Research, Institute of Medicine, The Sahlgrenska Academy, University of Gothenburg, Sweden; ¹⁰Department of Medical Sciences, University of Turin, Turin, Italy; ¹¹Intensive Care Unit, Besançon Hospital, Besançon, France; ¹²Intensive Care Unit, Kremlin-Bicêtre Hospital, Kremlin-Bicêtre, France; ¹³Internal Medicine Department, Bicêtre Hospital, Assistance Publique Hôpitaux de Paris, Paris Saclay University, Institut National de la Santé et de la Recherche Médicale U1018, Le Kremlin-Bicêtre, France; ¹⁴Laboratory of Neurogenetics and Neuroinflammation, Université de Paris, Imagine Institute, Paris, France; ¹⁵Centre for Genomic and Experimental Medicine, Medical Research Council Institute of Genetics and Molecular Medicine, Edinburgh, UK; ¹⁶Pediatric Endocrinology Department, Bicêtre Hospital, Assistance Publique Hôpitaux de Paris, Paris Saclay University, Le Kremlin-Bicêtre, France; ¹⁷Pediatric Medicine Unit, University Hospital of Besançon, Besançon, France; ¹⁸Pediatric Hematology Unit, University Hospital of Besançon, Besançon, France; ¹⁹Hematology department, University of Paris, Necker Hospital for Sick Children, Assistance Publique Hôpitaux de Paris, Paris, France; ²⁰Department of Clinical Science and K.G. Jebsen Center for Autoimmune Disorders, University of Bergen, Bergen, Norway; ²¹Department of Medicine, Haukeland University Hospital, Bergen, Norway; ²²Department of Medicine (Solna), Karolinska Institutet, Stockholm, Sweden; ²³Internal Medicine Unit, Besançon Hospital, Besançon, France; ²⁴Pediatric Hematology and Oncology unit, Centre Hospitalier Universitaire de Nice, Nice, France; ²⁵Laboratory of Virology, Besançon Hospital, Besançon, France; ²⁶Infectious Disease Unit, Lille Hospital, Lille, France; ²⁷Centre de Référence Déficiences Immunitaires Héritaires, Hôpital Universitaire Necker-Enfants Malades, Assistance Publique Hôpitaux de Paris, Paris, France; ²⁸Faculty of Medicine, University of Ljubljana, Ljubljana, Slovenia; ²⁹University Medical Centre Ljubljana, University Children's Hospital, Ljubljana, Slovenia; ³⁰Institute of Biomedicine and Translational Medicine, University of Tartu, Tartu, Estonia; ³¹National Institute of Dental and Craniofacial Research, National Institutes of Health, Bethesda, MD; ³²Royal Alexandra Hospital, Paisley, Scotland, UK; ³³Department of Endocrinology N°1, Sechenov University, Moscow, Russia; ³⁴Diabetes Center, University of California, San Francisco, San Francisco, CA; ³⁵Howard Hughes Medical Institute, New York, NY.

Correspondence to Paul Bastard: paul.bastard@institutimagine.org; Jean-Laurent Casanova: casanova@rockefeller.edu; Michail S. Lionakis: lionakism@mail.nih.gov.

© 2021 Bastard et al. This article is distributed under the terms of an Attribution–Noncommercial–Share Alike–No Mirror Sites license for the first six months after the publication date (see <http://www.rupress.org/terms/>). After six months it is available under a Creative Commons License (Attribution–Noncommercial–Share Alike 4.0 International license, as described at <https://creativecommons.org/licenses/by-nc-sa/4.0/>).

Introduction

Autoimmune polyendocrine syndrome type 1 (APS-1), also known as autoimmune polyendocrinopathy-candidiasis-ectodermal dystrophy or APECED, is a monogenic inborn error of immunity typically caused by biallelic deleterious variants of the autoimmune regulator (*AIRE*) gene (Ahonen et al., 1990; Nagamine et al., 1997, Finnish-German APECED Consortium, 1997; Ferre et al., 2016; Husebye et al., 2018). Heterozygous variants can also underlie autosomal dominant forms (Ofstedal et al., 2015). Patients with APS-1 have defective central T cell tolerance, leading to the thymic escape of autoreactive T cells and the development, from early childhood, of a broad range of autoantibodies (auto-Abs) against various autoantigens, including endocrine and other tissue antigens and cytokines (Bruserud et al., 2016; Chan and Anderson, 2015; Constantine and Lionakis, 2019; Guo et al., 2018; Orlova et al., 2017; Proekt et al., 2017). Among these anti-cytokine auto-Abs, neutralizing auto-Abs against IL-17A and IL-17F phenocopy inborn errors of IL-17A/F and underlie chronic mucocutaneous candidiasis (CMC; Kisand et al., 2010; Puel et al., 2011; Puel et al., 2010). High mucosal concentrations of IFN- γ were also proposed to contribute to CMC (Break et al., 2021). Virtually all patients with APS-1 produce auto-Abs against type I IFNs, generally against the 13 individual IFN- α subtypes and IFN- ω (Bruserud et al., 2016; Levin, 2006; Meager et al., 2006; Meyer et al., 2016; Orlova et al., 2017). These auto-Abs were long thought to be clinically silent. This was surprising, as these auto-Abs are neutralizing and type I IFNs are potent antiviral molecules, acting through both innate immunity (in particular via their secretion by plasmacytoid dendritic cells) and cell-intrinsic immunity (in most cell types; Duncan et al., 2021; Gresser, 1997; Hoffmann et al., 2015; Isaacs and Lindenmann, 1957; Isaacs et al., 1957; Jing and Su, 2019; Lazear et al., 2019). Moreover, the essential role of type I IFNs in fending off viruses in humans was confirmed by the description of patients with autosomal recessive, complete IFNAR1 or IFNAR2 deficiency and adverse reactions to measles-mumps-rubella (MMR) vaccine or yellow fever virus (YFV; YFV-17D) live-attenuated viral vaccine (Duncan et al., 2015; Gothe et al., 2020; Hernandez et al., 2019), herpes simplex encephalitis (Bastard et al., 2021b), or critical COVID-19 pneumonia (Bastard et al., 2021b; Zhang et al., 2020a; Zhang et al., 2020b). Nevertheless, the viral phenotype of these patients is not as broad as initially predicted, as neatly illustrated by two IFNAR1-deficient adults (26 and 38 yr old) who had never been hospitalized for severe viral disease until they were admitted for critical COVID-19 pneumonia (Zhang et al., 2020b).

In this context, we and others recently reported that three unrelated patients with APS-1 had life-threatening COVID-19 pneumonia (Bastard et al., 2020; Beccuti et al., 2020). These cases suggested that the auto-Abs neutralizing type I IFN were pathogenic. They further contributed to the discovery that they can also underlie life-threatening COVID-19 pneumonia in previously healthy individuals without APS-1, accounting for at least 10% of the cases in an international cohort of patients (Bastard et al., 2020). These auto-Abs were more frequent in men (95%) than in women (5%), and in elderly patients with critical COVID-19, half of the patients with auto-Abs were older

than 65 yr (Bastard et al., 2020). These auto-Abs typically neutralized the 13 individual IFN- α or IFN- ω (or both) but only rarely neutralized IFN- β , IFN- κ , and IFN- ϵ . These findings were replicated in other cohorts (Combes et al., 2021; de Prost et al., 2021; Koning et al., 2021; Troya et al., 2021; Wang et al., 2020 Preprint; Wijst et al., 2021 Preprint). Subjects with inborn errors of type I IFN immunity or neutralizing auto-Abs against type I IFN are, thus, at high risk of critical COVID-19 pneumonia, with impaired control of viral replication in the first few days of SARS-CoV-2 infection probably resulting in a secondary phase of pulmonary and systemic hyperinflammation (Zhang et al., 2020a). Subjects with such auto-Abs are also at high risk of YFV-17D disease, with these antibodies accounting for three of the eight cases studied (Bastard et al., 2021c). Interestingly, the three patients with YFV-17D disease had auto-Abs that neutralized both the 13 IFN- α and IFN- ω , and two also had auto-Abs against IFN- β , these proportions being higher than those reported for COVID-19 patients. It is unknown whether patients with APS-1 have ever been vaccinated with YFV-17D. Following on from the brief description of three APS-1 patients with critical COVID-19 pneumonia, we report here the immunological and clinical features of 22 patients with APS-1 during the course of SARS-CoV-2 infection.

Results and discussion

Baseline characteristics of the patients

The 22 patients studied were aged 8 to 48 yr at the time of infection with SARS-CoV-2 (median, 24.5 yr). 9 were male and 13 were female. 8 were children under the age of 16 yr (Table 1). All had undergone vaccination according to the schedules in force in their country of origin, including vaccination with the live-attenuated MMR, with no overt adverse events, between the ages of 1 and 2 yr. None of the patients had a previous history of severe viral infection, and only one had a history of pneumonia. The 22 patients came from 21 unrelated families (two patients were siblings). The patients originated from and lived in England ($n = 1$), France ($n = 5$), Italy ($n = 1$), Russia ($n = 11$), Scotland ($n = 1$), Sweden ($n = 1$), and the United States ($n = 2$). 21 of the 22 patients had a typical clinical diagnosis of APS-1 (i.e., any two of the classic triad of manifestations: hypoparathyroidism, adrenal insufficiency, and CMC), with confirmation of the presence of homozygous or compound heterozygous loss-of-function variants of *AIRE* in the 17 patients tested. One 16-yr-old patient with biallelic loss-of-function *AIRE* mutations (p.R257X) presented only CMC. 21 of the 22 patients had a history of severe tissue autoimmunity, including hypoparathyroidism ($n = 20$), adrenal insufficiency ($n = 20$), hypogonadism ($n = 9$), enteropathy ($n = 9$), pernicious anemia ($n = 6$), alopecia ($n = 6$), autoimmune hepatitis ($n = 3$), and vitiligo ($n = 3$), and all but four had a history of CMC. One patient was on immunosuppressive treatment with the B cell-depleting mAb rituximab and monthly intravenous Ig (IVIg) substitution, another was on treatment with the JAK inhibitor ruxolitinib, a third patient was receiving treatment with the calcineurin inhibitor tacrolimus, and another two patients were on monthly IVIg treatment. Other treatments included endocrine replacement therapy (hydrocortisone and/or

Table 1. **Baseline demographic, genetic, and clinical characteristics of the 22 APS-1 patients with SARS-CoV-2 infection included in this study**

Patient no.	Ancestry/residence	Age (yr)	Sex	AIRE variants	IFN-α, IFN-β, IFN-ω auto-Ab positivity	Prior noninfectious clinical manifestations	Prior infections	Treatments at the time of SARS-CoV-2 infection diagnosis
1	European/Italy	32	F	R203X/R203X	IFN- α and IFN- ω positive	AI, HP, ectodermal dystrophy, hypogonadism PA, enteropathy	CMC	Hydrocortisone, fludrocortisone, calcium, iron, magnesium, vitamin B12, folic acid, cholecalciferol, PTH, HRT, mesalamine, pancreatic enzyme replacement therapy, rifaximin
2	European/Scotland	35	F	L323SfsX51/L323SfsX51	IFN- α and IFN- ω positive	AI, HP, hypogonadism, gastroparesis	None	Hydrocortisone, fludrocortisone, estrogen, PTH
3	European/USA	48	F	L323SfsX51/S64TfsX71	IFN- α , IFN- β , and IFN- ω positive	AI, HP, HT, hypogonadism, Sjögren's syndrome	CMC	Hydrocortisone, fludrocortisone, calcitriol, levothyroxine, HRT
4	European/France	21	M	R257X/P539L	IFN- α and IFN- ω positive	AI, HP, enteropathy, DM, HT, asplenia, exocrine pancreatic insufficiency, myocarditis	CMC	Hydrocortisone, fludrocortisone, levothyroxine, insulin, fluconazole, trimethoprim/sulfamethoxazole, pancreatic enzymes, monthly IVIg
5	European/Russia	34	M	NT	IFN- ω positive	AI, HP, enteropathy, nail dystrophy	None	Hydrocortisone, fludrocortisone, calcitriol
6	European/Russia	13	F	R257X/R257X	NT	AI, HP, autoimmune hepatitis, enteropathy, pancreatitis, nephritis	CMC	Hydrocortisone, fludrocortisone, calcium, amlodipine, enalapril, rituximab (treatment initiation in October 2017 with re-dosing every 6 mo; last dose 8 mo prior to SARS-CoV-2 infection diagnosis), monthly IVIg
7	European/Russia	28	M	R257X/R257X	IFN- α and IFN- ω positive	AI, HP, enteropathy, alopecia, ptosis, enamel dysplasia	CMC	Hydrocortisone, fludrocortisone, calcitriol, fluconazole
8	European/Russia	32	F	R257X/R257X	IFN- α and IFN- ω positive	AI, HP, hypogonadism, enteropathy, autoimmune hepatitis, alopecia, vitiligo, asplenia, Sjögren's syndrome, PA, deep vein thrombosis, ptosis, enamel dysplasia, cataract	CMC, pneumonia	Hydrocortisone, fludrocortisone, calcium carbonate, alfacalcidol, fluconazole, rivaroxaban
9	European/Russia	14	M	R257X/R257X	IFN- α and IFN- ω positive	AI, DM, alopecia, enamel dysplasia, asthma	CMC	Hydrocortisone, fludrocortisone, fluconazole
10	European/Russia	8	F	R257X/E298X	IFN- α and IFN- ω positive	AI, HP, enteropathy, alopecia, PA, autoimmune hepatitis, autoimmune encephalitis	CMC	Hydrocortisone, fludrocortisone, calcitriol, fluconazole, monthly IVIg
11	European/Russia	28	F	R257X/R257X	IFN- α and IFN- ω positive	HP	CMC	Alfacalcidol, fluconazole
12	European/Russia	16	M	R257X/R257X	IFN- α and IFN- ω positive	enamel hypoplasia	CMC	Fluconazole
13	European/Russia	20	F	R257X/R257X	IFN- α and IFN- ω positive	AI, HP, hypogonadism, HT	CMC	Hydrocortisone, fludrocortisone, alfacalcidol, levothyroxine, HRT
14	European/France	31	F	NT	IFN- α and IFN- ω positive	AI, HP, hypogonadism, PA, hypopituitarism, achalasia	CMC	Hydrocortisone, levothyroxine
15	European/USA	45	M	S64TfsX71/L323SfsX51	IFN- α and IFN- ω positive	AI, HP, HT, end-stage renal disease, alopecia, PA, vitiligo, enteropathy	CMC	Hydrocortisone, fludrocortisone, calcium, ruxolitinib

Table 1. **Baseline demographic, genetic, and clinical characteristics of the 22 APS-1 patients with SARS-CoV-2 infection included in this study (Continued)**

Patient no.	Ancestry/residence	Age (yr)	Sex	AIRE variants	IFN- α , IFN- β , IFN- ω auto-Ab positivity	Prior noninfectious clinical manifestations	Prior infections	Treatments at the time of SARS-CoV-2 infection diagnosis
16	European/France	38	F	NT	IFN- α and IFN- ω positive	AI, HP, myocarditis, PA, hypogonadism, cutaneous lupus	CMC, urinary tract infections	Hydrocortisone, fludrocortisone, PTH, iron, magnesium, 1- α -HRT, perindopril, vitamin C, posaconazole
17	European/Sweden	8	F	P538L/P538L	IFN- α and IFN- ω positive	AI, HP, urticarial eruption, vitiligo, lupus-like systemic inflammation	None	Hydrocortisone, fludrocortisone, alfacalcidol, calcium, magnesium
18	European/France	11	M	NT	IFN- α and IFN- ω positive	AI, HP, HT	CMC	Hydrocortisone, fludrocortisone, calcium, levothyroxine, tacrolimus
19	European/England	18	M	c.242T>C/C.1265delC	IFN- α and IFN- ω positive	AI, HP, urticarial eruption, DM, alopecia, hypogonadism	CMC	Hydrocortisone, fludrocortisone, calcium
20	European/France	15	F	NT	IFN- α and IFN- ω positive	HP, ovarian insufficiency, retinitis	CMC	Hydrocortisone, fludrocortisone, calcium, weekly methotrexate
21	European/Russia	10	M	R257X/R257X	IFN- α and IFN- ω positive	AI, HP, urticarial eruption, enteropathy, retinitis	CMC	Hydrocortisone, fludrocortisone, calcium, calcitriol, fluconazole
22	European/Russia	30	F	R257X/L323SfsX51	IFN- ω positive	AI, HP, hypogonadism	None	Hydrocortisone, fludrocortisone, calcitriol

AI, adrenal insufficiency; DM, diabetes mellitus; F, female; HP, hypoparathyroidism; HRT, hormone replacement therapy; HT, hypothyroidism; M, male; NT, not tested; PA, pernicious anemia; PTH, parathyroid hormone.

fludrocortisone, $n = 20$; levothyroxine, $n = 5$) and antifungal prophylaxis (fluconazole, $n = 8$).

Clinical, radiographical, and laboratory characteristics of COVID-19 infection in 22 patients with APS-1, in chronological order

Patient 1 is a 32-yr-old Italian woman with a history of the classic triad manifestations, enteropathy, and pernicious anemia (Beccuti et al., 2020). She was diagnosed with bilateral COVID-19 pneumonia in February 2020 and hospitalized for 37 d in Northern Italy. She developed hypoxemia requiring intensive care unit (ICU) admission and mechanical ventilation for 6 d. She developed secondary pneumococcal pneumonia and sepsis-induced ventricular dysfunction. She was treated with corticosteroids and broad-spectrum antibiotics. 2 mo after discharge from hospital, her pulmonary function was persistently impaired (i.e., diffusing capacity for carbon monoxide, 55%).

Patient 2 is a 35-yr-old Scottish woman with a history of hypoparathyroidism, adrenal insufficiency, and hypogonadism, but not CMC (Bastard et al., 2020). She was diagnosed with bilateral COVID-19 pneumonia in March 2020 and hospitalized for 12 d. She developed hypoxemia and was intubated and mechanically ventilated in the ICU for 5 d. She developed lymphopenia (absolute lymphocyte count [ALC], 600/mm³) and a mild increase in transaminase levels (aspartate transaminase [AST], 89 U/liter). She was treated with corticosteroids; she recovered and was discharged home.

Patient 3 is a 48-yr-old American woman of Danish ancestry with a history of the classic triad manifestations, hypogonadism, hypothyroidism, and Sjögren's syndrome (Bastard et al., 2020). She was diagnosed with bilateral COVID-19 pneumonia and hospitalized in March 2020 for 17 d. She developed hypoxemia and was intubated in the ICU for 11 d. She developed lymphopenia (ALC, 650/mm³), an increase in transaminase levels (AST, 1,668 U/liter), hyperferritinemia (14,679 μ g/dl), and high D-dimer levels. She was treated with corticosteroids and broad-spectrum antibiotics; she recovered and was discharged home.

Patient 4 is a 21-yr-old French man with a history of the classic triad manifestations, type 1 diabetes, asplenia, and myocarditis (Puel et al., 2010). He was on monthly IVIg substitution at the time of infection. He developed a high fever and mild respiratory symptoms in May 2020. He was hospitalized, with radiographical evidence of mild pneumonia not requiring oxygen therapy.

Patient 5 is a 34-yr-old Russian man with a history of hypoparathyroidism, adrenal insufficiency, and enteropathy, but no CMC. He was hospitalized for 10 d in January 2021 with bilateral COVID-19 pneumonia. He developed hypoxemia requiring oxygen supplementation, lymphopenia (ALC, 380/mm³), and an increase in D-dimer levels. He received corticosteroids, tocilizumab, and broad-spectrum antibiotics and made a full recovery.

Patient 6 is a 13-yr-old Russian girl with a history of the classic triad manifestations, autoimmune hepatitis, and enteropathy. She

was diagnosed with COVID-19 infection while asymptomatic during a SARS-CoV-2 PCR test performed for screening purposes before a routine clinic visit in July 2020. Interestingly, she had been on rituximab since October 2017 and was also receiving IVIg substitution (0.5 g/kg monthly).

Patient 7 was a 28-yr-old Russian man with a history of the classic triad manifestations, enteropathy, and alopecia who was hospitalized in the ICU for bilateral COVID-19 pneumonia in October 2020. He suffered severe hypoxemia requiring mechanical ventilation for 4 wk, complicated by secondary bacterial sepsis, acute renal failure requiring hemodialysis, and two episodes of pneumothorax. He developed lymphopenia (ALC, 100/mm³), high transaminase levels (ALT, 225 U/liter), and high D-dimer levels. He was treated with broad-spectrum antibiotics, with the initiation of corticosteroids and tofacitinib 3–8 d after the onset of hypoxemia. He died after 47 d in the hospital.

Patient 8 was a 32-yr-old Russian woman with a history of the classic triad manifestations, autoimmune hepatitis, alopecia, and a previous episode of pneumonia, which is seen in the setting of autoimmune pneumonitis in APS-1 patients (Ferré et al., 2019). She was hospitalized in the ICU for COVID-19 for 15 d in October 2020. She developed severe hypoxemia requiring mechanical ventilation and died of respiratory failure. She was treated with corticosteroids from day 13 of hospitalization, 2 d before her death.

Patient 9 is a 14-yr-old Russian adolescent with a history of CMC, adrenal insufficiency, alopecia, and type 1 diabetes. He was hospitalized for bilateral COVID-19 pneumonia for 15 d in October 2020. He developed hypoxemia requiring oxygen supplementation by a nasal cannula for 6 d. He recovered and was discharged home.

Patient 10 is an 8-yr-old Russian girl with a history of the classic triad manifestations, enteropathy, autoimmune hepatitis, and autoimmune encephalitis. She was receiving IVIg substitution (0.5 g/kg monthly) at the time of infection. She was diagnosed with asymptomatic COVID-19 following screening by serological SARS-CoV-2 IgG testing after her mother was diagnosed with mild COVID-19 infection.

Patient 11 is a 28-yr-old Russian woman with a history of CMC, hypoparathyroidism, and enteropathy. She was hospitalized in October 2020 for 12 d for bilateral COVID-19 pneumonia not requiring oxygen supplementation. She developed lymphopenia (ALC, 190/mm³). She recovered and was discharged home.

Patient 12 is a 16-yr-old Russian man with a history of CMC and enamel hypoplasia. He was hospitalized for 26 d in October 2020 for bilateral COVID-19 pneumonia. He developed hypoxemia requiring ICU admission and mechanical ventilation. He developed lymphopenia (ALC, 600/mm³), and his D-dimer levels increased. He was treated with corticosteroids, tocilizumab, and broad-spectrum antibiotics. He recovered and was discharged home.

Patient 13 was a 20-yr-old Russian woman with a history of the classic triad manifestations and hypothyroidism. She was hospitalized for 14 d for COVID-19 pneumonia. She was already hypoxemic at admission, and her hospital course was further complicated by worsening hypoxemia, requiring ICU admission and mechanical ventilation on day 9 of hospitalization. She was

then treated with corticosteroids and tocilizumab but died from respiratory failure 5 d after intubation.

Patient 14 is a 31-yr-old French woman with a history of the classic triad manifestations, hypogonadism, and pernicious anemia. She was hospitalized for more than 60 d for COVID-19 pneumonia in November 2020. She developed hypoxemia requiring ICU admission, mechanical ventilation, and extracorporeal membrane oxygenation (ECMO). She suffered from multiple secondary bacterial infections, including pneumonia, bacteremia, and sepsis, and ventricular tachycardia. She developed mild increases in transaminase (AST, 77 U/liter) and D-dimer levels. She was treated with corticosteroids. She survived but required tracheostomy and intensive respiratory rehabilitation due to persistent respiratory insufficiency.

Patient 15 is a 45-yr-old American man of Danish ancestry and brother of patient 3, with a history of the classic triad manifestations, enteropathy, alopecia, pernicious anemia, hypothyroidism, and end-stage renal disease on hemodialysis. He was hospitalized in November 2020 as a prophylactic measure to facilitate close monitoring after his diagnosis with COVID-19 at an external facility. He was febrile upon admission, with mild respiratory symptoms, no hypoxemia, and bilateral pneumonia on imaging. He was treated with remdesivir and corticosteroids, while ruxolitinib was continued to prevent progression to hypoxemia and rebound inflammation. His hospital course was complicated by pulmonary embolism (Fig. S1 B), which was treated with anticoagulation. He recovered without needing oxygen supplementation or ICU admission and was discharged home after an 18-d stay in hospital.

Patient 16 was a 38-yr-old French woman with a history of the classic triad manifestations, hypogonadism, pernicious anemia, myocarditis, and cutaneous lupus. She was hospitalized for 13 d in November 2020. She developed hypoxemia requiring ICU admission and mechanical ventilation. She developed multiple bacterial superinfections and pneumothorax. She was treated with corticosteroids after intubation. She developed lymphopenia (ALC, 290/mm³), and her transaminase (AST, 76 U/liter) and D-dimer levels increased slightly. She died of respiratory failure after 12 d of intubation.

Patient 17 is an 8-yr-old Swedish girl with a history of hypoparathyroidism, adrenal insufficiency, and vitiligo, but not CMC. She was hospitalized for bilateral COVID-19 pneumonia at the end of November 2020. She developed hypoxemia requiring ICU admission and mechanical ventilation for 4 d. She was treated with corticosteroids, plasmapheresis (which successfully decreased type I IFN auto-Ab titers; Fig. 1 C), and IVIg substitution. She recovered and was discharged home after a 20-d stay in hospital (Lemarquis et al., 2021).

Patient 18 is an 11-yr-old French boy with the classic triad manifestations and hypothyroidism. He was hospitalized for 56 d in December 2020 for bilateral COVID-19 pneumonia. His course was complicated by hypoxemia requiring ICU admission and mechanical ventilation. He developed lymphopenia (ALC, 300/mm³) and increases in D-dimer and transaminase (AST, 48 U/liter) levels. He was receiving tacrolimus before COVID-19. He was treated with corticosteroids, IFN- β (45 μ g, Avonex, three injections), convalescent plasma, and plasmapheresis, which

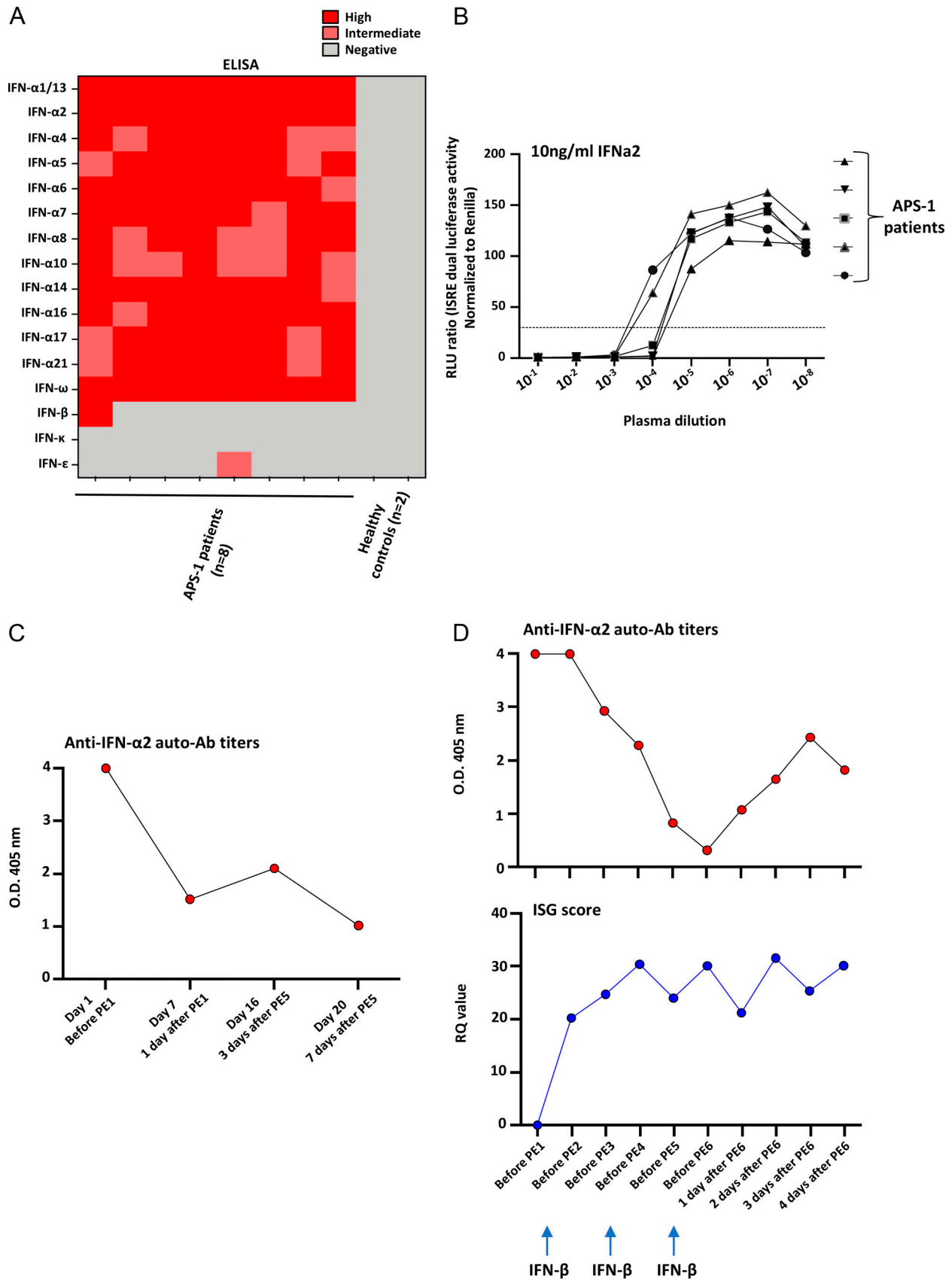


Figure 1. **APS-1 patients have neutralizing auto-Abs against type I IFNs, the titers of which can be decreased by plasmapheresis. (A)** Titers of auto-Ab titers against the 17 type I IFNs in APS-1 patients infected with SARS-CoV-2 ($n = 8$). **(B)** Neutralization of IFN- α 2 by various dilutions of auto-Ab-containing serum from APS-1 patients with COVID-19 ($n = 5$). Relative luciferase activity is shown after stimulation with 10 ng/ml of IFN- α 2. Results representative of two

independent experiments are shown. ISRE, IFN stimulation response element; RLU, relative light units. **(C)** Plasmapheresis decreased the titers of type I IFN auto-Abs in one APS-1 patient (patient 17) with COVID-19 pneumonia. The titers of auto-Abs against IFN- α 2 are shown for one of the APS-1 patients treated by plasmapheresis (PE). **(D)** Plasmapheresis (PE) decreased the titers of type I IFN auto-Abs in another APS-1 patient (patient 18) with COVID-19 pneumonia, treated with plasmapheresis, convalescent plasma, and IFN- β (as shown with arrows). The titers of auto-Abs against IFN- α 2 are shown for the APS-1 patients treated by plasmapheresis in the upper panel. In the lower panel, ISG scores (evaluated by NanoString) show an increase after the initiation of treatments. ISG score cutoff for positivity is 2,758. RQ, relative quantitation.

decreased type I IFN auto-Ab titers and increased the IFN-stimulated gene (ISG) score (Fig. 1 D).

Patient 19 is an 18-yr-old British man with a history of the classic triad manifestations, hypogonadism, type 1 diabetes, and alopecia. He was diagnosed with COVID-19 infection at the end of December 2020 after the diagnosis of his parents. He developed a high fever and mild cough and was instructed to initiate stress-dose corticosteroid treatment and continue until the symptoms had completely resolved to prevent secondary hyperinflammation. He remained at home without the need for hospitalization and recovered after 7 d.

Patient 20 is a 15-yr-old French girl with a history of hypoparathyroidism, ovarian insufficiency, and retinitis. She had weekly methotrexate treatment for her retinitis. She was diagnosed with mild COVID-19 pneumonia in early January 2021. She had radiological evidence of bilateral COVID-19 pneumonia (Fig. S1 C). After multidisciplinary discussion, she was hospitalized for treatment with three injections of IFN- β (45 μ g, Avonex) and convalescent plasma therapy to prevent progression to hypoxemic COVID-19 pneumonia. She developed a high fever for 72 h, recovered without requiring oxygen supplementation, and was discharged home.

Patient 21 is a 10-yr-old Russian boy with a history of the classic triad manifestations, enteropathy, and retinitis. He was hospitalized for 24 d in January 2021 for bilateral COVID-19 pneumonia. He developed hypoxemia requiring oxygen supplementation by nasal cannula. He developed lymphopenia (ALC, 840/mm³), and his D-dimer levels increased. He was treated with corticosteroids, tocilizumab, prophylactic anticoagulation, and broad-spectrum antibiotics. He recovered and was discharged home.

Patient 22 is a 30-yr-old Russian woman with a history of hypoparathyroidism, adrenal insufficiency, and hypogonadism. She was hospitalized for 6 d in January 2021 for COVID-19 pneumonia. She developed hypoxemia requiring oxygen supplementation by a nasal cannula. She presented a mild increase in transaminase levels (ALT, 128 U/liter). She received corticosteroids, tofacitinib, faripiravir, and prophylactic anticoagulation. She recovered and was discharged home.

Auto-Abs against type I IFNs in the patients

All the patients tested ($n = 21$, patient 6 not tested) had high titers of neutralizing auto-Abs against IFN- α 2 and/or IFN- ω , and one (patient 3) also had auto-Abs against IFN- β (Table 1). All patients but two had been tested for the auto-Abs before the COVID-19 pandemic. We also tested for the presence of auto-Abs against the 17 individual type I IFNs for all patients for whom serum or plasma samples were available. Eight patients were tested for the presence of auto-Abs against all 13 individual IFN- α and IFN-

ω , and they all tested positive (Fig. 1 A). Only one patient had auto-Abs against IFN- β , and one other patient had auto-Abs against IFN- ϵ , and none of the patients tested had auto-Abs against IFN- κ . We then confirmed that these auto-Abs had neutralizing activity (Fig. 1 B) against IFN- α 2 and IFN- ω in all patients and against IFN- β in the only patient positive for auto-Abs against this cytokine. We could not test the neutralizing activity of the auto-Abs to IFN- ϵ . The serum and plasma samples from patients without detectable auto-Abs against IFN- β did not neutralize the activity of this cytokine. Pre- and post-COVID serum samples were available for four patients, and we found no significant differences in titer or neutralization capacity of anti-IFN auto-Abs before and after SARS-CoV-2 infection. We also tested for lung-targeted auto-Abs against the lung antigens KCNRG and BPIFB1 in eight patients (five severe and three mild/moderate; Ferré et al., 2019). All examined patients were negative for KCNRG auto-Abs, but two patients, one with severe (patient 17) and another with mild COVID-19 (patient 19), tested positive for BPIFB1 auto-Abs (Fig. S2).

Life-threatening COVID-19 pneumonia in 15 APS-1 patients

All 15 patients with hypoxemic COVID-19 pneumonia had positive SARS-CoV-2 PCR results. They had a median age of 30 yr (range, 8–48 yr). Six were male and nine were female (Table 1 and Table 2). Five were children under the age of 16 yr. The patients were admitted to hospital between 2 and 10 d after the onset of clinical manifestations (median, 5 d) and were hospitalized for a median of 16 d (range, 6–50 d). We applied the National Institutes of Health (NIH) ordinal scale (range, 1–8; Beigel et al., 2020) to assess the severity of COVID-19 in these patients. They were found to have a median ordinal scale score of 7 (range, 5–8). The degree of hypoxemia was variable, with a median nadir partial pressure of O₂ of 82 mmHg (range, 60–93 mmHg). 11 patients required intubation and mechanical ventilation for a median of 6 d (range, 1–27 d), and 1 patient required ECMO for 42 d. All patients had a chest computed tomography (CT) scan or x ray showing extensive bilateral ground-glass opacities due to severe COVID-19 pneumonia (Fig. S1 A). Four patients suffered from bacterial superinfections, including ventilator-associated pneumonia, bacteremia, and sepsis. Two patients developed pneumothorax requiring chest tube placement (twice in one patient), and ventricular tachycardia and sepsis-induced cardiomyopathy occurred in one patient each. One patient was discharged with a tracheostomy. All patients had high C-reactive protein (CRP) levels, eight had lymphopenia, seven had high D-dimer levels, six had high transaminase levels, and four had high ferritin and lactate dehydrogenase (LDH) levels.

Table 2. Clinical features of 22 APS-1 patients with SARS-CoV-2 infection

Patient no.	Days from symptom onset to hospital admission	COVID-19 severity (NIH ordinal score)	COVID-19 complications (other than hypoxemia related)	Duration of hospital stay (d)	Hypoxemia support ^a (nadir SpO ₂)	Intubation duration (d)	Laboratory abnormalities	Radiographical abnormalities	Treatment	Outcome
1	4	Critical (7)	Hypotension requiring dobutamine/norepinephrine infusion; pneumococcal pneumonia; sepsis-induced ventricular dysfunction (EF, 30%); <i>C. difficile</i> infection	37	Mechanical ventilation (N/A)	6	N/A	Bilateral, multiple GGO	High-dose hydrocortisone, LOP/RIT, ribavirin, HCQ, piperacillin/tazobactam	Survival: low DLCO (55%) 2 mo after discharge
2	8	Critical (7)	None	12	Mechanical ventilation (N/A)	5	↑CRP, ↓ALC, ↑AST	Bilateral, multiple GGO	High-dose hydrocortisone	Survival
3	7	Critical (7)	None	17	Mechanical ventilation (80%)	11	↑CRP, ↓ALC, ↑AST, ↑ALT, ↑ferritin, ↑LDH, ↑D-dimer	Bilateral, multiple GGO	High-dose methyl-prednisolone, azithromycin, ceftriaxone, HCQ	Survival
4	4	Mild (4)	None	3	No	No	N/A	Bilateral GGO	None	Survival
5	10	Moderate-severe (5)	Antibiotic-associated diarrhea	10	No (93%)	No	↑CRP, ↓ALC, ↑LDH, ↑D-dimer	Bilateral, multiple GGO	High-dose prednisone, tocilizumab, vancomycin, ertapenem, levofloxacin, HCQ	Survival
6	Not hospitalized	Mild (1)	None	0	No	No	Not tested	Not performed	None	Survival
7	3	Critical (8)	Bacterial sepsis (<i>Acinetobacter</i> , <i>Klebsiella</i>) pneumothorax (twice), acute renal failure (requiring hemodialysis)	47	Mechanical ventilation (60%)	28	↑CRP, ↓ALC, ↑AST, ↑ALT, ↑creatinine, ↑D-dimer, ↑IL-6	Bilateral, multiple GGO	High-dose prednisone, tofacitinib, cefepime, sulbactam, polymyxin B, linezolid, caspofungin	Death
8	4	Critical (8)	None	15	Mechanical ventilation (82%)	1	N/A	Bilateral, multiple GGO	High-dose dexamethasone	Death
9	7	Moderate-severe (5)	None	15	Nasal cannula (86%)	No	↑CRP, ↑LDH	Bilateral, multiple GGO	No	Survival
10	Not hospitalized	Mild (1)	None	0	No	No	Not tested	Not performed	No	Survival
11	5	Mild (4)	None	12	No	No	↓ALC	Bilateral GGO	No	Survival

Table 2. Clinical features of 22 APS-1 patients with SARS-CoV-2 infection (Continued)

Patient no.	Days from symptom onset to hospital admission	COVID-19 severity (NIH ordinal scale score)	COVID-19 complications (other than hypoxemia related)	Duration of hospital stay (d)	Hypoxemia support* (nadir SpO ₂)	Intubation duration (d)	Laboratory abnormalities	Radiographical abnormalities	Treatment	Outcome
12	5	Critical (7)	None	26	Mechanical ventilation (82%)	N/A	↑CRP, ↓ALC, ↑LDH, ↑D-dimer	Bilateral, multiple GGO	High-dose dexamethasone, tocilizumab, ribavirin, azithromycin, cefepime, vancomycin, voriconazole	Survival
13	3	Critical (8)	None	14	Mechanical ventilation (N/A)	5	N/A	N/A	High-dose dexamethasone, tocilizumab	Death
14	9	Critical (7)	Bacterial pneumonia, bacteremia, and sepsis (<i>Klebsiella</i> , <i>Serratia</i> , <i>Enterobacter</i> , <i>E. coli</i>), ventricular arrhythmia	>60	Mechanical ventilation and ECMO (N/A)	42	↑CRP, ↑ferritin, ↓ALT, ↑AST, ↑D-dimer	Bilateral, multiple GGO	High-dose dexamethasone	Survival, tracheostomy
15	4	Moderate (4)	Pulmonary embolism	18	No	No	↑CRP, ↓ALC, ↑D-dimer	Bilateral GGO	High-dose hydrocortisone, remdesivir, azithromycin, ceftriaxone, apixaban	Survival
16	7	Critical (8)	Bacterial pneumonia (<i>Enterobacter</i>) pneumothorax	13	Mechanical ventilation (60%)	12	↑CRP, ↓ALC, ↑AST, ↑ALT, ↑D-dimer	Bilateral, multiple GGO	High-dose dexamethasone	Death
17	2	Critical (7)	Transient diabetes insipidus	20	Mechanical ventilation (80%)	4	↑CRP, ↑AST, ↑IL-6	Bilateral, multiple GGO	High-dose betamethasone, plasmapheresis	Survival
18	2	Critical (7)	Hemoptysis	56	Mechanical ventilation (87%)	25	↑CRP, ↑ferritin, ↓ALC, ↑AST, ↑D-dimer	Bilateral, multiple GGO	High-dose dexamethasone, IFN-β, convalescent plasma, plasmapheresis	Survival
19	Not hospitalized	Mild (2)	None	0	No	No	Not tested	Not performed	Prolonged course of stress-dose steroids	Survival
20	5	Mild (4)	None	7	No	No	N/A	Bilateral GGO	IFN-β, convalescent plasma	Survival
21	5	Moderate-severe (5)	GI bleeding	21	Nasal cannula (87%)	No	↑CRP, ↓ALC, ↑LDH, ↑D-dimer	Bilateral, multiple GGO	High-dose dexamethasone, tocilizumab, meropenem, fluconazole, IVIg	Survival

Table 2. Clinical features of 22 APS-1 patients with SARS-CoV-2 infection (Continued)

Patient no.	Days from symptom onset to hospital admission	COVID-19 severity (NIH ordinal scale score)	COVID-19 complications (other than hypoxemia related)	Duration of hospital stay (d)	Hypoxemia support ^a (nadir SpO ₂)	Intubation duration (d)	Laboratory abnormalities	Radiographical abnormalities	Treatment	Outcome
22	8	Moderate-severe (5)	None	6	Nasal cannula (89%)	No	↑CRP, ↓ALC, ↑AST, ↑ALT, ↑ferritin	Bilateral, multiple GGO	High-dose dexamethasone, tofacitinib, favipiravir, amoxicillin-clavulanic acid, IVIg	Survival

DLCO, diffusing capacity for carbon monoxide; *C. difficile*, *Clostridium difficile*; EF, ejection fraction; *E. coli*, *Escherichia coli*; GGO, ground-glass opacity; GI, gastrointestinal; HCO, hydroxychloroquine; LOP/RTI, lopinavir/ritonavir; N/A, not available.

^aHypoxemia defined as SpO₂ <94 mmHg.

Managements of the 15 patients with life-threatening COVID-19

14 patients received high-dose corticosteroids (>0.5 mg/kg prednisone equivalent/day) in the form of dexamethasone, betamethasone, hydrocortisone, methylprednisolone, or prednisone (Table 2); all 10 patients given corticosteroids within 24 h of the onset of hypoxemia survived, whereas all 4 patients receiving corticosteroids later in the course of their hypoxemic disease died ($P = 0.002$; χ^2 test with Yates correction). Six patients received broad-spectrum antibacterial antibiotics, and three patients received antiviral treatment with favipiravir, ribavirin, or a combination of lopinavir/ritonavir with ribavirin. Four patients received anti-IL-6 receptor therapy (tocilizumab), and two patients received the JAK inhibitor tofacitinib. One patient (patient 20) received convalescent plasma (twice, 24 h apart) and intramuscular recombinant IFN- β (Avonex, 45 μ g every 48 h, three injections). Plasmapheresis was performed in two patients (daily, five times for patient 17 and six times for patient 18), resulting in a decrease in type I IFN auto-Ab titers in both (Fig. 1, C and D). One patient (patient 18) also received three injections of intramuscular IFN- β as well as convalescent plasma after the first three plasmapheresis sessions. We monitored the blood ISG response in this patient using NanoString. Interestingly, we found a clear increase of ISGs after the initiation of plasmapheresis and IFN- β treatment (Figs. 1 D and S3). Four patients (18%) died from sepsis and/or respiratory failure. All the patients who died were adults (aged 20, 28, 32, and 38 yr). The 11 survivors, aged 8 to 48 yr, have been discharged from hospital, including one patient suffering from chronic respiratory failure and still dependent on oxygen therapy at most recent follow-up.

Mild nonhypoxemic SARS-CoV-2 infection in seven APS-1 patients and the efficacy of early treatment in three of these patients

7 of 22 patients (32%) had SARS-CoV-2 infection without developing hypoxemia (Table 1 and Table 2). The median age of these patients was 18 yr (range, 8–45 yr). Three were male and four were female. Three were children under the age of 15 yr. Interestingly, two of these patients were receiving monthly IVIg therapy at the time of infection; one remained asymptomatic and was treated as an outpatient, whereas the other was hospitalized with a high fever and bilateral pneumonia but did not develop hypoxemia. Another patient with asymptomatic infection was receiving IVIg and had also received rituximab 8 mo before the diagnosis of COVID-19. Moreover, an American man on ruxolitinib treatment was admitted for prophylactic monitoring when he developed a high fever and pneumonia. Treatment with corticosteroids and a 10-d course of remdesivir were initiated in this patient, with the aim of preventing progression to hypoxemic COVID-19. In addition, a British patient harboring BPIFB1 auto-Abs recovered at home following the early initiation and prolonged administration of stress-dose corticosteroid therapy after the development of a high fever with symptoms of pneumonia. Finally, a French patient whose family was made aware of the risk of severe COVID-19 in APS-1 was hospitalized prophylactically 2 d after symptom onset while presenting mild radiographical lesions on a chest CT scan (Fig. S1 C). She was

treated with subcutaneous recombinant IFN- β (Avonex, 45 μ g dose every 48 h, three doses) and convalescent plasma therapy for two consecutive days, with the goal of preventing progression to hypoxemic COVID-19. She recovered fully without the need for oxygen supplementation and was discharged home without sequelae.

Preexisting auto-Abs to type I IFNs underlie life-threatening COVID-19 in APS-1 patients

We describe 22 patients with APS-1 from 21 kindreds from seven countries who were infected with SARS-CoV-2 between February 2020 and January 2021. 19 patients (86%) were hospitalized; 15 (68%) developed life-threatening bilateral COVID-19 pneumonia with hypoxemia requiring admission to an ICU, 11 of whom required mechanical ventilation, including 5 who developed life-threatening secondary complications such as sepsis, pneumothorax, arrhythmias, and/or pulmonary embolism, 4 of whom died (18%). As we do not know how many SARS-CoV-2-infected APS-1 patients there are worldwide and our series probably reflects an ascertainment bias, we cannot rigorously estimate the proportion of life-threatening cases. However, our findings strongly suggest that APS-1 patients are at very high risk of critical COVID-19 pneumonia. Our previous report of auto-Abs against type I IFNs in at least 10% of patients with critical COVID-19 pneumonia and none of the subjects with asymptomatic or benign SARS-CoV-2 infection tested (Bastard et al., 2020) further suggests that APS-1 patients are at high risk of developing critical disease because of their neutralizing auto-Abs against type I IFNs. This very poor outcome seems to be independent of age, sex, European ancestry, and the nature of any other autoimmune manifestations. Importantly, our findings confirm that auto-Abs neutralizing type I IFNs present before SARS-CoV-2 infection, as opposed to other auto-Abs potentially triggered by this infection, confer a very high risk of critical COVID-19 (Bastard et al., 2020; Beck and Aksentijevich, 2020; de Prost et al., 2021; Koning et al., 2021; Meffre and Iwasaki, 2020; Troya et al., 2021; Wijst et al., 2021 Preprint; Zhang et al., 2020b). We also found similar levels of auto-Abs before and after COVID-19 in the patients tested, further suggesting that the infection does not significantly trigger their production.

Vaccination or early treatment to avoid life-threatening COVID-19 pneumonia

Patients with APS-1 should be prioritized for vaccination against COVID-19. Nevertheless, APS-1 patients should not be vaccinated with the newly developed vaccine against SARS-CoV-2 that uses the YFV live attenuated vaccine as a carrier (Bastard et al., 2021c; Sanchez-Felipe et al., 2021). In the meantime, all necessary measures should be taken to avoid infection. Our report of seven patients with SARS-CoV-2 infection following a mild or moderate, nonhypoxemic course is of interest in this respect. Three of these seven patients were on monthly IVIg treatment, which may have decreased the pathogenicity of the auto-Abs against type I IFNs or acted through other mechanisms. Consistently, one of these patients was also receiving rituximab at the time of COVID-19 diagnosis, which may have altered the nature or

decreased the titer of auto-Abs against type I IFNs. In addition, three patients whose medical teams had been informed by us of the risk of critical COVID-19 were treated early in the course of infection, one with an early and prolonged course of stress-dose corticosteroids, another by prophylactic admission with the administration of corticosteroids and remdesivir, and the third by early administration of subcutaneous IFN- β . We thus recommend that infected patients should be hospitalized promptly. In patients diagnosed early, ideally before the development of pneumonia, several treatments may be considered. First, cocktails of mAb against the SARS-CoV-2 spike protein may be given to accelerate the decline in viral load (Chen et al., 2021; Weinreich et al., 2021); these antibodies should be preferred over convalescent plasma, which has not shown efficacy in severe COVID-19 pneumonia and may also contain auto-Abs against type I IFNs or other detrimental components (Simonovich et al., 2021). Intramuscular or nebulized IFN- β or subcutaneous pegylated-IFN- β may also be considered in patients without auto-Abs against IFN- β (Monk et al., 2021), as successfully reported for intramuscular IFN- α 2 in patients with inborn errors of type I IFN (Lévy et al., 2021) and for IFN- β in a patient with incontinentia pigmenti and auto-Abs against type I IFNs (Bastard et al., 2021a). Obviously, the administration of IFN- α 2 is not indicated in APS-1 patients. In patients treated with IFN- β , a monitoring of anti-IFN- β auto-Abs will be important. In the small minority of APS-1 patients carrying auto-Abs against IFN- β , alternative options could be considered.

Rescue treatment in patients with APS-1 and life-threatening COVID-19

When patients present with hypoxemia in the later phase of COVID-19, the administration of mAbs against the SARS-CoV-2 spike protein and of IFN- β should be avoided, given the potential risk of worsening the hyperinflammation and hypoxemia (Pan et al., 2021; Hung et al., 2020). In hypoxemic APS-1 patients, the early initiation of high-dose corticosteroid treatment is important to prevent a worsening of lung injury and death, as suggested by the observation that other patients receiving high-dose corticosteroids at or within 24 h of the onset of hypoxemia recovered, whereas the later initiation of corticosteroids was associated with death (Horby et al., 2021). Indeed, two symptomatic patients without hypoxemic disease who received corticosteroids did not progress to severe disease, further suggesting that early corticosteroid treatment might prevent or attenuate the secondary hyperinflammatory phase of disease (Zhang et al., 2020a). The prompt initiation of corticosteroid treatment is of particular importance in APS-1 patients, because of their common adrenal insufficiency, and especially in those with preexisting autoimmune pneumonitis, a frequently overlooked manifestation of APS-1 that affects up to ~40% of patients (Ferré et al., 2019), as the inflammation-prone lung tissue in these patients may confer a predisposition to a worsening of lung injury. Two of the eight patients tested here had auto-Abs against the lung auto-Ab BPIFB1. Such patients are often misdiagnosed as having a prior history of reactive airway disease or recurrent pneumonia (Ferré et al., 2019). Finally, both in the early phase of disease and after the development of COVID-19

pneumonia, plasmapheresis should be considered, as it has been safely performed in two APS-1 patients (this report) and four patients without APS-1 (de Prost et al., 2021). This procedure can lower the titers of circulating auto-Abs against type I IFNs without lowering the titers of antiviral Abs (de Prost et al., 2021), and it may be more beneficial when performed early in the course of hospitalization.

No previous viral disease before severe COVID-19

None of the 22 APS-1 patients had previously suffered from severe viral infections, consistent with the history of most patients with APS-1 (Constantine and Lionakis, 2019). By inference from our recent observation that auto-Abs against type I IFNs can underlie life-threatening disease due to the YFV-17D live-attenuated virus vaccine (Bastard et al., 2021c), APS-1 patients should not be vaccinated against YFV. None of the 22 patients described here reported having been inoculated with the YFV-17D vaccine. It is intriguing that these and other APS-1 patients have not been reported to suffer from other severe viral infections, including MMR disease and herpes simplex virus encephalitis, which have been reported in patients with IFNAR1 or IFNAR2 deficiency (Bastard et al., 2021b; Duncan et al., 2015; Gothe et al., 2020; Hernandez et al., 2019). This may reflect the residual activity of some of the 17 type I IFNs, including IFN- β in particular, or that at the age of vaccination or HSV-1 infection, the auto-Abs were not yet present, not as potent, or did not target all the type I IFNs neutralized in older APS-1 patients. There is, nevertheless, one case report of an APS-1 patient suffering from recurrent cutaneous HSV-1 infection (Nagafuchi et al., 2007). The paucity of viral infections in patients with inherited IFNAR1 or IFNAR2 deficiency is, itself, intriguing (Duncan et al., 2015; Hernandez et al., 2019; Gothe et al., 2020; Zhang et al., 2020a; Bastard et al., 2021b; Meyts and Casanova, 2021). Careful retrospective and prospective studies of viral infections and viral diseases in APS-1 patients are therefore warranted. More generally, a careful study of viral infections and viral diseases in patients with inherited IFNAR1 or IFNAR2 deficiency, and in patients with auto-Abs against type I IFNs, regardless of their etiology, is also warranted.

Materials and methods

Patients and study approval

Written informed consent was obtained from patients or their parents in the country in which they were followed, in accordance with local regulations. The study was approved by the institutional review boards of The Rockefeller University and Institut National de la Santé et de la Recherche Médicale, the National Institute of Allergy and Infectious Diseases (NIAID)/NIH, the Endocrinology Research Center of Russia, and the University of Gothenburg, Sweden. Experiments were conducted in the United States and France, in accordance with local regulations and with the approval of the institutional review boards of The Rockefeller University, NIAID/NIH, and Institut National de la Santé et de la Recherche Médicale. Anonymized samples were studied at the NIAID under nonhuman subject research conditions; no additional institutional review board

consent was required at the NIH. APS-1 patients gave consent under institutional review board-approved protocol 11-I-0187 (ClinicalTrials.gov, NCT01386437) at the NIAID/NIH. The Swedish patient was enrolled in study no. 779-11, approved by the Central Ethical Review Board at the University of Gothenburg. The study has been approved by the local ethics committee at Endocrinology Research Center of Russia (protocol no. 11 from 23.10.2013), and all patients or their parents or guardians signed the informed consent.

Detection of anti-cytokine auto-Abs using a cell-based assay

All Russian patients were tested for neutralizing auto-Abs against IFN- α 2 and/or IFN- ω using a cell-based assay as previously described (Breivik et al., 2014; Orlova et al., 2017).

Detection of anti-cytokine auto-Abs in a multiplex particle-based assay

Serum/plasma samples were screened for auto-Abs against IFN- α 2 and IFN- ω targets in a multiplex particle-based assay, in which magnetic beads with differential fluorescence were covalently coupled to recombinant human proteins (2.5 μ g/reaction). Beads were combined and incubated with 1:100 diluted serum/plasma samples for 30 min. Each sample was tested once. The beads were then washed and incubated with PE-labeled goat anti-human IgG antibody (1 μ g/ml) for 30 min. They were washed again and used in a multiplex assay run on a BioPlex X200 instrument. Patients with a fluorescence intensity >1,500 for IFN- α 2 or IFN- β or >1,000 for IFN- ω were tested for blocking activity.

ELISA for anti-cytokine auto-Abs

ELISA was performed as previously described (Bastard et al., 2020). In brief, 96-well ELISA plates (MaxiSorp; Thermo Fisher Scientific) were coated by incubation overnight at 4°C with 2 μ g/ml recombinant human IFN- α , and recombinant human IFN- ω (R&D Systems). Plates were then washed (PBS/0.005% Tween), blocked by incubation with 5% nonfat milk powder in the same buffer, washed, and incubated with 1:50 dilutions of plasma from the patients or controls for 2 h at room temperature (or with specific mAbs as positive controls). Each sample was tested once. Plates were thoroughly washed. HRP-conjugated Fc-specific IgG fractions from polyclonal goat anti-serum against human IgG (Nordic Immunological Laboratories) were added to a final concentration of 2 μ g/ml. Plates were incubated for 1 h at room temperature and washed. Substrate was added, and the optical density was measured. A similar protocol was used to test for antibodies against 12 subtypes of IFN- α , except that the plates were coated with cytokines from PBL Assay Science (catalog no. 11002-1).

Functional evaluation of anti-cytokine auto-Abs in PBMCs

The blocking activity of auto-Abs against IFN- α 2 and IFN- ω was assessed by evaluating STAT1 phosphorylation in healthy control cells following stimulation with the appropriate cytokines in the presence of 10% serum/plasma from a healthy control or a patient. Surface-stained healthy control peripheral blood mononuclear cells (350,000/reaction) were cultured in serum-free

RPMI medium supplemented with 10% healthy control or patient serum/plasma and were either left unstimulated or were stimulated with IFN- α 2 and IFN- ω (10 ng/ml) for 15 min at 37°C. Each sample was tested once. Cells were fixed, permeabilized, and stained for intranuclear phospho-STAT1 (Y701). Cells were acquired on a BD LSRFortessa cytometer with gating on CD14⁺ monocytes and analyzed with FlowJo software.

Functional evaluation of anti-cytokine auto-Abs by a luciferase reporter assay

The blocking activity of auto-Abs against IFN- α 2 and IFN- ω was also determined by assessing reporter luciferase activity. Briefly, HEK293T cells were transfected with the firefly luciferase plasmids under the control human *ISRE* promoters in the pGL4.45 backbone, and a constitutively expressing *Renilla* luciferase plasmid for normalization (pRL-SV40). Cells were transfected in the presence of the X-tremeGene 9 transfection reagent (Sigma-Aldrich) for 36 h. DMEM (Thermo Fisher Scientific) was supplemented with 10% healthy control or patient serum/plasma and was either left unstimulated or was stimulated with IFN- α 2 and IFN- ω (10 ng/ml) for 16 h at 37°C. Finally, luciferase levels were measured with the Dual-Glo reagent according to the manufacturer's protocol (Promega). Firefly luciferase values were normalized against *Renilla* luciferase values.

Luciferase immunoprecipitation systems assay for lung-targeted auto-Abs

We used the luciferase immunoprecipitation systems immunoassay to detect auto-Ab immunoreactivity against the lung targeting the potassium regulator KCNRG and bactericidal/permeability-increasing fold-containing B1 (BPIFB1) in APS-1 patient sera. Seropositivity was defined as a value greater than the mean for healthy donors plus 3 SDs, as previously described (Ferré et al., 2019).

IFN score (Rice et al., 2013)

Total RNA was extracted from whole blood with a PAXgene (PreAnalytix) RNA isolation kit. RNA concentration was assessed with a spectrophotometer (FLUOstar Omega; Labtech). Analysis of 24 genes and three housekeeping genes was conducted using the NanoString customer-designed CodeSets according to the manufacturer's recommendations (NanoString Technologies). Agilent TapeStation was used to assess the quality of the RNA. 100 ng total RNA was loaded for each sample. Data were processed with nSolver software (NanoString Technologies). The data were normalized relative to the internal positive and negative calibrators, the three reference probes, and the control samples. The median of the 24 probes for each of 27 healthy control samples was calculated. The mean NanoString score of the 27 healthy controls +2 SD of the mean was calculated. Scores above this value (>2.724) were designated as positive. The list of probes used in NanoString ISG analysis is supplied in Table S1.

Online supplemental material

Fig. S1 provides radiological images of COVID-19 in the patients. Fig. S2 shows the auto-Ab result for lung-targeted auto-Abs

(KCNRG and BPIFB1). Fig. S3 shows the ISGs used in the NanoString at the different time points, as well as the neutrophil score. Table S1 provides additional data on the probes used in the NanoString ISG analysis.

Acknowledgments

We thank the patients and their families for placing their trust in us. We warmly thank the members of both branches of the Laboratory of Human Genetics of Infectious Diseases. We warmly thank Y. Nemirovskaya, M. Woollet, D. Liu, S. Boucherit, C. Rivalain, M. Chrabieh, and L. Lorenzo for administrative assistance. Y.J. Crow thanks Carolina Uggetti and Gillian Rice for their generous help in generating ISG data.

The Laboratory of Human Genetics of Infectious Diseases is supported by the Howard Hughes Medical Institute, The Rockefeller University, the St. Giles Foundation, the NIH (grant R01AI088364), the National Center for Advancing Translational Sciences, NIH Clinical and Translational Science Award program (UL1 TR001866), an Emergent Ventures fast grant, the Mercatus Center at George Mason University, the Yale Center for Mendelian Genomics and the GSP Coordinating Center funded by the National Human Genome Research Institute (grants UMIHG006504 and U24HG008956), the Yale High Performance Computing Center (grant S10OD018521), the Fisher Center for Alzheimer's Research Foundation, the Meyer Foundation, the French National Research Agency (ANR) under the "Investments for the Future" program (ANR-10-IAHU-01), the Integrative Biology of Emerging Infectious Diseases Laboratory of Excellence (ANR-10-LABX-62-IBEID), the ANR project AABIFNCOV (ANR-20-CO11-0001), the French Foundation for Medical Research (EQU201903007798), the French Foundation for Medical Research and ANR GENCOV project, the ANRS-COV05 grant, the Square Foundation, Grandir - Fonds de solidarité pour l'enfance, the Fondation du Souffle, the SCOR Corporate Foundation for Science, Institut National de la Santé et de la Recherche Médicale, and the University of Paris. This work was further supported in part by the Intramural Research Program of the NIAID and National Institute of Dental and Craniofacial Research, NIH. The work was also supported in part by the Russian Science Foundation (project number 17-75-30035). P. Bastard was supported by the French Foundation for Medical Research (EA20170638020). P. Bastard and T. Le Voyer were supported by the MD-PhD program of the Imagine Institute (with the support of the Fondation Bettencourt-Schueller). A.-L. Neehus was supported by the Fondation Bettencourt-Schueller and the International PhD program of the Imagine Institute. The content in the manuscript is solely the responsibility of the authors and does not necessarily represent the official views of the any of the funding sources.

Author contributions: P. Bastard, E. Orlova, L. Sozaeva, R. Lévy, A. James, M.M. Schmitt, S. Ochoa, M. Kareva, Y. Rodina, A. Gervais, T. Le Voyer, J. Rosain, Q. Philippot, A.-L. Neehus, E. Shaw, M. Migaud, L. Bizien, O. Ekwall, S. Berg, G. Beccuti, L. Ghizzoni, G. Thiriez, A. Pavot, C. Goujard, M.-L. Frémond, E. Carter, A. Rothenbuhler, A. Linglart, B. Mignot, A. Comte, N. Cheikh, O. Hermine, L. Breivik, E.S. Husebye, S. Humbert, P.

Rohrlich, A. Coquette, F. Vuoto, K. Faure, N. Mahlaoui, P. Kotnik, T. Battelino, K. Trebušak Podkrajšek, K. Kisand, E.M.N. Ferré, T. DiMaggio, L.B. Rosen, P.D. Burbelo, M. McIntyre, N.Y. Kann, A. Shcherbina, M. Pavlova, A. Kolodkina, S.M. Holland, S.-Y. Zhang, Y.J. Crow, L.D. Notarangelo, H.C. Su, L. Abel, M.S. Anderson, E. Jouanguy, B. Neven, and A. Puel collected the clinical data and recruited and/or treated the patients. M.S. Lionakis and J.-L. Casanova supervised the project. P. Bastard, J.-L. Casanova, and M.S. Lionakis wrote the manuscript. All authors edited the manuscript.

Disclosures: P.D. Burbelo reported US Patent no. 10,564,152 issued. J.C. Casanova reported a patent to 63/055,155 pending and a patent to 63/141,669 pending. No other disclosures were reported.

Submitted: 8 March 2021

Revised: 1 April 2021

Accepted: 7 April 2021

References

Ahonen, P., S. Myllärniemi, I. Sipilä, and J. Perheentupa. 1990. Clinical variation of autoimmune polyendocrinopathy-candidiasis-ectodermal dystrophy (APECED) in a series of 68 patients. *N. Engl. J. Med.* 322: 1829–1836. <https://doi.org/10.1056/NEJM199006283222601>

Bastard, P., L.B. Rosen, Q. Zhang, E. Michailidis, H.H. Hoffmann, Y. Zhang, K. Dorgham, Q. Philippot, J. Rosain, V. Béziat, et al. COVID Human Genetic Effort. 2020. Autoantibodies against type I IFNs in patients with life-threatening COVID-19. *Science*. 370:eabd4585. <https://doi.org/10.1126/science.abd4585>

Bastard, P., R. Lévy, S. Henriquez, C. Bodemer, T.A. Szwebel, and J.L. Casanova. 2021a. Interferon- β Therapy in a Patient with Incontinentia Pigmenti and Autoantibodies against Type I IFNs Infected with SARS-CoV-2. *J. Clin. Immunol.* <https://doi.org/10.1007/s10875-021-01023-5>

Bastard, P., J. Manry, J. Chen, J. Rosain, Y. Seeleuthner, O. AbuZaitun, L. Lorenzo, T. Khan, M. Hasek, N. Hernandez, et al. 2021b. Herpes simplex encephalitis in a patient with a distinctive form of inherited IFNAR1 deficiency. *J. Clin. Invest.* 131:139980. <https://doi.org/10.1172/JCI139980>

Bastard, P., E. Michailidis, H.H. Hoffmann, M. Chbihi, T. Le Voyer, J. Rosain, Q. Philippot, Y. Seeleuthner, A. Gervais, M. Materna, et al. 2021c. Autoantibodies to type I IFNs can underlie adverse reactions to yellow fever live attenuated vaccine. *J. Exp. Med.* 218:e20202486. <https://doi.org/10.1084/jem.20202486>

Beccuti, G., L. Ghizzoni, V. Cambria, V. Codullo, P. Sacchi, E. Lovati, S. Mongodi, G.A. Iotti, and F. Mojoli. 2020. A COVID-19 pneumonia case report of autoimmune polyendocrine syndrome type 1 in Lombardy, Italy: letter to the editor. *J. Endocrinol. Invest.* 43:1175–1177. <https://doi.org/10.1007/s40618-020-01323-4>

Beck, D.B., and I. Aksentijevich. 2020. Susceptibility to severe COVID-19. *Science*. 370:404–405. <https://doi.org/10.1126/science.abe7591>

Beigel, J.H., K.M. Tomashek, L.E. Dodd, A.K. Mehta, B.S. Zingman, A.C. Kalil, E. Hohmann, H.Y. Chu, A. Luetkemeyer, S. Kline, et al. ACTT-1 Study Group Members. 2020. Remdesivir for the Treatment of Covid-19 - Final Report. *N. Engl. J. Med.* 383:1813–1826. <https://doi.org/10.1056/NEJMoa2007764>

Break, T.J., V. Oikonomou, N. Dutzan, J.V. Desai, M. Swidergall, T. Freiwald, D. Chauss, O.J. Harrison, J. Alejo, D.W. Williams, et al. Genomics and Computational Biology Core. 2021. Aberrant type 1 immunity drives susceptibility to mucosal fungal infections. *Science*. 371:eaay5731. <https://doi.org/10.1126/science.aay5731>

Breivik, L., B.E. Oftedal, A.S. Bøe Wolff, E. Bratland, E.M. Orlova, and E.S. Husebye. 2014. A novel cell-based assay for measuring neutralizing autoantibodies against type I interferons in patients with autoimmune polyendocrine syndrome type 1. *Clin. Immunol.* 153:220–227. <https://doi.org/10.1016/j.clim.2014.04.013>

Bruserud, Ø., B.E. Oftedal, N. Landegren, M.M. Erichsen, E. Bratland, K. Lima, A.P. Jørgensen, A.G. Myhre, J. Svartberg, K.J. Fougner, et al. 2016. A

Longitudinal Follow-up of Autoimmune Polyendocrine Syndrome Type 1. *J. Clin. Endocrinol. Metab.* 101:2975–2983. <https://doi.org/10.1210/je.2016-1821>

Chan, A.Y., and M.S. Anderson. 2015. Central tolerance to self revealed by the autoimmune regulator. *Ann. N. Y. Acad. Sci.* 1356:80–89. <https://doi.org/10.1111/nyas.12960>

Chen, P., A. Nirula, B. Heller, R.L. Gottlieb, J. Boscia, J. Morris, G. Huhn, J. Cardona, B. Mocherla, V. Stosor, et al. BLAZE-1 Investigators. 2021. SARS-CoV-2 Neutralizing Antibody LY-CoV555 in Outpatients with Covid-19. *N. Engl. J. Med.* 384:229–237. <https://doi.org/10.1056/NEJMoa2029849>

Combes, A.J., T. Courau, N.F. Kuhn, K.H. Hu, A. Ray, W.S. Chen, N.W. Chew, S.J. Cleary, D. Kushnoor, G.C. Reeder, et al. UCSF COMET Consortium. 2021. Global absence and targeting of protective immune states in severe COVID-19. *Nature*. 591:124–130. <https://doi.org/10.1038/s41586-021-03234-7>

Constantine, G.M., and M.S. Lionakis. 2019. Lessons from primary immunodeficiencies: Autoimmune regulator and autoimmune polyendocrinopathy-candidiasis-ectodermal dystrophy. *Immunol. Rev.* 287: 103–120. <https://doi.org/10.1111/imr.12714>

de Prost, N., P. Bastard, R. Arrestier, S. Fourati, M. Mahévas, S. Burrel, K. Dorgham, G. Gorochoy, Y. Tandjaoui-Lambiotte, I. Azzaoui, et al. 2021. Plasma Exchange to Rescue Patients with Autoantibodies Against Type I Interferons and Life-Threatening COVID-19 Pneumonia. *J. Clin. Immunol.* 41:536–544. <https://doi.org/10.1007/s10875-021-00994-9>

Duncan, C.J., S.M. Mohamad, D.F. Young, A.J. Skelton, T.R. Leahy, D.C. Munday, K.M. Butler, S. Morfopoulou, J.R. Brown, M. Hubank, et al. 2015. Human IFNAR2 deficiency: Lessons for antiviral immunity. *Sci. Transl. Med.* 7:307ra154. <https://doi.org/10.1126/scitranslmed.aac4227>

Duncan, C.J.A., R.E. Randall, and S. Hambleton. 2021. Genetic Lesions of Type I Interferon Signalling in Human Antiviral Immunity. *Trends Genet.* 37: 46–58. <https://doi.org/10.1016/j.tig.2020.08.017>

Ferre, E.M., S.R. Rose, S.D. Rosenzweig, P.D. Burbelo, K.R. Romito, J.E. Niemela, L.B. Rosen, T.J. Break, W. Gu, S. Hunsberger, et al. 2016. Redefined clinical features and diagnostic criteria in autoimmune polyendocrinopathy-candidiasis-ectodermal dystrophy. *JCI Insight*. 1:1. <https://doi.org/10.1172/jci.insight.88782>

Ferré, E.M.N., T.J. Break, P.D. Burbelo, M. Allgäuer, D.E. Kleiner, D. Jin, Z. Xu, L.R. Folio, D.J. Mollura, M. Swamydas, et al. 2019. Lymphocyte-driven regional immunopathology in pneumonitis caused by impaired central immune tolerance. *Sci. Transl. Med.* 11:eaav5597. <https://doi.org/10.1126/scitranslmed.aav5597>

Finnish-German APECED Consortium. 1997. An autoimmune disease, APECED, caused by mutations in a novel gene featuring two PHD-type zinc-finger domains. *Nat. Genet.* 17:399–403. <https://doi.org/10.1038/ng1297-399>

Gothe, F., C.F. Hatton, L. Truong, Z. Klimova, V. Kanderova, M. Fejtikova, A. Grainger, V. Bigley, J. Perthen, D. Mitra, et al. 2020. A novel case of homozygous IFNAR1 deficiency with haemophagocytic lymphohistiocytosis. *Clin. Infect. Dis.:*ciaal790. <https://doi.org/10.1093/cid/ciaal790>

Gresser, I. 1997. Wherefore interferon? *J. Leukoc. Biol.* 61:567–574. <https://doi.org/10.1002/jlb.61.5.567>

Guo, C.J., P.S.C. Leung, W. Zhang, X. Ma, and M.E. Gershwin. 2018. The immunobiology and clinical features of type 1 autoimmune polyglandular syndrome (APS-1). *Autoimmun. Rev.* 17:78–85. <https://doi.org/10.1016/j.autrev.2017.11.012>

Hernandez, N., G. Bucciol, L. Moens, J. Le Pen, M. Shahrooei, E. Goudouris, A. Shirvani, M. Changi-Ashtiani, H. Rokni-Zadeh, E.H. Sayar, et al. 2019. Inherited IFNAR1 deficiency in otherwise healthy patients with adverse reaction to measles and yellow fever live vaccines. *J. Exp. Med.* 216: 2057–2070. <https://doi.org/10.1084/jem.20182295>

Hoffmann, H.H., W.M. Schneider, and C.M. Rice. 2015. Interferons and viruses: an evolutionary arms race of molecular interactions. *Trends Immunol.* 36:124–138. <https://doi.org/10.1016/j.it.2015.01.004>

Hung, I.F., K.C. Lung, E.Y. Tso, R. Liu, T.W. Chung, M.Y. Chu, Y.Y. Ng, J. Lo, J. Chan, A.R. Tam, et al. 2020. Triple combination of interferon beta-1b, lopinavir-ritonavir, and ribavirin in the treatment of patients admitted to hospital with COVID-19: an open-label, randomised, phase 2 trial. *Lancet*. 395:1695–1704. [https://doi.org/10.1016/S0140-6736\(20\)31042-4](https://doi.org/10.1016/S0140-6736(20)31042-4)

Husebye, E.S., M.S. Anderson, and O. Kämpe. 2018. Autoimmune Polyendocrine Syndromes. *N. Engl. J. Med.* 378:2543–2544. <https://doi.org/10.1056/NEJMra1713301>

Isaacs, A., and J. Lindenmann. 1957. Virus interference. I. The interferon. *Proc. R. Soc. Lond. B Biol. Sci.* 147:258–267. <https://doi.org/10.1098/rspb.1957.0048>

- Isaacs, A., J. Lindenmann, and R.C. Valentine. 1957. Virus interference. II. Some properties of interferon. *Proc. R. Soc. Lond. B Biol. Sci.* 147:268–273. <https://doi.org/10.1098/rspb.1957.0049>
- Jing, H., and H.C. Su. 2019. New immunodeficiency syndromes that help us understand the IFN-mediated antiviral immune response. *Curr. Opin. Pediatr.* 31:815–820. <https://doi.org/10.1097/MOP.0000000000000827>
- Kisand, K., A.S. Bøe Wolff, K.T. Podkrajsek, L. Tserel, M. Link, K.V. Kisand, E. Ersvaer, J. Perheentupa, M.M. Erichsen, N. Bratonic, et al. 2010. Chronic mucocutaneous candidiasis in APECED or thymoma patients correlates with autoimmunity to Th17-associated cytokines. *J. Exp. Med.* 207:299–308. <https://doi.org/10.1084/jem.20091669>
- Koning, R., P. Bastard, J.L. Casanova, M.C. Brouwer, and D. van de Beek; with the Amsterdam U.M.C. COVID-19 Biobank Investigators. 2021. Autoantibodies against type I interferons are associated with multi-organ failure in COVID-19 patients. *Intensive Care Med.* <https://doi.org/10.1007/s00134-021-06392-4>
- Lazear, H.M., J.W. Schoggins, and M.S. Diamond. 2019. Shared and Distinct Functions of Type I and Type III Interferons. *Immunity.* 50:907–923. <https://doi.org/10.1016/j.immuni.2019.03.025>
- Lemarquis, A., T. Campbell, M. Aranda-Guillen, V. Hennings, P. Brodin, O. Kampe, K. Blennow, H. Zetterberg, C. Wenneras, K. Eriksson, et al. 2021. Severe COVID-19 in an APS1 patient with interferon autoantibodies treated with plasmapheresis. *JACI.* In press. <https://doi.org/10.1016/j.jaci.2021.03.034>
- Levin, M. 2006. Anti-interferon auto-antibodies in autoimmune polyendocrinopathy syndrome type 1. *PLoS Med.* 3:e292. <https://doi.org/10.1371/journal.pmed.0030292>
- Lévy, R., P. Bastard, F. Lantermier, M. Lecuit, S.Y. Zhang, and J.L. Casanova. 2021. IFN- α 2a Therapy in Two Patients with Inborn Errors of TLR3 and IRF3 Infected with SARS-CoV-2. *J. Clin. Immunol.* 41:26–27. <https://doi.org/10.1007/s10875-020-00933-0>
- Meager, A., K. Visvalingam, P. Peterson, K. Möll, A. Murumägi, K. Krohn, P. Eskelin, J. Perheentupa, E. Husebye, Y. Kadota, and N. Willcox. 2006. Anti-interferon autoantibodies in autoimmune polyendocrinopathy syndrome type 1. *PLoS Med.* 3:e289. <https://doi.org/10.1371/journal.pmed.0030289>
- Meffre, E., and A. Iwasaki. 2020. Interferon deficiency can lead to severe COVID. *Nature.* 587:374–376. <https://doi.org/10.1038/d41586-020-03070-1>
- Meyer, S., M. Woodward, C. Hertel, P. Vlaicu, Y. Haque, J. Kärner, A. Macagno, S.C. Onuoha, D. Fishman, H. Peterson, et al. APECED patient collaborative. 2016. AIRE-Deficient Patients Harbor Unique High-Affinity Disease-Ameliorating Autoantibodies. *Cell.* 166:582–595. <https://doi.org/10.1016/j.cell.2016.06.024>
- Meyts, I., and J.L. Casanova. 2021. Viral infections in humans and mice with genetic deficiencies of the type I IFN response pathway. *Eur. J. Immunol.* <https://doi.org/10.1002/eji.202048793>
- Monk, P.D., R.J. Marsden, V.J. Tear, J. Brookes, T.N. Batten, M. Mankowski, F.J. Gabbay, D.E. Davies, S.T. Holgate, L.P. Ho, et al. Inhaled Interferon Beta COVID-19 Study Group. 2021. Safety and efficacy of inhaled nebulised interferon beta-1a (SNG001) for treatment of SARS-CoV-2 infection: a randomised, double-blind, placebo-controlled, phase 2 trial. *Lancet Respir. Med.* 9:196–206. [https://doi.org/10.1016/S2213-2600\(20\)30511-7](https://doi.org/10.1016/S2213-2600(20)30511-7)
- Nagafuchi, S., K. Umene, F. Yamanaka, S. Oohashi, M. Shindo, H. Kurisaki, J. Kudoh, N. Shimizu, T. Hara, and M. Harada. 2007. Recurrent herpes simplex virus infection in a patient with autoimmune polyendocrinopathy-candidiasis-ectodermal dystrophy associated with L29P and IVS9-1G>C compound heterozygous autoimmune regulator gene mutations. *J. Intern. Med.* 261:605–610. <https://doi.org/10.1111/j.1365-2796.2007.01786.x>
- Nagamine, K., P. Peterson, H.S. Scott, J. Kudoh, S. Minoshima, M. Heino, K.J. Krohn, M.D. Lalioti, P.E. Mullis, S.E. Antonarakis, et al. 1997. Positional cloning of the APECED gene. *Nat. Genet.* 17:393–398. <https://doi.org/10.1038/ng1297-393>
- Oftedal, B.E., A. Hellesen, M.M. Erichsen, E. Bratland, A. Vardi, J. Perheentupa, E.H. Kemp, T. Fiskerstrand, M.K. Viken, A.P. Weetman, et al. 2015. Dominant Mutations in the Autoimmune Regulator AIRE Are Associated with Common Organ-Specific Autoimmune Diseases. *Immunity.* 42:1185–1196. <https://doi.org/10.1016/j.immuni.2015.04.021>
- Orlova, E.M., L.S. Sozaeva, M.A. Kareva, B.E. Oftedal, A.S.B. Wolff, L. Breivik, E.Y. Zakharova, O.N. Ivanova, O. Kämpe, I.I. Dedov, et al. 2017. Expanding the Phenotypic and Genotypic Landscape of Autoimmune Polyendocrine Syndrome Type 1. *J. Clin. Endocrinol. Metab.* 102:3546–3556. <https://doi.org/10.1210/jc.2017-00139>
- Proekt, I., C.N. Miller, M.S. Lionakis, and M.S. Anderson. 2017. Insights into immune tolerance from AIRE deficiency. *Curr. Opin. Immunol.* 49:71–78. <https://doi.org/10.1016/j.coi.2017.10.003>
- Puel, A., R. Döffinger, A. Natividad, M. Chrabieh, G. Barcenas-Morales, C. Picard, A. Cobat, M. Ouachée-Chardin, A. Toulon, J. Bustamante, et al. 2010. Autoantibodies against IL-17A, IL-17F, and IL-22 in patients with chronic mucocutaneous candidiasis and autoimmune polyendocrine syndrome type I. *J. Exp. Med.* 207:291–297. <https://doi.org/10.1084/jem.20091983>
- Puel, A., S. Cypowyj, J. Bustamante, J.F. Wright, L. Liu, H.K. Lim, M. Migaud, L. Israel, M. Chrabieh, M. Audry, et al. 2011. Chronic mucocutaneous candidiasis in humans with inborn errors of interleukin-17 immunity. *Science.* 332:65–68. <https://doi.org/10.1126/science.1200439>
- Horby, P., W.S. Lim, J.R. Emberson, M. Mafham, J.L. Bell, L. Linsell, N. Staplin, C. Brightling, A. Ustianowski, E. Elmahi, et al. RECOVERY Collaborative Group. 2021. Dexamethasone in Hospitalized Patients with Covid-19. *N. Engl. J. Med.* 384:693–704. <https://doi.org/10.1056/NEJMoa2021436>
- Rice, G.I., G.M. Forte, M. Szykiewicz, D.S. Chase, A. Aeby, M.S. Abdel-Hamid, S. Ackroyd, R. Allcock, K.M. Bailey, U. Balottin, et al. 2013. Assessment of interferon-related biomarkers in Aicardi-Goutières syndrome associated with mutations in TREX1, RNASEH2A, RNASEH2B, RNASEH2C, SAMHD1, and ADAR: a case-control study. *Lancet Neurol.* 12:1159–1169. [https://doi.org/10.1016/S1474-4422\(13\)70258-8](https://doi.org/10.1016/S1474-4422(13)70258-8)
- Sanchez-Felipe, L., T. Vercautysse, S. Sharma, J. Ma, V. Lemmens, D. Van Looveren, M.P. Arkalagud Javarappa, R. Boudewijns, B. Malengier-Devlies, L. Liesenborghs, et al. 2021. A single-dose live-attenuated YF17D-vectored SARS-CoV-2 vaccine candidate. *Nature.* 590:320–325. <https://doi.org/10.1038/s41586-020-3035-9>
- Simonovich, V.A., L.D. Burgos Pratz, P. Scibona, M.V. Beruto, M.G. Vallone, C. Vázquez, N. Savoy, D.H. Giunta, L.G. Pérez, M.D.L. Sánchez, et al. PlasmAr Study Group. 2021. A Randomized Trial of Convalescent Plasma in Covid-19 Severe Pneumonia. *N. Engl. J. Med.* 384:619–629. <https://doi.org/10.1056/NEJMoa2031304>
- Troya, J., P. Bastard, L. Planas-Serra, P. Ryan, M. Ruiz, M. de Carranza, J. Torres, A. Martínez, L. Abel, J.L. Casanova, and A. Pujol. 2021. Neutralizing autoantibodies to type I IFNs in >10% of patients with severe COVID-19 pneumonia hospitalized in Madrid, Spain. *J. Clin. Immunol.* <https://doi.org/10.1007/s10875-021-01036-0>
- Wang, E.Y., T. Mao, J. Klein, Y. Dai, J.D. Huck, F. Liu, N.S. Zheng, T. Zhou, B. Israelow, P. Wong, et al. 2020. Diverse Functional Autoantibodies in Patients with COVID-19. *medRxiv* (Preprint posted February 1, 2021) <https://doi.org/10.1101/2020.12.10.20247205>
- Weinreich, D.M., S. Sivapalasingam, T. Norton, S. Ali, H. Gao, R. Bhore, B.J. Musser, Y. Soo, D. Rofail, J. Im, et al. Trial Investigators. 2021. REGN-COV2, a Neutralizing Antibody Cocktail, in Outpatients with Covid-19. *N. Engl. J. Med.* 384:238–251. <https://doi.org/10.1056/NEJMoa2035002>
- Pan, H., R. Peto, A.M. Henaó-Restrepo, M.P. Preziosi, V. Sathiyamoorthy, Q. Abdool Karim, M.M. Alejandria, C. Hernández García, M.P. Kieny, R. Malekzadeh, et al. WHO Solidarity Trial Consortium. 2021. Repurposed Antiviral Drugs for Covid-19 - Interim WHO Solidarity Trial Results. *N. Engl. J. Med.* 384:497–511. <https://doi.org/10.1056/NEJMoa2023184>
- Wijst, M.G.P.d., S.E. Vazquez, G.C. Hartoularos, P. Bastard, T. Grant, R. Bueno, D.S. Lee, J.R. Greenland, Y. Sun, R. Perez, et al. 2021. Longitudinal single-cell epitope and RNA-sequencing reveals the immunological impact of type I interferon autoantibodies in critical COVID-19. *bioRxiv.* (Preprint posted March 10, 2021) <https://doi.org/10.1101/2021.03.09.434529>
- Zhang, Q., P. Bastard, A. Bolze, E. Jouanguy, S.Y. Zhang, A. Cobat, L.D. Notarangelo, H.C. Su, L. Abel, and J.L. Casanova. COVID Human Genetic Effort. 2020a. Life-Threatening COVID-19: Defective Interferons Unleash Excessive Inflammation. *Med (N Y).* 1:14–20. <https://doi.org/10.1016/j.medj.2020.12.001>
- Zhang, Q., P. Bastard, Z. Liu, J. Le Pen, M. Moncada-Velez, J. Chen, M. Ogishi, I.K.D. Sabli, S. Hodeib, C. Korol, et al. NIAID-USUHS/TAGC COVID Immunity Group. 2020b. Inborn errors of type I IFN immunity in patients with life-threatening COVID-19. *Science.* 370:eabd4570. <https://doi.org/10.1126/science.abd4570>

Supplemental material

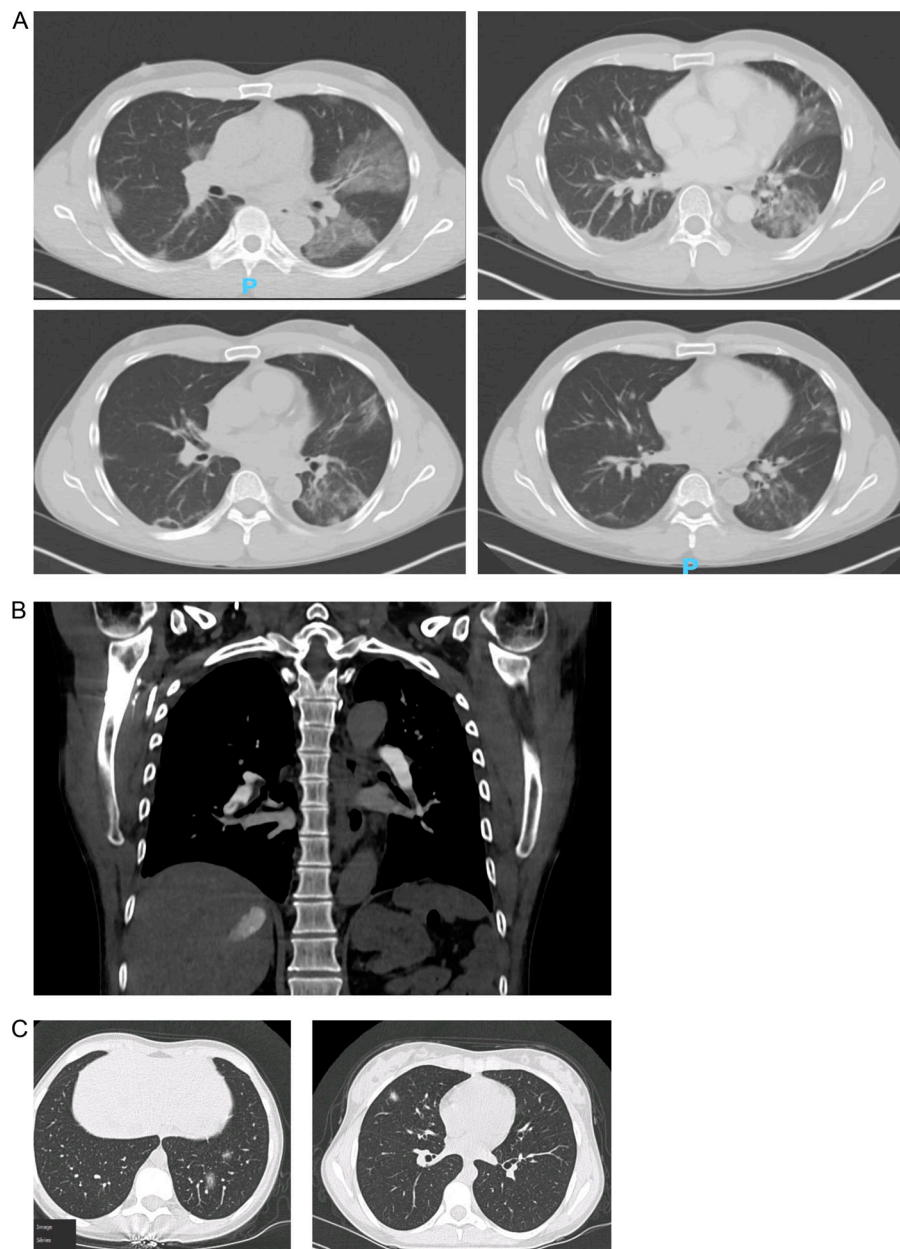


Figure S1. **Imaging of COVID-19 pneumonia in APS-1 patients. (A)** Course of COVID-19 pneumonia in an APS-1 patient. Bilateral (left to right) ground-glass opacities are seen on initial chest CT 6 d after symptom onset (left upper panel). Persistence of bilateral ground-glass opacities with a worsening of radiographical signs in the left lung base on day 10 after symptom onset (right upper panel). Improvement of ground-glass opacities on days 16 (left lower panel) and 37 (right lower panel) after symptom onset. **(B)** Coronal chest CT angiogram demonstrating nonocclusive segmental pulmonary embolus to the distal pulmonary arterial branches of the right lower lobe. **(C)** Chest CT scan of an APS-1 patient showing bilateral alveolo-interstitial lesions of COVID-19 pneumonia.

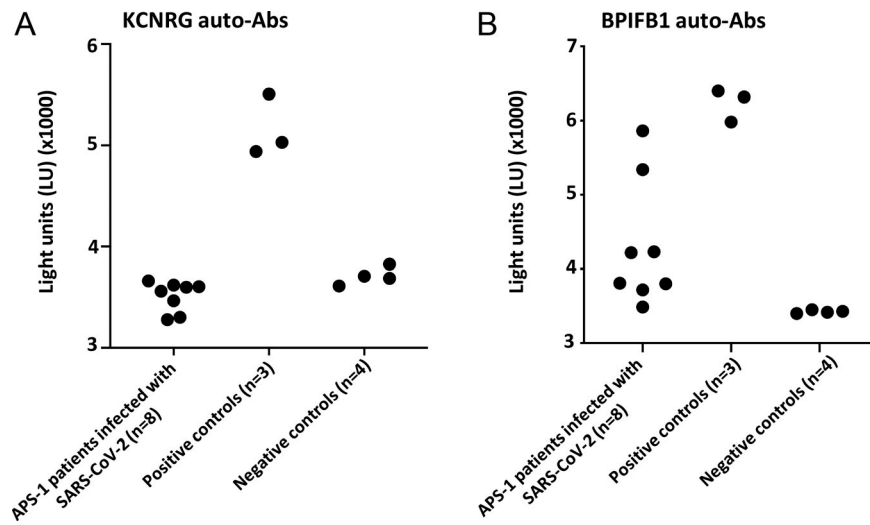


Figure S2. **Analysis of lung-targeting auto-Abs against KCNRG and BPIFB1 in APS-1 patients with COVID-19. (A and B)** Auto-Ab titers to KCNRG (A) and BPIFB1 (B) in APS-1 patients with COVID-19 ($n = 8$). Positive and negative control sample results are also shown.

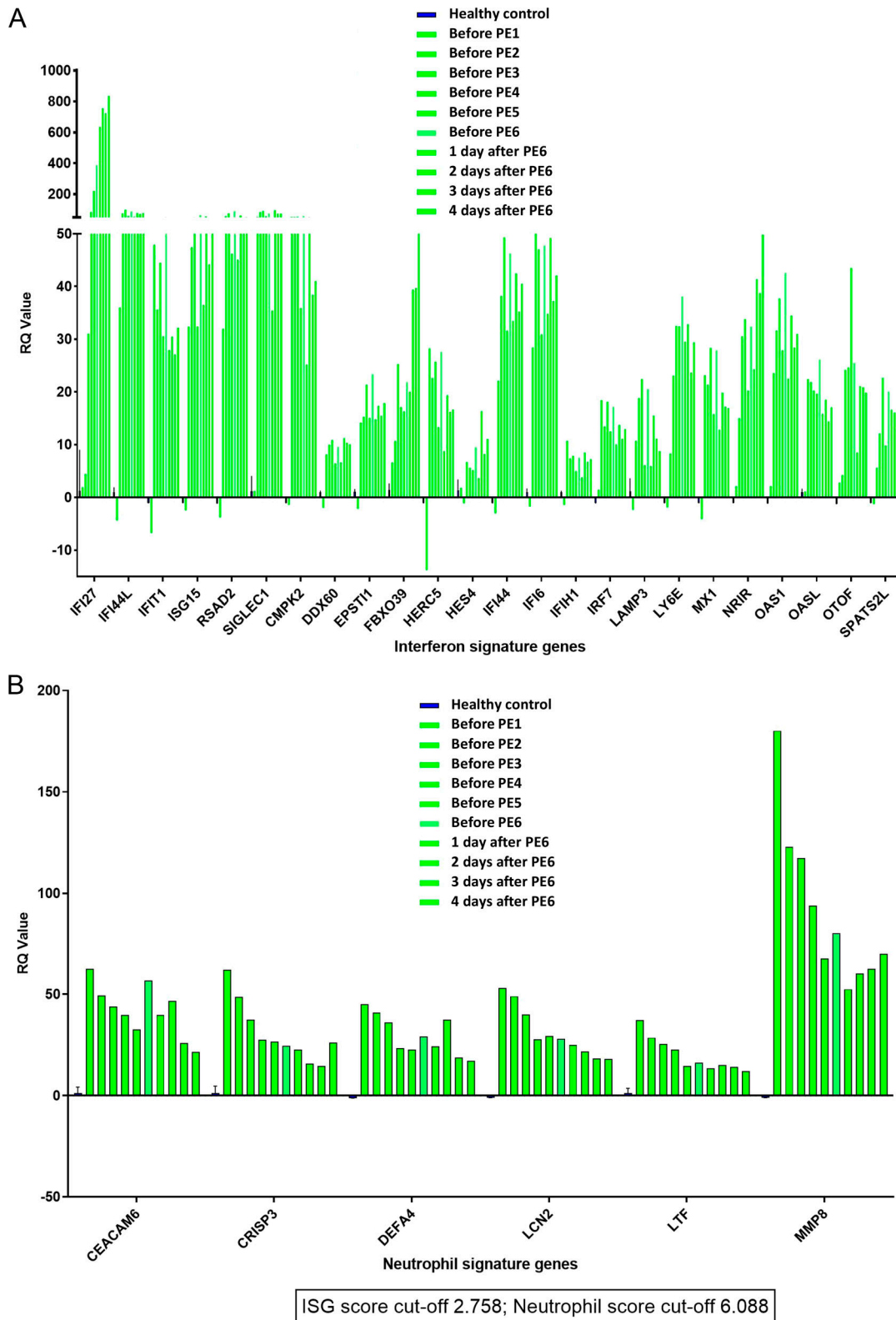


Figure S3. ISG score and neutrophil score at different time points in an APS-1 patient with severe COVID-19 treated with plasmapheresis, convalescent plasma, and IFN- β . (A and B) 24 ISGs are shown at each time point (A), and 6 neutrophil signature genes are shown (B). ISG score are higher during treatment, while the neutrophil score diminishes. PE, plasma exchange.

Table S1 is provided online as a separate Word file and lists the probes used for NanoString ISG analysis.