

# UC San Diego

## UC San Diego Previously Published Works

### Title

Retroperitoneal Hematoma After Femoral Arterial Catheterization

### Permalink

<https://escholarship.org/uc/item/5g00370w>

### Journal

Journal of Emergency Medicine, 49(3)

### ISSN

0736-4679

### Authors

Vilke, Gary M  
Kass, Peter

### Publication Date

2015-09-01

### DOI

10.1016/j.jemermed.2015.05.002

Peer reviewed



<http://dx.doi.org/10.1016/j.jemermed.2015.05.002>

## Visual Diagnosis in Emergency Medicine

### RETROPERITONEAL HEMATOMA AFTER FEMORAL ARTERIAL CATHETERIZATION

Gary M. Vilke, MD and Peter Kass, MS

Department of Emergency Medicine, University of California at San Diego Medical Center, San Diego, California

Reprint Address: Gary M. Vilke, MD, Department of Emergency Medicine, UC San Diego Medical Center, 200 West Arbor Drive Mailcode #8676, San Diego, CA 92103

#### CASE REPORT

A 74-year-old woman presented to the Emergency Department (ED) complaining of several hours of progressively worsening lower abdominal discomfort. The patient had been suffering ongoing pain since her right femoral cardiac catheterization 2 weeks earlier. She also reported the onset of dizziness, lightheadedness, and weakness at the time of presentation. The patient denied chest pain, shortness of breath, or syncope. Her initial vital signs were: temperature 34.1°C (93.4°F), blood pressure 86/69 mm Hg, heart rate 60 beats/min, respiratory rate 17 breaths/min, and SpO<sub>2</sub> 100%. Her examination was significant for diffuse abdominal tenderness, distension, and ecchymosis in the bilateral lower quadrants. An initial complete blood count was remarkable for a white blood cell count of 18.4 and a hemoglobin of 6.1. Computed tomography (CT) of the abdomen and pelvis with/without intravenous contrast demonstrated a large pelvic mass with contrast flow suggestive of active bleeding, which at the time, was of an unclear etiology (Figure 1). The patient was transfused in the ED, and vascular and interventional radiology were consulted. Ultimately, the hematoma was evacuated by interventional radiology and the patient was subsequently admitted to the vascular surgery team with the final diagnosis being an actively bleeding, right femoral pseudoaneurysm with a large, extraperitoneal, pelvic hematoma.

#### DISCUSSION

This patient presented with common findings of a retroperitoneal hematoma, a rare but often morbid complication of femoral arterial catheterizations. This complication has an incidence of approximately .5% and a mortality of 4–12% (1). The risk of developing a hematoma may depend on the type of catheterization performed. Placement of a coronary

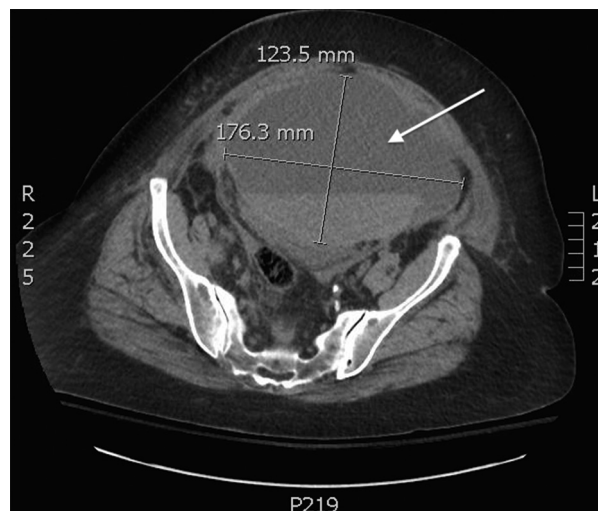


Figure 1. Arrow pointing to pelvic hematoma seen on axial slice from a computed tomography scan of abdomen and pelvis with intravenous contrast.

RECEIVED: 26 February 2015;

ACCEPTED: 14 May 2015

artery stent has been associated with the highest risk of hematoma development, whereas placement of a diagnostic catheterization or coronary atherectomy has been associated with the lowest risk (2). Risk factors for this complication include female gender, low body surface area, higher femoral puncture site, use of vasculature closure devices, chronic renal insufficiency, chronic obstructive pulmonary disease, and use of preprocedural anticoagulation (3–5). Although initially asymptomatic, the hematoma, once large enough, can cause cutaneous bruising, lower abdominal pain, back and flank pain, and lead to shock (6). These hematomas are often mistaken for adnexal masses in female patients and should be on the differential of any women presenting with a poorly defined adnexal mass after recent femoral artery catheterization (7). The nonspecific symptoms and often-delayed diagnosis of this condition can lead to serious complications including hypovolemic shock, abdominal compartment syndrome, and femoral neuropathy (8). Ultrasound and CT imaging are the most effective ways to make this diagnosis. Patients can be managed either conservatively with close monitoring, fluid resuscitation, cessation/reversal of anticoagulation, and blood transfusions as needed, or more aggressively with endovascular embolization or open repair (9). Open repair is generally reserved for patients who have failed more conservative treatment measures.

## REFERENCES

1. Tiroch KA, Arora N, Matheny ME, Liu C, Lee TC, Resnik FS. Risk predictors of retroperitoneal hemorrhage following percutaneous coronary intervention. *Am J Cardiol* 2008;102:1473–6.
2. Kent KC, Moscucci M, Mansour KA, et al. Retroperitoneal hematoma after cardiac catheterization: prevalence, risk factors, and optimal management. *J Vasc Surg* 1994;20:905–10.
3. Ellis S, Bhatt D, Kapadia S, Lee D, Yen M, Whitlow P. Correlates and outcomes of retroperitoneal hemorrhage complicating percutaneous coronary intervention. *Catheter Cardiovasc Interv* 2006;67:541–5.
4. Doyle BJ, Ting HH, Bell MR, et al. Major femoral bleeding complications after percutaneous coronary intervention: incidence, predictors, and impact on long term survival among 17,901 patients treated at the mayo clinic from 1994 to 2005. *JACC Cardiovasc Interv* 2008;1:202–9.
5. Trimarchi S, Smith D, Share D, et al. Retroperitoneal hematoma after percutaneous coronary intervention: prevalence, risk factors, management, outcomes, and predictors of mortality. *JACC Cardiovasc Interv* 2010;3:845–50.
6. Farouque HMO, Tremmel JA, Raissi Shabari F, et al. Risk factors for the development of retroperitoneal hematoma after percutaneous coronary intervention in the era of glycoprotein IIb/IIIa inhibitors and vascular closure devices. *J Am Coll Cardiol* 2005;45:363–8.
7. Davenport WB, Taylor DP, Davenport TC, Meeks GR. Retroperitoneal hematoma presenting as an adnexal mass after femoral catheterization. *Obstet Gynecol* 2010;116(Suppl 2):539–41.
8. Foley P. A retrospective study of the management of retroperitoneal bleeding after percutaneous coronary intervention in the era of combination anti-platelet therapy. *J Cardiovasc Med* 2008;9:56–8.
9. Chan YC, Morales JP, Reidy JF, Taylor PR. Management of spontaneous and iatrogenic retroperitoneal haemorrhage: conservative management, endovascular or open surgery? *Int J Clin Pract* 2008;62:1604–13.