

## **UC Irvine**

### **Western Journal of Emergency Medicine: Integrating Emergency Care with Population Health**

#### **Title**

Point-of-Care Ultrasound to Diagnose a Simple Ranula

#### **Permalink**

<https://escholarship.org/uc/item/5fq5397v>

#### **Journal**

Western Journal of Emergency Medicine: Integrating Emergency Care with Population Health, 17(6)

#### **ISSN**

1936-900X

#### **Authors**

Margalit, Ili  
Berant, Ron

#### **Publication Date**

2016

#### **DOI**

10.5811/westjem.2016.9.30890

#### **Supplemental Material**

<https://escholarship.org/uc/item/5fq5397v#supplemental>

#### **Copyright Information**

Copyright 2016 by the author(s). This work is made available under the terms of a Creative Commons Attribution License, available at <https://creativecommons.org/licenses/by/4.0/>

Peer reviewed

## Point-of-Care Ultrasound to Diagnose a Simple Ranula

Ili Margalit, MD  
Ron Berant, MD

Schneider Children's Medical Center of Israel, Department of Pediatric Emergency  
Medicine, Petah Tikva, Israel

Section Editor: Rick A. McPheeters, DO

Submission history: Submitted May 15, 2016; Revision received September 2, 2016; Accepted September 14, 2016

Electronically published November 2, 2016

Full text available through open access at [http://escholarship.org/uc/uciem\\_westjem](http://escholarship.org/uc/uciem_westjem)

DOI: 10.5811/westjem.2016.9.30890

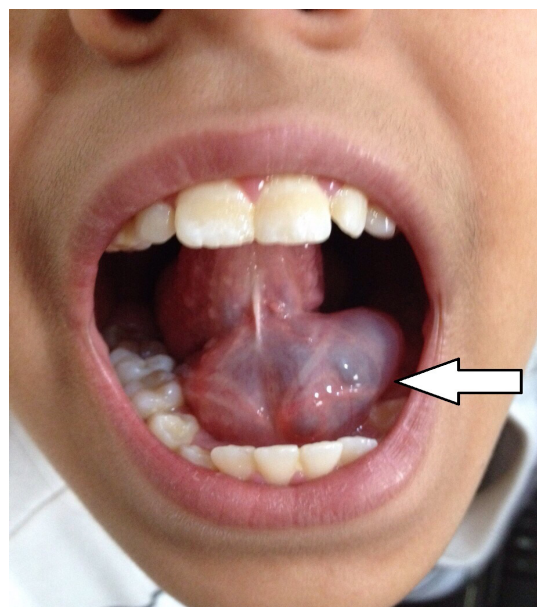
In the following vignette we demonstrate the use of point-of-care ultrasound to diagnose a simple ranula.  
[West J Emerg Med. 2016;17(6)827-8.]

### CASE

An 11-year-old previously healthy girl presented to the emergency department (ED) with three weeks of a rapidly progressive swelling underneath her tongue, causing difficulty in talking and eating. Physical examination revealed a 4.5 X 3 cm sublingual mass arising from the base of the tongue, around the midline (Figure 1). The mass was soft, movable and non-tender. The contents had a bluish hue, which was covered with normal appearing mucosa. A point-of-care ultrasound (POCUS) revealed a well-circumscribed homogenous cystic mass, separated from the muscular fibers of the tongue, without extravasation towards the neck (Figure 2) and without intra-cystic flow. A diagnosis of simple ranula was made.

### DISCUSSION

A ranula is a pseudocyst that is formed after oral trauma or inflammation, causing extravasation of mucous from the sublingual salivary gland or from the main salivary duct. A simple ranula is restricted to the oral cavity floor. A plunging ranula extravasates through the mylohyoid muscle, towards the cervical structures in the submandibular space.<sup>1</sup> The differential diagnosis includes dermoid and epidermoid cysts as well as rarer conditions.<sup>2</sup> Ultrasonography is a useful imaging method for the sublingual space, particularly for simple ranulas, as it is unaffected by dental amalgam and can locate the lesion.<sup>3</sup> Furthermore, ultrasonography has been suggested as a key component in the management of floor-of-the-mouth masses in children.<sup>4</sup> The now-accepted treatment of simple ranulas in pediatric patients consists of a six-month period of observation before considering other treatments.<sup>1</sup> In this case, a POCUS was consistent with the clinical diagnosis, reassured the parents and prevented an additional medical visit as the entire management took place in the ED. The follow-up visit at the otorhinolaryngology clinic was scheduled for a few months later; by that time the ranula had completely resolved.

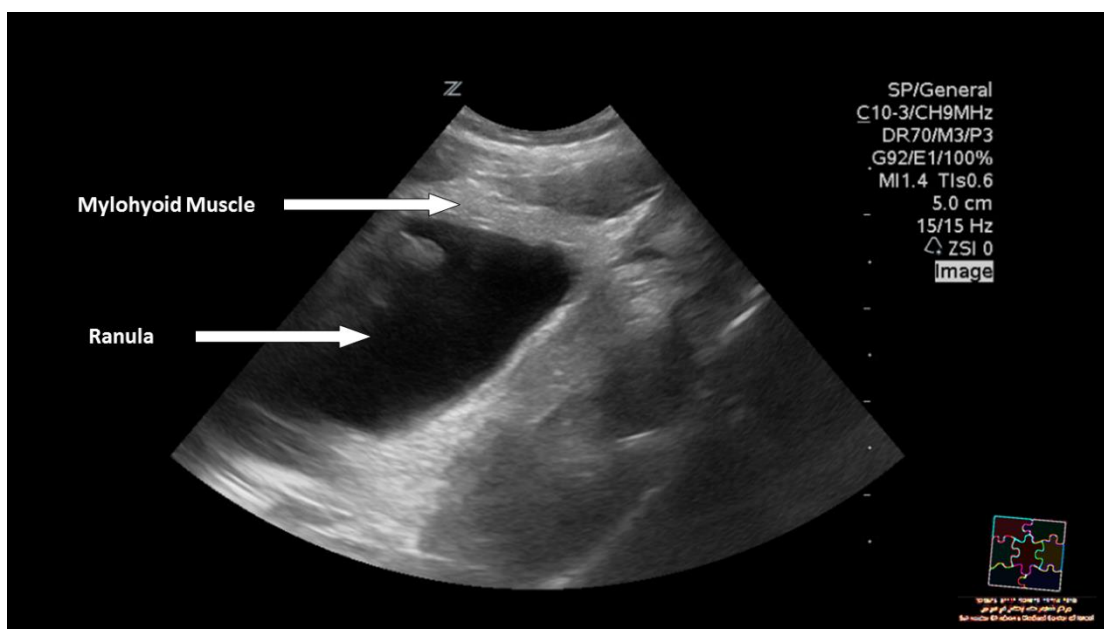


**Figure 1.** The sublingual mass, a simple ranula, seen on physical exam of a pediatric patient.

*Address for Correspondence:* Ron Berant, MD, Schneider Children's Medical Center of Israel, Department of Pediatric Emergency Medicine, 14 Kaplan St. Petah Tikva, 4920235 Israel. Email: ron.berant@gmail.com.

*Conflicts of Interest:* By the WestJEM article submission agreement, all authors are required to disclose all affiliations, funding sources and financial or management relationships that could be perceived as potential sources of bias. The authors disclosed none.

*Copyright:* © 2016 Berant et al. This is an open access article distributed in accordance with the terms of the Creative Commons Attribution (CC BY 4.0) License. See: <http://creativecommons.org/licenses/by/4.0/>



**Figure 2.** The ultrasonographic image, demonstrating the isolated ranula without extravasation through the mylohyoid muscle.

#### REFERENCES

1. Zhi K, Gao L, Ren W. What is new in management of pediatric ranula? *Curr Opin Otolaryngol Head Neck Surg.* 2014;22(6):525-9.
2. La'porte SJ, Juttla JK, Lingam RK. Imaging the floor of the mouth and the sublingual space. *Radiographics.* 31(5):1215-30.
3. Jain P. High-resolution sonography of sublingual space. *J Med Imaging Radiat Oncol.* 2008;52(2):101-8.
4. Schwanke TW, Oomen KPQ, April MM, et al. Floor of mouth masses in children: proposal of a new algorithm. *Int J Pediatr Otorhinolaryngol.* 2013;77(9):1489-94.