

# UC Irvine

## UC Irvine Previously Published Works

### Title

Angiographic optical coherence tomography imaging of hemangiomas and port wine birthmarks

### Permalink

<https://escholarship.org/uc/item/5f66s8p8>

### Journal

Lasers in Surgery and Medicine, 50(7)

### ISSN

0196-8092

### Authors

Waibel, Jill S  
Holmes, Jon  
Rudnick, Ashley  
[et al.](#)

### Publication Date

2018-09-01

### DOI

10.1002/lsm.22816

### Copyright Information

This work is made available under the terms of a Creative Commons Attribution License, available at <https://creativecommons.org/licenses/by/4.0/>

Peer reviewed

# Angiographic Optical Coherence Tomography Imaging of Hemangiomas and Port Wine Birthmarks

Jill S. Waibel,<sup>1\*</sup> Jon Holmes,<sup>2</sup> Ashley Rudnick,<sup>1</sup> Daniel Woods,<sup>2</sup> and Kristen M. Kelly<sup>3</sup>

<sup>1</sup>Miami Dermatology and Laser Institute, 7800 S.W 87th Ave Suite B200, Miami, Florida 33173

<sup>2</sup>Michelson Diagnostics Ltd., Eclipse House, Eclipse Park, Sittingbourne Road, Maidstone, Kent, United Kingdom

<sup>3</sup>Department of Dermatology, University of California, Irvine

**Objectives:** A current therapeutic challenge of vascular lesions is that they do not always respond effectively to laser treatment. Information on targeted vessels could potentially be used to guide laser treatments. Optical coherence tomography (OCT) is a useful tool for the non-invasive imaging of tissues, including skin hemangiomas and port wine birthmarks. Dynamic OCT is able to rapidly characterize cutaneous blood vessels. The primary goal of this study was to demonstrate the ability of bedside OCT to image (i) overall vessel pattern; (ii) individual vessel morphology, diameter and depth; and (iii) total vessel density as a function of depth in infantile hemangiomas and port wine birthmarks (PWB).

**Materials and Methods:** This IRB approved, observational clinical trial was performed among healthy volunteers ages 3 months–73 years old. All patients presented for laser treatment of either infantile hemangiomas or PWB with skin types ranging from Fitzpatrick I–V. OCT imaging of 49 hemangioma and PWB scans were performed pre- and post-treatment. The diameter and depth of the blood vessels making up the vascular lesions were measured. In addition, normal skin was scanned for comparison. Five datasets for infantile hemangiomas and five for PWB that were without motion artifacts were analyzed.

**Results:** Scanned lesions exhibited variable and highly heterogeneous blood vessel patterns with vessel diameters ranging from 20 to 160  $\mu\text{m}$ , suggesting that the laser treatment with single pulse durations may not be optimal. The largest blood vessel diameter observed (160  $\mu\text{m}$ ) may not be adequately treated by commonly used pulsed dye laser pulse durations.

**Conclusion:** OCT allowed rapid, non-invasive characterization of the diameter and depth of blood vessels in individual vascular lesions. Imaged lesions consisted of a heterogeneous population of vessel sizes, morphologies, and depth. Future studies could utilize this information to assist development of individualized treatment protocols in an effort to improve vascular birthmark removal. *Lasers Surg. Med.* 50:718–726, 2018. © 2018 Wiley Periodicals, Inc.

**Key words:** laser; optical coherence tomography; port wine birthmarks; capillary malformations; infantile hemangiomas; selective photothermolysis

## INTRODUCTION

Treating cutaneous vascular lesions was the first indication for the medical use of lasers. Early therapeutic use sought to remove vascular birthmarks, especially port wine birthmarks (PWB), on the skin of children [1].

PWB are congenital cutaneous capillary malformations composed of ecstatic vessels. PWB's have often previously been called Port Wine Stains. However, a relatively recent survey of patients [2] indicated that they preferred the terminology PWB, so this term will be used in this manuscript. PWBs may be resistant to laser therapy. Despite many studies showing efficacy of lasers for the treatment of PWB, less than 25% of lesions have complete clearing after multiple laser sessions [3]. Methods to improve the treatment effect need to be sought.

Infantile hemangiomas (IH) are benign vascular tumors that are made of progenitor stem cells and disorganized blood vessels [4]. Various options have been explored for the treatment of hemangiomas including pharmacologic, laser and surgical interventions. Several beta-blockers have been evaluated although propranolol is currently standard of care [5,6]. While treatment with beta blockers is a current standard of care, adjunctive laser treatment can provide benefit [7].

**Conflict of Interest Disclosures:** All authors have completed and submitted the ICMJE Form for Disclosure of Potential Conflicts of Interest and have disclosed the following: Jill S. Waibel: ASDS Cutting Edge Research Grant, Lumenis—Clinical Trial, Speaker, Advisory Board, Lutronic—Equipment, Clinical Trial, Advisory Board, Michelson Diagnostics—Equipment, Sciton—Clinical Trial, Speaker, Advisory Board, Sebacia—Clinical Trial, Advisory Board, Syneron/Candela—Clinical Trial, Speaker; Ashley Rudnick has no conflicts of interest disclosures; Jon Holmes: Michelson Diagnostics employee; Daniel Woods: Michelson Diagnostics employee; Kristen M. Kelly: Light Sciences Oncology—Researcher, Drug from Research, Novartis—Researcher, Drug from Research, Candela/Syneron—Researcher, Equipment, ThermiGen—Equipment, MundiPharma—Consultant, Allergan—Consultant, Research Grant.

\*Correspondence to: Jill S. Waibel, MD, Miami Dermatology and Laser Institute, 7800 S.W 87th Ave Suite B200, Miami, FL 33173. E-mail: jwaibelmd@miamidermlaser.com

Accepted 23 February 2018

Published online 22 March 2018 in Wiley Online Library (wileyonlinelibrary.com).

DOI 10.1002/lsm.22816

The goal of laser therapy for vascular birthmarks is to selectively target aberrant blood vessels present in these lesions. The goal of laser therapy is to induce endothelial cell apoptosis in the vessels that create the hemangioma. In order

to selectively destroy vessels, both vessel diameter and depth of lesion must be considered when determining laser settings.

Optical coherence tomography (OCT) is a non-invasive, high resolution imaging method, which can provide real-

**TABLE 1. The Table Demonstrates the Various Patient Ages and Locations of the Vascular Lesions (Hemangioma and PWB)**

Patient#	Age (years old)	Vascular lesion	Location of lesion
6	SI	Hemangioma	Left jaw
15	2	Hemangioma	Upper back
48	1	Hemangioma	Left buttock
55	11	Hemangioma	Right cheek
57	1	Hemangioma	Left cheek
67	15	Hemangioma	Right thigh
77	1	Hemangioma	Forehead
79	1	Hemangioma	Right cheek
90	0	PHACES - Hemangioma	Right ear
91	0	Ulcerating Hemangioma	Groin, left forearm
96	1	Hemangioma	Left temple, right periocular
100	1	hemangioma	left infraorbital
107	0	Hemangioma	Forehead
109	6	Hemangioma	Right shoulder
110	2	Hemangioma	Nose, right upper arm
123	63	Hemangioma	Right nose
124	0	hemangioma	Left flank
125	0	Hemangioma	Upper lip
111	0	Hemangioma	Left jawline
120	6	Hemangioma	Right neck
121	1	Hemangioma	Left cheek
7	40	PWB	Face
9	44	PWB	Left back of knee, left thigh
36	43	PWB	Left labia
37	28	PWB	Left jaw, nose
41	28	PWB	Right periocular, right cheek
42	16	PWB	Right periocular, right cheek
44	45	PWB	Left cheek, nose, left jaw, upper lip, left periocular
51	36	PWB	Left cheek, right temple, nose, right cheek
59	29	PWB	Right cheek
63	30	PWB	Chin
65	54	PWB	Right forearm
66	18	PWB	Left face
72	33	PWB	Right forearm, left forearm
73	25	PWB	Right abdomen, left abdomen
75	18	PWB	Left jaw
76	34	PWB	Left jaw
78	28	PWB	Right cheek
80	5	PWB	Right cheek, left cheek
81	9	PWB	Right cheek
89	59	PWB	Left cheek
94	49	PWB	Left lower leg
97	73	PWB	Right rear of neck, right upper arm, forehead, right temple
105	24	PWB	Left upper arm
106	23	PWB	Chin and neck
112	70	PWB	Right eye
113	5	PWB	lower face
117	38	PWB	Neck
122	3	PWB	Right arm

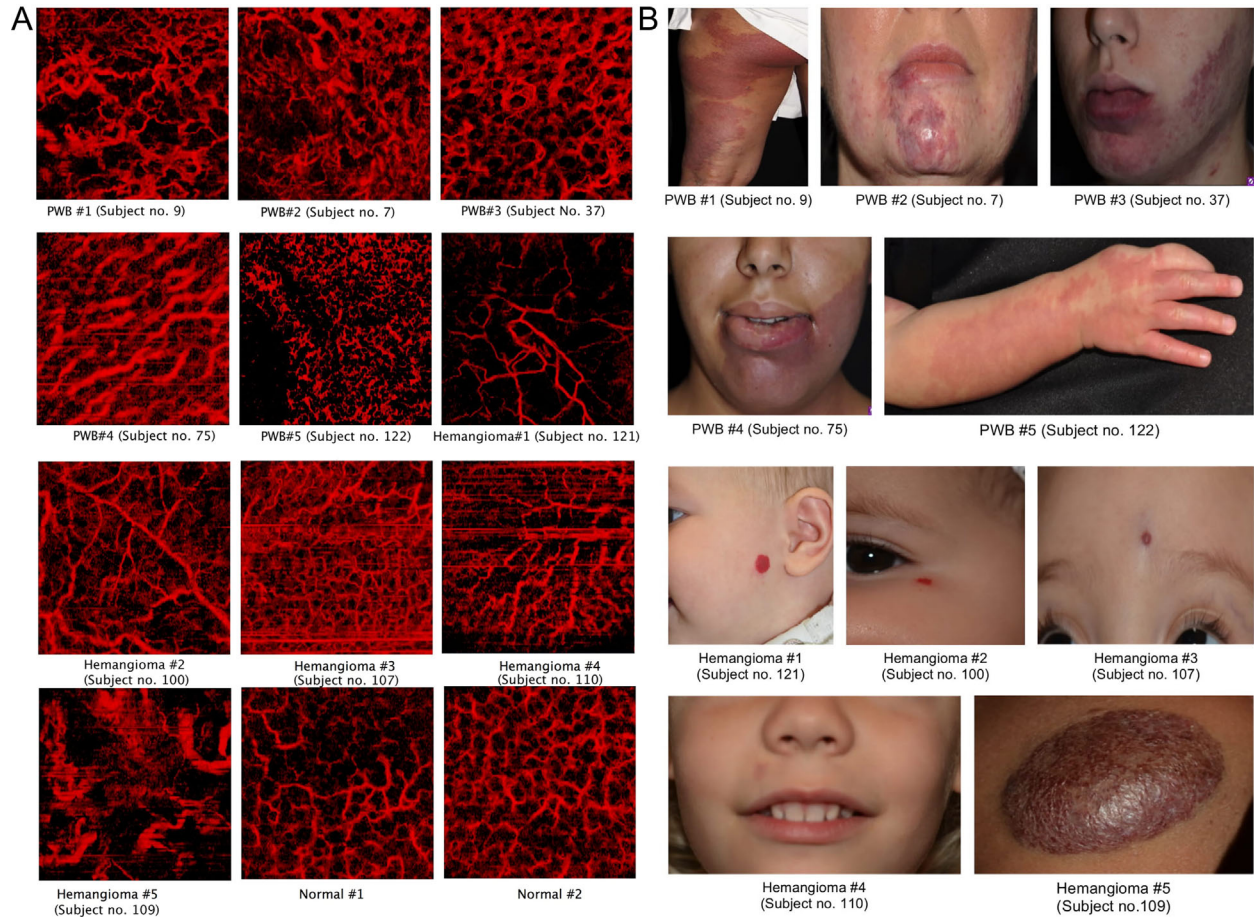


Fig. 1. (A) En-face dynamic OCT scans of five port wine birthmarks, five hemangiomas, and two from normal skin. (B) Clinical photographs of above OCT images of five PWB, five hemangiomas. Normal skin clinical photographs are not shown.

time information at the bedside. OCT was first described for retinal imaging [8] as early as 1991, but has since been applied to many other parts of the body including the skin [9,10]. OCT uses a tightly focused visible or near-infrared laser beam to interrogate the surface layers of tissue, and applies the principles of interferometry to

enable imaging to depths of 0.5–1.5 mm (depending on the tissue). Resolution is considerably higher than ultrasound, typically on the order of 10–20  $\mu\text{m}$  (in all axes) and OCT provides greater depth penetration than confocal microscopy. Conventional OCT images reveal the layered structure of epidermis, upper dermis, and skin appendages, and




Fig. 2. Raw image (left), thresholded frangi-filtered Image (middle), skeletonized image (right).

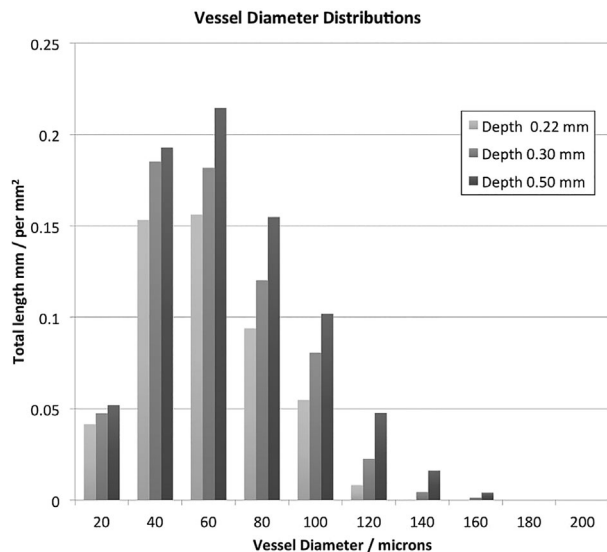


Fig. 3. Histograms of vessel diameters at three selected depths in hemangiomas. For example, from this data it is possible to estimate both the cross-sectional area and the volume of vessels of a particular diameter range and depth range that is to be treated by laser.

also the presence of blood vessels (as dark areas in the image due to the strong light absorption by water), but it is challenging to have high enough resolution to determine blood vessel characteristics. Attempts were also made to detect blood flow using Doppler-OCT [11], but the technique suffers from the fact that the blood flow direction is orthogonal to the Doppler sensing direction.

In 2010, FDA-cleared commercial OCT imaging systems were introduced (Vivosight, Michelson Diagnostic, UK) using multiple laser beams scanned simultaneously at multiple depths to push the resolution to  $7.5\ \mu\text{m}$  over a 6 mm scan width. These devices have been mainly studied in the context of non-invasive, non-melanoma skin cancer diagnosis, and margin mapping. Jemec and co-workers [12] first reported OCT imaging of telangiectasia with this method.

OCT imaging has been applied to evaluation of vascular birthmarks in the past, but results were limited due to technology. In 2001, Nelson et al. [13] were the first to demonstrate that Optical Doppler Tomography (ODT) could image blood vessels in PWB and proposed it as a method for laser therapy optimization. This study measured the vascular response post laser treatment, noting that at low light doses, PDL had only temporary effects on the vasculature of PWB and reperfusion occurred with resultant blood flow to pre-irradiation levels. It was theorized that higher light dosages may be more effective [13]. In 2010, Zhao and co-workers [14] used conventional OCT to scan 41 PWB patients and obtained an average vessel diameter of  $95 \pm 20\ \mu\text{m}$  and depth of  $360 \pm 50\ \mu\text{m}$ , and suggested that OCT measurements of vessel dimensions could be very meaningful for clinical treatment dosage. In 2013, the University of California Irvine group demonstrated a 3D Doppler OCT system with enface and projection images of a PWB on two patients and

reported that the vessel diameters and morphology varied with depth and between subjects [15]. In 2015, Latrive and co-workers [16] used Doppler OCT to image a PWB and a few infantile hemangiomas and reported some statistics on the observed vessel diameters, noting that the vessel diameters had a wide variation. They concluded that there was a significant difference between vascular characteristics of PWB and infantile hemangiomas.

OCT angiography, otherwise known as Dynamic OCT, has been used to apply statistical analysis of intensity variation to motion, such as that of blood cells, to determine the vessel pattern in the superficial dermal plexus and upper dermal capillaries [17]. The wider potential of OCT angiography in clinical dermatology has been described elsewhere [18,19], along with preliminary validation of the quantitative results [20]. OCT angiography offers a non-invasive tool to image and quantify blood vessels rapidly at the bedside and could be applied to routine clinical use. In this study, we used bedside OCT to image (i) overall vessel pattern; (ii) individual vessel morphology, diameter and depth; and (iii) total vessel density as a function of depth in infantile hemangiomas and port wine birthmarks (PWB).

## MATERIALS AND METHODS.

### Subject Population

Under IRB approval, a total of 49 subjects with infantile hemangiomas and PWB were enrolled in the study. Exclusion criteria were pregnancy, breastfeeding, use of oral retinoids 6 months prior to treatment, active infection, or lesions suspicious for malignancy.

This is a prospective, single-arm, pilot study conducted to study the morphology, depth, and diameters of blood vessels in infantile hemangiomas and PWB. Written informed consent was obtained from each patient. Patient had OCT scans performed pre- and post-treatment with the PDL (Vbeam Perfecta, Candela/Syneron, Wayland, MA, 7–10 mm spot size; 7.0–9.5 J/cm<sup>2</sup>, 1.5–10 ms, 30/20–20/10 cooling). The research coordinator reviewed laser schedules and indiscriminately assigned the physician to scan a portion of our new infantile hemangioma and PWB patients to receive OCT and subsequent laser treatment over a six-month period.

### OCT Procedure

Prior to laser treatment, OCT scans were captured from the lesion site using the OCT probe (Vivosight, Michelson Diagnostics, Maidstone, UK). OCT captured 120 vertical scans, across a  $6 \times 6\ \text{mm}$  area of skin. Image pixel size was  $4\ \mu\text{m}$ ; imaging depth was 0.7–1.5 mm. OCT angiography was used to detect blood vessel structure. The “en-face” imaging mode was utilized to visualize the blood vessel plexus from above enabling an initial assessment of the vessel morphology and structure.

The dataset was filtered to remove all pixels with intensity below a threshold chosen to remove background noise (all pixels below 30% of maximum were removed). The dataset was processed with a filter (Frangi and co-workers) implemented in MatLab (MathWorks, Cambridge, UK),

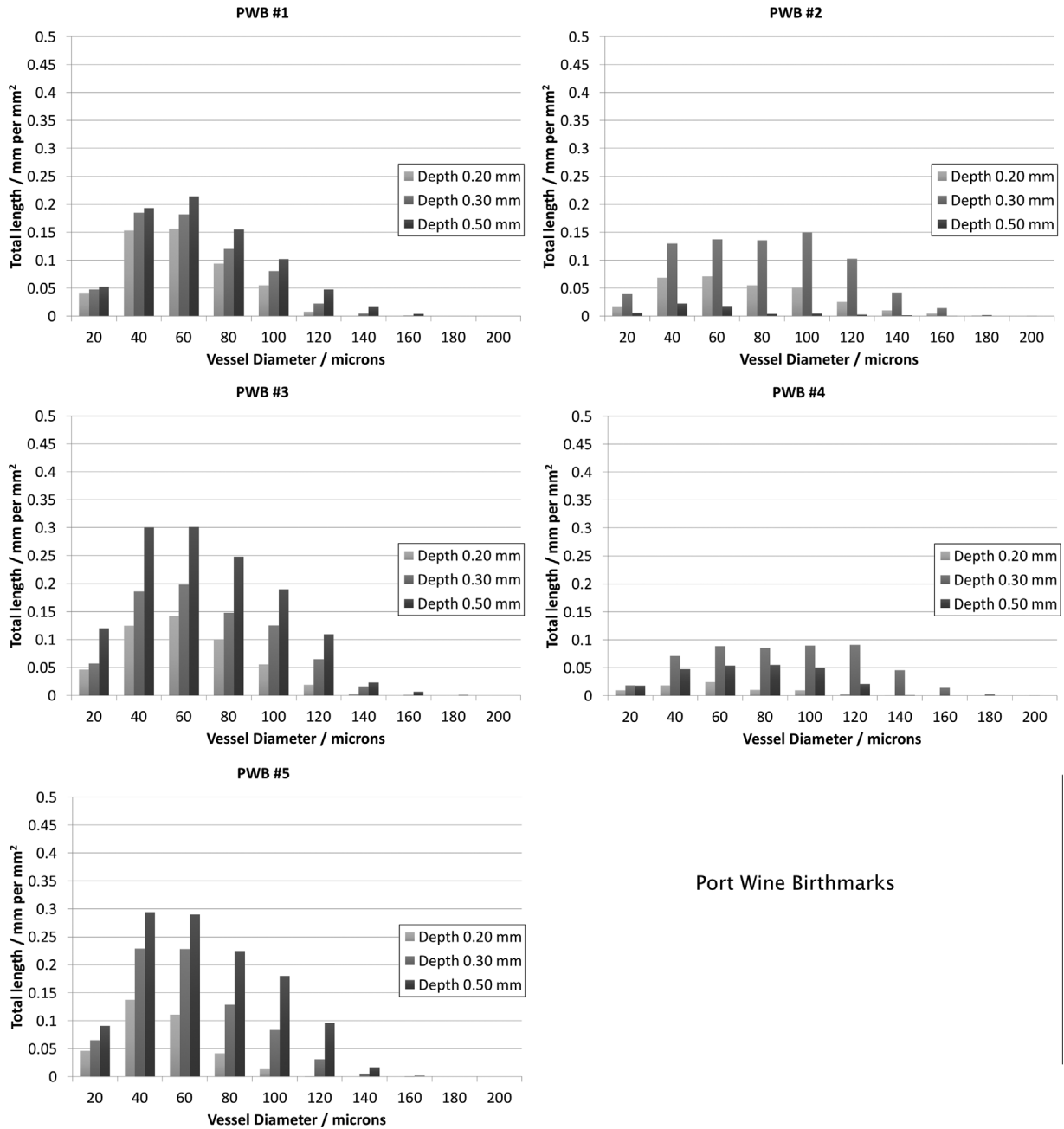
which enhances and extracts vessel-shaped features in a 3D dataset. Results were then skeletonized to extract the vessel network structure. Vessel diameters and depths were extracted for all vessel segments in the resulting vessel “skeleton” to a maximum depth of 0.5 mm (at greater depths the background noise signal is too high for the Frangi filter to effectively discriminate vessel features).

The resulting datasets were amenable to statistical analysis. The total length of vessel segments per square millimeter of tissue was extracted, for each range of vessel diameters and depths. With our method, the total lengths of vessels of a given

diameter at a given depth, it is possible to calculate both the cross-sectional area and the volume of vessels presented to an incident laser pulse. The median, upper and lower quartiles, and upper and lower decile vessel diameters were determined to inform the distribution of vessel diameters at each depth range, in 100 μm steps and overall.

**RESULTS**

Forty-nine subjects (21 hemangioma subjects and 28 PWB subjects) were imaged with OCT. Patient ages ranged from 3 months to 73 years old (Table 1). Table 1 demonstrates the



Port Wine Birthmarks

Fig. 4. Histograms of length of vessel in each square mm of tissue at selected depths of 0.15, 0.30, and 0.50 mm for the five PWB shown in Figure 1A.

diversity of age for hemangiomas and PWB along with the variety of locations these lesions are located.

The OCT images revealed that the blood vessel patterns in vascular lesions appeared dramatically different from that seen in normal skin (Fig. 1A). Figure 1A also shows two image of normal cheek skin (not area of vascular lesion) at bottom right for comparison. The red color denotes image pixels in which high dynamic signal intensity was detected, indicating motion due to blood

flow. Figure 1B shows the clinical photo of the Figure 1A OCT scanned patients. Figure 2 demonstrates the steps in processing; the raw image of the scan along with a Frangi-filtered image and skeletonized image.

Some datasets exhibited artifacts due to motion of the probe or patient during the scan, which was found to be a problem particularly for very young children. For this analysis we focused on five datasets for infantile hemangiomas and five for PWB without motion artifacts.

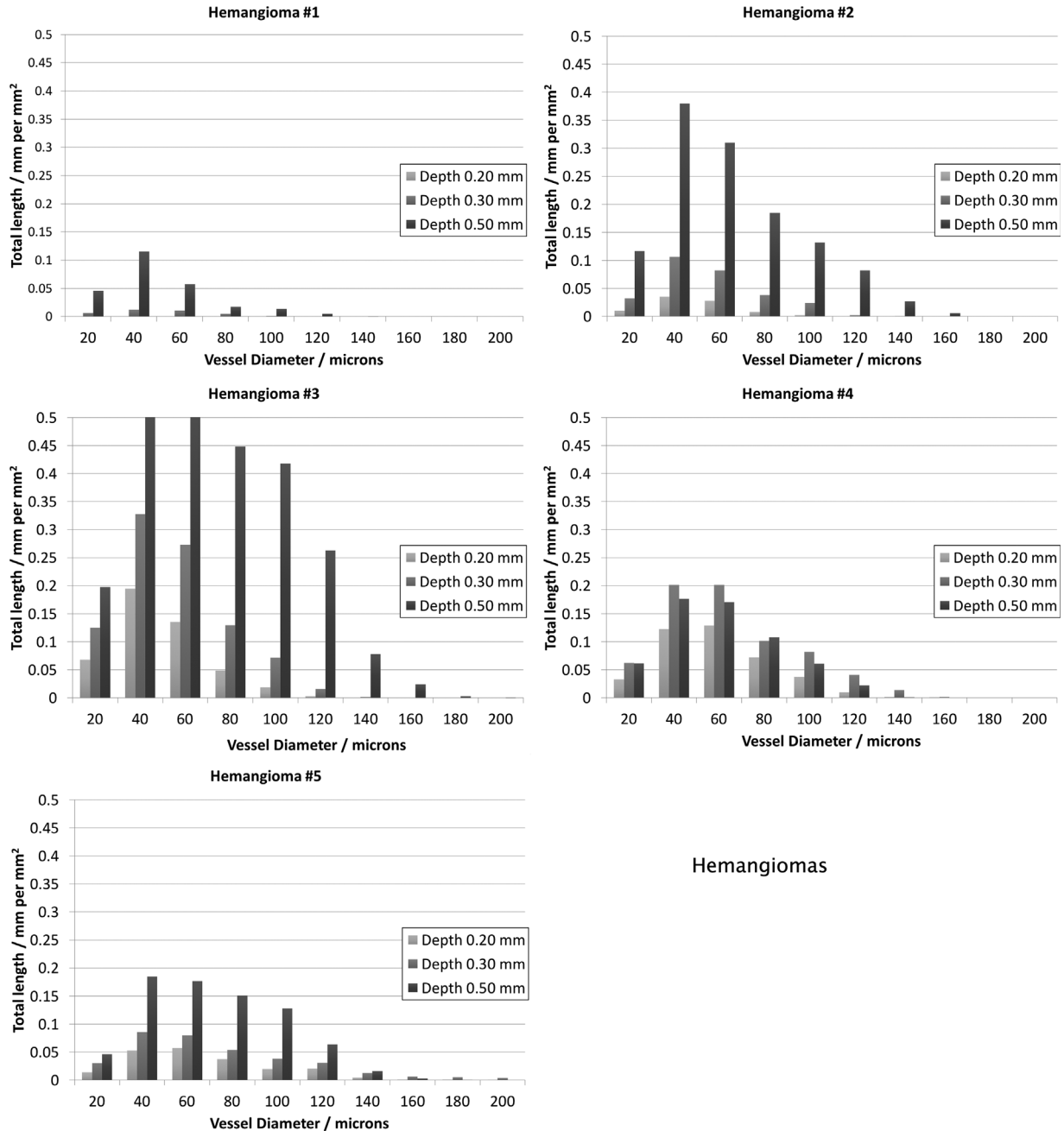


Fig. 5. Histograms of length of vessel in each square mm of tissue at selected depths of 0.15, 0.30, and 0.50 mm for the five hemangiomas shown in Figure 1A.

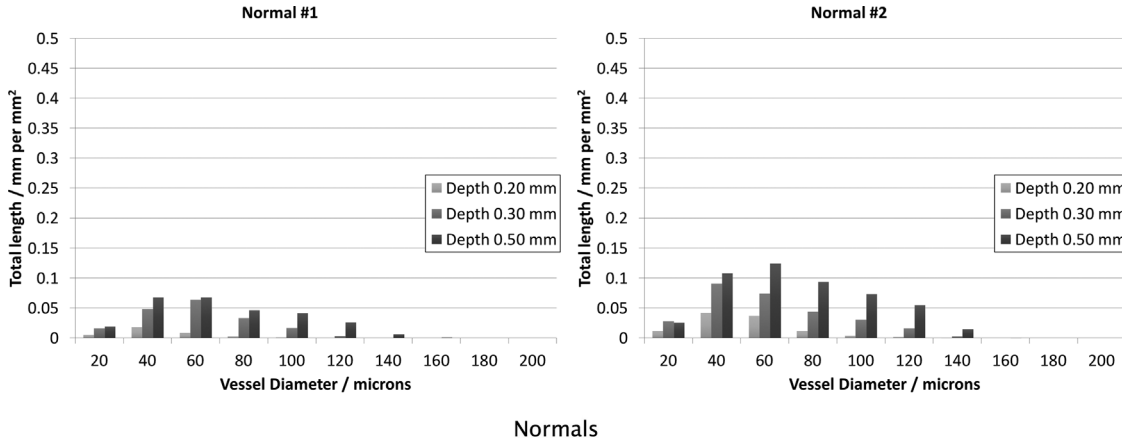


Fig. 6. Histograms of length of vessel in each square millimeter of tissue at selected depths of 0.15, 0.30, and 0.50 mm for the two normal scans shown in Figure 1A.

In both infantile hemangiomas and PWB, blood vessel diameters ranged from 20 to 160  $\mu\text{m}$  (Figs. 3–5). An example of the statistical analysis is shown in Figure 3, which is from the scan of a PWB. It shows that detected vessels ranged in diameter from 20 to 160  $\mu\text{m}$ , and that the quantity of vessels of all diameters was slightly higher at 0.30 mm depth than at 0.22 mm, and slightly higher still at 0.50 mm but the largest vessels in the range 120–160  $\mu\text{m}$  diameter were mainly at 0.50 mm depth. The most common vessel diameter was 60  $\mu\text{m}$ ; at 0.50 mm (for example), the total length of vessel segments with this diameter was found to be just over 0.2 mm for each square millimeter of tissue. We used this method of quantifying vascular density because we feel it is more useful than simply providing a count of the number of vessels detected. Scans at depths greater than 0.50 mm were not analyzed with this method because the noise present at greater depths interfered caused problems for the Frangi filter detecting vessel-like features. The histograms show a heterogeneous

variation in vessel diameters in all types of lesions, but also wide variations from lesion to lesion (Fig. 6). PWB tended to have larger vessel diameters than hemangiomas but not necessarily higher density. Nevertheless, because the vessels are larger in diameter, the total blood vessel volume is likely higher for PWB (Fig. 7).

Figures 8 and 9 are contour plots of the vessel distribution for both hemangiomas and PWB as a function of diameter and depth; the z-direction representing total vessel length per square millimeter of tissue. Comparing Figure 8 with Figure 9, we see that for this small sample of lesions, PWB tended to have larger diameter vessels at shallow depths and that hemangiomas exhibited higher vessel density as depth increased.

Summarizing the above data sets we note a trend that hemangiomas have significant variation in the diameter of the vessels that comprise the lesions. The median diameter of hemangioma in our data set were 50–70  $\mu\text{m}$ . It was also noted there is a wide variation in overall

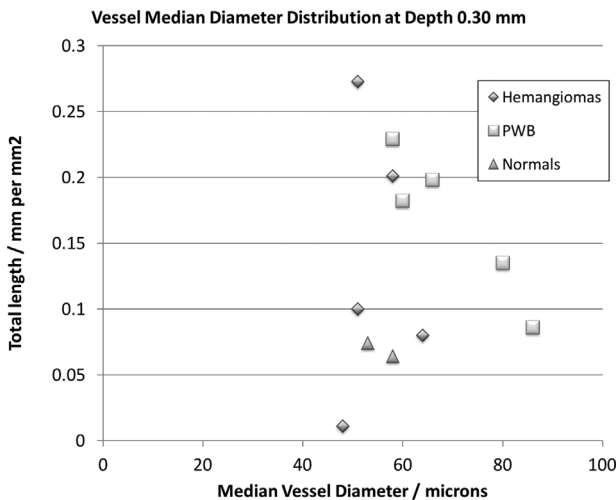


Fig. 7. X–Y scatter plot of the distribution of vessels by median vessel diameter.

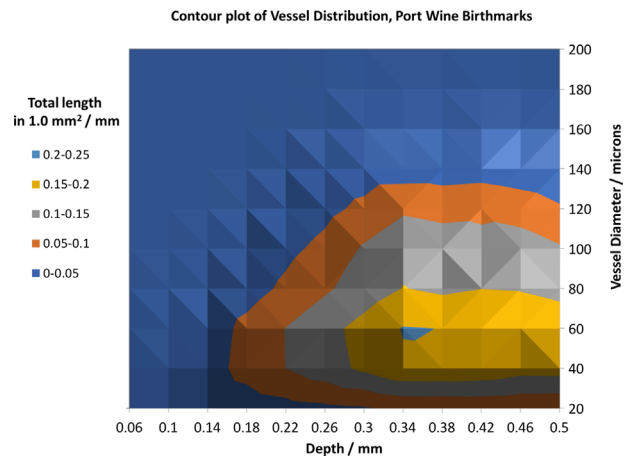


Fig. 8. Contour plot of total vessel length at each diameter and depth, for five PWB in Figure 1A.



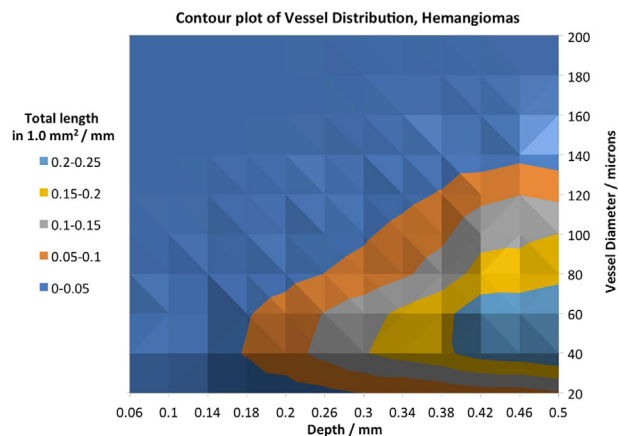


Fig. 9. Contour plot of total vessel length at each diameter and depth, for five Hemangiomas in Figure 1A.

vessel density with hemangiomas. The hemangioma blood vessel densities increase with depth (Figures 8 and 9). The port wine birthmarks trends showed they were greater in diameter than the hemangiomas with the median diameter 70–100  $\mu\text{m}$ . In addition the port wine birthmarks were thicker and had more total volume than the hemangiomas (Fig. 7).

## DISCUSSION

OCT is an imaging tool, which can be applied for assessment of skin vascular lesions *in vivo* and in real time in a non-invasive bedside imaging procedure. This procedure is easily done and taught in clinical practice. A limitation is that the existing OCT technology does not allow statistical analysis of vessels deeper than 0.5 mm, but this may improve in the future as the technology develops.

In this study, we demonstrated blood vessel diameters range from 20 to 160  $\mu\text{m}$ . There was a heterogeneous population of both small and larger blood vessels in both infantile hemangiomas and PWB. Vascular OCT may be used to give us information to individualize laser settings. Furthermore, comparing the statistics of vessel diameters and OCT images of the lesions with the clinical photographs, it is clear that the visible appearance of a PWB or hemangioma is a complex function of vessel diameter, density, and depth that requires further study. For example PWB#4 has relatively few vessels, but they are large diameter and occur at shallow depths, whereas PWB #1 has many more vessels but they are mostly much smaller diameter and tend to be deeper, yet both lesions appear clinically similar. OCT provides a powerful tool for further research into vascular lesion structure and how they present clinically.

In 1983, Anderson and Parrish [21] established the concept of the ‘Thermal Relaxation Time’ (TRT) for blood vessels. They explained how pulses with shorter duration than the TRT of a vessel result in the heating effect of the laser pulse to be confined to the vessel, limiting the collateral damage to the surrounding tissue. The TRT is related to the square of the vessel diameter. Our results

indicate the complex nature of vessel diameter and depth distribution in hemangiomas and PWB. Currently clinicians do not know the vessel characteristics of lesions they are treating. We speculate that more complex treatment protocols are required, tailored to individual vessel diameters and depths in a lesion, which can be observed using OCT. Optimized protocols may require utilization of multiple pulse durations, in the same or in multiple sessions. It might be efficacious to start with longer pulses with pulse durations set for the largest vessels and fluence for purpura. Once the largest vessels have been destroyed, then the lesion can be re-imaged and TRT set for the next size down that are still viable. Performing multiple passes, will require the physician to carefully monitor epidermal health to avoid damage to the skin surface that could result in scarring or permanent discoloration. Based on the trends seen with our OCT images the actual diameters of the blood vessels appear larger than expected with a median blood vessel diameters ranging from 50 to 100  $\mu\text{m}$ , suggesting that longer pulse durations than conventionally used may be more effective especially for the PWB. Additional OCT data with larger number of patients is needed to further evaluate these blood vessels diameters.

## CONCLUSION

OCT allowed rapid, non-invasive characterization of the diameter and depth of blood vessels in individual vascular lesions. Imaged lesions consisted of a heterogeneous population of vessel sizes, morphologies, and depth. Future studies could utilize this information to assist development of individualized treatment protocols in an effort to improve vascular birthmark removal.

OCT gives us a tool to rapidly and non-invasively characterize the diameter and depth of blood vessels in individual vascular lesions. We demonstrated the vascular lesion consist of a heterogeneous population of vessel sizes, morphologies, and depth distributions. Use of this information has great potential to evaluate and individualize treatment protocols and ultimately, may improve treatment of vascular birthmarks.

## ACKNOWLEDGMENTS

Michelson Diagnostics has loaned equipment for the clinical trial.

## REFERENCES

- Admani S, Krakowski A, Nelson J, Eichenfield L, Friedlander S. Beneficial effects of early pulsed dye laser therapy in individuals with infantile hemangiomas. *Dermatol Surg* 2012;38:1732–1738.
- Hagen L, Grey KR, Korta DZ, Kelly KM. Quality of life in adults with facial port-wine stains. *J Am Acad Dermatol* 2017;76(4):695–702.
- Geronemus RG, Ashinoff R. The medical necessity of evaluation and treatment of port-wine stains. *J Dermatol Surg Oncol* 1991;17(1):76–79.
- Leaute-Lebreze C, Harper JI, Hoeger PH. Infantile hemangioma. *Lancet* 2017;390(10089):85–94.
- Chen L, Tsai TF. The role of  $\beta$ -blockers in dermatological treatment: A review. *J Eur Acad Dermatol Venereol* 2017; DOI: 10.1111/jdv.14566. Epub ahead of print.

6. Bayart CB, Brandling-Bennett HA. Beta-blockers for childhood vascular tumors. *Curr Opin Pediatr* 2015;27(4):454–459.
7. Brightman L, Geronemus R, Reddy K. Laser treatment of port wine stains. *Clin Cosmet Investig Dermatol* 2015;8:27–33.
8. Huang D, Swanson A, Lin P, et al. Optical coherence tomography. *Science* 1991;254(5035):1178–1181.
9. Welzel J, Lankenau E, Birngurber R, Engelhardt R. Optical coherence tomography of the human skin. *J Am Acad Dermatol* 1997;37(6):958–963.
10. Holmes J, Welzel J. OCT in dermatology. In: Drexler W, Fujimoto J, editors. *Optical Coherence Tomography*. Cham: Springer; 2015. pp 2189–2207.
11. Zhao Y, Chen Z, Saxer C, Xiang S, de Boer JF, Nelson JS. Phase-resolved optical coherence tomography and optical Doppler tomography for imaging blood flow in human skin with fast scanning speed and high velocity sensitivity. *Optics Lett* 2000;25(2):114–116.
12. Ring HC, Mogenson M, Banzhaf C, Themstrup L, Jemec JB. Optical coherence tomography imaging of telangectasias during intense pulsed light treatment: A potential tool for rapid outcome assessment. *Arch Dermatol Res* 2013;305(4):299–303.
13. Nelson JS, Kelly KM, Zhao Y, Chen Z. Imaging blood flow in human port-wine stain *in situ* and in real time using optical Doppler tomography. *Arch Dermatol* 2001;137(6):741–744.
14. Zhao S, Gu Y, Xue P, et al. Imaging port wine stains by fiber optical coherence tomography. *J Biomed Opt* 2010;15(3):036020.
15. Liu G, Jia W, Nelson JS, Chen Z. In vivo, high-resolution, three-dimensional imaging of port wine stain microvasculature in human skin. *Lasers Surg Med* 2013;45(10):628–632.
16. Latrive A, Teixeira LR, Gomes AS, Zezell DM. Characterization of skin port-wine stain and hemangioma vascular lesions using Doppler OCT. *Skin Res Technol* 2016;22(2):223–229.
17. Mariampillai A, Standish BA, Moriyama EH, et al. Speckle variance detection of microvasculature using swept-source optical coherence tomography. *Opt Lett* 2008;33(13):1530–1532.
18. Ulrich M, Themstrup L, de Carvalho N, et al. Dynamic optical coherence tomography of skin blood vessels—Proposed terminology and practical guidelines. *J Eur Acad Dermatol Venereol* 2018;32(1):152–155.
19. Markowitz O, Schwartz M, Minhas S, Siegel DM. Speckle-variance optical coherence tomography: A novel approach to skin cancer characterization using vascular pattern. *Dermatology Online J* 2016;22(4):13030/qt7w10290r.
20. Themstrup L, Ciardo S, Manfredi M, et al. In vivo, micro-morphological vascular changes induced by topical brimonidine studied by dynamic optical coherence tomography. *J Eur Acad Dermatol Venereol* 2016;30(6):974–979.
21. Anderson RR, Parrish JA. Selective photothermolysis: Precise microsurgery by selective absorption of pulsed radiation. *Science* 1983;220(4596):524–527.