

# UC Davis

## UC Davis Previously Published Works

### Title

Photographic Standards for the Massive Weight Loss Patient

### Permalink

<https://escholarship.org/uc/item/5dx6m491>

### Journal

Annals of Plastic Surgery, 73(&NA;)

### ISSN

0148-7043

### Authors

Wong, Michael S  
Vinyard, William J

### Publication Date

2014-09-01

### DOI

10.1097/sap.0000000000000249

Peer reviewed

# Photographic Standards for the Massive Weight Loss Patient

Michael S. Wong, MD, and William J. Vinyard, MD

**Background:** Photographic standards issued by the Plastic Surgery Educational Foundation ensure accurate comparisons between preoperative and postoperative imaging. These standards, however, do not properly display the circumferential body ptosis seen in massive weight loss (MWL) patients. Photographic standardization for massive weight loss patients is needed for patient consultation, surgical planning, and accurate analysis and comparison of postoperative results.

**Patients and Methods:** A 10-year review of the photographic standards used for MWL patients at the University of California Davis Medical Center were reviewed and compared to current photographic standards in plastic surgery and clinical photo documentation seen in the literature for body contouring after MWL. Evaluation of arm position in obscuring the evaluation of circumferential ptosis in the upper and lower body was performed.

**Results:** Current photographic standards in plastic surgery do not capture the circumferential ptosis often seen in MWL patients, and there are no consistent modifications or standards recommended for MWL patients. Arm position was noted to affect shadowing and obstruction as well as distortion of circumferential excess. During the first 5 years reviewed, initial consultations included 8 images captured at 45-degree increments with the arms abducted to 90 degrees to document the circumferential excess from shoulders to the knees (Total Body, Fig. 1). They also included 8 images focused on the lower body (Fig. 2) and 8 images focused on the upper body. This required a total of 24 images captured per consultation. During the latter 5 years reviewed, the 8 Total Body images continued to be captured whereas the 16 images focusing on the upper and lower body have been discarded and replaced with 10 images (Fig. 3), captured from shoulders to knees at 45-degree increments with arms positioned behind the back (5) and in the lap (5) for a total of 18 images captured per consultation.

**Conclusion:** Currently there are no photographic standards for MWL patients that accurately capture their circumferential ptosis. All arm positions affect the evaluation of the circumferential excess to some degree, thus any choice of arm position represents a compromise between visibility and distortion of anatomy. Having considered these issues, we recommend the use of 360-degree clinical photo documentation obtained at 45-degree increments with arms abducted to 90 degrees to capture the total body. We have discarded focused upper and lower body images as these are visible in the Total Body images, thus decreasing patient fatigue and discomfort from excessive pictures. As techniques in post-bariatric body contouring have improved, we now routinely compare our results to non-post-bariatric body contouring patients and thus have added more standard arm positioning to facilitate these comparisons.

**Key Words:** photographic standards, massive weight loss, post-bariatric

(*Ann Plast Surg* 2014;73: S82–S87)

## BACKGROUND

Photographic Standards in Plastic Surgery<sup>1</sup> were disseminated in 1991 by the American Society of Plastic Surgeons (ASPS) and the Plastic Surgery Educational Foundation to facilitate more accurate comparisons between preoperative and postoperative imaging. These standards have been accepted by most plastic surgeons as the gold standard to follow when creating photographic documentation. This information helps plastic surgeons capture consistent pre- and postoperative images. With consistent photographic documentation, surgeons can compare their results with those of their colleagues.

After this time, there was a significant increase in bariatric surgery procedures performed. In the 1990s, there were fewer than 20,000 procedures being performed each year. This increased exponentially, peaking at nearly 120,000 procedures being performed in 2004.<sup>2</sup> With this, a new population of plastic surgery patients was born resulting from the significant deflation seen after significant weight loss. This has contributed to the dramatic increases in the number of surgical procedures over the past 15 years. Abdominoplasties increased nearly 340% and mastopexies increased nearly 540% in the United States as reported by the American Society for Aesthetic Plastic Surgery, 1997 versus 2011 data.<sup>3</sup> Circumferential lower body lifts have seen similarly dramatic increases with a 278% increase from 2000 (3,362)<sup>4</sup> to 2004 (15,094).<sup>5</sup>

The current photographic standards limit the framing to specific anatomic regions and ignore the circumferential changes commonly occurring after significant weight loss.<sup>1</sup> Using these standards to image our massive weight loss (MWL) patients, we would need to obtain 22 images to capture all the areas most commonly affected after significant weight loss; 5 images of the breast, 5 images of the abdomen, 8 images of the hips and thighs, and 4 images of the arms. Even after taking all of these photographs, the circumferential contour changes are ignored in the upper torso. The upper body posterior and posterior oblique views are excluded. We have found the current photographic standards, when applied to the MWL patient, requires an excessive number of photographs to be taken, potentially causing patient discomfort and increases consultation times. Moreover, important information regarding the circumferential nature of the patient's contour changes are often lost or obscured. Plastic surgeons have modified the current photographic standards in an attempt to capture these deformities. However, the various modifications have led to difficulty in making photographic comparisons between surgeons. The purpose of our study is to review our experience in imaging the MWL patient and suggest standard photographic views to capture the circumferential deformities often seen in patients after significant weight loss, and facilitate surgical planning and assessment of surgical results in both MWL and non-MWL patients.

## PATIENTS AND METHODS

A standard MWL patient was used to assess the affect of arm position in obscuring the evaluation of circumferential ptosis in the upper and lower body and distortion of anatomy. These pictures were obtained by a professional medical photographer using a digital photography studio consisting of a digital SLR camera with a fixed 100-mm lens positioned on a tripod, 2 synchronized stand-alone umbrella flashes, and a neutral background. Arm positions noted in publications of post-bariatric body contouring patients<sup>6–13</sup> were assessed in 360-degree fashion. These arm positions ranged from

Received March 14, 2014, and accepted for publication, after revision, April 1, 2014.

From the Department of Surgery, Division of Plastic Surgery, University of California Davis Medical Center, Sacramento, CA.

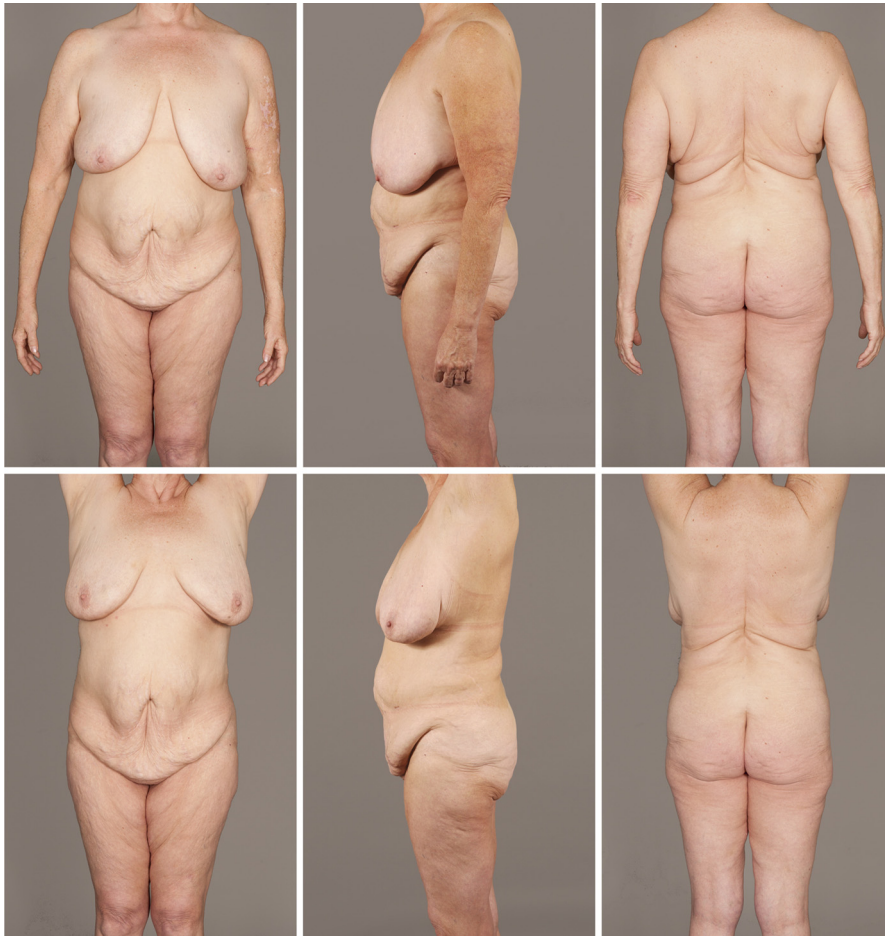Conflicts of interest and sources of funding: none declared.

Reprints: Michael S. Wong, MD, FACS, 2221 Stockton Boulevard, Suite 2123, Sacramento, CA. E-mail: michael.wong@ucdmc.ucdavis.edu.

Copyright © 2014 by Lippincott Williams & Wilkins

ISSN: 0148-7043/14/7301-S082

DOI: 10.1097/SAP.0000000000000249



**FIGURE 1.** Arm positioning at the sides obscures the circumferential upper body ptosis seen as rolls transitioning from the breasts to the back. Elevation of the arms lifts the position of the breasts and minimizes the appearance of back rolls.

arms adducted with hands against the thighs to 180 degrees of shoulder abduction with arms positioned above the head. In addition, arm positions with hands clasped behind the back and in the lap and shoulders extended and flexed to 90 degrees, with and without arms crossed. Each of the photographs was evaluated for shadowing, arm distraction, obstruction, and distortion of the anatomy.

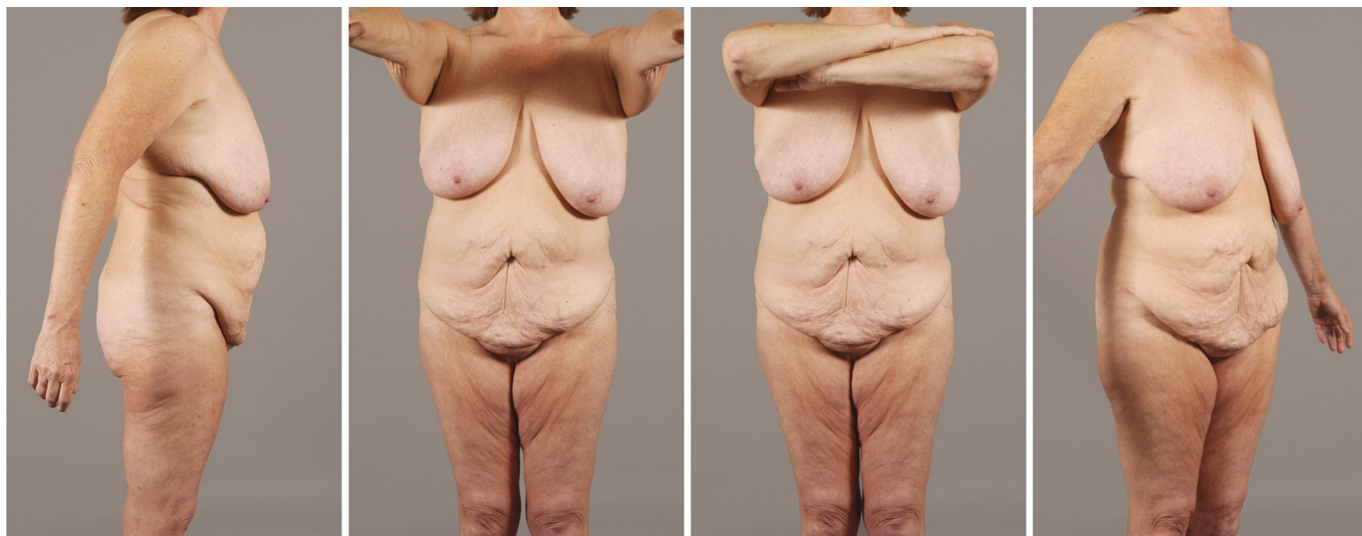
A 10-year review of the photographic standards used for MWL patients at the University of California Davis Medical Center were reviewed and compared to the Photographic Standards in Plastic Surgery issued by the ASPS<sup>1</sup> and clinical photo documentation seen in the literature and books on body contouring after MWL.<sup>6–13</sup> We compared the photographs to determine the consistency of the photographic documentation with respect to framing, patient positioning, camera position (vertical vs. horizontal), and number of images needed to document the circumferential body ptosis. In addition, evaluation of arm position and its contribution to obscuring the circumferential ptosis in the upper and lower body was performed. In addition, the standard arm positioning and framing from the first 5 years was compared with the latter 5 years. Total number of photographs taken were noted.

## RESULTS

The current Photographic Standards in Plastic Surgery<sup>1</sup> provide specific information regarding the photographic target area, camera position (vertical vs. horizontal), camera-to-patient distance,

reproduction ratio, patient preparation, patient positioning, and framing. Standards have been established for specific anatomic regions such as the close-up face, full face, ears, mouth, breasts, abdomen, hip/thighs, calves/feet, forearm, hand, and the finger.<sup>1</sup> No standards have been established for circumferential body changes seen in patients after MWL. This was reflected in our review of the current literature and textbooks for body contouring after MWL, finding no consistency in photographic documentation with respect to patient framing or patient positioning, specifically with regard to arm position. Although generally accepted that 360-degree imaging is required to document the circumferential skin ptosis, arm position varied significantly. Some authors followed the current standards whereas others modified the patient framing and positioning to capture the appropriate anatomy. From this review, it is clear the ASPS Photographic Standards in Plastic Surgery<sup>1</sup> do not capture the circumferential ptosis often seen in MWL patients and there are no consistent modifications or standards recommended for MWL patients.

Arm position was noted to affect shadowing and obstruction and distortion of circumferential excess (Fig. 1). When arms are positioned at the side, as is standard for breast and abdominal photographs, this clearly can obscure the circumferential extent of the deformity seen in both the lower and upper body. When taking postoperative photographs for procedures that address circumferential excess such as lower body and upper body lifts, these scars are

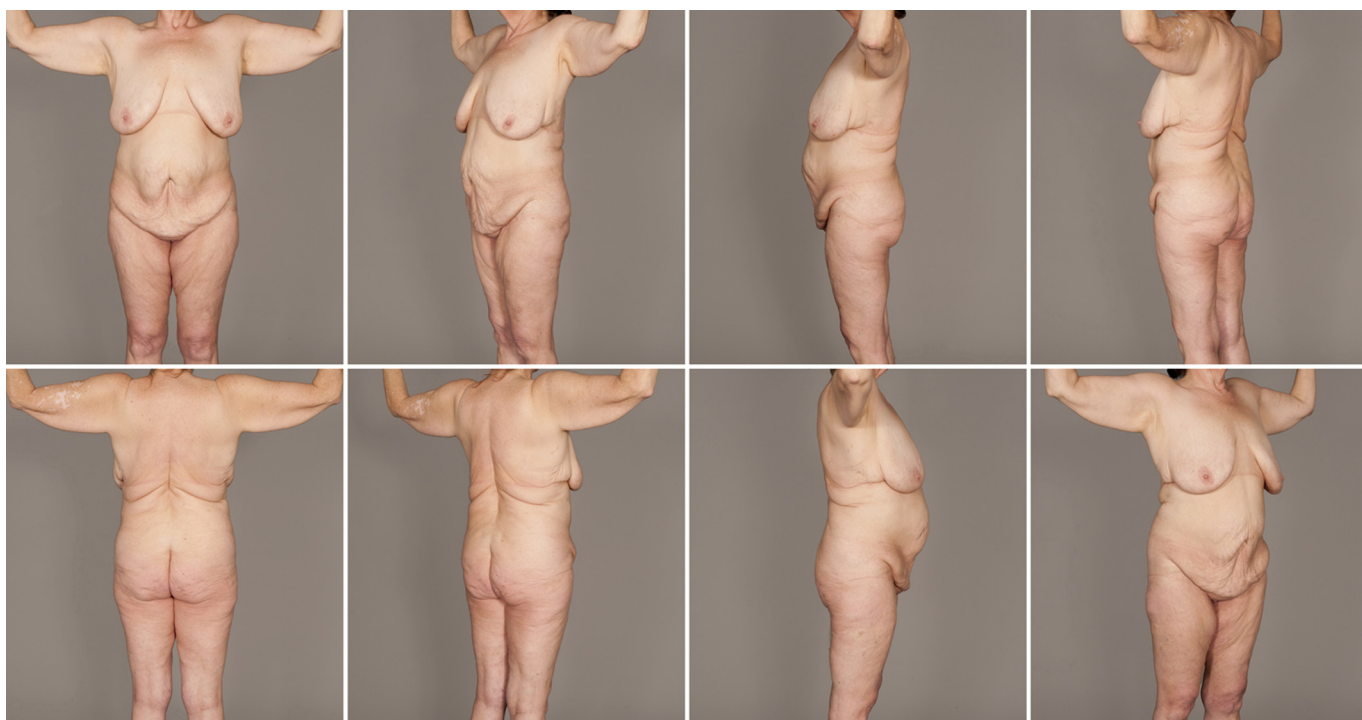

**FIGURE 2.** Arm positioning with shoulder extension creates shadows as does shoulder flexion to 90 degrees with and without arms crossed. Shoulder abduction less than 90 degrees also results in unwanted shadows.

clearly hidden by this arm positioning. In the extreme, when the shoulders are abducted to 180 degrees, the breasts are elevated and the circumferential upper body ptosis is minimized through the recruitment of the upper body excess. In some patients with mild to moderate breast and upper body ptosis, a “positional mastopexy and upper body lift” will be seen, minimizing the true extent of the deformity. Extension and flexion of the shoulders with and without crossed arms and arm abduction less than 90 degrees introduced

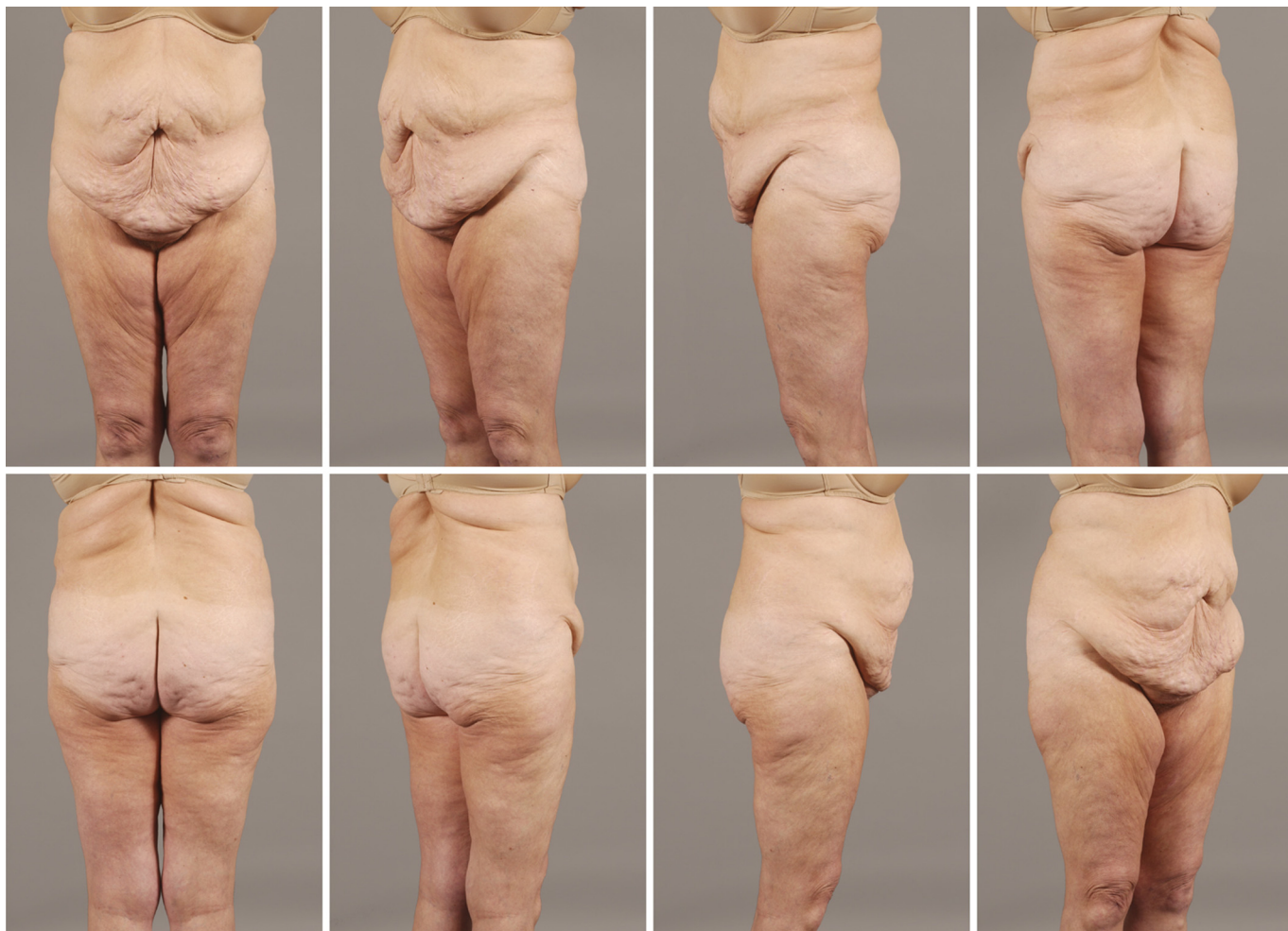additional shadowing (Fig. 2). Balancing the goals of visualizing the circumferential excess with the least distortion and shadowing led to the acceptance of arms positioned with 90-degree shoulder abduction and 90-degree elbow flexion, framing from shoulders to knees.

The 10-year review of our institution’s photographic documentation shows variations in patient framing, camera position, camera type, body position, arm position, and background. These routine pre- and postoperative photographs were all obtained using a



**FIGURE 3.** Total Body Imaging—shoulders abducted to 90 degrees and elbows flexed to 90 degrees allows the maximal visualization of the circumferential contour changes while minimizing shadows. Vertical camera positioning vertically frames from neck to knees and horizontally frames from elbow to elbow on the initial photograph, determining camera distance and total frame for all 8 images.

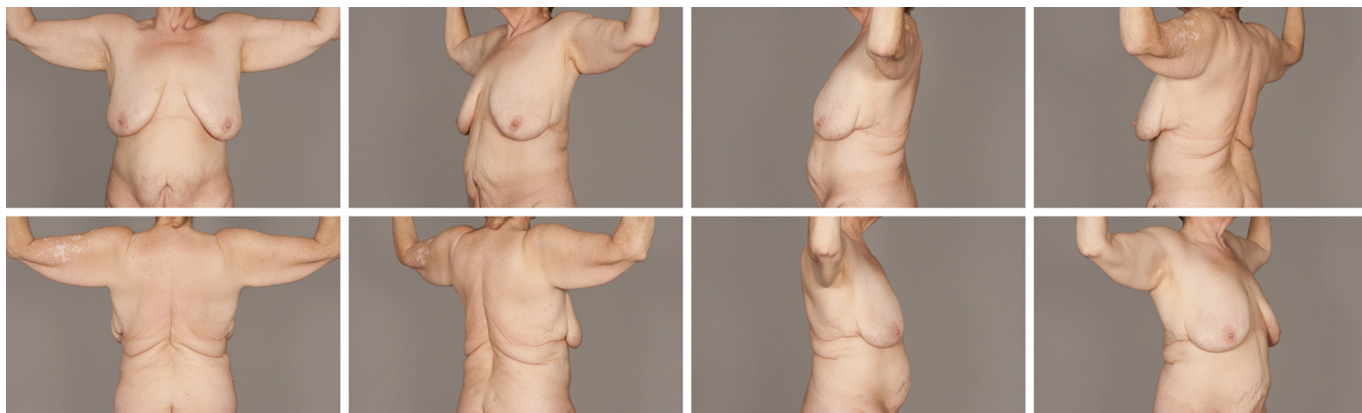




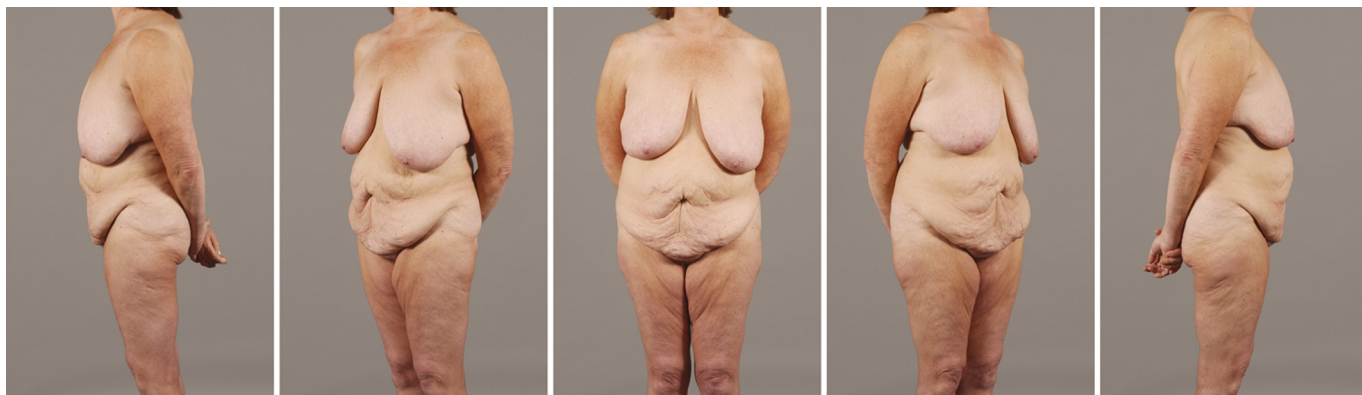
**FIGURE 4.** Lower Body Imaging—shoulders are abducted to 90 degrees and elbows are flexed to 90 degrees. Vertical camera positioning frames from the breast to the knees for 360-degree imaging.

digital point-and-shoot camera in the limited space of our patient examination rooms. During the first 5 years reviewed, initial consultations included 8 images captured at 45-degree increments with the arms abducted to 90 degrees to document the circumferential

excess from shoulders to knees (Fig. 3). They also included 360-degree photodocumentation at 45-degree intervals or 8 images focused on the lower body, framing from breasts to knee (Fig. 4), and 8 images focused on the upper body, framing from neck to gluteal



**FIGURE 5.** Upper Body Imaging—shoulders are abducted to 90 degrees and elbows are flexed to 90 degrees. Horizontal camera positioning vertically frames from neck to knees and horizontally frames from elbow to elbow on the initial photograph, determining camera distance and total frame for all 8 images.



**FIGURE 6.** Hands gently clasped behind the back allows for evaluation of the anterior half of the body. Vertical camera positioning frames from neck to knees with initial anterior image determining camera distance and framing for all 8 images.

cleft (Fig. 5) as severe upper body ptosis can extend this far inferiorly. This required a minimum total of 24 images captured per consultation with additional images taken to document panniculitis and intertrigo for insurance purposes.

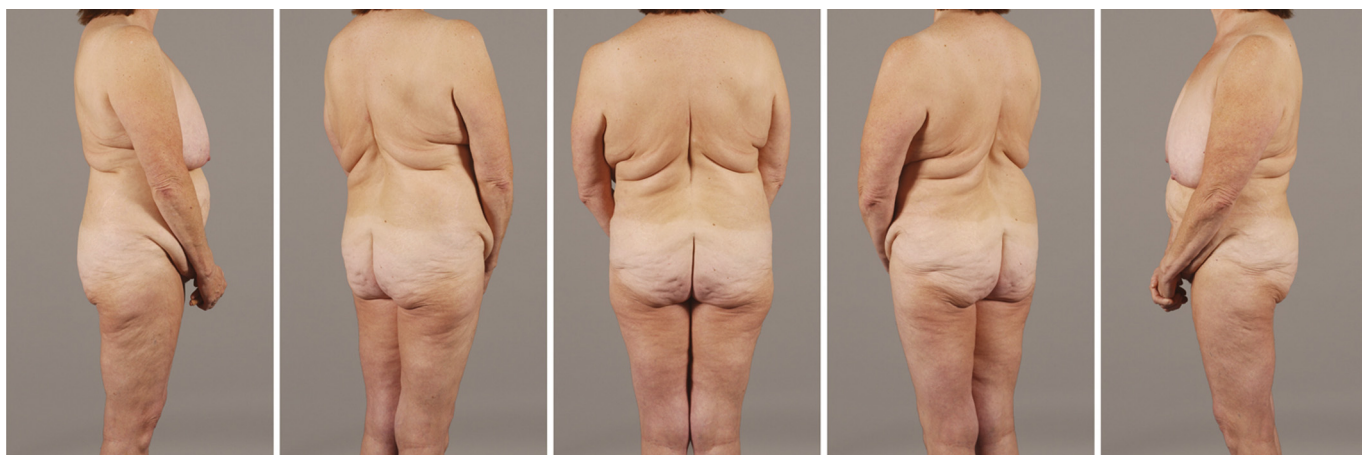In the latter 5-year period of review, initial consultations included the same 8 images captured at 45-degree increments with the arms abducted to 90 degrees to document the circumferential excess from shoulders to the knees (Fig. 3). Instead of the additional 16 images focused on the lower body (Fig. 4) separate from the upper body (Fig. 5), 5 images are obtained with arms behind the back for those photographs focusing on the anterior portion of the body (Fig. 6) and 5 images taken with the hands clasped in the lap for those photographs focusing on the posterior portion of the body (Fig. 7). This required a minimum of 18 images captured per consultation.

### DISCUSSION

Although there are well-accepted standards for photographing non-MWL patients, there are currently no photographic standards for the MWL patient. Clearly, these will need to incorporate 360-degree imaging and accept the impact of arm positioning. Additionally, because many post-bariatric body deformities continue into adjacent anatomic regions, framing needs to be expanded to include all relevant anatomy.

All arm positions assessed affect the evaluation of circumferential excess to some degree. The maximal circumferential deformity noted is present with arms adducted, but with maximal obstruction of the deformity by the arms. The least obstruction of the circumferential deformity is detected when shoulders are fully abducted to 180 degree, but this distorts the anatomy and minimizes the apparent circumferential excess. Balancing the goals of visualizing the circumferential excess with the least distortion and shadowing resulted in our acceptance of arms positioned in 90 degrees of shoulder abduction. We also added 90 degrees of elbow flexion to accommodate for space limitations often seen in clinical examination rooms.

Initially, separate photographs were obtained for the upper and lower body, consistent with the ASPS Photographic Standards<sup>1</sup> resulting in twice as many photographs required to image the upper and lower body. This also had the effect of losing the forest for the trees as many MWL patients ultimately have contouring procedures involving both the upper and lower bodies. Similar to TRAM patients where framing includes both the abdomen and breasts, framing for MWL patients needs to be expanded to include all affected areas. Lower body procedures have effects that can extend to the knees and upper body procedures can affect the upper abdomen and lower back. Framing from the knees to the shoulders has the advantage of capturing information for all these areas with half as many pictures.



**FIGURE 7.** Hands clasped and gently resting in the lap allows for evaluation of the posterior half of the body. Vertical camera positioning frames from neck to knees with initial anterior image determining camera distance and framing for all 8 images.



Because the arms are a common area of concern after significant weight loss, it is prudent to also include the arms. This widened framing more comprehensively documents the overall improvement seen with each contouring procedure in the context of the whole patient.

In the latter 5-year period of review, with improvements in technique and consistency of results, the need to be able to compare MWL patient results to non-MWL patient results was appreciated. To facilitate more consistent comparisons between these groups, arm positioning was returned to the side of the patient with arms adducted, with a minor modification in hand positioning. To highlight the anterior body, the hands were placed behind the back. To image the posterior body, the hands were positioned in the lap. Patient framing is performed from above the shoulders to below the knees with the camera in a vertical position and the camera oriented to cast the shadow behind the area of interest. When the hands are clasped, the shadow is cast in the direction of the hands, highlighting the area of interest. This set of 10 photographs replaced the 16 upper and lower body images enabling comparison of results with non-MWL patients and responding to patient discomfort associated with taking so many pictures.

Although more common in non-MWL patients, privacy garments are not commonly used as they obscure anatomy and may influence ptosis of tissues. Bikini briefs can hide skin dimpling and rhytids that can be indicators of tissue deflation and ptosis. Straps from bikinis and bras can result in additional indentations in contour, distorting tissue ptosis. Brassieres may be used selectively to aid in more effectively imaging abdominal contour in the face of significant breast ptosis (Fig. 4).

Two sets of photographs are now obtained on each patient. At the initial patient consultation, framing from the neck to the knees with the camera in a vertical position to obtain an overall view of the patient is beneficial. This can help facilitate discussions of patient concerns and counsel on available surgical options. This framing allows both the patient and surgeon to visualize the skin ptosis seen in the arms, chest, abdomen, hips, thighs, and back. To get an appreciation of the true extent of circumferential ptosis, the first set of photographs are obtained with the hands clasped behind the patient to highlight the anterior body (Fig. 6) and in the lap to focus on the posterior body (Fig. 7) with 10 images obtained at 45-degree increments. To get an unobstructed view of the circumferential deformity with the least distortion and shadowing, the second set of 8 photographs are taken every 45 degrees with the shoulders abducted to 90 degrees and the elbows flexed to 90 degrees to permit 360-degree evaluation in typical patient examination rooms (Fig. 3).

Clearly, the best quality images are obtained in a professional photography studio with synchronized stand-alone umbrella flashes. This, however, is certainly not required and often not practical in maintaining efficient patient flow through the office. With the improved quality of point-and-shoot cameras available to plastic surgeons, the benefits of a formal photography studio is decreasing. As

most point-and-shoot digital cameras have the built-in flash positioned above the lens, attention needs to be paid to positioning the flash so its shadow is cast behind the area of interest.

## CONCLUSIONS

The Photographic Standards in Plastic Surgery<sup>1</sup> have benefited our profession in many ways. However, these standards do not address the circumferential excess seen in patients after significant weight loss who are encountered in great frequency. We propose new framing and arm positions to capture the circumferential nature of MWL patients. In doing so, the maximal amount of information is obtained in the least number of images taken at each encounter with the least shadowing and distortion of anatomy. These will not only help facilitate our discussion about our patients concerns and the development of surgical plans but will also improve our ability to compare our results in a more uniform fashion with other MWL and non-MWL patients.

## ACKNOWLEDGMENT

*The authors thank Emi Manning, Medical Photographer for the University of California Davis Medical Center, for her assistance in photographing our patient featured in this manuscript.*

## REFERENCES

1. American Society of Plastic Surgeons and Plastic Surgery Educational Foundation. Photographic Standards in Plastic Surgery. 2006. Available at: [http://trebol.sirexmedica.com/download/Photographic\\_Standards.pdf](http://trebol.sirexmedica.com/download/Photographic_Standards.pdf). Accessed February 20, 2013.
2. Livingston EH. The incidence of bariatric surgery has plateaued in the U.S. *Am J Surg*. 2010;200:378–385.
3. American Society for Aesthetic Plastic Surgery. Surgical and Nonsurgical Procedures: 15-Year comparison, 1997–2011. Available at: <http://www.surgery.org/sites/default/files/2011-15yrcomparison.pdf>. Accessed January 30, 2013.
4. ASAPS Cosmetic Surgery National Data Bank Statistics 2000.
5. ASAPS Cosmetic Surgery National Data Bank Statistics 2004.
6. Aly AS, Cram AE, Heddens C. Truncal contouring surgery in the massive weight loss patient. *Clin Plast Surg*. 2004;31:61.
7. Hurwitz DJ. *Total Body Lift*. New York: MD Publish.com; 2005.
8. Aly AS. *Body Contouring After Massive Weight Loss*. St. Louis: Quality Medical Publishing, Inc.; 2006.
9. Rubin JP, Matarasso A. *Aesthetic Surgery After Massive Weight Loss*. Philadelphia: Saunders Elsevier; 2007.
10. Aly AS. *Clinics of Plastic Surgery: Body Contouring After Massive Weight Loss*. Philadelphia: Elsevier Saunders; 2008.
11. Borud LJ, Lin SJ, Rezak KM, et al. *Atlas of Body Contouring After Weight Loss*. Woodbury: Cine-Med; 2008.
12. Aly AS, Cram AE. Body lift: belt lipectomy. In: Nahai F, ed. *The Art of Aesthetic Surgery: Principles & Techniques*. St. Louis: Quality Medical Publishing, Inc.; 2005:2301–2350.
13. De La Pena JA. Gluteal augmentation. In: Nahai F, ed. *The Art of Aesthetic Surgery: Principles & Techniques*. St. Louis: Quality Medical Publishing, Inc.; 2005:2461–2481.