

UC Davis

UC Davis Previously Published Works

Title

Effects of topically applied heterologous serum on reepithelialization rate of superficial chronic corneal epithelial defects in dogs.

Permalink

<https://escholarship.org/uc/item/5d27j949>

Journal

Journal of the American Veterinary Medical Association, 250(9)

ISSN

0003-1488

Authors

Eaton, J Seth
Hollingsworth, Steven R
Holmberg, Bradford J
[et al.](#)

Publication Date

2017-05-01

DOI

10.2460/javma.250.9.1014

Peer reviewed

Effects of topically applied heterologous serum on reepithelialization rate of superficial chronic corneal epithelial defects in dogs

J. Seth Eaton VMD

Steven R. Hollingsworth DVM

Bradford J. Holmberg DVM, PhD

Michael H. Brown DVM, MS

Patricia J. Smith DVM, PhD

David J. Maggs BVSc

From the Veterinary Medical Teaching Hospital (Eaton) and Department of Surgical and Radiological Sciences (Hollingsworth, Maggs), School of Veterinary Medicine, University of California-Davis, Davis, CA 95616; Veterinary Ophthalmology Services Inc, 48 Notch Rd, Little Falls, NJ 07424 (Holmberg, Brown); and Animal Eye Care, 1612 Washington Blvd, Fremont, CA 94539 (Smith).

Address correspondence to Dr. Maggs (djmaggs@ucdavis.edu).

OBJECTIVE

To assess the effects of topical application of undiluted heterologous serum on time to corneal reepithelialization in dogs with superficial chronic corneal epithelial defects (SCCEDs).

DESIGN

Multicenter, randomized, double-masked, controlled clinical trial.

ANIMALS

41 client-owned dogs.

PROCEDURES

After collection of baseline clinical and historical data, dogs were randomly assigned to receive topically applied undiluted heterologous serum ($n = 22$) or isotonic saline (0.9% NaCl) solution (19) along with tobramycin and atropine. Epithelial debridement (at all visits) and grid keratotomy (at visits 2, 3, and 4) of SCCEDs were performed. Ophthalmic examination including fluorescein application was performed once weekly for 4 weeks or until corneal reepithelialization. Clinicians and owners were masked to treatment group.

RESULTS

No differences in baseline data were detected between treatment groups. No difficulties with medication administration, noncompliance, or adverse reactions were noted. All SCCEDs in both groups healed by 4 weeks after treatment began. Median time to reepithelialization (2 weeks) was not significantly different between serum-treated and placebo-treated eyes. Irrespective of treatment group, median time to reepithelialization was not significantly different for Boxers versus non-Boxer breeds. Direct correlations were detected between time to reepithelialization and vascularization score at study entry, vascularization score at time of reepithelialization, and ulcer area at study entry in both groups. Time to reepithelialization was not correlated with age, sex, or duration of signs in either group.

CONCLUSIONS AND CLINICAL RELEVANCE

Topical application of undiluted heterologous serum was well tolerated by dogs with SCCEDs but, as an adjunct to standard treatment, did not reduce time to corneal reepithelialization. (*J Am Vet Med Assoc* 2017;250:1014–1022)

Superficial corneal ulcers are encountered in veterinary and human patients and are characterized by loss of corneal epithelium, exposure of corneal stroma without stromal loss, and, often, marked discomfort. They are readily diagnosed by slit-lamp biomicroscopy and fluorescein retention by the exposed corneal stroma.¹ Factors such as conformation-related exposure, adnexal disease, or tear deficiency can reduce protection of the corneal surface and contribute to epithelial cell damage or loss, but are not always evident on examination.¹

In dogs, a form of chronic superficial corneal ulceration with no identifiable cause or complicating

factor is common. Such ulceration is often referred to as indolent ulcer or SCCED. This disorder is most commonly diagnosed in middle-aged to older dogs, and the Boxer breed is overrepresented.^{1,2} The cardinal clinical feature unique to SCCEDs is a lip of non-adherent epithelium surrounding the epithelial defect.^{1,2} Debridement of this loose tissue is diagnostic and a common component of therapeutic approaches used for this condition.²⁻⁴

The pathogenesis of SCCED remains poorly understood, with some proposing that it represents a primary epithelial abnormality,⁵ while others claim that stromal dysfunction or anatomic derangement is causative or contributory.⁶ It is possible that both contribute to the pathogenesis of this disease, maybe in different degrees, depending on chronicity.

Because of the ill-defined pathogenesis, definitive treatment of SCCED remains controversial. However,

ABBREVIATIONS

IQR Interquartile range
SCCED Superficial chronic corneal epithelial defect

in combination with standard topical antimicrobial treatment and corneal epithelial debridement, anterior stromal puncture techniques such as punctate or grid keratotomy or diamond-burr debridement are widely used, with or without bandage contact lenses, and are associated with variable clinical success rates.^{1-4,7-11}

Adjunctive use of topical treatments is associated with favorable effects on healing rates of SCCEDs.^{3,12-18} In humans, serum has been used as an adjunctive topical treatment for many ocular surface diseases, especially ulcerative corneal disease. In particular, topical application of serum has been associated with improvements in corneal healing rates and comfort in patients with persistent corneal epithelial defect, which is a disease with a similar clinical appearance to SCCED.¹⁹⁻²⁹ The clinical benefits of topical treatment with serum are believed to be at least partially due to high concentrations of numerous growth factors, particularly epidermal growth factor, as well as vitamin A, fibronectin, and others.³⁰ Collectively, the abundance of such components in serum is believed to promote epithelial health and wound healing capacity.^{25,31}

Serum has also been used as a therapeutic agent in veterinary patients, particularly those with corneal malacia, wherein the antiproteinase activity of serum reduces enzymatic corneal stromal degradation.^{32,33} To the authors' knowledge, however, no published reports exist of studies evaluating the effect of topically applied serum in dogs with SCCED. Therefore, the purpose of the multicenter, randomized, double-masked clinical trial reported here was to assess the effects on corneal wound healing of topical application of undiluted serum as an adjunct to standard treatment in dogs with SCCED. We hypothesized that, relative to placebo, adjunctive treatment with topically applied, undiluted serum would promote wound healing and shorten time to reepithelialization of spontaneously arising SCCED in client-owned dogs.

Materials and Methods

Animals

Dogs that received a diagnosis of SCCED at Veterinary Ophthalmology Services Inc (Little Falls, NJ), Animal Eye Care (Fremont, Calif), or the Veterinary Ophthalmology Service at the University of California-Davis William R. Pritchard Veterinary Medical Teaching Hospital between January 1, 2008, and January 1, 2010, were considered for inclusion in the study. All dogs received a complete ophthalmic examination, including slit-lamp biomicroscopy, indirect ophthalmoscopy, and fluorescein application. The diagnosis of SCCED was made on the basis of evidence of corneal epithelial loss without stromal loss present for > 7 days, surrounded by nonadherent epithelium, and lacking an identifiable underlying or perpetuating cause. Exclusion criteria included evidence of stromal loss, malacia, or infection; bilateral SCCEDs at the time of diagnosis; clinical

evidence of concurrent tear film deficiency; prior treatment with grid or punctate keratotomy; or prior topical treatment with serum.

All protocols used in the study were approved by the University of California-Davis Institutional Animal Care and Use Committee, and enrollment of dogs adhered to the guidelines established by the Veterinary Medical Teaching Hospital's Clinical Trials Review Board. Informed consent was obtained in writing from all owners prior to enrollment of their dog in the study. All study-related drugs and materials were provided to owners without charge. All other fees were charged at the discretion of the attending veterinarian.

Preparation of serum and placebo

Serum for use in this study was obtained from blood samples from 16 adult client-owned dogs, each weighing > 25 kg (55 lb) and judged to be healthy on the basis of history and results of physical examination, CBC, serum biochemical analysis, and serologic tests for *Rickettsia rickettsii*, *Borrelia burgdorferi*, *Ehrlichia canis*, *Anaplasma phagocytophila*, *Babesia canis*, *Babesia gibsoni*, and *Dirofilaria immitis*. A volume of blood not exceeding 10% of total blood volume (as estimated on the basis of body weight) was collected from each dog via jugular venipuncture and placed into sterile 10-mL blood collection tubes (range in total volume, 50 to 150 mL/donor). Blood samples were refrigerated at 4°C for 2 hours and centrifuged at 3,000 X g for 15 minutes, and serum was manually aspirated. Undiluted serum from all donors was pooled and divided into 2-mL aliquots, each of which was placed into a sterile 3-mL eye-dropper bottle^a and stored at -20°C for up to 24 weeks until distribution to dog owners for topical ophthalmic use.

Blood collection and serum processing were performed by use of a sterile technique, with all processing performed under a laminar flow hood. A commercial saline (0.9% NaCl) solution-based eyewash^b was used as the placebo, with 2-mL aliquots placed in eye-dropper bottles identical to those used to contain serum by use of the same sterile technique, and similarly stored at -20°C for up to 24 weeks. Sets of 4 bottles of serum or placebo were each assigned a unique identification number randomly generated by commercial software.^c Prepared aliquots of frozen serum and placebo were shipped overnight on dry ice to the 2 participating private practices.

Treatment protocol

All dogs enrolled in the study received identical treatment except for topical application of serum or placebo (**Figure 1**). At study entry, routine epithelial debridement of the SCCED was performed for all dogs in both treatment groups. Briefly, 1 drop of 0.5% proparacaine solution^d was applied to the ulcerated eye, and approximately 1 minute later, a sterile cotton-tipped applicator was used to debride all nonadherent epithelial tissue from the corneal surface. All

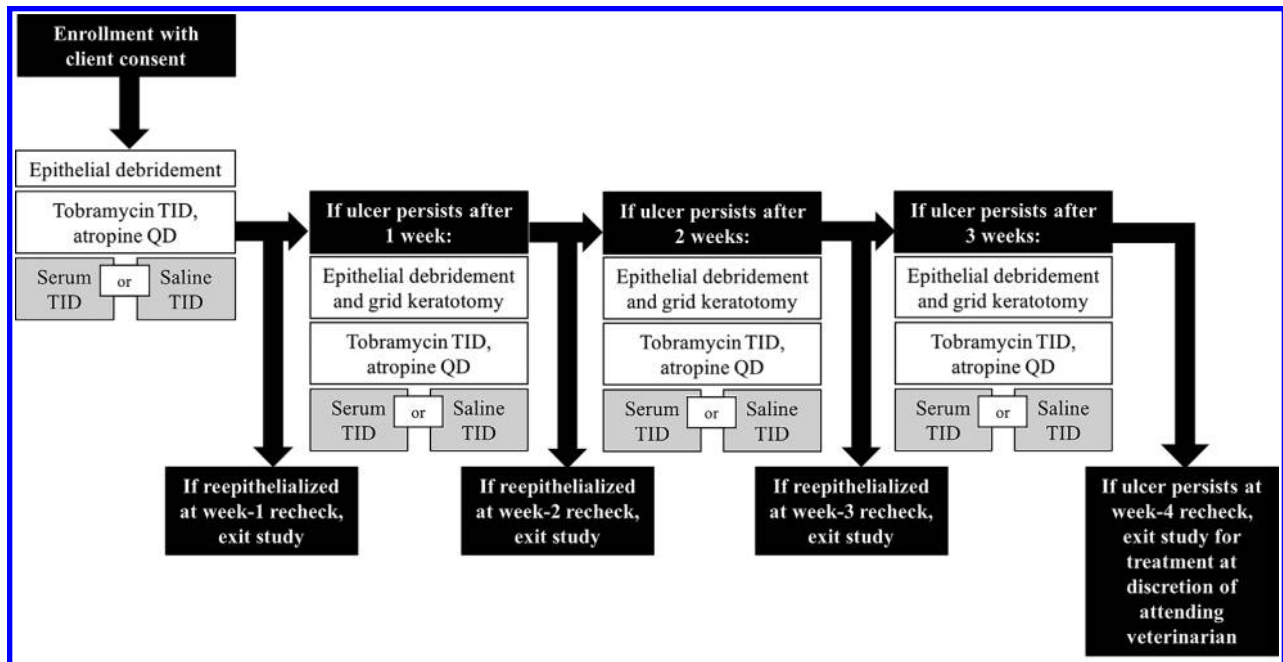


Figure 1—Diagram of the study design used to assess 41 client-owned dogs with spontaneously arising, unilateral, SCCEDs randomized to receive topically applied serum ($n = 22$) or placebo (saline [0.9% NaCl] solution; 19) 3 times daily (TID) for 4 weeks or until corneal reepithelialization. Other treatments were identical for both treatment groups. Equal spacing of treatments was not requested of owners. Recheck examinations were performed once weekly for 4 weeks. QD = Four times daily.

affected eyes were also treated topically with 0.3% tobramycin ophthalmic solution^c (1 drop to the affected eye, 3 times daily) and 1% atropine sulfate ophthalmic solution^c (1 drop to the affected eye, once daily).

At enrollment, each dog was assigned a patient number and the owner was provided with a set of 4 dropper bottles with the corresponding randomly assigned number. Thus, both the treating clinician and owner were masked regarding the study agent (serum or placebo) prescribed. Owners were instructed to apply 1 drop of the study agent to the affected eye 3 times daily (equal spacing of treatments not requested) until recheck examination and, when administering multiple topical medications, to wait 5 minutes between doses and to always administer the study agent last. Owners were instructed to keep unused bottles frozen until use and to thaw 1 of the 4 bottles of study agent provided, to use this bottle for 1 week (keeping the bottle refrigerated at all times when not in use), and then to discard that bottle and repeat the process weekly. An Elizabethan collar was provided to prevent self-trauma by dogs during the treatment period.

Dogs were reexamined at the 3 participating veterinary ophthalmology clinics at weekly intervals following initiation of treatment. At each visit, complete ophthalmic examination and fluorescein staining were performed in the same manner as at baseline. Dogs with healed ulcers (diagnosed by failure of the cornea to retain fluorescein and absence of nonadherent epithelial tissue) exited the study protocol and were

censored from subsequent data analysis at that point. Dogs with persistent ulceration remained in the study and underwent another epithelial debridement (as described for baseline), followed by grid keratotomy performed with a 25-gauge needle. Topical administration of tobramycin, atropine, and a new bottle of the study agent and placement of the Elizabethan collar were continued as previously described.

All clinicians were issued standardized forms (**Supplemental Appendix S1**, available at avmajournals.avma.org/doi/suppl/10.2460/javma.250.9.1014) to record signalment; treatment identity number; pertinent medical history; ophthalmic examination findings, including approximate ulcer area prior to and following epithelial debridement (estimated as the percentage of total corneal area); and degree of corneal vascularization scored on a semiquantitative scale (0 = no corneal vessels noted, 1 = vessels extended $\leq 50\%$ of the distance from the limbus to the ulcer edge, 2 = vessels extended $> 50\%$ of the distance from the limbus to the ulcer edge, 3 = vessels reached the ulcer edge, and 4 = vessels or fibrovascular tissue extended into the ulcer bed). Distances were estimated before and following debridement, with only the latter used for data analysis. Response to treatment and any adverse reactions were also noted at each recheck evaluation.

Statistical analysis

Distributions and values of various dog characteristics were compared between the serum- and

placebo-treated groups by means of χ^2 analysis (sex, Boxer breed vs non-Boxer breed, right vs left eye, and presence of concurrent systemic disease), the Fisher exact test (neuter status, purebred vs mixed breed, previous topical medication use, prior epithelial debridement, concurrent endocrinopathy, prior SCCED, and prior ocular disease), 2-tailed *t* test (age), or Mann-Whitney rank sum test (duration of clinical signs prior to referral, time from first veterinary visit to referral, vascularization score at baseline, and ulcer size at baseline). Time to reepithelialization was compared between the serum- and placebo-treated groups by means of the log rank survival analysis and Mann-Whitney rank sum test. Correlations between time to reepithelialization and various factors were assessed by calculation of the Spearman (ρ ; vascularization score) or Pearson (*r*; all other factors) correlation coefficients, and regression lines were calculated with the least squares method. Change in vascularization score throughout the study was compared between the 2 treatment groups by means of the Mann-Whitney rank sum test.

All normally distributed data are reported as mean \pm SD; nonnormally distributed data are report-

ed as median (IQR). Missing or unspecified data were omitted from all analyses. For all analyses, statistical software^f was used and a value of $P < 0.05$ was considered significant.

Results

Forty-one dogs with unilateral SCCED and comprising 18 breeds were enrolled in the study; 22 dogs were assigned to receive heterologous serum and 19 to receive saline solution (placebo). Mean \pm SD age did not significantly ($P = 0.82$) differ between dogs assigned to the treatment (9 ± 2.8 years; range, 4 to 15 years) or placebo (8.8 ± 2.9 years; range, 1.5 to 16 years) group, nor were any significant differences identified between groups in sex, neuter status, affected eye distributions, or other characteristics (**Table 1**). Although Boxers represented 37% (15/41) of all dogs enrolled, the proportion assigned to the treatment group (6/22 [27%]) did not differ significantly ($P = 0.31$) from that assigned to the placebo group (9/19 [47%]).

No significant ($P = 0.32$) difference was detected between the proportion of serum-treated dogs (1/22 [5%]) and placebo-treated dogs (3/19 [16%]) with a

Table 1—Baseline characteristics of 41 client-owned dogs with spontaneously arising, unilateral, SCCEDs randomized to receive topically applied serum (n = 22) or placebo (saline; 19) 3 times daily for 4 weeks or until corneal reepithelialization.

Characteristic	No. (%) of serum-treated dogs	No. (%) of saline-treated dogs	P value
Sex			0.89
Male	11 (50)	10 (53)	
Female	11 (50)	9 (47)	
Neuter status			0.66
Neutered or spayed	19 (86)	16 (84)	
Sexually intact	2 (9)	3 (16)	
Unspecified	1 (5)	0 (0)	
Breed			0.31
Boxer	6 (27)	9 (47)	
Other breed	16 (73)	10 (53)	
Breed status			0.65
Pure breed	20 (91)	16 (84)	
Mixed breed	2 (9)	3 (16)	
Eye affected			0.85
Right	10 (45)	9 (47)	
Left	12 (55)	10 (53)	
Prior topical ophthalmic medication			1.00
Yes	20 (91)	18 (95)	
No	2 (9)	1 (5)	
Prior epithelial debridement			0.61
Yes	3 (14)	1 (5)	
No	19 (86)	18 (95)	
Concurrent systemic disease			0.52
Yes	5 (23)	7 (37)	
No	17 (77)	12 (63)	

Other treatments were identical for both treatment groups, and recheck examinations were performed once weekly for 4 weeks (See Figure 1). Values of $P < 0.05$ were considered significant.

concurrent endocrinopathy known or suspected to influence corneal wound healing, such as diabetes mellitus, hypothyroidism, or hyperadrenocorticism. Concurrent or prior ocular diseases were reported or detected in 4 (18%) serum-treated dogs and 4 (21%) placebo-treated dogs ($P = 1.00$). These diseases included chronic bilateral immature cataracts (1 serum-treated dog), bilateral cataract surgery > 2 years previously (1 placebo-treated dog), cherry-eye surgery as a juvenile (1 serum-treated dog), and ipsilateral eyelid tumor removal 1 to 2 years previously (1 serum-treated dog). One (5%) serum-treated dog and 3 (16%) placebo-treated dogs had a prior diagnosis of SCCED ($P = 0.32$).

Duration of clinical signs prior to referral was not recorded for 1 serum-treated dog. For the remaining 40 dogs for which this information was available, no significant ($P = 1.00$) difference in median duration of clinical signs prior to referral was detected between serum-treated dogs (4 weeks; IQR, 3 to 6 weeks) and placebo-treated dogs (4 weeks; IQR, 2.5 to 7 weeks). Median (IQR) interval between the first treatment by a veterinarian and study enrollment was 2.6 weeks (0.9 to 10.2 weeks) for serum-treated dogs and 2.4 weeks (1.3 to 7.4 weeks) for placebo-treated dogs ($P = 0.89$). Although 93% of dogs had received medical treatment for their SCCED prior to study enrollment, the proportions of previously treated dogs in the serum-treated group (20/22 [91%]) and placebo-treated group (18/19 [95%]) were not significantly ($P = 1.00$) different.

Prior topical ophthalmic medications prescribed were similar for both treatment groups and included antimicrobials (20 serum-treated dogs and 17 placebo-treated dogs), atropine (9 serum-treated dogs and 7 placebo-treated dogs), NSAIDs (1 serum-treated dog), and a tear supplement (1 serum-treated dog). A combined antimicrobial-dexamethasone ophthalmic medication (formulation unspecified) was administered topically to 2 placebo-treated dogs prior to referral. Anti-inflammatory drugs were administered orally prior to referral as a treatment for SCCED or a concurrent condition and included NSAIDs (4 serum-treated dogs and 1 placebo-treated dog) or a corticosteroid (1 serum-treated dog). Corneal epithelial debridement was performed prior to study enrollment for 3 (14%) serum-treated dogs and 1 (5%) placebo-treated dog ($P = 0.61$). At study entry, neither median grade of corneal vascularization (1; IQR, 0 to 2.25; $P = 0.69$) nor ulcer size (percentage of corneal area; 17%; IQR, 11% to 26%; $P = 0.57$) differed significantly between serum-treated and placebo-treated dogs.

No owners reported difficulty with medication administration or noncompliance with the treatment prescribed during the course of the study, and no adverse reactions to any topically applied medications or study agents were reported by owners or noted by clinicians at recheck examinations. All SCCEDs in both treatment groups healed within the 4-week study period, and no complications attributable to

debridement or grid keratotomy (eg, corneal malacia, stromal loss, or corneal perforation) or to the topically applied treatments were reported. Median time to reepithelialization was not significantly ($P = 0.99$) different between the serum-treated (2 weeks; IQR, 1 to 2 weeks) and placebo-treated dogs (2 weeks; IQR, 1 to 2 weeks). Kaplan-Meier survival analysis also failed to reveal a significant ($P = 0.75$) difference in time to reepithelialization between the 2 treatment groups (**Figure 2**).

For serum-treated dogs, median time to reepithelialization was not significantly ($P = 0.23$) different between Boxers (2 weeks; IQR, 1.75 to 2.25 weeks) and non-Boxers (2 weeks; IQR, 1 to 2 weeks). Likewise, for placebo-treated dogs, mean time to reepithelialization did not differ significantly ($P = 0.27$) between Boxers (mean \pm SD, 1.6 \pm 0.5 weeks) and non-Boxers (2 \pm 1.1 weeks). Regardless of treatment group, 16 of 41 (39%) dogs had reepithelialization with debridement only (8/22 [36%] receiving serum, and 8/19 [42%] receiving placebo). In all dogs in both treatment groups, corneal vascularization scores either remained the same or increased between study entry and reepithelialization, but no significant ($P = 0.73$) difference was detected in median corneal vascularization score at the time of reepithelialization between serum-treated dogs (2; IQR, 0.75 to 3) and placebo-treated dogs (2; IQR, 0 to 3). Median change in vascularization score between study entry and reepithelialization was not significantly ($P = 0.50$) dif-

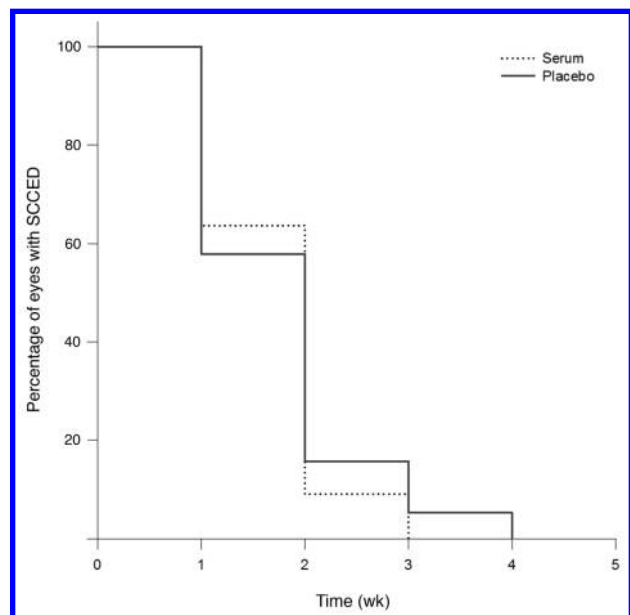


Figure 2—Kaplan-Meier curves of the percentage of 41 eyes of client-owned dogs in which spontaneously arising, unilateral SCCEDs persisted after initiation of treatment (week 0) with serum ($n = 22$) or placebo (saline solution; 19) applied topically 3 times daily for 4 weeks or until corneal reepithelialization. Other treatments were identical for both treatment groups, and recheck examinations were performed once weekly for 4 weeks. See Figure 1 for study design.

ferent between serum-treated dogs (0; IQR, 0 to 1) and placebo-treated dogs (0; IQR, 0 to 1).

Irrespective of whether eyes were treated with serum or placebo, significant and direct positive correlations were detected between time to reepithelial-

ization and vascularization score at study entry, vascularization score at time of reepithelialization, and ulcer area at study entry (**Figure 3**). Time to reepithelialization in serum- or placebo-treated eyes was not significantly ($P \geq 0.10$) correlated with dog age

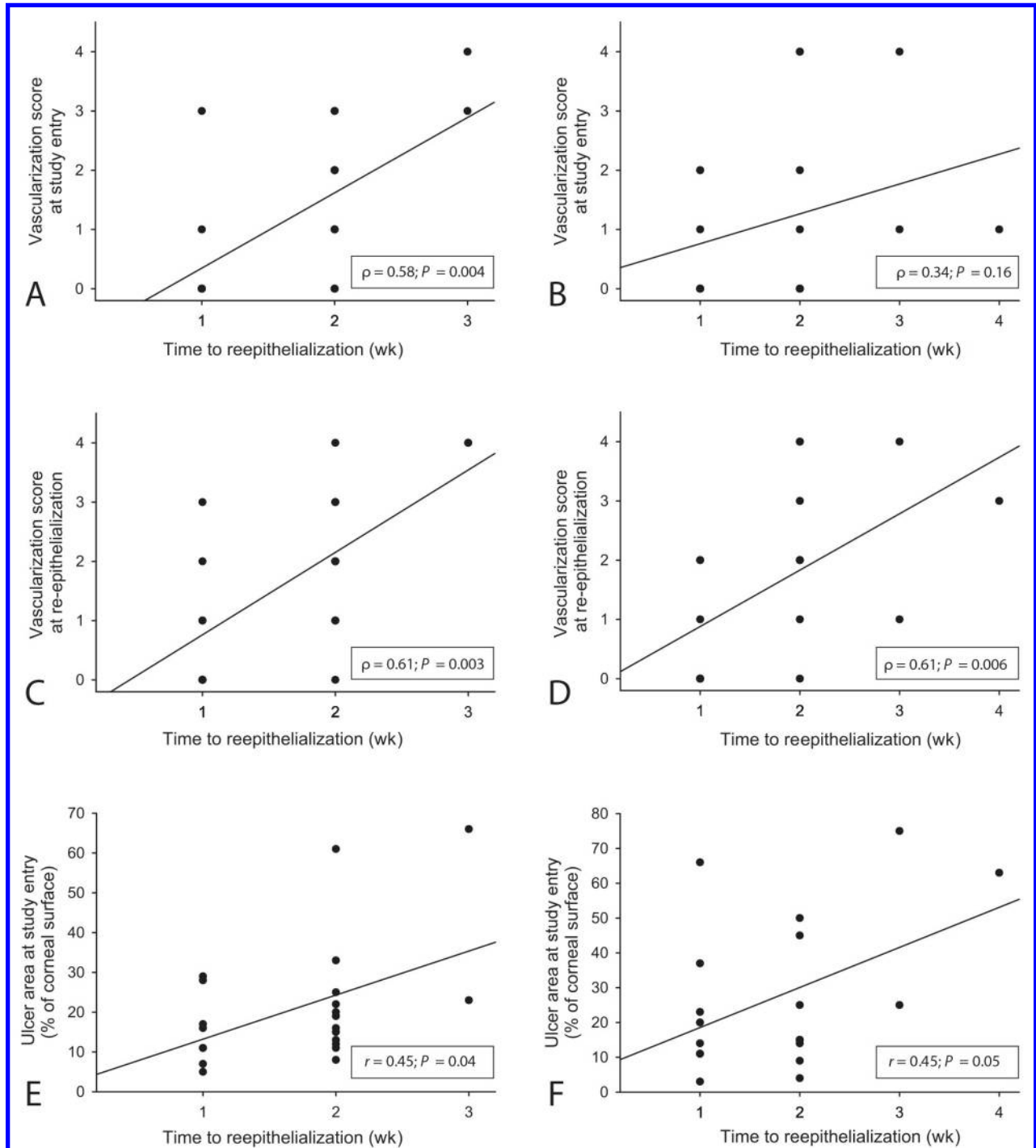


Figure 3—Scatterplots and regression lines of relationships between time to reepithelialization and vascularization score at study entry (A, B), vascularization score at time of reepithelialization (C, D), and ulcer area at study entry (E, F) for 41 eyes of client-owned dogs with SCCEDs treated topically with serum ($n = 22$; A, C, E) or placebo (saline solution; 19; B, D, F) 3 times daily until corneal reepithelialization. Other treatments were identical for both treatment groups, and recheck examinations were performed once weekly for 4 weeks. Values of correlation coefficients and associated P values are provided. Values of $P < 0.05$ were considered significant. See Figure 1 for study design.

($r = 0.20$ and 0.02 , respectively), sex ($r = 0.30$ and -0.39 , respectively), or duration of signs prior to study entry ($r = -0.04$ and 0.18 , respectively). Because so few dogs had undergone epithelial debridement prior to referral, the effect of this treatment on time to reepithelialization could not be assessed.

Discussion

The goal of the present study was to evaluate the effectiveness of topically applied, undiluted, heterologous serum as an adjunctive treatment in a group of dogs with spontaneously occurring SCCED and to do so by use of a methodology and population readily applicable to a typical clinical situation. Serum application was combined with debridement and grid keratotomy because this was the standard treatment approach for SCCEDs at the participating clinics, and 3-times-daily serum application was chosen to replicate a regimen that could likely be performed by many clients. Results indicated that topically applied undiluted serum was well tolerated by dogs with SCCED but, compared with placebo, did not accelerate corneal reepithelialization when combined with topically applied atropine and tobramycin and debridement alone or debridement and grid keratotomy. Although no significant difference in the rate of reepithelialization (ie, healing) was detected between treatment groups, a greater proportion of ulcers in serum-treated dogs had healed at 2 and 3 weeks of treatment, and serum-treated dogs had a shorter healing time than did placebo-treated dogs. In addition, all serum-treated ulcers had healed by 3 weeks, whereas 1 of 19 (5%) placebo-treated eyes required an additional week before healing was evident. Enrollment of a greater number of dogs may have permitted demonstration of a significant difference in healing rate and proportion of dogs with healed SCCEDs at each assessment point.

The population of dogs from which study subjects were enrolled was similar to those of previous studies^{4,13,14,16} involving dogs with SCCED, with middle-aged dogs and the Boxer breed overrepresented in both treatment groups. Treatment groups were similar to each other with respect to distributions of sex, age, neuter status, and affected eye. Although these factors facilitate direct clinical application of the study results, some conditions of the present study may have differed from other clinical situations. For example, use of serum from healthy donor dogs may be less common in clinical settings than use of autologous serum. Donation and pooling of serum was chosen in the present study to control for possible variability in serum components within a heterogeneous group of client-owned dogs. Additionally, serum handling and storage temperature can influence long-term stability and activity of growth factors and other molecules in serum; however, a study³⁴ of serum collected from dogs, cats, and horses revealed no difference in *in vitro* anticollagenase activity when stored at -20°C or -80°C for 180 days. On the basis of the available data, we centrifuged se-

rum in the present study at $3,000 \times g$ for 15 minutes, pooled all samples, and stored them at -20°C for < 6 months prior to use.

Clinical evaluations in the present study were performed weekly, primarily to offer owners a convenient recheck interval. Although this likely reflects a typical clinical situation, evaluation at shorter intervals would have provided greater accuracy regarding the rate of reepithelialization and may have altered the significance of some outcomes assessed.

Concurrent endocrine diseases such as diabetes mellitus, hyperadrenocorticism, and hypothyroidism with the potential to influence corneal wound healing³⁵⁻⁴² were uncommon in both treatment groups of the present study. However, of the 3 dogs with endocrinopathies, all received the placebo treatment and all had reepithelialization within 3 weeks after treatment began. It is noteworthy that the 1 dog with diabetes mellitus had the longest time to reepithelialization (3 weeks) of these dogs.

Delivery of serum-borne factors via spontaneously arising corneal vessels is a desirable therapeutic effect of surgical procedures such as conjunctival pedicle grafting,^{43,44} and corneal vascularization may exist in 58% to 64% of dogs with SCCED.^{6,16} Therefore, it is intriguing to consider the semiquantitative data from the present study regarding extent of spontaneous corneal vascularization at study entry and at healing. Regardless of treatment group, a significant and direct positive correlation was identified between vascularization scores and time to reepithelialization (ie, increased vascularization was associated with longer time to healing). As such, our data failed to support the supposition that increased vascularization and delivery of serum-borne factors are associated with faster healing; however, the design of the present study did not permit investigation of whether this relationship was causal.

It is also possible that increased vascularization and ulcer chronicity both result from another primary factor that slows healing. A similar significant and direct positive correlation was observed between ulcer size and time to reepithelialization. However, these data were more difficult to assess because dimensions were estimated on the basis of hand-drawn clinical diagrams and because poor epithelial adhesion means that ulcer size can change considerably as soon as the epithelium exfoliates or is debrided. In future studies, examination with digital caliper measurement, confocal microscopy, anterior segment optical coherence tomography, or digital image analysis of clinical photographs of fluorescein-stained eyes would provide more objective and precise means of determining ulcer size.

Numerous studies^{19,20,22-28,45} involving humans with persistent corneal epithelial defects have revealed beneficial effects of topically applied serum on epithelial healing, but epithelial deficiency may not be a primary contributor to the pathogenesis of SCCED in dogs. Although abnormal histologic features have been demonstrated in the epithelium of

up to 94% of dogs with SCCED,⁶ similar findings have also been reported for dogs with chronic, experimentally induced corneal wounds.⁴⁶ Furthermore, the unique corneal stromal histologic features of SCCED (presence of a hyalinized superficial stromal membrane and an abnormal plexus of perilesional corneal nerves) and clinical success of anterior stromal alteration procedures more strongly suggest a primary stromal abnormality.^{1,6,16}

Despite evidence supporting a primary stromal defect in SCCEDs, as many as 50% of dogs will have reepithelialization without stromal alteration following debridement of nonadherent epithelium alone.¹ This previously reported finding was supported by data obtained in the study reported here, in which 39% of enrolled dogs, regardless of treatment group, had corneas that healed with debridement alone. These data suggested that stromal abnormalities may not prevent healing of all SCCEDs, and veterinarians should consider debridement alone prior to pursuing a stromal alteration procedure.

The benefit of topical serum application in the treatment of SCCEDs likely depends on a number of factors. Clinical success in studies^{30,47} of humans with persistent corneal epithelial defects is frequently attributed to supplementation of the ocular surface with high concentrations of biologically active growth factors. It is likely, however, that the concentration of growth factors at the ocular surface is substantially influenced by species and disease process. In a placebo-controlled study¹⁵ of dogs with nonhealing corneal erosions, topical administration of epidermal growth factor improved healing rate, but the concentration of epidermal growth factor at the ocular surface in those dogs was not determined. Another investigation⁸ revealed a low tear concentration of transforming growth factor β in dogs with SCCED; in a subsequent study,¹³ topical and oral administration of tetracyclines had a positive effect on healing of SCCEDs, putatively through the modulation of growth factors including transforming growth factor β . In another study,⁴⁸ high concentrations of nerve growth factor were identified in the tears, corneas, and lacrimal glands of dogs with experimentally induced corneal wounds, but topical application of additional exogenous nerve growth factor failed to accelerate reepithelialization. Collectively, these varied results suggest that the benefit of growth factor supplementation would be best understood with a more complete characterization of the ocular surface microenvironment in dogs with SCCEDs.

Results of the present study suggested that topical application of undiluted heterologous serum was well tolerated by dogs with SCCED and did not cause any identifiable deleterious effects. As an adjunct to SCCED treatment with debridement alone or with grid keratotomy, however, it did not offer a therapeutic advantage with respect to the reepithelialization rate. Additional research is needed to establish normative relative concentrations of epithelial and

restorative constituents in canine serum, and optimized centrifugation techniques and storage methods will enhance our understanding of the therapeutic potential of serum in dogs with SCCED and other forms of ocular surface disease.

Acknowledgments

Supported by the Center for Companion Animal Health, School of Veterinary Medicine, University of California-Davis.

Interim data presented in abstract form at the 39th Annual Meeting of the American College of Veterinary Ophthalmologists, Boston, October 2008.

The authors thank Dr. Philip Kass for assistance with statistical analysis and Helen Kado-Fong for technical assistance.

Footnotes

- a. Steri-Dropper bottles, Medi-Dose, Ivyland, Pa.
- b. Steri Optics sterile isotonic buffered eyewash, Steri Optics Amityville, NY.
- c. Microsoft Excel 2008, version 12.0, Microsoft Corp, Redmond, Wash.
- d. Proparacaine ophthalmic solution (0.5%), Bausch & Lomb, Tampa, Fla.
- e. Falcon Pharmaceuticals Ltd, Fort Worth, Tex.
- f. SigmaPlot, version 13.0, Systat Software Inc, San Jose, Calif.
- g. Jurk I, Gilger B, Malok E, et al. TGF- β 2 levels in tears of normal dogs and dogs with refractory corneal ulcers (abstr), in *Proceedings*. Am Coll Vet Ophthalmol 2000;31:66.

References

1. Ledbetter E, Gilger B. Diseases and surgery of the canine cornea and sclera. In: Gelatt KN, Gilger BC, Kern TJ, eds. *Veterinary ophthalmology*. 5th ed. Ames, Iowa: Wiley-Blackwell, 2013;5:976-1049.
2. Bentley E. Spontaneous chronic corneal epithelial defects in dogs: a review. *J Am Anim Hosp Assoc* 2005;41:158-165.
3. Morgan RV, Abrams KL. A comparison of six different therapies for persistent corneal erosions in dogs and cats. *Vet Comp Ophthalmol* 1994;4:38-43.
4. Stanley RG, Hardman C, Johnson BW. Results of grid keratotomy, superficial keratectomy and debridement for the management of persistent corneal erosions in 92 dogs. *Vet Ophthalmol* 1998;1:233-238.
5. Gelatt K, Samuelson D. Recurrent corneal erosions and epithelial dystrophy in the Boxer dog. *J Am Anim Hosp Assoc* 1982;18:453-460.
6. Bentley E, Abrams GA, Covitz D, et al. Morphology and immunohistochemistry of spontaneous chronic corneal epithelial defects (SCCED) in dogs. *Invest Ophthalmol Vis Sci* 2001;42:2262-2269.
7. Champagne ES, Munger RJ. Multiple punctate keratotomy for the treatment of recurrent epithelial erosions in dogs. *J Am Anim Hosp Assoc* 1992;28:213-216.
8. Turner AG, Blogg JR. Multiple striate keratotomy: a treatment for corneal erosions caused by epithelial basement membrane disease. *Aust Vet J* 1997;75:27-30.
9. Gosling AA, Labelle AL, Breaux CB. Management of spontaneous chronic corneal epithelial defects (SCCEDs) in dogs with diamond burr debridement and placement of a bandage contact lens. *Vet Ophthalmol* 2013;16:83-88.
10. Wooff PJ, Norman JC. Effect of corneal contact lens wear on healing time and comfort post LGK for treatment of SCCEDs in Boxers. *Vet Ophthalmol* 2015;18:364-370.
11. Chavkin MJ, Riis RC, Scherlie PH. Management of a persistent corneal erosion in a Boxer dog. *Cornell Vet* 1990;80:347-356.
12. Regnier A, Cazalot G, Cantaloube B. Topical treatment of non-healing corneal epithelial ulcers in dogs with aminocaproic acid. *Vet Rec* 2005;157:510-513.
13. Chandler HL, Gemensky-Metzler AJ, Bras ID, et al. In vivo ef-

- fects of adjunctive tetracycline treatment on refractory corneal ulcers in dogs. *J Am Vet Med Assoc* 2010;237:378-386.
14. Ledbetter EC, Munger RJ, Ring RD, et al. Efficacy of two chondroitin sulfate ophthalmic solutions in the therapy of spontaneous chronic corneal epithelial defects and ulcerative keratitis associated with bullous keratopathy in dogs. *Vet Ophthalmol* 2006;9:77-87.
 15. Kirschner SE, Brazzell RK, Stern ME, et al. The use of topical epidermal growth factor for treatment of nonhealing corneal erosions in dogs. *J Am Anim Hosp Assoc* 1991;27:449-452.
 16. Murphy CJ, Marfurt CF, McDermott A, et al. Spontaneous chronic corneal epithelial defects (SCCED) in dogs: clinical features, innervation, and effect of topical SP, with or without IGF-1. *Invest Ophthalmol Vis Sci* 2001;42:2252-2261.
 17. Bromberg NM. Cyanoacrylate tissue adhesive for treatment of refractory corneal ulceration. *Vet Ophthalmol* 2002;5:55-60.
 18. Willeford KO, Miller WW, Abrams KL, et al. Modulation of proteolytic activity associated with persistent corneal ulcers in dogs. *Vet Ophthalmol* 1998;1:5-8.
 19. Alvarado Valero MC, Martínez Toldos JJ, Borrás Blasco J, et al. Treatment of persistent epithelial defects using autologous serum application [in Spanish]. *Arch Soc Esp Ophthalmol* 2004;79:537-542.
 20. Chiang CC, Chen WL, Lin JM, et al. Allogeneic serum eye drops for the treatment of persistent corneal epithelial defect. *Eye (Lond)* 2009;23:290-293.
 21. Ferreira de Souza R, Kruse FE, Seitz B. Autologous serum for otherwise therapy resistant corneal epithelial defects: prospective report on the first 70 eyes [in German]. *Klin Monatsbl Augenheilkd* 2001;218:720-726.
 22. Huang W-C, Chiang C-C, Tsai Y-Y. Autologous serum eye drops for treating persistent corneal epithelial defect after vitreoretinal surgery. *Cornea* 2008;27:1097.
 23. Jeng BH, Dupps, Jr. WJ. Autologous serum 50% eyedrops in the treatment of persistent corneal epithelial defects. *Cornea* 2009;28:1104-1108.
 24. Poon AC, Geerling G, Dart JK, et al. Autologous serum eye drops for dry eyes and epithelial defects: clinical and in vitro toxicity studies. *Br J Ophthalmol* 2001;85:1188-1197.
 25. Tsubota K, Goto E, Shimmura S, et al. Treatment of persistent corneal epithelial defect by autologous serum application. *Ophthalmology* 1999;106:1984-1989.
 26. Vajpayee RB, Mukerji N, Tandon R, et al. Evaluation of umbilical cord serum therapy for persistent corneal epithelial defects. *Br J Ophthalmol* 2003;87:1312-1316.
 27. Young AL, Cheng ACO, Ng HK, et al. The use of autologous serum tears in persistent corneal epithelial defects. *Eye (Lond)* 2004;18:609-614.
 28. Ziakas NG, Boboridis KG, Terzidou C, et al. Long-term follow up of autologous serum treatment for recurrent corneal erosions. *Clin Experiment Ophthalmol* 2010;38:683-687.
 29. Hartwig D, Herminghaus P, Wedel T, et al. Topical treatment of ocular surface defects: comparison of the epitheliotrophic capacity of fresh frozen plasma and serum on corneal epithelial cells in an in vitro cell culture model. *Transfus Med* 2005;15:107-113.
 30. Geerling G, MacLennan S, Hartwig D. Autologous serum eye drops for ocular surface disorders. *Br J Ophthalmol* 2004;88:1467-1474.
 31. Geerling G, Daniels JT, Dart JKG, et al. Toxicity of natural tear substitutes in a fully defined culture model of human corneal epithelial cells. *Invest Ophthalmol Vis Sci* 2001;42:948-956.
 32. Ollivier FJ, Brooks DE, Kallberg ME, et al. Evaluation of various compounds to inhibit activity of matrix metalloproteinases in the tear film of horses with ulcerative keratitis. *Am J Vet Res* 2003;64:1081-1087.
 33. Ollivier FJ, Gilger BC, Barrie KP, et al. Proteinases of the cornea and precocular tear film. *Vet Ophthalmol* 2007;10:199-206.
 34. Conway ED, Stiles J, Townsend WM, et al. Evaluation of species differences and the effects of storage duration and temperature on the anticollagenase efficacy of canine, feline, and equine serum on in vitro corneal degradation. *Am J Vet Res* 2015;76:989-995.
 35. Good KL, Maggs DJ, Hollingsworth SR, et al. Corneal sensitivity in dogs with diabetes mellitus. *Am J Vet Res* 2003;64:7-11.
 36. Williams DL, Pierce V, Mellor P, et al. Reduced tear production in three canine endocrinopathies. *J Small Anim Pract* 2007;48:252-256.
 37. Cullen CL, Ihle SL, Webb AA, et al. Keratoconjunctival effects of diabetes mellitus in dogs. *Vet Ophthalmol* 2005;8:215-224.
 38. Moss SE, Klein R, Klein BE. Prevalence of and risk factors for dry eye syndrome. *Arch Ophthalmol* 2000;118:1264-1268.
 39. Spearman JG, Little PB. Hyperadrenocorticism in dogs: a study of eight cases. *Can Vet J* 1978;19:33-39.
 40. Roberts MS, Lattimer JK. The surgical treatment of Cushing's syndrome. *JAMA* 1961;175:93-97.
 41. Ekmektzoglou KA, Zografos GC. A concomitant review of the effects of diabetes mellitus and hypothyroidism in wound healing. *World J Gastroenterol* 2006;12:2721-2729.
 42. Ladenson PW, Levin AA, Ridgway EC, et al. Complications of surgery in hypothyroid patients. *Am J Med* 1984;77:261-266.
 43. Hakanson N, Lorimer D, Merideth R. Further comments on conjunctival pedicle grafting in the treatment of corneal ulcers in the dog and cat. *J Am Anim Hosp Assoc* 1988;24:602-605.
 44. Hakanson N, Merideth R. Conjunctival pedicle grafting in the treatment of corneal ulcers in the dog and cat. *J Am Anim Hosp Assoc* 1987;23:641-648.
 45. Cho YK, Huang W, Kim GY, et al. Comparison of autologous serum eye drops with different diluents. *Curr Eye Res* 2013;38:9-17.
 46. Bentley E, Campbell S, Woo HM, et al. The effect of chronic corneal epithelial debridement on epithelial and stromal morphology in dogs. *Invest Ophthalmol Vis Sci* 2002;43:2136-2142.
 47. Bradley JC, Bradley RH, McCartney DL, et al. Serum growth factor analysis in dry eye syndrome. *Clin Experiment Ophthalmol* 2008;36:717-720.
 48. Woo H-M, Bentley E, Campbell SF, et al. Nerve growth factor and corneal wound healing in dogs. *Exp Eye Res* 2005;80:633-642.