

# UC Davis

## Dermatology Online Journal

### Title

A case report of granulomatous lymphomatoid papulosis

### Permalink

<https://escholarship.org/uc/item/5c13t4s4>

### Journal

Dermatology Online Journal, 29(1)

### Authors

Vincek, Vladimir  
Vause, Ava  
Harrison, Alex  
et al.

### Publication Date

2023

### DOI

10.5070/D329160213

### Copyright Information

Copyright 2023 by the author(s). This work is made available under the terms of a Creative Commons Attribution-NonCommercial-NoDerivatives License, available at <https://creativecommons.org/licenses/by-nc-nd/4.0/>

Peer reviewed

# A case report of granulomatous lymphomatoid papulosis

Vladimir Vincek<sup>1</sup> MD PhD, Ava Vause<sup>2</sup> BS, Alex Harrison<sup>3</sup> DO, Michael Krutchik<sup>3</sup> DO, Richard Miller<sup>3</sup> DO, and Kiran Motaparathi<sup>1</sup> MD

Affiliations: <sup>1</sup>Department of Dermatology, College of Medicine, University of Florida, Gainesville, Florida, USA, <sup>2</sup>The Frank H Netter MD School of Medicine, Quinnipiac University, North Haven, Connecticut, USA, <sup>3</sup>Bay Dermatology and Cosmetic Surgery, Largo, Florida, USA

Corresponding Author: Vladimir Vincek MD PhD, Department of Dermatology, College of Medicine, University of Florida, 4037 NW 86<sup>th</sup> Terrace, Gainesville, FL 32606, Tel: 352-594-1500, Fax 352-733-4336, Email: [Vincek26@ufl.edu](mailto:Vincek26@ufl.edu)

## Abstract

Lymphomatoid papulosis is a chronic CD30-positive cutaneous lymphoproliferative disorder that is characterized by recurring red-brown necrotic papules. It exhibits a wide spectrum of histopathologic findings and is often associated with cutaneous T-cell lymphomas. Six different histological subtypes have been classified by the WHO, but there is limited understanding regarding rare histopathologic variants. We describe a 51-year-old man who presented with recurring, necrotic papules for 6 years that progressed to involve the face, scalp, trunk, axilla, and scrotum. Histopathology demonstrated sarcoidal granulomas, along with a CD30-positive T cell infiltrate which demonstrated clonality by T cell receptor gamma gene rearrangement. A diagnosis of lymphomatoid papulosis associated with granulomas was established based on the clinical and histopathologic presentation. The clinical understanding of granulomatous lymphomatoid papulosis is limited in the available literature and more awareness of this histopathologic variant is required for accurate classification of this disorder.

*Keywords: CD30, granulomas, lymphomatoid papulosis, lymphoproliferative disorders, mycosis fungoides*

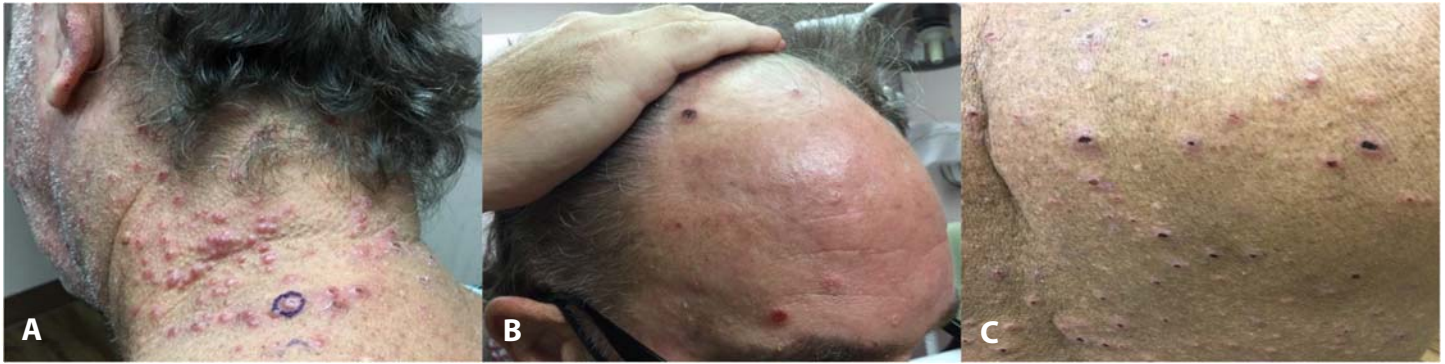## Introduction

Lymphomatoid papulosis (LyP) is a cutaneous CD30-positive lymphoproliferative disorder characterized by recurrent crops of red-brown ulceronecrotic

papules or nodules of variable size [1,2]. The number of lesions may range from a single lesion to over a hundred lesions that typically cover the trunk and extremities [3,4]. In more rare cases, lesions can have a more segmental and localized distribution including the face [5-7]. Several unusual clinical variants were described including pustular, bullous, follicular, and mucosal [8-11]. Between 10-20% of cases of lymphomatoid papulosis are associated with concurrent or subsequent development of lymphomas such as mycosis fungoides (MF), CD30-positive anaplastic large cell lymphoma (ALCL), or Hodgkin lymphoma [12]. Classically, six different histopathologic subtypes (A, B, C, D, E and LyP with *DUSP22-IRF4* rearrangement) have been recognized and classified by the WHO [13]. Type A is the predominant histopathologic type that is present in about 80% of cases. Overlapping cases with more than one subtype in a single case have also been reported [14]. Less common variants such as folliculotropic (F subtype), [15,16], syringotropic, spindle cell, angioinvasive, pseudoepitheliomatous, intralymphatic, and granulomatous eccrinotropic [17-22] are not yet listed in the official WHO classification. Unfortunately, there is no established correlation between histopathologic subtypes and clinical presentation, apart from type E which includes eschar-like necrosis [2,23].

## Case Synopsis

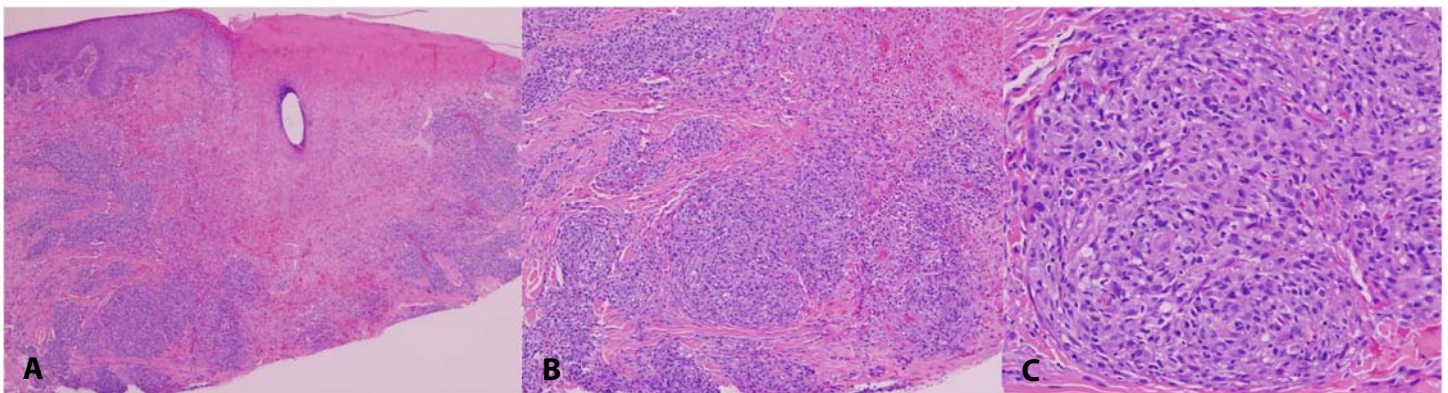
A 51-year-old man presented with recurring, necrotic papules for 6 years. The papules initially erupted on the neck but progressed over the years to involve the



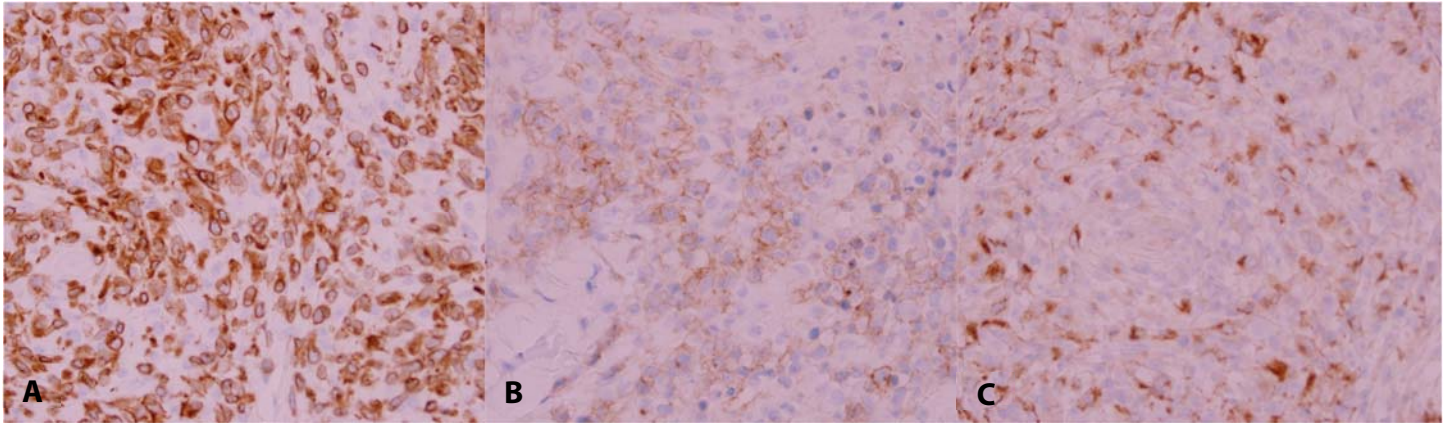
**Figure 1.** Clinical images. Papulonecrotic papules involving **A)** neck, **B)** scalp, and **C)** trunk.

face, scalp, trunk, axilla, and scrotum. The papules would heal spontaneously in several weeks. The lesions were pruritic, affecting activities of daily living and causing emotional distress. Previous clinical diagnoses included hidradenitis suppurativa, lichen planus, and neurotic excoriations. Therapy with topical corticosteroids, prednisone, adalimumab, and antihistamines was ineffective. He reported improvement with methotrexate and minocycline for suspected hidradenitis suppurativa, but the treatment was discontinued due to blue discoloration. The patient presented with an acute flare of widespread papulonecrotic papules involving the neck, scalp, trunk (**Figure 1**) abdomen, and scrotum. He reported minor weight loss but denied all other systemic symptoms. Histopathology demonstrated an eroded epidermis and dermal necrosis [**Figure 2A**] with surrounding multiple non-necrotizing, sarcoidal granulomas (**Figure 2B**). Granulomas consisted mostly of larger cells, some with abundant cytoplasm and some with irregular nuclei, admixed with few smaller cells with sparse

cytoplasm (**Figure 2C**). Immunohistochemical staining demonstrated that a majority of cells forming granulomas (large and small cells) were CD3-positive T cells (**Figure 3A**) of which the majority were CD4 positive and CD8 and CD7 negative. About a half of the larger CD3 positive T cells demonstrated CD30-positive membrane staining (**Figure 3B**). Larger cells that were CD3 negative were CD68 positive histiocytes (**Figure 3C**). There was no evidence of epidermal lymphocyte exocytosis. Special stains for infectious organisms, including Ziehl-Neelsen and Grocott methenamine silver, were negative. A T cell receptor gamma gene rearrangement study by polymerase chain reaction showed monoclonality. After a review of the clinical history and molecular study, a diagnosis of granulomatous lymphomatoid papulosis was made. The patient was restarted on methotrexate 20mg weekly and sarecycline 150mg daily and rapid improvement was noted. The patient was also referred to the oncology department for systemic evaluation.



**Figure 2.** H&E histopathology images demonstrate **A)** ulcerated shave biopsy with dermal necrosis, 40 $\times$ ; **B)** multiple dermal sarcoidal granulomas, 200 $\times$ ; **C)** granuloma consisting of large epithelioid cells admixed with some smaller lymphocytes, 400 $\times$ .



**Figure 3.** Immunohistopathology images (400×): **A)** CD3 outlines T cell lymphocytes; **B)** CD30 stains large atypical cells; **C)** CD68 detects scattered histiocytes.

### Case Discussion

The presence of cutaneous granulomas raises a broad spectrum of clinical possibilities including a variety of infectious disorders, numerous inflammatory disorders, foreign body reactions, and rarely, lymphoproliferative disorders [24]. Although histopathological findings can be quite specific in instances of granuloma annulare, necrobiosis lipoidica, or foreign body granuloma, special stains may be required for cases involving infection. In sarcoidosis, rosacea, or cutaneous Crohn disease, clinical correlation is vital [24].

Cutaneous granulomatous lymphoproliferative disorders are uncommon compared to other non-malignant cutaneous granulomatous disorders. The granulomatous variant of MF is well described. Granulomas are less commonly observed in Sezary syndrome, CD30-positive lymphoproliferative disorders, subcutaneous panniculitis-like T-cell lymphoma, primary cutaneous B-cell lymphoma, and Epstein-Barr virus-associated B-cell lymphomatoid granulomatosis [24-28].

The granulomatous variant of mycosis fungoides was the major entity in the differential diagnosis for our patient. Similar to the case presented here, about half of described cases of granulomatous MF do not show epidermotropism [25]. In addition, the majority of cases of granulomatous mycosis fungoides contain granulomas with a sarcoidal appearance that are associated with T cells that are CD3 and CD4 positive and CD8 negative [25]. However, the abundance of CD30-positive large cells present in the case presented is not typical of granulomatous

MF except in cases with large cell transformation [25,28]. The major difference between granulomatous lymphomatoid papulosis and granulomatous MF is in the clinical presentation. Granulomatous MF presents with longstanding patches and plaques, without resolution and recurrence. In contrast, the patient presented here had a several-year history of recurrent crops of papules that resolved over several weeks, typical of lymphomatoid papulosis. The patient also responded well to methotrexate therapy.

Lymphomatoid papulosis associated with granulomas is very rare, with only two prior reports in the literature. The granulomas described in both prior reports were prominently associated with eccrine and vascular structures, unlike the case presented here. In contrast to previously reported patients in which granulomas were observed within a mixed infiltrate of eosinophils, neutrophils, and small cytologically bland lymphocytes, the granulomas in this case were sarcoidal mostly made of large epithelioid cells. Therefore, the preferred designation in this case is granulomatous lymphomatoid papulosis. Further understanding of the histopathologic variants of this rare condition, will permit accurate differentiation of lymphomatoid papulosis subtypes.

### Conclusion

We report a case of lymphomatoid papulosis with sarcoidal granulomas. Although rare syringotropic granulomatous cases of lymphomatoid papulosis

have been reported, to the best of our knowledge this is the first case described that exhibits a sarcoidal granulomatous infiltrate without eccrine involvement.

## References

1. Macaulay WL. Lymphomatoid papulosis. A continuing self-healing eruption, clinically benign–histologically malignant. *Arch Dermatol.* 1968;97:23–30. [PMID: 5634442].
2. Martinez-Cabriales SA, Walsh SM, Sade S, Shear NH. Lymphomatoid papulosis: an update and review. *J Eur Acad Dermatol Venereol.* 2019;34:59–73. [PMID: 31494989].
3. Liu HL, Hoppe RT, Kohler S, et al. CD30+ cutaneous lymphoproliferative disorders: the Stanford experience in lymphomatoid papulosis and primary cutaneous anaplastic large cell lymphoma. *J Am Acad Dermatol.* 2003;49:1049–1058. [PMID: 14639383].
4. Tomaszewski MM, Lupton GP, Krishnan J, May DL. A comparison of clinical, morphological and immunohistochemical features of lymphomatoid papulosis and primary cutaneous CD30(Ki1)-positive anaplastic large cell lymphoma. *J Cutan Pathol.* 1995;22:310–318. [PMID: 7499570].
5. Dalle S, Balme B, Thomas L. Lymphomatoid papulosis localized to the face. *Dermatol Online J.* 2006;12:9. [PMID: 16638423].
6. Scarisbrick JJ, Evans AV, Woolford AJ, Black MM, Russell-Jones R. Regional lymphomatoid papulosis: a report of four cases. *Br J Dermatol.* 1999;141:1125–1128. [PMID: 10606866].
7. Yancovitz M, Walters RF, Kamino H, Brown LH. Acral lymphomatoid papulosis. *J Am Acad Dermatol.* 2010;62:530–531. [PMID: 20159331].
8. Kempf W, Kazakov DV, Baumgartner HP, Kutzner H. Follicular lymphomatoid papulosis revisited: a study of 11 cases, with new histopathological findings. *J Am Acad Dermatol.* 2013;68:809–816. [PMID: 23375516].
9. Barnadas MA, Lopez D, Pujol RM, et al. Pustular lymphomatoid papulosis in childhood. *J Am Acad Dermatol.* 1992;27:627–628. [PMID: 1401319].
10. Chimenti S, Fagnoli MC, Pacifico A, Peris K. Mucosal involvement in a patient with lymphomatoid papulosis. *J Am Acad Dermatol.* 2001;44(2 Suppl):339–341. [PMID: 11174410].
11. Sureda N, Thomas L, Bathelier E, et al. Bullous lymphomatoid papulosis. *Clin Exp Dermatol.* 2011;36:800–801. [PMID: 21575041].
12. Bekkenk MW, Geelen FA, van Voorst Vader PC, et al. Primary and secondary cutaneous CD30(+) lymphoproliferative disorders: a report from the Dutch Cutaneous Lymphoma Group on the long-term follow-up data of 219 patients and guidelines for diagnosis and treatment. *Blood.* 2000;95:3653–3661. [PMID: 10845893].
13. Swerdlow SH, Campo E, Pileri SA, et al. The 2016 revision of the World Health Organization classification of lymphoid neoplasms. *Blood.* 2016;127:2375–2390. [PMID: 26980727].
14. Fernandez-de-Misa R, Hernandez-Machin B, Servitje O, et al. First-line treatment in lymphomatoid papulosis: a retrospective multicentre study. *Clin Exp Dermatol.* 2018;43:137–143. [PMID: 28994134].
15. Pierard GE. A reappraisal of lymphomatoid papulosis and of its follicular variant. *Am J Dermatopathol.* 1981;3:179–181. [PMID: 7270815].
16. Kato N, Matsue K. Follicular lymphomatoid papulosis. *Am J Dermatopathol.* 1997;19:189–196. [PMID: 9129706].
17. Crowson AN, Baschinsky DY, Kovatich A, Magro C. Granulomatous eccrinotropic lymphomatoid papulosis. *Am J Clin Pathol.* 2003;119:731–739. [PMID: 12760293].
18. Martires KJ, Cohen BE, Cassarino DS. CD30+ lymphoproliferative disorder with spindle-cell morphology. *J Cutan Pathol.* 2016;43:1041–1044. [PMID: 27433975].
19. Jain N, Gutte R, Jadhav P, Khopkar U. Granulomatous and eccrinotropic lymphomatoid papulosis. *Indian J Dermatol Venereol Leprol.* 2012;78:82–84. [PMID: 22199065].
20. Ba W, Yang Y, Zhang Z, et al. Lymphomatoid papulosis with folliculotropism, eccrinotropism and neurotropism. *J Cutan Pathol.* 2018;45:530–534. [PMID: 29660166].
21. Samols MA, Su A, Ra S, et al. Intralymphatic cutaneous anaplastic large cell lymphoma/lymphomatoid papulosis: expanding the spectrum of CD30-positive lymphoproliferative disorders. *Am J Surg Pathol.* 2014;38:1203–1211. [PMID: 24805854].
22. Wang T, Guo CL, Xu CC, et al. Regional lymphomatoid papulosis in association with pseudoepitheliomatous hyperplasia: 13 years follow-up. *J Eur Acad Dermatol Venereol.* 2015;29:1853–1854. [PMID: 24841636].
23. Kempf W, Kazakov DV, Scharer L, et al. Angioinvasive lymphomatoid papulosis: a new variant simulating aggressive lymphomas. *Am J Surg Pathol.* 2013;37:1–13. [PMID: 23026936].
24. Vincek V. In: *Dermatopathology Compass.* Vincek V editor 1<sup>st</sup> ed. Amazon; 2021.p.114-123.
25. Kempf W, Ostheeren-Michaelis S, Paulli M, et al. Granulomatous mycosis fungoides and granulomatous slack skin: a multicenter study of the Cutaneous Lymphoma Histopathology Task Force Group of the European Organization for Research and Treatment of Cancer (EORTC). *Arch Dermatol.* 2008;144:1609-17. [PMID: 19075143].
26. Gallardo F, Garcia-Muret MP, Servitje O, et al. Cutaneous lymphomas showing prominent granulomatous component: clinicopathological features in a series of 16 cases. *J Eur Acad Dermatol Venereol.* 2009;23:639-47. [PMID: 19207677].
27. Rysgaard CD, Stone MS. Lymphomatoid granulomatosis presenting with cutaneous involvement: a case report and review of the literature. *J Cutan Pathol.* 2015;42:188-193. [PMID: 25355540].
28. Kampa F, Mitteldorf C. A review of CD30 expression in cutaneous neoplasms. *J Cutan Pathol.* 2021;48:495-510. [PMID: 33047376].

## Potential conflicts of interest

The authors declare no conflicts of interest.