

# UCSF

## UC San Francisco Previously Published Works

### Title

International Surgical Week ISW 2011

### Permalink

<https://escholarship.org/uc/item/5bf242t0>

### Journal

World Journal of Surgery, 35(Suppl 1)

### ISSN

0364-2313

### Authors

Juillard, Catherine  
Mballa, Georges Alain Etoundi  
Ndongo, Chancelline Bilounga  
et al.

### Publication Date

2011-08-01

### DOI

10.1007/s00268-011-1190-8

Peer reviewed

# International Surgical Week ISW 2011

Yokohama, Japan, August 28–September 1, 2011



Exploring the Future of Surgery

International Society of Surgery  
Société Internationale de Chirurgie  
ISS/SIC



**and its Integrated Societies**

International Association of Endocrine Surgeons (IAES)  
International Association for Trauma Surgery and Intensive Care (IATSIC)  
International Association for Surgical Metabolism and Nutrition (IASMEN)  
Breast Surgery International (BSI)  
International Society for Digestive Surgery (ISDS)

This supplement was not sponsored by outside commercial interests. It was funded entirely by the publisher.

## Congress Organization and Committees

### Organizing Society

International Society of Surgery (ISS)  
Soci t  Internationale de Chirurgie (SIC)  
Seltisbergerstrasse 16  
4419 Lupsingen  
Switzerland  
www.iss-sic.ch

### Congress President

Kenneth D. Boffard, South Africa

### Congress Vice Presidents

Akimasa Nakao, Japan (ISS/SIC)  
Gerard M. Doherty, USA (IAES)  
Ian D. Civil, New Zealand (IATSIC)  
Dan L. Waitzberg, Brazil (IASMEN)  
Kerstin Sandelin, Sweden (BSI)  
Chung-Mau Lo, China PR (ISDS)

### ISS/SIC Program Committee

President	
& Congress President	Kenneth D. Boffard, Johannesburg, South Africa
President elect ISS/SIC	G�ran Akerstr�m, Uppsala, Sweden
Immediate Past President	Michael G. Sarr, Rochester, USA
Secretary General ISS/SIC	Jean-Claude Givel, Lausanne, Switzerland
General Treasurer	Sats S. Pillay, Port Elizabeth, South Africa
Editor in Chief WJS	John G. Hunter, Portland, USA
Councilor	Abdel-Hadi S.T. Al-Briezat, Amman, Jordan
Councilor	Dionysios Voros, Athens, Greece
Councilor	Nopadol Wora-Urai, Bangkok, Thailand
Councilor	Tatsuo Yamakawa, Tokyo, Japan
IAES Representative	Leigh W. Delbridge, St. Leonards, Australia
IATSIC Representative	C. William Schwab, Philadelphia, USA
IASMEN Representative	Olle Ljungqvist, �rebro, Sweden
BSI Representative	Jay K. Harness, Orange, USA
ISDS Representative	Masaki Kitajima, Tokyo, Japan

### Integrated Societies of ISS/SIC

and their Representatives

IAES	The International Association of Endocrine Surgeons Leigh W. Delbridge, Australia – Geoffrey B. Thompson, USA
IATSIC	The International Association for Trauma Surgery and Intensive Care C. William Schwab, USA – Erwin R. Thal, USA
IASMEN	The International Association for Surgical Metabolism and Nutrition Olle Ljungqvist, Sweden – Jos� E. Aguilar-Nascimento, Brazil
BSI	Breast Surgery International Jay K. Harness, USA – Gaurav Agarwal, India
ISDS	International Society for Digestive Surgery Masaki Kitajima, Japan – Tonia Young-Fadok, USA – Go Wakabayashi, Japan

### Participating Societies

and their Representatives in the Program Committee of ISW 2011

AAST	American Association for the Surgery of Trauma Andrew B. Peitzman, USA – C. William Schwab, USA
APIMSF	The Ambroise Par� International Military Surgery Forum Fran�ois Pons, France – Norman M. Rich, USA
AWS	Association of Women Surgeons Patricia Numann, USA – Hilary A. Sanfey, USA
EAES	European Association for Endoscopic Surgery Abe Fingerhut, France – Selman Uranues, Austria
ELSA	Endoscopic and Laparoscopic Surgeons of Asia Min Hua Zheng, China PR
FELAC	Federaci�n Latinoamericana de Ciru�a Italo Braghetto, Chile – Samuel Shuchleib, Mexico
IFSES	International Federation of Societies of Endoscopic Surgeons Alberto Chousleb, Mexico – Jacques P�rissat, France – Tatsuo Yamakawa, Japan
ISBI	International Society for Burn Injuries Basil A. Pruitt, Jr., USA – Richard L. Gamelli, USA
JAWS	Japan Association of Women Surgeons Yasuko Tomita, Japan
JBCS	The Japanese Breast Cancer Society Tadashi Ikeda, Japan
JEAS	Japanese Association of Endocrine Surgeons Hiroshi Takami, Japan
JSACS	Japanese Society for the Acute Care Surgery Yasuhiro Otomo, Japan
JSES	Japanese Society for Endoscopic Surgery Seigo Kitano, Japan

---

JSGS	The Japanese Society of Gastroenterological Surgery Kenichi Sugihara, Japan
JSPS	Japanese Society of Pediatric Surgeons Tadashi Iwanaka, Japan
JSS	Japan Surgical Society Susumu Satomi, Japan
JSSMN	Japanese Society for Surgical Metabolism and Nutrition Katsuyoshi Hatakeyama, Japan
WOFAPS	World Federation of Associations of Pediatric Surgeons Jay L. Grosfeld, USA

---

**Local Organizing Committee**

---

Honorary President:	Masaki Kitajima
Honorary Members:	Teruo Kakegawa Yoshiki Hiki Yasuo Idezuki Tatsuo Yamakawa
President:	Masahiko Watanabe
Vice-President:	Seigo Kitano
Secretary General:	Yuko Kitagawa



**Abstract ID: 0001** Specific Field: **Endoscopic Surgery****Mode of pres.: Free Paper**  
**ISW 2011 Session 19.01****The operative management of laparoscopic distal pancreatectomy**

H. Katagiri, Y. Kumamoto, K. Ishii, H. Kamata, H. Tajima, H. Kawamata, K. Nakamura, M. Watanabe

Kitasato university, School of Medicine, Sagamihara, Japan

**Introduction:** The laparoscopic surgery for pancreatic disease is progressing technically. Also this procedure will bring more benefit for the patients as minimally invasive operation. However the safety of procedure and target disease for operation have not been provided a general consensus in Japan. The aim of this study is analyzing of operative outcome of distal pancreatectomy for various tumor and to confirm safety of this procedure.

**Material and Methods:** We performed a retrospective analysis of patients who underwent laparoscopic distal pancreatectomy from 2004 to 2009 at Kitasato university east hospital in Japan. 24 patients were included in the study with varying preoperative diagnosis such as endocrine tumors (7 patients), cystic lesions (8 patients) and IPMN (9 patient). The median age was 54.1 years with female to male ratio of 14:10. Technically, In addition to 3 ports, a hand port was placed in the midline to aid in dissection and the pancreas was divided with a stapler. When we remove pancreas surgically, we spend time more than one minute per single fire to avoid postoperative pancreatic fistula.

**Results:** Of 24 patients, two were converted to an open procedure due to an uncertain adhesion and inadequate exposure. The median operating time was 213 min with a tumor size of 3.8 cm. The median time for resuming regular diet and converting to oral pain medications was 2.5 days and 4 days respectively. The length of hospitalization was 11.6 days (5–17). 22 patients who underwent the laparoscopic operation successfully and these were no postoperative complication. With a median follow up of 27.5 months (1–53), 5 patients with a diagnosis of malignancy have no evidence of recurrence until now.

**Conclusions:** A minimally invasive approach to pancreatic disease is safe and technically feasible. Further large series studies with longer follow up are necessary to determine the role of laparoscopic surgery in the treatment algorithm of management of pancreatic disease.

**Abstract ID: 0002** Specific Field: **Endoscopic Surgery****Mode of pres.: Free Paper**  
**ISW 2011 Session 19.02****Single incision laparoscopic surgery for totally extraperitoneal inguinal hernia repair: a clinical case report of 58 patients**

M. Kitamura, Y. Hirata, M. Onayama, Y. Takahashi, R. Ota, Y. Kawahara, M. Gto, K. Sekikawa

Kawasaki Saiwai Hospital, Kawasaki, Japan

**Introduction:** Performing laparoscopic operations through one single skin incision has recently emerged as a possible alternative to conventional laparoscopy in a variety of surgical cases. We were started single incision laparoscopic surgery for totally extraperitoneal inguinal hernia repair (Single-TEP) in August 2009. Here we report the operation procedure of Single TEP and its current situation.

**Material and Methods:** During the period from August 2009 to December 2010, 58 consecutive patients underwent Single-TEP. Single-TEP was performed under general anesthesia. Concerning

approach of Single-TEP, we use multi trocar approach for 7 patients and multiple-channel port for 51 patients.

**Results:** Among the 58 patients (average age: 65.6 years, 47 males and 11 females), a total of 63 hernias were repaired. Unilateral hernias were present in 53 patients and bilateral hernias were in 5 patients. We also operated three patients with hernia recurrence. Mean operative times for unilateral and bilateral hernia were 77.6 (range; 45–142) min and 111.8 (range; 80–143) min each. Multi trocar method, because it was difficult to insert the trocar two patients who underwent preperitoneal space, we have changed the expression from double incision laparoscopic surgery for totally extraperitoneal inguinal hernia repair procedures. There was no complications during intra- nor postoperation. Mean hospital stay was 1.10 (range; 0–2) days.

**Conclusions:** Single incision laparoscopic surgery for totally extraperitoneal inguinal hernia repair is feasible technique comparing conventional approach for TEP. However we should have sufficient technical knowledge and the technique for endoscopic surgery to do this surgical procedure safely. Moreover Single-TEP of hernias provides excellent cosmetic results comparing conventional approach.

**Abstract ID: 0003** Specific Field: **Endoscopic Surgery****Mode of pres.: Free Paper**  
**ISW 2011 Session 19.03****Surgical outcomes of laparoscopy-assisted gastrectomy versus open gastrectomy for gastric cancer: a case-control study**

C. Kunisaki [1], T. Kosaka [1], T. Oshima [1], S. Fujii [1], R. Takagawa [2], H. Makino [2], H. Akiyama [2], I. Endo [2]

[1] Yokohama City University, Gastroenterological Center, Yokohama, Japan, [2] Yokohama City University, Graduate School of Medicine, Yokohama, Japan

**Introduction:** To clarify the technical feasibility and oncological efficacy of laparoscopy-assisted gastrectomy (LAG) for gastric cancer compared with open gastrectomy (OG).

**Material and Methods:** Between April 2002 and March 2008, a series of 623 patients with gastric cancer underwent curative R0 gastrectomy (314 patients underwent LAG and the remaining 309 patients underwent OG) Age, gender, lymph node dissection, and pathological stage were matched by propensity scoring, and 222 patients (111 LAG patients and 111 OG patients) were selected for analysis.

**Results:** There was no significant difference in preoperative characteristics between the two patient groups. Regarding intraoperative characteristics, blood loss was significantly lower in the LAG group (159 ml) than the ODG group (274 ml), while operation time was significantly longer in the LAG group (276 min) than the OG group (235 min). The degree of lymph node dissection and number of retrieved lymph nodes did not differ between the two groups. Macroscopic tumor type was the only significant pathological finding difference between groups, with the LAG group having a significantly frequent occurrence of superficial tumor type. There were no significant differences in postoperative courses or overall and disease-specific survivals (86.2% vs. 86.0%,  $P = 0.3540$ ; 100% vs. 98.7%,  $P = 0.3571$ ) except time to first flatus and time to use of non-steroidal anti-inflammatory derivatives between the two groups.

**Conclusions:** LAG for gastric cancer may be both feasible and safe. However, it will be necessary to conduct a well-designed randomized controlled trial comparing short-term and long-term outcomes between LAG and OG in a larger number of patients.

**Abstract ID: 0004** Specific Field: **Endoscopic Surgery**

**Mode of pres.: Free Paper**  
**ISW 2011 Session 19.04**

**Auto-fluorescence imaging for detecting superficial liver tumors in laparoscopic surgery**

M. Minagawa [1], I. Kurosaki [1], K. Hatakeyama [1], C. Kitami [1], K. Takano [2]

[1] Digestive and General Surgery, Niigata University, Niigata, Japan,  
 [2] Niigata University, Japan

**Introduction:** Laparoscopic liver surgery has recently been performed in patients with severe liver cirrhosis. Detection of small superficial liver tumors is sometimes difficult in cirrhotic liver. Especially in laparoscopic surgery, visual approach for tumor detection is only permitted. As a new approach for detection of superficial liver tumor, we have been trying auto-fluorescence imaging (AFI) in detection of superficial liver tumors. This technique has been developed in order to detect submucosal tumors in endoscopic diagnosis. We also have reported a case in whom we succeed in using auto-fluorescence imaging to detect small hepatocellular carcinoma (HCC) invisible ultrasonography. This study evaluated the limitation and the feasibility of AFI during laparoscopic liver surgery.

**Material and Methods:** Six patients underwent AFI during open (3 patients) or laparoscopic liver surgery (3 patients). The range of tumor size was 1 to 3 cm. Superficial liver tumors (HCC 3, metastatic tumor 2, other 1) were evaluated in size and depth from the hepatic surface in pre-operative computed tomography. In two patients, both AFI and infra-red radiation (IRI) were performed and these methods were compared in discrimination and resolution.

**Results:** All tumors were identified using intra-operative ultrasonography. Tumors located more than 3 mm in depth were unable to be detected with AFI. It was difficult to classify tumor types using AFI. IRI was superior to AFI in resolution. Otherwise, the specificity of tumor detection in cirrhotic liver was higher in AFI than IRI.

**Conclusions:** AFI is feasible for detection of small superficial liver tumors, though the detection of tumor is limited in depth. However, AFI is needed to improve the resolution in order to find micro tumors. AFI may become one of useful techniques for laparoscopic surgery in the future.

**Abstract ID: 0005** Specific Field: **Endoscopic Surgery**

**Mode of pres.: Free Paper**  
**ISW 2011 Session 19.05**

**Laparoscopic surgery for colorectal cancer with the umbilical reconstruction: the examination of validity for cosmetic and surgical site infection**

M. Naito, M. Watanabe, T. Sato, A. Ikeda, N. Ogura, W. Onozato, T. Nakamura

Kitasato University, Sagamihara, Japan

**Introduction:** Laparoscopic surgery for colorectal cancer by the umbilical approach is excellent in cosmetic and minimally invasive procedure. However, there are demerits that surgical site infection (SSI) increases for detrition of tissue, and the length of wound needs for extraction of tumor. We performed laparoscopic surgery for colorectal cancer with the umbilical trimming and reconstruction. Thereby, we improved in cosmetic of wound, and make SSI decrease. Here we clarify the efficacy and safety of laparoscopic surgery for colorectal cancer with the umbilical reconstruction.

**Material and Methods:** There were 74 patients (median age, 68 years, range 40–82) who underwent laparoscopic colorectal surgery with the umbilical reconstruction from January to December 2010. We examined operative times, the amount of bleeding, and complications. The procedure was performed by the vertical incision of umbilicus, and reconstructed the umbilicus after the trimming of the umbilical skin.

**Results:** The procedure was underwent the resection to 27 patients, the left side colectomy to 27 patients, the right side colectomy to 18 patients, and the partial resection to 4 patients. As for the anastomosis between two bowels, 46 patients performed double stapling technique and 27 patients performed functional end to end anastomosis. The median lengths of umbilical incision were 40 mm (range 15–100). The median operation time was 210 min (range 63–425) and the median amounts of bleeding were 30 ml (range 5–210). Post- and intraoperative complications occurred in 13 patients, including six (8.1%) with SSI, five (6.8%) with anastomotic leakage, two (2.7%) with anastomotic bleeding, one (1.4%) with bowel obstruction, and one (1.4%) with small bowel injury.

**Conclusions:** Since the skin of umbilicus is extended easily, the length of skin incision have been shorter than incision of peritoneum and rectus sheath. In addition, the umbilical trimming and reconstruction have made postoperative scar unremarkable, and reduced SSI rates. In this examination, we have shown that laparoscopic surgery for colorectal cancer with the umbilical reconstruction is technically safe and minimally invasive procedure.

**Abstract ID: 0006** Specific Field: **Endoscopic Surgery**

**Mode of pres.: Free Paper**  
**ISW 2011 Session 19.06**

**A new hybrid technology of laparoscopy assisted endoscopic full thickness resection for intraluminal type SMT of the stomach**

M. Terashima, M. Tokunaga, E. Bando, Y. Tanizawa, T. Kawamura, Y. Kinugasa, K. Uesaka, H. Ono

Shizuoka Cancer Center, Nagaizumi-Cho, Japan

**Introduction:** Submucosal tumor (SMT) of the stomach is a good candidate for minimal-invasive surgery. Laparoscopic partial gastrectomy using linear stapler is most popular procedure for this type of tumor. However, delayed gastric emptying due to severe deformity of the stomach after partial gastrectomy is sometimes observed in patients with intraluminal type SMT especially located near the cardia or the pylorus. Recently, several investigators had been reported the usefulness of hybrid technology using laparoscopic and endoscopic procedure to prevent the deformity of the stomach after partial gastrectomy. Even though using this modern technology, deformity of the stomach is sometimes inevitable if the surgeons use linear staple for tumor located near the cardia or the pylorus. Therefore, we have developed a new hybrid technology to avoid the gastric deformity for intraluminal type SMT of the stomach.

**Material and Methods:** At first, vessels around the tumor were dissected using ultrasonically activated device under usual laparoscopic procedure. Mucosal and submucosal layers around the tumor were cut circumferentially using the technique of endoscopic submucosal dissection via intraluminal endoscopy. Then, full thickness of gastric wall was also dissected under intraluminal endoscope using IT knife2 under the observation and guide of laparoscope. Tumor was completely dissected circumferentially using intraluminal endoscope, and retrieved from abdominal cavity with usual laparoscopic procedure. Seromuscular layer of the stomach was sutured using hand-sawn technique under laparoscope, and mucosal

and submucosal layer was closed using hemostatic clip under intraluminal endoscope.

**Results:** From January 2010 to August 2010, this operation was performed for a total of 6 patients. The pathological diagnosis was GIST in all patients. The median operation time was 166 (122–207) min, and the median estimated blood loss was 0 (0–304) ml. Oral feeding was started at the 3rd postoperative day in all patients. The median duration of hospital stay was 7.5 (6–9) days. The postoperative course was uneventful and delayed gastric emptying was not observed in all patients.

**Conclusions:** Our new hybrid technology of laparoscopy assisted endoscopic full thickness resection appears to be a safe and effective procedure for intraluminal type SMT of the stomach.

**Abstract ID: 0007** Specific Field: **Endoscopic Surgery**

**Mode of pres.: Free Paper**  
**ISW 2011 Session 19.07**

**A laparoendoscopic rendezvous in spatium peritonealis on megasplenectomy for cirrhotic patients with slim chance: a feasibility study**

M. Tomikawa, T. Akahoshi, N. Kinjo, Y. Nagao, N. Hashimoto, H. Uehara, Y. Maehara, M. Hashizume

Kyushu University, Fukuoka, Japan

**Introduction:** We recently experienced 10 cirrhotic patients who had undergone laparoscopic splenectomy, in part of which laparoendoscopic procedures in peritoneal space had been performed. This pilot series mainly focuses on the technical aspects and the immediate results, and points out the problems of this technique to be overcome in the future.

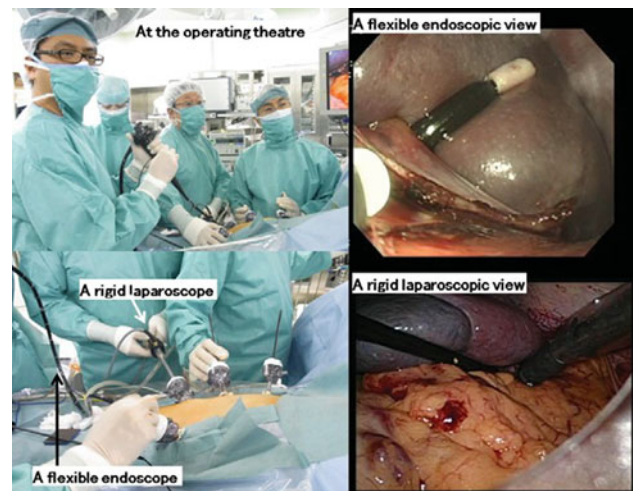
**Material and Methods:** Patients: From November 2009 to September 2010, 10 cirrhotic patients with hypersplenism were entered in this feasibility study. They were indicated to undergo splenectomy to treat portal hypertension and to facilitate the initiation and completion of either PEG-IFN therapy or anti-cancer therapy for hepatocellular carcinoma.

**Techniques:** To dissect the marginal region between the left diaphragm and the upper pole of the spleen and to dissect the upper end of the gastrosplenic ligament, a conventional flexible single-channel endoscope was simultaneously introduced with the use of a rigid laparoscope. The dissection was performed mainly using an insulation-tipped electro-surgical knife.

**Results:** The flexible endoscope offered a magnified operative view, a water-jet lens cleaner and a powerful lavage capability. The upper pole of the spleen could be easily seen with the tip-bending function of the flexible endoscope especially in the case with splenomegaly. All of the patients tolerated the operations well. None of the patients required a conversion to open surgery, and encountered major intraoperative complications. All of the patients tolerated the operations well. The subsequent therapies were performed as planned in all patients with the higher platelet count than before splenectomy.

**Limitations:** Considering feasibility of pure NOTES from this study, the loss of orientation, the acquisition of a good operative view with adequate lifting of the megaspleen, the lack of light intensity, and the narrow view angle of a flexible endoscope were still the problems that should be overcome.

**Conclusions:** The laparoendoscopic procedures in peritoneal space demonstrated to be feasible for cirrhotic patients with splenomegaly. The patients with slim chances could receive further subsequent planned main therapies.



**Figure:** A laparoendoscopic rendezvous in laparoscopic splenectomy

**Abstract ID: 0008** Specific Field: **Endoscopic Surgery**

**Mode of pres.: Free Paper**  
**ISW 2011 Session 19.08**

**Single incision laparoscopic surgery (SILS) with colon lifting method for right sided and sigmoid colon cancer: comparison of short-term outcomes between standard multiport laparoscopic surgery and SILS**

S. Fujii [1], K. Watanabe [1], M. Ota [2], K. Tatsumi [2], H. Suwa [2], Y. Ichikawa [2], C. Kunisaki [1], I. Endo [2]

[1] Yokohama City University, Yokohama, Japan, [2] Yokohama City University, Graduate School of Medicine, Yokohama, Japan

**Introduction:** There are still many problems on the procedure in SILS; especially difficulties to doing effective counter traction. (Aim) To show the usefulness of colon lifting method and the short-term result.

**Material and Methods:** This method was indicated to the right (RC) and sigmoid (SC) colon of T1. The port was placed only at the navel. A suture string penetrated the mesocolon and then was lifted and fixed at the abdominal wall. The main nutrient artery was stretched in the mesocolon, so the lymph node dissection was performed easily with medial approach. In the sigmoid colon, the lifted-up colon was moved to the left upper abdominal wall when the anal side colon was dissected, and thus, the anal side colon was straightened. Pulling the colon by the forceps to the caudal direction formed triangle-shaped traction. (Method) Between 2006 and 2010, short-term results were compared between SILS (S) and multiport (M) which backgrounds were case-matched. From 2006, an advisor passed Endoscopic Surgical Skill Qualification System.

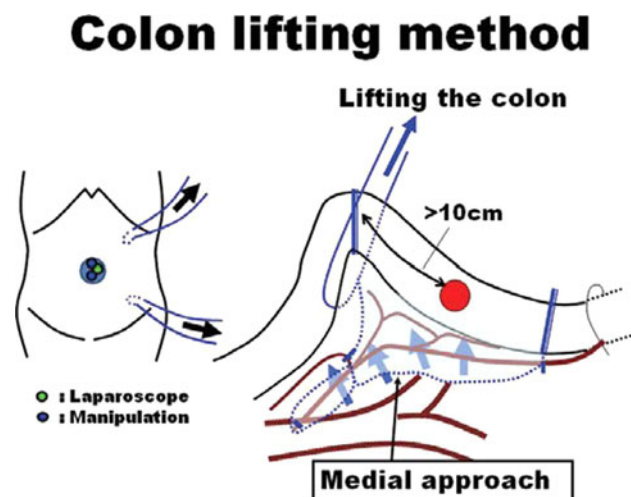
**Results:** Twenty patients (10 RC, 10 SC) were operated by S and 68 (16 RC, 52 SC) by M. There was no difference between two groups in background factors excluding lesion site. There was no difference in the number of dissected lymph nodes (S:M = 20:23), operation time (min) (177:179), intraoperative bleeding(ml) (8:60), conversion rate to open surgery (%) (0:2.9), postoperative complication rate (%) (15:24) and postoperative hospital stay (days) (8.6:10.7 days) except wound length (cm) (3.4:5.4,  $v < 0.05$ ).



**Conclusions:** SILS with colon lifting method was advantageous in the point that the radical surgery can be performed without increasing ports and incision. Further technical improvement will be expected in SILS in near future.

Comparison of short-term outcomes between standard multiport laparoscopic surgery and SILS

	multiport laparoscopic surgery	SILS	<i>P</i>
Number of dissected lymph nodes	23.0	19.5	0.224
Operation time (min)	179	177	0.902
Bleeding (ml)	60	8	0.319
Conversion rate to open surgery (%)	2.9	0	1.000
Early complication rate (%)	23.5	15.0	0.544
Postoperative hospital stay (days)	10.7	8.6	0.328
Maximum wound length (cm)	5.4	3.4	<0.001



**Figure:** Colon lifting method

**Abstract ID: 0009** Specific Field: **Endoscopic Surgery**

**Mode of pres.: Free Paper**  
ISW 2011 Session 19.09

**A new approach of renal hilum control in retroperitoneoscopic radical nephrectomy**

W. An, W. Wang, Y. Wang, J. Wang, J. Gao, Y. Sun

The First Bethune Hospital of Jilin University, Changchun, China, People's Republic

**Introduction:** Renal hilum control plays a key role in a successful laparoscopic radical nephrectomy. Nowadays, the renal hilum control through the posteriorpararenal space approach has been widely used in retroperitoneoscopic radical nephrectomy for kidney neoplasms. But the severe complications and the conversion to an open procedure

always can be found by using posteriorpararenal space approach, especially for the patients with bigger size of tumor and synechia around renal hilum. The aim of this study is to investigate a new approach of renal hilum control-lower pole of kidney approach in retroperitoneoscopic radical nephrectomy.

**Material and Methods:** 95 patients with various types of renal disease received retroperitoneoscopic radical nephrectomy in our department from January 2009 to January 2011. 48 cases of renal hilum control were treated through posteriorpararenal space approach (group A) and 47 cases of renal hilum control were treated through lower pole of kidney approach (group B). The clinical data of age, sex, body mass index, tumor size, average operative time, amount of bleeding, volume of drainage solution and length of hospitalization were analyzed retrospectively.

**Results:** Because of the difficulty of operation, the average operative time of group B was significantly prolonged compared to the group A (group B vs. group A:  $174 \pm 20.3$  min vs.  $142 \pm 15.7$  min), consistent with the tumor size (group B vs. group A:  $5.2 \pm 0.3$  vs.  $3.2 \pm 0.2$  cm<sup>3</sup>). Furthermore, there were 8 cases of renal hilum control converted from posteriorpararenal space approach to lower pole of kidney approach because of the difficulty during the term of renal hilum mobilization. There was no significant difference of age, sex, body mass index, amount of bleeding, volume of drainage solution and hospital stay between two groups.

**Conclusions:** For the patient with bigger size of tumor, mid-pole of kidney tumor or severe synechia, renal hilar control through lower pole of kidney approach may be a safe and reliable pathway for retroperitoneoscopic radical nephrectomy with the advantages of clear anatomic landmarks, less complication.

**Abstract ID: 0010** Specific Field: **Endoscopic Surgery**

**Mode of pres.: Poster Discussion**  
ISW 2011 Session 60.01

**Surgical outcome of laparoscopy-assisted proximal gastrectomy for early upper gastric cancer: compared with conventional open proximal gastrectomy**

N. Futawatari [1], S. Sakuramoto [2], N. Katada [2], S. Kikuchi [2], Y. Nishi [1], Y. Yasogawa [1], M. Watanabe [2]

[1] Kitasato University Kitasato Institute Medical Center Hospital, Kitamoto, Japan, [2] School of Medicine, Kitasato University, Sagami-hara, Japan

**Introduction:** We investigated the effects of laparoscopy-assisted proximal gastrectomy (LAPG) as a minimally invasive approach to treating early upper gastric cancer.

**Material and Methods:** We compared clinicopathological factors and postoperative functions between patients with upper early gastric cancer who underwent LAPG ( $n = 21$ ) and open proximal gastrectomy (PG;  $n = 20$ ) at our hospital between January 2006 and July 2008 and between January 2001 and December 2007, respectively. Reconstructive surgery comprised esophagogastrostomy and fundoplication, and side-to-side anastomosis was performed using a linear stapler for the LAPG group and a 25-mm circular stapler for the PG group (28-mm for one patient).

**Results:** Almost clinicopathological factors and postoperative functions did not significantly differ between the two groups. The following significantly differed between the LAPG and PG groups: operation time, 286.0 vs. 164.4 min; blood loss, 94.3 vs. 652.5 ml, start of oral ingestion, 4.2 vs. 7.4 days and postoperative stay, 12.7 vs. 16.4 days. Complications comprised leakage in one patient in the LAPG group and abdominal abscess and cholecystitis in one patient

each in the PG group. Due to postoperative anastomotic stricture, endoscopic dilatation was performed on one and four patients in the LAPG and PG groups, respectively, and the incidence of endoscopic reflux esophagitis was 42.8 and 20%, respectively.

**Conclusions:** The LAPG approach required more time, but blood loss was less, the postoperative stay was shorter, the therapeutic results were more favorable and the incidence of anastomotic stricture was low. Thus LAPG appears to be a useful technique. However, measures are required to lower the incidence of reflux esophagitis.

#### Abstract ID: 0011 Specific Field: Endoscopic Surgery

**Mode of pres.: Poster Discussion**  
ISW 2011 Session 60.02

##### Prospective randomized multi-institutional study of single incision versus laparoscopic cholecystectomy

S. Obara [1], A. Sasaki [2], G. Wakabayashi [2]

[1] Iwate Prefectural Kamaishi Hospital, Kamaishi, Japan, [2] Iwate Medical University, Morioka, Japan

**Introduction:** Single incision laparoscopic surgery offers improved cosmesis over, and usually causes less incisional pain than traditional laparoscopic surgery. We report a prospective randomized multi-institutional study of single incision laparoscopic cholecystectomy (SILC) versus laparoscopic cholecystectomy (LC) in patients with symptomatic cholelithiasis or benign gallbladder polyps.

**Material and Methods:** Forty-two patients were randomized to SILC or LC using the 4-port technique (21 in each group). The exclusion criteria were American Society of Anesthesiologists Class more than 3, age older than 80 years, previous major upper abdominal surgical procedures, severe cholecystitis or pancreatitis, and acute cholecystitis or choledocholithiasis. Variables analyzed included demographic and operative data, incisional pain and cosmesis. To assess these variables on postoperative days 3 and 14, a visual analog scale (VAS) was used (i.e., a 10-point score ranging from 0 [no pain] to 10 [worst possible pain] and 0 [worst] to 10 [best] for cosmesis).

**Results:** SILC and LC were performed successfully in all 42 patients. No significant differences were noted between the groups for blood loss, length of hospital stay, or complications. The mean operating time was significantly longer in the SILC group than in the LC group (86 vs. 69 min;  $P = 0.021$ ). The group's mean VAS scores for incisional pain on postoperative days 3 and 14 did not differ significantly, but the mean VAS score for cosmetic outcome on postoperative day 14 was significantly greater in the SILC group than in the LC group (9.8 vs. 9.4;  $P = 0.031$ ).

**Conclusions:** Although SILC takes longer than LC, under experienced laparoscopic surgeons can perform SILC safely with results comparable with LC. SILC is superior to LC in terms of short-term cosmetic outcomes, but not incisional pain or requirement for analgesics.

#### Abstract ID: 0012 Specific Field: Endoscopic Surgery

**Mode of pres.: Poster Discussion**  
ISW 2011 Session 60.03

##### SILS: single incision laparoscopic surgery, a bridge toward NOTES—the case of appendectomy

K. Pinnagoda, O. Martinet, D. Roulet, E. Pezzetta

Hopital RIVIERA Montreux, Switzerland

**Introduction:** minimally invasive surgery techniques are in continuous and dramatic evolution, NOTES with surgical procedures performed through natural access is, nowadays, the ultimate acquisition in this field.

With SILS, or single-incision laparoscopic surgery, surgeons make only one incision instead of several through the abdominal wall. For patients fewer incisions can mean a faster recovery, less risk for infection or later hernia, less risk for bleeding, and less pain.

**Material and Methods:** we present an institutional retrospective evaluation of the experience with the SILS concept in patients presenting right lower quadrant abdominal pain or clinical uncomplicated appendicitis and submitted to laparoscopic exploration and appendectomy. Postoperative QOL was evaluated with SF-12 health status questionnaire.

**Results:** between the 01 June 2007 and 31 December 2008 we performed 22 single incision laparoscopic explorations of the right lower quadrant and appendectomy. There were 10 male and 12 female patients with a mean age of 21.05 years. The mean duration of the procedure was 30.4 min and the mean length of the hospital stay was 24.5 h. Conversion to conventional three ports laparoscopy was necessary in 2 cases (9%). Post-operative complications were encountered 1 case (4.5%) presenting with a late wound infection.

**Conclusions:** Technically easy to perform, the SILS technique can be considered as a compromise between conventional laparoscopic surgery and NOTES. In the case of appendectomy the procedure may be indicated in cases of clinical pictures of lower quadrant abdominal pain or clinical uncomplicated acute appendicitis. The procedure can be accomplished with low postoperative morbidity, a quick recovery time, and a high degree of satisfaction for the patients.

#### Abstract ID: 0013 Specific Field: Endoscopic Surgery

**Mode of pres.: Video**  
ISW 2011 Session 62.01

##### Laparoscopic splenectomy in one hundred HCV-cirrhotic patients with hypersplenism and thrombocytopenia

T. Akahoshi, Y. Maehara, M. Tomikawa, M. Hashizume

Kyushu University, Fukuoka, Japan

**Introduction:** We intended to determine whether laparoscopic splenectomy (Lap-Sp) contributes to the treatment of interferon therapy in the HCV patients with thrombocytopenia due to hypersplenism.

**Material and Methods:** From September 2002 to August 2009, 100 cirrhotic patients (54 men and 46 women) underwent laparoscopic splenectomy for a clinical application of peginterferon alpha and ribavirin combination therapy (PEG-IFN and RBV). All patients were Child's class A or B with thrombocytopenia (less than  $9.0 \times 10^4/\text{mm}^3$ ). Their HCV genotypes were 80 patients with Type 1 and 20 with Type 2.

**Results:** Pure laparoscopic or hand-assisted laparoscopy was performed in 78 and 22 patients, respectively, without mortality. Conversion to open surgery was not required in any patient. Platelet counts improved from a preoperative mean of  $5.6 \pm 2.2 \times 10^4/\text{mm}^3$  to  $22.2 \pm 9.8 \times 10^4/\text{mm}^3$  postoperatively. After surgery, IFN therapy was started in 97 patients (peginterferon and ribavirin: 92 patients, and Interferon monotherapy: 5 patients). 76 patients completed IFN therapy and 32 (42.1%) of them obtained a sustained virologic response (SVR). Eight patients discontinued IFN therapy because of depression, neutropenia or for other reasons excluding thrombocytopenia. Pneumonitis meningitis occurred in one patient during IFN therapy.

**Conclusions:** Lap-Sp permits patients with HCV cirrhosis and hypersplenism to receive enough IFN therapy. Therefore Lap- Sp can become a strong supportive surgery for cirrhotic patients who require antiviral therapy.

**Abstract ID: 0014** Specific Field: **Endoscopic Surgery**

**Mode of pres.: Video**  
**ISW 2011 Session 62.02**

**Efficacy of intracorporeal double stapling gastroduodenostomy: as a technique to progress from laparoscopy-assisted to totally laparoscopic distal gastrectomy**

Y. Hisamatsu, Ikeda, Sonoda, Egashira, Ohga, Morita, Kakeji, Maehara

Department of Surgery and Science, Graduate School of Medical Sciences, Kyushu University, Fukuoka, Japan

**Introduction: Background:** Billroth I (B-I) gastroduodenostomy is an anastomotic procedure used widely after gastric resection for distal gastric cancer. B-I gastroduodenostomy with circular stapler is an anastomotic procedure used popularly in open and laparoscopic assisted distal gastrectomy (LADG). And recently, totally laparoscopic distal gastrectomy (TLDG) is expected as a less invasive method comparison with LADG. The technique of intracorporeal anastomosis without major changing is necessary for the institutions where a LADG is being performed and try to progress to a TLDG.

**Purpose:** The aim of this report is to introduce the technical details of intracorporeal double stapling technique for totally laparoscopic B-I reconstruction after distal gastrectomy for gastric cancer and evaluates its short-term results.

**Material and Methods:** Six patients who underwent a TLDG with double stapling technique between Feb 2010 and Oct 2010 were enrolled in this study. This investigation analyzed the clinicopathological data, the surgical data, and the postoperative outcome.

**Results:** In six patients who underwent this operation, there was no intraoperative complication or conversion to open surgery, and no patient required an extension of the initial incision for anastomosis. The total operation time was  $265 \pm 63$  min and the time required for anastomosis was  $29 \pm 8$  min. The mean length of the incision was 3.5 cm (range, 3.2–3.8 cm). The mean intraoperative blood loss was  $30 \pm 21$  g. Postoperative fluorography revealed no anastomosis leakage or stenosis in any of the patients. Patients resumed an oral liquid diet on postoperative day 3–5, and the mean postoperative hospital stay was 11 days.

**Conclusions:** Double Stapling B-I gastroduodenostomy is feasible and safety. This method is particularly useful for the cases with thick abdominal wall and with the lesion in the comparatively upper part of the stomach.

The surgical results and the postoperative course

Operating Time (min)	265
Anastomotic time (min)	29
Estimated Blood Loss (g)	68
Transfusion [n (%)]	0 (0)
Open conversion [n (%)]	0 (0)
Length of Post-Operative Ileus (day)	1.3

**Table continued**

Anastomotic leakage	0 (0)
Anastomotic hemorrhage	0 (0)
Anastomotic stricture	0 (0)
Wound infection	0 (0)
Mortality [n (%)]	0 (0)
Post-Operative Hospital Stay (day)	11

**Abstract ID: 0015** Specific Field: **Endoscopic Surgery**

**Mode of pres.: Video**  
**ISW 2011 Session 62.03**

**Single-incision laparoscopic transabdominal preperitoneal inguinal hernia repair (SI-TAPP)**

N. Kameyama [1], Y. Kitagawa [2], M. Tomita [1], H. Mitsuhashi [1], N. Matsumoto [1], T. Obuchi [1], Y. Katsuki [1]

[1] International Goodwill Hospital, Yokohama, Japan, [2] Keio University, Tokyo, Japan

**Introduction:** Recently, laparoendoscopic single site surgery (LESS) has become widespread, especially for cholecystectomy and appendectomy. LESS provides “scar-less surgery” resulting in much better cosmetic outcomes and higher patient satisfaction. Laparoscopic inguinal hernia repair procedures are suitable for LESS. This is because t inguinal hernia is a benign disease and therefore the aim of the procedure is to repair the defect without removing organs. Transabdominal preperitoneal inguinal hernia repair (TAPP) enables visualization of the inguinal region on both sides. This procedure allows simultaneous confirmation and pneumoperitoneum-based repair of all hernia orifices. Moreover, it can allow proper diagnosis of recurrent hernia. However, single-incision TAPP (SI-TAPP) is not performed frequently because it entails a highly complex technique.

**Material and Methods:** We performed non-tacking SI-TAPP in patients with symptomatic inguinal hernia and we will present our operation and results. The important features of our technique are the use of a self-gripping mesh (Parietex ProGrip™ Mesh) and running sutures and ligature (preparing end-loop sutures and performing laparoscopic 2-handed ligation (Loop & LTH ligation technique))

**Results:** Repair of 28 lesions was technically successful and was performed without placement of additional trocars. Two of four recurrent inguinal hernia was excluded from the statistics because these cases did not require repair of the peritoneum. The average time required for the Loop & LTH ligation technique was 23 min ( $n = 22$ ), which was lower than the 50 min required for the before ( $n = 4$ ). There were no cases of intraoperative complications or deaths. Postoperative complication was observed in only 1 case (seroma). No recurrence was detected.

Although the SI-TAPP is a technically difficult procedure, especially suturing the peritoneum and ligature, the operative time can be easily reduced by repairing the peritoneal tissue with the Loop & LTH ligation technique that was developed by our group.

**Conclusions:** Non-tacking SI-TAPP is one of the best operations for inguinal hernia. We believe our Loop & LTH ligation technique is the optimal technique for peritoneal repair with SI-TAPP.

**Abstract ID: 0016** Specific Field: **Endoscopic Surgery**

**Mode of pres.: Video**  
**ISW 2011 Session 62.04**

**A technique for reconstruction after laparoscopic total gastrectomy**

S. Mikami [1], T. Fukunaga [1], J. Sakurai [1], T. Enomoto [1],  
 M. Katayama [1], A. Fukuoka [1], N. Miyajima [2], T. Otsubo [1]

[1] St. Marianna University School of Medicine, Kawasaki-shi, Japan,  
 [2] St. Marianna University School of Medicine Toyoko Hospital,  
 Kawasaki-shi, Japan

**Introduction:** As a reconstructive procedure after laparoscopic total gastrectomy, we performed Roux-en Y reconstruction with OrVil under a laparoscope. We report the surgical procedure.

**Material and Methods:** After the completion of lymph node dissection, the esophagus was incised using a linear stapler. Laparoscopy-assisted side-to-side anastomosis with a linear stapler was performed to prepare a Y peduncle. OrVil was inserted into the esophagus through the oral cavity, and a tube was pulled out from the right esophageal stump into the abdominal cavity. In the umbilical region, a 3-cm longitudinal incision was added, and the elevated jejunum was pulled out to the extracorporeal area. The main body of a circular stapler was inserted into the abdominal cavity through the umbilical wound, and esophagojejunostomy was performed employing hemi-DST to complete the reconstructive procedure.

**Conclusions:** This reconstructive procedure requires intraperitoneal manipulation alone, and does not depend on patients' physical status. In addition, the use of OrVil facilitates the insertion/fixation of Anvil head, and this procedure can be applied for high-level anastomosis. In this article, we report our reconstructive procedure and strategies for laparoscopic total gastrectomy.

**Abstract ID: 0017** Specific Field: **Endoscopic Surgery**

**Mode of pres.: Video**  
**ISW 2011 Session 62.05**

**HALS-anterolateral approach for ultrasplenomegaly as safe and easy procedure**

M. Tori, H. Akamatsu, S. Ueshima, T. Omori, M. Tei, K. Tanaka,  
 M. Wakasugi, T. Nishida

Osaka Police Hospital, Osaka, Japan

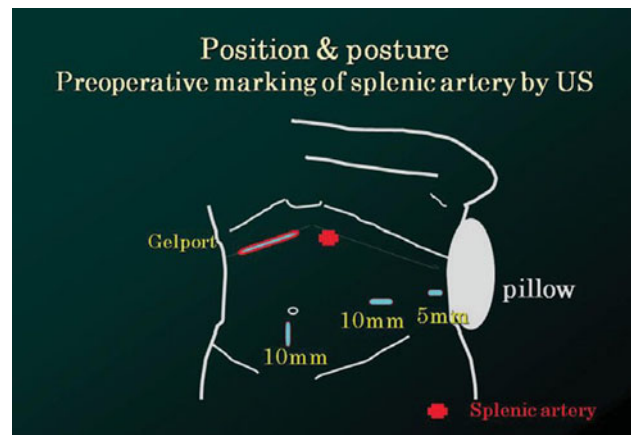
**Introduction:** Though laparoscopic splenectomy (LS) seems to be a standard method for normal-sized spleen, it cannot always be applied to splenomegaly. To get good view for performing splenectomy for ultrasplenomegaly, we developed "anterolateral approach" with hand-assisted laparoscopic maneuver. We present the essence of our methods.

**Material and Methods:** For the last 5 years, 13 patients with splenomegaly were treated with operations for splenectomy in our hospital. HALS with transperitoneal "antero-lateral" approach was performed in 7 patients (group A). Other cases consisted of open splenectomy ( $n = 3$ , group B) or conventional LS ( $n = 3$ ) (group C). The patients' features, the operative details and the postoperative outcomes in both groups were examined and compared with each other.

**Results:** In group A&B, the average hospital stay was 7 days, while 15 days in group C. Operation time, intraoperative blood loss did not show any difference. As to the intraoperative and postoperative

complications, there were none in all cases. (Case presentation with VTR) A male patient suffered Banti syndrome (4500 g with the maximum length of 35 cm). The site of splenic artery was evaluated and marked by US before op. Semilateral decubitus position on the right side is placed. Skin incision for 3 ports, one of which was just left side of umbilicus and the other two were along the subcostal lesion, and one Gel-port (right subcostal lesion) was made. First, the lower pole and the back side of spleen was dissected from retroperitoneum and then splenic artery was clipped just below the marking which was made preoperatively. Next, the lateral side then the upper pole of spleen was detached from the retroperitoneum. Finally, spleen was excised from pancreas tail by endo-GIA60 x 3 times. The isolated spleen was divided into 5 pieces by surgical scissors and then picked up through the Gel-port. The operative time was 280 min with little bleeding. Postoperative course was uneventful.

**Conclusions:** In the cases of splenomegaly, HALS with transperitoneal "antero-lateral" approach significantly facilitates the surgical procedure and reduces the operational risk, and therefore, is more feasible and more effective than conventional LS or open splenectomy.



**Figure:** Position and posture

**Abstract ID: 0018** Specific Field: **Endoscopic Surgery**

**Mode of pres.: Video**  
**ISW 2011 Session 62.06**

**Single-access laparoscopic complete mesocolic excision combined with extracorporeal magnetic retraction**

D. Uematsu, G. Akiyama, A. Magishi, M. Narita

Saku Central Hospital, Saku City, Japan

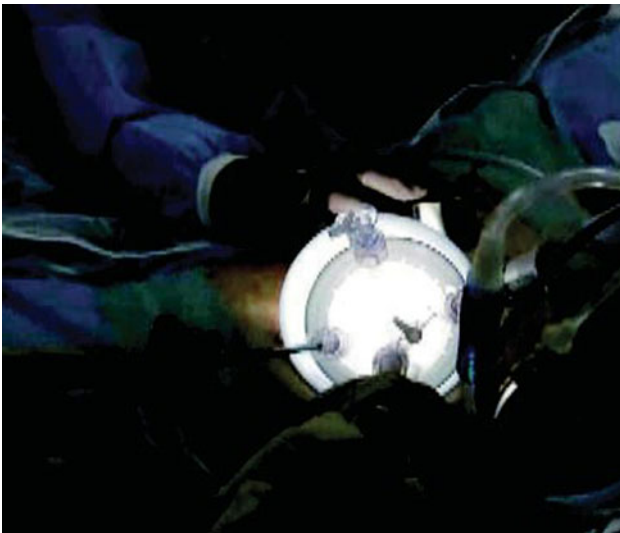**Introduction:** Complete mesocolic excision and central ligation for colonic cancer as lower local recurrence rates and better overall survival was proposed by W. Hohenberger. Single-access laparoscopic colectomy is rapidly widespread from 2008 all over the world. However, triangulation must be lost or instrumental collision must be sustained to compensate for the single-access site. Using a novel multiport device and extracorporeal magnetic retraction can restore triangulation and avoid instrumental collision. To achieve single-access laparoscopic complete mesocolic excision for advanced colonic cancer more safely and simply, we present radical lymphadenectomy as filleting the fish into 2 pieces.



**Material and Methods:** 50 consecutive patients with advanced colon cancer underwent a curative procedure. Single access to the abdomen was achieved with a 3.0 cm umbilical incision, where a novel multiport device was attached. The vascular forceps grasping the tissue were retracted by an extracorporeal magnetic tool, restoring triangulation. The mesocolon was dissected between the superficial layer of the fat tissue and the deep layer of the vascular sheath along the superior mesenteric artery. After the course of each branch was revealed under the mantle of the vascular sheath, each supplying or draining vessel was transected at its root. The use of a laparoscope and a spatula type electric cautery greatly contributes to this procedure. Next, the bowel was mobilized and the specimen was retrieved through the small incision. Finally, anastomosis was performed.

**Results:** There were no intra-operative complications except for two patients who underwent mobilization of the splenic flexure. The median number of retrieved lymph nodes was 38 (range, 13–52). The median total surgical time was 250 (range, 122–372 min). Surgical blood loss was slight (range, 1–20 ml). The postoperative course was uneventful for all patients except for one patient who had minor leakage of pancreatic juice.

**Conclusions:** Single-access laparoscopic complete mesocolic excision for colonic cancer may compare with conventional laparoscopic colectomy. However, left hemicolectomy including mobilization of the splenic flexure may be necessary for changing the single-access site from the umbilicus to the upper midline.



**Figure:** Multiport device

**Abstract ID: 0019** Specific Field: **Endoscopic Surgery**

**Mode of pres.: Nyhus Prize Session**  
**ISW 2011 Session 95.01**

**Laparoscopic ventral hernia repair with different type of meshes**

V. Grubnik, N.D. Parphentyeva, K.O. Vorotyntseva  
Odessa National Medical University, Odessa, Ukraine

**Introduction:** Laparoscopic operations are being used increasingly in the repair of ventral hernias. Results and rate of complications after laparoscopic hernia repair depend of type of mesh and methods of

mesh fixation The aim of the study was to compare different types of meshes for laparoscopic ventral hernia repair.

**Material and Methods:** Prospective randomized study was conducted from January 2009 to December 2010. Study group consisted of 54 patients (men—27, women—27) with a mean age  $56.4 \pm 11.5$  years (range, 28–79 years). Umbilical hernias were in 13 patients, paraumbilical hernias were in 5 patients and ventral postoperative hernias were in 36 patients. 28 patients (group I) were operated laparoscopically with the use of PTFEe mesh Gore – Tex, which was fixed to the abdominal wall with double row of spiral tackers. 26 patients (group II) were operated laparoscopically with MMDI mesh (new generation of mesh, made from lightweight PTFEe mesh strain on the nitinol framework). These meshes were adequately fixed to the abdominal wall using only 3–4 transfascial sutures.

**Results:** The patients in the two groups were comparable at baseline in terms of sex, size of hernia defects, presenting complains and comorbidity conditions The mean surgery duration was 115 min for the patients of the group I and 74 min for the patients of the group II ( $P < 0.05$ ). The pain score was significantly less at 24 and 48 h in the patients of group II (mean visual analog scale score, 2.74 vs. 3.82,  $P < 0.01$ ). There were fewer complications among the patients of group II (7 vs. 39%,  $P < 0.01$ ). Mean follow-up time was 6, 12 months. Recurrence of hernia was detected in 2 patients of the group I, and no recurrence among the patients of the group II.

**Conclusions:** Meshes of new generation with nitinol framework can significantly improve laparoscopic ventral hernia repair. The fixation of these meshes is very simple using 3–4 transfascial sutures. The absence of shrinkage of these meshes makes the probability of recurrence minimal Absences of takers allow avoiding the postoperative pain. We consider that these new meshes can make a revolution in laparoscopic ventral hernia repair.

**Abstract ID: 0020** Specific Field: **Endoscopic Surgery**

**Mode of pres.: Nyhus Prize Session**  
**ISW 2011 Session 95.02**

**Laparoscopic surgery for chronic groin pain in athletes is more effective than non-operative treatment: a randomized clinical trial with magnetic resonance imaging of 60 patients with sportsman's hernia (pubalgia)**

H. Paajanen [1], I. Airo [2], T. Brinck [3]

[1] Kuopio University Hospital, Kuopio, Finland, [2] Päijät-Häme Central Hospital, Lahti, Finland, [3] Pohjois-Karjala Central Hospital, Joensuu, Finland

**Introduction:** Sportsman's hernia and related pubalgia is a deficiency of the posterior wall of the inguinal canal, often repaired by laparoscopic mesh placement. Endoscopic mesh repair may offer faster recovery for athletes with sportsman's hernia compared to non-operative therapy.

**Material and Methods:** A randomized, prospective study was conducted on 30 operated and 30 conservatively treated patients with a diagnosis of chronic groin pain and suspected sportsman's hernia. Clinical data and magnetic resonance imaging were collected on all patients After 3 to 6 months of groin symptoms, the patients were randomized into operative or physiotherapy groups. Operation was performed by a placement of totally extraperitoneal endoscopic (TEP) mesh behind the symphysis and painful groin area. Conservative treatment included at least 2 months of active physiotherapy. The outcome measures were pre- and postoperative pain and partial or full recovery to sport activity at 1, 3, 6 and 12 months after randomization.



**Results:** The athletes in both treatment groups had similar characteristics and pain scores. Operative repair was more effective than non-operative treatment to decrease chronic groin pain after one month and up to 12 months of following up ( $P < 0.001$ ). Twenty seven of 30 athletes (90%) returned to sport activities after three months of convalescence compared to eight of 30 (27%) in the non-operative group ( $P < 0.0001$ ). Seven athletes (23%) in the conservative group were later operated because of persistent groin pain.

**Conclusions:** This randomized controlled study indicated that the endoscopic placement of retropubic mesh was more efficient than conservative therapy for the treatment of sportsman's hernia type pubalgia in athletes.

Outcome of the patients after 12 months

	Operative ( <i>n</i> = 30)	Non-operative ( <i>n</i> = 30)	<i>P</i>
Full return to sport	29 (97%)	15 (50%)	< 0.0001
Complete pain relief	29 (97%)	14 (47%)	< 0.0001

### Abstract ID: 0021 Specific Field: Endoscopic Surgery

**Mode of pres.: Nyhus Prize Session**  
**ISW 2011 Session 95.03**

#### Laparoscopic colorectal cancer surgery for patients with cardiopulmonary risk

S. Toda, S. Matoba, H. Kuroyanagi, K. Tomizawa, Y. Hanaoka, J. Moriyama, T. Sawada

Toranomon Hospital, Tokyo, Japan

**Introduction:** Although laparoscopic surgery for colorectal cancer has become widespread, laparoscopic surgery to patients with cardiopulmonary risk is controversial because of intraoperative stress due to pneumoperitoneum and a head down position. We have performed laparoscopic surgery even for patients with cardiopulmonary risk as much as possible because we consider that postoperative benefits surpass intraoperative risk.

**Material and Methods:** We have experienced 2719 cases of colorectal cancer since 1999. Among those patients, 404 patients had cardiopulmonary risk. Type and severity of risk, type of surgery, reasons for selection of open surgery, intra- and post-operative complications were retrospectively reviewed.

**Results:** 287 patients had cardiac risk as follows: 145 cases of ischemic heart disease, 95 cases of arrhythmia and 27 cases of valvular diseases, and 20 cases of other conditions. The median value of left ventricular ejection fraction (LVEF) was 68% (minimum 24% and maximum 85%). 167 patients had pulmonary risk as follows: 76 cases of chronic obstructive pulmonary disease (COPD), 58 cases of bronchial asthma, 33 cases of other conditions. Median %FEV1 (forced expiratory volume in one second) is 58% (minimum 23% and maximum 88%) and median FEV1 is 1.6 l (minimum 0.5 l and maximum 3.7 l). ASA score is 2 in 281 patients, 3 in 119 patients and 4 in 4 patients. Among 404 cases, 349 cases were treated by laparoscopic surgery and 55 cases by open surgery. Though we selected open surgery because of cardiovascular risk in 12 cases, in recent 5 years there was no case of open surgery attributable to cardiopulmonary risk. However there were 6 cases (1.7%) of conversion to open surgery, there was no case of conversion owing to

pneumoperitoneum and a head-down position. The median time of pneumoperitoneum was 65 min. During the pneumoperitoneum, the median minimum SBP (systolic blood pressure) was 90 mm Hg, and the minimum SpO<sub>2</sub> was 98%. There were 2 cases of postoperative death. One was because of myocardial infarction, and the other was because of sepsis continued from before surgery. There was 4 cases of postoperative cardiac complication but no case of pulmonary complication.

**Conclusions:** Laparoscopic colorectal cancer surgery was safe and feasible even for patients with cardiopulmonary risk. Moreover, postoperative complications can be reduced by laparoscopic surgery.

### Abstract ID: 0022 Specific Field: Endoscopic Surgery

**Mode of pres.: Free Paper**  
**ISW 2011 Session 148.01**

#### Impact of modern hospital management and specialized laparoscopic training on the quality of emergency minimally invasive surgery: experience in a governmental hospital in a Gulf country

N. Balalaa, S. Rahman, I. Hassan

Alain Hospital, Alain, United Arab Emirates

**Introduction:** to assess the impact on the quality of emergency minimally invasive surgery in a governmental hospital in a Gulf country (AlainUAE) of a modern hospital management and specialized laparoscopic training.

**Material and Methods:** Study concerned all laparoscopic procedures for emergency done one year before (01–11 2009) and one year after (112009–102010) introduction of a specialized training program. Number of laparoscopic procedure, complexity of cases, conversions rate and complications for period before the program were assessed and compared to the period after the program.

**Results:** Before starting the specialized program a total of 97 lap. Procedures was done compared to 186 after the program ( $P = 0.001$ ). The conversion rate has decreased from 13.6% before to 2.1% after the program ( $P = 0.0001$ ), while complexity of case (14% vs. 26%,  $P = 0.025$ ) and needs for post operative ICU treatment (1% vs. 4.8%,  $P = 0.035$ ) was increased. There was no mortality or major complications required reoperation in both periods, but the overall complication rate was decreased from 19.5% before to 10.2% ( $P = 0.032$ ) after the training program. For the entire study there was only 2 out of 58 cholecystectomy had postoperative cystic duct leakage treated with ERCP and stent and 2 out 160 appendicectomy had postoperative intraabdominal abscess treated with PAD. The overall port side infection rate was 1.4%.

**Conclusions:** The improvement of laparoscopic surgery for emergency resulting from modern hospital management and standardized training through specialized leadership was obvious at Alain-hospital and reached the required international standard. However, training needs to be continued and practices homogenized.

### Abstract ID: 0023 Specific Field: Endoscopic Surgery

**Mode of pres.: Free Paper**  
**ISW 2011 Session 148.03**

#### Is obesity a contraindication for laparoscopic assisted transvaginal cholecystectomy

C. Bohner, Th. Kocher, A. Keerl

Kantonsspital Baden, Baden, Switzerland

**Introduction:** At the cantonal Hospital in Baden about 300 cholecystectomies are performed annually. The laparoscopic cholecystectomy (LC) is standard. 2/3 of all patients are female. NOTES (natural orifice transluminal endoscopic surgery) is an important issue for surgeons and many other medical disciplines. By the use of natural orifices the operative trauma and the development of incisional/trocar hernias shall be reduced, further better cosmetic results are/can be achieved. The majority of the female patients with symptomatic cholelithiasis is obese.

**Material and Methods:** From June 2009 until December 2010 we performed 170 laparoscopic transvaginal cholecystectomies (LTVC) at our surgical department. Initially we operated only on “easy patients” (no former abdominal surgical interventions, slim, no cholecystitis). With increasing experience we also operated on obese patients with a BMI >30.

**Results:** An obesity with a BMI >30 was present in 55 of 170 patients. We compared the two groups BMI < 30 and BMI >30. The group BMI >30 showed the following results: The average age was 52.6 years, (BMI < 30 51.9 years). The postoperative hospital stay was 4.1 days (BMI < 30 2.3 days). In the group BMI < 30 there were 2 side complications (urinary infection, candidosis of the vaginal introitus), in the group BMI >30 we had 4 complications: a serosa lesion of the rectum, an lesion of the urinary bladder and two insufficiencies of the cystic duct. The average operating time was 68.8 min (BMI < 30 60.6 min). In 24% of all cases there was an additional trocar necessary (BMI < 30 13%).

**Conclusions:** The LTVC can be performed in obese patients as well. The postoperative hospital stay however is longer. More often additional trocars are necessary and the rate of complications is increased. All complications healed without any problem or secondary operative intervention.

**Abstract ID: 0024** Specific Field: **Endoscopic Surgery**

**Mode of pres.: Free Paper**  
**ISW 2011 Session 148.04**

**Laparoscopic assisted transvaginal cholecystectomy: a new standard?**

A. Keerl, C. Bohner, Th. Kocher  
Kantonsspital Baden, Switzerland

**Introduction:** At the cantonal Hospital in Baden, Switzerland about 300 cholecystectomies are performed annually. The laparoscopic cholecystectomy (LC) is standard. 2/3 of all patients are female. NOTES (natural orifice transluminal endoscopic surgery) has become an important issue for surgeons and many other medical disciplines. By the use of natural orifices the operative trauma and the development of incisional/trocar hernias shall be reduced, further better cosmetic results are achieved. In June 2009 the first laparoscopic transvaginal cholecystectomy (LTVC) was performed at our surgical department.

**Material and Methods:** After studying the method at congresses, we evaluated the technique during two visitations (11/2008 und 04/2009). In May 2009 the technique was interdisciplinary defined/set as a standard intervention. The necessary equipment was purchased. Initially the operation was limited to two surgeons. From June 2009 until December 2010 we performed 170 laparoscopic transvaginal cholecystectomies (LTVC) at our surgical department. At first we operated only on “easy patients” (no former abdominal surgical interventions, slim/slender, no cholecystitis). With increasing experience we

extended the indication and the criterions for exclusion were reduced on present pregnancy and infections of the vagina.

**Results:** The average age of the female patients was 54 Years (LC: 53 years). The average postoperative hospital stay was 2.6 days. (LC 3.4 days). The average BMI was 28.3 in the LTVC group and 28.2 in the LC group. We had 6 complications in total: a serosa lesion of the rectum, an lesion of the urinary bladder and two insufficiencies of the cystic duct, 2 urinary infections and one candidosis of the vaginal introitus. The average operating time was 63 min (24–140 min). In 19 cases an additional trocar was necessary. 18 patients had an additional gynaecological intervention simultaneously. 97% of all patients would chose the transvaginal method again

**Conclusions:** The LTVC has proven to be of equal standard as the LC. The feedback of the patients is excellent and the rate of complications is low. Currently about 80% of all cholecystectomies in female patients are performed transvaginal.

**Abstract ID: 0025** Specific Field: **Endoscopic Surgery**

**Mode of pres.: Free Paper**  
**ISW 2011 Session 148.05**

**Cost effectiveness and advantages of investing newer medical technology in developing country (Ghana)**

S. Tabiri, M.S. Alhassan

Tamale Teaching Hospital of University for Development Studies,  
Tamale - Northern Region, Ghana

**Introduction:** Evaluating the advantages and cost-effectiveness of Gastrointestinal Endoscopy at Tamale Teaching Hospital in Northern, Ghana may be useful for assessing the role of newer medical technology in developing countries.

**Material and Methods:** The Minimal Access Therapy and Operative Endoscopy Unit was established in September 15, 2010 at the Department General Surgery of Tamale Teaching Hospital, University of Development Studies in the Northern Region of Ghana. Diagnostic and Interventional procedures were performed with Olympus Evis Gastrointestinal Videoendoscopic Systems CV160 from September 2010 to January 2011. The unit serves three Northern regions (Northern Region, Upper East Region and Upper West Region) and Brong Ahafo Region of Ghana. One locally trained endoscopic nurse and one Endoscopist work at the unit. Before the establishment of the unit, patients had to travel for about 460 km to wait in a queue for about six months to have endoscopy done.

**Results:** Various flexible endoscopic procedures were performed in 106 patients: Upper Gastrointestinal endoscopy procedures performed in 99 (93.4%); Colonoscopy in 6 (5.7%) patients; Sigmoidoscopy in 1 (0.9%) patients. Interventional procedures includes: Biopsies in 59 (55.7%); adrenaline injection for bleeding peptic ulcer disease in 10 (9.3%) patients; Endoscopic clips for upper gastrointestinal bleeding secondary to peptic ulcer disease in 8 (7.5%); removal of foreign body in 3 (2.8%) patients; injection sclerotherapy for oesophageal varices in 4 (3.8%) patients. In 5 months, the total income of 37852 Ghana New Cedis (25,234 US dollars) was generated which is 63% of initial investment of 40,000 US dollars.

**Conclusions:** Investing in newer medical technology in developing countries is cost effective. It is of great benefit to patients and major source of income generating for health care provider not only in the private but also in the government hospitals.

**Abstract ID: 0026** Specific Field: **Endoscopic Surgery****Mode of pres.: Free Paper**  
**ISW 2011 Session 148.06****Single incision endoscopic thyroidectomy (SET) using a gasless axillary approach**H.N. Kwak [1], J.H. Kim [2], J.S. Yoon [1], Y.L. Park [1],  
CH Park [1]

[1] Department of Surgery, Breast & Thyroid Cancer Center, Kangbuk Samsung Hospital, Sungkyunkwan University School of Medicine, Seoul, Korea, Republic of, [2] Department of Surgery, Pyoungchon Sacred Heart Hospital, Hallym University College of Medicine, Korea, Republic of

**Introduction:** With the recent advances of the operative instruments and technique and its superior cosmetic results, endoscopic thyroidectomy has become a widely used operative procedure. Various approaches for endoscopic thyroidectomy have been proposed, mainly including via the neck, the anterior chest, the breast, and the axilla. Here we applied single axillary incision without another skin incision on the anterolateral chest wall used in conventional gasless trans-axillary endoscopic thyroidectomy.

**Material and Methods:** Between March 2008 and June 2010, 213 patients underwent gasless trans-axillary endoscopic thyroidectomy: 77 patients by conventional approach (C group), 136 patients by single incision approach (S group). The clinicopathologic characteristics, perioperative outcomes and hospital courses were retrospectively compared between two groups.

**Results:** The S group was younger than the C group. On histologic review, 47 cases in the C group and 98 cases in the S group had malignant thyroid nodules (61% vs. 72.1%,  $P = 0.097$ ). No significant differences in gender, number of retrieved lymph nodes, extent of surgery and size, multiplicity, bilaterality, and extracapsular invasion of the tumor between two groups were found. The operating time and length of post-operative hospital stay in S group were significantly shorter than that in C group ( $84.7 \pm 18.9$  min vs.  $97.5 \pm 22.7$  min;  $P \leq 0.001$ ,  $2.6 \pm 0.8$  days vs.  $3.1 \pm 1.0$  days;  $P \leq 0.001$ ). There were several minor complications (transient tingling sensation; 5 cases, mild voice change; 26 cases, and hematoma; 2 cases) in both group, but not significant difference between two groups ( $P = 0.910$ ). One patient in the S group underwent re-operation due to postoperative bleeding.

**Conclusions:** Compared with conventional gasless trans-axillary endoscopic thyroidectomy, the single incision endoscopic thyroidectomy is efficient, feasible and safe operative procedure without another skin incision on anterior chest wall.

**Abstract ID: 0027** Specific Field: **Endoscopic Surgery****Mode of pres.: Free Paper**  
**ISW 2011 Session 148.07****Hybrid-NOTES for gastric GIST**M. Hagiike, H. Mori, H. Kashiwagi, M. Fujiwara, T. Takama,  
H. Inoue, T. Masaki, Y. Suzuki

Faculty of Medicine, Kagawa University, Kagawa, Japan

**Introduction:** Basic surgical treatment for GIST is complete excision of the tumor. Laparoscopic resection is less invasive procedure and recommended for this reason. We performed intra-operative endoscopy for the assistance of laparoscopic resection for several years.

Recently we introduced Natural Orifice Transluminal Endoscopic Surgery (NOTES) technique for gastric GIST during laparoscopic procedure. We refer this procedure and evaluated early cases.

**Material and Methods:** We performed 4 cases of gastric GIST excision by Hybrid-NOTES (H-NOTES) using the combination of endoscopic resection and laparoscopic procedure in cooperation with gastroenterologists. H-NOTES facilitates the identification of GIST from in and outside of the stomach and adequate surgical margin can be obtained without unexpected gastric deformity by unnecessary over resection. (H-NOTES Technique) Insert a laparoscope from umbilical port and required laparoscopic procedures i.e. adhesiolysis, mesenteric resection and so forth were done prior to the endoscopic resection. Then, flexible endoscope is inserted per os and duodenal bulb is occluded by endoscopic balloon. Endoscopic full-thickness resection for GIST is performed using endoscopic submucosal resection technique with laparoscopic intervention. Gastric closure is done by laparoscopic intracorporeal suturing or automatic suture instruments to avoid the huge gastric deformity. We evaluated operation time and hospital stay of H-NOTES group compared with laparoscopic and open cases.

**Results:** Operation time of H-NOTES group was significantly longer than other groups. Hospital stay of H-NOTES groups is almost the same as laparoscopic resection group. Surgical margin were enough for complete resection and gastric deformity was not seen in H-NOTES group.

**Conclusions:** H-NOTES takes longer operation time at present but it is feasible and useful procedure for gastric GIST to minimize post-operative gastric deformity without losing the curability. It is an important step in the way to Pure-NOTES in the future.

OP time and hospital stay

	H-NOTES	Laparoscopic surgery	Open surgery
OP time (min)	312	205	93
hospital stay (day)	9	12	16

**Abstract ID: 0028** Specific Field: **Endoscopic Surgery****Mode of pres.: Free Paper**  
**ISW 2011 Session 148.08****ERCP findings after MRCP diagnosis of choledocholithiasis: results from 152 cases**L. Polese [1], D. Neri [1], B. Mungo [1], U. Cillo [1],  
R. Del Villano [2], S. Merigliano [1], L. Norberto [1]

[1] University of Padova, Department of Surgical and Gastroenterological Sciences, Padova, Italy, [2] University of Padova, Department of Radiology, Padova, Italy

**Introduction:** Patients with gallbladder stones present common bile duct (CBD) stones in 15–20% of cases and this is an indication for papillotomy and stone removal by ERCP. Magnetic resonance cholangio-pancreatography (MRCP) is a completely non-invasive investigation to diagnose CBD stones with high sensitivity and specificity. The performance of MRCP for the diagnosis of common bile duct stones reduces the number of unnecessary ERCP only to therapeutic purpose. Anyway in some cases the diagnosis of choledocholithiasis by MRCP is not confirmed by following ERCP.

Spontaneous passage of stones is one of the causes. In the present study we analyse the findings at 152 consecutive ERCP performed after MRCP diagnosis of CBD stones.

**Material and Methods:** We considered for enrolment all the consecutive patients referred to ERCP after MRCP diagnosis of CBD stones. Clinical history, MRCP findings, blood tests, findings at ERCP, time between the diagnosis of CBD stones at MRCP and the performance of ERCP were prospectively recorded.

**Results:** 152 patients underwent ERCP for suspect of CBD stones at MRCP. ERCP was completed in 134 patients (88.15%). Sixty six patients had already been operated of cholecystectomy, the other 68 presented lithiasis in the gallbladder and in the CBD. Time between performance of MRCP and ERCP was in median 13 days (C.I. 8.7 days). CBD stones were confirmed in 96 patients by retrograde endoscopic cholangiography (71.6%), while in 38 patients the cholangiogram excluded the presence of stones. The study for predictive factors by univariate analysis demonstrated that presence of stones at ERCP was associated with early ERCP performance after MRCP (6 days with respect to 7 days,  $P = 0.012$ ), patient's age ( $>67$  years with respect to  $<67$   $P = 0.042$ ), choledochal ( $P = 0.001$ ) and intrahepatic dilation found at MRCP ( $P = 0.051$ ), and diameter of the defect (6 mm with respect to 5 mm,  $P = 0.0001$ ). By multivariate analysis diameter of the defect confirmed to be a significant predictor of the presence of stone.

**Conclusions:** In our experience common bile duct stones diagnosed at MRCP were confirmed by ERCP in 71.6% of the cases. Most important predictive factor is the diameter of the defect. Early performance after MRCP and choledochal dilation seem to be also predictive factors.

#### Abstract ID: 0029 Specific Field: Endoscopic Surgery

**Mode of pres.: Poster Exhibition only**  
ISW 2011 Session PE 1

##### **A case of pure laparoscopic hepatectomy for HCC patients with severe liver cirrhosis (Child-Pugh C and ICG R15 of 48.9%)**

J. Kawase, Z. Morise, S. Umemoto, N. Kawabe, H. Nagata, H. Oshima, S. Arakawa, R. Yoshida

Fujita Health University School of Medicine Banbuntanhouokukai Hospital Department of Surgery, Nagoya, Japan

**Introduction:** Recent development of devices facilitates the expansion of indication for pure laparoscopic hepatectomy and common advantages of laparoscopic surgery have been reported. On the other hand, the patients with severe liver cirrhosis who undergo hepatectomy often develop post-operative liver failure, even if the hepatectomy is very limited. We herein report a case of pure laparoscopic hepatectomy for HCC patients with severe liver cirrhosis (Child-Pugh C and ICG R15 of 48.9%)

**Material and Methods:** 50 years old man with type-C viral liver cirrhosis introduced to our department for the 1.5 cm liver tumor in the surface of segment 5. He had history of hepatic encephalopathy and his blood examination data shows severe liver dysfunction with plasma total bilirubin level of 2.0 mg/dl, platelet count of 48000/ $\mu$ l,

prothrombin time of 66.2% and ICG R15 of 48.9%. The tumor was diagnosed as HCC. Since RFA was not applicable due to the location, he underwent pure laparoscopic partial resection of the liver segment 5.

**Results:** The operation time was 140 min and the intraoperative blood loss was 10 ml. He discharged at 11 POD without any complications and there is no sign of recurrence at 10 POM. From May 2005, 30 patients with liver cancer underwent pure laparoscopic hepatectomy. There are 18 patients with HCC and chronic liver disease. Among them, there were 6 patients with severe liver cirrhosis (Child-Pugh B/C and ICG R15 of 40% or above). Perioperative course of 6 HCC patients with severe liver cirrhosis and pure laparoscopic hepatectomy was favorable and comparable to that of the other HCC patients with mild/moderate liver cirrhosis.

**Conclusions:** Our experiences suggest that pure laparoscopic hepatectomy for patients with severe liver cirrhosis has an specific advantage of minimal postoperative drain discharge. The procedure minimize destruction of the collateral blood and lymphatic flow caused by laparotomy and mobilization of the liver and, also, mesenchymal injury caused by compression of the liver. It restrains the complications, which lead to the postoperative serious liver failure. Severe cirrhotic patients with tumors on the surface of the liver, in case of difficult adaptation of percutaneous ablation therapy and/or local recurrence after repeat treatments, are the good candidates for this procedure.

#### Abstract ID: 0030 Specific Field: Endoscopic Surgery

**Mode of pres.: Poster Exhibition only**  
ISW 2011 Session PE 2

##### **Minimal incision based on measurement of the to-be-resected specimen in laparoscopic hepatectomy**

K. Kida, T. Oida, K. Mimatsu, H. Kano, A. Kawasaki, Y. Kuboi, N. Fukino, S. Amano

Social Insurance Yokohama Central Hospital, Yokohama, Japan

**Introduction:** We performed laparoscopic liver resection via a minimal incision that was based on the measurement of the to-be-resected specimen intraoperatively by ultrasonography.

**Material and Methods:** The resection line was marked including 2-cm around the tumor margin, and the size of the intended resection specimen was measured by laparoscopic ultrasound. According to this measurement, a minimal abdominal incision was made on the abdominal wall above the tumor for its extraction. The resected specimen was extracted through the minimal incision.

**Results:** The mean size of the resected tumors was  $31.7 \pm 3.4$  mm in diameter. The mean maximum size of the resected specimens was  $53 \pm 8$  mm. The mean length of the abdominal incision for extraction of the resected specimens was  $54 \pm 8$  mm. The mean surgical margin was  $12.5 \pm 2.5$  mm.

**Conclusions:** Our procedure, which was based on the intraoperative ultrasonographic measurement of the to-be-resected specimen, a minimal abdominal incision can provide both an adequate surgical margin along with the cosmetic.



## Outcomes

	Operative procedure	Operative time (min)	Blood loss (ml)	Size of resected specimen (mm)	Length of incision (mm)	Surgical margin (mm)
1	Partial resection	125	95	63	60	18
2	Partial resection	135	55	40	45	11
3	Partial resection	130	45	47	45	12
4	Partial resection	145	70	48	50	11
5	Partial resection	160	75	55	60	10
6	Partial resection	110	65	55	60	15
7	Partial resection	155	55	55	55	12
8	Partial resection	125	70	70	70	16
9	Partial resection	135	65	55	60	13
10	Partial resection	140	55	50	52	11
11	Partial resection	125	45	50	50	10
12	Partial resection	120	50	45	45	11
	Mean	134	62	53	54	12.5

**Abstract ID: 0031** Specific Field: **Endoscopic Surgery**

**Mode of pres.: Poster Exhibition only**  
**ISW 2011 Session PE 3**

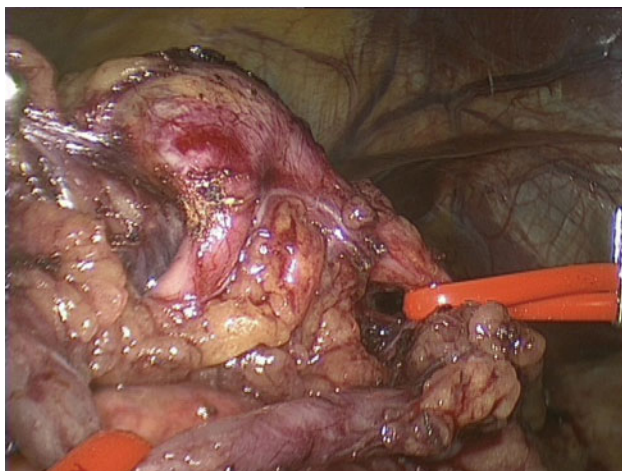
**Laparoscopic resection for splenic artery aneurysm: lateral approach for the precise resection**

A. Iida, K. Koneri, H. Nagano, M. Murakami, Y. Hirono, T. Goi, K. Katayama, A. Yamaguchi

University of Fukui, Fukui, Japan

**Introduction:** Splenic artery aneurysm (SAA) has a risk of rupture. There are only few reports to treat it by laparoscopic surgery. We report two cases of successful laparoscopic surgery for SAA.

**Material and Methods:** [Case presentation and operative procedure] Case 1; 59-year-old man who had hypertension admitted a hospital complaining slight back pain. CT scanning showed the winding splenic artery and an aneurysm behind the pancreas body. Case 2; 71-year-old woman who had hypertension consulted us by diagnosed SAA. Her aneurysm had grown up 2 cm from 1 cm in size after one year follow



**Figure:** The splenic artery was isolated and banded by a tape for safety at the both side of the aneurysm

up. We set the same settings as our laparoscopic splenectomy. After the dissection of spleen and pancreas body from the left lateral side, the aneurysm was clipped and resected. Splenectomy was performed after confirming the changing into dusky color of the spleen.

**Results:** The operating times were 210–259 min and the bleeding was 60–100 g. Post operative course was uneventful and the patients were discharged at the five post operative days.

**Conclusions:** Laparoscopic surgery for SAA was feasible treatment in the complication and the result. Lateral approach from the left side was able us the precise resection of SAA under the stable operative view, and made us easy to diagnose and treat the possibility for following splenectomy.

**Abstract ID: 0032** Specific Field: **Endoscopic Surgery**

**Mode of pres.: Poster Exhibition only**  
**ISW 2011 Session PE 4**

**The utility and standardization of single port cholecystectomy by Glove method**

F. Hirokawa, M. Hayashi, M. Asakuma, Y. Miyamoto, K. Komeda, T. Shimizu, Y. Inoue

Osaka Medical College, Takatsuki, Japan

**Introduction:** Conventional four-port laparoscopic cholecystectomy has been standard operation for benign gallbladder disease for a long time. In recent years, single-port cholecystectomy (SPC) that is superior to conventional four-port laparoscopic cholecystectomy (CLC) in minimal invasiveness and cosmetic advantage has been attracted attention and widespread.

**Material and Methods:** Between June 2009 and December 2010, 75 patients were performed single port surgery by Glove method (65 cholecystectomy, 1 choledocholithotomy, 3 appendectomy, 3 right colectomy, 1 lateral sectionectomy of the liver, 2 partial resection of the liver and 1 gastropexy). 1. At the first, we compared the post-operative pain of CLC and SPC to clarify the minimal invasiveness. 2. After that, we considered the potentiality that. SPC become the standard operation for benign gallbladder disease. 65 patients performed SPC were divided into 3 groups. Group A patients ( $n = 14$ ) were performed SPC before the surgical technique was established,

Group B ( $n = 41$ ) were done by the same operator after the surgical technique was established and Group C ( $n = 10$ ) were done by 3 different operator after the surgical technique was established. Operative time was compared among 3 groups

**Results:** 1. The visual analog scale (VAS) on postoperative day 1 was significantly smaller in the SPC group than in the LC group (median: 24 [3–63] mm vs. 44 [14–72] mm;  $P = 0.001$ ). 2. The mean operative time in Group C ( $90 \pm 17$  min) was similar to Group B ( $94 \pm 32$  min) and was significantly shorter than Group A ( $116 \pm 23$  min;  $P = 0.047$ ). The postoperative complications and intraoperative bile duct injury were not occurred.

**Conclusions:** This presentation suggests that the postoperative pain of SPC by Glove method was clearly painless than CLC and stereotyping the surgical technique is effectiveness to acquire SPC.

**Abstract ID: 0033** Specific Field: **Endoscopic Surgery**

**Mode of pres.: Poster Exhibition only**  
**ISW 2011 Session PE 5**

**A unique method of single incision laparoscopic surgery in total extraperitoneal approach for inguinal hernia**

N. Hayashi, T. Ichihara

Nishinomiya Municipal Hospital, Nishinomiya, Japan

**Introduction:** The growing cost of operation for single-incision laparoscopic surgery (SILS) has been a social issue worldwide. We here present the cheap and easy method for SILS in the total extraperitoneal (TEP) operation for inguinal hernia.

**Material and Methods:** Under general anesthesia, a 2 cm infraumbilical skin incision was made for placement of a wound retractor A home made single port device was made with a size 6 surgical glove, which was attached to the outer ring of the wound retractor After insufflation of CO<sub>2</sub> gas to a pressure of 10 mm Hg through an inlet of the trocar, we carried out blunt dissection of the preperitoneal space under scope vision with a standard rigid laparoscope. Three reusable trocars were inserted into the glove and fixed with rubber bands. We then performed a routine TEP inguinal hernia repair. Standard laparoscopic instruments and polypropylene mesh were utilized for the operation.

**Results:** From July to December 2010, a total of 10 inguinal hernia cases were managed at our hospital with this technique. All cases were successfully performed without any intra or postoperative complication. No conversion to other procedures was needed. The median operative time for tep was 110 (range, 100–120) min. This procedure was seemed to be almost the same as the conventional laparoscopic one, except for slight discomfort with visualization and retraction due to collision of the instruments. There was no difference in operative time between the group managed with conventional TEP and this technique. The mean hospital stay was 1.1 days (range 1–2 days). Average saving for our frugal way for each operation was as much as 400 dollars.

**Conclusions:** SILS TEP for inguinal hernia using a home made multichannel port system and cheap instruments could be one of the alternative methods for treatment of inguinal hernia.

**Abstract ID: 0034** Specific Field: **Endoscopic Surgery**

**Mode of pres.: Poster Exhibition only**  
**ISW 2011 Session PE 6**

**Single port surgery by glove method for the submucosal tumor of the stomach**

K. Hayashi, Y. Munakata, K. Okita, H. Seki, M. Takada, S. Tagami, F. Muranaka, M. Matsumura

Nagano Municipal Hospital, Nagano City, Japan

**Introduction:** In our institute, single port laparoscopic surgery were started for the gastric submucosal tumors, in June, 2009. The strategy was different in tumor size, location, and histology. We will show the 3 operation methods for submucosal tumor of the stomach.

**Material and Methods:** Thirteen cases of submucosal tumor was operated by single port or port reduced surgery, during 1 year and 6 months. 7 are male, 6 are female, and average age was 62.7 years. Location of upper thirds were 12 cases and lower thirds was only one case. Three cases were evaluated histology as GIST by FNAB, and finally evaluated as GIST were 9 cases, shwanoma were 2 cases, and leiomyoma and duplication of the stomach was 1 respectively. Operation methods were created for intragastric surgery (A-group) in 6 cases, partial resection by staplers by lesion lifting (B-group) were 6 cases, and 1 was performed segmental resection of the stomach (C-group). A-group was made by Glove method using wound retractor-XS, three trocars were introduce in to the stomach via small wound, 2–3 cm in diameter, at the umbilicus. The tumors were made marking and resected by an electrocautery and USAD and repaired by SILS or ENDO-stich for 4 cases, Resection and repair was made by staplers was 1 case, and sutured by had thorn technique from outer side of the stomach was 1 respectively. B-group were performed resection with 1–3 trocars. C-group was performed segmentectomy of the stomach for big SMT and repaired by functional end to end anastomosis.

**Results:** Plus 1 port was needed in 1 case in A-group, 4 cases in B-group and 1 case in C-group. The average blood loss was 25.8 g in A-group, 11.5 g in B-group and 20 g in C-group. The average operation time was followed, A group was 146.5 s. B- group was 111.4 s. and C-group was 172 s. Hospital stay after surgery was 6.7 days in A-group, 6.0 days in B-group, and 8 days in C-group without complication. No tumor was encountered recurrence in short followed up period.

**Conclusions:** Single port (+1 port) surgery for SMT of the stomach was feasible. This procedure was cosmetic, less pain, and not so expensive If the tumor was big in size(>5 cm) or located in posterior side were planned for 1 port plus, and make more safe and high quality procedure.

---

Intragastric surgery    Partial gastrectomy    Segmental Gastrectomy

---

**Abstract ID: 0035** Specific Field: **Endoscopic Surgery**

**Mode of pres.: Poster Exhibition only**  
**ISW 2011 Session PE 7**

**Laparoscopy-assisted proximal gastrectomy with preserving of vagus nerve for gastrointestinal stromal tumor: a case report**

M. Katayama, J. Sakurai, J. Shimada, A. Fukuoka, T. Enomoto, S. Mikami, T. Fukunaga, T. Otsubo

St. Marianna University School of Medicine, Kawasaki, Japan

**Introduction:** A-59-year-old man was diagnosed with having a submucosal gastric tumor as a result of a medical check-up. Upper gastrointestinal endoscopy revealed a submucosal gastric tumor without ulcer lesion, about 20 mm in diameter, in the cardia. Pathological findings of biopsy specimens showed normal gastric mucosa. After 6 month from first examination, follow up upper gastrointestinal endoscopy revealed a growth of the tumor, about 30 mm in diameter. Abdominal computed tomography (CT) showed a mass in the cardia, measuring 30 mm, and some lymph nodes around the cardia (station 1, 2) and along left gastric artery (station 3a). From these findings, we should be performing proximal gastrectomy with lymph node dissection. Because the tumor was close to the cardia, lymph node

metastasis in a case of GIST is rare, but has a poor prognosis. The esophago-gastric anastomosis was created using a 25 mm anvil (OrVii™) passed trans-orally and a circular stapler (end-to-end anastomosis stapler (EEA XL™) 25 mm with 4.8-mm staples) in the gastric anterior wall. And we reconstructed by esophagogastrostomy with Toupet-like partial fundoplication. Postoperative histological examination showed that the tumor was positive for c-kit and CD34 immunohistochemically, and consisted of spindle cells. We made a diagnosis of GIST with a low malignant potential. The case report of laparoscopy-assisted proximal gastrectomy with preserving of vagus nerve and lymph node dissection for GIST is rare. We describe a case of performed laparoscopy-assisted proximal gastrectomy with preserving of vagus nerve for GIST and show the operative procedure.

**Abstract ID: 0036** Specific Field: **Endoscopic Surgery**

**Mode of pres.: Poster Exhibition only**  
**ISW 2011 Session PE 8**

**Our new procedure of RY reconstruction with inverted J-shaped pouch in laparoscopically assisted total gastrectomy**

K. Hattori [1], Y. Kamiya [1], M. Takeyama [2], M. Hatoh [1], Y. Itoh [1], T. Miyamae [1], H. Sagawa [1]

[1] Kakegawa City General Hospital, Kakegawa, Japan,  
[2] Gastroenterological Surgery of Nagoya City University, Nagoya, Japan

**Introduction:** Since 2004, after open total gastrectomy (OTG), we have included a pouch formation in Roux en Y reconstruction protocol (PRY), to increase the amount of meal to be taken once. And since 2007, we had performed the PRY in laparoscopically assisted total gastrectomy (LATG) in 8 cases. However, the LATG-PRY method took longer operation time and had to make a mini open incision. So, since 2009 we tried to improve our LATG-PRY method in 12 cases and reduced reconstruction time by the new method without a mini open incision. In the present study, we propose a protocol to overcome the technical weak points encountered during the former PRY procedures in LATG.

**Material and Methods:** The former procedures of PRY: Skin incision of 6 cm length was made at the midline of epigastric region. Jejunum was pull out through the incision, formed an inverted J-shaped pouch of 15 cm long or a Y-shaped anastomosis, and then it was placed back into the abdominal cavity each other. The pouch was anastomosed with a circular stapler to the esophagus under direct vision through the 6 cm midline incision. The new procedures of PRY: All reconstructive procedures were performed laparoscopically without a mini open incision. An pouch was formed and was anastomosed to the esophagus with a linear staplers and its entry hole was closed. Then laparoscopically the Y-shaped anastomosis was formed with a linear stapler and its entry hole was closed.

**Results:** Reconstruction time: Average reconstruction time of the former procedure (8 cases) was 78 min and one of the new procedure (12 cases) was 45 min. Hospital stay: Average length of hospital stay after operation was 6.0 days in the former procedure and 6.1 days in the new procedure. Amount of meals: Average amount of meals the patients could take per once in six months after the operations were 78.0% in the former procedure and 75.0% in the new procedure. The amount of meals the patients of both pouch methods could take were twice as much the patients of LATG-RY method (37.5%) could take. In all of methods presented here, no severe complications such as anastomotic stenosis or leakage were encountered, indicating that these methods are safe and practical.

**Conclusions:** With the new procedures of LATG-PRY we had no handles through the mini open incision. Therefore we had less stress

under these operations and could reduce the average operation time by about 30 min

**Abstract ID: 0037** Specific Field: **Endoscopic Surgery**

**Mode of pres.: Poster Exhibition only**  
**ISW 2011 Session PE 9**

**Single-incision laparoscopic cholecystectomy in situs inversus totalis with acute cholecystitis: a case report**

Y. Kaiwa [1], Y. Ohashi [2], K. Satoh [2], H. Satoh [2], T. Sakurai [2], R. Abe [2]

[1] Katta General Hospital, Shiroishi, Japan, [2] Katta General Hospital, Japan

**Introduction:** Laparoscopic cholecystectomy has been the gold standard procedure for gallbladder removal. Recently surgeon's efforts are continuing to reduction of the size and number of ports. Now single-incision laparoscopic cholecystectomy has gained greater interest and popularity. On the other hand, situs inversus totalis is a rare congenital disorder estimated to occur in 1 in 5000–10000 births. It is characterized by the transposition of the major thoracic organs and all the visceral organs of the abdomen to the side opposite to normal position in the body. We report a case of successful single-incision laparoscopic cholecystectomy in a patient with acute cholecystitis and situs inversus totalis.

**Material and Methods:** A 69-year-old male with situs inversus totalis was admitted to our hospital because of acute cholecystitis. We performed a single-incision laparoscopic cholecystectomy on the next day of the admission. In order to conduct the laparoscopic cholecystectomy all theatre equipment including electrocautery, monitors and video systems were positioned in the mirror image of their normal position. The surgical team also changed sides with the primary surgeon and camera assistant on the patient right and first assistant on the left. A single intraumbilical 25-mm incision was made, and the umbilicus was pulled out, exposing the fascia. A 5-mm trocar was placed, and the abdominal cavity was explored with a 5-mm 30° laparoscope. Two 5-mm trocars were introduced laterally from the laparoscope port. A 5-mm grasper was inserted directly caudally from the scope port. Dissection was performed using an electric cautery hook and ultrasonic coagulating shears. After the dissection, one of the trocars was replaced by a 10-mm trocar, and the gallbladder was removed inside a bag through the umbilical incision. The trocar sites on the fascia and the skin incision were closed with absorbable sutures.

**Results:** All procedures were safely completed without any perioperative complications.

**Conclusions:** Single-incision laparoscopic cholecystectomy was feasible, safe, and effective for the treatment of acute cholecystitis with situs inversus totalis.

**Abstract ID: 0038** Specific Field: **Endoscopic Surgery**

**Mode of pres.: Poster Exhibition only**  
**ISW 2011 Session PE 10**

**Single-port cholecystectomy with the patient in the lithotomy position and the surgeon seated: a unique approach at Hiratsuka City Hospital for expanded indications**

T. Akatsu, M. Nakagawa, T. Kanai

Hiratsuka City Hospital, Hiratsuka, Japan

**Introduction:** When single-port cholecystectomy (SPC) was first introduced at our hospital, just as with conventional methods, the



surgeon and scopist stood on the left side of the patient to perform surgery. However, this places the “line connecting the gallbladder and umbilicus” far away from the surgeon, so that surgery must be performed in an uncomfortable position. Furthermore, the surgeon and scopist may interfere with each other, thus restricting movement. In addition, in “glove procedure”, because the forceps and the camera are not fixed and manipulation becomes unstable, this creates a highly stressful surgical procedure. A new method used at our hospital to solve these problems is reported.

**Material and Methods:** After induction of general anesthesia, the patient is placed in the lithotomy position. The surgeon stands on the left of the patient, the assistant stands on the right, the scopist stands between the patient’s thighs, and an umbilical incision is made. A wound retractor (Alexis) is placed in the incision, a glove is put on it, four ports are inserted inside its fingers, and insufflation is initiated. Then, the surgeon moves between the patient’s thighs, the scopist moves to the left side, and the assistant moves to the right side. After elevating the patient’s head, the surgeon and scopist are seated, and cholecystectomy is started.

**Results:** With this approach, the surgeon, now between the patient’s thighs, is located along a line extending from the “line connecting the gallbladder and umbilicus,” which creates a comfortable position for surgery. The surgeon and scopist no longer interfere with each other, thus permitting smoother manipulation. In addition, in a seated position, unsteadiness of the body and arms is reduced, so manipulation of forceps by the surgeon, and the camera by the scopist, become much more stable.

**Conclusions:** In SPC, which is often a difficult and highly stressful procedure, the patient in the lithotomy position and the surgeon seated may be very effective. We currently use this not only in patients with cholelithiasis and gallbladder polyps, but also for expanded surgical indications in patients with acute cholecystitis including cases after PTGBD and even for those with previous upper abdominal surgery.

#### Abstract ID: 0039 Specific Field: Endoscopic Surgery

**Mode of pres.: Poster Exhibition only**  
**ISW 2011 Session PE 11**

##### Short-term outcomes of laparoscopic surgery for stage IV colorectal cancer

Y. Kuriu, Y. Kokuba, E. Otsuji

Kyoto Prefectural University of Medicine, Kyoto, Japan

**Introduction:** The safety and efficacy of laparoscopic surgery for Stage IV colorectal cancer remain uncertain. Short-term outcomes of laparoscopic surgery for patients with Stage IV colorectal cancer were compared with that of open surgery in our institute.

**Material and Methods:** A total 314 patients underwent laparoscopic surgery (resection of primary tumors) between June 2007 and March 2010. 23 patients with Stage IV disease who underwent laparoscopic surgery only for primary tumors were compared with 17 patients who underwent open surgery. The criteria for excluding Stage IV patients from laparoscopic surgery were huge rectal cancer, peritoneal seeding, bowel obstruction and perforation.

**Results:** The age range, sex distribution, tumor location (colon/rectum), and depth of invasion were similar in both groups. The median estimated blood loss of laparoscopic surgery group was significantly smaller than that of open surgery group (30 vs. 200 g,  $P = 0.0014$ ). The median operating time in the two groups was similar (218 vs. 227 min,  $P = 0.891$ ). The postoperative morbidity rates of the two groups were similar (laparoscopic group, 17%; open group, 41%;  $P = 0.095$ ). Length of hospital stay of laparoscopic surgery group was significantly shorter than that of open surgery group (14 vs. 20 days,  $P = 0.02$ ).

**Conclusions:** Laparoscopic surgery for Stage IV colorectal cancer is a safe and feasible option, and presents acceptable morbidity. These results indicate laparoscopic surgery can be successfully performed in selected Stage IV colorectal cancer patients.

#### Abstract ID: 0040 Specific Field: Endoscopic Surgery

**Mode of pres.: Poster Exhibition only**  
**ISW 2011 Session PE 12**

##### Reduced port surgery for laparoscopic anterior resection

H. Kawahara [1], K. Watanabe [1], T. Ushigome [1], S. Yanagisawa [1], S. Kobayashi [1], H. Kashiwagi [2], K. Yanaga [2]

[1] Dept. Surg., Kashiwa Hospital, Jikei Univ. Sch. Med., Chiba, Japan, [2] Dept. Surg., Jikei Univ. Sch. Med., Tokyo, Japan

**Introduction:** High surgical technique is required for laparoscopic anterior resection using single incision laparoscopic surgery (SILS) like multiport surgery. We report a novel surgical technique of umbilical incision laparoscopic surgery with one assist port as reduced port surgery, which could be performed like conventional multiport surgery. The aim of this study was to evaluate the usefulness of our reduced port surgery for laparoscopic anterior resection.

**Material and Methods:** Patients: Between August in 2009 and December in 2010, seventeen patients underwent umbilical incision laparoscopic surgery with one assist port, two port surgery (TPS), for anterior resection as reduced port surgery. Technique: With the patient in the lithotomy position, a 3 cm longitudinal skin incision is made at the umbilicus and carried down to the peritoneum. A SILS port (Covidien) is placed through the incision. After pneumoperitoneum, a 12-mm trocar is placed for insertion of laparoscopic coagulation shears (LCS) and stapler in the right lower quadrant. After surgery, the trocar in the right lower quadrant is removed and a drain is replaced with the trocar. The operator mainly uses two trocars, 5-mm one placed at the SILS port and the right lower quadrant 12-mm one, which simulates conventional laparoscopic surgery. The assistant uses the other 5-mm trocar placed at the SILS port to give counter tractions.

**Results:** The mean operation time was 164.6 (range 115–255) min, the mean intraoperative blood loss was 7.1 (range 0–60) ml, and the mean postoperative hospital stay was 9.8 (range 9–11) days. Postoperatively, none of the seventeen patients had any complications.

**Conclusions:** TPS for anterior resection seems to be useful Tis to T2 rectal cancer rather than multiport surgery.

#### Abstract ID: 0041 Specific Field: Endoscopic Surgery

**Mode of pres.: Poster Exhibition only**  
**ISW 2011 Session PE 13**

##### Simultaneous robotic colon and liver resection using da Vinci surgical system for a cecal cancer with a synchronous liver metastasis

T. Kagawa, Y. Kato, T. Tokoro, Y. Tanahashi, J. Yoshida, C. Takeura, A. Sugioka, I. Uyama

Department of Surgery, Fujita Health University School of Medicine, Toyoake, Aichi, Japan

**Introduction:** Liver resection using da Vinci Surgical System (da Vinci) has a potential to overcome shortcomings and limitations of conventional laparoscopic liver resection. The mechanical advantages of da Vinci include the three-dimensional high definition images served on the view port and robot arms applied with multi-articulated



forceps with 7-degrees of freedom, which enable smooth and accurate movement with the aid of the scaling and filtering functions. We have performed 5 liver resections using da Vinci for colorectal metastases since December 2009. In one of the patients, we performed a simultaneous robotic colon and liver resection for a cecal cancer with a synchronous liver metastasis.

**Material and Methods:** The patient was a 60-year-old man diagnosed with a 4 cm cecal cancer with a 1 cm liver metastasis in the segment 8 (S8). He underwent a robotic ileocecal resection in conjunction with partial resection of S8. The camera port was inserted in the left lower quadrant. Three robot arm ports were placed in the upper abdomen, with two ports for assistants. Ileocecal resection was done with a technique of internal approach. The bowel specimen was brought out from the umbilicus. Liver resection followed After marking the cutting line using intraoperative ultrasonography, liver was transected with Harmonic Scalpel R. Significant Glissonian and hepatic venous branches were ligated or clipped.

**Results:** Intraoperative blood loss and operating time were 240 g and 11 h 19 min in total, respectively. Oral intake was started on the first postoperative day, and there were no perioperative complications. The patient was discharged on the 9th postoperative day. From 2 months after resection, the patient received adjuvant chemotherapy, and at 9 months he had no recurrence.

**Conclusions:** Reports on robotic simultaneous bowel and liver resection is limited, but this case suggests that this procedure using da Vinci is safe and feasible, and may improve oncologic outcome by offering high-quality surgical techniques.

#### **Abstract ID: 0042** Specific Field: **Endoscopic Surgery**

**Mode of pres.: Poster Exhibition only**  
**ISW 2011 Session PE 14**

##### **Clinical analysis of indication for laparoscopic colectomy in early (M/SM1) colorectal cancer**

Y. Kabeshima [1], T. Kakefuda [2], T. Omori [2]

[1] Kawasaki Municipal Hospital, Japan, [2] Kawasaki Municipal Hospital, Kanagawa, Japan

**Introduction:** EMR is indicated for the treatment of intramucosal (M), submucosal superficial (SM1) colorectal cancer. On the other hand, there are several cases require surgical operations because of its difficulty of endoscopic treatment. We investigated the indication boundaries for EMR, endoscopic submucosal resection (ESD) and laparoscopic colectomy (LAC) as standard treatments for early (M/SM1) colorectal cancer.

**Material and Methods:** We retrospectively analyzed 487 lesions of early colorectal cancer (M/SM) treated between 2005 and 2008.

**Results:** Results for 328 lesions treated between 2005 and July 2007 were 315 lesions for endoscopic therapy (EMR 260 lesions, EPMR 51 lesions, anal surgery 5 lesions. 50% of tumor types not possible to treat with EMR were flat elevated type which size were 20–25 mm (36%), and 25–30 mm (29%) in a diameter. Analysis performed by dividing the morphological causes for EPMR, and LAC into three groups, namely (A) lesions exceeding 30 mm in a diameter (large type), (B) flexura type, and (C) lesions that astrided the fold (fold type), it was shown that the most frequent was the fold type with 34%. LAC (12 cases) cases as well had 8 cases of the fold type (67%). It was thought that the introduction of ESD was beneficial for the avoidance of LAC in flat elevated type or fold type with a width of less than 30 mm. The LAC percentage for the large type was 0.3% (1 case) among all cases, the reason for which is thought to be the fact that many of the lesions were capable of being treated by EPMR.

From August 2007. We treated flat elevated type or fold type lesions under 30 mm by ESD. By the end of 2008, 148 of the 159 lesions underwent endoscopic therapy (ESD 10 cases), 4 underwent anal surgery, 6 underwent LAC. Only 1 case (0.6%) of the LAC was considered possible to avoid surgery. LAC (60 cases: 2000–2008) for large and flexura types of early colorectal cancer was considered feasible because of the outcome of 157 min Op time, 40 ml blood loss, 7 days of postoperative hospital stay and its complication rate. **Conclusions:** EMR is appropriate for unified or planned EPMR. ESD is for fold-type/ flat elevated type less than 30 mm that are difficult to treat by EMR. Flexura types and large types for impossible to treat with planned EPMR are indicated by LAC. With the above indications no recurrence case has been confirmed as of December 2010.

#### **Abstract ID: 0043** Specific Field: **Endoscopic Surgery**

**Mode of pres.: Poster Exhibition only**  
**ISW 2011 Session PE 15**

##### **A case of mucosal ascending colon cancer recurrence in the form of submucosal invasive tumor following endoscopic piecemeal mucosal resection**

Y. Inoue, T. Oki, M. Yamamoto

Tokyo Women's Medical University, Tokyo, Japan

**Introduction:** Resection of early colorectal cancer by endoscopy has become possible with progress in colonoscopic diagnosis and technology. Thus, most colorectal mucosal cancer and benign tumor cases have been resected by endoscopy. Here, we describe a case mucosal ascending colon cancer recurrence in the form of a submucosal invasive tumor (SMT) following endoscopic piecemeal mucosal resection (EPMR). The patient was a 63-year-old woman who underwent colonoscopy at another hospital because of fecal occult blood. She was referred to our hospital for endoscopic treatment of a tumor detected in the ascending colon near the cecum by colonoscopy. At our hospital, colonoscopy revealed lateral spreading tumor-granular type of about 40 mm diameter in the ascending colon. EPMR was performed together with argon plasma coagulation. Follow-up colonoscopy after 4 months showed recurrence in the form of SMT in the ascending colon. As this lesion was thought to be unresectable by endoscopy, surgical bowel resection was performed. Histopathologic findings showed a well-differentiated tubular adenocarcinoma (pSS, n1(+)). Postoperative chemotherapy (UFT/LV) was carried out for 6 months and no recurrence was observed.

#### **Abstract ID: 0044** Specific Field: **Endoscopic Surgery**

**Mode of pres.: Poster Exhibition only**  
**ISW 2011 Session PE 16**

##### **Double-incision laparoscopic surgery (DILS) for colorectal cancer**

H. Hirukawa [1], T. Kobayashi [1], T. Tada [2]

[1] Tachikawa General Hospital, Nagaoka, Japan, [2] Tachikawa General Hospital, Japan

**Introduction:** Single-incision laparoscopic surgery (SILS) has begun to develop. The most apparent benefit of SILS has been reported as postoperative cosmesis, but its real benefits have not been proven. In SILS, triangulation must be forfeited to avoid collision of the instruments. The surgeon must create and maintain proper tension with only one forceps. The surgical technique becomes more difficult

in comparison with standard laparoscopic surgery. Therefore, SILS should be adapted carefully to advanced colorectal cancer surgery. We perform double incision laparoscopic surgery, so called DILS for colorectal cancer. We aimed to evaluate the safety and efficacy of our DILS technique for colorectal cancer surgery.

**Material and Methods:** In the period from November 2009 through December 2010, 28 patients underwent DILS for colorectal cancer. Data were collected on these cases retrospectively. The abdomen was approached through a 2.5- to 3-cm incision via the umbilicus. A multiple instrument access port (SILS™ Port, COVIDIEN, Japan) was inserted through the incision, and a 5- or 12-mm additional port was placed premeditatedly. Operator inserted the forceps or an energy device by right hand through an additional port, and inserted another forceps through SILS™ Port by left hand, and assistant inserted forceps through SILS™ Port to make traction to operative field. The surgical procedure was same with conventional laparoscopic colorectal surgery. A drainage tube was inserted through the additional port site if necessary.

**Results:** Surgical procedures were right hemicolectomy ( $n = 14$ ), transverse colectomy ( $n = 1$ ), left hemicolectomy ( $n = 2$ ), sigmoidectomy ( $n = 4$ ), anterior resection ( $n = 7$ ). The median total surgical time was 201 min (range, 139–351), median amount of surgical blood loss was 10 ml (range, 5–100). 1 case required an additional port placement. There were no conversions to open surgery. Post operative complications were wound infection in 1 case, and anastomotic hemorrhage in 1 case. The mean postoperative hospital stay was 10 days (range, 6–28).

**Conclusions:** In DILS, the surgeon's working hand was free and there were no limitations with regard to movement range. The surgeon was able to make an adequate traction and triangulation for dissection. DILS for colon cancer is a safe, effective and minimally invasive procedure.

#### Abstract ID: 0045 Specific Field: Endoscopic Surgery

**Mode of pres.: Poster Exhibition only**  
ISW 2011 Session PE 17

##### Endoscopic transanal resection (ETAR) in treating rectal adenomas: 14 years' experience

V. Sallinen [1], H. Santti [1], T. Liukkonen [2], V.-M. Puolukka [1]

[1] South Carelia Central Hospital, Lappeenranta, Finland,  
[2] Mikkeli Central Hospital, Mikkeli, Finland

**Introduction:** Rectal adenomas present a challenge for treatment due to their anatomical location. Treatment options include conventional transanal excision, snare polypectomy and transanal endoscopic microsurgery. Earlier, a few studies have reported the use of standard urological resectoscope to treat rectal adenomas with success. Our hospitals have used endoscopic transanal resection (ETAR) to operate rectal adenomas not amenable to polypectomy. Treatment was carried out in interdisciplinary approach in which urologist provided technical expertise while colorectal surgeon handled selection of patients and long-term follow-up.

**Material and Methods:** Records of all patients ( $n = 66$ ) undergone ETAR during 1996–2009 in Mikkeli Central Hospital ( $n = 17$ ) and South Carelia Central Hospital ( $n = 49$ ) were retrospectively studied. Gathered information included patient, adenoma and technical characteristics as well as follow-up information.

**Results:** Mean age of patients was 70.5 years (range 43–92). 45.5% were male. ASA classes were 1 in 14%, 2 in 30%, 3 in 53%, and 4 in 3%. Mean distance of adenoma from the anal verge was 6.3 cm (0–15 cm) and size 3.3 cm (1–12 cm). 30% were tubular, 3% villous and 67% tubulovillous adenomas. Mean operation time for first ETAR

was 42 min (10–123 min). Complication rate was 17%. All complications were minor (Clavien grade I–II), except for one case where explorative laparotomy was carried out. There was no perioperative mortality. Mean hospital stay was 4.3 days (2–16 days). Mean follow-up time was 32 month (0–111 month). 12 of patients (18%) had recurrence in follow-up. 3 were handled with ETAR, 2 with transanal excision, 2 with polypectomy or biopsy forceps, 1 with electrocoagulation, and 3 underwent abdominoperineal resection. One patient with recurrence was still under evaluation. Median number of re-ETARs was 1 (1–8).

**Conclusions:** ETAR is mini-invasive, safe—even in frail patients—and inexpensive method to deal with adenomas of rectum not amenable to snare polypectomy. Major drawback of ETAR is lack of oriented tissue sample for pathologist. As margins cannot be assessed, treated patients require strict follow-up regime. We advocate interdisciplinary approach using expertise of both urologist and colorectal surgeon.

#### Abstract ID: 0046 Specific Field: Endoscopic Surgery

**Mode of pres.: Poster Exhibition only**  
ISW 2011 Session PE 18

##### A case of malignant peritoneal mesothelioma were diagnosed by laparoscopic biopsy

H. Harada, M. Watanabe, M. Naito, T. Sato, A. Ikeda, N. Ogura, W. Onozato, T. Nakamura

Kitasato University, Sagamihara, Japan

**Introduction:** Malignant peritoneal mesothelioma is a rare disease. Diagnosis is difficult because of the low accuracy rate of cytology. We report a case of malignant peritoneal mesothelioma diagnosed by laparoscopic biopsy. A seventeen year old man showed abdominal distention and pain. Computed tomography (CT) scan revealed ascites, hypertrophy of the peritoneum, and nodules scattered in the mesentery. Positron emission tomography-CT revealed FDG uptake of greater omentum and mesentery. Cytologic examination of ascites revealed a large atypical cells. He was suspected malignant peritoneal mesothelioma because immunostain of those cells were positive of the Calretinin, EMA, and HBME-1. Laparoscopic biopsy was performed for definitive diagnosis. The procedure was performed by the vertical incision of umbilicus, aspirated a great deal ascites, and picked some nodules from lesser omentum. Nodules were showed greater and lesser omentum, peritoneum, and mesentery. Pathological examination revealed a nodule forming cells with enlarged nuclei, and immunostain of those cells were positive of CK5/6, CK7, HBME-1, Calretinin, Vimentin, and RCC. He was diagnosed the malignant peritoneal mesothelioma by laparoscopic biopsy. Laparoscopic surgery is minimally invasive and technically safe. In addition, this procedure is useful as method of biopsy for definitive diagnosis.

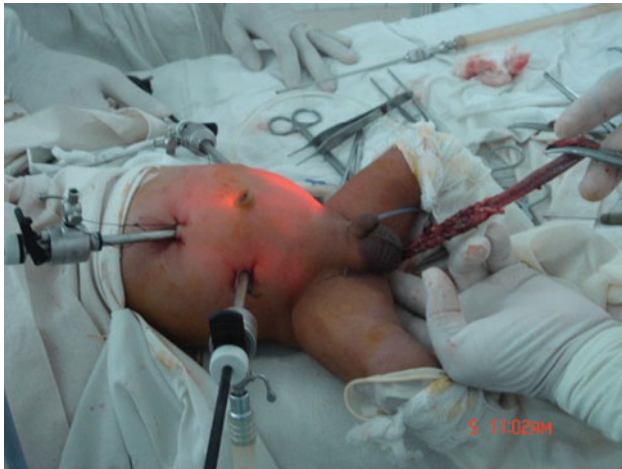#### Abstract ID: 0047 Specific Field: Endoscopic Surgery

**Mode of pres.: Poster Exhibition only**  
ISW 2011 Session PE 19

##### Pediatric laparoscopy in Bangladesh: pioneering role and experience in Chittagong

M.J. Hannan [1], M.M. Hoque [2]

[1] Chattagram Maa-O-Shishu Hospital Medical College, Chittagong, Bangladesh, [2] Chattagram Maa-O-Shishu Hospital, Bangladesh



**Figure:** Laparoscopy-assisted pull-through operation

**Introduction:** Pediatric Laparoscopy i.e. Minimally Invasive Approaches in children continue to develop both in technical complexity and equipments over the years. This is a newer concept in Bangladesh and started just five and a half years ago. However, due to resource constraints we are to practice with conventional equipments and still performing some advanced procedures. This article will review the common procedures as well as the first Bangladesh experience of some advanced laparoscopic procedures in children.

**Material and Methods:** From 7, October 2005 to 31, December 2010, 1817 cases underwent laparoscopic procedures. We use conventional laparoscopic instruments including 5 mm 30 telescope & single chip camera. All the cases were done under general endotracheal anesthesia. We keep CO<sub>2</sub> pressure below 8 mm Hg in neonates and upto 15 mm Hg in older children. We use counter traction with silk bites during introduction of 2nd and subsequent trocars in neonates. We avoid handling cystic artery during cholecystectomy. Age, sex, indications, operative procedures, complications and outcome are evaluated retrospectively.

**Results:** Age of the patients ranged from 3 days to 16 years and 88 were neonates. Two percent had some problems with less than .05% with serious complications. Nine cases needed conversion (6 appendectomies, 4 Georgeson's and one pyloromyotomy). Port-site infection occurred in 5 early cases and post-operative ileus in 3 post-appendectomy cases. Five cases of Georgeson's operation developed sepsis needing colostomy and two of them died. One orchiopexy patient developed ureteral obstruction. Three inguinal hernia recurred.

**Conclusions:** Laparo-endoscopic surgery is safe and can achieve a same, sometimes better surgical goal as in open surgery.

#### Different laparoscopic procedures and age distribution

0–1 month	1–12 months	1–3 years	Above 3 years	Total
68	21	13	5	107
Appendectomy	0	3	106	1362
Inguinal Hernia Repair	11	27	19	24
81				
Orchiopexy	0	6	32	23
61				

#### Table continued

0–1 month	1–12 months	1–3 years	Above 3 years	Total
Pyloromyotomy	19	14	0	0
33				
Cholecystectomy	0	0	3	18
21				
Ovarian Cystectomy	5	3	3	12
23				
Others	4	5	4	7
20				
Total	107	79	180	1451
1817				

**Abstract ID: 0048** Specific Field: Endoscopic Surgery

**Mode of pres.: Poster Exhibition only**  
**ISW 2011 Session PE 20**

#### Hepalift X: new device for the retraction of the liver in laparoscopic gastrectomy

M. Fujiwara [1], T. Nakamura [2], C. Tanaka [1], N. Ohashi [1], G. Nakayama [1], M. Koike [1], Y. Kodera [1], A. Nakao [1]

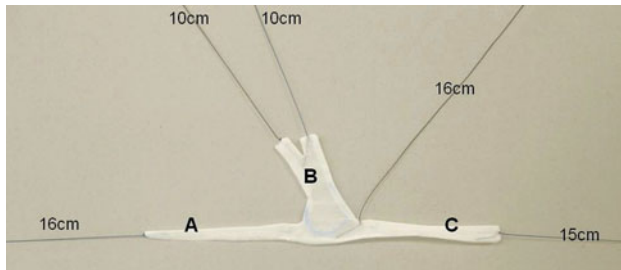
[1] Nagoya university, Nagoya, Japan, [2] Osaki Medical Corporation, Nagoya, Japan

**Introduction:** The left lobe of the liver overlies the lesser curvature of the stomach to obstruct good surgical field in laparoscopic operations of the stomach or abdominal esophagus. Many techniques has been described for retracting the left lobe of the liver, such as simple falciform lifting by the suture, the technique using a Penrose drain or a metallic liver retractor. We also used the technique suturing falciform ligament in early period and afterwards we contrived various shaped Penrose. We have developed ready-made device based on the experience of processed Penrose.

**Material and Methods:** The new device named Hepalift X is made by polyester with 3 legs (Fig.; A, B, C), including radiopaque line. B leg divides into two ends to be Y-shaped. The each end of the legs is connected with 10–16 cm nylon thread, and 16 cm nylon thread is fixed at the crotch of B leg and C leg. Surgical technique: First, small hole is made at the coronary ligament of the left lobe of the liver. Secondly, A, B legs of Hepalift X is inserted through the hole and pulled into the ventral side of the liver. And then, the thread fixed to C leg is pulled out of the abdominal wall beneath the xiphoid process with End Close™ (Covidien, Mansfield, MA, USA). Next, the thread fixed to A leg is pulled out through 7 or 8th intercostals space or fixed by the forceps as weight at Morrison's pouch (hepatorenal fossa). And then the threads fixed to B legs are pulled out beneath the xiphoid process, which forks lift up the falciform ligament. Finally, the 16 cm thread from the crotch of B and C legs is pulled out at the left subcostal region, which complements lifting up the left lobe of the liver.

**Results:** We have used this new device in 11 cases of laparoscopic gastrectomy and Heller-Dor operations. In all cases the liver is successfully lifted up and no complement is needed.

**Conclusions:** The usefulness of this device is equivalent to Penrose method. It is timesaving compared to processing Penrose. The usefulness of this device is equivalent to Penrose method. It is inexpensive and saves the time to processing Penrose.



**Figure:** Hepalift X

**Abstract ID: 0049** Specific Field: **Endoscopic Surgery**

**Mode of pres.: Poster Exhibition only**  
**ISW 2011 Session PE 21**

**Efficacy of fluoroscopy-assisted thoracoscopic surgery under local anesthesia for the treatment of empyema**

Y. Kita [1], Y. Shundo [2], K. Suzuki [3]

[1] Haibara General Hospital, Makinohara, Japan, [2] Tenryu Suzukake Hospital, Hamamatsu, Japan, [3] Hamamatsu Toyooka Hospital, Hamamatsu, Japan

**Introduction:** Recent thoracoscopic advances have altered the approach for thoracic diseases. Less invasive surgery produces the reduction of morbidity, shortness of hospitalization, and cost reduction. The thoracoscopic surgery, 7 mm semi-rigid thoracoscope with working channel provides excellent visualization and developed for both diagnostic and therapeutic purposes, especially for acute empyema.

**Material and Methods:** The operation was usually performed with the patient in the lateral position. Our methods were as follows. Under local anesthesia, small skin incision, less than 10 mm length, was made in the mid-axillary line and 8 mm soft thoracoport was introduced. The 7 mm semi-rigid thoracoscope with single working channel (Olympus LTF type 240, Olympus, Japan) was introduced into pleural cavity, and the intrathoracic condition was inspected. We ordinary operated through one thoracoport. These procedures were followed by cleaning the cavity and placement of drain under thoracoscopic visualization with fluoroscopy. We checked the lung was expanded under thoracoscopic visualization.

**Results:** From January 2003, 120 patients were studied, including 35 cases in fluoroscopy group. There were no operative complications associated this fluoroscopy-assisted surgery, and no recurrence of empyema. However, in ordinary methods without fluoroscopy, 5 cases needed some additional procedures. This modified method was very safe and effective.

**Conclusions:** These procedures were safe, effective, and minimally invasive. For elderly patients with chronic empyema and severe condition, the indication of operation must be discussed.

**Abstract ID: 0050** Specific Field: **Endoscopic Surgery**

**Mode of pres.: Poster Exhibition only**  
**ISW 2011 Session PE 22**

**Laparoscopic treatment of acute small bowel obstruction**

I. Kishimoto [1], T. Omura [2], K. Kawamoto [1], Y. Takemoto [1], Y. Koba [1], T. Takahashi [3], K. Sato [1], T. Takahashi [1]

[1] Higashiyamoto-Hospital, Higasiyamoto-si Tokyo, Japan, [2] Higashiyamoto Hospital, Japan, [3] Musashimurayama Hospital, Musashimurayama-si Tokyo, Japan

**Introduction:** Laparoscopic management of acute small bowel obstruction may have clinical advantages. We have applied this procedure in patients, (1) with no signs indicating severe bowel ischemic change, (2) who had no previous surgery or no more than 2, (3) in whom intestinal decompression was achieved using a nasogastric tube, preoperatively. The aim of this study was to clarify the usefulness of this procedure.

**Material and Methods:** From July 1994 through December 2010, 165 patients were admitted to our hospital for acute bowel obstruction. Among these patients, laparoscopic approach was undertaken in 26 cases and was completed in 20 (lap group). Remaining 138 cases were treated with conventional open surgery (open group). Operation time, post operative hospital stay, and post operative complications were compared between the groups.

**Results:** The laparoscopic procedures in the lap group included freeing of adhesion (in 13 cases), partial resection of the small bowel (in 5), and extirpation of the foreign body (in 2). In the half of the patients, the site of obstruction was preoperatively assumed with contrast fluoroscopy through the nasogastric tube. Operation time was not significantly different in the two groups (97.2 vs 101.0 min, NS). Post operative hospital stay was shorter in the lap group than in the open group (14.0 vs 29.5 days;  $P < 0.05$ ). Post operative complications were less frequent in the lap group (5.0% vs 41.0%,  $P < 0.05$ ). No mortality was observed in the lap group. Six cases were converted to open surgery because of insufficient bowel decompression in 3 cases, strong adhesions in 2, and injury to the small bowel during the procedure in 1.

**Conclusions:** Laparoscopic treatment for patients with acute bowel obstruction was safely performed and was effective resulting in shorter hospital stay and less complications in selected patients.

**Abstract ID: 0051** Specific Field: **Endoscopic Surgery**

**Mode of pres.: Poster Exhibition only**  
**ISW 2011 Session PE 23**

**Usefulness of laparoscopic liver resection for multiple HCCs**

S. Kodai, T. Tsukamoto, A. Kanazawa

Department of Hepato-Biliary-Pancreatic Surgery, Osaka City General Hospital, Osaka, Japan

**Introduction:** Laparoscopic liver resection minimizes hepatic and parietal injury, thereby decreasing the risk of liver failure and ascites, above all for patients with hepatocellular carcinoma (HCC) and cirrhosis. This approach is mainly adapted for solitary tumor and which are located in the anterior-inferior parts of the liver. However, we believe there is room for laparoscopic liver resections of multiple liver tumors especially exists in both lobes. The aim of this study is to assess the safety and the usefulness of laparoscopic liver resection for multiple HCCs.

**Material and Methods:** Among 104 hepatocellular carcinoma patients who received laparoscopic liver resection, 19 cases received laparoscopic liver resection for multiple HCCs. There were 13 cases that HCCs exist in both lobes and 6 cases that HCCs exist in same lobe. Results were analyzed retrospectively.

**Results:** Of 19 cases, 10 cases received pure laparoscopic liver resections. 9 case received combination operation (3 cases received pure laparoscopic liver resection and HALS. 5 cases received laparoscopy-assisted liver resections. One case received pure laparoscopic liver resection and thoracotomy liver resection). All cases were



successfully performed with no intraoperative complications. In laparoscopic liver resection, by using the postural rotation for the change of organ position, a visual field was made better from the same port. Mean number of resected tumors was 2.1 pieces (2–4 pieces), median operative time was 389 (120–703) min, median blood loss was 389 (5–2300) ml, and median hospital stay was 10 days. Postoperative complication caused by laparoscopy, for example HCC recurrence of the port site was not occurred. Bile leakage occurred in two laparoscopy-assisted cases that tumor contacted Glisson sheath.

**Conclusions:** Our experience with carefully selected cases suggests that laparoscopic liver resection is safe and feasible not only for solitary HCC but multiple HCCs by using the postural rotation and combination surgery. This approach seems to be complementing the weakness of conventional laparotomy, and can become the new therapeutic options for HCC.

### Abstract ID: 0052 Specific Field: Endoscopic Surgery

**Mode of pres.: Poster Exhibition only**  
**ISW 2011 Session PE 24**

#### Laparoscopic surgery for ulcerative colitis that leaves no incisional wound

Y. Kokuba, Y. Kuriu, E. Otuji

Kyoto Prefectural University of Medicine, Kyoto, Japan

**Introduction:** Surgery for ulcerative colitis (UC) is highly invasive due to the poor general condition of most UC patients and the large section of the colon excised. Studies have been performed to develop a surgical method with minimal invasiveness. We have applied these techniques to UC surgery to establish minimally invasive standard surgery that does not leave an incisional wound.

**Material and Methods:** A 5-mm flexible laparoscope is used. A small incision of about 3 cm is made at the marking for the stoma site. Under laparoscopic guidance, five 5-mm trocars and two 12-mm trocars are inserted. For intestinal mobilization, the omental sac is first opened, and the splenic flexure with marked inflammation where dissection is difficult is mobilized. To minimize the time required for surgery, the right and left sides of the colon are mobilized by rolling the mesentery from the caudal to the cephalic direction. A 5-mm vessel sealing system is used to handle vessels. For rectal dissection, a proper dissection layer is maintained to the levator muscle of the anus without damaging the autonomic nerve. The colon is removed from the body through a small incision. A “J”-shaped ileoanal pouch is formed, and an anvil head is inserted to establish a pneumoperitoneum once again and then to perform ileoanal anastomosis. Surgery is completed by performing an ileostomy at the small incisional wound.

**Results:** Laparoscopic surgery was performed on 50 patients with UC. With previous methods, the intestine was mobilized under laparoscopic guidance from the cecum to the sigmoid colon. All UC patients are surgically treated laparoscopically today. The median time of surgery for the entire patient population was 364 min, and oral intake was initiated after an average of 13.2 days. After the introduction of the present method, the median time of surgery for the entire patient population was 306 min, and oral intake was initiated after an average of 5.3 days.

**Conclusions:** While this low-invasive method that eliminates even small incisional wounds has been performed on only five patients, it has been associated with less pain from the wound, earlier postoperative recovery, earlier postoperative oral intake, and easier management of the artificial anus in these patients.

### Abstract ID: 0053 Specific Field: Endoscopic Surgery

**Mode of pres.: Poster Exhibition only**  
**ISW 2011 Session PE 25**

#### An initial experience of single incision laparoscopic hepatectomy for hepatocellular carcinoma

T. Maeda, Y. Otsuka, M. Tsuchiya, Y. Kubota, J. Ishii, A. Tamura, H. Shimada, H. Kaneko

Department of Surgery, Toho University Omori Medical Center, Omori, Tokyo, Japan

**Introduction:** In our hospital, laparoscopic hepatectomy has been applied positively for the liver tumor lesion since 1993. Recently, single incision laparoscopic surgery has been widely adopted. Here we show our initial case of single incision laparoscopic hepatectomy (SILH).

**Material and Methods:** A 76 years old woman with a solitary 2 cm diameter located at segment 3 was referred to our hospital. The laboratory examinations were positive for hepatitis C viral markers and elevated alpha-fetoprotein level. The preoperative liver function was Child-Pugh class B. SILH was performed with a supine position and a one-inch umbilical incision was placed using the SILS™ port (Covidien Ltd., Norwalk, CT, USA) and the SILS™ port cannulae with three of 5 mm each were introduced through the access channels. After the pneumoperitoneum, the abdominal cavity was explored with a 5 mm semi-flexible laparoscope. Operative field was obtained using a forceps or a Roticulator™ Endo Grasp™ (Covidien Ltd.). The liver tumor was confirmed at the edge of segment 3 and pre-coagulation was performed by the needle type of Microtaze™ (Alfresa-Pharma Co, Inc., Osaka, Japan) on dissection plane under the low pneumoperitoneal pressure of 8 mm Hg. The liver was transected and sealed by the EnSeal<sup>R</sup> (Ethicon Endo-Surgery Inc., Cincinnati, USA) without mobilization of the liver. The resected liver was maneuvered into a specimen bag and removed through the umbilical incision.

**Results:** The surgical time was 183 min and blood loss was trivial. The postoperative pathology confirmed a 2.1 × 1.8 cm HCC with safe margins. The patient was able to start oral intake on the first postoperative days and the postoperative stay was 8 days.

**Conclusions:** We show a case of single incision laparoscopic hepatectomy to maintain the surgical view. Cross location of the forceps or Roticulator™ was useful. Hemostasis procedure was controllable by both Microtaze™ and EnSeal<sup>R</sup>. With careful operative indication, SILH is feasible for alternative method for the treatment with the hepatic tumor lesion. But it is necessary to improve the procedure and devices for the better surgical view.

### Abstract ID: 0054 Specific Field: Endoscopic Surgery

**Mode of pres.: Poster Exhibition only**  
**ISW 2011 Session PE 26**

#### Development of new needle holder for laparoscopic surgery

K. Maemura [1], H. Shinchi [1], Y. Mataka [1], H. Kurahara [1], T. Hayashi [1], T. Kuwahata [1], S. Takao [2], S. Natsugoe [1]

[1] Kagoshima University Department of Surgical Oncology and Digestive Surgery, Kagoshima, Japan, [2] Kagoshima University Frontier Science Research Center, Kagoshima, Japan

**Introduction:** The skillful technique is required for manual suturing and ligation under laparoscopic image. Therefore, various types of needle holders and forceps are devised for this procedure until now. Since we developed the original needle holder for laparoscopic surgery, we report the usefulness of this new device including the result of use test in live tissue.

**Material and Methods:** Previously, we designed and marketed a new style deep part needle holder for open surgery which has an ankyroid slot in a length of 1 cm at the side of the holder's nib. Even if we hold the surgical needle to a lengthwise direction with this, it has the mechanism where a body does not interfere in the curve part of a needle. Based on the efficacy of this device in use for conventional open surgery, the new needle holder for laparoscopic surgery with the same form of the tip was created. This needle holder makes to have linear retention to the axis of a surgical needle, and has the trait which can perform perpendicular impalement to a tissue. Fifteen surgeons, including six authorized specialists of Japan society for endoscopic surgery, evaluated the operability and the facility of new needle holder compared with conventional one in use of manual suturing and ligation under laparoscopic image in dry box and live tissue.

**Results:** It was revealed that ligation in the body using new needle holder became easier compared with using conventional type due to the ankyroid shape of a tip part which prevented thread escaping during ligation. Twelve surgeons (80%) evaluated that new needle holder was superior in ordinary suturing and ligation. Ligation procedure was estimated that eight surgeons (53%) admitted being very useful by using new needle holder. Fourteen surgeons (93%) evaluated that new needle holder made easier to perform suture in any direction by perpendicular impalement with the vertical retention of a needle.

**Conclusions:** We consider that our new developed needle holder improves operability and facility for laparoscopic manual suturing and ligation compared with the conventional type, and clinical application is recommended for advanced laparoscopic surgery.

#### Abstract ID: 0055 Specific Field: Endoscopic Surgery

Mode of pres.: Poster Exhibition only  
ISW 2011 Session PE 27

##### The feasibility of laparoscopic surgery for primary and recurrent Crohn's disease

Manabe, Ueki, Toma

Graduate School of Medical Sciences Kyushu University, Fukuoka, Japan

**Introduction:** Laparoscopic surgery has been reported to be a valuable approach for Crohn's disease (CD). However, surgical strategy would vary depending on the intestinal district and behavior affected by CD. The aim of this study was to assess the clinical outcome, safety and feasibility of laparoscopic surgery for CD.

**Material and Methods:** The study subjects consisted of 151 patients who underwent abdominal surgery for CD at our institution from 1996 to 2010. Our contraindications of laparoscopic surgery were fistula from the intestine to the skin, past history of multiple open surgeries, and expected severe and widespread adhesion. Forty-four patients in them, who underwent laparoscopic surgery (laparoscopy group [LG]), were compared with the other 107 patients who underwent conventional laparotomy (open group [OG]). The location affected by CD was clarified using Montreal classification (MC).

**Results:** The numbers of patients in MC were as follows: L1, 25; L2, 3; L3, 16; L4, 0; B1, 0; B2, 29; B3, 15 in LG and L1, 32; L2, 12; L3, 59; L4, 0; B1, 1; B2, 31; B3, 71 in OG. In LG, recurrent CD was 7 of 44, and there was no conversion to laparotomy. The median length of the wound was 5.15 cm in LG. The operating time tended to be longer

in LG than in OG. However, significant differences between two groups were blood loss found smaller in LG than in OG ( $P = 0.0019$ ), the passage of flatus found faster in LG ( $P = 0.0006$ ), and hospital stay of surgical department found shorter in LG ( $P = 0.0001$ ). The complication late was lower in LG (9.1%) than in OG (32.7%) ( $P = 0.0025$ ). Moreover, there was no surgical wound infection and post-operative ileus in LG. By location, in L1 and L3 region the operating time was no significantly different between LG and OG. In L1 region the passage of flatus and hospital stay after surgery were significantly shorter in LG than in OG. In L3 region the passage of flatus and hospital stay after surgery tended to be shorter in LG than in OG. By contrast, in L2 region the operating time was significantly longer in LG, and the passage of flatus and hospital stay after surgery were not significant between two groups. The group of laparoscopic surgery for recurrent CD showed the same tendency.

**Conclusions:** Laparoscopic surgery for CD is safe and feasible in CD, especially in L1 and L3 region. Laparoscopic surgery for recurrent CD also could be feasible.

#### Abstract ID: 0056 Specific Field: Endoscopic Surgery

Mode of pres.: Poster Exhibition only  
ISW 2011 Session PE 28

##### Surgical outcome of laparoscopic surgery for colon cancer in our hospital

S. Matoba, H. Kuroyanagi, T. Sawada, K. Tomizawa, Y. Hanaoka, S. Toda, J. Moriyama

Toranomon Hospital, Tokyo, Japan

**Introduction:** Laparoscopic assisted colectomy (LAC) for colon cancer was introduced to our hospital in 1997. We gradually gained experience and its total number of LAC counts over 2500 so far. Although LAC for early cancer is now accepted as a better method because of its less invasiveness, in the case of advanced cancer it is still controversial since the long term prognosis remains unclear. The aim of this study is to verify whether LAC for colon cancer is not inferior to conventional open method.

**Material and Methods:** We retrospectively collected data from cases whose postoperative observation time exceed at least 3 years. We had experienced 676 cases of LAC from 1997 to 2007. Operation time, intra- and post-operative complications and long term prognosis were reviewed.

**Results:** Average operation time was 197 min. Intra-operative accident was observed in 1.0% and the rate of conversion to laparotomy was 1.2%. As for complications, wound infection was seen in 2.1%, anastomotic leakage was 0.5%, and post-operative bowel obstruction was 6.2%. 5-year survival rate was as follows: 97.8% for Stage I, 93.7% for Stage II, 91.1% for Stage IIIa, and 78.6% for stage IIIb. (According to Japanese classification for colorectal cancer).

**Conclusions:** LAC is acceptable according to the results of short-term prognosis, operative time and intra-operative accident. There was no apparent aggravation tendency in long-term prognosis or cumulative survival rate.

#### Abstract ID: 0057 Specific Field: Endoscopic Surgery

Mode of pres.: Poster Exhibition only  
ISW 2011 Session PE 29

##### Intraoperative colonoscopy for anastomosis assessment in laparoscopic assisted left-sided colorectal surgery

C. Matsuda, K. Iwase, K. Tamagawa, K. Nishikawa, T. Takahashi, T. Deguchi, O. Nishiyama, T. Ryoji

Osaka General Medical Center, Osaka City, Japan

**Introduction:** The aim of our study was to evaluate the use of intraoperative colonoscopy in laparoscopic assisted left-sided colorectal resection for the assessment of anastomosis.

**Material and Methods:** All consecutive laparoscopic assisted left-sided colorectal resections performed at our department between October 2008 and January 2011 were included in this study. After colorectal resection and reanastomosis with double stapling technique, an intraoperative colonoscopy was performed to detect anastomosis risk.

**Results:** A total of 83 patients were enrolled in this study, and the anastomosis was checked via colonoscopy. Of the 83 patients, 33 (39.8%) underwent a laparoscopic assisted sigmoid resection, 24 (28.9%) a laparoscopic assisted high anterior resection, 26 (31.3%) a laparoscopic assisted low anterior resection. In this study, 3 (3.6%) anastomotic bleeding were detected and endoscopic clipping was performed during surgery. A total of 3 (3.6%) postoperative anastomotic bleeding occurred, but did not require hemostasis. 2 (2.4%) anastomotic leakages were detected and oversewn. A total of 4 (4.8%) anastomotic leakage occurred in the early postoperative period.

**Conclusions:** Intraoperative evaluation of anastomosis prevents early anastomotic insufficiency because intraoperative identification of bleedings and leaks allows for repair during surgery.

**Abstract ID: 0058** Specific Field: **Endoscopic Surgery**

**Mode of pres.: Poster Exhibition only**  
**ISW 2011 Session PE 30**

**Early experience of single-incision laparoscopic Nissen fundoplication for gastroesophageal reflux disease with mental retardation**

M. Mizuno, M. Kobayashi, G. Wakabayashi, A. Sasaki, K. Koeda, H. Nitta, K. Otsuka, Y. Kimura

Iwate Medical University, Morioka, Japan

**Introduction:** Mental retardation (MR) patients are frequently accompanied by gastroesophageal reflux disease (GERD). We have performed multiport laparoscopic Nissen fundoplication (MLNF) for these patients as a standard procedure since April 2001. Following these experiences, we have been performing single-incision laparoscopic Nissen fundoplication (SILNF) for GERD with MR as the first choice since October 2009. In this presentation we report the early experiences of SILNF for GERD with MR.

**Material and Methods:** A retrospective review of all patients who underwent SILNF from October 2009 was performed. Collected data included pneumoperitoneal time; intraoperative complications, such as conversion to MLNF or open laparotomy and blood loss; hospital stay; and postoperative complications such as surgical site infection, intestinal obstructions and recurrence of GERD. The data were compared with those for 10 cases underwent MLNF from 2008 as a control group.

**Results:** The patients performed SILNF were 7 males and 1 female with MR aged 1–50 years old. The body weight at operation was 5–31 kg. All cases were accompanied by severe body deformity. Diagnosis of GERD was made by an upper gastro-intestinal series and 24 h pH monitoring. One case was recurrence of GERD 2 years after conventional MLNF. Other 7 cases were not accompanied by any surgical history. There was only one conversion from SILNF to MLNF because of poor surgical view. Including this case, pneumoperitoneal time was 115–180 min and intraoperative blood loss was

1–15 ml. The entire procedure ended without any problems. Hospital stay after operation was under 8 days in all cases. No surgical site infections, postoperative intestinal obstructions, or recurrence of GERD were observed at 2–16 months after operation. There were no significant difference between the data of the SILNF group and those of the MLNF group.

**Conclusions:** In SILNF, there is no disadvantage compared with the MLNF in this study. In addition, the incidence of postoperative intestinal obstruction is very low in this procedure and a single-incision operation is superior especially in MR patients with severe body deformity and a small abdominal wall. We consider that SILNF can be a standard operation for GERD patients with MR in future.

**Abstract ID: 0059** Specific Field: **Endoscopic Surgery**

**Mode of pres.: Poster Exhibition only**  
**ISW 2011 Session PE 31**

**Malignant lymphoma of the ileum treated by laparoscope-assisted bowel resection**

A. Nagayama [1], N. Kobayashi [1], J. Saito [1], T. Nakamura [1], Y. Kitagawa [2]

[1] Department of Surgery, Inagi Municipal Hospital, Tokyo, Japan, [2] Department of Surgery, School of Medicine, Keio University, Tokyo, Japan

**Introduction:** Primary malignant lymphoma of the small intestine is uncommon. We herein present a case of the malignant lymphoma of the ileum which was treated by laparoscopically-assisted surgery. A 60-year-old male with lower abdominal pain and vomiting was admitted to our hospital. A standing abdominal X-ray showed niveau formation. Computed tomography demonstrated circumferential wall thickness in the terminal ileum. Laparoscopically-assisted surgery was performed under the diagnosis of tumor of the ileum. Under laparoscopic exploration, the tumor of the ileum was detected. Partial resection of the ileum and dissection of lymph nodes were performed extracorporeally. Histological findings demonstrated diffuse large atypical lymphocytes with vesicle-like chromatin and clear nucleolus. Immunologically, CD20 and CD79a were positive. These findings were compatible with those of diffuse large B-cell lymphoma. Para-intestinal lymph nodes were also involved. The postoperative course was uneventful. Neither gallium scintigraphy nor FDG-PET showed any scintillation. The patient was given R-CHOP therapy and is currently doing well with no sign of recurrence. In conclusion, we propose that laparoscopic surgery for malignant lymphoma of the small intestine is a feasible and promising therapeutic option, especially in a case demonstrating bowel obstruction, because this procedure is thought to be minimally invasive, allows quick postoperative recovery and shorten hospital stay could be expected.

**Abstract ID: 0060** Specific Field: **Endoscopic Surgery**

**Mode of pres.: Poster Exhibition only**  
**ISW 2011 Session PE 32**

**Long term prognosis of laparoscopic incisional and ventral hernia repair and the analysis of mesh shrinkage by computed tomography**

K. Nakano, H. Idani, S. Asami, K. Kumano, Y. Kurose, T. Iguchi, H. Kin, N. Takakura

Fukuyama City Hospital, Fukuyama, Japan

**Introduction:** Laparoscopic incisional and ventral hernia repair (LIVR) has been introduced expecting lower recurrence rate as well as lower morbidity compared to open repair. However, Long term prognosis of LIVR and the shrinkage rate of mesh have not been precisely evaluated. The aim of this study was to evaluate the outcome of the LIVR and to analyze the shrinkage rate of mesh after surgery.

**Material and Methods:** A total of 50 patients undergoing LIVR in our hospital between April 2002 and June 2010 were enrolled in this study. The initial port was inserted at the left upper abdomen by minilaparotomy followed by the insertion of two trocars at the left lateral abdomen. Composix E/X mesh ( $n = 20$ ), Dual mesh ( $n = 27$ ), C-QUR edge ( $n = 2$ ) or Ventralex ( $n = 1$ ) was fashioned so that the defect was overlapped in all dimensions by 3–5 cm. The mesh was fixed intracorporeally on the anterior abdomen by O nonabsorbable monofilament suture materials and tucks. The degree of mesh shrinkage after LIVR were evaluated on eighteen patients who were performed CT scanning after surgery. The outline of the mesh was traced under CT image and its area was calculated. Shrinkage rate was defined as the relative loss of surface as compared with the original size of the mesh (%).

**Results:** The patients consisted of 13 men and 37 women with a mean age of 71.6 years. Conversion to an open repair was required in two patients because of massive adhesion into the hernia sac. The mean operation time was  $108.5 \pm 41.9$  min (range, 44–208 min) and the mean duration of postoperative hospital stay was  $8.0 \pm 2.8$  days. There was no mortality and the morbidity was 12%. During a median follow up period of 48 months, recurrence was noted on one patient (2.0%). The mean period to CT scanning from surgery was  $50.6 \pm 29.2$  (range 8–77) months in Composix mesh cases ( $n = 5$ ), and  $12.7 \pm 11.2$  months (range 3–41) in Dual mesh cases ( $n = 13$ ). The shrinkage rate of Composix mesh and Dual mesh was  $30.3 \pm 13.6\%$  (range 15–46.4) and  $17.6 \pm 14.0\%$  (range 0–38.5%), respectively. In the patient with recurrence 21 months after the repair with Dual mesh, the shrinkage rate of the mesh was 28.8%.

**Conclusions:** LIVR has an excellent long term prognosis. Our results clearly supported that an overlap of 3–5 cm is necessary in the treatment of LIVR using mesh.

**Abstract ID: 0061** Specific Field: Endoscopic Surgery

**Mode of pres.: Poster Exhibition only**  
ISW 2011 Session PE 33

#### Conventional laparoscopic versus single incision laparoscopic appendectomy: a retrospective comparison

T. Obuchi [1], N. Kameyama [1], M. Tomita [1], H. Mitsuhashi [1], N. Matsumoto [1], Y. Katsuki [1], G. Wakabayashi [2], Y. Kitagawa [3]

[1] International Goodwill Hospital, Yokohama-city, Kanagawa, Japan, [2] Iwate Medical University, School of Medicine, Morioka-city, Iwate, Japan, [3] Keio university, School of medicine, Tokyo, Japan

**Introduction:** Laparoscopic surgery is thought to have diagnostic and therapeutic advantages over conventional surgery. This study aimed to compare conventional laparoscopic appendectomy (CA) with single incision laparoscopic appendectomy (SA) and to ascertain its therapeutic benefit.

**Material and Methods:** The clinical data of patients who underwent SA or CA at the International Goodwill Hospital in Yokohama between 1 January 2008 and 20 December 2010 was reviewed. Retrospectively collected data from 41 consecutive patients with acute appendicitis who received laparoscopic surgery were studied. Of these patients, 20 underwent CA and 21 underwent SA. Comparisons were based on operative time, blood loss, time to diet resumption,

ileus, wound infection, intra-abdominal abscess formation, postoperative hospital stay, and clinicopathologic characteristics.

**Results:** There were no statistical differences between the two groups regarding patient characteristics. The operating time seemed to be shorter for the SA patients than for the CA group (63.4 min vs. 74.8 min;  $P = 0.02$ ). The blood loss was less for the SA group than for the CA group, but the difference was not significant (16.5 ml vs. 24.6 ml;  $P = 0.4$ ). The time to diet resumption was significantly shorter in the SA group (1.0 d vs. 1.6 d;  $P < 0.05$ ). The complication rate did not reveal any significant difference between the two groups for any of the three complications, but there were more complications in the CA group (three cases of ileus, two cases of wound infection, and one case of intra-abdominal abscess formation). The SA group was associated with a shorter postoperative hospital stay (3.6 d vs. 7.4 d;  $P < 0.05$ ). Gangrenous appendicitis was diagnosed more often (10 cases or 50.0%) in the CA group than in the SA group (3 cases or 14.2%). No conversions to open laparotomy were required in either group.

**Conclusions:** Single incision laparoscopic appendectomy is a useful method of treating acute appendicitis. Its advantages lie in its minimal invasiveness, better cosmetic outcome, and lower rate of complications based on surgical expertise. It can be recommended as an adoptable method for the routine patient with appendicitis.

**Abstract ID: 0062** Specific Field: Endoscopic Surgery

**Mode of pres.: Poster Exhibition only**  
ISW 2011 Session PE 34

#### Index case report: application of single incision laparoscopic surgery for the pelvic disease

M. Ohtsuka, I. Takemasa, M. Mori

Graduated School of Medicine, Osaka University, Osaka prefecture Suita city Yamadaoka 2-2, Japan

**Introduction:** Transumbilical single incision laparoscopic surgery that provides supreme cosmesis with minimal invasiveness has been gradually indicated not only for the benign diseases such as gallstone or appendicitis but also for malignant diseases. It is possible to pursue aesthetics and concealment for the benign disease with ensuring safe procedure, while it should be careful for both safe and radical treatment to apply it for the malignant diseases. There were only a few reports for the pelvic disease with this procedure.

**Material and Methods:** We have performed laparoscopic resection of over 100 colorectal or pelvic diseases since June 2009. Two interesting cases were included in this series. First case was 20 year-old-woman with 4 cm growing retroperitoneal tumor located between the rectum and the sacrum. Second was 38 year-old-woman with hermaphrodite who desired vaginoplasty. They desire less invasive treatment and fewer scars in their abdomen after treatment.

**Results:** The tumor was resected laparoscopically via 2.0 cm umbilical incision without any other scar in the first case. Neovagina was constructed with sigmoid in Ruge procedure with transumbilical single incision laparoscopic surgery in the second case. The operative time and bleeding were 230–270 min and 20–30 g, respectively. These procedures were performed successfully with usual laparoscopic instruments only through the umbilical incision without any additional ports. There was no intra and postoperative complication. Surgical wounds within the umbilicus became almost invisible three months after the surgery. They are very satisfied with their excellent aesthetics and concealment obtained with this procedure.

**Conclusions:** While there are some technical limitations with the current devices, single incision laparoscopic surgery for the selected patients with the pelvic diseases was feasible. This procedure may be



promising treatment that provides a lot of advantages for the patients in the future.

### Abstract ID: 0063 Specific Field: Endoscopic Surgery

Mode of pres.: Poster Exhibition only  
ISW 2011 Session PE 35

#### Clinical experience of three-dimensional dome-shaped display system in laparoscopic surgery

K. Ohuchida, E. Nagai, S. Ieiri, T. Tsutsumi, M. Nakamura, M. Tomikawa, M. Tanaka, M. Hashizume

Kyushu University, Fukuoka, Japan

**Introduction:** The indications for laparoscopic intervention are constantly expanding, and laparoscopic surgery is currently the standard for an increasing number of operations. Advances in laparoscopic surgery have led to less postoperative pain, shorter hospital stays and an earlier return to work for many patients. However, laparoscopic surgeons require extended experience of cases to overcome the lack of depth perception on a two-dimensional (2D) display. Therefore, a three-dimensional (3D) display was reported to be useful over two decades ago. However, conventional 3D systems have not been widely used because of low quality of images or unacceptability of their use. Recently, we developed a novel 3D dome-shaped display (3DD) system, CyberDome, which provide depth perception with high resolution.

**Material and Methods:** We used 3DD system in 65 cases of laparoscopic surgery, including cholecystectomy, total gastrectomy, distal gastrectomy, hernioplasty, Nissen fundoplication, colectomy, and partial pancreatectomy. We also investigated the effect of 3DD on fatigue by subjective symptom tests.

**Results:** 3DD system significantly improved depth perception and laparoscopic performance. In gastric surgery, 3DD was useful for suturing such as holding a needle and management of threads. In pancreatic surgery, 3DD was useful for observation of pancreatic nodules and pancreaticojejunostomy (Duval operation). 3DD system was also useful for single port surgery including cholecystectomy and hernioplasty. According to the subjective symptom tests, 3DD system provided more depth perception than 2D high definition systems and seemed to reduce fatigues of laparoscopic surgeons.

**Conclusions:** The novel 3DD system, CyberDome, is a promising tool for providing depth perception to laparoscopic surgeons.

### Abstract ID: 0064 Specific Field: Endoscopic Surgery

Mode of pres.: Poster Exhibition only  
ISW 2011 Session PE 36

#### The impact of abdominal shape index of patients on laparoscopy-assisted distal gastrectomy for early gastric cancer

T. Ojima, M. Iwahashi, M. Nakamori, M. Nakamura, M. Katsuda, T. Iida, T. Tsuji, H. Yamaue

Second Department of Surgery, Wakayama Medical University, School of Medicine, Wakayama, Japan

**Introduction:** The aim of this study was to explore the effects of the abdominal shape index on gastric cancer patient short-term surgical outcomes of laparoscopy-assisted distal gastrectomy (LADG) in both genders.

**Material and Methods:** This retrospective study included 231 consecutive patients with early gastric cancer who underwent LADG with Billroth I anastomosis between January 1, 1998, and December 31, 2009. The abdominal shape index of patients was calculated using preoperative abdominal computed tomography (CT) scans and the Fat Scan software program.

**Results:** In male patients, the mean duration of surgery was longer in the patients with a body mass index (BMI) > 25 kg/m<sup>2</sup> group ( $P = .016$ ), in the anterior to posterior diameter (APD) > 200 mm group ( $P < .0001$ ), in the transverse diameter (TD) > 300 mm group ( $P = .030$ ), in the waist > 85 cm group ( $P = .039$ ), and in the visceral fat area (VFA) > 100 cm<sup>2</sup> group ( $P = .029$ ). The mean intraoperative blood loss was higher in the large TD group ( $P = .049$ ), in the high waist group ( $P = .006$ ), and in the large VFA group ( $P = .007$ ). In female patients, the correlations between these surgical outcomes and this abdominal shape index were not found. No significant relationships between each body shape index and the number of lymph nodes retrieved were found in either gender. Postoperative complications were not associated with the fat volume and abdominal shape index.

**Conclusions:** LADG is a useful technique in terms of accurate lymph node dissection and minimal postoperative complications in obese patients.

### Abstract ID: 0065 Specific Field: Endoscopic Surgery

Mode of pres.: Poster Exhibition only  
ISW 2011 Session PE 37

#### Development of bioabsorbable materials aimed at a closure following the NOTES transluminal procedure

K. Okada, M. Miyazawa, M. Aikawa

Saitama Medical University International Medical Center, Saitamaken Hidaka, Japan

**Introduction:** Aim: Endoscopic procedures represent an advance from conventional laparoscopic operations, with NOTES seeing clinical applications. However, in transluminal procedures, there can be difficulty with the closure of the luminal defect area, or even when closure is possible, there are issues with stenosis and deformation arising after closure. In cases where direct suturing of a defective area with the opening or resection of the stomach and large intestines is not possible, and if closure became easily possible using some kind of replacement materials, it is thought that applications of endoscopic surgery would increase. In this research we have introduced the bioabsorbable polymer (BAP) developed by us to defective areas in the stomach and small and large intestines, and examined the feasibility of its use for operational closure.

**Material and Methods:** Methods: (Examination of the stomach): the abdominal cavities of hybrid pigs were opened, and an 44 cm area of the anterior wall of the middle gastric body was excised, and a patch-like section of BAP where the same size was transplanted to close the defect. (Examination of the large intestine): A 2 cm defect in circumference was made in the sigmoid colon, and a BAP patch was transplanted endoscopically. The pigs were re-opened in all areas twenty weeks after the transplant, and the area was examined histologically and verified by cross examination.

**Results:** In all cases the pigs did not exhibit a loss of appetite and survived until euthanization. Twenty weeks after the patch was transplanted, there was tiny adherence to the surrounding material, infection, deformity in the stomach or large intestine and a gross examination revealed a normal regeneration of mucosa. The area that had been transplanted with the patch histologically did not appear to

have any polymer remaining and the mucosa, submucosa, and muscularis had all regenerated to the same extent as the native stomach and large intestine.

**Conclusions:** This BAP patch is thought to be able to be useful in NOTES operation closures. We would like to demonstrate the results of this research to date in a NOTES operational closure using the BAP patch.

**Abstract ID: 0066** Specific Field: **Endoscopic Surgery**

**Mode of pres.: Poster Exhibition only**  
**ISW 2011 Session PE 38**

**The study of validation of our criteria for laparoscopic colon resection**

K. Okita [1], T. Furuhashi [2], T. Nishidate [2], K. Hirata [2]

[1] First Department of Surgery, Sapporo Medical University, Sapporo, Japan, [2] Sapporo Medical University, Japan

**Introduction:** We adopt all colon cancer cases, except T4 and N3 in preoperative diagnosis, as indication of laparoscopic resection. The purpose of this presentation is to investigate the validity of our indicative criteria by laparoscopic completion rates and complication rates.

**Material and Methods:** We retrospectively investigated clinical data from 227 patients who underwent colon cancer resection from January 2006 to September 2010 at our institution. Laparoscopic completion rates according to clinicopathological factors (Stage, T factor, N factor, tumor location) and surgical outcomes (operation times, bleeding volume, number of dissected lymph nodes) and complication rates (leakage, ileus after operation, surgical wound infection) were analyzed.

**Results:** Laparoscopic completion rate was 85.9% (192/227) in all cases. Laparoscopic completion rates according to Stage were, Stage 0: 100%, Stage 1: 92.9%, Stage 2: 81.7%, Stage 3: 87.7%, Stage 4: 67.5%, according to T factor were, M: 100%, SM: 100%, MP: 92%, SS: 87.6%, SE: 69.2%, SI: 50%, according to N factor were, N0: 86.4%, N1: 86.6%, N2: 61.1%, according to tumor location were, V: 71.4%, C: 88.9%, A: 68.2%, T: 76%, D: 77.8%, S: 87.8%, RS: 83.3%. The mean operation time of the laparoscopic group was 238 min and that of the open group was 361 min. The mean bleeding volume of the laparoscopic group was 119 ml and that of the open group was 780 ml. The mean number of dissected lymph nodes of the laparoscopic group was 12.6 and that of the open group was 20.5. The leakage rate of the laparoscopic group was 0.5% and that of the open group was 5.7%. The surgical wound infection rate of the laparoscopic group was 3.6% and that of the open group was 5.7%. The ileus rate of the laparoscopic group was 2.1% and that of the open group was 5.7%.

**Conclusions:** It was thought that our criteria for laparoscopic colon resection was valid at least in short term outcome.

**Abstract ID: 0067** Specific Field: **Endoscopic Surgery**

**Mode of pres.: Poster Exhibition only**  
**ISW 2011 Session PE 39**

**Preservation of vagus nerve technique using left-sided approach in laparoscopy-assisted distal gastrectomy**

J. Sakurai, T. Fukunaga, S. Mikami, S. Kobayashi, T. Enomoto, A. Fukuoka, M. Katayama, T. Otsubo

St. Marianna University School of Medicine, Kawasaki, Kanagawa, Japan

**Introduction:** Laparoscopy-assisted gastrectomy is mainly performed for early or early-like advanced gastric cancer, and it is preferable to perform the vagus nerve preserving operation to maintain long-term quality of life.

**Material and Methods:** In preservation of vagus nerve, celiac branch and hepatic branch are generally preserved, but in conventional laparoscopic surgery, preservation of celiac branch has been so demanding. In 2005, we developed a new surgical procedure to easily preserve the celiac branch. With the use of left-sided approach for left gastropancreatic fold, a method we had developed, the celiac branch is identified at the root of the left gastric artery, and from there, celiac branch is followed and preserved toward its center.

**Results:** By using this method, preservation was conducted definitely in all of 304 patients undergoing vagus-nerve preserving gastrectomy.

**Conclusions:** Here, we describe our new technique.

**Abstract ID: 0068** Specific Field: **Endoscopic Surgery**

**Mode of pres.: Poster Exhibition only**  
**ISW 2011 Session PE 40**

**Technique of esophagojejunostomy using transoral placement of the pretilted anvil head after laparoscopic total gastrectomy for gastric cancer**

S. Sakuramoto, K. Yamashita, H. Mieno, M. Nemoto, T. Shibata, N. Katada, S. Kikuchi, M. Watanabe

Kitasato University, Sagami-hara, Japan

**Introduction:** During esophagojejunostomy using a circular stapler after laparoscopy-assisted total gastrectomy (LATG), placement of the anvil head via the transabdominal approach proved difficult. The authors report on a method modified for laparoscopy-assisted, esophagojejunostomy performed by placing the pretilted anvil head via the transoral approach.

**Material and Methods:** Between November 2007 and December 2010, esophagojejunostomy was performed using the transoral, pretilted anvil head in 66 patients after LATG. The anesthesiologist introduced the anvil while observing its passage through the pharynx. During the anastomosis, we kept the jejunum fixed in position with a silicone band Lig-A-Loops, thereby preventing the intestine from slipping off the shaft of the stapler.

**Results:** Esophagojejunal anastomosis using the transoral anvil head was achieved successfully in 65 patients; for 1 patient, passage of the anvil head was difficult owing to esophageal stenosis. No other complications, such as hypopharyngeal perforation and/or esophageal mucosal injury, occurred during passage. No postoperative complications occurred, except for 2 patient who developed anastomotic stenosis, in whom mild relief was achieved using a bougie.

**Conclusions:** Esophagojejunostomy using the transoral pretilted anvil head is a simple and safe technique.

**Abstract ID: 0069** Specific Field: **Endoscopic Surgery**

**Mode of pres.: Poster Exhibition only**  
**ISW 2011 Session PE 41**

**A comparison between fountain-pen inks and India ink for colonic tattooing agents in laparoscopic surgery**

H. Sasaki, Y. Tokunaga, T. Saito

Osaka North Japan Post Hospital, Osaka, Japan

**Introduction:** Laparoscopic surgery for colon neoplasm requires precise tumor localization. Preoperative colonoscopic tattooing has been reported as safe and efficient method. However, an appropriate agent has not yet been determined. We compared fountain-pen inks (blue ink, blue-black ink and black ink) with India ink in terms of effectiveness for localization of the lesion and visibility of the colon lumen when the agents overflowed.

**Material and Methods:** In 17 patients with colon cancer, colonoscopic tattooing was performed pre-operatively using sterile agents, and assessed the agents in terms of effectiveness for localization of the lesion and visibility of the colon lumen when the agents overflowed. Prepackaged sterile tattooing agents, including blue ink, blue-black ink, black ink, and India ink were injected into the submucosa after submucosal elevation with saline injection. Each tattooing agent was also dropped on the mucosa to assess the visibility of the colon lumen.

**Results:** Tattoos with blue-black ink and those with black ink were easily identified in the serosa during laparoscopic surgery. The colon lumen was easily visualized by water flush after dropping of the agents. Tattoos with blue ink could not be detected during laparoscopic surgery. Although tattoos with India ink were well identified in the serosa, the colon lumen was not clearly visualized by water flush after dropping of India ink.

**Conclusions:** Blue-black ink and black ink would be safe and efficient as colonic tattooing agents for laparoscopic surgery. Blue-black ink and black ink may be a well balanced alternative for India ink as tattooing agents.

**Abstract ID: 0070** Specific Field: **Endoscopic Surgery**

**Mode of pres.: Poster Exhibition only**  
**ISW 2011 Session PE 42**

**Laparoscopic total gastrectomy with D2 lymphadenectomy for gastric cancer and intracorporeal roux-en-Y reconstruction using oro-gastric anvil, current standard reconstruction method**

H. Satodate [1], H. Inoue [2], J. Tanaka [1], S. Kudo [1]

[1] Showa University Northern Yokohama Hospital, Yokohama, Japan, [2] Showa University Northern Yokohama Hospital, Japan

**Introduction:** Laparoscopic total gastrectomy (LTG) for gastric cancer is becoming popular procedure in Japan. In our institution, about 100 cases of gastric cancer surgery are performed every year and over the 85% of the patients are performed laparoscopic. One outstanding problem has been intracorporeal esophago-jejunal anastomosis after LTG, because it's technical difficulty. We introduced newly devised oro-gastric anvil (Orvil) for the anastomosis, and have experienced over 100 cases.

**Material and Methods:** A 12-mm trocar is placed through umbilical incision, and four additional trocars are placed. Our standard lymphadenectomy is modified D2 dissection. After thorough mobilization of the abdominal esophagus, it is taped and retracted. Then the esophagus is divided with stapler, and the tube attached to the Orvil is inserted per orally as a conventional naso-gastric tube. The tube is extracted from the esophageal stump. The tube is extracted outside from the trocar, and the anvil is loaded into the esophageal stump. Then the handpiece of EEA stapler is introduced from the umbilical port incision, after the EEA stapler passed and fixed into the opening of the jejunal limb. And the anastomosis is stapled also under the direct vision of the laparoscope.

**Results:** We have performed 128 cases of the LTG with this procedure, and no major complications have occurred. Mean operation time is 248 min.

**Conclusions:** This technique is technically feasible, can be performed easily and securely. This technique could become one of the standard methods for reconstruction after LTG, facilitating the acceptance of LTG as a surgical option for patients with gastric cancer.

**Abstract ID: 0071** Specific Field: **Endoscopic Surgery**

**Mode of pres.: Poster Exhibition only**  
**ISW 2011 Session PE 43**

**Reduced port surgery in sigmoid colon cancer**

Y. Sudo [1], T. Inoue [2]

[1] Kamihukuoka General Hospital, Japan, [2] Kamifukuoka General Hospital, Fujimino City, Japan

**Introduction:** Single incision laparoscopic surgery has recently been introduced to colectomy; however, the degree of difficulty is high due to restricted forceps mobility. Moreover, single incision laparoscopic surgery is expensive if a specialized port is used. We performed double incision laparoscopic colectomy on patients with cancer of the sigmoid colon and/or the neighboring intestines; this surgery was performed through 2 entry ports created by small incisions at the navel and 1 port in the right lower abdomen. Although, the procedure was performed as a preparatory step for the introduction of single port surgery we still use this surgical approach as it is easy and cost effective.

**Material and Methods:** A 12-mm port for the scope was inserted at the upper part of the navel, and a 5-mm port for the surgeon's left hand was inserted at the lower part of the navel. These upper and lower incisions were connected and used for the small laparotomy. Usually, a 5-mm port for the surgeon's right hand is inserted through an incision in the right lower abdomen. However, for high anterior resection, a 12-mm port is inserted so that a surgical stapler can be inserted through the port which is used to carry out the actual surgical procedure using the right hand and to place a drain at the end of the procedure.

**Results:** The operation took 95–160 min (Median, 140 min) to complete, indicating no prolongation of the surgery.

**Conclusions:** This method is not only cost effective but patients can also benefit from reduced port surgery. As far as the current case of cancer of the sigmoid colon and/or the neighboring intestine is concerned, the surgical procedure was not especially difficult, and can be carried out by a surgeon and a scopist, thus saving manpower.

**Abstract ID: 0072** Specific Field: **Endoscopic Surgery**

**Mode of pres.: Poster Exhibition only**  
**ISW 2011 Session PE 44**

**Conversion factors of laparoscopic colectomy for colorectal cancer**

H. Suzuki [1], M. Ogata [1], E. Uchida [2]

[1] Nippon Medical School Musashikosugi Hospital, Kanagawa, Japan, [2] Department of Surgery Nippon Medical School, Tokyo, Japan

**Introduction:** Laparoscopic colectomy is getting one of standard treatments not only for early colorectal cancer but for advanced one.

There still exist some incidences of conversion to open surgery in spite of those technical advancements. We investigate the conversion factors of laparoscopic colectomy for colorectal cancer in our experiences.

**Material and Methods:** 413 cases of laparoscopic colectomy including 206 cases of early period from 2000 to 2006 and 207 cases of late period from 2007 to 2009 carried out in our department for colorectal cancer were enrolled in this study retrospectively. Conversion factors of 44 cases which were converted to open surgery were analyzed.

**Results:** Total conversion rate was 10.7% (44 cases) including 14 females and 30 males, and gender rate were resembled to the whole cases.

There were 21 cases (10.2%) in early period and 23 cases (11.1%) in late period, which had no significant difference. Concerning of the location of the tumor, there were 26 rectal cancer and 18 colon cancer in conversion group, which indicates rectal cases had significantly high risk of conversion. Body Mass Index (BMI) was  $22.7 \pm 3.1$  in non-conversion group and  $22.5 \pm 2.7$  in early period and  $24.6 \pm 3.4$  in late period of conversion group. There was no significant difference in the diameter of the tumor in both groups. The reason of the conversion were classified as follows, A: Adhesion, B: Obesity, C: Organ injury, D: Bleeding, E: Difficulty in cutting of distal side of the rectum, F: Others. A: 6, B: 4, C: 2, D: 3, E: 1, F: 0 in the early period, and A: 6, B: 8, C: 1, D: 2, E: 1, F: 5 in the late period, which indicates adhesion were dominant in the early period and obesity and difficulty in cutting of distal side of the rectum were main reasons in the late period.

**Conclusions:** Total conversion rate of 10.7% was not necessarily low, and there was no improvement in the late period in spite of technical development. The reason of conversion was altered because of the extension of the indication of laparoscopic colectomy. There were not only technical reasons such as organ injury and bleeding but patient factors such as adhesion and obesity in conversion to open surgery, obesity and rectal tumor were the risk factors of conversion.

#### Abstract ID: 0073 Specific Field: Endoscopic Surgery

**Mode of pres.: Poster Exhibition only**  
**ISW 2011 Session PE 45**

##### Laparoscopically assisted resection of small bowel polyps in a patient with Peutz-Jeghers syndrome

H. Tada, Y. Kuriu, Y. Murayama, M. Nakanishi, Y. Kokuba, E. Otsuji

Division of Digestive Surgery, Department of Surgery, Kyoto Prefectural University of Medicine, Kyoto, Japan

**Introduction:** Peutz-Jeghers syndrome (PJS) is autosomal dominant disorder characterized by the association of gastrointestinal polyposis and mucocutaneous pigmentation. The polyps can occur anywhere in the gastrointestinal tract and result in chronic bleeding with secondary anemia and cause recurrent obstruction and interruption requiring repeated laparotomy and bowel resection. Endoscopic and Laparoscopic treatments are regarded as a standard therapy for PJS polyps. There are many reports of endoscopic treatments for PJS polyps, however the reports of the laparoscopic treatment are not many. In this report we could resect the PJS polyp measuring 50 mm in size by laparoscopic approach.

**Material and Methods:** A 48-year-old woman had an abdominal pain and was hospitalized with a diagnosis of enteritis. She developed interruption of the ileocecal area during the course of hospitalization and recovered by spontaneous resolution. She was examined carefully because she had undergone the partial resection of the ileum under the

diagnosis of Peutz-Jeghers syndrome at her age of 14. The enterocolonoscopy and enteroscopy revealed a 50 mm polyp in upper jejunum and 5 mm polyp at the terminal ileum.

**Results:** The endoscopic resection could not be available, so we performed laparoscopic resection of the ileum for the lesion. In the operation, we found a polyp localized at the terminal ileum measuring 5 mm in size. We judged the polyp as the responsible lesion of interruption and we added the resection. The pathological report was compatible with that of Peutz-Jeghers syndrome.

**Conclusions:** This time we reported a case of laparoscopically assisted resection of small bowel polyp measuring 50 mm in size in a patient with Peutz-Jeghers syndrome.

#### Abstract ID: 0074 Specific Field: Endoscopic Surgery

**Mode of pres.: Poster Exhibition only**  
**ISW 2011 Session PE 46**

##### Re-consideration of needlescopic surgery

N. Tagaya, K. Kubota

Dokkyo Medical University, Tochigi, Japan

**Introduction:** Single port surgery (SPS) gradually penetrated into the surgical field. However, we propose the re-evaluation of needlescopic surgery (NS) to improve an esthetic result and postoperative quality of life of the patients and reduce costs and stress of surgeons, and evaluated the results of needlescopic surgeries in our department.

**Material and Methods:** We experienced NS in 197 patients between May 1998 and November 2010. Their surgical procedures were cholecystectomy in 149 patients, bullectomy in 11, thyroidectomy and axillary lymph node dissection in each 10, unroofing of cyst in 4, splenectomy, appendectomy and abdominal wall hernia repair in each 3, adrenalectomy in each 2, and lysis of adhesion and resection of gastric tumor in each one, respectively. Under general anesthesia, one 12-mm and 2 or 3 of 2- or 3-mm ports were introduced into the operative field. The specimen was retrieved from the 12-mm wound using a plastic bag. **Results:** The procedure was successfully completed in all patients without the conversion to open procedure. Four (2.7%) of 149 cholecystectomies required the exchange of 2 or 3-mm instruments. There were no perioperative complications. Technical points were no direct organ mobilization to avoid organ injuries, the rotation of operating table and the utilization of organ gravity to create the better operative field, the minimum use of needlescope to perform safe maneuver and the improvement of bi-hand technique.

**Conclusions:** Needlescopic Surgery is a safe and feasible procedure to achieve a minimal invasive surgery. We should have a better option of needlescopic surgery.

#### Abstract ID: 0075 Specific Field: Endoscopic Surgery

**Mode of pres.: Poster Exhibition only**  
**ISW 2011 Session PE 47**

##### Single incision transabdominal preperitoneal repair for inguinal hernia

S. Takayama, M. Sakamoto, H. Takeyama

Nagoya City University, Nagoya, Japan

**Introduction:** The laparoscopic cholecystectomy using a single incision at the umbilicus has gradually spread in this decade. This



method offers the potential advantages of reduced postoperative pain and a lower incidence of port-site complications. Moreover, this surgery rarely leaves a scar is aimed at improving post-surgical cosmetic outcome. In these days it is increasingly being used not only for laparoscopic cholecystectomy but also for other surgeries such as appendectomy, prostatectomy, and herniorrhaphy. Here we introduce single incision transabdominal preperitoneal (TAPP) approach with new methodology.

**Material and Methods:** Under general anesthesia, firstly we inserted a Covidien SILS port via an umbilical incision, through which three trocars of sizes 5, 5, and 12 mm were inserted. The peritoneum was then opened using flexible scissors and electrocautery. The preperitoneal space was then dissected and the 3-D mesh was placed. Finally, the peritoneum was closed using SILS Stitch Articulating Suturing Device or flexible needle holder with barbed suture.

**Results:** The mean operative time was about 30 min longer than conventional TAPP. And the all patients were discharged without any complications.

**Conclusions:** The case of laparoscopic single incisional herniorrhaphy, most reports focus on the total extraperitoneal (TEP) approach. This is because in the TAPP approach, the peritoneal closure is technically demanding. Thus, addressing this problem, we used SILS Stitch or flexible needle holder with barbed suture. The challenge of this surgery still lies in manipulating instruments and in highly demand skill within the limitations of the closely inserted ports. However, regular use of this method and our experience would make it more practicable.

**Abstract ID: 0076** Specific Field: **Endoscopic Surgery**

**Mode of pres.: Poster Exhibition only**  
**ISW 2011 Session PE 48**

**Long-term clinical outcomes after laparoscopic distal gastrectomy for pT1 and pT2 gastric cancer**

M. Takemura [1], Y. Fujiwara [2], K. Morimura [2], T. Hori [1]

[1] Hyogo College of Medicine, Nishinomiya, Japan, [2] Osaka City Juso Hospital, Osaka, Japan

**Introduction:** More than decade has passed from introducing laparoscopic distal gastrectomy (LDG) for gastric cancer, and becoming popular for management of early gastric cancer. But this technique is not widely accepted because it has not been evaluated from the point of oncologic outcomes. Although short-term outcomes after LDG is proven, but reports of long-term outcomes are still rare. We have introduced LDG for gastric cancer from 1998. In this report, we evaluated the long-term outcomes of the patients after LDG for pT1 or pT2 gastric cancer.

**Material and Methods:** This study comprised 295 patients who have pT1 or pT2 gastric cancer after LDG during the period January 2005 through December 2009. The surgery related factors, postoperative complications, type of recurrence and survival rate of these patients were examined.

**Results:** There were 181 men and 114 women, and average age was 63.6 years. The average duration of operation was 232.7 min and amount of blood loss was 153.7 g. Histologically, 132 patients had pT1(M) cancer, 105 had pT1(SM), 37 had pT2(MP), and 21 had pT2(SS). Lymph node metastasis is diagnosed in 38 patients. The most frequent postoperative complications was pancreatic injury ( $n = 15$ , 5%). The intraabdominal abscess occurred in 10 patients

(3.4%), and anastomotic leakage only in 3 (1%). The cause of death included recurrent disease in 9 patients, another primary cancer in 9, pneumonia in 1, and cardiovascular disease in 1. The type of recurrence included hematogenous metastasis in 5 patients, lymph node recurrence in 3, and peritoneal disseminations in 1. In 7 of 9 patients with cancer recurrence, lymph node metastasis was detected histologically. The cancer recurrence was diagnosed less than 2 years in most recurrent cases. The 1-years and 5- year survival rate were 99.6 and 94.6%, respectively. The pathological staging and lymph node metastasis were significant factors affected for survival.

**Conclusions:** Long-term oncological outcomes of the patients after LDG with regional lymph node dissection for pT1 and pT2 gastric cancer are acceptable. The careful attention for the recurrent disease during 2 years from operation in the patients with lymph node metastasis was required.

**Abstract ID: 0077** Specific Field: **Endoscopic Surgery**

**Mode of pres.: Poster Exhibition only**  
**ISW 2011 Session PE 49**

**Endoscopic submucosal dissection for treatment of early stage oropharyngeal and hypopharyngeal carcinomas**

H. Takeuchi [1], N. Abe [1], O. Yanagida [1], T. Mori [1], M. Sugiyama [1], Y. Atomi [1], H. Nagafuji [2], N. Kohno [2]

[1] Department of Surgery, Kyorin University School of Medicine, Tokyo, Japan, [2] Department of Otorhinolaryngology, Kyorin University School of Medicine, Tokyo, Japan

**Introduction:** Early detection of oropharyngeal and hypopharyngeal carcinomas are increasing with some recent advances in endoscopic technology. Patients with such early lesions can be treated with locoregional control, however, conventional local resection method in these areas are not attractive in view points of oncology. Recent developed ESD (endoscopic submucosal dissection) is a powerful technique of en-bloc resection of neoplasms in gastrointestinal tract. ESD may be a good alternative to conventional resection method in treating early oropharyngeal and hypopharyngeal carcinomas. We herein present cases of early oropharyngeal and hypopharyngeal carcinomas who successfully carried out ESD.

**Material and Methods:** We carried out ESD in 3 patients with early pharyngeal carcinomas (1, oropharyngeal carcinoma; 2, hypopharyngeal carcinomas) between October 2009 and August 2010. Mean age was 74 years (M:F = 2:1). Short-term outcomes (en-bloc resection rate, complications, operative time, length of postoperative stay, recurrence after ESD) were retrospectively reviewed. All procedures were performed under general anesthesia with transnasal endobronchial intubation.

**Results:** En-block resection rate was 100%. Histological examination of resected specimens revealed that 2 patients had carcinoma in situ and 1 patient had tumor invasion of the subepithelium. Lateral surgical margins in 1 patient was difficult to evaluate for burn effect. Mean operative time was 118 min (range; 77–198). Complications were not observed. The mean postoperative hospital stay after the ESD was 11 days (range ;6–18). One case had underwent a tracheostomy immediately after ESD. There was no local recurrence or distant metastasis in any of the patients during the follow-up period (1–11 months).

**Conclusions:** ESD is safe and useful for treating early oropharyngeal and hypopharyngeal carcinomas.

**Abstract ID: 0078** Specific Field: **Endoscopic Surgery****Mode of pres.: Poster Exhibition only**  
**ISW 2011 Session PE 50****Successful laparoscopic resection of a sacrococcygeal teratoma in an adult**A. Tsutsui, T. Nakamura, M. Watanabe  
Kitasato University, Sagamihara, Japan**Introduction:** Sacrococcygeal teratoma is a relatively rare congenital retroperitoneal tumor in adults. Teratomas are associated with an age-related increase in the risk of malignancy. The standard treatment is a complete tumor resection. This report describes the successful laparoscopic resection of a sacrococcygeal teratoma.**Material and Methods:** The patient was a 27-year-old woman with a well-demarcated cystic mass, 6 cm in diameter, in the retroperitoneum overlying the anterior surface of the sacrum. A retroperitoneal sacral tumor was diagnosed, and laparoscopic surgery was performed. An examination of the intrapelvic region showed a mass on the anterior aspect of the sacrum, with no invasion of the sacrum or the ureter or the hypogastric plexus overlying the sacrum. The laparoscope provided a good view of the pelvic cavity, allowing for the mass to be safely resected without damaging the cystic wall or coming into contact with the surrounding tissue. A histopathological examination showed a mature teratoma. The patient recovered uneventfully after surgery and was discharged from hospital on the 7th hospital day. The patient remains relapse-free at 3 year 6 months after surgery.**Results:** Laparoscopic surgery allows for teratomas arising on the anterior surface of the sacrum to be safely resected by providing a good view of the narrow pelvic cavity. Laparoscopic surgery is a useful, well-tolerated, minimally invasive technique with excellent aesthetic outcomes.**Conclusions:** This report describes a case of sacrococcygeal teratoma that was successfully treated by a laparoscopic resection.**Abstract ID: 0079** Specific Field: **Endoscopic Surgery****Mode of pres.: Poster Exhibition only**  
**ISW 2011 Session PE 51****Image-guided laparoscopic surgery and its environments in an open MRI operating theatre**

N. Tsutsumi [1], M. Tomikawa [1], M. Uemura [2], T. Akahoshi [2], S. Ieiri [1], J. Hong [2], Y. Maehara [2], M. Hashizume [1]

[1] Kyushu University Hospital, Fukuoka, Japan, [2] Kyushu University, Fukuoka, Japan

**Introduction:** The recent development of open MRI has provided an opportunity for the next stage of image-guided surgical and interventional procedures. The purpose of this study was to evaluate the feasibility of laparoscopic surgery under the pneumoperitoneum with the system of an open MRI operating theatre.**Material and Methods:** Six patients underwent laparoscopic surgery with the real-time augmented reality navigation system that we have previously developed in a horizontal-type 0.4-T open MRI operating theatre. An initial MRI scanning was performed with the patient in the MR gantry to image the intraperitoneal structures with pneumoperitoneum. The registration between the patient and the MR images was done using the build-in Polaris optical tracking system. The acquired MR images and the patient coordinates were integrated using an

image analysis workstation (Virtual Place Raijin; Aze Ltd., Tokyo, Japan).

**Results:** Laparoscopic cholecystectomy was performed for 3 patients, and laparoscopic ventral hernia repair for 3 patients. Although we used many MR-incompatible surgical instruments, all these operations were completed safely and no intraoperative complications or other difficulties occurred. During the operations, the laparoscopic monitor clearly showed the augmented reality models of the intraperitoneal structures such as the common bile ducts, the urinary bladder, or the proper positions of the prosthesis. The mean time required to complete the operations was 208.8 min that tended to get longer depending on an operative complexity and times of acquisition of MR images. The postoperative outcomes of all patients were excellent. According to the type of laparoscopic surgery we needed to design the layouts of the positions of surgeons, nurses, anesthesiologists, the operating table, the respirator, the monitors, the gas cylinders, the laparoscopic instruments, and the navigation devices not to be affected by the magnetic field of the open MRI.**Conclusions:** Laparoscopic surgery with our developed real-time augmented reality navigation system in the open MRI operating theatre is a feasible option.**Abstract ID: 0080** Specific Field: **Endoscopic Surgery****Mode of pres.: Poster Exhibition only**  
**ISW 2011 Session PE 52****Contralateral occurrence after totally extraperitoneal hernia repair (TEP) for inguinal hernia and safety of repeat TEP**

H. Uchida [1], T. Matsumoto [1], Y. Endo [1], S. Hiroshige [1], E. Oki [1], T. Kusumoto [1], Y. Muto [1], S. Kitano [2]

[1] National Hospital Organization Beppu Medical Center, Beppu, Japan, [2] Oita University Faculty of Medicine, Yufu, Japan

**Introduction:** Laparoscopic totally extraperitoneal repair (TEP) has been reported to have a low recurrence rate and relatively little postoperative pain. However, there have been few studies reported regarding contralateral occurrence after TEP. And it is unknown whether occult hernias have some significances in clinical settings although a high incidence of occult contralateral hernias during laparoscopic transabdominal preperitoneal repair has been reported in the literature. The aim of this study was to evaluate the incidence of contralateral occurrence after TEP for unilateral inguinal hernia and the efficacy of repeat TEP for contralateral occurrence after primary TEP.**Material and Methods:** We retrospectively reviewed the medical charts of 215 patients undergoing TEP performed between April 2003 and May 2009. No patients had undergone contralateral exploration during TEP for unilateral inguinal hernias. The follow-up period was between 1 and 72 months (median 35.9 months).**Results:** 187 of 215 patients underwent primary TEP for inguinal hernia. 157 of those had unilateral inguinal hernia, and other 30 had bilateral. Five (3.2%) of those 157 patients developed a hernia on the contralateral side after primary TEP. Three patients had contralateral occurrence within 6 months after the primary TEP, while in 2 over a year passed before contralateral occurrence. 28 of 215 patients underwent repeat TEP for contralateral-side hernia occurring after primary TEP. Mean TEP operation time for the contralateral occurrence was 73.3 min, and there was little intraoperative blood loss. Three patients were converted to an anterior approach because of insufficient surgical field due to injury of the peritoneum. There were no difficulties during surgery. The postoperative course in all patients was uneventful.**Conclusions:** The present study suggests that the incidence of contralateral occurrence after TEP is low. TEP is a valuable procedure

with a low contralateral occurrence rate, and repeated TEP for contralateral occurrence is feasible and safe. Repeat TEP can be recommended in patients with new occurrence of contralateral inguinal hernia after primary TEP.

### Abstract ID: 0081 Specific Field: Endoscopic Surgery

Mode of pres.: Poster Exhibition only  
ISW 2011 Session PE 53

#### Preoperative segmentation of the liver, based on 3D CT images, facilitates laparoscopic anatomic hepatic resection for small nodular hepatocellular carcinoma in patients with cirrhosis

S. Ueno [1], M. Sakoda [1], S. Iino [1], H. Kurahara [1], M. Yukou [1], K. Maemura [1], H. Shinchi [2], S. Natsugoe [1]

[1] Kagoshima University, Department of Surgical Oncology and Digestive Surgery, Kagoshima, Japan, [2] Kagoshima University, Department of Insurance Health, Kagoshima, Japan

**Introduction:** It is important to minimize surgical invasiveness in the therapy of patients with hepatocellular carcinoma (HCC) complicated with cirrhosis. Laparoscopic hepatectomy is feasible for such patients; however, most procedures undertaken at the present time are non-anatomic partial resection or limited resection, except for left hepatectomy and bisegmentectomy 2 and 3. Because anatomic hepatic resection for small HCC yielded more favorable results than non-anatomic resection, we conducted laparoscopic anatomic hepatic resection as image-navigated surgery by referring to portal 3D images.

**Material and Methods:** Detailed descriptions of laparoscopic anatomic resection, such as segmentectomy and subsegmentectomy, are presented. Preoperative 3D images clarified the anatomical relationships between HCC and its portal territory and enabled determination of the transection line. Laparoscopic anatomic resection was completed with mini-laparotomy or -thoracotomy with equal success to the conventional procedure under an open approach.

**Results:** Ten patients with primary HCC with cirrhosis underwent the above procedure between January 2008 and November 2010. There were 5 male and 5 female patients, with a median age of 72.2 (65–80) years. All procedures were successful, with no conversions to open surgery required. The median operation time was 265 min (range:

222–310 min), and the median estimated blood loss was 426 ml (range 50–620 ml). There was no surgical mortality and major morbidity.

**Conclusions:** These procedures contributed reduced invasiveness, even for elderly patients with cirrhosis: low blood loss and no post-operative complication. Laparoscopic anatomic hepatic resection based on navigation of the portal 3D images might be useful not only to facilitate minimally invasive surgery but also to improve the therapeutic efficacy.

### Abstract ID: 0082 Specific Field: Endoscopic Surgery

Mode of pres.: Poster Exhibition only  
ISW 2011 Session PE 54

#### Laparoscopic distal pancreatectomy with spleen preservation for pediatric patient

M. Urao [1], N. Fujiwara [1], Y. Kakita [1], T. Miyano [1], K. Kojima [2], M. Fujisawa [2], T. Kitabatake [2], M. Machida [2]

[1] Juntendo Nerima Hospital, Dep. Pediatric Surgery, Tokyo, Japan, [2] Juntendo Nerima Hospital, Dep General Surgery, Tokyo, Japan

**Introduction:** Laparoscopic distal pancreatectomy is a challenging procedure that has been reported in the last decade. We performed laparoscopic distal pancreatectomy with spleen preservation on a girl with solid pseudopapillary tumor (SPT) at pancreas body.

**Material and Methods:** Case. A 13-year-old girl was found to have a heterogenous 6 × 5 cm mass in her pancreas body after blunt abdominal trauma examination. With radiological assessment, we suspected SPT by which splenic artery and vein were obstructed.

**Results:** With right semi-lateral positioning, three 5 mm trocars were positioned, and 12 mm trocar was placed at her left lower quadrant. The gastrosolic ligament was opened by a vessel-sealing electro-surgical device and the stomach was retracted superiorly. Although the splenic artery and vein could not be mobilized from the pancreas, there were many collateral veins draining the splenic blood flow. Laparoscopic ultrasound showed good blood flow in the spleen during the splenic artery occlusion test. We expected that spleen could be preserved even after dissection of the splenic artery and vein. Endo-GIA Universal with Duet TRS (tissue reinforce system) was used for dissection of pancreas body including the splenic artery and vein. The color of the spleen did not change after dissection of the splenic artery. The specimen was removed through left lower quadrant trocar wound. Drainage tube was placed prior to closure. Blood loss was less than 40 g. Patients were able to tolerate to regular diet 5 days after operation. None of complications were seen with minimal wound pain post-operatively.

**Conclusions:** With using new device for laparoscopic surgery, the operation was able to perform without any difficulties. Laparoscopic pancreatic resection in children is feasible and safe with a fast post-operative recovery.

### Abstract ID: 0083 Specific Field: Endoscopic Surgery

Mode of pres.: Poster Exhibition only  
ISW 2011 Session PE 55

#### Did the development of surgical technology create the happiness of human being?

H. Usuki, Y. Suzuki, K. Okano, M. Hagiike, T. Takama, S. Yachida, K. Kakinoki, M. Fujiwara

Kagawa University, Kita, Japan

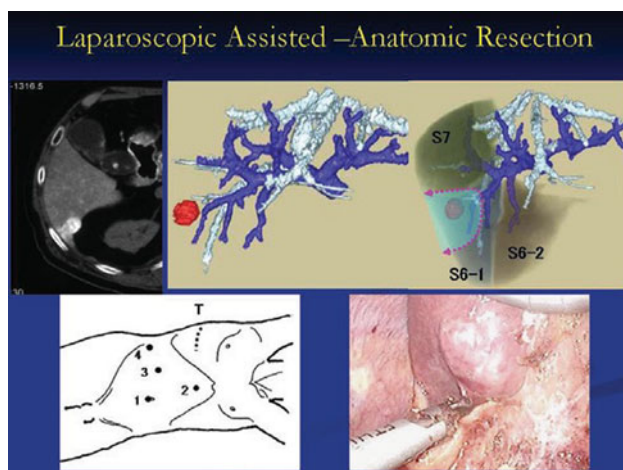


Figure: Laparoscopic assisted-anatomic resection

**Introduction:** The development of surgical technology created much happiness to the human being in the last 20 years. The development of the endoscopic surgery decreased the postoperative wound pain and increased the cosmetic satisfaction. However, it is doubtful whether the patients, who could not stand by the open surgery, became to be able to undergo the endoscopic surgery. On the other hand the weight of the waste after surgery has increased in the last 30 years. There had been very little waste, because, there had been almost no disposable material 30 years ago.

**Material and Methods:** The medical waste was only the gauzes containing much blood. The weight of them was 234 g for colon cancer treatment. The automatic suturing devices were created and the many convenient and disposable devices were developed. Many reusable devices were changed to disposable devices for the countermeasure for infection. The weight of the disposable devices using in open colectomy was 555 g. The weight of disposable surgical drapes and gowns was 1957 g. The weight of the medical waste increased to 2746 g. Then, the endoscopic surgeries came to be executed widely in 1990s. Many doctors requested more convenient devices and many companies created many useful devices to respond the surgeon's demand and for their commercialism. The number of endoscopic surgery became twice every ten years in the past. And the number of the disposable devices used for the surgeries also increased dramatically.

**Results:** The weight of the disposable devices using in laparoscopic colectomy is 2615 g. The weight of the medical waste increased to 4806 g. The weight of CO<sub>2</sub> emission for colon cancer treatment was 0.18 kg per one patient 30 years ago. It has increased to 11.01 kg for the open colectomy and 24.31 kg for the laparoscopic colectomy. The weight of CO<sub>2</sub> emission increased 665 t per year in Japan. If all colon cancer patients in the world received the benefit of laparoscopic surgery, the weight of CO<sub>2</sub> emission increased 62,215 t per year only for the colon cancer treatment.

**Conclusions:** Therefore, it must be struck a balance between ecology and endoscopic surgery for many people can get the benefit of this minimum invasive surgery over a long period of time. And it is hoped that many safe and convenient reusable devices are developed for such purpose.

**Abstract ID: 0084** Specific Field: **Endoscopic Surgery**

**Mode of pres.: Poster Exhibition only**  
ISW 2011 Session PE 56

#### **Retrospective study of laparoscopic omental patch repair for perforated gastroduodenal peptic ulcer**

H. Watanabe, H. Tonouchi, T. Ikeda, T. Yokoe, E. Ojima, N. Konishi, H. Ito

Mie Prefectural General Medical Center, Yokkaichi, Japan

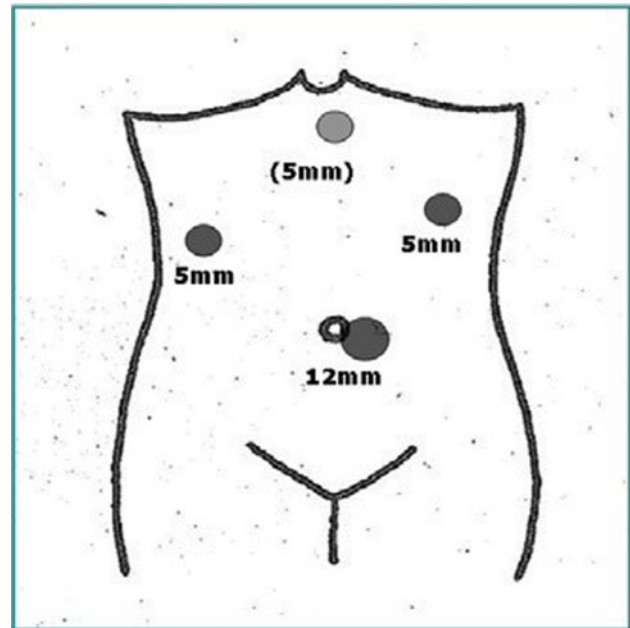
**Introduction:** Perforated gastroduodenal peptic ulcer is a common abdominal disease that is treated by surgery. Laparoscopic surgery has become popular during last decade, mainly because it is associated with fewer surgical stress than the conventional open approach. 5 years ago, we have changed open surgery to laparoscopic surgery for abdominal surgical emergencies. However, the advantages of laparoscopic surgery compare with open surgery for perforated gastroduodenal ulcer are not obviously known. The object of this report is to compare the results of laparoscopic surgery with those of open surgery for the patients with perforated gastroduodenal peptic ulcer.

**Material and Methods:** We reviewed 12 cases of laparoscopic surgery for perforated gastroduodenal peptic ulcer patients from April

2005 to December 2010 in our institute. We also reviewed 13 cases of open surgery patients before induction of laparoscopic surgery from April 2003 to March 2005.

**Results:** Operating time in the laparoscopic surgery group was significantly longer than the open surgery group (107.5 min versus 60.2  $P = 0.0035$ ). Hospital stay in the laparoscopic surgery group was significantly shorter than the open surgery group (11.3 versus 15.3  $P = 0.0423$ ). Complications were equally distributed.

**Conclusions:** Laparoscopic surgery for perforated gastroduodenal peptic ulcer can be considered as safe procedure as open surgery.



**Figure:** Surgical procedure of laparoscopic omental patch repair for perforated gastroduodenal peptic ulcer

**Abstract ID: 0085** Specific Field: **Endoscopic Surgery**

**Mode of pres.: Poster Exhibition only**  
ISW 2011 Session PE 57

#### **Comparison of short-term outcomes between reconstruction procedures in laparoscopic total gastrectomy**

Y. Watanabe, K. Sato, Y. Kojima, M. Morimoto, Y. Matsuno, S. Kikuchi, J. Kuwabara, K. Kameoka

Ehime University, Graduate School of medicine, Toon-shi, Japan

**Introduction:** Laparoscopy-assisted total gastrectomy (LATG) is not a commonly performed procedure due to the surgical difficulty associated with esophago-jejunal anastomosis. Although two stapling devices including circular and linear ones are available for LATG, there have not been discussed about a selection of stapling device by the point of view based on the residual esophageal length. In this study, we compared the short-term outcomes of LATG using both stapling devices.

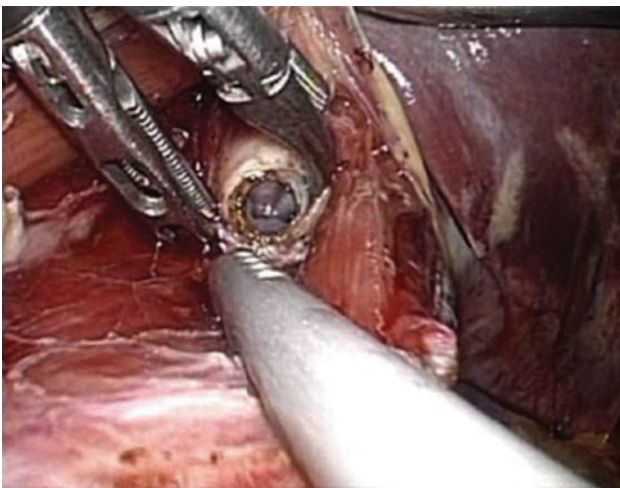
**Material and Methods:** 16 cases underwent LATG since November 2006 until November 2010. Circular and linear stapling devices were used in 11 and 5 cases, respectively. A selection of stapling device was selected according to the residual esophageal length during operation.



In cases with short residual abdominal esophagus, circular stapler was used by Orvil TM device (the initial two patients by direct insertion via the esophageal stump). In cases with extremely short one, anastomosis was performed by circular stapler with end-to-end fashion (triple stapling technique). In other cases with relatively long residual one, linear stapling device was used by a functional end-to-end fashion.

**Results:** The procedure using circular stapler was complicated in a narrow operating field. However, the procedure seemed to be essential for cases with the short residual esophagus. On the other hand, a side-to-side anastomosis by linear stapler is simple and easy in cases with the relatively long residual esophagus. In fact, an operation time using a linear stapling device was significantly short with an average of 334 min than that with a circular device (387 min). Initial two patients (1 case in each procedure) had a failure of the suture but since then 14 patients did not have it. No differences were observed in an oral intake, weight loss, blood loss, hospital stay between two procedures. However, a longer skin incision was necessary to introduce a circular stapling device than linear one which lead to a postoperative wound pain.

**Conclusions:** Linear stapling devices seems to offer us a short operation time and less skin incision and better operation view. However, a circular stapling device is essential for those cases with the short residual esophagus. Thus we should acquire both procedures.



**Figure:** Introducing anvil head transorally

#### Abstract ID: 0086 Specific Field: Endoscopic Surgery

**Mode of pres.: Poster Exhibition only**  
ISW 2011 Session PE 58

#### Laparoscopic endoscopic cooperative surgery for gastric submucosal tumor

Y. Watanabe

KKR Tonan Hospital, Sapporo, Japan

**Introduction:** Recently advances in laparoscopic surgery have resulted in widespread acceptance of gastric submucosal tumor including gastrointestinal stromal tumor. Laparoscopic endoscopic cooperative surgery (LECS) is gastric wedge resection for gastric submucosal tumor using endoscopic submucosal dissection (ESD).

LECS had preserved the volume of the residual stomach without compromising the gastric lumen, whereby prevented from the removal of the excess mucosa.

**Material and Methods:** Five patients underwent LECS for gastric submucosal tumors. In LECS, resection line is determined from using ESD technique. A submucosal or full-thickness dissection around the tumor were circumferentially made using endoscopy. Subsequently, a seromuscular or full-thickness incision of the remaining wall was resected laparoscopically.

**Results:** In all cases, LECS was completed successfully. In four of five cases, the tumor was located in the upper gastric portion near the esophagogastric junction. A remaining tumor was in greater curvature of the posterior gastric wall. The median operation time was 148 (range 140–192), and the median estimated blood loss was 10 ml (range 10–100). There was no conversion to open surgery. The postoperative course was uneventful in all cases without anastomosis troubles (leakage, stenosis, and bleeding), gastric fullness, and reflex esophagitis.

**Conclusions:** LECS is a safe and feasible procedure for resecting a gastric submucosal tumor with minimum removal of the stomach wall and preserving gastric function. Especially, this approach can be an effective procedure for tumors located at the vicinity of the esogastric junction.

#### Abstract ID: 0087 Specific Field: Endoscopic Surgery

**Mode of pres.: Poster Exhibition only**  
ISW 2011 Session PE 59

#### Comparison of single-incision laparoscopic appendectomy and conventional laparoscopic appendectomy

D. Yamamoto, M. Kotake, H. Bando, M. Kaneko, M. Yamamoto, N. Inaki, M. Kurokawa, T. Yamada

Ishikawa Prefectural Central Hospital, Kanazawa, Japan

**Introduction:** Laparoscopic appendectomy has become a standard procedure for performing appendectomy. Single-incision laparoscopic surgery (SILS) is a new technique developed for better cosmetic wound. We started SILS technique for appendectomy since October 2009. We analyzed retrospectively data in our hospital to confirm safety and feasibility of Single-incision laparoscopic appendectomy (SILA).

**Material and Methods:** From October 2009 to December 2010, a total of 83 patients were performed laparoscopic appendectomy in our hospital. Among them, 15 patients who were mild appendicitis or appendicitis after treated with antibiotics were performed SILA. We performed four operative procedures at SILA. First two patients performed involved placement of 3 ports within a single supraumbilical curvilinear skin incision through separate fascial incisions, and a novel single port device (SILS port, Covidien) was used next 6 patients, a wound protector and a surgical glove with three trocars were used next 3 patients, the latest single port device (EZ access, Hakko) was used next 4 patients. Surgical results and perioperative outcomes were compared between SILA ( $n = 15$ ) and conventional laparoscopic appendectomy (CLA) ( $n = 68$ ).

**Results:** There were no significant differences in the mean of total operative time (63.8 vs 71.0 min), the mean hospital stay after operation (5.3 vs 5.1 days), the rate of complication (6.6% vs 2.9%) the patients between SILA groups and CLA groups.

**Conclusions:** SILA is feasible with safety in the mild appendicitis or appendicitis after treated with antibiotics. It can be considered as one of the alternative methods for treating acute appendicitis. EZ access the single port device is very useful to control forceps, to prevent air leakage, to limit the cost increase for SILA.

**Abstract ID: 0088** Specific Field: **Endoscopic Surgery**

**Mode of pres.: Poster Exhibition only**  
**ISW 2011 Session PE 60**

**Is end-to-anterior wall anastomosis safe and useful in conversion of DST of laparoscopic sigmoidectomy?**

H. Yamamoto, M. Sekimoto, M. Ikeda, I. Takemasa, T. Mizushima, J. Nishimura, Y. Doki, M. Mori

Graduate School of Medicine, Osaka University, Suita, Japan

**Introduction:** Double stapling technique (DST) is a physiological end-to-end anastomosis which is frequently used widely in rectal surgery and in sigmoidectomy. In laparoscopy-assisted sigmoidectomy, we occasionally encounter obstruction during insertion of the circular stapler device from the anus. In such cases, we used to cut the residual rectosigmoid colon additionally and to allow DST anastomosis. Here, we propose an alternative way to overcome this difficulty, that is to perform an anastomosis to the anterior wall of the rectosigmoid colon.

**Material and Methods:** Between 2001 and 2007, we experienced the cases of 10 sigmoid colon cancer patients who underwent laparoscopic surgeries with a conversion from DST to end to side (anterior wall) anastomosis.

**Results:** None of the patients suffered from anastomosis leakage, and none had complained of their stool habits. Colonoscopy showed that anastomosis window is kept wide and that stool is not pooled in the blind pocket of the rectosigmoid colon, suggesting the passage is well preserved.

**Conclusions:** Our experience indicates that though several technical points should be noted, an end to anterior wall anastomosis procedure is easy and safe. This method is a useful alternative way when end-to-end DST anastomosis is not performed smoothly in laparoscopic surgery. Our experience indicates that though several technical points should be noted, an end to anterior wall anastomosis procedure is easy and safe. This method is a useful alternative way when end-to-end DST anastomosis is not performed smoothly in laparoscopic surgery.

**Abstract ID: 0089** Specific Field: **Endoscopic Surgery**

**Mode of pres.: Poster Exhibition only**  
**ISW 2011 Session PE 61**

**Intraperitoneal local anaesthetic for pain reduction after laparoscopic gastric procedures: systematic review and meta-analysis of randomised controlled trials**

A. Kahokehr, T. Sammour, S. Srinivasa, A.G. Hill

University of Auckland, Auckland, New Zealand

**Introduction:** With the advent of minimally invasive gastric surgery, and natural orifice techniques emerging, visceral nociception has become an important area of investigation as a potential cause for postoperative pain. A systemic review and meta-analysis was carried out to investigate the clinical effects of intraperitoneal local anaesthetic (IPLA) in laparoscopic gastric procedures (LGP).

**Material and Methods:** Comprehensive searches were conducted independently without language restriction. Studies were identified from the following databases from inception to February 2010: Cochrane Central Register of Controlled Trials (CENTRAL/CCTR), Cochrane Library, Medline, PubMed, EMBASE and CINHALL. Relevant meeting abstracts and reference lists were manually searched. Appropriate methodology as per Cochrane Collaboration hand book

was utilised. Data analysis was performed using Review Manager Version 5.0 software.

**Results:** Five randomised controlled trials in LGP were identified for review. There was no significant heterogeneity between the trials (Chi = 10.27,  $P = 0.34$ ,  $I = 3\%$ ). Based on meta-analysis of trials, there appeared to be reduced abdominal pain intensity (overall mean difference  $-1.64$  [ $-2.09$  to  $-1.19$ ];  $P < 0.00001$ ), incidence of shoulder tip pain (overall odds ratio 0.15 [ $0.05$  to  $0.44$ ];  $P = 0.0005$ ) and opioid use (overall mean difference  $-3.23$  [ $-4.81$ ,  $-1.66$ ];  $P < 0.0001$ ).

**Conclusions:** There is evidence in favour of IPLA in LGP for reduction of abdominal pain intensity, incidence of shoulder pain, and postoperative opioid consumption.

**Abstract ID: 0090** Specific Field: **Endoscopic Surgery**

**Mode of pres.: Poster Exhibition only**  
**ISW 2011 Session PE 62**

**Local adaptations for laparoscopic surgeries in Ile-Ife, Nigeria**

A.O. Adisa, O.O. Lawal, O. Alatise, O.A. Arowolo, E.A. Agbakwuro Obafemi Awolowo University, Ile-Ife, Nigeria

**Introduction:** After several years of lagging behind due to several constraints, many general surgeons across Nigeria are now performing laparoscopic surgery. Many are however still concerned about its feasibility and safety in view of several local adaptations employed.

**Material and Methods:** All patients with general surgical conditions who had laparoscopic surgery from January 2009 through December 2010 in our hospital were prospectively studied. A modified laparoscopic set-up employing locally assembled and a few imported materials were employed for the procedures.

**Results:** Eighty-five patients whose ages ranged between 18 and 72 years had laparoscopic surgeries within the study period. These include 22 (25.9%) laparoscopic cholecystectomies, 14 (16.5%) appendectomies, 13(15.3%) adhesiolyses, while 36 (42.4%) others had diagnostic laparoscopies as well as biopsies of intra-abdominal masses. All diagnostic procedures were performed as day cases while the duration of hospital stay was 1-2 days for the therapeutic procedures. No mortality was recorded.

**Conclusions:** Our outcome shows the feasibility of laparoscopic surgery in Nigeria. We advocate local adaptations and improvisations to increase the use of laparoscopic surgery in Nigerian hospitals.

**Abstract ID: 0091** Specific Field: **Endoscopic Surgery**

**Mode of pres.: Poster Exhibition only**  
**ISW 2011 Session PE 63**

**Water-jet assisted endoscopic mucosal resection**

J. Rudnicki, J. Wierzbicki, M. Sebastian, T. Rudnicki

Wroclaw Medical University, Wroclaw, Poland

**Introduction:** The endoscopic mucosal resection/submucosal technique (EMR-endoscopic mucosal resection/ESD- endoscopic submucosal dissection) has been applied for a few years in the operative endoscopy in the treatment of benign neoplasms, preneoplastic conditions and even early forms of malignant neoplasms in the upper and lower segment of the alimentary tract. It enables radical removal of extensive and flat lesions found in the mucous membrane and submucosa, what is considered to be a great progress in

comparison with the previously applied loop or piecemeal polypectomy and mucosectomy.

**Material and Methods:** The authors of the work present their own experience based on the first 10 procedures on lesions in the form of adenomas, mild GIST and gastric mucosal dysplasia carried out with the use of the water-jet system in the oesophagus, stomach and large intestine. This technique is based on a submucosal injection/elevating the mucosa with the use of physiologic saline or hyaluronic acid administered with an injection needle and then dissection of lesions with special instruments: a small hook, ball or trocar. Injection of fluid with the use of injection needle or manual syringe is quite inconvenient and extends the treatment. Therefore, an endoscopic probe has been worked out for the water-jet (Erbejet 2) cooperating with electrosurgical unit (Erbe Vio 300 D), which enables submucosal application of fluid with the use of an irrigation pump and washout of the surgical field, which significantly facilitates the procedure.

**Results:** Good early and late results have been achieved in all the cases. There were observed two complications in form of bleeding. In one case bleeding was recorded directly after the procedure and was controlled endoscopically, in other it was late bleeding, which was treated conservatively. No other complications were observed.

**Conclusions:** It has been confirmed that this technique is very useful and it makes it possible to significantly reduce duration of procedures maintaining all advantages of the submucosal resection: radicality and great safety of the resection.

#### **Abstract ID: 0092** Specific Field: **Infection/Antibiotics/Wound Healing**

**Mode of pres.: Free Paper**  
**ISW 2011 Session 9.08**

##### **Postoperative chronic pain and discomfort after inguinal hernia repair**

T. Inaba, K. Okinaga, R. Fukushima, K. Iwasaki, E. Yamazaki, M. Horikawa, T. Inoue, E. Ogawa

Department of Surgery, Teikyo University School of Medicine, Tokyo, Japan

**Introduction:** Recently many specialists of inguinal hernia surgery in Japan think that to prevent chronic pain and discomfort is as important as to decrease the recurrence rate after surgery. Few studies have investigated the situation of it, however most of them were performed in Europe where the surgical procedures and nationality were different from those in Japan. The purpose of this study was to reveal the situation of postoperative chronic pain after inguinal hernia repair in Japan.

**Material and Methods:** Two hundreds and nineteen adult patients who had undergone inguinal hernia repair during Mar 2008 and Sep 2009 were included in this study. The study was performed by the method of questionnaire by mail asking the frequency and intensity of inguinal pain and discomfort after hernia repair. The choice of frequency were rare, 1–2 a week, almost every day, or continuous. Those of intensity were mild, tolerable, or need pain killer. We also asked the impression of the pain or discomfort by visual face scale varied “0” to “11”.

**Results:** One hundred and ninety-nine patients (87.2%) answered the questionnaire. Twenty-eight (14.7%) patients complained pain, and 33 (17.3%) patients complained discomfort of the inguinal lesion respectively (some of them were overwrapped). The frequency of pain was “rare” in more than half of the patients who complained chronic pain. No one answered to have “continuous” pain The intensity of the pain was “mild” in most of the patients and nobody

complained “need pain killer” pain. The answers of face scale questionnaire were “0” or “1” in most of the patients, however 9 patients checked “5” or higher. The incidence of patients with chronic pain and/or discomfort was significantly higher in women than men, and tended to be higher in patients who had undergone repairs using onlay mesh.

**Conclusions:** The frequency and intensity of postoperative chronic pain or discomfort after inguinal hernia repair were not so high or severe. We believe that our data are useful for further studies to discuss the best treatment for adult inguinal hernia patients.

#### **Abstract ID: 0093** Specific Field: **Infection/Antibiotics/Wound Healing**

**Mode of pres.: Free Paper**  
**ISW 2011 Session 9.09**

##### **Vastus lateralis muscle flap for infected hips after resection arthroplasty**

A.J. Suda, V. Heppert

BG Trauma Center Ludwigshafen, Ludwigshafen, Germany

**Introduction:** The treatment of resection arthroplasty of the hip after prosthetic infection remains a considerable challenge in reconstructive joint surgery. Therefore permanent solutions with a good clinical outcome and high patient acceptance are needed. The purpose of this study was to evaluate the potential of the vastus lateralis muscle flap in controlling hip infection after resection arthroplasty.

**Material and Methods:** We retrospectively reviewed 119 patients with 120 chronic infections after resection arthroplasty treated by a vastus lateralis muscle flap. The flap was fixed with Mitek anchors in the acetabular cavity. The average duration of infection after resection was 6.5 months. The patients had previously undergone an average of 4.9 operations. In all patients, we found the infected cavity to be the origin of the persistent infection.

**Results:** The minimum followup was 1 year (mean, 2.6 years; range 1.0 to 4.7 years). No recurrent infection has occurred in any of the 119 cases to date. Follow-up investigation by questionnaire occurred on average 2.6 years after flap transfer and showed less pain and a better quality of life.

**Conclusions:** The treatment of infected THA remains one of the great challenges in orthopedic surgery. Persistent infection after hip resection arthroplasty requires new approaches to this problem The vastus lateralis muscle flap is not a treatment of choice after an initial infection in the hip joint region. Instead the indication for this operation should be considered early on in the treatment of the chronic persistent infection after hip resection arthroplasty. Our patients underwent mean 2.3 (range 1–4) revision arthroplasties, so it is clear that this procedure should not be performed until the gold standard treatment had failed and the infection is still present. This present study it shows that the vastus lateralis muscle flap is a good salvage procedure in these cases.

#### **Abstract ID: 0094** Specific Field: **Infection/Antibiotics/Wound Healing**

**Mode of pres.: Free Paper**  
**ISW 2011 Session 31.06**

##### **Peritoneal cytokines and endotoxins as early markers of peritonitis following surgery for colorectal carcinoma**



D.M. Smirnov

Chelyabinsk State Medical Academy, Chelyabinsk, Russian Federation

**Introduction:** This study was to investigate if measurement of peritoneal cytokines and endotoxins is valuable for an early diagnosis of peritonitis following colorectal surgery.

**Material and Methods:** Sixty five consecutive patients who were to undergo elective resection for carcinoma of the sigmoid colon or the rectum were investigated within one year. Abdominal exudate was obtained from a drainage tube daily after surgery for measuring interleukins (IL)-1 $\beta$ , IL-6 and tumor necrosis factor (TNF)- $\alpha$ . Also peritoneal levels of endotoxin (also known as lipopolysaccharide (LPS)) were measured from the same time using the Pyrosate LAL (Limulus Amoebocyte Lysate) Test. The relationship between peritoneal cytokine and endotoxins levels during the first 4 days after surgery and the development of peritonitis was investigated.

**Results:** 9 patients developed postoperative peritonitis due to anastomotic leakage and pelvic abscess, which was diagnosed on postoperative days 4–9. Peritoneal cytokine and LPS levels on postoperative days 1 and 2 were not significantly different between the 6 patients who developed peritonitis and 56 patients who did not: day 1, IL-1 $\beta$   $P = 0.16$ , IL-6  $P = 0.27$ , TNF- $\alpha$   $P = 0.74$ , LPS  $P = 0.43$ ; day 2, IL-1 $\beta$   $P = 0.31$ , IL-6  $P = 0.09$ , TNF- $\alpha$   $P = 0.17$ , LPS  $P = 0.39$ . In contrast, the cytokine and LPS levels on days 3 and 4 were significantly higher in patients who developed peritonitis as compared with patients who did not: day 3, IL-1 $\beta$   $P = 0.03$ , IL-6  $P = 0.0012$ , TNF- $\alpha$   $P = 0.0001$ , LPS  $P = 0.002$ ; day 4, IL-1 $\beta$   $P = 0.006$ , IL-6  $P = 0.0001$ , TNF- $\alpha$   $P < 0.0001$ , LPS  $P = 0.0032$ . The LPS significantly increased during the first 4 days in patients who developed peritonitis ( $P = 0.0039$ ), while significantly decreased in patients who did not ( $P = 0.001$ ).

**Conclusions:** The outcomes of this investigation showed that the rise in peritoneal IL-1 $\beta$ , IL-6, TNF- $\alpha$  and LPS levels may be an additional early diagnostic predictor of intraabdominal infectious complications following colorectal surgery.

#### Abstract ID: 0095 Specific Field: Infection/Antibiotics/Wound Healing

Mode of pres.: Free Paper  
ISW 2011 Session 31.07

#### Antibacterial sutures to decrease surgical site infections: systematic review and meta-analysis of randomised trials

S. Srinivasa, W.K. Chang, R.P. Morton, A.G. Hill

Department of Surgery, University of Auckland, Auckland, New Zealand

**Introduction:** There have been considerable efforts to decrease the incidence of surgical-site infections (SSIs) as they pose considerable morbidity and increase healthcare costs. A potential strategy to decrease the rates of SSIs may be the use of antibacterial sutures. These have been endorsed and/or funded by professional and governmental bodies in numerous countries. Laboratory studies and non-randomised reviews have suggested that these sutures may reduce SSIs but there has been no summative assessment of this intervention with regards to clinical efficacy and safety. Hence, a systematic review and meta-analysis of all Randomised Controlled Trials (RCTs) investigating antibacterial sutures was conducted.

**Material and Methods:** The Cochrane Central Register of Controlled Trials, MEDLINE, EMBASE, Pubmed databases and trial registries were searched for published and unpublished RCTs. The endpoints of

interest were the incidence of SSIs and wound breakdown. A random effects model was used and pooled estimates were reported as odds ratio (OR) with the corresponding 95% confidence interval.

**Results:** Seven RCTs encompassing a total of 836 patients were included in the final analysis. The studies were of moderate quality. Antibacterial sutures did not statistically significantly reduce the rates of SSIs (OR = 0.77; 95% CI 0.40–1.51;  $P = 0.45$ ;  $I^2 = 24\%$ ). There was no difference in the rates of wound breakdown between the two groups (OR = 1.07; 95% CI 0.21–5.43;  $P = 0.93$ ;  $I^2 = 44\%$ ).

**Conclusions:** Although antibacterial sutures do not have adverse effects on wound healing, they do not decrease the rate of SSIs. Further studies within the right context are required before clinical use is considered.

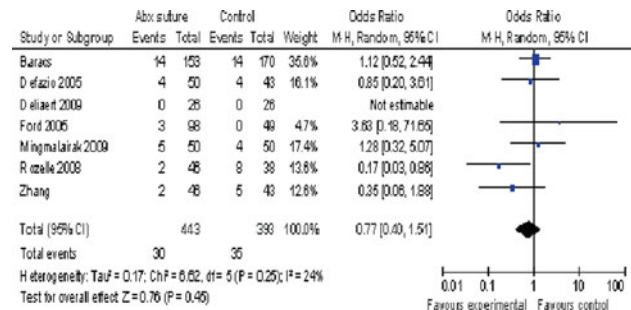


Figure: Surgical site infection

#### Abstract ID: 0096 Specific Field: Infection/Antibiotics/Wound Healing

Mode of pres.: Free Paper  
ISW 2011 Session 31.08

#### Synbiotics reduce infectious complications by improving intestinal environment and enhancing immune function in critically ill trauma or emergency surgical patients

Y. Kataoka

Kitasato University School Medicine, Sagamihara, Japan

**Introduction:** Critically ill patients frequently become susceptible to infectious complications that significantly increase morbidity and mortality. The objective of this study was to investigate the effects of synbiotics upon intestinal environment, immune response, and infection in critically ill patients.

**Material and Methods:** This study was performed as a prospective randomized trial. The following inclusion criteria were applied to patients: (1) ICU admission from emergency center, (2) trauma or emergency surgical adult patients, and (3) fed enterally within 72 h of admission. Patients in synbiotic group (S group) received synbiotics enterally within 48 h of admission for 14 days and those in control group (C group) received no synbiotics. Synbiotics used were Bio-lactis containing living *Lactobacillus casei* strain Shirota and BBG-01 containing living *Bifidobacterium breve* strain Yakult; as well as galactooligosaccharides.

**Results:** Thirty-two patients completed the trial; 20 had been assigned to S group, and 12 had been assigned to C group. The two groups were comparable at baseline. NK cell activity in S group increased significantly ( $P < 0.001$ ) during trial; in contrast, in C group unchanged. Lymphocyte counts in S group increased significantly ( $P < 0.01$ ), while in C group unchanged. C-reactive protein concentrations decreased significantly in the both groups. White blood



cell counts decreased significantly in S group, while in C group unchanged. In the analysis of fecal flora sampled after the trial, the numbers of *Bifidobacterium*, *Lactobacillus casei*, and *Lactobacillus plantarum* were significantly greater in S group than in C group. In the analysis of fecal organic acids, concentrations of total organic acids, acetic acid, and propionic acid were significantly greater in S group than in C group. Administration of synbiotics significantly reduced incidence of infectious complications compared with control (25% vs. 75%,  $P < 0.01$ ). ICU length of stay was significantly shorter in S group than in C group. There were no patients died and no adverse events during hospital stay.

**Conclusions:** Synbiotics in critically ill trauma or emergency surgical patients enhanced host immune function, based upon improving gut environment, and resulted in decreasing infectious complications.

### Abstract ID: 0097 Specific Field: Infection/Antibiotics/ Wound Healing

**Mode of pres.: Free Paper**  
ISW 2011 Session 31.09

#### Verification of the Tokyo guideline for the diagnosis and management of acute cholangitis

Y. Fujii, J. Ohuchida, K. Chijiwa, M. Nagano, M. Hiyoshi, K. Ohtani, M. Kai, K. Kondo

Miyazaki University, Miyazaki, Japan

**Introduction:** Four years have passed since the Tokyo Guideline for the management of acute cholangitis and cholecystitis was published. The purpose of this study is to verify the diagnostic criteria and severity grade of the Guideline for acute cholangitis.

**Material and Methods:** We evaluated 243 patients who were admitted to our hospital due to choledocholithiasis from 2001 through 2010. All the patients were examined whether acute cholangitis was able to be diagnosed by Tokyo Guideline. (Method 1) We compared the patients with acute cholangitis by Tokyo Guideline with those by our conventional diagnosis. (Method 2) We examined the hospital courses of the patients with acute cholangitis according to the severity grade of Tokyo Guideline.

**Results:** (Result 1) Acute cholangitis was diagnosed in 57 patients by Tokyo Guideline, while in 44 patients by conventional criteria. Three of 5 patients who were negative by Tokyo Guideline but positive by conventional criteria must receive a false negative diagnosis because the clinical courses obviously exhibited acute cholangitis. Whereas 7 of 18 patients who were positive by Tokyo Guideline but negative by conventional criteria had a false positive diagnosis because acute cholecystitis ( $n = 4$ ) or pancreatitis ( $n = 3$ ) exactly developed. (Result 2) Severity grades included mild in 9, moderate in 34 and severe in 14 patients. Five of 14 patients with severe grade had the following underlying or concomitant disease: liver cirrhosis ( $n = 2$ ), chronic renal failure ( $n = 2$ ) and severe acute pancreatitis ( $n = 1$ ). Complications occurred in 3 patients after endoscopic lithotomy with no episodes ending fatally (morbidity 5%, mortality 0%). Two thirds of the patients received early biliary drainage and the mean interval between admission and drainage was  $1.6 \pm 0.5$  (s.e.) days.

**Conclusions:** The patients with choledocholithiasis, who had concomitant acute cholecystitis or pancreatitis possibly receive a false positive diagnosis of acute cholangitis by Tokyo Guideline. On the other hand, there are a few cases of false negative diagnosis according to Tokyo Guideline for acute cholangitis. Classification between mild and moderate grade is not very important because the early drainage is necessary for satisfactory outcome. In case of severe grade cholangitis, some organ dysfunctions can be attributed to the underlying disease of the patient.

### Abstract ID: 0098 Specific Field: Infection/Antibiotics/ Wound Healing

**Mode of pres.: Nyhus Prize Session**  
ISW 2011 Session 95.06

#### The effect of triclosan-coated sutures on the incidence of surgical wound infection after lower limb vascular surgery: a randomized controlled trial

T. Hakala [1], M.J. Turtiainen [1], K. M [1], E. Saimanen [2], A. Nykanen [3], M. Venermo [3], I. Uurto [4]

[1] North Karelia Central Hospital, Joensuu, Finland, [2] South Karelia Central Hospital, Lappeenranta, Finland, [3] Helsinki University Hospital, Helsinki, Finland, [4] Tampere University Hospital, Tampere, Finland

**Introduction:** Surgical wound infection (SWI) is a common complication after lower limb vascular surgery. SWI increase morbidity and costs of treatment. Triclosan-coated sutures are reported to decrease the incidence of SWI in retrospective studies. The aim of our study was to test the hypothesis that use of triclosan-coated sutures decreases the incidence of SWI after lower limb vascular surgery.

**Material and Methods:** This prospective, randomized, multicenter, double-blinded trial was conducted between July 2010 and November 2010 in four secondary referral hospitals in Finland. We randomly allocated 112 patients undergoing lower limb revascularization surgery to study ( $n = 60$ ) or a control ( $n = 52$ ) group. Surgical wounds in the study group were closed with triclosan coated suture material (Vicryl Plus, Monocryl Plus; Ethicon, GmbH), and wounds in the control group were closed with non triclosan-coated sutures (Vicryl, Monocryl; Ethicon, GmbH). Subcutaneous tissue was closed with continuous and skin with intracutaneous sutures. Patients and investigators did not know which suture material were used. A majority of the patients were men, mean age was 71 years. The indication for surgery was critical limb ischemia in 64% of cases, and 29% had ischemic ulcer. The main outcome was SWI. A surgical wound complication was considered to be an infection if there were bacteria isolated from the wound or if there were areas of localized redness, heat, swelling and pain around the wound appearing within 30 days after the operative procedure. Patients were followed up for 30 days. Differences between groups were calculated by  $\chi^2$  or Fisher exact test for categorical variables and by Mann-Whitney U or  $t$ -test for continuously variables. Logistic regression analysis was used to assess the independent effect of triclosan coated sutures on the incidence of SWI.

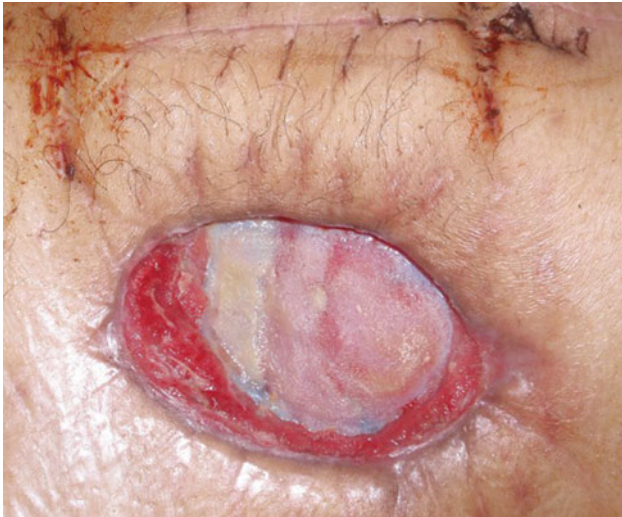**Results:** Altogether 27 (24%) patients developed SWI. There were two vascular graft infections. SWI occurred in 18 (30%) in the study group and in 9 (17%) in the control group [odds ratio 2.17, 95% confidence interval 0.82–5.72,  $P = 0.12$ ]. The incidence of major amputation was 2.7% and the 30-day mortality was 1.8% with no difference between groups.

**Conclusions:** The use of triclosan-coated sutures does not reduce the incidence of SWI after lower limb vascular surgery.

### Abstract ID: 0099 Specific Field: Infection/Antibiotics/ Wound Healing

**Mode of pres.: Poster Exhibition only**  
ISW 2011 Session PE 97

#### The use of human acellular dermal matrix mesh for abdominal wall reconstruction in definitive surgery for enterocutaneous fistulas



**Figure:** A biological mesh used to repair abdominal defect after resection the fistula of sigmoid colon

X. Zhang [1], G. Zhang [2], Q. Meng [1], W. Ji [1], F. Li [1], J. Zhao [1], J. Song [1]

[1] Department of General Surgery, General Hospital of Jinan Military Area, Jinan, China, People's Republic, [2] Department of General Surgery, Affiliated Hospital of Jining Medical College, Jining, China, People's Republic

**Introduction:** During the definitive surgery for enterocutaneous fistula (ECF), the affected abdominal wall usually requires partial resection and sometimes results in large abdominal wall defect. Repair of such a large contaminated defect is quite a challenge to surgeon, as there is a common consensus that use of synthetic mesh in contamination field is contraindicated. Herein we reported our experience about the use of biological mesh (RENOV<sup>®</sup> allogeneic acellular dermal matrix mesh) in abdominal wall reconstruction in definitive surgery for ECF.

**Material and Methods:** From Apr, 2009 to Dec, 2010, 22 patients with ECF received definitive surgery. Among them, RENOV<sup>®</sup> biological mesh was used in abdominal wall defect repair in 10 patients. The criteria for the application included any circumstance when a defect more than 3 cm or can not be sutured without tension. And in two cases, the retroperitoneal tissue was invade by colonic fistula and a biological mesh was used to isolate the intestine from the scared retroperitoneal tissue. For these patients, after the completion of digestive reconstruction and debridement of the defect, a sheet of RENOV<sup>®</sup> mesh, ranged from 64 to 108 cm, was placed in the abdominal cavity and secured to the surrounding abdominal wall with continuous absorbable suture (intraperitoneal onlay mesh technique, IPOM). In 3 cases, the skin and/or subcutaneous tissue could not be approximated and a vacuum-assisted closure was used. For the other 12 patients, the defect was closed by primary suture. All these patients were followed up for 8 months averagely (1–21 month).

**Results:** There wasn't operative mortality, all the patients recovered uneventfully. Among the 10 patients with biological mesh, there were 3 cases of recurrence 2 to 6 months later and two were operated successfully 3 months later. The reoperation revealed that the recurrence were not related to the mesh. An incisional hernia occurred at 6 months after surgery in two patients, and neither of them was repaired with mesh.

**Conclusions:** Our results indicated that the application of biological mesh in the reconstruction of abdominal wall defect during definitive surgery for ECF is safe and effective in decreasing the occurrence of incisional hernia.

**Abstract ID: 0100** Specific Field: **Infection/Antibiotics/Wound Healing**

**Mode of pres.: Poster Exhibition only**  
**ISW 2011 Session PE 98**

**Detection of plasma endotoxin using a novel endotoxin assay, endotoxin scattering photometry (ESP), in a patient with sepsis caused by colorectal perforation during tocilizumab treatment**

T. Shimizu [1], H. Akabori [1], E. Mekata [1], S. Murata [1], H. Yamamoto [1], T. Obata [2], H. Shiomi [1], T. Tani [1]

[1] Shiga University of Medical Science, Otsu, Japan, [2] Microbial Chemistry Research Foundation, Tokyo, Japan

**Introduction:** Endotoxin appears to play a major role in the development of toxic symptoms in sepsis. The turbidimetric Limulus amoebocyte lysate (LAL) assay is usually used for the detection of endotoxin; however, a novel rapid LAL assay for endotoxin has recently been developed that uses a laser light-scattering particle-counting method, called endotoxin scattering photometry (ESP).

**Material and Methods:** We report a case of sepsis in a patient with colorectal perforation, in which plasma endotoxin was detected by the ESP but not by turbidimetric assay.

**Results:** A 70-year-old woman with severe abdominal pain who received tocilizumab, an interleukin-6 receptor antagonist, was diagnosed with diffuse peritonitis caused by intestinal perforation. Emergency surgery revealed perforation of a rectosigmoid diverticulum, and the patient underwent Hartmann's procedure. She presented with sepsis after surgery; however, her overall condition rapidly improved. Decreased plasma endotoxin measured by EPS and reduction in plasma interleukin-6 appeared to accompany her improved septic condition.

**Conclusions:** We experienced a successfully treated case of sepsis caused by colorectal perforation, despite tocilizumab administration. Moreover, ESP may more sensitively detect sepsis than the widely-used quantitative turbidimetric endotoxin assay.

**Abstract ID: 0101** Specific Field: **Infection/Antibiotics/Wound Healing**

**Mode of pres.: Poster Exhibition only**  
**ISW 2011 Session PE 99**

**The infection in the pancreatic fistula after pancreaticoduodenectomy**

H. Ikoma, T. Ochiai, E. Otsuji, A. Shiozaki, M. Nakanishi, D. Ichikawa, K. Okamoto, Y. Kokuba

Kyoto Prefectural University of Medicine, Kyoto, Japan

**Introduction:** There is a case for critical situation pancreatic juice leak for pancreatectomy. Furthermore, the effective prophylactic approach is not established yet. However, it is considered that the critical situation is involved in infection complication.

**Material and Methods:** Since we conducted a retrospective review for pancreatic juice leak and infection responsible bacteria developed after pancreaticoduodenectomy at this time, the subjects for our report are 21 cases with pancreatic juice leak among pancreaticoduodenectomy PD53 at our hospital from April 2003 to March 2008, and we reviewed the cultivation test results from pancreatic juice leak, the clinicopathological factor and treatment method for the cases, the treatment content, and the prognosis.

**Results:** Among 21 cases with pancreatic juice leak development, the number of cases for submitting culture specimen from pancreatic juice leak was 19 cases and 366 specimens. Both MRSA and *Enterococcus faecalis* were separated from 43 specimens and then 31 specimens of *Klebsiella pneumoniae*, 24 specimens of *Stenotrophomonas maltophilia*, and 23 specimens of *Pseudomonas aeruginosa* were also separated respectively. The number of cases with MRSA infection complication for pancreatic juice leak was 9 out of 19 cases. 2 cases for false aneurysm by pancreatic juice leak were included and a complication by MRSA infection was found.

**Conclusions:** Most of the bacteria separated from pancreatic juice leak were resistant for antibiotics. When pancreatic juice leak occurs, its healing process would be prolonged and needs to have a whole-body management including a nutritional care to facilitate the healing such as a local control against a complication for resistant bacteria infection and a focus of infection by resistant bacteria. In addition, it was considered that a hospital ward management is necessary to prevent a resistant bacteria infection.

**Abstract ID: 0102** Specific Field: **Infection/Antibiotics/Wound Healing**

**Mode of pres.: Poster Exhibition only**  
**ISW 2011 Session PE 100**

**Risk factors of surgical site infection: the difference among the organs operated**

K. Kondo, K. Chijiwa, M. Kai, M. Hotokezaka, Y. Fujii, K. Otani, J. Ohuchida

Miyazaki University School of Medicine, Miyazaki, Japan

**Introduction:** Prevention of the surgical site infection (SSI) is important not only for patients' safety but also for medical economy. Investigation for risk factors of SSI contributes to prevent SSI. However, the risk factors may be different among the organs operated.

**Material and Methods:** From 2007 to 2010, 280 patients (age: mean  $\pm$  SD = 60.7  $\pm$  17.5, sex: M/F = 193/87), 178 patients (65.8  $\pm$  11.4, 149/65), and 133 patients (67.7  $\pm$  12.0, 73/60) underwent colorectal surgeries (CRS), hepatectomies (Hx), and pancreatectomies (Px), respectively, in our institute. The presence of SSI (including superficial, deep, and organ/space) was carefully examined prospectively until postoperative 30 days, and the incidence of SSI was investigated in each surgical procedure. The possible risk factors including patients' background (age, sex), nutrition (BMI, serum albumin), concomitant diseases (hypertension, diabetes mellitus, ASA class), liver function (serum total bilirubin, prothrombin time, pre-operative biliary drainage (POBD)), operation factors (operative procedure (laparoscopic or open for CRS, with or without biliary reconstruction (BR) for Hx, and pancreaticoduodenectomy or distal pancreatectomy for Px), operation time (OT), and operative blood loss (OBL)) were compared between the patients with SSI and those without SSI by univariate (UVA) and multivariate analysis (MVA).

**Results:** In CRS, Hx, and Px, the incidences of SSI were 17.5, 13.5, and 35.3%, respectively. In CRS, significant risk factors for SSI were high BMI, long OT, and large amounts of OBL by UVA. Of these factors, BMI ( $\geq 23$  kg/m<sup>2</sup>) and OBL ( $\geq 500$  ml) were independent factors by MVA (Odds ratio (OR): 2.0 and 2.1, respectively). In Hx, significant risk factors were female, POBD, long OT, and BR. The independent factors by MVA were female and POBD (OR: 3.8 and 5.7, respectively). In Px, significant risk factors were high BMI, hypertension, ASA class, POBD, and long OT. Of these factors, high BMI ( $\geq 24$ ) and ASA class 3 were independent factors by MVA (OR: 2.9 and 6.2, respectively).

**Conclusions:** Risk factors and the incidence of SSI were different among the organs operated. Preventive measures and special attention against SSI are required for CRS patients with high BMI and large amount of OBL, for Hx patients received POBD, and for Px patients with high BMI and high ASA class.

**Abstract ID: 0103** Specific Field: **Infection/Antibiotics/Wound Healing**

**Mode of pres.: Poster Exhibition only**  
**ISW 2011 Session PE 101**

**Preoperative systemic inflammation is a novel predictor of postoperative infectious complications in patients undergoing resection for gastrointestinal cancer**

Y. Mohri, M. Kusunoki, M. Kobayashi, Y. Okita, K. Tanaka, Y. Inoue, Y. Toiyama, M. Ohi

Mie University Graduate School of Medicine, Tsu, Mie, Japan

**Introduction:** The presence of systemic inflammation before surgery predicts poor long-term survival in cancer patients. However, few studies have investigated the relationship the preoperative systemic inflammatory response and postoperative complications in the field of gastrointestinal cancer surgery. Our aim was to evaluate the significance of preoperative systemic inflammatory response on postoperative infectious complications of patients with gastrointestinal cancer.

**Material and Methods:** The systemic inflammatory response was classified on the basis of admission data as follows: a normal C-reactive protein (<1.0 mg/dl) and normal albumin (>3.5 g/dl) scores 0, with an elevated C-reactive protein scoring 1 and an elevated C-reactive protein together with a low albumin scoring 2. The significance of postoperative infectious complication was analyzed by univariate and multivariate logistic regression analyses.

**Results:** A total of 481 patients were evaluated. After surgery, 81 (17%) patients developed a postoperative infectious complication. Univariate analysis revealed that a score of preoperative systemic inflammatory response was most sensitive predictor of postoperative infectious complication (odds ratio, 2.775; 95% confidence interval, 1.345–5.588;  $P = 0.0063$ ). Multivariate analyses using factors such as gender, operation time, operative blood loss, serosal invasion, distant metastasis, and systemic inflammatory response revealed that systemic inflammatory response (odds ratio, 2.462; 95% confidence interval, 1.118–5.319;  $P = 0.0257$ ) was associated with a postoperative infection.

**Conclusions:** Preoperative systemic inflammatory response is considered to be a useful predictor of postoperative infectious complications in patients undergoing resection for gastrointestinal cancer.

**Abstract ID: 0104** Specific Field: **Infection/Antibiotics/Wound Healing**

**Mode of pres.: Poster Exhibition only**  
**ISW 2011 Session PE 102**

**Does obesity relate to postoperative surgical site infection?**

G. Nagao, H. Matsuoka, T. Kishiki, A. Nobutsugu, O. Yanagida, T. Masaki, T. Mori, M. Sugiyama

Department of Surgery, Kyorin University, Tokyo, Japan

**Introduction:** Obesity became rapidly increasing morbidity in Japan. Abundant adipose tissue is problematic especially in abdominal surgery. It causes technical difficulty and leads to prolonged operative time or increases intra-operative blood loss. In addition, these patients



often accompanied with co-morbidity such as hypertension, diabetes and more. These backgrounds are potential fears for postoperative surgical site infection.

**Material and Methods:** Retrospective chart review was performed in 338 patients with colorectal cancer treated from March 2006 through September 2008. Fifty-seven patients with body mass index (BMI) equal to or higher than 25 (Obesity group) and 281 patients with BMI under 25 (Non-obesity group) were evaluated in terms of background factors including patients gender, age, American Society of Anesthesiology performance status (ASA-PS), blood sugar (BS) at starvation, history of diabetes, smoking, operative time, intra-operative blood loss, simultaneous other organ resection and use of laparoscopy.

**Results:** Comparing between the obesity versus non-obesity groups, age (71 vs. 69 y.o.), male female ratio (0.8 vs. 1), proportion of ASA-PS 3 and 4 (17 vs. 17%), diabetes (16 vs. 10%), smoking rate (11 vs. 17%) showed no statistical significant difference. In terms of operative factors, time (255 vs. 255 min), blood loss (257 vs. 306 ml), simultaneous other organ resection rate (9 vs. 17%) and use of laparoscopy also showed no significant difference. Although these factors were not different significantly including obesity, BS at starvation showed significantly higher value in the obesity group (157 vs. 136 mg/dl ( $P = 0.001$ )).

**Conclusions:** Obesity did not related to postoperative surgical site infection.

#### **Abstract ID: 0105** Specific Field: **Infection/Antibiotics/Wound Healing**

**Mode of pres.: Poster Exhibition only**  
**ISW 2011 Session PE 103**

##### **Effect of Smithwick operation for intractable pain of diabetic/ischemic lower limb ulceration**

K. Nagasaki [1], A. Asami [1], H. Obara [2], Y. Kitagawa [2]

[1] Saitama Municipal Hospital, Saitama, Japan, [2] Keio University School of Medicine, Tokyo, Japan

**Introduction:** The treatment for the pain of lower limb, especially infectious, ulceration with diabetes or sever leg ischemia, which exists even after revascularization, is the use of non-steroidal anti-inflammatory drugs or narcotic analgesic in general. However some patients with these ulcerations suffer intractable pain in spite of the use of analgesics. In such case, pain control is very important and necessary in disposal of ulceration, although keeping sensory is needed for foot care. To explore the usefulness of Smithwick operation for intractable pain of diabetic/ischemic lower limb ulceration, we have investigated the effect and period of pain relief, and side effects following this operation.

**Material and Methods:** Twenty-five limbs in 20 patients (65% male, mean age 72) were treated with Smithwick operation from April, 2009 through October, 2010. Smithwick operations were performed in all limbs, as follows. Sensory nerves of foot consist of saphenous, sural, superficial /deep perineal, and tibial nerve. Whereas the first two are pure sensory nerves, the latter two are mixed nerve without major motor nerves in less than one-third leg. Therefore, skin incisions for each are made at the height of ankle under local anesthesia. After these nerves are hold, they are crushed by forceps in 1.0 cm length.

**Results:** Thirteen limbs in 11 patients exhibited diabetic ulceration, eight limbs in 6 were ischemic, and all others had diabetic- and-ischemic ulceration. Revascularizations were performed in seven ischemic limbs of 5, and in four ischemic-and-diabetic limbs of 3. Sixteen limbs in 14 had infection, including MRSA (seven limbs in 7) in the ulcerations already on admission. After the operation, seventeen limbs in 20 had complete pain relief, but other five limbs in 3 incomplete, followed by

re-operation. Major side effect was wound infection in five limbs (20%) of 3, all of whom had MRSA infection in the ulcerations. All of 17 patients, except for 3 dead from myocardial infarction (2) and cerebral infarction (1), recovered perception in 6 months.

**Conclusions:** Smithwick operation is very useful and should be looked over again in the treatment for diabetic/ischemic lower limb ulceration with intractable pain, even through this operation is classical and may not be popular method.

#### **Abstract ID: 0106** Specific Field: **Infection/Antibiotics/Wound Healing**

**Mode of pres.: Poster Exhibition only**  
**ISW 2011 Session PE 104**

##### **Tetanus prophylaxis for trauma patient in Japan**

R. Sasaki, A. Kimura, A. Hagiwara

National Center for Global Health and Medicine, Tokyo, Japan

**Introduction:** Supplemental prophylaxis in adults varies among individuals or institutions in Japan, because it is not clearly defined. This is attributable to decreased interest in diagnosis or prevention of tetanus due to its low incidence and the fact that few conventional tetanus immune antibody tests are performed due to being time and cost consuming. In this study, we aimed to establish a tetanus prophylaxis algorithm for trauma care using a rapid test kit to objectively determine the presence of tetanus antibodies.

**Material and Methods:** In 228 subjects brought to our hospital by ambulance from October 2009 to August 2010, we measured tetanus antibody titers (IU/ml) with Tetanus Quick Stick (TQS<sup>®</sup>), which is a tetanus rapid test kit, and with enzyme-linked immunosorbent assay (ELISA). We also recorded age, vaccination history, etc. of the subjects. **Results:** In 137 (60.1%) of 228 subjects, the tetanus antibody titer was 0.1 IU/ml or more that is a sufficient protection level against tetanus. The accuracy of TQS<sup>®</sup> was 69.3% sensitivity, 95.6% specificity, and 96.0% positive predictive value. In all of 15 subjects with less than 10 years of vaccination history, the titer measured by ELISA was 0.1 IU/ml or more. We compared tetanus antibody titers between the subjects born before and after 1968 when tetanus toxoid was introduced into routine immunization in Japan. As a result, subjects with a sufficient antibody titer accounted for only 37% of those born in 1967 or before and nearly 90% of those born in 1968 or after.

**Conclusions:** The accuracy of TQS<sup>®</sup> was almost similar to those in previous reports. We consider difference in the prevalence of tetanus antibody due to vaccination history or age as an important factor for establishing a tetanus prophylaxis algorithm in Japan.

#### **Abstract ID: 0107** Specific Field: **Infection/Antibiotics/Wound Healing**

**Mode of pres.: Poster Exhibition only**  
**ISW 2011 Session PE 105**

##### **ESWL for ureteric stone: unusual cause of necrotizing fasciitis in previously healthy young female**

O. Sadieh, A. Ghasoup, A. Al-Ani

AlBashir Hospital - MOH, Amman, Jordan

**Introduction:** Necrotizing fasciitis (flesh-eating disease) is an insidiously advancing soft tissue infection characterized by widespread fascial necrosis. It was first described in 1848. The causative bacteria



may be aerobic, anaerobic, or mixed flora, and the expected clinical course varies from patient to patient. The 3 most important types of necrotizing fasciitis syndromes are type I (polymicrobial); type II (group A streptococcal); and type III gas gangrene (clostridial myonecrosis). The mean age of the patients is 38–44 years. The male-to-female ratio is 3:1. Necrotizing fasciitis can be difficult to recognize in their early stages, but they rapidly progress. They require aggressive treatment to combat the associated high morbidity and mortality (which is in overall 70–80%).

**Material and Methods:** A 24 year old female presented with 3 months history of right loinpain following labour, Intravenous pyelogram showed Right sided hydronephroureter due to ureteric stone. Extracorporeal Shock Wave Lithotripsy session was performed for the patient. One day later, she started to develop severe abdominal pain different from the previous one.

**Results:** On examination she got tenderness and feeling of crepitus in the wall of the right side of the abdominal wall, which was not present previously, CT scan revealed Right abdominal wall necrotizing fasciitis, extending to the retroperitoneum, Diagnostic Laparoscopy confirm the diagnosis. We treated her by repeated aggressive wound excision, antibiotics and treatment was completed by skin graft.

**Conclusions:** This case not only represent a concurrence of an unusual entity but also alerts us that necrotizing fasciitis may developed after Extracorporeal Shock Wave Lithotripsy. A retroperitoneal nidus of infection may be considered. Early diagnosis, aggressive and emergent surgical intervention are required for the survival of these patients.

**Abstract ID: 0108**

**Specific Field: Oncology**

**Mode of pres.: Free Paper**  
**ISW 2011 Session 48.01**

**Tissue IL-8 mRNA expression is a predominant risk and prognostic marker for gastric cancer with independent correlation to low pepsinogen I/II ratio, and cagA mutation of *H. pylori***

S. Yamada [1], S. Kato [2], M. Takeshi [2], L. Makonkawkeyoon [1], M. Yoshida [3], T. Charkrabandhu [1], N. Lertprasertsuk [1], T. Azuma [3]

[1] Chiang Mai University, Chiang Mai, Thailand, [2] Nippon Medical School, Tokyo, Japan, [3] Kobe University School of Medicine, Kobe, Japan

**Introduction:** Regardless of high land such as Northern Thailand still gets the higher incidence rate of gastric cancer, that is 6.6:100,000 for male and 4.5:100,000 for female. The Interleukin-8 (IL-8) gene is one of the principal mediators for the inflammatory response. Recently, in vitro study showed the association of the mucosal tissue IL-8 mRNA expression related to *H. pylori*, cagA gene, East Asian genotype in gastric cancer. Low serum pepsinogen I/II ratio less than 3.0 with pepsinogen I level less than 70 ng/dl was referred as an important risk factor found in Japanese gastric cancer with significant relative risk. The cagA, East Asian genotype was commonly related in Japanese gastric cancer. There was no recent in vivo study reported of linkage among these factors. We aim to search for in vivo tissue IL-8 mRNA expression as a risk for advance gastric cancer in correlation with other recent reported factors.

**Material and Methods:** There were consent 186 Thai non-cancer volunteers who underwent endoscopic NBI examination during 2006–2008, and 97 Thais gastric cancer patients who underwent endoscopy and gastric surgery during year 2007–2009. All patients in this studied were in stage II to IVa (locally advanced gastric cancer) who were all resectable cases, and received standard i.v. 5-FU based chemotherapy post surgery. Tissue samples were taken before any

treatment by endoscopy with 3 points biopsies, and from surgical specimen immediately after gastric resection at lesser curvature and tumor site above non-necrotic area All tissues were preserved at  $-80^{\circ}\text{C}$ . Blood exam and serum separation were done, and preserved at  $-20^{\circ}\text{C}$ . The serum pepsinogen I, II, and IgG Antibody for *H. pylori* were tested by standard ELISA technique. The Histopathology description of tumor, defined histologic type, chronic gastritis, and metaplasia with *H. pylori* detection were done with modified Sydney Score System by 2 pathologists. The serum *H. pylori* IgG antibody for *H. pylori* and pepsinogen I and II were tested. Tissue *H. pylori* DNA extracted from antral position in stomach was examined and genotyped for cagA mutation. Tissue mRNA were extracted and converted to cDNA kept in banking for all genetic testing in year 2009–2010. From 5 novel expressions of TNF- $\alpha$ , IL-4, IL-10, IL-8, and COX-2, we measured horizontal expression on 5 same cancers, benign, normal tissue cDNA sample, and AGS cell line as a control Then, we decided to select for measurement of IL-8 and COX-2 mRNA expression due to regular detection, and much difference on cancer and normal and cell line control samples. We measured Tissue IL-8 mRNA expression conducted by RT-PCR and demonstrated on gel electrophoresis, and then on real time RT-PCR (Relative quantitation technique) by using AGS cell line control in all sets of samples. From 17 Japanese cancer and 12 benign gastric tissue samples, all were tested with same methods as in Thai tissue samples to compare on IL-8 and COX-2 expression. Univariate and multivariate were used for risk study. Standardized *T*-test was used for quantitative data.

Correlation study on pair factors was done in subgroup analysis for defined group of cancer population and non-cancer population. STATA and SPSS 16 were used for statistical analysis and *P* value  $<0.05$  was considered as a statistically significant.

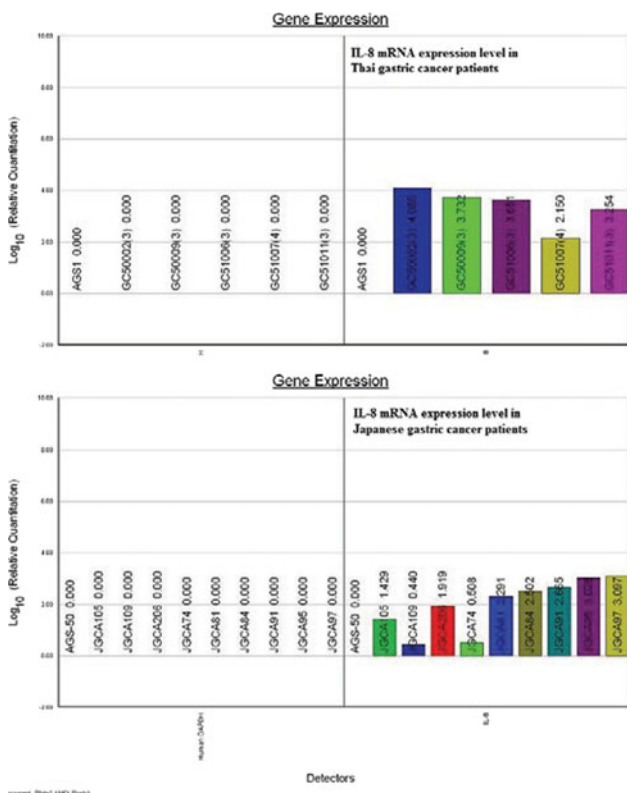
**Results:** There are 71 normal control, 50 peptic ulcers and other benign lesion, 65 chronic gastritis, and 97 cancer cases. Thai male and female cancer incidences are 59.79% (58/97) and 40.21% (39/97), respectively. The *H. pylori* infection prevalence was reported by combined histopathology and *H. pylori* IgG Ab test with 77.12 and 97.44% of sensitivity and specificity, respectively. Among Thai non-cancer volunteers, *H. pylori* prevalence is 64.3%. There were 39.56% negative cagA genotyping and 60.44% positive cagA genotyping that yields 29.67% of East Asian type, 16.48% of Western, and 14.29% of Mix type. In the followed up case of Thai CAG group who had long term *H. pylori* cagA East Asian type infection, no one developed to be cancer. Meanwhile, Thai gastric cancer group had 69.6% of *H. pylori* prevalence, but cagA genotype could be found in only 13.21% of cases that yields 11.32% of East Asian and 1.89% of western type There is a significantly lower PGI/II ratio at means of  $3.3 \pm 1.7$  in cancer patients,  $P = 0.042$ , and in chronic active gastritis (CAG),  $P = 0.002$  when compared to ratio in normal control The detection rate of IL-8 expression is 77/86 (79.38%) in gastric cancer patients. The mean level of IL-8 mRNA expression in Thai cancer group is higher than in non-cancer group,  $P = 0.058$ . The mean level of IL-8 mRNA expression in Thai cancer and Japanese cancer were 9,615.65 ( $\log_{10} = 2.62$ , 95% CI = 2.37–2.87) and 1,490.67 ( $\log_{10} = 2.2$ , 95% CI = 1.78– 2.68), respectively The means IL-8 mRNA expression in non-cancer Thais is 2,262 ( $\log_{10} = 1.49$ , 95% CI = 0.48–1.47). There is higher means IL-8 mRNA expression level in Thais than in Japanese for both cancer and non-cancer cases. In univariate analysis, there are 5 significant factors related gastric cancer risk in Thais, and showed in Table 1. For the multivariate analysis application, 3 remaining factors related to gastric cancer risk are male, IL-8 expression level  $>100$ , and PG I/II less than 3.0.

There is a significantly lower PGI/II ratio in Japanese than in Thai gastric cancer,  $P = 0.026$ . Serum PGI/II ratio at cut off less than 3.0 and IL-8 mRNA expression  $>100$  or  $\log_{10} >2$  are significantly found in cancer group when compared to non-cancer group,  $P = 0.013$  and  $P < 0.001$ , respectively. In the correlation study, low PGI/II ratio did not associate with CAG severity score in Thais non-cancer cases.

However, there is a trend, but not significant convert correlation between IL-8 mRNA expression level and low pepsinogen I/II ratio. **Conclusions:** In this study, we found that IL-8 cytokine expression is a significant risk and may act as a prognostic marker in gastric cancer. There is independent correlation with very low PGI/II ratio in gastric cancer as well as in CAG, but not with *H. pylori* infection. The results of IL-8 mRNA expression and pepsinogen ratio in both ethnics reflect to individualized host stomach mucosal defense and nature of cancer. Almost all of Thai cancer cases are diffuse type, while Japanese are commonly found to be intestinal type. Higher level IL-8 mRNA expression in non-cancer Thais comparing with non-cancer Japanese showed difference in mucosal defense of gastric mucosa between the two, while the higher expression matched also the poorer prognosis histopathology cell type. There is possibility to use serum pepsinogen for early gastric cancer detection in low incidence area. We found that IL-8 mRNA expression is a significant risk with independent correlation to low serum pepsinogen I/II, and *H. pylori* infection in gastric cancer. There is possibility to use IL-8 mRNA expression as a biomarker for further chemotherapy study in advance gastric cancer.

**Table 1** Univariate analysis result for significant gastric cancer risk factors in Thais

	Relative risk (OR)	95% CI	P -value
Smoking	1.74	1.04–2.90	0.033
Male	2.05	1.30–3.24	0.002
PGI/II < 3	1.61	0.98–2.63	0.059
Interleukin-8 Raw RQ >100	2.59	1.59–4.20	< 0.001
Interleukin-8 Log 10 >2	2.79	1.69–4.59	< 0.001



**Figure:** IL-8 mRNA expression level in Thai and Japanese cancer patients

**Abstract ID: 0109**

**Specific Field: Oncology**

**Mode of pres.: Free Paper**  
**ISW 2011 Session 48.02**

**Neoadjuvant, adjuvant and palliative treatment with imatinib in patients with gastrointestinal stromal tumors**

B. Nilsson [1], H. Ahlman [1], O. Nilsson [2], K. Sjölund [1], B. Wangberg [3]

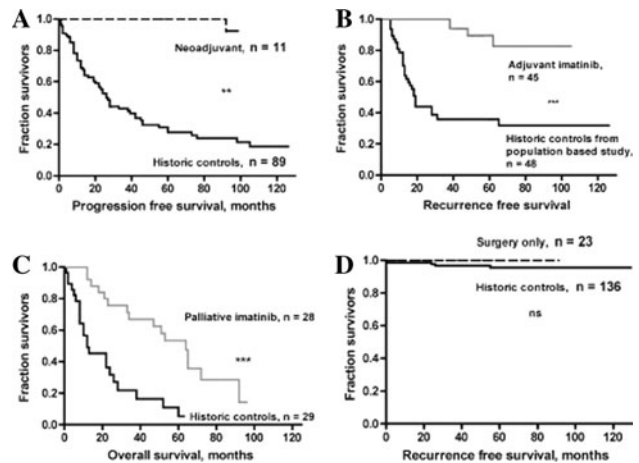
[1] Surgery, Gothenburg, Sweden, [2] Pathology, Gothenburg, Sweden, [3] Surgery, Sweden

**Introduction:** The tyrosine kinase inhibitor (TKI) imatinib is the first-line palliative treatment inhibiting mutated KIT. Our aim was to compare the survival of patients only surgically treated in the pre-imatinib era with that after introduction of the drug in a defined population.

**Material and Methods:** During 2002–2008, 107 GIST patients were treated. Neoadjuvant imatinib (*n* = 11) was used for organ-preservation, patients with R0-resection received imatinib adjuvantly (*n* = 45), and those with R2-resection had life-long palliative imatinib (*n* = 28). Patients with low/intermediate risk GISTs (*n* = 23) underwent surgery only. These groups were compared with historic controls from our population-based series (*n* = 259) matched for sex, age, tumor size, and mitotic rate. Mutational analysis of KIT and PDGFRA was performed in all cases.

**Results:** Patients treated with neoadjuvant imatinib (A) had 90% 5-year estimated progression-free survival (vs. 30% in 89 matched historic controls, *P* = 0.01). The mean size of these tumors decreased in diameter from 20.3 to 10.1 cm and the surgical procedures were thus limited (gastric resection, wedge liver resections, and salvage of cardia, pancreas and rectum). Patients treated with 1 year adjuvant imatinib (B) after radical (R0) surgery, had 85% 5-year estimated recurrence-free survival (*P* = 0.001) vs. 35% in controls; Patients treated with palliative imatinib (C) after tumor reduction (R2) had 55% 5-year estimated over all survival vs. 5% in 29 controls (*P* = 0.001). In the low/intermediate-risk (NIH consensus) group there were no recurrences after surgery only (D) vs. 3 in the control group (Fig. 1).

**Conclusions:** Neoadjuvant treatment with imatinib is recommended for patients with bulky tumors to facilitate organ preserving surgery, and adjuvant imatinib only for high risk patients after R0 resection. Intermediate risk GIST patients do not need adjuvant imatinib. Palliative imatinib improves survival in R2 resected patients.



**Fig. 1** Survival of GIST patients treated during 2002–2008 with neoadjuvant, adjuvant and palliative imatinib compared to historic controls from our population based series from western Sweden

**Abstract ID: 0110**Specific Field: **Oncology****Mode of pres.: Free Paper**  
**ISW 2011 Session 48.03****Surgical injury accelerates tumor growth by inducing mobilization and recruitment of bone marrow-derived stem cells**

Y. Takemoto, T.-S. Li, M. Kubo, K. Ueda, E. Harada, N. Uesugi, T. Enoki, K. Hamano

Yamaguchi University, Ube, Japan

**Introduction:** Surgical injury may accelerate tumor growth and metastasis, negatively affecting patients' prognosis. Previous studies have demonstrated that many factors, but the precise mechanisms are not yet fully understood. We tested the hypothesis that surgical injury induces mobilization and recruitment of bone marrow-derived stem cells, thereby enhancing angiogenesis and accelerating tumor growth.

**Material and Methods:** Mice were subjected to open gastrotomy, and naive mice were used as controls. Mobilization of bone marrow-derived stem cells was monitored after surgery. Using an established tumor model in GFP<sup>+</sup> bone marrow-transplanted chimera mice, we further investigated whether the mobilized stem cells affected tumor growth. To evaluate the influence on tumor growth of surgical injury and the inhibition of SDF-1/CXCR4 signals, we used AMD3100, a CXCR4 antagonist.

**Results:** Compared to control, gastrotomy significantly increased the populations of CD34<sup>+</sup> cells ( $6.9 \pm 4.5\%$  vs  $3.3 \pm 0.4\%$ ,  $P < 0.05$ ) and CD34<sup>+</sup>/Flk-1<sup>+</sup> cells ( $0.08 \pm 0.02\%$  vs  $0.05 \pm 0.01\%$ ,  $P < 0.05$ ) in peripheral blood 12 h after surgery. Twelve days after surgery, the tumor volume was almost double in mice after gastrotomy compared with control ( $580 \pm 106 \text{ mm}^3$  vs  $299 \pm 162 \text{ mm}^3$ ,  $P < 0.05$ ). Histological analysis of tumor tissue revealed that the microvessel density and number of proliferating cells were significantly higher, but those of apoptotic cells were significantly lower, in mice after gastrotomy as compared with control. Furthermore, the number of GFP<sup>+</sup> cells found in tumor tissue was significantly larger in mice that underwent gastrotomy than in control. Some of the stained GFP<sup>+</sup> cells were positive for CD34 and had been incorporated into microvessels. However, administration of AMD3100 significantly inhibited the recruitment of GFP<sup>+</sup> cells and completely negated the acceleration in tumor growth after surgery ( $345 \pm 172 \text{ mm}^3$ ,  $P < 0.05$ ).

**Conclusions:** Surgical injury induces mobilization and recruitment of bone marrow-derived stem cells, resulting in enhancement of angiogenesis and acceleration of tumor growth. Temporary inhibition of the SDF-1/CXCR4 signals may represent new therapeutic strategies for preventing acceleration of tumor growth after surgery.

**Abstract ID: 0111**Specific Field: **Oncology****Mode of pres.: Free Paper**  
**ISW 2011 Session 48.04****Relationship between additive effects of irinotecan to fluorouracil and genetic polymorphisms of UGT1A1 in chemosensitivity**

T. Ochiai, T. Watanabe, M. Kitajima, T. Hashiguchi, A. Nakatani, T. Uchida, K. Nishimura, S. Futagawa

Tobu Chiiki Hospital, Tokyo Metropolitan Health and Medical Treatment Corporation, Tokyo, Japan

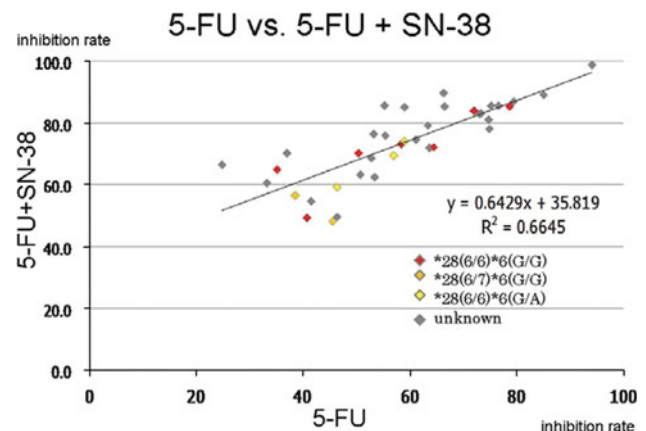
**Introduction:** FOLFOX or FOLFIRI are widely used as first-line chemotherapy in the treatment of advanced colorectal cancer (CRC). In general, it is not important whether FOLFOX or FOLFIRI is

administered first. Where possible, the most effective regimen should be chosen as the first line of treatment. We have already reported that FOLFIRI should be selected as the first-line chemotherapy in the treatment of poor responders to 5-FU using the collagen gel droplet embedded culture-drug sensitivity test (CD-DST). However, there are remarkable individual differences in the additive effects of irinotecan (SN-38) to 5-FU. The aim of this study was to determine individual differences in the additive effects of SN-38 to 5-FU based on genetic polymorphisms of UGT1A1.

**Material and Methods:** Specimens of primary tumors were obtained from 45 CRC patients who had received no preoperative chemotherapy between March 2008 and October 2010. Informed consent for measuring drug sensitivity was obtained from all patients. The CD-DST was performed and the inhibition rate was obtained under incubation conditions (5-FU at  $6.0 \mu\text{g}$  for 24 h and 5-FU + SN-38 at  $6.0 + 0.2 \mu\text{g}$  for 24 h). The effects of addition of SN-38 were evaluated based on linear regression analysis. In 13 patients, the relationship between the additive effects of SN-38 and genetic polymorphisms of UGT1A1 was determined.

**Results:** The approximate expression and correlation coefficients (5-FU vs. 5-FU + SN-38) were  $y = 0.6427x + 35.823$  and  $R^2 = 0.6646$ , respectively. Addition of SN-38 yielded a greater additive effect (synergetic effect) due to the lower efficacy of 5-FU. The UGT1A1 genotypes \*28(6/6)\*6(G/G), \*28(6/7)\*6(G/G) and \*28(6/6)\*6(G/A) were observed in 7 patients, 3 patients and 3 patients, respectively. In these patients, the approximate expression and correlation coefficients (5-FU vs. 5-FU + SN-38) were  $y = 0.7773x + 25.57$  and  $R^2 = 0.7588$ , respectively.

**Conclusions:** In patients with the UGT1A1 \*28(6/6)\*6(G/G), \*28(6/7)\*6(G/G) or \*28(6/6)\*6(G/A) genotypes, no notable additive effect was observed with addition of SN-38 to 5-FU. These data suggest that a lower antitumor response will be achieved in vivo in patients with these genotypes.

**Figure:** Relationship (5-FU vs. 5-FU + SN-38)**Abstract ID: 0112**Specific Field: **Oncology****Mode of pres.: Free Paper**  
**ISW 2011 Session 48.05****An isolation strategy for biomarkers that predict cancer relapse after adjuvant chemotherapy**

S. Nishizuka, K. Ishida, T. Chiba, T. Matsuo, K. Otsuka, K. Koeda, G. Wakabayashi



Dept. Surg. Iwate Med. Univ. Sch. Med., Morioka, Japan

**Introduction:** Although postoperative adjuvant chemotherapy has shown a favorable success rate, there are still considerable numbers of patients who experience cancer relapse following this therapy. Therefore, being able to predict chemosensitivity by solid molecular evidence would allow us to select biologically reasonable drugs and to avoid adverse effects in those patients who may fail to benefit from chemotherapy.

**Material and Methods:** Several candidate markers have been isolated based on the drug-protein association from a “chemosensitivity and protein expression matrix” obtained by a “conventional chemosensitivity assay for 12 drugs” and a “quantitative lysate array for 50 proteins” using a panel of 12 cancer cell lines. The panel of candidate proteins was examined by immunohistochemistry and tissue microarrays of 79 gastrointestinal cancer cases with adjuvant chemotherapy after operation. A functional assay by siRNA gene knockdown was also performed to confirm whether the protein expression actually affects the chemosensitivity.

**Results:** The 79 gastrointestinal cancer patients who underwent operation followed by 5-FU based adjuvant chemotherapy were investigated. Among the candidate proteins measured in these 79 patients, expression of nuclear NF $\kappa$ B showed a significant association with cancer relapse (median observation period, 2.8 years;  $P < 0.0001$ , Fisher’s exact test). A Kaplan–Meier estimation confirmed that the time to relapse (TTR) was significantly shorter for patients who were positive for nuclear NF $\kappa$ B expression-positive than for negative cases ( $P < 0.0001$ , Log-Rank test). In a subset analysis, in terms of cancer lesions, the nuclear expression of NF $\kappa$ B showed stronger discriminatory power in predicting the relapse of gastric cancer than of colon cancer. A functional validation study using gene knockdown of NF $\kappa$ B by siRNA revealed increased chemosensitivity for 5-FU in gastrointestinal cancer cell lines ( $P < 0.05$ , *t*-test).

**Conclusions:** We adopted the technologies which have been used for small molecule screening in anti-cancer drug discovery, on clinically approved drugs to predict chemosensitivity in terms of cancer relapse. Our results indicate that nuclear expression of NF $\kappa$ B may be a good marker for consideration of alternative chemotherapeutic regimens for post-operative gastrointestinal cancer patients immediately after the operation.

**Abstract ID: 0113**

Specific Field: **Oncology**

**Mode of pres.: Free Paper**  
**ISW 2011 Session 48.06**

**Splenomegaly in FOLFOX-naïve patients due to chemotherapy-associated hepatotoxicity can be predicted by the aspartate aminotransferase to platelet ratio before chemotherapy in stage IV or recurrent colorectal cancer**

H. Nakano [1], K. Miura [2], T. Otsubo [2]

[1] St. Marianna University School of Medicine, Kawasaki, Japan,  
[2] St. Marianna University Yokohama-City-West Hospital, Japan

**Introduction:** Chemotherapy-associated hepatotoxicity cannot be disregarded due to postoperative complications after major hepatectomy. Splenomegaly may indicate portal hypertension due to chemotherapy. To identify chemotherapy-naïve patients with liver damage, splenic volume (SV) and aspartate aminotransferase to platelet ratio (APR) were investigated.

**Material and Methods:** Seventy-one patients receiving FOLFIRI, FOLFOX, and FOLFOX plus Bevacizumab as the first-line of chemotherapy were included. The SV measurement was performed by helical CT volumetry, and the SV index (SVI) was calculated during 6

cycles of chemotherapy. The APR was used as an indicator for liver injury and an APR index (APRI) was calculated.

**Results:** The SVI and APRI were significantly greater in the FOLFOX than in the FOLFIRI group. In the FOLFOX group, the maximum APR during FOLFOX was significantly higher in the SVI +30% than in the SVI < +30% group ( $P < 0.01$ ). The incidences of Grade 3 or 4 adverse events and Grade 2 or more histopathologic sinusoidal injury were significantly higher in the SVI +30% than in the SVI < +30% group. Interestingly, the SVI was significantly greater in the group with APR 0.17 before FOLFOX than in that with an APR < 0.17 before FOLFOX ( $P < 0.05$ ).

**Conclusions:** Splenomegaly due to FOLFOX-associated hepatotoxicity can be predicted if the APR before FOLFOX was 0.17 or more.

**Abstract ID: 0114**

Specific Field: **Oncology**

**Mode of pres.: Free Paper**  
**ISW 2011 Session 48.07**

**Preoperative blood vessel imaging by three-dimensional CT: in laparoscopic colectomy for right-side colon cancer**

A. Ikeda, T. Sato, M. Watanabe

Kitasato University Hospital, Sagami, Japan

**Introduction:** There are many vascular variations in branch from superior mesenteric artery (SMA) compared with inferior mesenteric artery. Therefore it is important that we understand blood vessels anatomy before surgery especially for laparoscopic operation. This study was planned to examine the variations of SMA before operation. Furthermore we compared open colectomy (OC) with laparoscopic colectomy (LAC) in regard to safety and validity simultaneously.

**Material and Methods:** From April 2005 to December 2009, 102 patients underwent three-dimensional computed tomography (3D-CT), and performed to examine vascular anatomy before surgery for right-side colon cancer. We evaluated branch configuration of SMA, positional relation between branch of SMA and superior mesenteric vein (SMV).

**Results:** We were able to reconstruct blood stream by 3D-CT with 114 among 119 patients. We found the ileocolic artery (ICA) and middle colic artery were observed in all of our cases. The right colic artery (RCA) was observed in 14 cases directly branch off from the SMA (13.7%) and 11 cases branch off from the ICA (10.8%). The ICA passed anterior to the SMV in 51 cases (52.6%) and posterior in 46 cases (47.4%). The RCA passed anterior to the SMV in 11 cases (84.6%) and posterior in 2(15.4%) cases. Six cases were converted LAC to OC. However, we did not recognize postoperative complications. Concerning the number of lymph nodes evaluated after complete mesocolic excision, there was no difference between OC and LAC group.

**Conclusions:** This study showed that 3D-CT was useful for understanding of blood stream of SMA. We were able to perform safety and validity laparoscopic operation by understanding positional relation between branch of SMA and SMV before surgery.

**Abstract ID: 0115**

Specific Field: **Oncology**

**Mode of pres.: Free Paper**  
**ISW 2011 Session 48.08**

**Genotype subset selection of multi-UGT1As polymorphisms can predict severe neutropenia and tumour responses of metastatic CRC patients received FOLFIRI regimen**



S. Hazama [1], T. Katoh [2], K. Takahashi [3], H. Nozawa [4], F. Kimura [5], M. Oka [1], J. Sakamoto [6], H. Mishima [7]

[1] Yamaguchi University Graduate School of Medicine, Ube, Yamaguchi, Japan, [2] Minoh City Hospital, Minoh, Japan, [3] Akita City Hospital, Akita, Japan, [4] Kouseiren Takaoka Hospital, Takaoka, Japan, [5] Itami City Hospital, Itami, Japan, [6] Nagoya University Graduate School of Medicine, Nagoya, Japan, [7] Osaka National Hospital, Osaka, Japan

**Introduction:** The pharmacogenetics of irinotecan indicate that a common polymorphism in the uridine diphosphate glucuronosyl-transferase 1As (UGT1As) gene predict severe toxicity. However the tumor response to irinotecan is variable and unpredictable.

**Material and Methods:** Two multi-center phase II studies of FOLFIRI (FLIGHT-1 and FLIGHT-2 study) were conducted for patients with metastatic colorectal cancer (CRC) in Japan. FLIGHT-1 study was first-line chemotherapy, and FLIGHT-2 study was FOLFOX-refractory second-line chemotherapy. 103 patients have been enrolled in these studies (53 patients in FLIGHT-1 and 50 patients in FLIGHT-2) from 20 institutions by April 2007 from November 2005. Seventy one patients were analyzed UGT1As polymorphisms, UGT1A1\*28 (TA6 > TA7), UGT1A1\*6 (G > A), UGT1A1\*60 (T > C), UGT1A7 (N129K; T > G), UGT1A7 (-57 T > G), UGT1A9\*22 (T10 > T9).

**Results:** Out of 71 patients, 34 had G3/4 neutropenia or leukopenia, and 23 had tumor responses (CR + PR). G3/4 neutropenia was more frequent in patients with \*6, N129K(G), -57(G), \*22 allele than patients without these allele ( $P < 0.05$ ). Other polymorphism was not the predictive factor for toxicity and tumor response, independently. On the other hand, genotype subset selection of multi-UGT1As polymorphisms was useful to predict severe toxicities and tumor responses. Twelve out of 16 patients with G3/4 neutropenia had either, UGT1A1\*28(TA6/6) & UGT1A9\*22(T9/9) or UGT1A1\*28(TA6/7) & UGT1A7(-57; T/G). While, 22 out of 29 patients with G0/1/2 neutropenia had either UGT1A1\*28(TA6/6) & UGT1A9\*22(T10/10), UGT1A1\*28(TA6/7) & UGT1A7(-57; T/T) or UGT1A1\*6(G/G) & UGT1A1\*60(T/T). Thirteen patients out of 15 non-response patients had either UGT1A1\*60(G/G), UGT1A1\*6(G/G) & UGT1A7(-57; T/G), UGT1A1\*28(TA6/7) & UGT1A1\*6(G/G), UGT1A1\*28(TA6/7) & UGT1A9\*22(T9/10). While, 8 out of 12 response patients had either UGT1A1\*6(G/A) & UGT1A9\*22(T9/9), UGT1A9\*22(T10/10) & UGT1A1\*60(T/G), UGT1A1\*28(TA6/6) & UGT1A1\*60(T/G) & UGT1A7(-57; T/G), UGT1A1\*28(TA6/6) & UGT1A7(-57; G/G).

**Conclusions:** Genotype subset selection of multi-UGT1As polymorphisms were the excellent predictor for severe toxicities and tumor responses of metastatic CRC patients received FOLFIRI regimen.

**Abstract ID: 0116**

Specific Field: **Oncology**

**Mode of pres.: Free Paper**  
**ISW 2011 Session 48.09**

**Highly sensitive diagnostic method for colorectal cancer using the ratio of free DNA fragments in the serum**

S. Arakawa [1], S. Ozawa [2], T. Ando [3], H. Takeuchi [3], U. Kitagawa [3], S. Umemoto [1], Z. Morise [1]

[1] School of Medicine, Fujita Health University, Nagoya, Japan, [2] Tokai University School of Medicine, Kanagawa, Japan, [3] School of Medicine, Keio University, Tokyo, Japan

**Introduction:** The correlations between the ratio of long/short-chain DNA fragments in blood and the existence of cancer as well as the

clinicopathological features of colorectal cancer (CRC) patients were examined and the potential use of this ratio for diagnostic screening was evaluated.

**Material and Methods:** The Alu247/115 ratio (DNA quantities amplified with Alu247 [long-chain DNA fragments]/DNA quantities amplified with Alu115 [long-chain and short-chain DNA fragments]) was calculated and examined in 60 CRC patients and 24 non-cancer healthy subjects. **PURPOSE:** The correlations between the ratio of long/short-chain DNA fragments in blood and the existence of cancer as well as the clinicopathological features of colorectal cancer (CRC) patients were examined and the potential use of this ratio for diagnostic screening was evaluated. **METHODS:** The Alu247/115 ratio (DNA quantities amplified with Alu247 [long-chain DNA fragments]/DNA quantities amplified with Alu115 [long-chain and short-chain DNA fragments]) was calculated and examined in 60 CRC patients and 24 non-cancer healthy subjects.

**Results:** The Alu247/115 ratio for CRC patients was significantly higher than that for non-cancer healthy subjects ( $P < 0.001$ ). Similarly, the ratio for Dukes A or B patients was significantly higher than that for the non-cancer healthy subjects ( $P = 0.034$ ), and the ratio for Dukes C or D patients was also significantly higher than that for Dukes A or B patients ( $P = 0.016$ ). The Alu247/115 ratio for the  $n(+)$  CRC patients was significantly higher than that for the  $n(-)$  CRC patients ( $P = 0.011$ ). The ratio for the  $v(+)$  CRC patients was significantly higher than that for the  $v(-)$  CRC patients ( $P = 0.031$ ). When a receiver operating characteristic (ROC) curve was plotted to discriminate CRC patients from healthy subjects, the area under the curve was 0.828. Using the cut-off value set from the ROC curve, the sensitivity of the Alu247/115 ratio was significantly higher than that of the CEA or CA19-9 value (Alu247/115 vs. CEA,  $P = 0.004$ ; Alu247/115 vs. CA19-9,  $P < 0.001$ ).

**Conclusions:** Our data suggests that the Alu247/115 ratio is a promising tool for the highly sensitive, early detection of CRC.

**Abstract ID: 0117**

Specific Field: **Oncology**

**Mode of pres.: Free Paper**  
**ISW 2011 Session 48.10**

**Surgical intervention for metastatic liver GIST in the era of TKIs**

H. Kikuchi, T. Setoguchi, Y. Hiramatsu, M. Baba, M. Ohta, K. Kamiya, T. Sakaguchi, H. Konno

Hamamatsu University School of Medicine, Hamamatsu, Japan

**Introduction:** Imatinib (IM) and sunitinib (SU) are effective treatments for recurrent or metastatic gastrointestinal stromal tumors (GISTs), but secondary resistance has been reported. In the era of tyrosine kinase inhibitors (TKIs), surgical intervention for recurrent GIST, particularly, hepatectomy for metastatic liver GIST has been reevaluated. However, indication and timing of such surgery remain to be discussed. We identified the mechanisms responsible for GIST liver metastasis and discuss the indication of hepatectomy as well as novel therapeutic targets.

**Material and Methods:** Three primary and 17 metastatic liver GISTs in 14 patients who had undergone a hepatectomy for metachronous liver metastases without IM treatment were analyzed immunohistochemically and genetically. Clinicopathological findings were compared between the two patients who had undergone hepatectomy for metastatic liver GISTs sensitive to IM and resistant to IM/SU, respectively. Microarray analyses were performed to compare gene expressions between 3 non-metastatic primaries and 4 metastatic liver GISTs.

**Results:** (1) Ki67 in the metastatic GISTs was higher than that of the primary GISTs and the LOH of the c-kit gene was observed mainly in the metastatic tumors (58.3%). Patients with “Ki67 <5% and LOH (–)” had a significantly longer post recurrent disease free survival (PRDFS) after hepatectomy than those with “Ki67 5% or LOH (+)” ( $P = 0.032$ ). (2) Metastatic tumors in a patient with IM/SU-resistant GISTs showed heterogeneous secondary mutations in the c-kit gene, indicating the polyclonal evolution of recurrent GISTs, while a patient with metastatic liver GIST sensitive to IM had no resistant clones and has been alive without recurrence. (3) Microarray and immunohistochemistry revealed that versican, known to recruit myeloid-derived mononuclear cells and facilitate tumor metastasis, was up-regulated in metastatic GISTs. Furthermore, high expression of versican in the primary GIST correlated with poor prognosis.

**Conclusions:** (1) “Ki67 <5% and LOH of the c-kit gene (–)” in the metastatic liver could be a potential prognostic marker after hepatectomy and may select the patients who can be treated with surgery alone. (2) If R0 resection is expected, surgical intervention under the control of TKI should be considered for the control of metastatic GIST. (3) Versican could have a potential to be a novel therapeutic target.

**Abstract ID: 0118**

Specific Field: **Oncology**

**Mode of pres.: Poster Discussion**  
**ISW 2011 Session 60.07**

#### MicroRNAs as regulators of metastasis in pancreatic ductal adenocarcinoma

W.A. Mardin [1], S.A. Dhayat [1], N. Elshorst [1], C. Haane [1], N. Senninger [1], J. Haier [2], S.T. Mees [1]

[1] Dept. of General and Visceral Surgery, University Hospital of Muenster, Muenster, Germany, [2] Comprehensive Cancer Center, University Hospital of Muenster, Muenster, Germany

**Introduction:** Pancreatic ductal adenocarcinoma (PDAC) is recognized for its lethality which is largely due to late clinical manifestation combined with rapid dissemination. Molecular profiling and comparison of primary tumors with metastatic lesions will identify regulators of metastasis and potential therapeutic targets. MicroRNAs are an emerging class of molecules involved in a multitude of cellular processes including tumorigenesis and metastasis. The aim of this study was to identify novel regulators in the metastatic cascade of PDAC.

**Material and Methods:** Using an orthotopic mouse model, tissue was collected from primary tumors and metastases of 3 PDAC cell lines (MiaPaCa2, SU86.86, Panc1). RNA expression was determined by microarray and qRT-PCR. Immunohistochemical analysis was carried out for relevant proteins (E-cadherin and vimentin) and histological appearance was evaluated by a pathologist. Statistical analysis was performed using SPSS 16.0 and GeneSpring 7.3.1 (*t*-test, Bonferroni Correction).

**Results:** The miRNA let-7 family, a proposed tumor suppressor, was significantly upregulated in metastases vs. primary tumors ( $P < 0.001$ ) and its target HMGA2 was correspondingly downregulated. The miRNA 200 family, recognized as stemness- and metastasis-inhibitors, along with its connected mRNAs E-cadherin and ZEB1 was not differentially expressed between tissues ( $P = 0.64$ ).

**Conclusions:** Both investigated miRNA clusters are implicated in the inhibition of epithelial to mesenchymal transition (EMT), which in turn is a facilitator of metastasis. Their upregulation in PDAC metastases suggests that while EMT may be a prerequisite in the

initiation of metastasis, it may be reversed in the final metastatic colony. These observations suggest that current metastasis models proposing initial EMT followed by mesenchymal to epithelial transition apply to PDAC. (Supported by a grant from Foerderverein Peter Geiger e.V.)

**Abstract ID: 0119**

Specific Field: **Oncology**

**Mode of pres.: Poster Discussion**  
**ISW 2011 Session 60.08**

#### Bone marrow-derived EP3-expressing stromal cells enhanced tumor-associated angiogenesis and tumor growth with increased recruitment of VEGFR-1/VEGFR-2 positive cells

Y. Ogawa [1], A. Oikawa [2], T. Suzuki [2], S. Hosoya [1], Y. Nishiyama [1], H. Amano [2], M. Watanabe [3], M. Majima [2]

[1] Japanese Red Cross Tsukui Hospital, Sagamihara, Japan, [2] Department of Pharmacology, Kitasato University, Sagamihara, Japan, [3] Department of Surgery, Kitasato University, Sagamihara, Japan

**Introduction:** Recent results have suggested that hematopoietic cells recruited from the bone marrow (BM) were major components of tumor stroma that determine the tumor microenvironment, and showed crucial roles in tumor growth and angiogenesis.

**Material and Methods:** We examined the role of recruited BM cells expressing EP3 in tumor-induced angiogenesis and tumor growth. Stroma was developed by recruitment of BM cells, when wild-type (WT) BM was replaced with BM cells from green fluorescent protein (GFP) transgenic mice.

**Results:** Selective knockdown of EP3 by recruitment of genetically modified BM cells lacking EP3 receptors was performed by transplantation of BM cells from EP3 knockout (EP3<sup>-/-</sup>) mice. In WT mice transplanted with BM cells from EP3<sup>-/-</sup> mice, tumor growth and tumor-induced angiogenesis were suppressed compared with those in mice transplanted with WT BM cells. Immunohistochemical study revealed that vascular endothelial growth factor (VEGF) expression in the stroma was suppressed in mice transplanted with BM cells from EP3<sup>-/-</sup> mice. EP3 signaling has a significant role in the recruitment of vascular endothelial growth factor receptor-1 (VEGFR-1) positive cells and VEGFR-2 positive cells from BM to the stroma.

**Conclusions:** These results indicate that host stromal VEGF up-regulation and the recruitment of VEGFR-1/VEGFR-2 positive cells via EP3 signaling is a key regulator of tumor-associated angiogenesis, and that blockade of EP3 signaling together with the recruitment of EP3-expressing stromal cells may become a novel strategy for fighting cancers.

**Abstract ID: 0120**

Specific Field: **Oncology**

**Mode of pres.: Poster Discussion**  
**ISW 2011 Session 60.09**

#### Familial gastric cancer by hereditary cancer population screening: implications for prevention

A. Vanags, I. Strumfa, G. Trofimovics, J. Gardovskis

Riga Stradins University, Riga, Latvia

**Introduction:** Advanced gastric cancer (GCA) has poor prognosis therefore prevention or early diagnostics is important. We present

## Characteristics of familial gastric cancer (FGC) and suspected FGC syndromes

	FGC	Suspected FGC
Population frequency,% [95% CI]	0.11 [0.07–0.17]	0.40 [0.32–0.50]
Gastric cancer (GCA) frequency,% [95% CI]	25.5 [20.6–30.4]	16.0 [13.8–18.5]
Age of GCA diagnostics, years [95% CI]	56.9 [53.4–66.3]	62.5 [60.1–64.8]
Age of GCA-related death, years [95% CI]	58.3 [55.3–61.3]	65.6 [63.4–67.6]
Endometrial cancer frequency,% [95% CI]	6.3 [3.1–12.4]	3.0 [1.7–5.2]
Fraction of GCA,% [95% CI]	4.7 [3.8–5.9]	13.8 [12.2–15.6]

hereditary cancer population screening (PS) to highlight the possibilities for hereditary/familial GCA prevention.

**Material and Methods:** PS was carried out in a territorial unit analysing cancer family histories by questionnaire from 18642 adult respondents (76.6% of population). The familial gastric cancer syndrome (FGC) was diagnosed if 3 first-degree blood relatives (BR) were affected by GCA, but suspected (sFGC) if 2 first-degree BR were affected. Statistics was performed by CIA software.

**Results:** High GCA frequency in BR (Table) exceeded significantly the spouse correlation: 3.6% [95% confidence interval: 1.2–10.2]. Familial GCA constituted significant fraction of all GCA cases. The population frequency, age of familial GCA diagnostics and GCA-related death was estimated. The age of probands ranged 19–88 years, mean 56.8 [53.6–60.0] years. Only 1.1% [0.2–5.7] probands was affected by GCA. The GCA frequency tended to be higher in families reporting only GCA in comparison to pedigrees showing presence of other tumours. Endometrial cancer was the most frequent extragastric tumour.

**Conclusions:** PS by simple questionnaire allows identifying families with high frequency of GCA. Surveillance is justified by GCA frequency if 2 or 3 BR have had GCA. In PS approach, the probands are mostly oncologically healthy providing opportunity for surveillance and surgical prophylaxis in the setting of appropriate molecular diagnostics. The age characteristics of the tumours can be used to adjust the surveillance schedule.

**Material and Methods:** From February 2009 to September 2010, 96 patients (PDAC:  $n = 53$ , pancreatitis:  $n = 30$ , healthy control:  $n = 13$ ) were enrolled in the study and consent was obtained. Serum was collected from each patient and frozen at  $-80^{\circ}\text{C}$  till further processing. RNA isolation was carried out using a modified TRIzol method and artificial miRNAs were spiked in at 5 nM. MicroRNA-microarray was carried out by febit GmbH (Heidelberg, Germany) for 19 PDAC, 15 pancreatitis and 8 control samples. Significantly differentially expressed miRNAs were validated by quantitative reverse transcriptase PCR in all 96 samples. Statistical analysis was performed using SPSS 16.0 and GeneSpring 7.3.1.

**Results:** The following miRNAs were validated to be upregulated in PDAC vs. both pancreatitis and healthy controls: miR-190, -1246, -26a, -3152, -1265, -924, while miR-509-3-5p, -519c-5p, -501-3p, -548s-195\* were downregulated. Using the validated miRNAs, PDAC was differentiated from pancreatitis with a sensitivity of 0.84 and specificity of 0.94.

**Conclusions:** This is the first investigation of circulating miRNAs as biomarkers for PDAC that has made use of microarrays to investigate global expression rather than employing qRT-PCR to focus on specific miRNAs. Thus, novel biomarker candidates have been identified. Further functional analysis of these miRNAs will uncover their significance and role in the progression of PDAC. (Supported by a grant from Foerderverein Peter Geiger e.V.)

**Abstract ID: 0121**

Specific Field: **Oncology**

**Mode of pres.: Nyhus Prize Session  
ISW 2011 Session 95.05**

#### Serum microRNA signatures differentiate pancreatic ductal adenocarcinoma from pancreatitis and healthy pancreas

W.A. Mardin [1], S.A. Dhayat [1], E. Willscher [2], C. Schleicher [1], N. Senninger [1], J. Haier [3], S.T. Mees [1]

[1] Dept. of General and Visceral Surgery, University Hospital of Muenster, Muenster, Germany, [2] Dept. of Bioinformatics, Integrated Functional Genomics, Muenster, Germany, [3] Comprehensive Cancer Center, University Hospital of Muenster, Muenster, Germany

**Introduction:** Pancreatic ductal adenocarcinoma (PDAC) is recognized for its lethality which is largely due to late clinical manifestation combined with rapid dissemination. Current treatment relies heavily on surgery, however most tumors are unresectable at time of presentation. In order to move forward the time of diagnosis, specific, sensitive and easily accessible markers are essential. MicroRNAs are an emerging class of molecules involved in a multitude of cellular processes including tumorigenesis and metastasis. Additionally, they are disease specific and highly stable in blood, predestined to become a novel class of biomarkers.

**Abstract ID: 0122**

Specific Field: **Oncology**

**Mode of pres.: Free Paper  
ISW 2011 Session 148.02**

#### CT lymphography for the preoperative detection of sentinel node stations in laparoscopic gastrectomy with early gastric cancer

Y. Yaguchi [1], H. Tsujimoto [1], I. Kumano [1], K. Fujino [2], S. Ono [3], T. Ichikura [1], J. Yamamoto [1], K. Hase [1]

[1] Department of Surgery, National Defense Medical College, Tokorozawa, Japan, [2] Department of General Medicine, National Defense Medical College, Tokorozawa, Japan, [3] Division of Traumatology, National Defense Medical College Research Institute, Tokorozawa, Japan

**Introduction:** The sentinel node (SN) concept has been found to be valuable in gastric cancer. However, the lymphatic network of gastric cancer may be more complex than in other cancers to which this concept is applied, and it may be difficult to visualize all the SNs distributed in unexpected areas by conventional modalities such as RI and dye methods. In this study, we evaluated the feasibility and efficacy of computed tomographic lymphography (CT-LG) for the detection of SN stations (SSs) in early gastric cancer.

**Material and Methods:** A total of 20 patients with early gastric cancer (cT1N0) who underwent a laparoscopic gastrectomy were

enrolled in this study. Three modalities (CT-LG, dye, and RI method) were performed for the detection of SS. Under endoscopy, CT-LG images were obtained at 1, 3, 5, and 10 min after injection of iodinated contrast agents (Iopamidol, 19 cases; Lipiodol, 1 case) before the surgery. The regional LN area of an enhanced lymphatic duct and node was defined as an SS. We evaluated the detection rate and the number of SSs, and the detection rate of metastatic LNs.

**Results:** SSs were successfully identified by CT-LG in 85% (17/20) of patients. The median number of SSs was 1 (range 0–3). Three metastatic LN cases were detected. CT-LG revealed a metastatic LN in an SS in one of these patients; the SS had not been detected by RI and dye methods. In the other 2 cases, one had no SS detection, and the other had an SS in the No. 3 area while the metastatic LN existed in the infrapyloric LN (No. 6) area.

**Conclusions:** CT-LG for the preoperative detection of SS in early gastric cancer has advantages in laparoscopic gastrectomy. However, based on this initial experience, CT-LG had a relatively low detection rate. Further efforts will be necessary to improve the detection rate and widen the clinical application of CT-LG for the detection of SS in early gastric cancer.

**Abstract ID: 0123**

Specific Field: **Oncology**

**Mode of pres.: Free Paper**  
**ISW 2011 Session 152.01**

**MicroRNA miR-125a regulates ERBB2 and inhibits the proliferation of human gastric cancer cells in combination with trastuzumab**

N. Nishida [1], K. Mimori [1], M. Mori [2]

[1] Medical Institute of Bioregulation Kyushu University, Beppu, Japan, [2] Osaka University Graduate School of Medicine, Suita, Japan

**Introduction:** miR-125a-5p has been reported to be a tumor suppressor in malignancies of the breast, ovary, lung, and central nervous system. However, the clinical significance of miR-125a-5p in human gastrointestinal cancer has not been explored. We investigated a tumor inhibitory effect of miR-125a-5p in gastric cancer, focusing in particular on the miR-125a-ERBB2 (HER2, HER-2/neu) pathway.

**Material and Methods:** Quantitative RT-PCR was used to evaluate miR-125a-5p expression in 87 gastric cancer cases to determine the clinicopathologic significance of miR-125a-5p expression. The regulation of ERBB2 by miR-125a-5p was examined with precursor miR-125a-transfected cells. Furthermore, we investigated whether miR-125a-5p suppresses proliferation of gastric cancer cells in combination with trastuzumab, a monoclonal antibody against ERBB2.

**Results:** Low expression levels of miR-125a-5p were associated with enhanced malignant potential such as tumor size ( $P = 0.0068$ ), tumor invasion ( $P = 0.031$ ), liver metastasis ( $P = 0.029$ ) and poor prognosis ( $P = 0.0069$ ). Multivariate analysis indicated that low miR-125a-5p expression was an independent prognostic factor for survival. In vitro assays demonstrated that ERBB2 is a direct target of miR-125a-5p. MiR-125a-5p potently suppressed the proliferation of gastric cancer cells, and interestingly, the growth inhibitory effect was enhanced in combination with trastuzumab.

**Conclusions:** MiR-125a-5p is a meaningful prognostic marker. Furthermore, miR-125a-5p mimic alone or in combination with trastuzumab could be a novel therapeutic approach against gastric cancer.

**Abstract ID: 0124**

Specific Field: **Oncology**

**Mode of pres.: Free Paper**  
**ISW 2011 Session 152.02**

**A novel small molecule inhibitor of FAK inhibits the ability of proliferation and invasion of human cholangiocarcinoma cell lines in vitro**

N. Uyama, Y. Iimuro, N. Kuroda, T. Hirano, T. Okada, Y. Asano, K. Suzumura, J. Fujimoto

Hyogo College of Medicine, Nishinomiya, Japan

**Introduction:** Cholangiocarcinoma (CC) is an epithelial cancer originating from the bile ducts with features of cholangiocyte differentiation. It is the second most common primary hepatic malignancy with a poor prognosis and there is no molecular targeting drug in available. A common pathological feature of CC is abundant fibrous stromal formation which consists of extracellular matrix deposition, fibroblasts. Therefore, a new strategy for targeting fibroblasts as well as CC cells is necessary. Recently a novel Focal Adhesion Kinase (FAK) inhibitor is available. In the present study, we investigated the expression of FAK in CC tissues and the effect of a FAK inhibitor on function of CC cell line cells and a cell line of liver fibroblasts.

**Material and Methods:** Expression of FAK in human CC tissues was studied by immunohistochemistry. To identify fibroblasts in the stroma expressing FAK, double immunofluorostaining with ASMA was performed under confocal microscopy. Expression of FAK in RBE and SSP25 cells, human cholangiocellular carcinoma cell lines, LX-2 cells, a human cell line of liver myofibroblasts was investigated by western blot. FAK activity was inhibited by a novel FAK inhibitor, 1,2,4,5- Benzenetetraamine tetrahydrochloride (BTTC) which inhibits main autophosphorylation site (Y397) of FAK. Cell number was assayed by Alamar Blue assay kit. Migration ability was assayed by Matrigel-coated culture insert system.

**Results:** Immunohistochemistry and congocal microscopy indicated that FAK immunoreactivity was present in cancer cells as well as fibroblasts of human CC tissues. Expression of FAK in RBE, SSP25 cells and LX-2 cells was confirmed by western blot. BTTC (5  $\mu$ M) significantly reduced viable cell number of RBE and SSP25 cells to 70 and 42% of control, respectively. BTTC also lowered the migration activity of RBE and SSP25 cells to 52 and 42% of control, respectively. Viable cell number of LX-2 cells treated with BTTC (1.5 micro M) was significantly lower than that of control (57%).

**Conclusions:** FAK is expressed by cancer cells and fibroblasts in human CC tissues and cell lines of human CC cells and LX-2 cells. A FAK inhibitor (BTTC) may suppress cell proliferation and invasion ability of CC cells and cell proliferation of LX-2 cells. BTTC may be a molecular targeting drug for CC.

**Abstract ID: 0125**

Specific Field: **Oncology**

**Mode of pres.: Free Paper**  
**ISW 2011 Session 152.03**

**Morphological features of early gallbladder carcinoma: a review of 299 cases**



N. Nagino, T. Wakai, P.V. Korita, Y. Shirai, Y. Ajioka, K. Hatakeyama

Niigata University Graduate School of Medical and Dental Sciences, Niigata, Japan

**Introduction:** The aim of this study was to clarify the morphological features of early gallbladder carcinoma invading the lamina propria (pathologic tumor stage pT1a) or the muscle layer (pT1b).

**Material and Methods:** From 1982 through 2010, the histologic diagnosis of gallbladder carcinoma was made in 882 patients. Among these patients, 299 had early gallbladder carcinomas, which formed the basis of this retrospective study. Ultrasonography was employed in all patients. The macroscopic appearance of early gallbladder carcinoma was classified into 2 types: protruding ( $n = 107$ , 36%) or superficial type ( $n = 192$ , 64%). Protruding type was subdivided as pedunculated and sessile type, whereas superficial type was subdivided as raised, flat, and depressed type.

**Results:** Eighty-four of 107 (79%) protruding tumors were detected on preoperative imaging studies or intraoperative examination, whereas 47 of 192 (24%) superficial tumors were detected ( $P < 0.001$ ). Of 107 tumors with protruding type, 21 showed pedunculated and 86 showed sessile type. Fourteen of 21 protruding-pedunculated tumors showed carcinoma in adenoma. Seventy-six of 86 (88%) sessile tumors were accompanied with superficial type. Among 299 patients with early gallbladder carcinoma, 257 (86%) had pT1a tumors and 42 (14%) had pT1b tumors. No patient had lymphatic vessel, blood vessel, or perineural invasion on histology except that lymphatic vessel invasion was detected in one patient with pT1b tumor.

**Conclusions:** For early detection of gallbladder carcinoma, it is necessary to pay careful attention to minute mucosal changes, as two-thirds of early gallbladder carcinomas feature superficial type. Most pT1b gallbladder carcinomas spread only locally.

**Abstract ID: 0126**

Specific Field: **Oncology**

**Mode of pres.: Free Paper**  
**ISW 2011 Session 152.05**

**The association of microRNA expression with prognosis and progression in early stage, non small cell lung adenocarcinoma: a retrospective analysis of three independent cohorts**

M. Saito [1], A.J. Schetter [1], S. Mollerup [2], T. Kohno [3], S. Takenoshita [4], J. Yokota [3], A. Haugen [2], CC Harris [1]

[1] National Institute of Health, Bethesda, USA, [2] National Institute of Occupational Health, Oslo, Norway, [3] National Cancer Center Research Institute, Tokyo, Japan, [4] Fukushima Medical University, Fukushima, Japan

**Introduction:** There is increasing evidence that altered microRNA expression is associated with tumor progression and survival in cancer patients. We tested if the expression of specific microRNAs was associated with prognosis and disease progression in early stage lung adenocarcinoma.

**Material and Methods:** The expression of miR-21, miR-17 and miR-155 was measured by quantitative RT-PCR in tissues from 317 non small cell lung cancer (NSCLC) patients that originated from Maryland, Norway and Japan. Kaplan Meier and Cox regression analysis evaluated associations of microRNA expression with cancer-specific mortality and disease free survival.

**Results:** Elevated miR-21 (hazard ratio [HR] 2.06, 1.13–3.75), miR-17 (HR 2.00, 1.10–3.61), miR-155 (HR 2.37, 1.27–4.42) was associated with worse cancer-specific mortality in the Maryland cohort.

These were evaluated in two additional cohorts and only miR-21 was associated with worse cancer-specific mortality in the Norwegian cohort (HR 2.78, 1.22–6.31) and worse relapse free survival in the Japanese cohort (HR 2.82, 1.57–5.07). More advanced stage tumors expressed significantly higher levels of miR-21 compared to TNM stage I tumors. TNM stage I patients were evaluated separately and high levels of miR-21 was associated with worse cancer-specific mortality (HR 2.16, 1.11–4.21) and relapse-free survival (3.40, 1.57–7.36) independent of other clinical factors.

**Conclusions:** Increased miR-21 expression is associated with disease progression and survival in early stage lung cancer. This suggests that expression of miR-21 may contribute to lung carcinogenesis and serve as a therapeutic target or early stage prognostic biomarker for lung adenocarcinoma.

**Abstract ID: 0127**

Specific Field: **Oncology**

**Mode of pres.: Free Paper**  
**ISW 2011 Session 152.10**

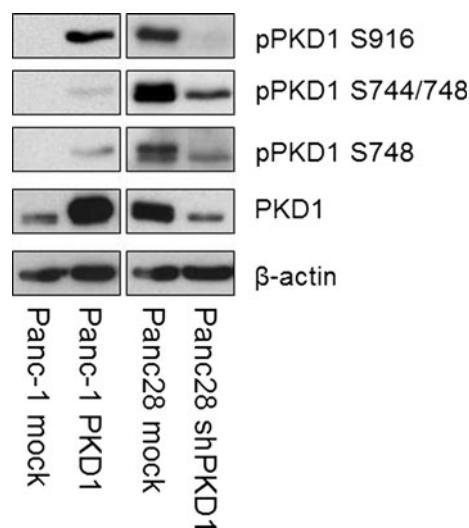
**Protein kinase D1 promotes proliferation, invasion, and angiogenesis in vitro in human pancreatic cancer cells**

N. Ochi [1], Y. Matsuo [1], Y. Okada [1], H. Takeyama [1], S. Guha [2]

[1] Nagoya City University, Nagoya, Japan, [2] MD Anderson Cancer Center, Houston, USA

**Introduction:** Protein kinase D (PKD) family was found as a new member of serine/threonine protein kinases and emerged as a key component in transduction of specific Protein kinase C (PKC) signals. However, little is known about their biological role of PKD in pancreatic cancer. We previously showed the expression of PKD1/2 in multiple pancreatic cancer cell lines. The aim of this study was to examine biological roles of PKD1 in pancreatic cancer.

**Material and Methods:** Given that Panc-1 express moderate levels of PKD1, we used retroviral mediated gene transfer to create a Panc-1 derivative that stably over-expresses PKD1 (Panc-1-PKD1). Reciprocally, we used shRNA targeting PKD1 in Panc-28 to produce a PKD1 under expressing Panc-28 derivative (Panc-28-shPKD1).



**Figure:** Western Blotting of stable cell lines

**Results:** We showed that stable PKD1 overexpression Panc-1 (Panc-1 PKD1) significantly increased anchorage-independent cell proliferation and cell invasion compared with Panc-1 mock. We demonstrated that human umbilical vein endothelial cell (HUVEC) tube formation was significantly enhanced by coculture with Panc-1 PKD1 compared with Panc-1 mock in an angiogenesis assay in vitro. These PKD1 effects were significantly inhibited by CRT0066101, which was identified as a specific inhibitor of all PKD isoforms. Using stable PKD1 under expression Panc28 (Panc28 shPKD1), we also performed the same examination.

**Conclusions:** Our results show that PKD1 plays an important role for biological consequence in pancreatic cancer. It is possible that specific PKD inhibitor becomes a novel therapeutic target for pancreatic cancer.

**Abstract ID: 0128**

**Specific Field: Oncology**

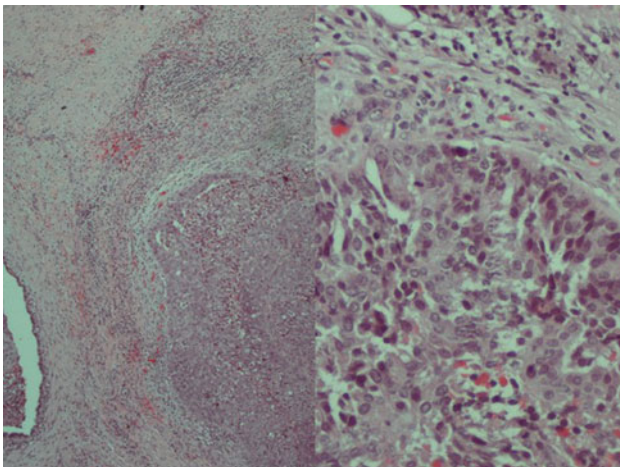
**Mode of pres.: Poster Exhibition only**  
**ISW 2011 Session PE 64**

**Sister Mary Joseph's nodule: a review of three cases**

E. Lostoridis, N. Salveridis, K. Theodosiou, N. Varsamis, G. Karageorgiou, A. Mekakas, K. Manafis, K. Pougouras

General Hospital of Kavala, Kavala, Greece

**Introduction:** Umbilical neoplastic nodules manifest cutaneous metastases that are universally referred to as "Sister Mary Joseph's Nodules" and derive mainly from the gastrointestinal or genitourinary tract and secondarily from haematological malignancies, lung or breast cancers. In 15% to 30% of cases the primary site of the tumor remains unknown. They are associated with advanced disease and a poor prognosis for the patient.



**Figure:** Lymphoid tissue with metastatic infiltrations,  $\times 40$  (left side), metastatic infiltrations

**Material and Methods:** Our material is three female patients. Two of them were admitted with the misleading diagnosis of incarcerated umbilical hernia. One was operated for bowel cancer and after six months she manifested an umbilical mass. The presented data include age, symptoms, size of nodules, timing of discovering, investigations

carried out, sites of origin of primary cancer, therapeutic options and duration of survival.

**Results:** The first 45-year-old patient underwent excision of the umbilical nodule. Pathology results revealed a non-differentiated metastatic lesion from an unidentified primary source. U/S, C.T. and P.E.T. scanning of the abdomen took place which did not reveal a primary tumor. Treatment included bilateral salpingo-oophorectomy and hysterectomy plus adjuvant chemotherapy and the patient is in a good clinical condition after 6 months. In the second 80-year-old patient U/S and C.T. scanning of the abdomen revealed a umbilical mass protruding from the peritoneal cavity, multiple hepatic metastases, enlarged bilateral iliac lymph nodes and a primary tumor of the right ovary. After refusal from the patient and due to advanced disease, age and poor prognosis no treatment was applied. The third patient was a 75-year-old woman who diagnosed and operated for carcinoma of right colon in another institute. After six months she admitted in our department with diagnosis of eileus and she underwent emergency laparotomy, which revealed an umbilical mass and peritoneum metastasis. The pathology report was positive for metastatic nodule originated from colon. The patient died 2 months later. **Conclusions:** Examination and early biopsy of all umbilical lesions is recommended, in order to determine the pathological nature of them. Seasonable diagnosis of metastatic umbilical nodule combined with aggressive surgical treatment and adjuvant chemotherapy may result in better survival outcome for the patient.

**Abstract ID: 0129**

**Specific Field: Oncology**

**Mode of pres.: Poster Exhibition only**  
**ISW 2011 Session PE 65**

**B7-H3 expression in gastric cancer: a novel molecular blood marker for detecting circulating tumor cells**

T. Arigami, Y. Uenosono, T. Hagihara, N. Haraguchi, S. Ishigami, S. Natsugoe

Kagoshima University Graduate School of Medical and Dental Sciences, Kagoshima, Japan

**Introduction:** The clinical significance of B7-H3 expression in gastric cancer remains unclear, although the B7 ligand family plays a critical role in the T cell-mediated immune response. We therefore investigated B7-H3 expression as a blood marker of circulating tumor cells and determined correlations with tumor progression in patients with gastric cancer.

**Material and Methods:** B7-H3 expression in gastric cell lines was initially evaluated by immunocytochemistry. Furthermore, we used quantitative RT-PCR (qRT-PCR) to assess B7-H3 mRNA expression in four cell lines and in 95 blood specimens from patients with gastric cancer, as well as in 21 samples of peripheral blood lymphocytes from healthy volunteers.

**Results:** B7-H3 expression in cell lines was identified by immunocytochemistry and qRT-PCR. Blood specimens from patients with gastric cancer contained significantly more copies of B7-H3 mRNA than those from healthy volunteers without cancer ( $P < 0.0001$ ). Levels of B7-H3 expression significantly correlated with overall stage ( $P = 0.013$ ). The 5-year survival rate was significantly lower in patients with high B7-H3 expression than with low expression ( $P = 0.02$ ). Multivariate analysis demonstrated that B7-H3 expression was an independent prognostic factor ( $P = 0.046$ ).

**Conclusions:** Our results indicate that B7-H3 appears to be a useful blood marker for predicting tumor progression in gastric cancer.

**Abstract ID: 0130**Specific Field: **Oncology****Mode of pres.: Poster Exhibition only**  
**ISW 2011 Session PE 66****Measuring of indoleamine 2,3-dioxygenase activity during chemotherapy in patients with breast cancer**

K. Sakurai [1], Y. Hara [1], M. Hagiwara [1], S. Fujisaki [2], M. Shibata [3], K. Enomoto [1], S. Amano [1]

[1] Nihon University School of Medicine, Tokyo, Japan, [2] Fujisaki Hospital, Tokyo, Japan, [3] Fukushima Medical University, School of Medicine, Fukushima, Japan

**Introduction:** Indoleamine 2,3-dioxygenase (IDO) is activated by interferon- $\gamma$  and is the rate-limiting enzyme for tryptophan catabolism-mediated immune regulation. The up-regulation of and expression and production of the Th1-type cytokine, interferon- $\gamma$ , by T-cell can result in increased expression of IDO by non-T-cells. IDO production by syncytiotrophoblasts, macrophages, and dendritic cells has recently been demonstrated to result in the inhibition of T cell proliferation due to tryptophan depletion by this enzyme.

**Material and Methods:** We evaluated the significance of indoleamine 2,3-dioxygenase (IDO) in recurrent breast cancer during chemotherapy. IDO activity can be measured by Tryptophan (Trp)/Kynurenine (Kyn) ratio. Trp and Kyn were measured by High Performance Liquid Chromatography (HPLC). The correlations among age and Trp/Kyn ratio or immunosuppressive acidic protein (IAP) value in pre-chemotherapies or post-chemotherapies were studied.

**Results:** In under 35 years-old patients, there are no correlations between pre-chemotherapy and post-chemotherapy in IAP values and Trp/Kyn ratio. But in over 36 years-old patients, both Trp/Kyn ratio and IAP value in post-chemotherapy are higher than in pre-chemotherapy.

**Conclusions:** These results suggest that the immunological damages for the patients during chemotherapy may depends on the age of patients.

**Abstract ID: 0131**Specific Field: **Oncology****Mode of pres.: Poster Exhibition only**  
**ISW 2011 Session PE 67****Chemotherapy with capecitabine for metastatic breast cancer patients**

Y. Kawaguchi, K. Morimitu, M. Nawa, K. Nonaka, T. Takahashi, K. Yamaguchi, S. Osada, K. Yoshida

Gifu University Graduate School of Medicine, Gifu, Japan

**Introduction:** Purpose: the oral fluoropyrimidine carbamate capecitabine is a highly active and well-tolerated treatment for metastatic breast cancer (MBC). We evaluate the safety and efficacy of capecitabine in patients treated previously with anthracyclines and Taxanes.

**Material and Methods:** Between Jun 2007 and Dec 2010, Total of 36 patients with advanced or recurred breast cancer, previously treated with anthracyclines and Taxanes, received oral capecitabine 1250 mg/m<sup>2</sup> twice daily on days 1 to 14 every 21 days. In 15 patients received cyclophosphamide in combination with capecitabine on days 1 to 14.

**Results:** Total of 36 patients received at least one course of capecitabine. No patient had a complete response (CR). We observed 4

patients (11.1%) partial response (PR). 13 patients (36.1%) had stable disease (SD) for more than 6 months, for a clinical benefit (CR + PR + SD more than 6 months) of 47.2%. The median TTP based on Kaplan–Meier estimate was 8.9 months (range, 2.3–28.5 months). 8 of 36 patients (22.2%) had duration of response more than 1 year. Hand-foot syndrome was the most frequent medication-related adverse effect in 24 patient (66.6%) and 6 of patients (16.6%) developed grade 3 and 4 Toxicity. Mucositis were more frequent adverse effect in 22 patients (61.1%). Severe hematologic adverse events were seen 5 patients (13.8%). The capecitabine dose was reduced to 75% of the starting dose in 15 patients (41.7%). The adverse events leading to dose reduction were Hand foot syndrome. Severe Mucositis and leucopenia were seen in 5 of the severe Hand foot syndrome patients.

**Conclusions:** The oral fluoropyrimidine capecitabine was approved for treatment of anthracycline and taxane pretreated metastatic breast cancer based on the demonstration of high efficacy and a favorable safety profile in a pivotal trial. In our study, hand foot syndrome was the most frequent medication related adverse effect. But it improved by dose reduction during therapy.

**Abstract ID: 0132**Specific Field: **Oncology****Mode of pres.: Poster Exhibition only**  
**ISW 2011 Session PE 68****Circulating regulatory T cells in patients with pancreatic cancer**

T. Yamamoto, H. Yanagimoto, S. Satoi, H. Toyokawa, S. Hirooka, S. Yamaki, Rintaro Yui, A.-H. Kwon

Department of Surgery, Kansai Medical University, Hirakata, Osaka, Japan

**Introduction:** Regulatory T cells (Treg) can inhibit immune responses mediated by T cells. It has been shown that there is an increased proportion of Treg in several different human malignancies. The aim of this study was to evaluate the prevalence of Treg in peripheral blood mononuclear cells (PBMCs) from patients with pancreatic cancers in relation to the clinical outcome.

**Material and Methods:** Between February 2002 and January 2008, a total of 100 patients with ductal adenocarcinoma of the pancreas were recruited. Forty patients underwent pancreatectomy, and 60 had unresectable disease. The peripheral blood mononuclear cells (PBMCs) were evaluated for the proportion of CD4+CD25+(FoxP3+) T cells, as a percentage of the total CD4+ cells, by flow cytometric analysis. Actuarial overall survival rates of the patients were analyzed by the Kaplan–Meier method. Twenty healthy volunteers were served as controls.

**Results:** The percentage of Treg in pancreatic cancer patients was significantly lower than in healthy volunteers ( $P = 0.048$ ), and Treg in patients who underwent surgical resection was significantly lower than it in patients with unresectable pancreatic cancer ( $P = 0.040$ ). The patients who underwent surgical resection were divided into subgroups according to the median value of Treg (<18.27% and 18.27%). Patients with a high percentage of Treg significantly survived longer than patients with a low percentage in peripheral blood ( $P = 0.021$ , Treg < 18.27%,  $n = 20$ , 1/3 year survival: 90%/58%. Treg  $\geq$  18.27%,  $n = 20$ , 1/3 year survival: 64%/30%).

**Conclusions:** The relative increase in Treg may be related to immunosuppression and tumor progression in patients with pancreatic cancer. The immunological monitoring of Treg may be a useful practice to predict the prognosis in patients with pancreatic cancer.



**Abstract ID: 0133**Specific Field: **Oncology****Mode of pres.: Poster Exhibition only**  
**ISW 2011 Session PE 69****Tumor suppressive role of HOPX in Pancreatic carcinogenesis**M. Waraya, K. Yamashita, M. Watanabe  
Kitasato University, Sagamihara, Japan

**Introduction:** The promoter regions of many genes are populated by many CpG dinucleotides. These regions have termed CpG islands, and CpG islands are protected from methylation in normal cells. This protection is critical since methylation of CpG islands is associated with loss of expression. Many studies have demonstrated that the silencing of tumor suppressor genes associated with promoter hypermethylation is a common feature in human cancers, and serves as an alternative mechanism for loss of tumor suppressor gene function. We previously identified HOPX as a tumour suppressor gene which is silenced by CpG islands methylation in human cancers by pharmacological unmasking microarray. It is frequently methylated in esophageal, gastric, and colorectal cancer, and inhibits their aggressive phenotypes. In this study, we studied methylation level of HOPX in pancreatic cancer, and added the functional assay to answer the question whether HOPX plays an important role in pancreatic carcinogenesis.

**Material and Methods:** We investigated promoter methylation status of HOPX in 8 pancreas cancer patients and 8 pancreatic cancer cell lines. Functional studies were also performed to elucidate the effect of HOPX on cell biology.

**Results:** HOPX expression was not found in any 8 pancreatic cancer cell lines, while its expression was robustly increased in pancreatic cancer tissues by quantitative PCR assessment for mRNA levels. Surprisingly, HOPX methylation was not found in any pancreatic cancer tissues as well as the corresponding normal tissues by Q-MSP, and we further validated the result in the cloned sequence analysis, either. Immunohistochemistry revealed that HOPX was not expressed in pancreatic cancer cells, while its expression was restricted exclusively to the islet cells of Langerhans. Stable transfectants with HOPX overexpression was made. They promote G1 arrest, inhibit tumorigenic and invasive ability. These results suggest that defective HOPX expression explained uniquely aggressive phenotype of pancreatic cancer, and its overexpression of the Langerhans cells may affect pancreatic carcinogenesis.

**Conclusions:** Defective expression of HOPX, which is characterized by lack of regulation of CpG islands methylation, may explain uniquely aggressive phenotype of pancreatic cancer, and intriguingly its overexpression in the Langerhans cells may contribute to pancreatic carcinogenesis.

**Abstract ID: 0134**Specific Field: **Oncology****Mode of pres.: Poster Exhibition only**  
**ISW 2011 Session PE 70****Clinical evaluation of activating factors on circulating T cells and antigen presenting cells in patients with pancreatic cancer**

S. Hirooka, S. Sato, H. Yanagimoto, H. Toyokawa, T. Yamamoto, S. Yamaki, Rintarou Yui, A.-H. Kon

Kansai Medical University, Moriguchi Osaka, Japan

**Introduction:** Regulatory T cells (T-reg), which are potent inhibitors of an anti-tumor immune response, directory suppressed the

expression of co-stimulatory molecules B7 (CD80/86) on antigen presenting cells (APC) via the process of CD28/CTLA4. There have been few reports concerning the dynamics of T-reg and APC in patients with pancreatic cancer. The current study was designed to evaluate circulating T-reg, T-cell activation as well as APC function in patients with pancreatic adenocarcinoma.

**Material and Methods:** This study involved 20 healthy volunteers and 51 patients with pancreatic adenocarcinoma who had consulted with our department between Jan 2009 and Dec 2010. The patients were classified as followed; Stage (UICC TMN) Ia (2); Ib (3); IIa (12); IIb (5); III (11); IV (18) and pancreas head (39); body & tail (12). Blood sample was taken before treatment, and analyzed circulating CD4+/CD25+/Foxp3+ cell (Foxp3+T-reg), CD28+/CD4+ T cell (CD28+Th), CD28+/CD8+ T cell (CD28+Tc) and CD86+/Lineage-/HLA-DR+ cell (CD86+APC) using flow cytometry.

**Results:** In pancreatic cancer patients, the ratio of Foxp3+T-reg to Th was significantly higher ( $P = 0.0211$ ), but the ratio of CD28+Th to Th and CD86+APC to APC were significantly lower ( $P = 0.0281$ ,  $P = 0.0082$ ) than that in healthy volunteers. There was a significantly negative correlation between the ratio of Foxp3+T-reg and mean fluorescence intensity (MFI) of CD86 ( $R^2 = 0.215$ ,  $P = 0.0034$ ). When we compared resectable group ( $n = 25$ ) and unresectable group ( $n = 26$ ) in pancreatic cancer patients, MFI of CD28 on Th and CD28 on Tc in unresectable group was significantly lower than that in resectable group ( $P = 0.0380$ ,  $P = 0.0239$ ).

**Conclusions:** These clinical data indicates that the proportion of Foxp3+T-reg was increased and CD86 expression on APC was suppressed in peripheral blood of pancreatic cancer patients. It is thought that the T-cell activation via CD28 was inhibited as patients go to advanced stage.

**Abstract ID: 0135**Specific Field: **Oncology****Mode of pres.: Poster Exhibition only**  
**ISW 2011 Session PE 71****Identification of malignant factors and prognostic factors for the patients with IPMN**

S. Hirono [1], M. Tani [1], M. Kawai [1], K. Okada [1], M. Miyazawa [2], A. Shimizu [1], K. Uchiyama [1], H. Yamaue [1]

[1] Wakayama Medical University, Wakayama, Japan, [2] Wakayama Medical University, Japan

**Introduction:** Noninvasive intraductal papillary mucinous neoplasm (IPMN) has favorable prognosis, however, the prognosis of invasive intraductal papillary mucinous carcinoma (IPMC) is poor. Predictive factors for differentiating IPMC from benign IPMN are required for the appropriate treatment.

**Material and Methods:** 200 patients with IPMN underwent surgery from 2000 to 2010 at Wakayama Medical University Hospital, in which the histological confirmation was adenoma in 79, carcinoma in situ in 45, and invasive carcinoma in 76 patients. We analyzed the clinicopathological data, and overall survival in the patients with IPMN.

**Results:** We identified malignant predictive factors for branch type and main duct type IPMN separately by comparing between benign IPMN and malignant IPMC (CIS and invasive IPMC). We found 2 independent malignant factors for branch type IPMN by comparing benign IPMN ( $n = 44$ ) with malignant IPMC ( $n = 63$ ) in multivariate analysis: mural nodule size  $>5$  mm ( $P < 0.01$ , odds ratio; 11.5) and the CEA level in the pancreatic juice  $>30$  ng/ml ( $P < 0.01$ , odds ratio; 55.6). For main duct type IPMN (35 benign IPMN vs. 58 malignant IPMC), we found that the CEA level in the pancreatic juice



>70 ng/ml was only independent malignant predictor in multivariate analysis ( $P < 0.01$ , odds ratio; 7.7). Only 1 patient died of disease among 124 patients with noninvasive IPMN, whereas the median survival of the 76 patients with an invasive component was 32 months ( $P < 0.01$ ).

**Conclusions:** The present study indicated that the measurement of mural nodule and a CEA level in the pancreatic juice should be considered in the diagnosis of IPMC. The most important strategy for IPMN is to resect tumors as soon as developing CIS, because the prognosis of invasive IPMC is poor.

**Abstract ID: 0136**

Specific Field: **Oncology**

**Mode of pres.: Poster Exhibition only**  
**ISW 2011 Session PE 72**

**The effects of n-6 polyunsaturated fatty acid on pancreatic cancer cell proliferation and invasion**

H. Funahashi, Y. Matuo, Y. Okada, M. Kimura, Y. Kuwabara, H. Takeyama

Nagoya City University, Nagoya, Japan

**Introduction:** Epidemiologic studies suggest that polyunsaturated fatty acids (PUFAs) possess tumor activity. The aim of the present study was to evaluate the effects of AA, as well as of PGE<sub>2</sub>, on the proliferation of pancreatic cancer cells in vitro.

**Material and Methods:** We used four pancreatic cancer cell lines (BxPC-3, MIA PaCa-2, HPAF-II, and Panc-1). The proliferative and invasive activities of pancreatic cancer cells were determined by cell count, MTT assay, and Matrigel Double Chamber Assay. Western blotting showed the presence of COX-2 or EP receptors. We used antibodies or antagonists of COX-2 or EP receptors to determine the inhibition effects on pancreatic cancer cells. We examined intracellular cAMP levels by ELISA.

**Results:** AA dose-dependently increased the growth of pancreatic cancer cells as determined by the MTT assay and cell count and stimulated cell invasion as measured by the Matrigel invasion assay. This effect was restricted to pancreatic cancer cells, which expressed the COX-2 enzyme. AA dose-dependently increased PGE<sub>2</sub> production of COX-2 positive pancreatic cancer cells. PGE<sub>2</sub> dose-dependently enhanced proliferation and invasion of COX-2 positive pancreatic cancer cells. PGE<sub>2</sub> signals by binding to EP receptors, of which 4 subtypes have been described. The effects of PGE<sub>2</sub> were inhibited by a combined EP<sub>1</sub>/EP<sub>2</sub> antagonist and a selective EP<sub>4</sub> antagonist. In contrast, selective EP<sub>1</sub> and EP<sub>3</sub> antagonists had no inhibitory effect.

**Conclusions:** The n-6 PUFA AA and PGE<sub>2</sub> stimulated pancreatic cancer cell growth and invasion in vitro. The effects of PGE<sub>2</sub> were mediated by the EP<sub>2</sub> and EP<sub>4</sub> receptors.

**Abstract ID: 0137**

Specific Field: **Oncology**

**Mode of pres.: Poster Exhibition only**  
**ISW 2011 Session PE 73**

**Active enhancement of anti-tumor effect by NF- $\kappa$ B inhibitor DHMEQ using PMBN conjugated with anti-EGFR antibody in human pancreatic adenocarcinoma cells in vivo and in vitro**

H. Fujisaki [1], K. Suzuki [2], S. Matsuda [1], K. Aiura [1], H. Yagi [1], O. Itano [1], M. Ueda [1], Y. Kitagawa [1]

[1] Keio University Hospital, Tokyo, Japan, [2] Kitasato Institute Hospital, Tokyo, Japan

**Introduction:** DHMEQ inhibits NF- $\kappa$ B activity by preventing nuclear translocation and has been shown anti-tumor effect. However, because of its hydrophobic property, DHMEQ has to be administered intraperitoneally or subcutaneously every day. Therefore, we have used PMBN polymer, which forms a stable polymer aggregate in water that can enhance the solubility of hydrophobic substance such as DHMEQ. The active ester group of PMBN can be replaced by proteins such as anti-epidermal growth factor receptor (EGFR) antibody. The aim of this study is that investigate active enhancement of anti-cancer effect by DHMEQ using PMBN.

**Material and Methods:** The human pancreas adenocarcinoma cell lines, AsPC-1, BxPC-3, MIA PaCa-2, which showed high expression level of EGFR were used in vitro study. DHMEQ, PMBN and mouse monoclonal anti-human EGFR antibody (528) were mixed and sonicated to prepare PMBN-DHMEQ antibody conjugate in advance. Control DHMEQ was dissolved in 0.5% chrolomethylcellulose (CMC-DHMEQ). The effect of cytotoxicity by each preparation was evaluated by WST assay in vitro. AsPC-1 cells which expressing Gaussia luciferase (AsPC-1-Luc) was used to investigate anti-tumor effect in vivo.  $5 \times 10^5$  of AsPC-1-Luc was injected into nice portal vein to develop liver metastases model of pancreatic cancer. Mice were given PMBN-DHMEQ antibody conjugate (intravenously) or CMC-DHMEQ (intraperitoneally) every three days at a dose of 12 mg/kg DHMEQ. Metastases level of each group was compared by measuring luciferase activity of mice whole liver homogenate using Renilla Luciferase Assay System (Promega).

**Results:** PMBN-DHMEQ antibody conjugate showed higher cytotoxicity effect than CMC-DHMEQ in vitro WST assay. Also it showed stronger growth inhibition effect than CMC-DHMEQ in vivo. Quantitative luciferase assay showed that PMBN-DHMEQ antibody conjugate have 49.2 times higher effect compare to CMC-DHMEQ.

**Conclusions:** Our results demonstrate that the PMBN-DHMEQ-anti-EGFR antibody conjugate can efficiently decrease cancer development of cells overexpressing EGFR by an active enhancement effect. This result suggest that increased accumulation of PMBN-DHMEQ anti-EGFR antibody conjugate increased tumor concentration of DHMEQ and the therapeutic response.

**Abstract ID: 0138**

Specific Field: **Oncology**

**Mode of pres.: Poster Exhibition only**  
**ISW 2011 Session PE 74**

**Combined therapy in advanced gastrointestinal stromal tumors (GIST)**

C. Osuch, J. Kulig

Jagiellonian University, Krakow, Poland

**Introduction:** Gastrointestinal stromal tumors (GIST) are uncommon mesenchymal neoplasms with malignant potential and positive reaction to CD 117(C-KIT) antigen or PDGFRA. They arise from the interstitial Cajal cells. Between 2001–2010, 89 patients with GIST were treated at our Department of Surgery. Of these, 37 (41%) patients with advanced GIST received combined treatment with imatinib (Glivec) in a dose of 400 mg/24 h increased to 800 mg/24 h, if necessary.

**Material and Methods:** A group consisted of 18 women (48.64%) and 19 men (51.35%) with intraperitoneal spread of GIST or liver metastases. Mean age of the patients was 53 years. Mitotic activity in the analyzed group was 5-78/50 HPF. Primary localization of GIST was: stomach—21 (56.76%) including 5 patients with multifocal lesions, small intestine—8 (21.62%), colon—3 (8.11%), rectum—2 (5.41%), small intestine mesentery—2 (5.41%), retroperitoneal

space—1 (2.69%) . In 5 (13.51%) cases synchronous GIST was detected, i.e. gastric stromal tumor and sigmoid stromal tumor (acc. to Aster Coller B2), gastric stromal tumor with pancreatic head cancer in 1 case, sigmoid stromal tumor and carcinoid tumor of the transverse colon in 1 case, and Carney’s triad in 39-year-old male (GIST, pheochromocytoma, lung chondroma). Mutations of all patients have been assessed. All patients were treated with surgery combined with adjuvant chemotherapy.

**Results:** Complete response (CR) to treatment was obtained in 3 (8.10%) patients, partial response (PR) in 15 (40.54%), stable disease (SD) in 14 (37.85%). Disease progress (PD) was observed in 5 (13.51%) patients two – three years after imatinib chemotherapy. Imatinib therapy was well-tolerated with low number of complications. In the patients with disease progress chemotherapy was continued with sunitinib (Sutent) in a dose of 37.5 mg/24 h and after with different inhibitors of tyrosine kinase.

**Conclusions:** Only combined surgery with targeted chemotherapy with tyrosine kinase inhibitors (or other new inhibitors) allows to significantly improve treatment results in the patients with advanced gastrointestinal stromal tumors. Detailed assessment of mutations gives us an ability to achieve accurate and successful chemotherapy in cases of GIST progression.

investigate the optimal distal resection margin of rectal cancer by considering the surgical survival benefits.

**Material and Methods:** This retrospective study involved 413 consecutive patients with stage I-IV rectal cancer. Both intramural and mesorectal DS were investigated, and the maximum length of DS was measured. The clinical impact of DS was evaluated by univariate and multivariate analyses.

**Results:** DS was detected in 60 patients (14.5%). Both the incidence and the maximum extent of DS were increased according to the TNM stage. The maximum extents of DS were 4, 19, 35, and 38 mm in Stage I, II, III, and IV, respectively. Although univariate analyses revealed that DS was a significant factor in five-year overall survival and five-year local recurrence, multivariate analyses established that DS was not an independent prognostic factor for these outcomes.

**Conclusions:** The prognosis of patients with DS is not much worse. These results indicate that the complete clearance of DS may contribute to an improvement in the prognosis and local control. In the present study, we have shown that to perform sphincter-saving surgery more aggressively without lack of disease curability, the distal resection margin of rectal cancer patients can be reduced theoretically to 1, 2, 3, and 4 cm in stage I, II, III, and IV disease, respectively.

**Abstract ID: 0139**

**Specific Field: Oncology**

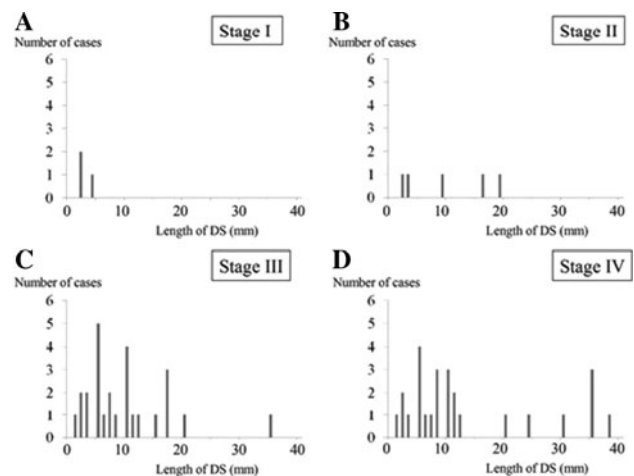
**Mode of pres.: Poster Exhibition only**  
**ISW 2011 Session PE 75**

**Intramural and mesorectal distal spread detected by whole-mount sections and optimal resection margin in rectal cancer patients without preoperative therapy**

Y. Shimada [1], Y. Takii [2], S. Maruyama [2]

[1] Department of Digestive and General Surgery, Niigata University Graduate School of Medical and Dental Sciences, Niigata, Japan, [2] Department of Surgery, Niigata Cancer Center Hospital, Niigata, Japan

**Introduction:** In the earlier reports, patients with distal spread (DS) are not an unusual and show poor prognosis. There is no consensus on whether a longer resection of the distal margin for complete clearance of DS improves the prognosis of patients with DS. Our purpose was to



**Figure:** Length of distal spread and number of patients in each TNM stage

Univariate and multivariate analysis of possible prognostic factors for 5-year overall survival

		Univariate analysis			Multivariate analysis	
		No. cases	5-year over-all survival (%)	<i>P</i> value	Hazard ratio (95% CI)	<i>P</i> value
Tumor stage	T1, 2	138	96.7	<0.001	1	< 0.01
	T3, 4	275	70.1			
Nodal involvement	Negative	202	90.6	<0.001	1	0.21
	Positive	211	67.2			
Distant metastasis	Negative	356	86.0	<0.001	1	< 0.01
	Positive	57	29.3			
Circumferential resection margin	Negative	390	81.3	<0.001	1	0.04
	Positive	23	25.9			
Distal spread	Negative	353	84.3	<0.001	1	0.20
	Positive	60	47.6			

**Abstract ID: 0140**Specific Field: **Oncology****Mode of pres.: Poster Exhibition only**  
**ISW 2011 Session PE 76****Fluorescence diagnosis of lymph node metastases in mouse rectal cancer after 5-aminolevulinic acid administration**

Y. Murayama, Y. Kokuba, E. Otsuji

Kyoto Prefectural University of Medicine, Kyoto City, Japan

**Introduction:** Accurate diagnosis of lymph node (LN) metastasis is essential for designing therapeutic strategies and predicting outcomes of gastrointestinal cancer patients. In this research, we evaluated the diagnostic usefulness of 5-aminolevulinic acid (5-ALA) for metastatic LN of rectal cancer in mice.**Material and Methods:** We studied colorectal cancer cell lines, isolated cells from normal mouse LNs, and also mouse model bearing rectal cancer with LN metastases after 5-ALA administration.**Results:** In vitro study, confocal images showed that all colorectal cancer cell lines were positive for 5-ALA-induced protoporphyrin IX (PPIX) fluorescence, but normal LN cells were negative. In vivo study, LN metastases were visualized after 5-ALA administration. And this method of 5-ALA-induced fluorescence imaging detected occult nodal metastases not identified by H-E staining. Furthermore, macroconfocal images clearly revealed PPIX-fluorescence-positive cancer cells in lymph vessels. The result of this method after 5-ALA administration corresponded with real-time RT-PCR method.**Conclusions:** The results show that fluorescence diagnosis with 5-ALA is accurate and suitable in the detection of LN micrometastases of mouse rectal cancer model.**Abstract ID: 0141**Specific Field: **Oncology****Mode of pres.: Poster Exhibition only**  
**ISW 2011 Session PE 77****Antitumor effects of a new  $\alpha$ -lipoic acid derivative, DHL-HisZnNa, are mediated by G1 cell cycle arrest in HT29 human colon cancer cells**

Y. Kono, M. Inomata, T. Hiratuka, T. Masuda, T. Hirashita, F. Yoshizumi, N. Shiraiishi, S. Kitano

Oita University Faculty of Medicine, Yufu, Oita, Japan

**Introduction:** Recently,  $\alpha$ -lipoic acid and its reduced form, dihydro-lipoic acid, have been reported to induce apoptosis in cancer cells in several cancer cell lines. However,  $\alpha$ -lipoic acid is prone to oxidation, polymerization, and desulfurization, and is insoluble in water. Our group, while searching for a more stable, water-soluble compound, synthesized sodium *N*-(dihydro-lipooyl)-L-histidinate zinc complex (DHL-HisZnNa), which can eliminate active oxygen species. We evaluated the antitumor action of a new  $\alpha$ -lipoic acid derivative, DHL-HisZnNa, on human colon cancer cell HT29 in vitro and in vivo.**Material and Methods:** We investigated whether DHL-HisZnNa elicits its anti-tumor effects by inducing apoptosis and cell cycle arrest on human colon cancer cell line HT-29.**Results:** DHL-HisZnNa inhibited cancer cell growth in cell culture and in a colon cancer xenograft model in rats. Cell cycle analysis by flow cytometry showed a time-dependent accumulation of HT-29 cells in the G1 phase after exposure to 0.5 mM of DHL-HisZnNa. However, analysis of DNA fragmentation did not reveal evidence of apoptosis after exposure to DHL-HisZnNa. Cells treated with DHL-HisZnNa showed a 2-fold increase in p53 phosphorylation at 6 h with

the Bio-Plex Phosphoprotein Assay. Moreover, DHL-HisZnNa increased protein levels of the CDK inhibitor p21 and decreased that of phosphorylated Rb by western blot analysis.

**Conclusions:** These antitumor effects were associated with induction of G1 cell cycle arrest and phosphorylation of p53 and p21 proteins. This is the first study to report the antitumor effects of DHL-HisZnNa and the molecular mechanisms by which it inhibits growth of human colon cancer cell HT29.**Abstract ID: 0142**Specific Field: **Oncology****Mode of pres.: Poster Exhibition only**  
**ISW 2011 Session PE 78****A case of advanced transverse colon cancer achieving pathological complete response by TS-1 + oxaliplatin chemotherapy**

Y. Kaneko, Y. Inoue, M. Yamamoto

Tokyo Women's Medical University, Tokyo, Japan

**Introduction:** We describe a 59-year-old man who presented with advanced transverse colon cancer with aortic lymph node and multiple lung metastases. The patient underwent operation because of stenosis of the colon. Perioperatively, the tumor could not be resected as it deeply invaded the transverse colon tissue, and therefore ileo-sigmoidostomy was performed. Postoperatively, the patient received chemotherapy consisting of TS-1 (80 mg/m<sup>2</sup>/day for 2 weeks with 2 weeks rest) + oxaliplatin (85 mg/m<sup>2</sup> on days 1 and 15). After 4 chemotherapy courses, a partial response was observed by CT scan, and the aortic lymph node and lung metastases disappeared. Thereafter, the transverse colon was resected, and postoperative pathological examination of the resected transverse colon and lymph nodes showed no residual cancer. As the changes induced by chemotherapy were considered Grade 3, radical operation could be performed in this case. In conclusion, we encountered a case of advanced colon cancer achieving pathological complete response by TS-1 + oxaliplatin chemotherapy.**Abstract ID: 0143**Specific Field: **Oncology****Mode of pres.: Poster Exhibition only**  
**ISW 2011 Session PE 79****Histologic evaluation of intraepithelial spread along the bile ducts for discrimination between colorectal carcinoma liver metastasis and intrahepatic cholangiocarcinoma**

M. Inoue, T. Wakai, Y. Shirai, J. Sakata, P.V. Korita, Y. Ajioka, K. Hatakeyama

Niigata University Graduate School of Medical and Dental Sciences, Niigata, Japan

**Introduction:** Colorectal carcinoma liver metastasis (CRLM) tends to spread superficially along the epithelium of the intrahepatic bile ducts, mimicking primary intrahepatic cholangiocarcinoma (ICC). This study aimed to evaluate the usefulness of immunohistochemical combinations for discrimination between intraepithelial ductal spread of CRLM and that of ICC.**Material and Methods:** A retrospective analysis of resected specimens from 151 patients with CRLM and 28 patients with ICC was conducted.

Intraepithelial spread along the bile ducts from CRLM was judged positive when tumor cells spreading along the intact basement membranes of intrahepatic bile ducts replaced non-neoplastic biliary epithelium. High-grade dysplasia and carcinoma in situ were treated as intraepithelial spread of ICC. We evaluated immunoreactivity of cytokeratin (CK) 7, CK20, CDX2, MUC2, MUC5AC and human gastric mucin focused on intraepithelial spread along the bile ducts.

**Results:** Of the 151 patients with CRLM, 21 had intrahepatic bile duct involvement verified histologically. Intraepithelial ductal spread was detected in 17 of 21 (81%) patients with CRLM with bile duct involvement, whereas it was detected in 22 of 28 (79%) patients with ICC. CDX2-positive/CK7-negative immunophenotype demonstrated the highest diagnostic accuracy of 97% for evaluation of intraepithelial spread from CRLM, whereas the accuracy of CK20-positive/CK7-negative immunophenotype was 95%. CK7-positive/CK20-negative immunophenotype demonstrated the highest accuracy of 85% for evaluation of intraepithelial ductal spread from ICC, whereas the accuracy of CK7-positive/CDX2-negative immunophenotype was 77%.

**Conclusions:** Intraepithelial ductal spread along the bile ducts is a common feature of CRLM with bile duct involvement. Immunohistochemical combination of CK7 and CK20 is useful for discrimination between intraepithelial ductal spread of CRLM and that of ICC.

**Abstract ID: 0144**

Specific Field: **Oncology**

**Mode of pres.: Poster Exhibition only**  
**ISW 2011 Session PE 80**

**The alpha-lipoic acid derivative, sodium zinc dihydrolipoylhistidinate (DHLHZn), reduces chemotherapy-induced alopecia in a rat model**

M. Inomata, Y. Kono, T. Hiratsuka, F. Yoshizumi, N. Shiraiishi, S. Hagiwara, T. Noguchi, S. Kitano

Oita University Faculty of Medicine, Oita, Japan

**Introduction:** Alopecia is one of the most common side effects of chemotherapy. In the present study, we evaluated the effects of sodium zinc dihydrolipoylhistidinate (DHLHZn), a new derivative of the multifunctional antioxidant alpha-lipoic acid, to treat chemotherapy-induced alopecia.

**Material and Methods:** Wistar rats (8-day-old) were cotreated with cytosine arabinoside (AraC; 20 mg/kg by daily intraperitoneal injection; day 0–day 6) and DHLHZn (0%, 0.5%, or 5% topically applied in a white petrolatum base; day 0–day 12). A control group received daily saline injections (day 0–day 6) and topical application of white petrolatum (day 0–day 12). At day 12, we evaluated hair loss and histologic changes to scalp tissue for each group ( $n = 10$ ).

**Results:** Rats treated with AraC and 0% DHLHZn cream exhibited complete hair loss; however, cotreatment with 0.5 or 5% DHLHZn significantly reduced chemotherapy-induced hair loss. Histologic analysis revealed that AraC treatment promoted inflammatory cell infiltration of hair follicles, but this inflammatory response was attenuated by DHLHZn.

**Conclusions:** Our findings demonstrate that DHLHZn attenuates chemotherapy-induced alopecia, indicating the potential use of this alpha-lipoic acid derivative as a therapeutic tool against this common side effect of chemotherapy.

**Abstract ID: 0145**

Specific Field: **Oncology**

**Mode of pres.: Poster Exhibition only**  
**ISW 2011 Session PE 81**

**In vitro pemetrexed sensitivity according to histological type in non-small cell lung cancer**

T. Yoshida, T. Yano, K. Ito, Y. Morodomi, T. Kameyama, Y. Shikada, R. Maruyama, Y. Maehara

Kyushu University, Fukuoka, Japan

**Introduction:** Pemetrexed (Alimta®) is a new multitarget antifolate metabolite anticancer drug. Non-small cell lung cancer is now treated with selective chemotherapy based on its classification as either non-squamous cell carcinoma or squamous cell carcinoma. This study was designed to investigate both the relationship between the histological type and in vitro chemosensitivity to pemetrexed and its mechanism of action in patients with non-small cell lung cancer.

**Material and Methods:** Fifty-one non-small cell lung cancer samples (39 adenocarcinoma and 12 squamous cell carcinoma) were used. Chemosensitivity was assessed by the succinate dehydrogenase inhibition (SDI) test for three anti-metabolic anti-cancer agents, including pemetrexed, 5-FU, gemcitabine. Samples showing more than 70% of succinate dehydrogenase (SD) activity, which, reflects the cell viability, were defined as 'resistant' and samples showing less than 70% of SD activity are 'sensitive' in comparison to the values without drugs. The expression levels of TS mRNA were measured by reverse transcriptase polymerase chain reaction analysis to examine the influence of thymidylate synthase (TS) on pemetrexed sensitivity.

**Results:** Pemetrexed was the only agent that showed a difference in chemosensitivity between adenocarcinoma and squamous cell carcinoma. Eleven of 12 squamous cell carcinoma samples showed resistance to pemetrexed. Clinicopathological factors (sex, smoking, EGFR mutation) did not affect the sensitivity to pemetrexed. The expression levels of TS mRNA are higher in squamous cell carcinoma than that of adenocarcinoma. However, the expression levels of TS mRNA in adenocarcinoma were not related to sensitivity to pemetrexed. This suggests that factors other than TS affect the sensitivity to pemetrexed.

**Conclusions:** Although squamous cell carcinoma showed resistance to pemetrexed as same that was comparable to the clinical results, no apparent relationship between pemetrexed sensitivity and TS expression was observed.

**Abstract ID: 0146**

Specific Field: **Oncology**

**Mode of pres.: Poster Exhibition only**  
**ISW 2011 Session PE 82**

**Clinicopathological study of Primary Superficial Leiomyosarcomas**

C. Burusapat [1], K. Satayasontorn [2]

[1] Phramongkutklao Army Hospital, Bangkok, Thailand, [2] Army Institute of Pathology, Bangkok, Thailand

**Introduction:** Primary Superficial Leiomyosarcomas (PSL) were rare malignant lesions and divided into cutaneous and subcutaneous tumors. Primary cutaneous and subcutaneous leiomyosarcomas were



## Clinicopathological and Immunohistochemistry study

	Case 1	Case 2	Case 3	Case 4	Case 5
Age/sex	39/M	2/F	52/M	35/M	84/M
Clinical	Painless mass 1 year	Intermittent bleeding mass 2 years	Painless mass 6 months	Painless mass 2 months	Painless mass 1 year
Location	Right cheek	Right back	Left thigh	Left hip	Left neck
Treatment	Excision	Excision	Wide excision	Wide excision	Wide excision
Adjuvant	No	No	Radiotherapy	No	Radiotherapy
Follow up	Lost follow up	1 year	6 months	2 years	3 years
Recurrence	No	No	No	No	No
Metastasis	spine	No	No	No	No
Mitosis/10 HPF	18	2	6	12	15
Necrosis	20%	–	–	10%	10%
FNCLCC Grd	2	1	2	2	3
SMA	+	+	+	+	+
Desmin	N/A	–	N/A	+	+
MSA (HHF35)	N/A	+	N/A	N/A	N/A
Vimentin	+	N/A	+	N/A	N/A

not only to difference in primary site of origins, but also to differences in prognosis. Guidelines for management and follow up were not clearly defined.

**Material and Methods:** Retrospective review between January 2000 and December 2009. Histopathology and immunohistochemistry were reviewed. Clinical and surgical records were reviewed for age, sex, symptoms, location, recurrence, metastasis and treatments.

**Results:** In period of 10 years review, we found five cases of PSL and divided into two cases of cutaneous leiomyosarcomas and three cases of subcutaneous leiomyosarcomas. Mean age was 42.4 years (2–84 years). Male: female ratio was 4:1. Clinical presentation were painless mass. One case presented with intermittent bleeding. Wide excision were performed in 3 cases with 2 cm margins. No local recurrence in the period of follow up (6 months–3 years). One case presented with bony metastasis 5 years after operation. Two cases of subcutaneous leiomyosarcomas received post operative radiotherapy because tumors closely to margins.

**Conclusions:** PSL were rare tumor. Cutaneous leiomyosarcoma and subcutaneous leiomyosarcoma differ microscopically and primary site of origin. Guideline for treatments and follow up were not clearly defined. Surgical resection has still the main option for curative treatment. Wide excision with at least 2 cm lateral margins was recommended. Natural history was not exactly clearly defined All patients should be followed up at least 5 years after treatments. Herein, we hoped that our cases will be benefit in treatment and follow up in the future.

**Abstract ID: 0147**

Specific Field: **Oncology**

**Mode of pres.: Poster Exhibition only**  
**ISW 2011 Session PE 83**

**Impact of the location of metastatic lymph nodes on survival of esophageal squamous cell carcinoma**

H. Tanaka, M. Ohira, N. Kubo, K. Muguruma, M. Yashiro,  
N. Yamada, K. Maeda, K. Hirakawa

Osaka City University Graduate School of Medicine, Osaka, Japan

**Introduction:** The presence of lymph node (LN) metastasis in patients with esophageal squamous cell carcinoma (ESCC) has important prognostic implications. Especially, patients with resectable cStage II/III esophageal carcinoma have often caused lymph nodes metastases. Some recent studies have addressed the association between prognosis and the number of metastatic LNs. However, these studies did not focus on assessing the significance of the location of LN metastasis sampled on survival. In the current study, we examined for the association between postoperative recurrence and the location of metastatic LNs among patients with clinical stage II/III ESCC.

**Material and Methods:** We retrospectively reviewed the clinical data of 90 patients with clinical stage II/III ESCC who underwent curative esophagectomy accompanied with systemic lymphadenectomy at Department of Surgical Oncology in Osaka City University Hospital from 2000 to 2007.

**Results:** Of 90 patients, we identified 49 recurrences and 37 deaths during follow-up. Using Cox regression model, UICC pathological stage, pathological intramural metastasis, total number of metastatic LNs, number of involved upperparaesophageal LNs, subcarinal LNs, lower paraesophageal LNs, post mediastinal LNs, perigastric LNs, and celiac LNs were significantly associated with recurrence free survival (RFS) in univariate analysis. In multivariate analysis, the number of involved subcarinal and lower paraesophageal LNs were independent factors predictive of postoperative recurrence. Profile of metastatic LNs was not associated with pattern of recurrence.

**Conclusions:** The strongest predictors for recurrence in cStage II/III esophageal SCC were the numbers of metastatic subcarinal LNs and lower paraesophageal LNs. Our findings suggested that patients who had metastatic lymph nodes at these locations were at risk for recurrence and may be considered for more aggressive adjuvant therapies.

**Abstract ID: 0148**

Specific Field: **Oncology**

**Mode of pres.: Poster Exhibition only**  
**ISW 2011 Session PE 84**

**Expression of VEGF-C & VEGFR-3 in esophageal squamous cell carcinoma was correlated with tumor lymphangiogenesis**

I. Omoto, M. Matsumoto, S. Natsugoe, H. Okumura, Y. Uchikado, T. Setoyama, Y. Kita, S. Ishigami

Department of Surgical Oncology and Digestive Surgery, Kagoshima University Graduate School of Medical and Dental Sciences, Kagoshima, Japan

**Introduction:** Esophageal cancer is one of the most aggressive gastrointestinal cancers, because of the existence of metastasis even at the early stage. Especially the lymph node metastasis is the most important prognostic factor. It has been reported that VEGF-C and VEGF-D induce not only angiogenesis but also lymphangiogenesis via VEGFR-2 and VEGFR-3 on lymphatic endothelial cells. They regulate lymphangiogenesis and enhance lymphatic metastasis. In addition, it has been recently reported that VEGF-C and VEGFR3 known as a marker for lymphatic endothelial cells, expressed on tumor cells correlate with invasion, metastasis and progression of cancer cells.

**Material and Methods:** One hundred twenty-one patients with ESCC (110 males and 11 females) who underwent curative esophagectomy with lymph node dissection were enrolled in this study. Expression of VEGF-C, VEGFR-3 and D2-40 were examined immunohistochemically. Microlymphatic vessel density (MLVD) was calculated by the count of D2-40 expression and examined the relationship between the expression and various clinicopathological factors.

**Results:** Positive expression of VEGF-C was significantly correlated with depth of tumor invasion, lymphatic invasion, and lymph node metastasis ( $P < 0.001$ ,  $P < 0.0001$ , and  $P < 0.0001$ , respectively). Moreover, patients with deeper tumor invasion had higher positivity of VEGFR-3 expression ( $P < 0.05$ ), while patients with lymph node metastasis had higher MLVD ( $P < 0.05$ ). When divided patients into three groups according to the expression of VEGF-C and VEGFR-3, patients with both expression of VEGF-C and VEGFR-3 had poorer prognosis, showing higher MLVD.

**Conclusions:** VEGF-C expression is an important factor for tumor lymphangiogenesis. In particular VEGF-C/VEGFR-3 axis is correlated with lymphangiogenesis and prognosis. The VEGF-C/VEGFR-3 axis may become a therapeutic target for cancer metastasis.

**Abstract ID: 0149**

Specific Field: **Oncology**

**Mode of pres.: Poster Exhibition only**  
**ISW 2011 Session PE 85**

#### Identification of microRNAs which are differentially expressed in p75NTR-positive esophageal squamous cell carcinoma

T. Okumura, Y. Shimada, S. Osawa, S. Sekine, M. Moriyama, T. Omura, K. Tsukada

Department of Surgery and Science, Graduate School of Medicine and Pharmaceutical Science, University of Toyama, Toyama, Japan

**Introduction:** We have reported that a candidate stem cell fraction in cultured esophageal keratinocytes was characterized by the expression of the low affinity neurotrophin receptor p75NTR (Oncogene 2003). Studies in human esophageal squamous carcinoma (ESCC) revealed that p75NTR is expressed in the actively proliferating, undifferentiated cell component of the tumors and investigation using ESCC cell lines demonstrated that p75NTR is intensely expressed in a small number of cells with high colony forming capacity (Clinical Cancer Research 2006). MicroRNAs are small noncoding RNAs that repress target messenger RNAs through an antisense mechanism and play a role in development and progression of cancer. The aim of our recent study is identification of microRNAs which are differentially expressed in p75NTR-positive ESCC.

**Material and Methods:** We obtained Formalin-Fixed Paraffin Embedded (FFPE) sections of ESCC from 8 patients who underwent esophagectomy. The expression of p75NTR was immunohistochemically detected. RNA was extracted from FFPE sections and the expression of microRNAs was assessed by microarray. The expression of microRNAs in p75NTR-positive and -negative human ESCC cell lines (KYSE790 and KYSE50, respectively) was assessed by Real-time PCR. miRNA expression vector was transfected into KYSE790 and the expression of p75NTR was detected by immunocytochemistry.

**Results:** p75NTR was expressed in 4 of 8 ESCC specimens. Histology of the specimens was well: 1, mod: 1, and poor: 2 in both p75NTR positive and negative cases. The expression of Let-7, miR-1274, and miR-143 was up-regulated with more than two fold increase in p75NTR positive cases than negative cases. On the other hand, the expression of miR-203 and miR-634 was down-regulated with less than half decrease in p75NTR positive cases than negative cases. The expression of let-7 and miR1274 was significantly up-regulated, while miR-203 and miR-634 was down-regulated in KYSE790, compared to KYSE50. Induction of miR203 expression into ESCC cell lines resulted in down regulation of p75NTR expression in vitro.

**Conclusions:** It is suggested that miR203 has a role in maintenance of p75NTR positive cells in ESCC and can be a candidate therapeutic target.

**Abstract ID: 0150**

Specific Field: **Oncology**

**Mode of pres.: Poster Exhibition only**  
**ISW 2011 Session PE 86**

#### Risk assessment of gastrointestinal stromal tumor by FDG PET

K. Shuto [1], K. Narushima [1], H. Matsubara [1], S. Okazumi [2]

[1] Frontier Surgery, Chiba University Graduate School of Medicine, Chiba, Japan, [2] Toho University Sakura Medical Center, Sakura, Japan

**Introduction:** In the treatment of gastrointestinal stromal tumor (GIST), risk assessment is made by CT, EUS and fiberoptic findings especially according to the morphologic status of the tumor. The purpose of this study is to investigate the biological malignant potential of GIST by FDG positron emission tomography and to compare with histological results.

**Material and Methods:** Forty-five patients who underwent surgical resection were enrolled (esophagus 4, stomach 34, ileum 4 and rectum 3; mean size 5.0 cm, range 2.0–30 cm). Prior to surgery, PET imaging was performed after injection of 370 MBq of F18-DG tracer. Standardized uptake value (SUV) of the tumor was measured for evaluation. Histological diagnosis was made by immunohistological staining of c-kit and CD34. Risk groups were estimated by assessing tumor size and mitotic rate (MR) per 50 HPFs based on the NCCN guideline of GIST. We evaluated the relationship between SUV and risk groups.

**Results:** There was a significantly strong correlation of SUV between MR than between tumor size ( $R = 0.61$ ,  $P < 0.0001$  vs.  $R = 0.32$ ,  $P = 0.028$ ). SUV of low-risk group was  $4.0 \pm 2.1$ , intermediate-risk  $3.5 \pm 1.9$  and high-risk  $7.4 \pm 3.6$ . SUV level of high-risk group was higher than that of low and intermediate group with a statistical difference ( $P = 0.015$ ,  $0.0004$ , respectively). The cut-off SUV level of 6.0 revealed 69% sensitivity and 90% specificity in predicting high-risk group. And the cut-off SUV level of 3.0 revealed 94% sensitivity and 34% specificity in predicting low-risk group.

**Conclusions:** FDG PET may enable to predict low-risk group with high sensitivity and to discriminate high-risk group from others with high specificity. It may become one of the valid clinical modalities for evaluating risk group of GIST. However comprehensive estimation is recommended because of low sensitivity in predicting high-risk and low specificity of low-risk. FDG PET may enable to predict low-risk group with high sensitivity and to discriminate high-risk group with high specificity as a valid clinical modality to evaluate the risk group of GIST.

**Abstract ID: 0151**

Specific Field: **Oncology**

**Mode of pres.: Poster Exhibition only**  
**ISW 2011 Session PE 87**

**CD133/prominin-1 as a potential diagnosis marker for gastrointestinal stromal tumor**

H. Sako, K. Fukuda, S. Tsuwano, T. Takahashi, N. Wada, H. Takeuchi, Y. Saikawa, Y. Kitagawa

Department of Surgery, School of Medicine, Keio University, Tokyo, Japan

**Introduction:** A gastrointestinal stromal tumor (GIST) is one of the most common mesenchymal tumors of the gastrointestinal tract. They are typically defined as tumors whose behavior is driven by mutations in the *c-kit* gene or *PDGFR $\alpha$*  gene. CD133 is also known in humans and rodents as Prominin 1 (PROM1). It is the founding member of pentaspan transmembrane glycoproteins (5-transmembrane, 5-TM), which specifically localizes to cellular protrusions. In addition to hematopoietic stem and progenitor cells, CD133 has been found to be a marker for other stem and progenitor cells including neural and embryonic stem cells. It has been shown to be expressed in cancers, including some leukemias and brain tumours that may be derived from stem cells. Low level expression has also been detected in the kidney, pancreas, placenta and fetal liver. But the relation of GIST was unknown. The aim of the present study is to determine whether CD133 is expressed in GIST, a tumor of neuronal origin, and its potential suitability as a diagnostic marker for this tumor entity.

**Material and Methods:** Sixty-two surgically resected and paraffin-embedded GIST clinical samples were analyzed by immunohistochemistry with peroxidase method for CD133 molecule. A total of 62 patients suffering from GISTs were included in our study. Expression of CD133 and KIT was investigated by FACS in these specimens, cells expressed CD133 were transplanted in NOG mouse, and we compared intensity of CD133 with ability of tumor formation.

**Results:** Briefly, the average age of GIST patients was 59.4 years old (range 26–86). 59 (95.2%) GIST patients were KIT positive and 61 (98.4%) were CD34 positive. According to the consensus classification 2002 (Fletcher score), 29 (46.8%) patients had low, 20 (32.3%) intermediate, 11 (17.7%) high-risk GIST. CD133 was detected in the majority of 62 GIST clinical samples (strong/moderate; 31 patients, weak; 21 patients). CD133 highly expressed cells in FACS were apt to form large tumor in mouse. Statistically, tumor size, mitotic rate and expression of Ki-67 did not correlated with expression of CD133.

**Conclusions:** CD133 highly expressed cells provided ability of tumor formation, but expression of CD133 did not correlated risk score. We considered CD133<sup>+</sup>/KIT<sup>+</sup> cells had the tumor-initiating ability. CD133 is expressed in the majority of GISTs, suggesting a novel, additional standard marker for identifying GIST.

**Abstract ID: 0152**

Specific Field: **Oncology**

**Mode of pres.: Poster Exhibition only**  
**ISW 2011 Session PE 88**

**ETV1 expression in gastrointestinal stromal tumor (GIST)**

M. Moriyama [1], Y. Shimada [1], T. Okumura [1], T. Omura [1], S. Sekine [1], S. Osawa [1], K. Tazawa [2], K. Tsukada [1]

[1] University of Toyama, Toyama, Japan, [2] Itoigawa General Hospital, Itoigawa, Japan

**Introduction:** Gastrointestinal stromal tumors (GIST) is defined by activating mutations in the KIT or PDGFRA receptor tyrosine kinases. It is suggested that the cellular context is important for KIT to mediate oncogenesis. Recent analysis revealed that the ETS family member ETV1 is highly expressed in the subtypes of interstitial cells of Cajal (ICCs) sensitive to oncogenic KIT mediated transformation, and is required for their development. In addition, ETV1 is universally highly expressed in GISTs (Nature 2010). In this paper, we examined the ETV1 expression and compared it to the clinicopathological factor of the patients.

**Material and Methods:** 39 cases (GIST; 31 cases, leiomyoma; 3 cases, leiomyosarcoma; 5 cases) of mesenchymal tumors in our hospital and GIST cell line (TYGIST-1) were examined. ETV1 antibody (ab81086) used was same antibody of the previous report.

**Results:** Immunohistochemical analyses revealed that 29/30 cases with ETV1 stained positive in GIST, 2/3 cases positive in leiomyoma, and 4/5 cases positive in leiomyosarcoma. The size of ETV1 positive tumor was larger than that of negative tumor, and the survival time of ETV1 negative patients longer than that of positive patients in GIST. However, a statistically significant difference was not found. It has been reported that ETV1 is specifically expressed in GIST, however, our study revealed that ETV1 were expressed in other mesenchymal tumors. The GIST cell line (TYGIST-1) also express ETV1.

**Conclusions:** Contrary to the previous report, ETV1 was not specifically expressed in GIST and had no effect on development of tumor. From the view point of immunohistochemical analysis, our results do not support the previous paper. ETV1 may not be a good biomarker of the GIST.

**Abstract ID: 0153**

Specific Field: **Oncology**

**Mode of pres.: Poster Exhibition only**  
**ISW 2011 Session PE 89**

**GIST-specific markers identified by comprehensive gene expression profiles**

M. Iwade, K. Miyamoto, E. Ito, J. Imai, S. Watanabe, N. Sawada, S. Waguri, S. Takenoshita

Fukushima Medical University, Fukushima, Japan

**Introduction:** Gastrointestinal stromal tumors (GISTs) are the most common mesenchymal neoplasm of the gastrointestinal tract and highly express *c-kit*. GISTs have an unpredictable behavior and a long term follow-up is essential for all patients, independent of their benign or malignant characteristics. There have been well-known biomarkers for cancers, such as colon, mammary, and ovarian cancers. But not for GIST. Therefore, we performed a comprehensive gene expression analysis to explore GIST-specific genes.

**Material and Methods:** We conducted DNA microarray analysis using approximately 900 tumor tissues obtained in Fukushima

Medical University Hospital so far since 2007 and assembled gene expression profiles acquired into a database comprising a single matrix. The database contained more than 30 kinds of tumors including 10 cases of GIST.

**Results:** From the gene expression profile, we extracted 547 genes whose expression ratio was greater than 2.0 in at least 2 out of 10 GIST samples when compared to other tumor samples. We further extracted 54 genes whose expression ratio was greater than 2.0 in at least 7 out of 10 GIST samples when compared to other tumor samples. Note that they include not only c-kit but also previously unappreciated genes.

**Conclusions:** These selected genes could be candidates for new molecular markers of GIST, as well as for a molecularly targeted therapy.

**Abstract ID: 0154**

Specific Field: **Oncology**

**Mode of pres.: Poster Exhibition only**  
**ISW 2011 Session PE 90**

**Development of ELISA measurement for endogenous urinary 3-hydroxyproline-containing peptides and its preliminary application to community healthy persons and cancer patients**

J. Saito [1], I. Okazaki [2], J. Itoh [3], Y. Kitagawa [4]

[1] Department of Surgery, Inagi Municipal Hospital, Inagi, Japan, [2] Department of Internal Medicine, International University of Health and Welfare, Otawara, Japan, [3] Itoh Co. Ltd., Chiba, Japan, [4] Department of Surgery, School of Medicine, Keio University, Tokyo, Japan

**Introduction:** We reported that endogenous urinary 3-Hyp is useful for cancer screening because basement membrane is degraded by cancer cell invasion and 3-Hyp is the unique component of type IV collagen in basement membrane. Here we report an ELISA method using a specific antibody against a synthetic peptide of 9 amino acids including 3-Hyp corresponding to the amino acid sequences of collagen type IV alpha chain. One hundred and eighty healthy controls and 22 cancer patients samples were assayed by this method. The values in controls were  $2.44 \pm 1.90$  (SD) mg peptide /gm creatinine for 52 men (with a range from 0.65 to 10.51) and  $2.87 \pm 2.01$  (0.94 to 17.31) for 128 women. At the beginning of this ELISA study the authors expected high urinary excretion values of the 3-Hyp-containing peptide in cancer patients, but the values in 22 cancer patients showed the very low value,  $0.110 \pm 0.137$  ( $P < 0.001$ ). The stage I and II of colon cancer revealed  $0.131 \pm 0.170$  ( $n = 9$ ), significantly lower than the levels of healthy persons, while the levels of 5 patients with stage III and IV colon cancer was  $0.121 \pm 0.113$ , showing lower tendency compared with those of Stage I and II. As reported previously, endogenous urinary excretion of 3-Hyp measured by an amino acid analysis, showed very low levels in healthy controls and high levels in cancer patients, but this ELISA study showed the opposite results.

**Abstract ID: 0155**

Specific Field: **Oncology**

**Mode of pres.: Poster Exhibition only**  
**ISW 2011 Session PE 91**

**Biological evaluation of paclitaxel-peptide conjugates as a model for MMP2-targeted drug delivery**

R. Yamada

University of Southern California, Los Angeles, USA

**Introduction:** Paclitaxel (PTX) is a highly effective cytotoxic agent widely used for the treatment of several solid tumors. However, PTX shows dose-limiting cytotoxicity and in most cases induces drug resistance followed by failure in treatment. To enhance the therapeutic index of a given drug, various drug delivery methods have been explored to systemically deliver sufficient amount of the drug to the desired site.

**Material and Methods:** In the present study, we designed and synthesized two PTX prodrugs by conjugating PTX at different sites with an octapeptide (AcGpLGlaGQ) that can be cleaved by MMP2 at tumor sites. As a result, PTX is expected to be released at the tumor sites, absorbed by the tumor cells, and thereby inhibit the tumor growth. We evaluated the in vitro activities of the two drugs in a panel of drug-sensitive and -resistant cancer cell lines and their in vivo efficacies in a HT1080 fibrosarcoma mouse xenograft model that overexpresses MMP2.

**Results:** Our in vitro results showed that the PTX-AcGpLGlaGQ conjugates inhibited cancer cell proliferation with higher activity compared to that observed for free PTX, both of which were mediated by an arrest of G2/M-phase of the cell cycle. Consistent with the invitro results, treatment with PTX-octapeptide conjugate resulted in extensive areas of necrosis and a lower percentage of proliferating cells in xenograft tumor sections.

**Conclusions:** Together, our results indicate the potential of the tumor-targeted delivery of PTX to exploit the specific recognition of MMP2, reduce toxicity, and selectively kill tumor cells.

**Abstract ID: 0156**

Specific Field: **Oncology**

**Mode of pres.: Poster Exhibition only**  
**ISW 2011 Session PE 92**

**Palliative treatment of percutaneous transesophageal gastrostomy/jejunostomy (PTEG/J), malignant stenosis in neck and intestinal obstruction**

Y. Tomisawa, H. Nitta, S. Ogasawara, J. Nakajima, T. Itabashi, T. Fujita, H. Itabashi, G. Wakabayashi

Iwate Medical University, Morioka, Japan

**Introduction:** Enteral feeding and gastric decompression devices are common in critical, terminal, and chronically ill patients. PEG/jejunostomy (PEG/J) is often placed in patients with cancer for palliating bowel obstruction or for feeding. However, PEG/J placement may not always be possible for many reasons. We wish to bring attention to the percutaneous transesophageal gastrostomy/jejunostomy (PTEG/J) as a viable alternative to nasogastric decompression in patients who are not candidates for PEG/J. We review our indications, technical experience, complications, and short- and long-term quality of life (QOL) in patients that underwent the PTEG procedure.

**Material and Methods:** Patients were terminally ill from advanced cancer requiring gastrointestinal decompression or had hostile abdomens needing long-term feeding access. After adequate sedation is administered, a  $22 \times 4$  mm balloon catheter is passed into the esophagus over a guidewire just below the thoracic inlet. The balloon is ruptured with a needle passed through the neck under US guidance. A guidewire is then passed through the needle into the balloon and carried into the stomach or proximal small bowel by advancing the balloon catheter. The track is then dilated over the guidewire and a pigtail 45-cm-long 14 F nephrostomy tube then passed into the stomach or into the proximal small bowel over the guidewire. The catheter is secured by suturing to the skin of the neck. **Results:** Of consecutive 81 patients performed PTEG in the hospital and the related institution from January 2004 to December 2010, nineteen patients were enrolled in this study. Subjects included 9 men and 10 women with a mean age of 66.1 years



(range, 49–84 years). Survival time was between 10 and 354 days (median, 103 days). Placement was successful in 18 patients (95%). There were no major complications and two minor complications (10.5%). One patient (0.05%) died within 1 month after the procedure from their preexisting medical conditions. Fifteen patients were capable of being discharged from the hospital with adequate enteral access and gastrointestinal decompression.

**Conclusions:** PTEG is a safe and effective method of enteral feeding and decompression in patients that have contraindications to standard enteral access. Appropriate patient selection and timing of PTEG placement is crucial for optimum benefit.

**Abstract ID: 0157**

Specific Field: **Oncology**

**Mode of pres.: Poster Exhibition only**  
**ISW 2011 Session PE 93**

**Study to predict optimal duration of chemotherapy with fluoropyrimidine by multi-point collagen gel droplet embedded drug sensitivity test**

Y. Tokunaga, H. Sasaki, T. Ohnishi

Osaka North Japan Post Hospital, Osaka, Japan

**Introduction:** In colorectal cancer (CRC), 5-fluorouracil (5-FU) has been a basic chemotherapeutic agent. Antitumor effects of 5-FU and its derivatives are likely due to inter-individual difference in the drug sensitivity. Feasibility of individualized chemotherapy was studied using drug sensitivity test.

**Material and Methods:** We evaluated 5-FU sensitivity of cancer cells from CRC patients using the collagen gel droplet-embedded culture drug sensitivity test (CD-DST) under multiple drug concentration and contact durations. The area under the concentration curve (AUC) and growth inhibition curve (IR) were combined in the AUC-IR curve, according to which, the individual  $AUC_{IR50}$  was calculated. Furthermore, using the AUC values of 5-FU during 24 h with chemotherapy with UFT and S-1, the durations to achieve the  $AUC_{IR50}$  were calculated in chemotherapy with UFT or S-1 for individual patient.

**Results:** The value of individual  $AUC_{IR50}$  ranged widely from less than 100  $\mu\text{g h/ml}$  to more than 1000  $\mu\text{g h/ml}$ . Approximately 13% of patients demonstrated a relatively low 5-FU sensitivity. In the chemotherapy with UFT, 55% of patients achieved  $AUC_{IR50}$  within 6 months, 13% of patients achieved it in 6 to 12 months, another 13% of patients in 12 to 24 months, and the other 19% after 24 months of chemotherapy. In the chemotherapy with S-1, 31% of patients achieved  $AUC_{IR50}$  within 1 course, 15% of patients achieved it in 1 to 2 courses, another 23% in 2 to 6 courses and the other 31% of patients achieved  $AUC_{IR50}$  after 6 courses. Durations of chemotherapy to achieve the  $AUC_{IR50}$  differed widely depending on the  $AUC_{IR50}$  of individual patient. Prolapse free survival was significantly better in the patients who have achieved individual  $AUC_{IR50}$  than those who have not achieved the  $AUC_{IR50}$ .

**Conclusions:** The present results suggest that the antitumor effects of 5-FU and its derivatives differ widely depending on inter-individual difference of sensitivity, and that individual  $AUC_{IR50}$  may be useful to predict the optimal duration of chemotherapy.

**Abstract ID: 0158**

Specific Field: **Oncology**

**Mode of pres.: Poster Exhibition only**  
**ISW 2011 Session PE 94**

**Evaluation of the effect of Keishi-ka-jutsu-bu-to on peripheral neuropathy disorder in FOLFOX therapy**

T. Sato, T. Ochiai, T. Hashiguchi, K. Nishimura, T. Watanabe, M. Kitajima, A. Nakatani, S. Futagawa

Tobu Chiiki Hospital, Tokyo Metropolitan Health and Medical Treatment Corporation, Tokyo, Japan

**Introduction:** FOLFOX (+ bevacizumab [BV]) has been established as the standard chemotherapy regimen for colorectal cancer. With an increase in the number of treatment cycles, however, peripheral neuropathy, the major adverse reaction and the dose-limiting toxicity of oxaliplatin (L-OHP), occurs at a high frequency and treatment has to be discontinued. It has been reported that this neuropathy can be prevented by Gosha-jinki-gan. In the present study, we started treatment with powdered aconite tuber and Keishi-ka-jutsu-bu-to after the onset of peripheral neuropathy and assessed the effect of this therapy.

**Material and Methods:** The subjects were 20 patients with recurrent colorectal cancer who had undergone FOLFOX + BV therapy as their initial treatment during the period from February 2007 to December 2010, and were treated with powdered aconite tuber and Keishi-ka-jutsu-bu-to after the onset of peripheral neuropathy. Their ages ranged from 28 to 83 years (median: 63.9 years). Thirteen were male and seven were female. When peripheral neuropathy appeared during a course of FOLFOX (+ BV) therapy, the patient was informed of the objective and procedures of the study and his or her consent was obtained to participation in the study. Keishi-ka-jutsu-bu-to (7.5 g/day) was administered orally and powdered aconite tuber (0.5-2.0 g/day) was also administered depending on the intensity of symptoms. Evaluation of the treatment effect was done according to the Neurotoxicity Criteria of Debiopharm (DEB-NTC).

**Results:** Thirteen patients (65%) were treated with Keishi-ka-jutsu-bu-to for at least 1 month. Among them, 7 (53.8%) showed improvement of symptoms by 1 grade or more. From immediately after dosing, a hyperthermic effect was noted in 10 patients and 7 of them showed improvement of symptoms. The improvement tended to be significantly more marked for numbness of the fingers than for numbness of the lower extremities.

**Conclusions:** It was suggested that Keishi-ka-jutsu-bu-to and powdered aconite tuber were likely to produce improvement of oxaliplatin (L-OHP)-related peripheral neuropathy.

**Abstract ID: 0159**

Specific Field: **Oncology**

**Mode of pres.: Poster Exhibition only**  
**ISW 2011 Session PE 95**

**Roles of an inducible prostaglandin E synthase, mPGES-1 in host in enhancement of tumor-associated angiogenesis**

H. Kamata, Y. Ogawa, H. Kubo, H. Katoh, Y. Ito, M. Masataka, M. Watanabe

Kitasato University School of Medicine, Sagami-hara, Japan

**Introduction:** Microsomal prostaglandin (PG) E synthase 1 (mPGES)-1 is a major PGE synthase and has recently been reported to be expressed at high levels in several cancer types. We previously reported that the PGE receptor EP3 is expressed in bone marrow (BM) derived cells, enriched in stromal tissue, and enhances the potential for tumor angiogenesis. In the present study, we examined the role of mPGES-1 in the host tissues in enhancement of tumor-associated angiogenesis.

**Material and Methods:** We used 8-week-old male mPGES-1 knockout mice (mPGES-1<sup>-/-</sup>) and backcrossed with their wild-type counterparts (WT, C57BL/6). Lewis lung carcinoma (LLC) tumors was injected into the subcutaneous dorsal tissue of mice. Tumor growth was evaluated over time. Serial sections were stained with

hematoxylin and eosin (H&E). Microvessel density (MVD) and microvessel area (MVA) were quantified as parameters of angiogenesis. High-dose irradiated WT mice were divided into two groups. mPGES-1 BM mononuclear cells collected from each of the femurs, tibias and pelvis were injected via the tail vein into irradiated WT mice. Another group were injected BM mononuclear cells from WT Mice. Sponge, chambers, and LLC, were injected. Angiogenesis was evaluated as well.

**Results:** Growth and tumor-associated angiogenesis were suppressed in mPGES-1 knockout mice (mPGES-1<sup>-/-</sup>) after the subcutaneous implantation of Lewis lung carcinoma cell, in comparison with those in wild-type (WT) mice. After lethal radiation, WT BMs were replaced with BM cells isolated from mPGES-1<sup>-/-</sup>. The levels of neoangiogenesis in sponge implants measured in mPGES-1<sup>-/-</sup> BM chimeric mice were significantly reduced compared to those observed in WT BM chimeric mice. Tumor-associated angiogenesis as measured by histological analysis was localized to tumor stroma, and was significantly lower in mPGES-1<sup>-/-</sup> BM chimeric mice compared to that in WT BM chimeric mice. Tumor sections probed by immunohistochemistry revealed that vascular endothelial growth factor (VEGF) that was present in the stromal tissue was markedly reduced in mPGES-1<sup>-/-</sup> BM chimeric mice compared to wild-type BM chimeras.

**Conclusions:** Host mPGES-1 enhanced tumor-associated angiogenesis, and that regulation of mPGES-1-expressing BM cell recruitment to the site of primary tumors may be a novel strategy for the treatment of solid tumors.

**Abstract ID: 0160**

Specific Field: **Oncology**

**Mode of pres.: Poster Exhibition only**  
**ISW 2011 Session PE 96**

**A randomized controlled trial to evaluate the effect of PC and VK2 for hepatocellular carcinoma**

S. Takeda, T. Sugae, H. Kasuya, T. Fujii, H. Sugimoto, S. Nomoto, A. Nakao

Nagoya University Graduate School of Medicine, Nagoya, Japan

**Introduction:** We reported that Phosphatidylcholine (PC) and Menatetrenone (VK2) can induce apoptosis and suppress the growth of hepatocellular carcinoma cells in vitro experiments. The aim of this study is to clarify the effect on hepatocellular carcinoma due to PC and VK2 in clinical trial.

**Material and Methods:** Between Nov 2006 to July 2009, 29 patients with HCC who have agreement with our clinical trial were enrolled and randomly assigned to 3 groups: PC group who received 900 mg of PC per day for 10 consecutive days prior surgery; PC+VK2 group who received 900 mg of PC and 45 mg of VK2 per day for 10 consecutive days prior surgery; and control group who received no treatment prior surgery. All patients underwent primary hepatectomy at our department. We assessed not only the change of the serum AFP, PIVKAI and Cytochrome C, but also Apoptosis using tunnel staining for the resected liver tissues.

**Results:** The level of serum AFP increased 1.5 times in average after 10 days compared with PC group and PC+VK2 group. In the same way, the level of PIVKAI also increased a little in control group, while that decreased significantly in PC group and PC+VK2 group. However, there was no significant statistic difference between control group, PC group and PC+VK2 group. Regarding the cancer tissues,

there were no significant differences in Apoptotic Index (AI) using Tunnel staining among 3 groups. Nevertheless, AI in non-cancerous tissue decreased in PC+VK2 group compared with control group and PC group.

**Conclusions:** PC+VK2 failed to suppress the growth of hepatocellular carcinoma. But it might be able to preserve liver tissues such as hepatitis and cirrhosis because it suppress more apoptosis only in non-cancerous tissue. Even though this research was inconclusive, we would definitely like to utilize it for future reference by reconsidering the observation span and the amount of medicine induced.

Patients characteristics

	PC	PC + VK2 control	
Age, mean	63.5	66.2	61.1
Sex, M/F	9/1	7/3	8/2
Virus, B/C/NBNC	3/3/4	1/7/2	2/6/2
Child Pugh, A/B/C	10/0/0	9/1/0	10/0/0

**Abstract ID: 0161**

Specific Field: **Plastic Surgery**

**Mode of pres.: Poster Discussion**  
**ISW 2011 Session 60.11**

**Successful repair of an extremely low birth weight infant with esophageal atresia**

M. Kobayashi [1], M. Mizuno [1], G. Wakabayashi [2]

[1] International Surgical Week 2011, Yokohama, Japan, [2] ISW, Japan

**Introduction:** Recent advances in neonatal intensive care have led to an increased survival of extremely low birth weight (ELBW) infants. So, we sometimes look at infants of EA with ELBW. We successfully operated on the infant with ELBW + EA by delayed primary repair.

**Material and Methods:** In 2004, a male infant was delivered at 27 weeks gestation by an emergency cesarean section due to the premature rupture of the membranes. The birth weight was 830 g. A gastric tube could not be successfully passed through. The patient was finally diagnosed to have esophageal atresia with distal tracheoesophageal fistula (Gross C type) based on plain X-P finding after the insertion of NGT. Gastrostomy was performed on day 1. No associated malformations were detected without PDA according to further examinations. The division of tracheoesophageal fistula and esophago-esophagostomy was performed at 385 g a bodyweight of 685 g on the day 7 after PDA was closed.

**Results:** On the postoperative day 15, started tube feeding was started. Extubation was done on the at 43rd day. The patient was discharged at 6 months after surgery. Now, at seven years after the operation, his subsequent development has been perfectly normal and without any problems. The patient currently attends primary school.

**Conclusions:** We consider that an aggressive repair is therefore indicated for ELBW and VLBW infants presenting with EA without any other life threatening malformations. This treatment modality is technically feasible and is considered to be a good treatment option for ELBW and VLBW infants.

**Abstract ID: 0162**      Specific Field: **Plastic Surgery**

**Mode of pres.: Poster Exhibition only**  
**ISW 2011 Session PE 148**

**Mandible fractures: an Asian institution's review of outcomes of management and maxillomandibular fixation**

V. Nallathamby, Y.M.S. Ho

Tan Tock Seng Hospital, Singapore, Singapore

**Introduction:** Mandibular fracture is a common presentation to the emergency room following trauma. However there is still a variety of management when it comes to maxillomandibular fixation, either following internal rigid fixation or conservative management. We discuss our institution's outcomes following mandibular fractures and cases which had maxillomandibular fixation.

**Material and Methods:** Retrospective review of facial fractures admitted to Tan Tock Seng Hospital from January 2009 to June 2010. Ethical board approval had been granted. Of the 140 patients admitted to our care, 35 patients had mandibular fractures.

**Results:** The patient's average age was 37.4 years. Six patients had presented as a delayed case to our clinic while the remaining 29 were acute admission to the ward. All but seven patients were operated on. All patients underwent surgery within two days of admission except for nine patients. Two patients were treated urgently for management of acute bleeding. Of the 18 patients who had maxillomandibular fixation, ten was with arch bars while eight was with intermaxillary screws. Overall there was one patient who developed a sinus tract and the plates were removed once the fractures healed. There were six patients who complaint of mental nerve numbness more than one month from surgery. Five had pre-operative numbness. Post-operatively, three patients had suboptimal mouth opening while one could no longer fit his dentures and two had malocclusion.

**Conclusions:** We found that anatomical reduction and fixation greatly reduces the complication of malocclusion. Non fixation of condylar or subcondylar fractures, with the aid of maxillomandibular fixation, did not lead to significant malocclusion. There were no significant differences between using arch bars or intermaxillary screws. However prolonged maxillomandibular fixation did lead to some degree of ankylosis and caused suboptimal mouth opening.

**Abstract ID: 0163**      Specific Field: **Surgical Education**

**Mode of pres.: Poster Discussion**  
**ISW 2011 Session 60.06**

**Working example from a surgical interest society: promoting undergraduate surgical teaching and education**

A.N. Ashrafi [1], R. Li [2], K.J. Drummond [1]

[1] The University of Melbourne, Melbourne, Australia,

[2] The Royal Melbourne Hospital, Australia

**Introduction:** There is an overt shortage of surgeons in Australia and New Zealand. Current undergraduate medical education has prioritises non-surgical teaching and clinical examinations focus predominantly on general medical content. Further, anatomy is given little precedence in many pre-clinical courses. Recent worldwide trends show a decline in graduates pursuing surgical careers. Undergraduate student interest in surgery plays an important role in

promoting surgical careers following graduation and may help tackle the shortage in our surgical workforce today.

**Material and Methods:** The Surgical Students Society of Melbourne (SSSM) endeavours to augment undergraduate surgical exposure and experiences, encourage surgery as a career choice and provide a forum by which to maintain and support student interest in surgery. The SSSM is a student led initiative which incorporates valuable input across all levels: from trainees to surgeons alike. It specifically hopes to provide surgical teaching and education, professional development sessions, research opportunities, as well as a unified representation for aspiring surgeons. In just over a year, it has grown to represent hundreds of students across five clinical schools. The group has received great feedback particularly with regards to its provision of surgical teaching.

**Results:** We will present the complete results of our survey of students and teachers.

**Conclusions:** We believe the SSSM and other like-minded societies serve an important role in fostering the interest of medical students in surgery. We will share our experiences thus far, and discuss areas for improvement and our visions for the future. With growing number of programs similar to ours, we believe inter-society communication is important for self appraisal and further refinement of a relatively new area.

**Abstract ID: 0164**      Specific Field: **Surgical Education**

**Mode of pres.: Video**  
**ISW 2011 Session 62.08**

**Inexpensive and cameraman-less full high vision video support system is useful for the education of open hepato-pancreato-biliary surgery**

H. Nakano, T. Otsubo

St. Marianna University School of Medicine, Kawasaki, Japan

**Introduction:** Filming and recording open surgeries of hepato-pancreato-biliary (HPB) surgery now seem important and essential to educate trainees of HPB surgery. However, recording system of surgical videos usually cost a lot and needs assistants for filming videos. We here present an inexpensive full high vision video support system for filming HPB surgeries. In addition, the present video system does not need cameramen.

**Material and Methods:** Pancreaticoduodenectomy for pancreatic adenocarcinoma and left hepatectomy with caudate lobectomy for hilar cholangiocarcinoma were recorded using a Video-Support-System (VSS, Takasago Medical Co., Tokyo, Japan) which can place and fix a video camera. The VSS is fixed at the operating bed. The two surgeries were filmed with Full High Vision Video Camera, which is not one for professional use (Everio GZ-HM1, Victor JVC, Tokyo, Japan).

**Results:** The two above-mentioned devices costed only approximately 4000 US dollars. The two surgeries were performed by an operator and two assistant surgeons and filmed without a cameraman. The two surgeries were filmed in a fine full-high vision video within 40 Mega-bites, respectively. The full high vision videos were easily edited by a computer software VideoStudio Pro X3 (Coreal Co., Tokyo, Japan), and were used for educating trainees of HPB surgery.

**Conclusions:** The above-mentioned Video System for open HPB surgeries is not costly and does not need cameramen, but can offer satisfied full high vision fine videos.

**Abstract ID: 0165** Specific Field: **Surgical Education**

**Mode of pres.: Video**  
**ISW 2011 Session 62.09**

**Totally laparoscopic proximal gastrectomy with intracorporeal end to side esophagogastrostomy: a case report and video presentation**

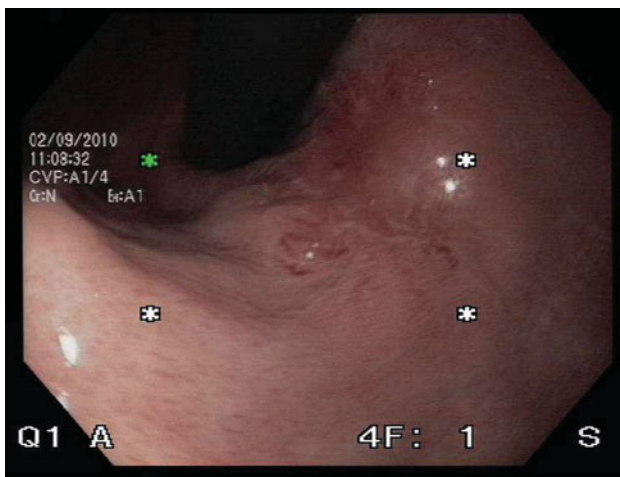
K.Y. How, A.D. Rao, J.K. Rao

Tan Tock Seng Hospital, Singapore, Singapore

**Introduction:** Traditionally, total gastrectomy has been the standard procedure for proximal gastric cancers. However, optimal extent of gastric resection in patients with cancer in the proximal third of the stomach is controversial. Advocates of total gastrectomy argue that it allows for better surgical margins and lymphadenectomy while proponents of proximal gastrectomy suggests that it achieves similar survival rates while providing for a better quality of life from preservation of the physiologic function of the gastric remnant. We describe a case of totally laparoscopic proximal gastrectomy with end to side esophagogastrostomy in a patient with early stage gastric cancer located in cardia. This technique is currently accepted by surgeons as the most favorable type of operation for the treatment of early stage gastric cancer in the upper third of the stomach, from both a hormonal and a nutritional perspective.

**Material and Methods:** A 79 year old lady with a history of Helicobacter-pylori associated gastritis presented with dyspepsia. She underwent esophago-gastroduodenoscopy which revealed a small ulcer with irregular margins at the cardia. Abnormal looking vessels were noted on Narrow Band Imaging. Biopsies of the ulcer were taken which later revealed areas of high grade dysplasia with a focus of irregular glands suspicious for stromal invasion. Staging Computed Tomography scan showed no metastatic disease or intra-abdominal lymphadenopathy. She underwent laparoscopic proximal gastrectomy with end to side esophagogastrostomy.

**Results:** Her post operative recovery was excellent, with minimal analgesic requirements and no reflux symptoms. Gastrografin study on post operative day 4 showed no anastomotic leak and she progressed to normal diet on post operative day 7 and was discharged. Histology showed a well differentiated adenocarcinoma with subse-



**Figure:** OGD image of early gastric cancer of cardia

rosal involvement (T3) There was no lymph nodes involvement (0/21) and margins were adequate.

**Conclusions:** Laparoscopic proximal gastrectomy can be performed safely for early stage cancers in the proximal one third of the stomach without compromising cure rate. It allows better preservation of the physiologic function of the stomach and thus potentially less complications and morbidity from hormonal and nutritional deficiencies.

**Abstract ID: 0166** Specific Field: **Surgical Education**

**Mode of pres.: Free Paper**  
**ISW 2011 Session 171.01**

**Errors in patients' hand-over from the operating room to the intensive care unit**

A.R. Ferreres [1], M.E. Gimenez [1], G.M. Tombetta [1], A.T. Ferreres [2], M. Fasano [1], V.P. Guti [1]

[1] University of Buenos Aires, Buenos Aires, Argentina,

[2] University of Washington, USA

**Introduction:** Surgical care is characterized by transition between different levels and implies a potentially problematic and error prone condition. Communication breakdowns represent a common threat to surgical patient safety, representing the immediate postoperative period the highest risk. Our aim was to analyze the effectiveness and quality of the transfer of information regarding postoperative care in patients referred from the operating room to the intensive care unit.

**Material and Methods:** Between August and December 2010, we investigate 100 surgical patients whose postoperative condition or recovery requested transfer to the intensive care unit. Three experienced observers, not related to the care teams, escorted the patient and evaluate the process of handover (verbal and written) using a 5-point Likert scale.

**Results:** Errors were achieved in 73% of the transfers between the operating room (OR) and the intensive care unit (ICU) and included missing, incomplete or inaccurate information. Most common communication breakdowns included: (a) Surgical residents failing to notify the receiving intensivists of critical events and omitting salient points (details from the operative procedure just completed, known medication, allergies or systemic illnesses), (b) Details of management or staffs prescriptions. The following associated factors were detected: status asymmetry and ambiguity about responsibilities associated.

The overall quality of hand-offs was considered as: poor (59%), fair (19%), good (22%).

Harmful consequences to the patient were achieved in 5 cases and were related to medication errors.

**Conclusions:** (a) The transfer of surgical patients from surgery to intensive care is a frequent but potentially hazardous activity. (b) The quality of handoffs proved to be substandard, with opportunities when important information is not transmitted and lack of essential operative background to the ICU medical staff. (c) An effective set of critical information must be developed and taught to minimize the potential for errors and near misses and assure an adequate continuum of care. (d) Best practice recommendations for handoffs must be implemented and observed to guarantee surgical patient safety in the immediate postoperative period. (e) Analysis of these "missed opportunities" can be used to develop an educational program on how to hand off more effectively.



**Abstract ID: 0167** Specific Field: **Surgical Education**

**Mode of pres.: Free Paper**  
**ISW 2011 Session 171.02**

**Pattern of surgical practice in a regional hospital in Cameroon and implications for training**

A. Chichom Mefire [1], P.M. Kuwong [2], J. Mbuagbaw [3], N.M. Lidwine [2], E.E. Malonga [4]

[1] Regional Hospital Limbe, Cameroon, [2] Regional Hospital Limbe, Limbe, Cameroon, [3] Faculty of Health Sciences, University of Buea, Buea, Cameroon, [4] Faculty of Medicine and Biomedical Sciences, University of Yaoundé, Yaounde, Cameroon

**Introduction:** In many areas of the world, it is still necessary to rely on general practitioners to perform a selected number of surgical procedures. WHO recommends that in African settings, surgery is practiced as much as possible at the level of the district. The workload and nature of procedures performed in surgical units of university hospitals help build teaching programs and curricula. The aim of this study is to document the surgical and anaesthetic procedures performed in a level III institution and analyse the implications for training.

**Material and Methods:** This is a retrospective study carried out in the Regional Hospital, Limbé, in the South West region of Cameroon. This level III institution was recently selected as University Teaching Hospital for the developing Faculty of Health Sciences of University of Buea. Post operative notes of the registry of the theatre were reviewed for all operative procedures carried out in this institution during the year 2007. These were then classified as major or minor procedures. The frequency of each type of procedures was matched with the clinical rotation of 4th year medical students to estimate their level of exposure; adequate exposure to a procedure was defined as watching it 10 times.

**Results:** A total of 1351 procedures were carried out during the study period. These included 620 major and 731 minor procedures. 713 (52.8%) procedures were carried out as an emergency and 1110 (82.2%) for a non injury related condition. 1133 (83.86%) of procedures were carried out by a general surgeon and 52.25% on females. The systems most frequently involved included urologic and genital system with 325 (24.05%) procedures, digestive system and abdominal wall with 290 (21.46%) procedures and obstetrics with 283 (20.9%) procedures. The most frequently performed procedures included Caesarian section ( $n = 131$ ), ritual circumcision ( $n = 148$ ), laparotomy for various indications ( $n = 144$ ), appendectomies ( $n = 81$ ) and hernia repairs ( $n = 81$ ).

**Conclusions:** Medical students were found to be adequately exposed to procedures such as hernia repair, appendectomy, midline laparotomy, caesarean section and most minor procedures. But, there is need to develop services related to management of injury related emergencies as well as sub-specialities of surgery (E.N.T., eye, etc.)

**Abstract ID: 0168** Specific Field: **Surgical Education**

**Mode of pres.: Free Paper**  
**ISW 2011 Session 171.03**

**Development of a simulation-based curriculum for the training and evaluation of laparoscopic inguinal hernia repair**

Y. Kurashima, P. Kaneva, L. Feldman, G. Fried, M. Vassiliou  
 McGill University, Montreal, Canada

**Introduction:** Despite the advantages of the laparoscopic inguinal hernia repair (LIHR), it has not gained widespread acceptance, possibly due to the longer learning curve. One way to address this training challenge may be through simulation. The purpose of this study is to develop and validate a comprehensive curriculum for the training and evaluation of LIHR.

**Material and Methods:** Firstly, we developed a tool to measure performance during LIHR called the Global Operative Assessment of Laparoscopic Skills Groin Hernia (GOALS-GH). GOALS-GH can be used to assess transabdominal preperitoneal (TAPP) or totally extra-peritoneal (TEP) repairs. It is a 5-item global-rating scale. We then designed a low-cost physical model: the McGill Laparoscopic Inguinal Hernia Simulator (MLIHS). MLIHS represents accurate anatomic relationships and allows learners to perform each step of a LIHR using a tower and instruments from the operating room (OR). To evaluate the reliability and validity of these tools, 17 novices and 8 experienced surgeons were assessed by observers, attending surgeons and self in the OR and/or on the simulator using GOALS-GH. To prepare participants, and to teach the underlying principles of LIHR, we created and conducted a hernia course with pre and post tests, and a step-by-step instructional video of the procedure.

**Results:** The inter-rater reliability of GOALS-GH was greater than 0.7 for all raters in the OR and simulator. The internal consistency of GOALS-GH items was 0.97 in the OR and 0.96 in the simulator. The mean GOALS-GH score for experienced surgeons was significantly higher compared to novices in both environments. The correlation between GOALS-GH scores in the OR and the simulator was 0.81 ( $P < 0.01$ ,  $n = 12$ ). Thirty three general surgery residents participated in the hernia course. Their knowledge about LIHR improved after the course (% correct pre vs post: anatomy & diagnosis 36 to 64 and steps of the procedure 50 to 74). 100% of participants rated the session as 5/5 with regards to educational value.

**Conclusions:** GOALS-GH is a reliable and valid measure of the skills required for LIHR and may be used with the MLIHS as an educational tool and as an outcome measure. Combined with a basic course and instructional video, these tools can be integrated into a comprehensive curriculum that may help to improve the learning curve for LIHR.

**Abstract ID: 0169** Specific Field: **Surgical Education**

**Mode of pres.: Free Paper**  
**ISW 2011 Session 171.04**

**Expanding the professional role of nurses in the surgical field in Japan**

E. Kono, Y. Yamasaki, T. Yumiba

Osaka Kosei-Nenkin Hospital, Osaka, Japan

**Introduction:** The surgical field in Japan's healthcare system is deteriorating and the working environment for surgeons is poor. The government plans to launch a trial designation of the "tokutei" (specifically qualified) nursing profession in February 2010. ("Tokutei" nurses are mid-level clinicians such as nurse practitioners (NP).) It is recognized that medical treatment by a team is preferable to doctor-centered care. Our aim is to examine whether nurses are ready to adopt an expanding professional role.

**Material and Methods:** A two-part questionnaire survey on nurses' role expansion was carried out with a target population of ward nurses who participate in surgery-based medical examination and treatment at Osaka Kosei-Nenkin Hospital. The first part inquired about nurses' approval or disapproval of their role expansion, their reasons, and their awareness of the NP profession, and the second part included 42

items to assess approval and disapproval regarding the surgery system related to society's requirements for nurses' role expansion as well as new medical responsibilities related to surgical operations and related medical actions.

**Results:** The response rate was 97.4%. Eighty-six respondents (77.7%) expressed approval of nurses' role expansion, and 23 respondents (20.5%) expressed disapproval. The reasons for approval were: (1) avoiding frequent reliance on doctors; (2) work worth doing; and (3) advantages to patients. Meanwhile, reasons for disapproval were: (1) greater responsibilities; (2) increased workload; and (3) changing the original role of the nurse. Thirty-nine (34.8%) respondents knew about NP. Approval was expressed regarding new medical work actions including: (1) changing bandages of post operative patients; (2) monitoring patients' vital signs; and (3) the respiratory tract securement and mask ventilation of a cardiopulmonary stop patient. Of the 42 items, 24 (57.1%) were endorsed by about half the respondents, and the need was expressed for an academic meeting to prepare a revised plan for the surgery system so as to clarify the nurses' role expansion.

**Conclusions:** It was found that nurses are generally supportive of expanding their professional role in the surgical field, following clarification of the planned changes. Through this process, the team approach in surgical care can be improved, leading to high-quality and safe healthcare, economic benefits, and patient satisfaction.

**Abstract ID: 0170** Specific Field: **Surgical Education**

**Mode of pres.: Free Paper**  
**ISW 2011 Session 171.05**

**Enhancing patient safety and care through advanced post-graduate medical education and training for the injured patients in the Middle East: the Qatar experience**

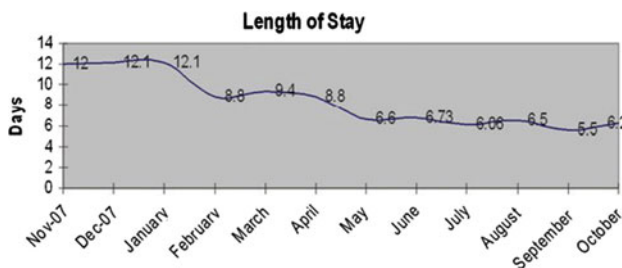
R. Peralta Rosario, H. Al-Thani

Hamad General Hospital, Doha, Qatar

**Introduction:** Trauma is the leading cause of dead in young population in the Middle East region, including Qatar. A significant number of trauma and injured patients will require sophisticated critical care services and a disproportionately high hospital resources are centered within critical care units.

**Aim:** The introduction of an advanced ACGME structured Trauma & Critical Care (TCC) Fellowship Program at the Hamad General Hospital in Doha, Qatar will enhance patient safety, medical care and professional satisfaction.

**Material and Methods:** A review of the clinical impact of the TCC Fellowship Program in the trauma service at the Hamad General Hospital, the only tertiary and national trauma center in Doha, was conducted after the first year of implementation as part of the effort of improving the care of the severe injured patients in Qatar, using tools



**Figure:** Results: reducing average length of stay for trauma patients in Qatar

from the ICU Resource, Evaluation, and Patient Outcomes Rating Tool (ICU Report)<sup>®</sup> developed by The Society of Critical Care Medicine.

**Results:** Since the implementation of the TCC Fellowship Program in 2008, structured educational and training curriculum have been implemented for physicians assigned to the trauma service at the Hamad General Hospital. Three fellows have successfully completed the program and graduated. A significant decrease of hospital length of stay have been observed in our trauma service. Two fellows have been promoted to consultant level and one to critical care teaching staff, enhancing staff satisfaction and the overall score of our Trauma ICU.

**Conclusions:** Advanced post-graduate medical education and training program in trauma & critical care medicine have significant contributed to patient safety and outcome of the critically injured patients in Qatar and have enhanced the overall performance of our trauma service and staff satisfaction. The fellowship program is expanding to other disciplines, and is enrolling candidates in Emergency Medicine and Anesthesia in our institution and is impacting in the healthcare delivery of the complex injured patients in the country.

**Abstract ID: 0171** Specific Field: **Surgical Education**

**Mode of pres.: Free Paper**  
**ISW 2011 Session 171.06**

**The Student Surgical Society: the South African experience**

D.M. Favara, D. Kahn

Department of Surgery, University of Cape Town, Cape Town, South Africa

**Introduction:** The UCT Surgical Society is a medical student-managed academic society which promotes undergraduate interest in the field of Surgery at the University of Cape Town. It is Africa's first student surgical society, and with currently close to 800 registered members in 2010, has grown to become one of the largest academic medical-student organisations in South Africa, and one of the largest student surgical societies in the world. This paper details the Society's activities and explores its benefit to the medical student, and also outlines a framework which medical students may use when creating similar societies at their home institutions. The authors hope that the story of the UCT Surgical Society will inspire the formation of similar groups elsewhere in Africa and the world.

**Abstract ID: 0172** Specific Field: **Transplantation**

**Mode of pres.: Nyhus Prize Session**  
**ISW 2011 Session 95.04**

**Laparoscopic-assisted living donor hepatectomy**

M. Takahashi, H. Nitta, G. Wakabayashi

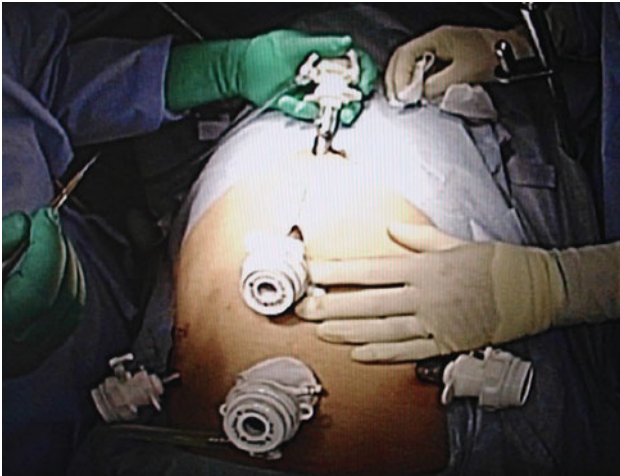
Iwate Medical University of Medicine, Morioka, Japan

**Introduction:** Because of cadaveric organ donors are not available, living donor liver transplantation has been developed in our country. For the purpose of improving the postoperative quality of life of donor, we developed an original procedure of laparoscopic donor hepatectomy. We describe to assess the safety, feasibility and short-term outcomes of our procedure.

**Material and Methods:** Since 2007, 26 donors underwent laparoscopic-assisted hepatectomy in our institution for liver transplantation.

**Results:** The median age was 34.8 years. The types of liver resection consisted of the following: right hepatectomy ( $n = 15$ ), extended right hepatectomy ( $n = 3$ ), left hepatectomy ( $n = 4$ ), extended left hepatectomy ( $n = 2$ ), left lateral segmentectomy ( $n = 2$ ). The median operating time was 377.7 min and median blood loss was 267.5 ml. Three donors experienced postoperative complication which was bile leakage and wound infection. No patient required reoperation. The median postoperative hospital stay was 9 days. About 70% of donors are pleased with their surgery.

**Conclusions:** Laparoscopic-assisted living donor hepatectomy can be safely performed without increasing operative risks. Complication rates are equivalent to open living donor hepatectomy. This surgery is useful in improving the postoperative quality of life of donors.



**Figure:** Ports position of pure laparoscopic surgery

**Abstract ID: 0173**      Specific Field: **Transplantation**

**Mode of pres.: Free Paper**  
**ISW 2011 Session 99.03**

**The outcome of the modified portal vein anastomosis for biliary atresia patients with portal vein thrombosis or stenosis before living donor liver transplantation**

T. Matsuura, Y. Yanagi, I. Saeki, M. Hayashida, T. Taguchi

Kyushu University, Japan

**Introduction:** Portal vein reconstruction is a crucial factor affecting the outcome of a successful living donor liver transplantation (LDLT). Pre-existing portal vein thrombosis (PVT) or portal vein stenosis (PVS), a common complication of end stage liver disease especially in small children, often need the surgical challenging technique for portal vein reconstruction. We reviewed retrospectively the outcome and risk factors for post-transplant PVT in LDLT patients with PVT/PVS.

**Material and Methods:** A total of 57 LDLT cases (10 adult cases, over 18-years-old; 47 child cases) were performed between October 1996 and December 2010 at our department. The number of cases with pre-existing PVT/PVS and using modified portal vein anastomosis (m-PVa) was 16 cases (28%) (adult in 1 case; children in 15 cases). The maneuver of m-PVa was classified into 3 groups; with patch graft (Type-1), with interposition graft (Type-2), and with using of huge collateral shunt vessels (Type-3). The reconstruction patterns were evaluated among age of recipients, type of using graft vessels, post-operative portal vein flow, and post-operative complication rate.

**Results:** The primary disease was biliary atresia in all cases with m-PVa. Nine cases (56%) had episodes of the treatment for portal hypertension before LDLT. The mean age at LDLT was 7.4-years-old. The methods of m-PVa were Type-1 in 10 cases, Type-2 in 3 cases, and Type-3 in 3 cases. The using vessel graft in Type-1 was donor inferior mesenteric vein (IMV) in 8 cases and jugular vein in 2 cases. That in Type-2 was IMV in 2 cases and saphenous vein in 1 case, and in Type-3 was reno-portal, gonadal-portal, and coronary-portal anastomosis, respectively. Post-operative portal vein flow (PVF: ml/min/100 g liver) was sufficient in all types and slightly high flow volume was obtained in Type-3 (mean PVF: Type-1; 177, Type-2; 132, Type-3; 291). The post-operative PV complications were occurred Type-1 in 20%, Type-2 in 33%, and Type-3 in 0%.

**Conclusions:** The m-PVa was effective maneuver to overcome the operative difficulty and post-operative complications. The pre-transplant planning for the selection of type of reconstruction to obtain sufficient portal reperfusion is important for success in LDLT for recipients with PVT/PVS.

**Abstract ID: 0174**      Specific Field: **Transplantation**

**Mode of pres.: Free Paper**  
**ISW 2011 Session 99.04**

**Retroperitoneoscopic right nephrectomy for living donor kidney transplant**

H. Zhou, W. Wang, Y. Wang, G. Wang, B. Gao, Y. Fu

First Bethune Hospital of Jilin University, Changchun, China, People's Republic

**Introduction:** laparoscopic living donor nephrectomy has been shown to decrease hospital stay, reduce blood loss, and hasten recovery of normal activities of donors. But most of laparoscopic living donor nephrectomies have been performed on the left side because the shorter length of the right renal vein poses technical challenges for the transplant surgeon in implanting the renal graft into the recipient. The aim of this study is to report our experience for retroperitoneoscopic right nephrectomy for living donor transplant.

**Material and Methods:** From January 2010 to January 2011, 15 right living donor nephrectomies for transplantation were performed by the retroperitoneoscopic approach at our department. Under general anesthesia, the patients were placed in the left lateral position. After infusion of 600 ml physiologic saline, a retroperitoneal space was made by a self-made dilation balloon. Three Trocars were placed to set up channels as described previously. After breaking through the perirenal fascia, the renal artery, renal vein and ureter were carefully mobilized. After the ureter was cut, a 8 cm skin incision was made along the axillary line. Thereafter, the dominant hand was inserted into the retroperitoneal space. After the renal hilum was controlled by the hand, the renal artery was ligated by two Hem-o-lock clips. And Sastinsky clips were used to clamp some parts of the inferior vena cava (IVC). Finally, the kidney was swiftly removed from the incision and immediately kept in ice saline for transplantation.

**Results:** The 15 retroperitoneoscopic living donor right nephrectomies were performed successfully. The time of these operations ranged from 55 to 75 min, and warm ischemia time of the graft varied from 55 to 105 seconds. The mean intraoperative blood loss ranged from 35 to 65 ml. The patients are allowed to drink at the same day of operation, mobilized after 12 h, and discharged on postoperative day 4. The postoperative hospital stay ranged from 4 days to 6 days. No complications were found in all the donors.

**Conclusions:** Retroperitoneoscopic right nephrectomy for living donor transplant is a safe and feasible procedure with an excellent postoperative course for the donors.



**Abstract ID: 0175**      Specific Field: **Transplantation****Mode of pres.: Free Paper**  
**ISW 2011 Session 99.05****Mechanism of donor-specific B-cell tolerance after ABO-incompatible infant liver transplantation**

Y. Fuchimoto [1], Y. Yamada [1], K. Hoshino [1], M. Tanabe [1], S. Kawachi [1], Y. Kitagawa [1], H. Ohdan [2], Y. Morikawa [1]

[1] Keio University School of Medicine, Tokyo, Japan, [2] Hiroshima University, Hiroshima, Japan

**Introduction:** ABO-incompatible liver transplantation is often performed because of organ shortage. Production of anti-donor blood type antibodies (Abs) is suppressed following ABO-incompatible liver transplantation in most cases, while non anti-donor blood type Abs still persist. This phenomenon suggests the development of donor blood type antigen-specific B-cell tolerance. Previous reports of B-cell tolerance following ABO-incompatible transplantation were limited to infant heart transplantation. We investigated the mechanism of development of such B-cell tolerance after ABO-incompatible infant liver transplantation using in-vivo humanized mouse models.

**Material and Methods:** We studied 4 recipients (A to O in 2, B to O in 2 cases) aged around 1 year old when they received the grafts. In order to investigate the immune responses to the donor blood type antigens, we inoculated the peripheral blood mononuclear cells (PBMCs) of the recipients into NOD-SCID $\gamma$ -null mice (human PBMC-NOG mice) and immunized the mice with the donor blood type antigens. Flow cytometry was performed for phenotyping to confirm the human cell engraftment and ELISA for detection of the human anti-A Abs, anti-B Abs and total immunoglobulin produced in the mice.

**Results:** All mice were successfully engrafted with the human PBMCs as determined by FACS and ELISA. In the mice inoculated with the PBMCs from recipients and immunized with the donor blood type antigens, no anti-donor blood type human Abs were detected despite the production of human immunoglobulins against other antigens.

**Conclusions:** In this study, we provide evidence of B-cell tolerance to blood group antigens. Deletion is the primary mechanism of suppression of antibody production in infant liver transplantation as well as heart transplantation.

**Abstract ID: 0176**      Specific Field: **Transplantation****Mode of pres.: Free Paper**  
**ISW 2011 Session 99.06****Intraportal infusion technique as a novel therapy to avoid graft loss to living donor liver transplantation for infantile fulminant hepatitis**

K. Hoshino, M. Mori, Y. Yamamoto, N. Shimojima, Y. Fuchimoto, M. Tanabe, Y. Kitagawa, Y. Morikawa

Keio university, school of medicine, Tokyo, Japan

**Introduction:** The prognosis of Infantile fulminant hepatitis is extremely poor. More than half of these patients fail to survive in early period after transplantation due to severe liver dysfunction possibly because of severe cellular and/or humoral rejection.

**Material and Methods:** Three pediatric (less than 12 months of life) patients underwent living-donor liver transplantation. The antirejection therapy included systemic triple immunosuppressive regimen with tacrolimus, methylprednisolone, and mycophenol mofetil. In addition to these conventional approaches, we performed intraportal infusion therapy after transplantation with methylprednisolone and prostaglandin E1.

**Results:** With our protocol, the postoperative courses of all three children were uneventful. There were no evidence of rejection or severe vascular complications throughout the postoperative course. Biliary complications were transient. The patients have now survived 30, 24 and 22 months posttransplantation and have regained normal life activity with good liver function. In contrast, only 2 patients survived after living donor liver transplantation out of five patients without intraportal infusion therapy. Three patients failed to survive in spite of administration of OKT-3 as anti-rejection therapy.

**Conclusions:** Our experience has shown the feasibility of preventing rejection and other complications in liver transplantation for infantile fulminant hepatitis under intraportal infusion therapy.

**Abstract ID: 0177**      Specific Field: **Transplantation****Mode of pres.: Free Paper**  
**ISW 2011 Session 99.07****Reconstruction of the hepatic sinusoid with decellularized liver matrix scaffold and mesenchymal stem cells**

Y. Kadota, H. Yagi, M. Shinoda, O. Itano, S. Kawachi, M. Tanabe, M. Ueda, Y. Kitagawa

Keio University, Tokyo, Japan

**Introduction:** To determine if the co-culture of liver cells with MSCs (mesenchymal stem cells) and HUVECs (human vascular endothelial cells) can generate liver sinusoid like structure in DLM (decellularized liver matrix) scaffold.

**Material and Methods:** We achieved whole-organ decellularization in rat livers by portal perfusion with SDS, an anionic detergent that lyses cells and solubilizes cytoplasmic components. Then we attempted to seed and culture MSCs and HUVECs via portal vein and followed the cells histologically for up to 5 days about their viability and distributions in DLM. To show the microvascular network was successfully retained, we characterized its perfusion with fluorescent particles. Then we introduced rat hepatocytes and observed the recellularized liver matrix would reconstruct the hepatic sinusoid like structure under the cell-to-cell contact between formerly introduced MSCs and HUVECs.

**Results:** SEM and histological analysis with immunostaining CD31, Lyve-1 and Integrin $\beta$  showed that co-cultured cells partially demonstrated hepatic sinusoid like pattern and preferred to line the smaller vessels expressing cell adhesion molecules. Viability and metabolic function of engrafted hepatocytes was maintained as assessed by albumin production, urea synthesis and cytochrome P450 expression. In addition, we successfully demonstrated the preservation of the three-dimensional liver architecture and functional vasculature with fluorescent particles, which showed less leakage, better microcirculation and vascular integrity.

**Conclusions:** Engineering of an entire liver requires cell interaction of hepatocytes with nonparenchymal cells. Our study demonstrated the possibility of reconstruction of the hepatic sinusoid by the co-culture of MSCs and HUVECs in DLM scaffold. This co-culture method gives better microvascular integrity to the recellularized liver graft, which will provide a better and longer function to this novel liver graft after transplantation.



Abstract ID: 0178 Specific Field: Transplantation

Mode of pres.: Free Paper  
ISW 2011 Session 99.08**The gross classification of hepatocellular carcinoma is a significant predictor for recurrence in patients undergoing living related donor liver transplantation**

T. Toshima, K. Shirabe, Y. Maehara

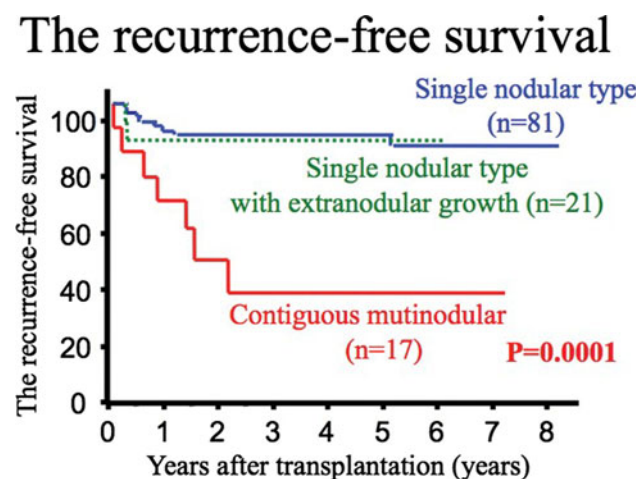
Graduate School of Medical Sciences, Kyushu University, Fukuoka, Japan

**Introduction:** The gross classification of hepatocellular carcinoma (HCC) has been reported to be a significant prognostic factor for patients with HCC undergoing a partial hepatectomy. The present study was conducted to investigate whether the gross classification of HCC is a prognostic factor for patients undergoing living related donor liver transplantation (LDLT).

**Material and Methods:** A series of 119 consecutive LDLT recipients with HCC were reviewed at the Department of Surgery and Science, Kyushu University. According to the gross classification of the largest tumor in the explanted liver, the patients were divided into three groups: type 1 HCC ( $n = 81$ ): single nodular type; type 2 HCC ( $n = 21$ ): single nodular type with extranodular growth; and type 3 HCC ( $n = 17$ ): contiguous multinodular type. The clinicopathological factors and recurrence-free survival rates were compared among the three groups.

**Results:** The recurrence-free survival rates of the 119 patients were 87.7% at 1 year, 83.5% at 3 years and 81% at 5 years after LDLT. Type 3 HCC was correlated with large tumor size, poor histological grade and high incidences of microvascular invasion and multiple tumors. By multivariate analyses, the independent predictors for poor recurrence-free survival were preoperative serum des-gamma-carboxy prothrombin levels of  $>300$  mAU/ml, presence of microvascular invasion and type 3 HCC.

**Conclusions:** The gross classification of HCC in liver explants after LDLT determined the clinicopathological tumor invasiveness. Type 3 HCC showed marked invasive potential compared with types 1 and 2 HCC. The gross classification of HCC was an independent predictor for HCC recurrence in patients undergoing LDLT.



**Figure:** Comparison of the recurrence-free survival rates after LDLT among the patients with types 1, 2, and 3 HCC

Abstract ID: 0179 Specific Field: Transplantation

Mode of pres.: Free Paper  
ISW 2011 Session 99.09**Liver transplantation for transthyretin systemic amyloidosis disorders: review from The Familial Amyloidotic Polyneuropathy World Transplant Register (FAPWTR)**

S. Yamamoto, H.E. Wilczek, M. Larsson, B.G. Ericson

Department of Transplantation Surgery, Karolinska University Hospital Huddinge, Karolinska Institute, Stockholm, Sweden

**Introduction:** The FAPWTR was established in 1993 to assemble data on orthotopic liver transplant (OLT) recipients transplanted because of transthyretin (TTR) systemic amyloidosis disorders.

**Material and Methods:** By Dec 2009, 1772 patients with 1921 OLTs were reported to the FAPWTR from 70 centers in 18 different countries.

**Results:** Most transplantations were done in Portugal ( $n = 866$ ), France ( $n = 216$ ), Sweden ( $n = 130$ ), USA ( $n = 79$ ), UK ( $n = 78$ ), Brazil ( $n = 76$ ), Spain ( $n = 74$ ) and Japan ( $n = 65$ ). Patients with more than 45 different variants of TTR mutations have been transplanted, the most common being Val30Met (86%) followed by Ser77Tyr, Thr60Ala and Tyr114Cys. 11 were nonTTR variants. 12% of the nonVal30Met patients underwent both liver and heart transplantation compared to 0.1% of the Val30Met patients. NonVal30Met patients had significantly more GI, cardiovascular and extraneurological manifestations than Val30Met patients ( $P < 0.001$ ). After OLT, 80–90% of the ValMet30 patients reported stable or improved clinical symptoms while the rates in nonVal30Met patients was 60–65%. With regard to cardiovascular status, 84% of the Val30Met patients reported stable or improved status versus 64% in non-Val30Met patients ( $P < 0.001$ ). The 5- and 10-year patient survival in Val30Met patients was significantly better than in nonVal30Met patients (5 year 81.1% and 57.5%, respectively,  $P < 0.001$ ; 10 year 72.8% and 43.7, respectively,  $P < 0.001$ ). However, the difference disappeared when analyzing patients transplanted in the last 5 years. For the whole time-period, the analysis revealed modified BMI, disease duration and type of mutation to be independent prognostic factors for patient survival after OLT.

**Conclusions:** OLT in patients with TTR amyloidosis is lifesaving. Val30Met and nonVal30Met TTR mutation differ clinically. FAPWTR data confirm the advantage of early transplantation with patients in better nutritional status. NonVal30Met patients appear more often to receive combined liver-heart transplantation than Val30Met patients, and they show inferior survival when analyzing the whole material. However, the difference in survival disappears when analyzing patients transplanted in the last 5 years. This may be due to better selection criteria for OLT and improved pre- and post-OLT patient management.

Abstract ID: 0180 Specific Field: Transplantation

Mode of pres.: Poster Exhibition only  
ISW 2011 Session PE 106**A case of successful conservative treatment for chylous ascites after living-related liver transplantation**

T. Gocho, K. Yanaga, S. Wakiyama, H. Shiba, R. Ito, N. Tsutsui, Y. Ishida, T. Misawa

Department of Surgery, The Jikei University School of Medicine, Tokyo, Japan

**Introduction:** Chylous ascites is a rare complication after living-related liver transplantation (LRLT). We herein report a successful conservative treatment for chylous ascites after LRLT.

**Material and Methods:** A 46-year-old male suffered from liver dysfunction for 10 years, and was diagnosed as primary biliary cirrhosis at 4 years ago. The patient's model for end-stage liver disease score became 19, and the patient underwent LRLT and splenectomy using the right lobe of his younger sister in October 2010. His postoperative status was uneventful, and oral ingestion was started from the postoperative day (POD) 1. On POD 8, however, drainage fluid from liver-graft inferior surface became cloudy. Because triglycerides of ascites was 106 mg/dl, and Sudan III staining was negative, we diagnosed as pseudo-chylous ascites. On POD 22, cloudiness of ascites increased, and triglycerides in ascites was as high as 1,046 mg/dl, and Sudan III staining became positive.

**Results:** With a diagnosis of chylous ascites, total parenteral nutrition (TPN) was started. On 9 days after starting TPN, cloudiness of ascites decreased, triglycerides in ascites decreased to 93 mg/dl, and oral ingestion was re-started. Chylous ascites did not recur, and the patient was discharged on POD 46.

**Conclusions:** TPN may be regarded as one of useful therapeutic strategies for chylous ascites after LRLT.

**Abstract ID: 0181**      Specific Field: **Transplantation**

**Mode of pres.: Poster Exhibition only**  
**ISW 2011 Session PE 107**

**Hemoadsorption of high-mobility group box 1 in swine acute liver failure model**

R. Nishiyama [1], M. Shinoda [1], M. Tanabe [1], G. Oshima [1], K. Takano [1], S. Kawachi [1], I. Maruyama [2], Y. Kitagawa [1]

[1] Surgery, School of Medicine, Keio University, Tokyo, Japan,  
[2] Department of Laboratory and Molecular Medicine, Kagoshima University, Kagoshima, Japan

**Introduction:** We investigated if the serum level of high-mobility group box 1 (HMGB-1) was increased in a drug-induced acute liver failure (ALF) model in swine, and if the level could be reduced using a new cytokine-adsorbing column.

**Material and Methods:** (i) Establishment of animal model. Adult male swine (Saitama Jikken, Saitama, Japan), weighing 20–25 kg, were injected with D-galactosamine to induce ALF at a dose of 0, 0.2, 0.6, or 1.0 g/kg ( $n = 3$ , respectively). The serum parameters of TB, AST, LDH, and HMGB-1 were determined. Hepatic tissue samples were evaluated by histological examination. Survival was observed for 7 days. (ii) In vitro adsorption study. A multi-cytokine adsorbing column was newly established modifying a commercially available column (CYT-860, Toray Inc. Tokyo, Japan). The plasma samples containing HMGB-1 were incubated with the fibers of column for 2 h. (iii) Extracorporeal perfusion study. The swine model of 0.6 g/kg was subjected to an extracorporeal direct hemoperfusion study. Perfusion was performed for 4 h using the column and the HMGB-1 levels at the inlet and outlet of the column were determined. Survival was observed for 7 days.

**Results:** (i) The levels of TB, AST, and LDH showed significant elevations in the groups of 0.6 and 1.0 g/kg compared with 0 or 0.2 g/kg. Survival study showed that the outcome was dose dependent. Histological examination of the hepatic tissue showed severe hemorrhage and massive hepatocellular necrosis in the groups of 0.6 and

1.0 g/kg. The levels of HMGB-1 were markedly increased in the groups of 0.6 and 1.0 g/kg. (ii) In vitro study showed that the fibers adsorbed  $94.3 \pm 3.1\%$  of HMGB1 (comparison between before and 2 h after incubation). (iii) The hemoperfusion study showed that the level of HMGB-1 was markedly suppressed in the outlet compared to the inlet during the perfusion. There was a tendency that the survival was improved in the group with column compared to without column.

**Conclusions:** We confirmed an increased serum level of HMGB-1 in swine ALF model. The newly established cytokine-adsorbing column reduced the serum HMGB-1 level and may be beneficial for ALF treatment.

**Abstract ID: 0182**      Specific Field: **Transplantation**

**Mode of pres.: Poster Exhibition only**  
**ISW 2011 Session PE 108**

**Experience of six pre-emptive living donor kidney transplantation**

H. Iwamoto

Tokyo Medical University Hachioji Medical Center, Hachioji, Japan

**Introduction:** The hemodialysis and the peritoneal dialysis have been selected by almost a hundred percent as a treatment method of chronic kidney disease of stage 5 in Japan so far. The dialysis of a long term before kidney transplantation causes the adverse effect of the kidney graft and the survival, both in deceased-donor as well as in living donor transplantations. On the other hand, several studies have shown a patient or graft survival advantage of pre-emptive transplantation which is kidney transplantation without hemodialysis mainly from western countries. And the number of these cases increases in Japan. We report on the experience of pre-emptive kidney transplantation (PKT) at our center this time.

**Material and Methods:** Fifty two kidney transplantations have performed at our center between September, 2005 and March, 2009. Of these, we analyze six pre-emptive kidney transplantation. All cases were adult living donor transplantation. Average patient's age was 45.5 years old. All patients were female. Three patient's blood type were compatible and three were incompatible. Original diseases were two IgA nephropathy, one diabetic nephropathy, one chronic glomerulonephritis and two uncertain causes. The immunosuppressive regimen was a combination of methylprednisolone, mycophenolate mofetil, basiliximab, and four cases of tacrolimus and two cases of cyclosporine.

**Results:** The patient and graft survival rate were 100% (mean follow up  $35.7 \pm 15$  months). Average serum creatinine levels were  $0.77 \pm 0.15$  mg/dl when leaving hospital. Average creatinine clearance were  $75.0 \pm 28.9$  ml/min when leaving hospital. Postoperative complications were three cases of cytomegalovirus infection and three acute rejection.

**Conclusions:** Our result was good enough to promote PKT.

**Abstract ID: 0183**      Specific Field: **Transplantation**

**Mode of pres.: Poster Exhibition only**  
**ISW 2011 Session PE 109**

**Efficacy of total pancreatectomy and islet autotransplantation for a patient in pancreatic arteriovenous malformation with acute pancreatitis**

N. Sakata [1], M. Goto [2], F. Motoi [1], S. Yamaguchi [3], H. Hayashi [1], H. Yamaya [4], S. Satomi [4], M. Unno [1]

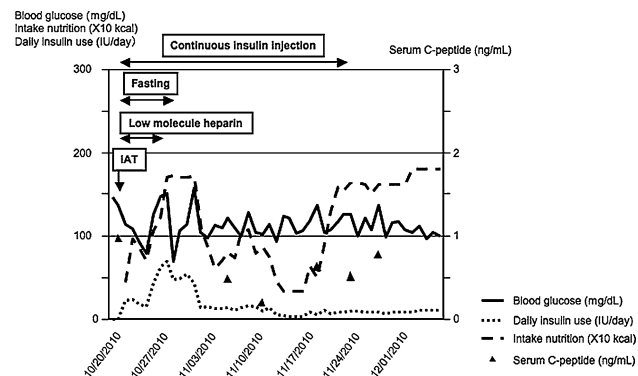
[1] Division of Hepato-Biliary-Pancreatic Surgery, Department of Surgery, Tohoku University Graduate School of Medicine, Sendai, Japan, [2] Innovation of New Biomedical Engineering Center, Tohoku University Graduate School of Medicine, Sendai, Japan, [3] Division of Molecular Metabolism and Diabetes, Department of Internal Medicine, Tohoku University Graduate School of Medicine, Sendai, Japan, [4] Division of Advanced Surgical Science and Technology, Department of Surgery, Tohoku University Graduate School of Medicine, Sendai, Japan

**Introduction:** Pancreatic arteriovenous malformation (AVM) is defined as a vascular anomaly which builds up via an aberrant bypass anastomosis of the arterial and venous systems in the pancreas. Some AVM patients, who were complicated with acute pancreatitis (AP), received surgical resection including total pancreatectomy (TP), but they have to suffer from uncontrollable diabetes mellitus (DM).

**Material and Methods:** A 59-years-old man who diagnosed as AVM referred to our hospital. Abdominal computed tomography (CT) examination revealed that the conglomeration of the small nodular stains in whole the pancreas. We considered TP could not be prevented and thus islet autotransplantation (IAT) should be done to prevent the severe DM. During hospitalization, the patient had abdominal pain and high fever with abnormalities of pancreatic enzymes. Abdominal CT exam at that time revealed formation of new pseudocyst around pancreas and high density area in pancreatic cyst. Due to diagnosis of recurrent of AP with bleeding in the cyst, emergent TP and IAT was performed.

**Results:** Pancreatic necrosis in head and body lesions was detected as intraoperative findings. We performed distal pancreatectomy and pancreatoduodenectomy and transported the pancreas to cell processing center (total pancreas weight was 54 g). We inserted venous catheter for transplantation into main portal vein via round ligament of the liver. Islet isolations were performed by collagenase digestion and purification. The number of acquired islets was 355,270 islet equivalents (IEQ) (6858 IEQ/kg). After certifying no bacterial contamination, we underwent transplantation. After transplantation, the patient received continuous intensive insulin therapy with high total parenteral nutrition under fasting for resting transplanted islets. Oral nutrition was started at POD 10. He has a good control in blood glucose with no hypoglycemic shock, sufficient level of fasting serum C-peptide (>0.5 ng/ml) and low doses of daily insulin need (13 IU/day) at 2 months after transplantation.

**Conclusions:** In conclusion, we succeeded islet autotransplantation first in Japan. It is important for success of islet autotransplantation to demonstrate speciality of each department and cooperate among departments.



**Figure**

**Abstract ID: 0184** Specific Field: **Transplantation**

**Mode of pres.: Poster Exhibition only**  
**ISW 2011 Session PE 110**

**Significance of portal venous velocity in short-term recovery of graft function in living donor liver transplantation**

S. Wakiyama, N. Tsutsui, R. Ito, T. Gocho, H. Shiba, T. Misawa, Y. Ishida, K. Yanaga

Jikei University School of Medicine, Tokyo, Japan

**Introduction:** To evaluate the significance of postoperative portal venous velocity (PVV) in short-term recovery of graft function in living donor liver transplantation (LDLT).

**Material and Methods:** From February 2007 through August 2009, we performed 7 LDLTs, who were included in the present study. The patients ranged in age from 12 to 62 years (median: 45 years), and the male:female ratio was 3:4. The reasons for LDLT consisted of primary biliary cirrhosis in 3 cases, hepatitis C virus-related cirrhosis in 2, biliary atresia in 1, and cryptogenic cirrhosis in 1. Grafts type consisted of the left lobe graft in 5 and the right lobe graft in 2 patients. Doppler ultrasonography was daily performed to measure PVV (cm/s) postoperatively, and liver function parameters such as serum aspartate aminotransferase (AST), alanine transaminase (ALT), total bilirubin (T-Bil), albumin (Alb), prothrombin time (PT), and lactate were also measured. The change of PVV ( $\Delta$ PVV) was defined as follows:  $\Delta$ PVV = PVV on postoperative days (POD) 1–PVV on POD 7. ASTmax and ALTmax, which represents reperfusion injury, were defined as maximal value of AST and ALT 24 h after graft reperfusion, respectively. Correlation analyses were performed as follows: (1) correlation of  $\Delta$ PVV and PVV on POD1 (PVVD1) with the following values such as ASTmax, ALTmax, and liver function parameters on POD7, respectively; (2) correlation of ASTmax and ALTmax with liver function parameters on POD7, respectively.

**Results:** PVVD1 was significantly correlated with ASTmax ( $P = 0.0001$ ), the value of T-Bil ( $P = 0.0078$ ), and the value of PT ( $P = 0.048$ ), while  $\Delta$ PVV was significantly correlated with the value of T-Bil ( $P = 0.0001$ ) and the value of PT ( $P = 0.0109$ ). Also there was significant correlation between ASTmax and the value of T-Bil ( $P = 0.0078$ ) or the value of PT ( $P = 0.048$ ).

**Conclusions:** The present study suggested that PVVD1,  $\Delta$ PVV, and ASTmax were useful parameters for short-term recovery of graft function in LDLT.

**Abstract ID: 0185** Specific Field: **Transplantation**

**Mode of pres.: Poster Exhibition only**  
**ISW 2011 Session PE 111**

**Ischemic postconditioning protective liver from ischemia-reperfusion injury by modulating mitochondrial permeability transition**

H.-C. Lin [1], T.-K. Lee [2], C.-C. Tsai [1], I.-R. Lai [1], K.-S. Lu [1]

[1] Department of Anatomy and Cell Biology, Medical College, National Taiwan University, Taipei, Taiwan, [2] Graduate Institute of microbiology, Medical College, National Taiwan University, Taipei, Taiwan

**Introduction:** Ischemic postconditioning (iPoC), a repetitive, brief ischemia-reperfusion maneuver performed at or before the initiation

of tissue reperfusion, has been shown to mitigate ischemia-reperfusion injury (I/R injury) in heart and brain. The aim of this study is to investigate the effects and protective mechanism of iPoC on liver injury.

**Material and Methods:** Ischemic postconditioning, performed by 3 cycles of one-minute' ischemia-reperfusion of the liver, was tested on a partial liver ischemia-reperfusion model on rats. The serum alanine transaminase (ALT) levels, TUNEL staining, cytochrome c release, and electron microscopy (EM) study were measured in rats with and without iPoC. Atractyloside (ATR), a mitochondrial permeability transition pore (mPTP) opener, was administered in selected groups.

**Results:** Ischemic postconditioning diminished the elevation of serum ALT level 4 h after I/R injury ( $174.0 \pm 28.3$  U/L) ( $P < 0.05$  vs other groups) when compared with control ( $416.3 \pm 16.7$  U/l) and ATR+ I/R group ( $557.0 \pm 86.7$  U/l). Ischemic postconditioning decrease apoptosis after I/R injury as well (apoptotic counts:  $723.3 \pm 98.7/50$  HPF for iPoC,  $1274 \pm 201.2/50$  HPF for control, and  $1057.6 \pm 39/50$  HPF for ATR+ I/R,  $P < 0.05$ ). Ischemic postconditioning decreased the expression of cytochrome c and maintained the morphology of mitochondria intact after I/R injury when compared with other groups.

**Conclusions:** Ischemic postconditioning attenuates cell deaths after I/R injury of liver. The addition of ATR negated the protective effects of iPoC, which indicated that iPoC conferred protection by modulating the opening of mPTP pore.

**Abstract ID: 0186**      Specific Field: **Transplantation**

**Mode of pres.: Poster Exhibition only**  
**ISW 2011 Session PE 112**

**Ischemic postconditioning protective small intestine from ischemia-reperfusion injury by modulating mitochondrial permeability transition**

C.-C. Tsai [1], I.-R. Lai [1], T.-L. Shen [2], H.-C. Lin [1]

[1] Department of Anatomy and Cell Biology, Medical College, National Taiwan University, Taipei, Taiwan, [2] Department of Plant Pathology and Microbiology, National Taiwan University, Taipei, Taiwan

**Introduction:** Ischemic postconditioning (iPoC), a repetitive, brief ischemia-reperfusion maneuver performed at or before the initiation of tissue reperfusion, has been shown to mitigate ischemia reperfusion (I/R) injury in heart and brain. The aim of this study is to investigate the effects and protective mechanism of iPoC on I/R-induced intestinal injury.

**Material and Methods:** I/R was induced by occluding the SMA for 60 min followed by reperfusion for 60 min on male Wistar rats. Ischemic postconditioning was elicited by 3 cycles of 90 s occlusion and reperfusion of superior mesenteric artery (SMA) at the initiation of I/R. Atractyloside (ATR), a mitochondrial permeability transition pore (mPTP) opener, was administered in selected groups. The test rats were randomized into four groups: sham, I/R, I/R + iPoC, and I/R + iPoC + ATR. The serum lactate dehydrogenase (LDH) levels, H&E staining, and expression of intestinal fatty acid binding protein (iFABP) were measured.

**Results:** Ischemic postconditioning diminished the elevation of serum LDH level 1 h after I/R injury ( $826.2 \pm 200.6$  IU/l) ( $P < 0.05$  vs other groups) when compared with I/R ( $2321.7 \pm 887.2$  IU/l) and I/R + iPoC + ATR group ( $2036.5 \pm 1021$  IU/l). Ischemic postconditioning mitigated mucosal damage after I/R injury as well (histopathological score:  $2.5 \pm 0.6$  for I/R+ iPoC,  $4.0 \pm 0.8$  for I/R, and  $3.8 \pm 0.5$  HPF for I/R + iPoC + ATR,  $P < 0.05$ ). Ischemic postconditioning decreased the expression of iFABP in portal blood after I/R injury when compared with other groups.

**Conclusions:** Ischemic postconditioning attenuates tissue injury after I/R injury of small intestine The addition of ATR negated the

protective effects of iPoC, which indicated that iPoC conferred protection by modulating the opening of mPTP pore.

**Abstract ID: 0187**      Specific Field: **Vascular Surgery**

**Mode of pres.: Free Paper**  
**ISW 2011 Session 29.01**

**Results of 54 vascular repairs done on military casualties at army base hospital Palaly and military hospital Anuradhapura**

K.M. Kosala Somaratne [1],

H.M. Thilanka Wasumathi Seneviratne [2], K.J. Senanayake [3]

[1] Teaching Hospital Peradeniya, Peradeniya, Sri Lanka, [2] Base Hospital Gampola, Gampola, Sri Lanka, [3] university of Rajarata, Mihintale, Sri Lanka

**Introduction:** During the last stages of humanitarian operations of Sri Lanka Armed Forces against terrorists of the LTTE, incidence of vascular injuries among military casualties was quite high. This was presumably due to the intense close quarter fighting that took place. We intend to present the results of such 54 vascular injuries managed at military surgical installations from 22nd January 2009 to 16th May 2009.

**Material and Methods:** Almost all injuries were due to T 56 rounds and only a few due to shrapnel from mortar and artillery rounds. 19 patients were having injuries to the upper limb and neck vessels and the rest 35 had injuries to the lower limb vessels. All vascular injuries were repaired with Reverse Saphenous Venous Bypass Grafts (RSVBG). Fasciotomy was performed for all those who presented later than 4 h. Cooling of the limb with ice bags was done for those which were delayed more than 5 h. The diagnosis was confirmed clinically alone. Even when bone fractures were there the vascular repairs were done without orthopedic fixation. All vascular anastomoses were done with 7/0 polypropylene in 13 mm 3/8 circle needle.

**Results:** 53 out of 54 vascular repairs had palpable distal pulses after the completion of anastomosis. In one case of SFA repair pulse reappeared only after 8 h of heparinization (yet had good distal saturation throughout) One SFA repair whose wounds were closed at 48 h was readmitted after 12 days with a pus collection and thrombosis of the graft. All injuries without fractures were started on mobilization at 6 days and discharged at a mean time of 09 days post op.

**Conclusions:** 1. 98% success was achieved in vascular repairs done at military field hospitals with very much limited expertise, instruments and under the pressure of heavy casualty influx. 2. Doing vascular repairs without fixation of fractures was a deviation from the standard practice. 3. Use of 7/0 polypropylene for anastomoses gave leak of proof smooth results with easy handling.

**Abstract ID: 0188**      Specific Field: **Vascular Surgery**

**Mode of pres.: Free Paper**  
**ISW 2011 Session 29.02**

**Pattern of recurrence of lower limb varicose veins post EVLT: a single center experience**

C.-S. Chong, B.-C. Toh, V. Chiang, S.-C. Cheng, C.-W. Lee

Tan Tock Seng Hospital, Singapore, Singapore

**Introduction:** Endovenous Laser Treatment (EVLT) for lower limb varicose veins emerging as a viable alternative to traditional high ligation and stab avulsion has been well documented in the past decade. Recurrence post treatment has been reported as being as high as 20% in 5 years in the literature. By analyzing the recurrence pattern



post EVLT in our institution we hope to elucidate possible factors for failure and at the same time formulate possible salvage strategies.

**Material and Methods:** Retrospective review of all the limbs that underwent EVLT in our vascular surgery unit from the period of Jan 2007 to Oct 2009 was conducted. The median follow up period was 706 days (range 365 to 1202). Recurrence is defined as significant lower limb varices either observed by the clinician or highlighted by the patient (during follow up visits) that were not present in the 30 day period after the 1st EVLT procedure. All recurrences underwent a venous duplex study to define the anatomy of recurrence.

**Results:** In 382 post-EVLT lower limbs, 37 (9.7%) limbs were found to have recurrence. Majority of the patients are female ( $n = 20$ , 83.3%) and median age is 56.5 (range 37–78). Median time to recurrence is 16.9 months (range 4.2–74.2). The recurrence patterns and their respective frequencies are as follows: (1) 11 (29.7%) Long Saphenous Vein (LSV) with incompetent Saphenous Femoral Junction (SFJ), (2) 6 (16.2%) LSV without incompetent SFJ, (3) 9 (24.3%) Short Saphenous Vein with incompetent Saphenous Popliteal Junction (SPJ), (4) 9 (24.3%) incompetent perforators and (5) 2 (5.4%) revascularization of varices from pelvic veins.

**Conclusions:** Recurrent varicose veins post surgery remains a significant clinical problem for the patient despite the 9.7% recurrence rate. The first and second types of recurrences are technically related (45.9%) and potentially treatable with repeat EVLT. In contrast, the third and fourth types (48.6%) of recurrences arose from previously untreated incompetent SPJ and perforators and these are preventable by performing SPJ ligation and perforator transfixation during the initial operation. In Summary, vast majority of recurrences (94.5%) can be prevented by a more complete ablation and treating other causes of venous hypertension during the first intervention. Repeat EVLT is suitable for recurrence secondary to technical issues but the effectiveness of the re-intervention remains to be seen.

**Abstract ID: 0189** Specific Field: **Vascular Surgery**

**Mode of pres.: Free Paper**  
**ISW 2011 Session 29.03**

#### **Embolic complications after endovascular treatment of abdominal aortic aneurysm**

N. Toya, A. Ishida, T. Fujita, T. Ohki

Jikei University School of Medicine, Minatoku, Japan

**Introduction:** The purpose of this study is to present our experience with the incidence, risk factors, and prognosis of embolic event after endovascular aneurysm repair (EVAR) of abdominal aortic aneurysms (AAAs).

**Material and Methods:** We performed a retrospective review of patients who underwent EVAR with the Zenith and the Excluder stentgraft at Jikei University during the last 3 years. A total of 539 patients underwent elective EVAR. We reviewed 438 patients (205 patients with Zenith, 233 patients with Excluder), excluding fenestrated and branched EVAR. Coil embolization of the hypogastric artery was performed as needed.

**Results:** Technical success rate was 91.1% (399/438) with no surgical mortality. The operation time, estimated blood loss, and amount of contrast used were 185 min, 380 ml, and 148 ml, respectively. Embolic complications occurred in 9 patients (2%), in whom bowel ischemia occurred in 4 cases that were successfully treated with bowel rest and hydration, lower extremity atheroembolization occurred in 3, and stroke in one. Two patients (one patient in each group) died of cholesterol crystal embolization. Seven of 9 embolic complications (77.8%) occurred in the Zenith patients. In our study, adjusted risk factor of Cox analysis showed that smoking (HR, 6.05; 95% CI 1.41–25.99;

$P = 0.016$ ) and shaggy aorta (HR, 29.86; 95% CI 7.02–127.04;  $P = 0.000$ ) were an independent predictor of embolic complications.

**Conclusions:** The presence of shaggy aorta and the smoking habit are an independent predictor of ischemic complications following EVAR.

**Abstract ID: 0190** Specific Field: **Vascular Surgery**

**Mode of pres.: Free Paper**  
**ISW 2011 Session 29.04**

#### **Pattern of peripheral arterial disease in Indian scenario**

R. Kaushal, A. Dhar, A. Srivastava, S. Gamanagati, S. Seth, P. Jagia

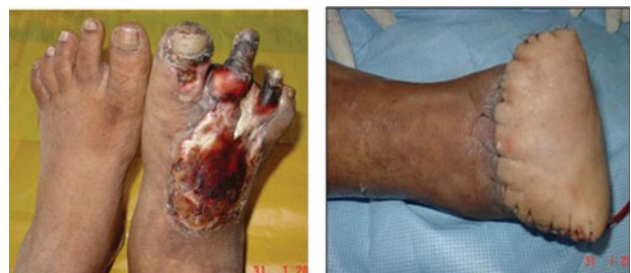All India Institute of Medical sciences, New Delhi, India

**Introduction:** Peripheral arterial disease (PAD) is a common disease, its complications take a great toll in terms of quality of life, and treatment costs. It is commonly neglected, with limited treatment options, however optimal treatment can be individualized for each patient with good results, both in terms of limb and life.

**Material and Methods:** A total of 227 patients of diagnosed PAD were included in this observational study. All patients who appeared in outpatient department with complaints of claudication/rest pain/ulcer/gangrene and diagnosed to have PAD clinically, and radiologically were included in this study. Different risk factors were assessed. Patients were given optimal therapy in the form of medical (foot care, cilostazole, antiplatelet agents), medical with stem cell therapy, and interventional therapy (surgery/endovascular) as per the extent of diseased segment. Outcome was measured with change in pain score (P. S), claudication distance (C.D), ulcer healing, Ankle Brachial Index (ABI) and Transcutaneous pressure of oxygen (TcPO<sub>2</sub>) and followed up for 6 months.

**Results:** The median age was 48 years (range 20–74). Majority 155 (68.3%) patients had chronic critical ischemic limb (CCL) (Fontaine's stage 3 and 4). Majority 40.5% had distal and 25% had diffuse disease. Homocysteine levels were elevated in 12.2% patients. Lipid profile was deranged in 9.2%. Statistically significant difference was seen in P.S, C.D and ABI within all the three therapy groups at 6 months ( $P$  value = 0.001, 0.0001, and 0.001) respectively. Ulcer healing rate was >90% in all the three groups. Significant difference in TcPO<sub>2</sub> was noted in medical and medical with stem cell therapy groups at 6 months ( $P$  value = 0.0001). Statistically significant difference was noted in P.S, C.D, and ABI within the diabetic group at 3 and 6 months ( $P$  value = 0.001). The non diabetic group behaved similarly. Major and minor amputation rate were 7.7 and 27.7% respectively.

**Conclusions:** Bidi smoking was strongly associated with PAD in Indian males. Good individualized optimal care restricted major amputation rate to 7.7% in contrast to 30–40% as reported in world literature in CCL cases. Prompt initiation of medical therapy improves both diabetic and non diabetics foot equally.



**Figure:** Forefoot amputation in gangrene of foot in patient on medical therapy

**Abstract ID: 0191**      Specific Field: **Vascular Surgery****Mode of pres.: Free Paper**  
**ISW 2011 Session 29.05****Supplemental postoperative oxygen in the prevention of surgical wound infection after lower limb vascular surgery: a randomized controlled trial**

J. Turtiainen [1], E. Saimanen [2], T. Partio [3], K. Mäkinen [4], J. Virkkunen [5], K. Vuorio [6], M. Reinikainen [1], T. Hakala [1]

[1] North Karelia Central Hospital, Joensuu, Finland, [2] South Karelia Central Hospital, Lappeenranta, Finland, [3] Mikkeli Central Hospital, Mikkeli, Finland, [4] Kuopio University Hospital, Kuopio, Finland, [5] Central Hospital of Central Finland, Jyväskylä, Finland, [6] Lapland Central Hospital, Rovaniemi, Finland

**Introduction:** Surgical wound infection (SWI) is a common complication after lower limb vascular surgery. Infections increase morbidity and costs of treatment. The aim of our study was to test the hypothesis that supplemental postoperative oxygen decreases the incidence of SWI after lower limb revascularization surgery.**Material and Methods:** This prospective, randomized, multicenter, single-blinded trial was conducted between May 2009 and February 2010 in six secondary referral hospitals in Finland. We randomly allocated 274 patients undergoing surgery for lower limb revascularization to study ( $n = 137$ ) or a control ( $n = 137$ ) group. The study group received supplemental inspired oxygen for the first two days after surgery, the control group breathed room air. There was no difference between groups in regards with demographic or operative data. A majority of the patients were male, mean age was 72 years. The indication for surgery was critical limb ischemia in 61% of cases, and 36% had ischemic ulcer. Antibiotic prophylaxis was standardized. The main outcome was SWI. Patients were followed up for 30 days or until the SWI was healed. Univariate analysis for comparing various characteristics between study and control group were performed using Fisher's exact test and independent samples *t*-test. Logistic regression analysis was used to assess the independent effect of supplemental oxygen on the incidence of SWI.**Results:** Altogether 63 (23%) patients developed SWI. 47 (75%) of infections were superficial. There were two vascular graft infections. SWI occurred in 25 patients (18.2%) in the study group and in 38 patients (27.7%) in the control group [odds ratio (OR) 0.56, 95% confidence interval (CI) 0.30–1.04,  $P = 0.07$ ]. In isolated groin incisions, 3 patients of 52 (5.8%) in the study group and 12 patients of 51 (23.5%) in the control group developed SWI, OR = 0.20, 95% CI 0.04–0.95,  $P = 0.04$ . The most commonly identified bacteria was *Staphylococcus Aureus*. The incidence of major amputation was 2.9% and the 30-day mortality was 1.5%, with no difference between groups.**Conclusions:** There was a tendency that supplemental inspired oxygen decreased the incidence of SWI after lower limb vascular surgery. In isolated groin incisions, the decrease of SWI incidence in supplemental oxygen group was significant.**Abstract ID: 0192**      Specific Field: **Vascular Surgery****Mode of pres.: Free Paper**  
**ISW 2011 Session 29.06****Efficacy of vein bypass grafting to the pedal arteries for limb salvage in diabetic patients**

A. Baumann, J. Fruhmann, T. Cohnert, G. Baumann

Medical University, Graz, Austria

**Introduction:** An aggressive multidisciplinary approach is required to achieve limb salvage in diabetic foot problems. Ischemia, neuropathy, and infection are the three pathologic components that leads to diabetic foot complications and they frequently occur together as an etiologic triad.

The theory of "small vessel disease" was mistakenly ascribed to be the cause of ischemic complications. It is now well-recognized that diabetic patients typically have tibial and peroneal arterial occlusive disease with relative sparing of the foot arteries; and the ischemia results from atherosclerotic macrovascular disease as well as from microcirculatory dysfunction. We reviewed our experience in pedal bypass grafting in 80 patients.

**Material and Methods:** Appropriate evaluation of the pedal arteries with MRA/DSA is mandatory in every patient with diabetes with critical foot ischemia. From 2002 to 2010 we performed at total of 80 pedal autogenous vein bypasses for limb salvage (80% non reversed, 20% reversed). The distal target vessels were in 75% the dorsalis pedis artery and in 25% the posterior tibial artery. In patients with concomitant active infection, the infection was controlled with broad-spectrum antibiotics, open debridement, drainage or partial foot amputation first.**Results:** Primary patency and limb salvage rate were 78.7% and 81.2% at 1 year and 67.5% and 73.75% at 5 years follow up.**Conclusions:** Pedal bypass to the ischemic infected foot in diabetic patients is an effective limb salvage procedure with long-term durability as long as infection is adequately controlled first.**Abstract ID: 0193**      Specific Field: **Vascular Surgery****Mode of pres.: Free Paper**  
**ISW 2011 Session 29.07****Acute mesenteric ischemia: operative results and long-term prognosis**T.U. Cohnert, S. Schweiger, M. Tomka, G. Schramayer, A. Baumann  
Dept. of Vascular Surgery, Graz Medical University, Graz, Austria**Introduction:** Acute mesenteric ischemia is a life-threatening surgical emergency associated with high morbidity and mortality rates. Physical exam, laboratory values and non-invasive imaging may all be non-specific. Treatment includes resuscitation, revascularization and bowel resection. Aim of this study was to analyze our results and to determine long-term outcome in patients surviving the acute event.**Material and Methods:** In 39 patients (pts.) surgery for acute mesenteric ischemia (AMI) was performed between Jan 1988 and Oct 2010 by the Vascular Surgery Department. Prospectively collected clinical data and follow-up were analyzed retrospectively. Statistical data are shown as mean values and standard deviation.**Results:** Of the 39 pts. with a mean age of 71.3 + 11.6 years (range 27–90 years) there were 19 female and 20 male pts. Operative Mortality was 48.7% (19/39 pts). Diagnosis was established by CT angiography, arteriography or laparotomy. Underlying disease was arterial embolism in 27 pts (mortality 40.7% = 11/27 pts) and arterial thrombosis in 12 pts (mortality 66.7% = 8/12 pts). Operative procedures consisted of revascularization without bowel resection in 24 pts (mortality 45.8% = 11/24 pts), revascularization and additional bowel resection in 10 pts (mortality 40% = 4/10 pts), resection without revascularization in 1 patient and exploratory laparotomy without further procedure in 4 pts. Revascularization was achieved by embolectomy/thrombectomy in 28 pts, additional patch implantation in 3 pts and bypass implantation in 3 pts. Second look laparotomy was performed in 5 pts. Postoperatively 3 pts suffered from short bowel syndrome. All pts underwent postoperative anticoagulation. After a

follow-up of 1 to 267 months (mean 62.4 + 79.2 months) 17 pts were alive and well whereas 1 pts. was lost to follow-up. 2 pts had died (1 liver cirrhosis, 1 stroke) during follow-up. The longest surviving patient is alive and well after 22 years and 3 months.

**Conclusions:** Long-term survival in patients after successful revascularization in acute mesenteric ischemia appears not limited. However, perioperative morbidity and mortality rates in patients presenting with this condition are still unacceptably high. Early diagnosis and treatment protocols to avoid delay of revascularization are important to improve prognosis in patients with acute mesenteric ischemia.

**Abstract ID: 0194**      Specific Field: **Vascular Surgery**

**Mode of pres.: Free Paper**  
**ISW 2011 Session 29.08**

**Short-term outcomes of 43 patients with visceral artery aneurysms treated in a high-volume center**

A. Ishida [1], N. Toya [1], T. Fujita [1], T. Ohki [2]

[1] Jikei University, School of Medicine, Tokyo, Japan, [2] Jikei University, School of Medicine, Japan

**Introduction:** The aim of this study is to evaluate the short-term outcomes of 43 patients who underwent open surgery or endovascular treatment because of visceral artery aneurysm (VAA) during the recent 3-year period.

**Material and Methods:** We reviewed preoperative data, operative records and short-term outcomes on 43 patients (18 men/25 women) with a mean age of 60.5 years. The average size of aneurysm was 23 mm in diameter. The origin of aneurysm was splenic artery in 16 cases (37.2%), superior mesenteric artery in 2 (4.7%), celiac artery in 6 (14.0%), hepatic artery in 3 (7.0%), and renal artery in 16 (37.2%). Among the patients, only one patient received emergency treatment for the rupture of splenic artery, elective treatments could be applied to the remaining 42 patients; coil embolization in 22 cases (51.2%), stent replacement and coil embolization in 2 (4.7%), covered stent replacement in 9 (20.9%), and open surgery in 10 (23.3%).

**Results:** Coil embolization was performed in all splenic artery cases, while all superior mesenteric aneurysms required open surgery. For 6 patients with celiac artery aneurysm, covered stent replacement was used in 2 and open surgery was performed in 4. For 3 patients with hepatic artery aneurysm, covered stent replacement was used in 2 and stent replacement with coil embolization was used in 1. For 16 patients with renal artery aneurysm, coil embolization was used in 6, stent replacement with coil embolization in 1, covered stent replacement in 3, and open surgery was performed in 6. The average operative duration and the length of postoperative stay are 130 min and 4.8 days in endovascular treatment group, while 336 min and 12 days in surgical treatment group. Neither major morbidity nor mortality was observed in any case.

**Conclusions:** Our treatment strategies exhibited excellent short-term outcomes of VAAs.

**Abstract ID: 0195**      Specific Field: **Vascular Surgery**

**Mode of pres.: Free Paper**  
**ISW 2011 Session 29.09**

**Treatment of visceral artery aneurysms**

K. Matsubara, H. Obara, S. Ichisaka, T. Fujii, T. Shoji, Y. Kitagawa  
Keio University School of Medicine, Tokyo, Japan

**Introduction:** Visceral artery aneurysms (VAAs) are uncommon but important as they have a significant potential for rupture, resulting in high mortality rates. The purpose of this study was to review our experience with VAA treatment at a single institution.

**Material and Methods:** Between January 1995 and December 2010, 39 VAAs were treated in 36 patients (25 males, 11 females) with mean age of 61 years (range, 21–80 years). Postoperative visceral artery pseudoaneurysms were excluded from this study.

**Results:** The lesion involved the splenic artery (SA; 18), superior mesenteric artery (SMA; 4), hepatic artery (HA; 3), common celiac-mesenteric trunk (CMT; 2), pancreaticoduodenal artery (PDA; 4), celiac trunk (CT; 4), gastroduodenal artery (GDA; 3), and renal artery (RA; 1). Three patients had multiple aneurysms, and one patient (PDA) had ruptured. 18 patients had endovascular procedures, 17 patients underwent open surgical repair, and one patient underwent embolization with bypass surgery. In the endovascular group, VAAs were treated by embolization ( $n = 16$ ), covered stent placement ( $n = 1$ ), and covered stent placement with embolization ( $n = 1$ ). In the surgical group, VAAs were treated by splenectomy ( $n = 4$ ), nephrectomy ( $n = 1$ ), aneurysmectomy ( $n = 2$ ), aneurysmorrhaphy ( $n = 2$ ), and aneurysmectomy with arterial reconstruction ( $n = 8$ ). The results were satisfactory enough with no severe perioperative complication or death, but one patient (PDA) had a duodenal stenosis, which resolved with conservative management. No aneurysm reperfusion or enlargement was observed at follow-up.

**Conclusions:** Our study suggests that an aggressive treatment of VAA is justified, even in the case of asymptomatic VAA, because of the low morbidity and mortality rates. Endovascular management of VAA is a reasonable and preferable alternative to open surgical repair in anatomically suitable patients. Regardless of the type of intervention, it is critically important to assess and maintain end organ perfusion via adequate collateral circulation or direct revascularization.

**Abstract ID: 0196**      Specific Field: **Vascular Surgery**

**Mode of pres.: Poster Discussion**  
**ISW 2011 Session 60.04**

**Successful endovascular treatment of hemosuccus pancreaticus due to primary splenic artery aneurysm associated with segmental arterial mediolysis**

T. Fujii, H. Obara, K. Matsubara, S. Ichisaka, T. Shoji, Y. Kitagawa  
Keio University School of Medicine, Tokyo, Japan

**Introduction:** Hemosuccus pancreaticus (HP) bleeding through the pancreatic duct into the duodenum, is a rare cause of intermittent gastrointestinal hemorrhage. Segmental arterial mediolysis (SAM) is a rare, non-atherosclerotic, non-vasculitic arteriopathy of unknown cause characterized by development of a dissecting hematoma, aneurysm, occlusion, and hemorrhage. We describe a case of HP due to primary splenic artery aneurysm associated with SAM which was successfully treated by staged endovascular treatment (EVT) using coil embolization and stent-grafting.

**Results:** A 54-year-old man with a huge splenic artery (SA) aneurysm was referred to us from another hospital for evaluation of several episodes of melena from an unknown source. Both an upper gastrointestinal endoscopy and a colonoscopy were unremarkable at the hospital. A computed tomography (CT) scan showed a large 5-cm saccular aneurysm of the SA that is indistinguishable from the distal part of the pancreatic body, a 2.5-cm fusiform aneurysm with a focal dissection arising from the origin of the celiac artery (CA), and small fusiform aneurysms (<1.5 cm) of the superior mesenteric artery



(SMA) containing regions of stenosis in the proximal portion. Magnetic resonance imaging (MRI) revealed the pseudoaneurysm of the SA eroding a dilated main pancreatic duct filled with a blood clot. Analysis of these data led to the likely diagnosis of HP on the basis of the huge aneurysm of the SA associated with SAM. Two-staged endovascular treatment was performed with coil embolization and a stent graft. Firstly selective transcatheter arterial embolization of the SA and the CA was performed, and thereafter Inflow to the pseudoaneurysm of CA was excluded by placing a stent graft at the CA orifice in the abdominal aorta. Postprocedural angiography showed total occlusion of the aneurysmal cavity, and but regular retrograde filling of the stomach, liver, and spleen by branches originating from the SMA was also confirmed.

**Conclusions:** To our knowledge, a successfully treated case of HP caused by SAM has not previously been described. Diagnosis of HP is often difficult and delayed, as bleeding is usually intermittent. EVT is a minimally invasive and an effective treatment for controlling hemorrhage in HP.

**Abstract ID: 0197**      Specific Field: **Vascular Surgery**

**Mode of pres.: Poster Discussion**  
**ISW 2011 Session 60.05**

#### **Surgical outcomes in patients with ruptured abdominal aortic aneurysms**

H. Ohkubo, Y. Uchida, Y. Tamura, M. Hirata, M. Watanabe  
Kitasato university, School of Medicine, Sagamihara, Japan

**Introduction:** Surgery for ruptured abdominal aortic aneurysms is difficult because of disorientation, leading to poor outcomes. Our basic policy is to rapidly clamp the abdominal aorta proximal and distal to the aneurysm, exercising adequate care to avoid collateral injuries. We studied recent outcomes after surgical repair of ruptured abdominal aortic aneurysms.

**Material and Methods:** During the 5 years from January 2006 through December 2010, we surgically repaired ruptured abdominal aortic aneurysms in 25 patients (16 men and 9 women) with a mean age of 73.4 years (range, 59 to 87). Severity according to Fitzgerald's classification, based on the intraoperative extent of hematoma, was type 1 in 4 patients, type 2 in 5, type 3 in 12, and type 4 in 3. Nine patients were in shock preoperatively. The surgical approach was laparotomy in all patients.

**Results:** There were 3 surgical-related deaths (12%) The first patient had a type 3 hematoma according to Fitzgerald's classification and died of disseminated intravascular coagulation (DIC) after surgery. The second patient had a type 3 hematoma and was transferred to our hospital because of cardiopulmonary arrest, but died postoperatively, with no improvement in DIC. The third patient had a type 4 hematoma. The superior mesenteric vein and artery were injured during surgery, causing intestinal ischemia. A right hemicolectomy and major enterectomy were performed, but the patient died of multiple organ failure postoperatively. Risk factors for death were preoperative shock ( $P < 0.01$ ) and impaired consciousness ( $P < 0.01$ ) and intraoperative collateral injuries ( $P < 0.01$ ). Bleeding volume and transfusion volume were unrelated to mortality. As for other surgery-related complications, 1 patient with collateral injury of the duodenum required postoperative surgical repair, 1 patient with acute renal failure received dialysis postoperatively but did not require maintenance dialysis, and 1 patient with ischemic colitis responded to conservative therapy.

**Conclusions:** In our hospital, surgical outcomes were good after the surgical repair of ruptured abdominal aortic aneurysms. Good

outcomes are attributed primarily to rapid aortic clamping and the avoidance of collateral injuries during surgery, even in patients with serious circulatory disorders associated with shock or other conditions.

**Abstract ID: 0198**      Specific Field: **Vascular Surgery**

**Mode of pres.: Free Paper**  
**ISW 2011 Session 99.10**

#### **Hepatic artery reconstruction with donor-saphenous vein interposition graft in pediatric living-donor liver transplantation**

H. Obara [1], M. Tanabe [1], K. Matsubara [1], S. Kawachi [1], K. Hoshino [2], Y. Fuchimoto [2], Y. Morikawa [2], Y. Kitagawa [1]

[1] Department of Surgery, Keio University School of Medicine, Tokyo, Japan, [2] Department of Pediatric Surgery, Keio University School of Medicine, Tokyo, Japan

**Introduction:** We report a living-donor liver transplantation (LDLT) of the left lateral liver segment for a pediatric recipient in which revascularization was achieved with interposition of the donor-saphenous vein between the recipient common iliac artery and the graft hepatic artery.

**Material and Methods:** A 20-month-old male patient with biliary atresia was scheduled for LDLT (father as donor) due to progressive cholestatic hepatitis following a Kasai operation. A preoperative contrast-enhanced CT scanning revealed total occlusion of the recipient hepatic artery. Since the recipient splenic and other visceral arteries were too small to supply enough inflow as arterial reconstruction, the donor saphenous vein was used as an interposition graft between the recipient right common iliac artery (CIA), which is approximately 3 mm in diameter, and the graft hepatic artery.

**Results:** Following the anastomosis between the saphenous vein and the recipient CIA in an end-to-side fashion using 7/0 monofilament polypropylene suture under loupe magnification, the saphenous vein was anastomosed to the graft hepatic artery by using an end-to-end anastomosis with interrupted 9/0 monofilament polypropylene suture under a microscope. Postoperative CT angiography showed good patency of both the hepatic artery and the recipient iliac artery. As a preventive measure against hepatic artery thrombosis, intravenous heparin was administered for the first two postoperative weeks. The patient has been observed for 8 months and is doing well.

**Conclusions:** This procedure should be very useful, when there is no recipient visceral artery suitable for the inflow.

**Abstract ID: 0199**      Specific Field: **Vascular Surgery**

**Mode of pres.: Free Paper**  
**ISW 2011 Session 152.07**

#### **Case series of 6 patients with blunt subclavian artery injuries presenting at Tan Tock Seng Hospital, Singapore**

T.H. Loong, M.T. Chiu, V. Appasamy, E.S. Wong, S.J. Punamiya, S.C. Cheng, C.W. Lee

Tan Tock Seng Hospital, Singapore, Singapore

**Introduction:** Subclavian artery injuries are relatively uncommon but when it occurs, early recognition and treatment can play an important role in the eventual outcome. Most subclavian artery injuries occur in the context of trauma. In Singapore, trauma is predominantly the result of motor vehicle accidents or industrial accidents. A recent spate of cases prompted us to review our experience in managing blunt



traumatic subclavian injuries. We present these 6 cases and examine the mechanism of injuries as well as the subsequent management.

**Material and Methods:** We examined the records of 6 patients, who presented over a 2 and a half year period, with blunt trauma and subclavian artery injuries. Data regarding the mechanism of injury, diagnostic imaging modality, extent and nature of the subclavian injury and the subsequent management was recorded and analyzed.

**Results:** In our series the median age is 24 years (range 21–70 years). All the individuals are male. Four patients sustained their injuries as a result of motor vehicle accidents as riders on motorcycles. There were also associated injuries ranging from fractures of ribs and clavicles to brachial plexus avulsions. The vascular injuries ranged from contusion of the subclavian artery to complete transection of the artery. Five of the patients required surgery to restore distal circulation whilst one was treated conservatively due to the presence of good collaterals. The limb salvage rate was 100%. In this case series, there were no mortalities as result of the injuries sustained. Morbidity was predominantly due to the associated brachial plexus injuries.

**Conclusions:** Recognition of subclavian artery injuries requires a high index of suspicion and early arteriography, which will assist in the identification of vascular injury and aid in the planning of surgical repair. In the setting of trauma, access is often hindered by the presence of the protective cervical collar and as such, an infraclavicular approach or via a median sternotomy may have to be considered. Associated brachial plexus injuries also need to be taken into account as this may affect eventual recovery.

**Abstract ID: 0200**      Specific Field: **Vascular Surgery**

**Mode of pres.: Poster Exhibition only**  
**ISW 2011 Session PE 116**

#### Extracranial internal carotid artery aneurism

M.I. Ramirez [1], R.E. Urrutia [1], A.A. Campos [1], M.E. Mellafe [1], CF Ramirez [2], M.I. Ramirez Jr. [1], L. Moyano [1], I.A. Ramirez [3]

[1] Hospital Clinico Universidad de Chile, Santiago, Chile,  
[2] Hospital San Jose, Santiago, Chile, [3] Universidad Mayor, Santiago, Chile

**Introduction:** EXTRACRANIAL INTERNAL CAROTID ARTERY ANEURYSM INTRODUCTION. Extracranial Internal Carotid Artery Aneurysm (EICAA) is a very uncommon disease first described and surgically treated by Sir Astley Cooper in 1808. Due to the potential danger of stroke or rupture with death, this disease must be promptly treated. During long time open surgery was the first choice treatment (at first only ligation and after 1952 resection with arterial reconstruction). In particular cases currently can be useful the endovascular approach.

**Material and Methods:** CASE REPORT. A 56-year old woman with a severe hypertension presented to us with a 3 months history of headaches, dysphagia, and a slowly progressive growing of a pulsatile mass in the left side of the neck. There was no evidence of previous TIA or stroke. Ultrasound imaging and CT angiography showed a 4 cm. aneurysm of the initial part of the left internal carotid artery (Figs. 1, 2).

**Results:** Open surgery was carried out. A big EICAA was found, and a transposition of the external carotid artery to the distal ICA with previous exclusion of the aneurysm and without use of shunt was performed (Figs. 3, 4, 5.). Hystologic study of the specimen showed atherosclerosis (Fig. 6). Surgical outcome was uneventful, and late CT examination showed only expected changes (Fig. 7).

**Conclusions:** DISCUSSION. EICAA is an unusual condition with only few reports in the medical literature, and the atherosclerotic

etiology is the most frequent (60%). EICAA represents approximately 2% of all peripheral arteries aneurysms. Surgery for EICAA constitutes 0, 1 to 2% of all carotid arterial interventions. From the symptomatic EICAA, 60% experiences TIA and 8% obvious stroke. Around 2% experiences rupture, with great mortality and morbidity. Although ultrasound imaging is initially useful, 3D CT angiography and MRI angiography are the definitive diagnostic methods and necessary in planning surgical strategy. Since 1970s reconstruction of the carotid arterial system became the standard treatment modality, through different possibilities: primary end-to-end anastomosis of the ICA, interposition graft (vein or PTFE) or by transposition of the ECA when the common carotid artery is free of disease. Endovascular approach may be used also in appropriate cases as an alternative to surgical therapy.

**Abstract ID: 0201**      Specific Field: **Vascular Surgery**

**Mode of pres.: Poster Exhibition only**  
**ISW 2011 Session PE 117**

#### Observational study on cilostazol in vascular surgical practice: significant impact on walking distance & quality of life in patients

F. Meyer [1], D. Graf [2], B. Panteli [3], D. Adolf [4], H. Lippert [1], Z. Halloul [1]

[1] Dept. of General, Abdominal and Vascular Surgery, University Hospital, Magdeburg, Germany, [2] Dept. of Internal Medicine, Municipal Hospital, Zerbst, Germany, [3] Dept. of Psychiatry, University Hospital, Magdeburg, Germany, [4] Institute of Biometry and Medical Statistics, University Hospital, Magdeburg, Germany

**Introduction:** Aim, to evaluate preliminary results (representative group of exclusively vascular surgical patients) on the effect of Cilostazol (2 × 100 mg; UCB, Mannheim, Germany) used according to its indication (PAOD, stage IIb) in daily clinical practice.

**Material and Methods:** Through a defined study period, all consecutive patients with initiated Cilostazol medication were enrolled plus a minimal observational period of 6 months & a 12-week-study-appointment interval. Primary study end point was the absolute increase of pain-free walking distance (as measured on the treadmill under standardized conditions); secondary end point was change of quality of life (determined semiquantitatively by the requested assessments worse=equal=better). The side effect profile & the spectrum of accompanying diseases with its possible altering impact on the Cilostazol effect were registered.

**Results:** Through 1.5 years, 40 patients were documented (m/f = 23:17 [67.5/32.5%]) with a mean age of 65.7 ± 9.1 (range, 41–88/median, 47.1) years. Accompanying diseases (registration rate, 95%; n = 38): Arterial hypertension (n = 25; 62%), hyper-lipoproteinemia (58%; n = 23), diabetes (28%; n = 11), obesity (25%; n = 10) & nicotine misuse (23%; n = 9) predominated. Treatments last 235 (mean/range, 3–566) day. Overall, there was a continuous prolongation of the walking distance up to 12 months after initiation of Cilostazol. The objective walking distance (treadmill) was 250 m at Time "0", after 3 & 6 months +114 m (P = 0.009) & +157 m (P = 0.001), resp. Quality of life reached a statistically detectable improvement after 6 months. In smokers, there was no significant increase of walking distance detectable. In 11/38 individuals (registration rate, 95%), side effects were reported: Hyperglycemia & tachycardia was found in 2 cases (5.3% each); diarrhoea, anxiousness, headache, changing blood pressure, jaundice, nausea, n = 1. AB index was not a feasible parameter.

**Conclusions:** Cilostazol medication is safe, effective & causes an early increase of the walking distance (after 3 months) as well as a prolonged improvement of the quality of life also in vascular surgical

patients. It can be considered a suitable tool as: (i) Initial step in the sequential therapeutic algorithm in stage IIb of PAOD; (ii) possible therapeutic alternative in exhausted vascular surgical interventions.

**Abstract ID: 0202**      Specific Field: **Vascular Surgery**

**Mode of pres.: Poster Exhibition only**  
**ISW 2011 Session PE 118**

**Clinical outcomes of the arterial reconstruction of the lower limbs for hemodialysis patients with severe ischemia**

H. Harada, J. Matsui

Tokyo Dental College Ichikawa General Hospital, Chiba, Japan

**Introduction:** It is well known that hemodialysis (HD) patients have great tendency to suffer from peripheral arterial disease (PAD). Moreover the need for a major amputation of the ischemic limb is much greater than in non-HD patients with subsequent greater mortality. In this study we examined the results of lower limb arterial bypass surgery for the severe PAD in HD patients.

**Material and Methods:** Between year 2006 and 2009 we have performed 112 lower limb arterial bypass surgeries for the critical limb ischemia (CLI). Patients were divided into two groups: group D (HD patients,  $N = 34$ ) and group N (non-HD patients,  $N = 78$ ). We examined the difference between those groups in the following points: graft patency rates, limb salvage rates, below-the-knee bypass rates and overall survival rates.

**Results:** Median observation periods were 720 days in group D and 585 days in group N (NS). Below-the-knee bypass rate was significantly higher in group D (59%) as compared with group N (24%;  $P < 0.05$ , Fisher's exact test). Nevertheless, graft patency rates were 87% in group D and 92% in group N (NS), and limb salvage rates were 87% in group D and 92% in group N (NS). However, overall survival rate was much lower in group D (44%) as compared with group N (93%,  $P < 0.01$ ).

**Conclusions:** The results show that in HD patients the limb salvage rate and the graft patency rate were as good as in non-HD patients. However, the mortality rate was significantly higher in HD patients showing that surgical revascularization for HD patients may rescue their ischemic limbs but not improve their survival. We conclude that the early detection of, as well as active protection from, the deleterious changes in hemodynamics in lower limbs may be important for the good results in the treatment of PAD in HD patients.

**Abstract ID: 0203**      Specific Field: **Vascular Surgery**

**Mode of pres.: Poster Exhibition only**  
**ISW 2011 Session PE 119**

**Efficacy of endovascular aortic repair in patients with abdominal aortic aneurysms for which endovascular aortic repair is not indicated according to the instructions for use**

M. Hirata, H. Nishimaki, Tamurea Yukio

Kitasato University School of Medicine, Sagamihara, Japan

**Introduction:** Recently, an increasing number of patients with abdominal aortic aneurysms(AAA) have multiple surgical risk factors. Therefore, endovascular aortic repair (EVAR) often has to be performed in patients in whom the procedure is not indicated according to the instructions for use (IFU) of commercially available stent graft. We studied outcomes after EVAR in patients with AAA in whom the procedure was not indicated according to the IFU.

**Material and Methods:** The study group comprised 44 patients who underwent EVAR for AAA from July 2007 to December 2010. The patients were divided into two groups according to whether the stent graft was used according to the IFU (match group,  $n = 21$ ) or not used according to the IFU (out group,  $n = 23$ ). Mortality rates, post-treatment endoleaks, and the presence or absence of an increase in aneurysm diameter were retrospectively compared.

**Results:** Mean age was 76.3 years in both group. Surgical risk factors were present in 95.2% of match group versus 91.3% of the out group. As for additional treatment during surgery, in the match group a proximal stent graft was placed in 1 patient with an endoleak, and a large Palmaz stent was placed in another patient. In the out group, proximal stent grafts were placed in 3 patients and large Palmaz stents were placed in 3 patients because of severe curvature of the proximal aortic neck or endoleaks. Among 7 patients with a narrow access root, 5 received endovascular treatment. Vascular injury did not occur in the out group. In the match group, the external iliac artery was injured in 2 patients, but was treated by the placement of a covered stent graft. As for endoleaks, in the match group 6 patients had type 2 endoleaks, but transcatheter arterial embolisation (TAE) was not required. In the out group, 7 patients had type 2 endoleaks, and 2 required TAE. There were no ruptures or deaths during the early or late periods in either group.

**Conclusions:** In patients with abdominal aortic aneurysms who have surgical risk factors, good treatment outcomes can be obtained by following a detailed treatment plan and closely following up patients, even if EVAR is not indicated according to the IFU of the EVAR.

**Abstract ID: 0204**      Specific Field: **Vascular Surgery**

**Mode of pres.: Poster Exhibition only**  
**ISW 2011 Session PE 120**

**Revascularization of the internal iliac artery during abdominal aortic aneurysm patients with internal iliac artery aneurysms**

H. Maeda

Nihon University Hospital, Tokyo, Japan

**Introduction:** One of the most serious and fatal complications during AAA repair is a colonic ischemia. The purpose of this retrospective study was to investigate efficacy of direct revascularization of Internal Iliac Arterial Aneurysm (IIAA) during AAA repair in the prevention of postoperative colonic and pelvic ischemia.

**Material and Methods:** we reviewed surgical treatment to prevent ischemic colitis following AAA patients with internal iliac artery aneurysm (IIAA). Methods. From 1990 to May 2009, we experienced 443 surgically repaired AAA patients in the elective situation consisted of 385 male and 58 female patients with a mean age of 71.5 year-old. Of those 443 AAA patients, 158 AAA patients with common iliac artery aneurysms (CIAA) and 54 with IIAA were identified respectively. The velocity of Sigmoid colon artery were measured with Doppler ultrasound during operations.

**Results:** Of those 54 AAA patients with IIAA, twenty two patients underwent AAAR with revascularization of inferior mesenteric artery (IMA) and direct revascularization of IIA was in 19 (uni:16.bi:3) included in concomitant direct reconstruction of IIA and IMA in 7 patients and ligation of both IIAs in 8 patients. IIA revascularization without IMA reconstruction were performed in 7 patients. Both IMA and IIA revascularization were not able to perform in 2 patients. One patient (0.2%) died of transmural necrosis of Sigmoid colon although colectomy and colostomy was performed following AAAR.

**Conclusions:** In this series there were lower incident of ischemic colitis following AAAR, so that we performed reconstruction of IMA

or IIA for the patients with absence of adequate flow of internal iliac artery after AAAR.

**Abstract ID: 0205**      Specific Field: **Vascular Surgery**

**Mode of pres.: Poster Exhibition only**  
**ISW 2011 Session PE 121**

**A case of late complication of an inferior vena cava filter associated with caval, aortic, and duodenal perforation**

S. Ono [1], S. Shibutani [1], T. Kakefuda [1], H. Obara [2], Y. Kitagawa [2]

[1] Kawasaki Municipal Hospital, Department of Vascular Surgery, Kanagawa, Japan, [2] Keio University School of Medicine, Department of Surgery, Tokyo, Japan

**Introduction:** Anticoagulant therapy is the conventional treatment for deep venous thrombosis (DVT), and secondary prevention of pulmonary embolism is achieved in many patients. However, the placement of an inferior vena cava (IVC) filter could be appropriate, when warfarin and heparin are contraindicated or ineffective, especially in those patients who are at high risk for major bleeding or need surgery within 2 weeks. On the other hand, insertion of IVC filters may result in clinically significant complications, such as IVC thrombosis and perforation of IVC and adjacent organs.

We report a unique case of multiple late complication of an IVC filter that caused IVC wall perforation, with penetration of the filter's hooks in the aorta, duodenum, and retroperitoneal space.

**Material and Methods:** An 84-year-old woman was referred to our institution because of hematemesis. An IVC filter had been placed at another institution about 35 years earlier because of DVT. A gastro-duodenoscopy was undertaken and revealed what seemed to be a part of the IVC filter protruding into the second portion of the duodenum.

An abdominal computed tomography (CT) scan also revealed that the IVC filter was fractured with multiple perforations of the IVC wall, producing a perforation of the aortic wall with a mural thrombus.

**Results:** Though it is considered that the surgical treatment may confirm the best outcome, the decision was made to manage her conservatively, because she and her families declined surgical intervention. She remained stable for 18 months after discharge. She had no symptom and systemically well with good oral intake.

**Conclusions:** IVC filters may be rarely associated with serious complications that may evolve in an asymptomatic fashion and may be diagnosed late in the follow-up. There may be a role for regular follow up of patients with IVC filters, taking care of unexpected adverse complications. A careful CT scan imaging follow-up should be performed, even in asymptomatic patients. In addition to a careful follow-up, an indication of permanent IVC filter insertion should be strictly determined.

Though it is considered that the surgical treatment guarantees the better outcome, in an asymptomatic case, conservative observation may be an alternative one.

**Abstract ID: 0206**      Specific Field: **Vascular Surgery**

**Mode of pres.: Poster Exhibition only**  
**ISW 2011 Session PE 122**

**Therapeutic usefulness of stent implantation in iliac compression syndrome**

Y. Tamura [1], M. Hirata [1], H. Nishimaki [2], Y. Uchida [1], H. Ohkubo [1], T. Mishima [1], M. Watanabe [1]

[1] Department of Surgery, Kitasato University, School of Medicine, Sagami-hara, Japan, [2] Department of Radiology, Kitasato University, School of Medicine, Sagami-hara, Japan

**Introduction:** Initial and long-term results were studied after stent implantation in patients with iliac compression syndrome.

**Material and Methods:** Heparin was given at a dose of 10 IU/kg/h 24/day. Before CDT, an inferior vena cava (IVC) filter was placed. CDT was performed with the use of a Fountain catheter. The catheter was introduced via the popliteal vein and placed in the superficial femoral artery or iliac vein. Urokinase was infused at a dose of 60,000 to 180,000 units 4/day for 3 days. Subsequently, when the superficial femoral artery or iliac vein was confirmed to be patent on venography, stent implantation was performed. Short-term results were evaluated on the basis of the change in lower limb circumference after CDT and the thrombus disappearance rate. Long-term results were based on the thrombus disappearance rate and the stent patency rate.

**Results:** The mean interval from the onset of symptoms until treatment was  $5.1 \pm 4.6$  days. Wallstents were placed in 8 patients, and Luminexx stents were placed in 6. A temporary IVC filter was used in 2 patients, and a retrievable IVC filter was used in 12; the filter could be removed in 2 patients. As compared with before CDT, the lower limb circumference decreased by  $4.0 \pm 2.9$  cm at the thigh,  $2.7 \pm 2.8$  cm at the lower leg, and  $1.6 \pm 1.8$  cm at the ankle. At discharge, thrombus had disappeared in all patients. At late follow-up, thrombus was still not evident in 10 (71.4%) of the 14 patients. Warfarin was able to be withdrawn in 6 patients. One patient had stent occlusion with angitis.

**Conclusions:** Stent implantation for iliac compression syndrome improved symptoms by reducing lower limb circumference soon after treatment. In the late phase, the stent remained patent for a prolonged period, and the thrombus disappearance rate (71.4%) was good. However, further long-term observations and evaluations are necessary to confirm late-stage effectiveness.

**Abstract ID: 0207**      Specific Field: **Vascular Surgery**

**Mode of pres.: Poster Exhibition only**  
**ISW 2011 Session PE 123**

**Technique for long-term patency of a femorocrural bypass by vasodilation on the distal side**

T. Toyofuku, Y. Inoue, T. Kudo, N. Sugano, M. Jibiki, H. Uchiyama, K. Yonekura, S. Koizumi

Tokyo medical and Dental University, Tokyo, Japan

**Introduction:** A femorocrural bypass procedure is effective for cases of peripheral artery disease accompanied by ischemia; however, compared to above knee bypass, a sufficient patency rate has not yet been obtained. Moreover, stenosis and occlusion are often observed at distal sites relative to the distal anastomosis; hence, it causes the graft patency rate to decrease and a delay in wound healing.

**Material and Methods:** At our hospital, the following measures are taken for long-term patency of bypass: a procedure using nerve block in high risk patients, a tourniquet method by raising the leg, a minimal arterial exposure, use of favorable sites for vein graft, branch ligation using duplex ultrasound, thus creating a shunt in cases of poor run off, graft surveillance by duplex ultrasound every 3 months, ligation of shunts when the maximum systolic velocity decreases. Moreover, from June 2009, balloon angioplasty has been introduced at the distal anastomosis and distal native artery for better long-term patency rate when the femorocrural bypass was failed due to distal native artery stenosis.

**Results:** There were 5 cases in which balloon angioplasty was performed at the distal anastomosis and native artery, and specifically the distal anastomosis included 3 posterior tibial artery, 1 dorsal pedis artery, and 1 peroneal artery. Among those, there were 3 stenosis and 2 post-thrombectomy for graft occlusion. With regard to the duration between the previous surgery and angioplasty, it ranged from 8 to 376 days, and there were patent in 3 cases and 2 occlusions immediately after vasodilation. Among the 2 occlusions immediately after vasodilation, 1 case was a stenosis case. The follow-up period was 197 to 435 days and limbs were salvaged for all cases. Bypass procedures were performed on a total of 23 cases during the same period.

**Conclusions:** Regarding the infrainguinal bypass surgery, and due to the fact that graft failure is directly related to major amputation and given that arterial lesions located at the foot causes delay in wound healing, it is important to ensure good run off at the distal native arteries; furthermore, balloon angioplasty is also considered important regarding better long-term patency. However, abrupt occlusion occurred immediately after angioplasty in one patients. It remains to be determine appropriate indications for balloon angioplasty and it is also important to clarify when it should be performed.

**Abstract ID: 0208**      Specific Field: **Vascular Surgery**

**Mode of pres.: Poster Exhibition only**  
**ISW 2011 Session PE 124**

**Outcomes of percutaneous transluminal angioplasty and stenting in patients with aortoiliac occlusive disease accompanied by total occlusion: efficacy and safety**

Y. Uchida [1], M. Hirata [1], Y. Tamura [1], T. Mishima [1], K. Saitoh [1], H. Okubo [1], M. Watanabe [2]

[1] Kitasato University School of Medicine, Sagamihara, Japan,  
[2] Kitasato University School of Medicine, Japan

**Introduction:** Owing to recent progress in techniques for endovascular therapy, percutaneous transluminal angioplasty/stenting is now becoming a treatment of choice for TransAtlantic Inter-Society Consensus (TASC) type C and type D aortoiliac lesions, for which surgery had been recommended previously. However, patients with total occlusion are at risk for serious complications, potentially precluding limb salvage. The aim of this study was to evaluate the effectiveness and safety of endovascular treatment in patients who had aortoiliac occlusive disease with total occlusion.

**Material and Methods:** From 2006 through 2010, we performed percutaneous transluminal angioplasty/stenting in 149 patients with ischemic symptoms caused by aortoiliac atherosclerosis. Thirty-eight patients had total aortoiliac occlusion. The TASC classification was type B in 20 patients, type C in 5, and type D in 13. Their median age was 70.3 years. Overall, 76% of the patients were men, and 24% were women.

**Results:** Endovascular recanalization was successfully achieved in all but 1 patient with aortoiliac occlusive lesions. The mean ankle brachial pressure index improved from 0.52 to 0.91. As for complications, 5 patients had distal embolization: 2 had minor embolization and were observed, 2 responded to percutaneous transluminal therapy by aspiration thrombectomy combined with catheter-directed thrombolysis, and the remaining patient required bypass surgery. Extravasation occurred in 3 patients: 1 responded to balloon tamponade, and a covered stent was placed at the bleeding site in the other 2 patients. No patient died of complications or underwent lower-extremity amputation.

**Conclusions:** Percutaneous transluminal angioplasty/stenting was safe and provided satisfactory outcomes in patients who had aortoiliac

occlusive disease with total occlusion. We believe that the indications of endovascular treatment can be extended to include TASC type C and type D lesions, many of which are difficult to manage.

**Abstract ID: 0209**      Specific Field: **Cardiac Surgery**

**Mode of pres.: Free Paper**  
**ISW 2011 Session 99.01**

**Miniperfusion (MECC) versus conventional perfusion (CECC) in the prevention of atrial fibrillation after cardiac surgery**

P. Korvenoja, J. Halonen, S. Ellam, J. Hartikainen

Kuopio University Hospital, Kuopio, Finland

**Introduction:** Atrial fibrillation (AF) is the most common arrhythmia after cardiac surgery with an incidence 20–50%. It is associated with postoperative complications, including increased risk of stroke, as well as prolonged hospital stay and increased costs. The aim of the study was to compare miniaturized extracorporeal circulation (MECC) and conventional extracorporeal circulation (CECC) in the prevention of AF after cardiac surgery.

**Material and Methods:** A prospective, randomized, open labelled trial in Kuopio University Hospital in Finland of 58 patients without prior AF or flutter and scheduled to undergo first on-pump coronary artery bypass graft (CABG) surgery. Patients were randomized to CABG surgery with using miniaturized extracorporeal circulation (MECC) or conventional extracorporeal circulation (CECC). The primary endpoint was the occurrence of AF during the hospitalization time.

**Results:** Atrial fibrillation occurred in 7 of 30 (23%) patients in the miniaturized extracorporeal circulation group (MECC) and 13 of 28 (47%) patients in conventional extracorporeal Circulation (CECC) group, ( $P \leq 0.05$ ) There were no statistically significant differences between the groups with respect of age, ejection fraction, pump time, weight, BSA, cross clamp time, diabetes, kreatinin, hemoglobin level and perfusion time. Also the use of intra- and postoperatively administrated red blood cells, vasoactive drugs, intraoperatively administrated cristaloids and postoperatively measured Ck-MBm were lower in patients in MECC group compared with patients in CECC group.

**Conclusions:** The miniaturized extracorporeal circulation (MECC), was effective method in the prevention of postoperative AF after cardiac surgery and it has many potentially advantages compared with CECC treated patients in cardiac surgery.

**Abstract ID: 0210**      Specific Field: **Cardiac Surgery**

**Mode of pres.: Free Paper**  
**ISW 2011 Session 99.02**

**Effect of left ventricular unloading on right ventricular systolic pressure**

T. Omoto, T. Tedoriya, N. Ishikawa, T. Miyauchi, N. Nagano, M. Oi  
Showa University, Tokyo, Japan

**Introduction:** Previous studies have shown that loading on one ventricle alter structure and function of the other ventricle (inter-ventricular interaction), right ventricular (RV) systolic pressure decreases with decrease in left ventricular (LV) end-diastolic volume.



There have been difficulties in demonstrating this phenomenon in patients undergoing mitral valve (MV) operation with tricuspid regurgitation (TR) due to multiple factors which influence RV performance.

**Material and Methods:** We reviewed 36 patients (mean age  $51.1 \pm 16.4$  year-old, 26 male and 10 female) who underwent MV repair due to MV regurgitation who had mild TR preoperatively. Patients with pre- and postoperative atrial fibrillation, ischemic heart disease, pulmonary hypertension and chronic obstructive lung disease were excluded. Assessment of LV end-diastolic dimension (LVDD), end-systolic dimension (LVDS), left atrial dimension (LAD), ejection fraction (EF) and fraction shortening (FS) were performed by trans-thoracic M-mode echocardiography preoperatively and 1 week after the operation. Tricuspid valve pressure gradient (TVPG) by continuous wave Doppler tracing was also assessed.

**Results:** LVDD ( $55.8 \pm 8.0$  mm vs.  $48.0 \pm 8.0$  mm,  $P < 0.001$ ) and LAD ( $43.4 \pm 6.4$  vs.  $38.4 \pm 6.9$  mm,  $P = 0.001$ ) were decreased postoperatively. EF ( $65.6 \pm 7.3\%$  vs.  $53.9 \pm 9.4\%$ ,  $P < 0.001$ ) and FS ( $37.1 \pm 5.8\%$  vs.  $28.7 \pm 7.1\%$ ,  $P < 0.001$ ) were decreased and TVPG ( $24.5 \pm 6.7$  mm Hg vs.  $21.2 \pm 7.2$  mm Hg,  $P = 0.04$ ) was also decreased postoperatively.

**Conclusions:** MV repair resulted in LV volume unloading. Decrease in RV systolic pressure might have been associated with functional and structural changes in LV volume unloading by interventricular interaction.

#### Abstract ID: 0211      Specific Field: Cardiac Surgery

**Mode of pres.: Poster Exhibition only**  
ISW 2011 Session PE 113

##### Intravenous metoprolol versus biatrial pacing in the prevention of atrial fibrillation after coronary bypass surgery: a prospective randomized trial

M. Maarros [1], T. Hakala [2], J. Halonen [1]

[1] Kuopio University Hospital, Kuopio, Finland, [2] Department of Surgery, North Karelia Central Hospital, Joensuu, Finland, Joensuu, Finland

**Introduction:** Atrial fibrillation (AF) is the most common arrhythmia after coronary artery bypass surgery (CABG). Both intravenous metoprolol and biatrial pacing have been reported to be effective AF prophylaxis after cardiac surgery. The purpose of this trial was to compare the efficacy of intravenous (IV) metoprolol and biatrial pacing in the prevention of AF after CABG.

**Material and Methods:** A single centre prospective randomized trial of 160 consecutive patients undergoing their first CABG. Patients were randomized to (1) intravenous metoprolol 1–3 mg per h or (2) biatrial overdrive pacing and oral metoprolol (50–150 mg) daily for 72 h after CABG starting immediately after the surgery. Patients had continuous ECG-monitoring. The primary end point was the first episode of AF.

**Results:** The incidence of postoperative AF in the intravenous and biatrial pacing groups did not differ from each other (14% vs 18%,  $P = 0.66$ ). There were no significant differences between two groups as regards to pre- and perioperative data. Minor technical problems with biatrial pacing wires was noticed, one bleeding from left atria needed suturation. Intravenous use of metoprolol was not associated with significant adverse effects.

**Conclusions:** Intravenous administration of metoprolol is as safe and effective as biatrial pacing and per oral metoprolol in the prevention of AF after CABG.

#### Abstract ID: 0212      Specific Field: Thoracic Surgery

**Mode of pres.: Video**  
ISW 2011 Session 62.07

##### Laparoscopic repair of morgagni hernia

S. Al-Sabah, L.S. Feldman, M.C. Vassiliou, L.E. Ferri, G.M. Fried  
McGill University Health Center, Montreal, Canada

**Introduction:** The laparoscopic approach for repair of Morgagni hernia avoids the morbidity of laparotomy. This video illustrates the case of a 72 years old woman with upper abdominal pain and a large Morgagni hernia was diagnosed on CT scan. The hernia defect was first closed primarily with non-absorbable trans-abdominal sutures and mesh pledgets placed with the aid of a suture passer. Polyester mesh was placed over the primary closure and secured with a combination of tacks (superiorly) and fibrin glue. The patient was discharged on postoperative day-2, and was symptom-free 4 months post operatively. Chest x-ray did not demonstrate any evidence of recurrence. Ten months post-operative the patient had to be operated for gall stone disease, which was an opportunity to demonstrate our previous repair.

#### Abstract ID: 0213      Specific Field: Thoracic Surgery

**Mode of pres.: Free Paper**  
ISW 2011 Session 152.08

##### Feasibility of a simple drainage method after thoracotomy and decortication in cameroonian children with empyema thoracis

B. Ngo Nonga, E. Malonga

Faculty of Medicine and Biomedical Science of Yaounde, Yaounde, Cameroon

**Introduction:** In Cameroon, Thoracic surgery is just evolving and we are still confronted to many difficulties: lack of proper equipment and infrastructures, there are no fibrinolytic drugs available due to their high prices. Forty one children have been referred to us for a life threatening empyema thoracis. All of them underwent thoracotomy and decortication. We used a simple method for drainage.

**Material and Methods:** Retrospective chart review from July 2001 to June 2010 of all cases of children who had a thoracotomy for empyema at the Douala General Hospital and the University Hospital Centre of Yaoundé. We used an endotracheal tube as chest drain and a urinary bag as a collector.

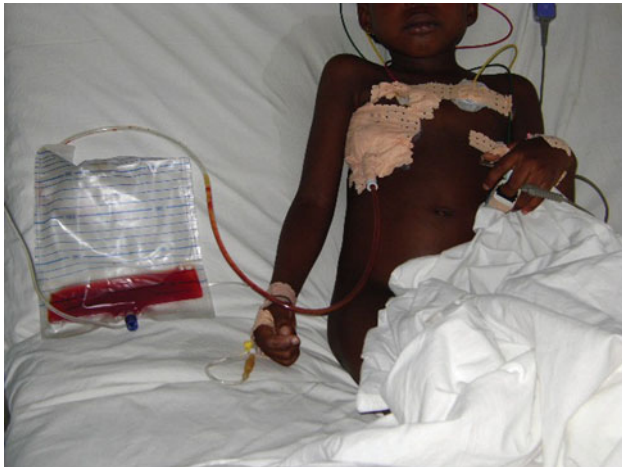**Results:** Forty one children underwent thoracotomy and decortication for empyema, there were 23 boys and 18 girls with a sex ratio of 1, 2. The mean age was 2 1/2 years with a minimum of 1 months and a maximum of 15 years; 27 children were below two years of age. All the patients have received antibiotic for a long period before surgery. The culture was negative except in two cases where we found Klebsiella pneumonia and staphylococcus aureus. In five cases the empyema was due to mycobacterium tuberculosis. Three children presented a complication: one child had a persistent purulent drainage for 2 weeks; another one was reoperated upon because of necrotic lung abscess and one child died of sepsis. In most cases, the chest tube was removed between day 4 and day 6 post operatively. The average length of hospital stay after the surgery was 10 days.

**Conclusions:** Thoracotomy and decortication in children with empyema can be safely done in Cameroon using a simple drainage

system with good results compared to those in the literature. This system can be very useful in other poor countries.

**Table 1** Laboratory values

	Minimum	Maximum
WBC	20200/ml	50700/ml
Hemoglobin	6 mg/dl	11 mg/dl
Platelet	504000/ml	600000/ml



**Figure:** A simple drainage system after decortication in a five years old baby girl

**Abstract ID: 0214** Specific Field: **Thoracic Surgery**

**Mode of pres.: Free Paper**  
**ISW 2011 Session 152.09**

**Bipolar scissors through flexible thoracoscope brings reasonable technical advantages for pure VATS lobectomy**

Y. Yamashita [1], H. Harada [1], K. Misumi [1], H. Mukaida [2]

[1] Kure Medical Center/Chugoku Cancer Center, Kure, Japan,  
[2] Hiroshima City Asa Hospital, Hiroshima, Japan

**Introduction:** To evaluate feasibility of our techniques of VATS lobectomy under monitor-view retrospectively. Especially, we would like to show utility of bipolar scissors and flexible scope.

**Material and Methods:** From April 2003, we performed VATS lobectomy via a pure thoracoscope view (Pure VATS) in 120 cases with cStageIA non-small cell lung cancer (NSCLC). The operative field of the view was accessed strictly via a monitor, thus avoiding spreading intercostal space. A flexible thoracoscope, which can contribute more resolved view, was inserted through the seventh or eighth intercostal space. A 2 to 4 cm minithoracotomy was made by cutting only intercostal muscle as same as the skin incision (2–4 cm) without the use of a rib spreader. The mini-thoracotomy and three other 0.5–1.0 cm ports were added. The operator usually placed on the front of the patients and mini-thoracotomy wound enabled the operator's right hand to hold the bipolar scissors which was useful for

cutting, coagulating and dissecting without switching instruments. The operator's left hand was usually holding pick-up through 5 mm port. Systematic mediastinal lymph node dissection was performed by means of an enlarged clear view in the same extent as the conventional open thoracotomy. Only difference of the technical maneuver from the conventional open thoracotomy was the direction of operator's eyes to the monitor.

**Results:** Average operation time, bleeding count and length of hospital stay were 220 min, 105 g, and 7.2 days, respectively. Only required painkiller for postthoracotomy pain was suppository diclofenac sodium, which was 11.0 mg on average within one week. Five cases (4.1%) were converted to the conventional thoracotomy. Postoperative complication was seen in 10 cases (8.3%), e.g., prolonged air leakage in three cases. Port recurrence was not seen. One case (0.8%) was died of cerebral infarction within 30 days. As to learning curve of this surgical technique, operation time and bleeding count were gradually reduced within the experience of 20–30 case for each surgeon, and then both indicators reached the plateau. Four young surgeons newly learned and completed this procedure until now.

**Conclusions:** Pure VATS lobectomy using bipolar scissors through flexible scope is useful, reasonable and feasible for cStageIA NSCLC.

**Abstract ID: 0215** Specific Field: **Thoracic Surgery**

**Mode of pres.: Poster Exhibition only**  
**ISW 2011 Session PE 114**

**New method for treating intractable postoperative chylothorax and chyloperitoneum**

Y.F. Zhao, Y. Hu, Y. Yuan, T.P. Xie, X. Zheng

West China Hospital, Sichuan University, Chengdu, China, People's Republic

**Introduction:** To confirm the assumption that postoperative chyle leak could be treated with increasing pressure surrounding the break.

**Material and Methods:** 8 patients of chylothorax and 3 patients of chyloperitoneum after esophagectomy were enrolled. Conservative treatment including drainage and total parental nutrition failed in all 10 patients. Secondary thoracic duct ligation given to 4 patients of chylothorax also failed. Low-fat diet was given after enrollment. For chylothorax, except for drainage, intrathoracic injection of 50% glucose solution was given everyday to form adhesion. After 7 days, no matter how much the drainage was, the chest tube was removed and normal diet was given. X ray film was repeated to record the change of the fluid in chest on 0, 2 and 7 days after tube removal. If there's no significant increasing in pleural fluid, the patient would discharge. For chyloperitoneum, abdominal paracentesis was given to reduce ascites as much as possible. Then abdominal bandage was used to limit the expansion of the abdominal wall to the extent that the patient would feel a little short breath. After 2 weeks, we removed the bandage and give the patient normal diet. If the abdomen circumference doesn't increase in 1 week, the patient would discharge. All patients were followed at least 3 months.

**Results:** For chylothorax, the drainage before and after treatment is listed in Fig. 1. 2 days after tube removal, no increasing in pleural fluid was documented in 4 patients. A little increasing was found in other 4 patients. But pleural fluid decreased in all these 4 patients 7 days after tube removal. For chyloperitoneum, no increasing in

abdomen circumference was recorded after removing bandage. And no recurrence of chyle leak was recorded when followed up.

**Conclusions:** For chylothorax, the potential space in thoracic cavity is very limited for the rigid chest wall and the intrathoracic adhesion. When stopping drainage, the pressure surrounding the break will soon increase. For chyloperitoneum, abdominal bandage could easily increase intraabdominal pressure. Once the pressure surrounding the break reaches that in chyle vessel, the leakage of chyle will stop. Then the break will heal. We think any postoperative even traumatic chyle leak could be cured with this method.

### Statistic title:

Drainage of the patients with chylothorax

### Statistic table:

	interval between primary operation and renrollment (day)	drainage at enrollment (ml/day)	drainage when revoving chest tube (ml/day)
case 1	14	800	800
case 2	12	1000	900
case 3	12	1100	900
case 4	7	1200	1000
case 5	11	900	1100
case 6	8	1500	1300
case 7	7	1350	1200
case 8	7	1150	1200

**Fig. 1** Drainage of the patients with chylothorax

**Abstract ID: 0216** Specific Field: **Thoracic Surgery**

**Mode of pres.: Poster Exhibition only**  
ISW 2011 Session PE 115

#### A study of surgical resection of postoperatively detected lung tumor after breast cancer surgery

T. Kiribayashi, S. Kusachi, J. Nagao, Y. Saida, Y. Okamoto, K. Asai, T. Enomoto, H. Nishimuta

The Department of Surgery, Toho University Ohashi Medical Center, Tokyo, Japan

**Introduction:** As metastatic lung tumor after breast cancer surgery has been effectively treated by endocrine therapy or chemotherapy, surgical resection is not necessary first choice. In some cases such as primary lung cancer, surgery might be indicated. In this study, we report cases of surgical resections for postoperatively detected lung tumor after breast cancer surgery with bibliographic consideration.

**Material and Methods:** From January 1989 to December 2010, we performed 943 breast cancer surgery at our institution. Eleven cases of them treated by lung tumor surgery after primary operation were evaluated in this study.

**Results:** The cases of lung tumor surgery included 5 metastatic lung tumor, 5 primary lung cancer and 1 epithelioid granuloma. The mean interval between primary breast cancer operation and secondary operation was 1428.5 days. Based on the 7th edition of classification of lung cancer, 5 cases were determined as T1a (tumor size  $\leq$  2cm) lesions; 3 primary lung cancer and 2 metastatic lung tumor; either case could be applied to curative surgery.

**Conclusions:** In cases that lung tumor was detected during follow-up period of breast cancer surgery, in order to determine pathological diagnosis and the courses of treatment, surgical therapy should be taken into consideration.

**Abstract ID: 0217** Specific Field: **Miscellaneous (Other)**

**Mode of pres.: Free Paper**  
ISW 2011 Session 9.01

#### Is routine early contrast-enhanced CT cost-effective in patients with acute abdomen? A prospective randomized study

T. Lehtim [1], P. Juvonen [2], P. Miettinen [2], I. Ilves [2], S. Kainulainen [1], H. Paajanen [2], H. Valtonen [3], R. Vanninen [1]

[1] Dept of Clinical Radiology, Kuopio University Hospital, Kuopio, Finland, [2] Dept of Surgery, Kuopio University Hospital, Kuopio, Finland, [3] Dept of Health and Social Management, University of Eastern Finland, Kuopio, Finland

**Introduction:** Utilization of computed tomography (CT) in acute abdominal pain has increased rapidly although it is unclear whether routine CT is justified or cost-effective. The purpose of our study was to evaluate the costs of treatment and use of hospital resources comparing routine contrast-enhanced abdominal CT and current standard practice in patients with acute abdominal pain.

**Material and Methods:** Altogether 254 patients with acute abdominal pain admitted to the emergency department were randomly assigned either to (1) early routine contrast-enhanced abdominal CT within 24 h of admission (CT group,  $n = 143$ ) or (2) local current standard practice with imaging based on clinical grounds, e.g. ultrasonography, plain radiographs, CT or none (SP group,  $n = 111$ ). Institutional review board approval and informed consent were obtained. Total costs of treatment were calculated for each patient using actual production costs from hospital registers. Costs include acute care and a three-month follow-up period. Length and cost of hospital stay, number and cost of imaging and other diagnostic, surgical and rehabilitation procedures as well as consultations and contacts at the outpatient department were calculated. *T*-test was used for statistical analysis.

**Results:** The groups were homogenous in terms of age, gender, distribution of diagnoses and mortality. Operation rate was 33% in CT group and 28% in SP group (ns). Total costs of treatment per patient were statistically significantly higher in CT group with a difference of 1218 euro ( $P = 0.003$ ). Imaging costs were statistically significantly higher in CT group both per examination and per patient. There was no significant difference in the number of imaging examinations. Costs of diagnostic procedures other than imaging were significantly higher in CT group. Length of hospital stay was 1.2 days longer in CT group (mean 3.7 vs. 2.5 days,  $P = 0.014$ ). There was no significant difference in daily bed cost. 22% of patients in CT group versus 32% in SP group were discharged from the emergency department (ns).

**Conclusions:** Routine early contrast-enhanced abdominal CT results in higher costs in patients with acute abdomen. There was no single reason (activity type) that explains the cost difference between the groups.

**Abstract ID: 0218**      Specific Field: **Miscellaneous (Other)**

**Mode of pres.: Free Paper**  
**ISW 2011 Session 9.02**

#### **Pre-emptive analgesia in laparoscopic surgery**

C.G. Mixer, A.V. Rayner

Grey Hospital, Greymouth, New Zealand

**Introduction:** Since 1995 a comprehensive program of pre-emptive analgesics has been developed and implemented resulting in a decreased length of stay and increased use of day surgery for laparoscopic surgical procedures.

**Material and Methods:** A registry was prospectively maintained for all laparoscopic procedures in a personal series of over 2000 cases. This included surgery performed in both suburban New Hampshire and rural New Zealand. The registry was analysed regarding age, type of surgery, rural v suburban location and their effect on length of stay, complications and need for readmission.

**Results:** A collaborative plan of care involving non-narcotic analgesia, early ambulation and early feeding is feasible and results in decreased length of stay and early return to activity and work. Outcomes were similar regardless of age, demography, or type of operation. Paramount to the success of the program is avoidance of any narcotic analgesics. Most patients were candidates for use of non-steroidal anti-inflammatory drugs (NSAIDs). Patients receiving narcotics and/or failing to receive pre-operative NSAIDs were over-represented in delayed discharge. When the guidelines for administration of NSAIDs, no complications were reported. Unplanned returns and unplanned readmissions were rare. The model, successful in the US, was adapted for use in an isolated region of rural New Zealand. The pre-emptive analgesia protocol was modified for New Zealand with the addition of paracetamol and preoperative ibuprofen was used rather than intraoperative ketorolac (which is not available). After overcoming initial resistance by nurses and anaesthetists, outcomes mirrored those in New Hampshire.

**Conclusions:** Implementation of an effective pre-emptive analgesia program requires staff education and acceptance of a collaborative plan of care as well as pre-operative teaching of the patients, routine timed administration of non-narcotic analgesics, rapid ambulation, and early feeding. Avoidance of narcotics and early mobilization resulted in improved outcomes with rapid discharge from the hospital

and early return to function and work. Programs must be adapted to local needs. This program could be adapted to a wide range of populations, including countries with limited resources. It is cost effective and decreases the demands for patient care by health care professionals.

**Abstract ID: 0219**      Specific Field: **Miscellaneous (Other)**

**Mode of pres.: Free Paper**  
**ISW 2011 Session 9.03**

#### **General surgical short stay ward initiative: hurdles and achievements**

V.G. Shelat, A. Vijayan, G.S. Tay

Tan Tock Seng Hospital, Singapore

**Introduction:** Health-care delivery is a complex process and institutions are under constant pressure of managing hospital beds. It is possible to increase patient turn-over per bed by reducing the waste and focusing on value added patient care.

**Material and Methods:** Surgical department discharge data was collected from the hospital medical records office for period of two months May–June 2008. Common surgical diseases which resulted in length of stay of less than three days were focused. Value stream mapping and GAP analysis was done by medical, nursing, paramedical and administrative teams. Wastes were identified and specific interventions were planned for coordinated care provision of selected group of patients. Clinical care pathways were developed and nursing staff were empowered in patient management.

**Results:** Out of common surgical conditions resulting in short length of hospital stay, three conditions (acute appendicitis, superficial skin abscess, piles) were identified and clinical care pathways were developed for focused standardized care delivery. Average length of hospital stay was reduced over the time period for all the three conditions. In patient turn-over increased by one third.

**Conclusions:** Clinical care pathway development can provide a standardized care and can result in indirect cost savings by improving the bed turn-over of selected surgical conditions.

**Abstract ID: 0220**      Specific Field: **Miscellaneous (Other)**

**Mode of pres.: Free Paper**  
**ISW 2011 Session 9.04**

#### **Postoperative mortality and complications among surgical patients with schizophrenia: a population-based study**

C.-C. Liao, T.L. Chen

Department of Anesthesiology, Taipei Medical University Hospital, Taipei, Taiwan

**Introduction:** Medical and surgical hospitalizations for persons with schizophrenia have an increased risk of complications. Few studies have investigated the association between schizophrenia and postoperative mortality. To investigate whether schizophrenia is associated with increased risk of postoperative mortality and complications among surgical patients.



**Material and Methods:** In this population-based cross-sectional study in Taiwan, we used data obtained from the National Health Insurance program to identify 12703 surgical patients with schizophrenia during the period 2004–2007 and 50812 controls without mental disorders. The 30-days postoperative mortality and complications including stroke, septicemia, postoperative bleeding, pneumonia, deep wound infection, acute renal failure, acute myocardial infarction, and pulmonary embolism were evaluated.

**Results:** Surgical patients with schizophrenia had higher 30-days mortality and complications compared with controls. After adjustment, patients with schizophrenia were at higher risk of postoperative 30-day mortality (odds ratio [OR] = 2.46, 95% confidence interval [CI] = 1.97–3.08), acute renal failure (OR = 2.11, 95% CI = 1.30–3.44), pneumonia (OR = 2.19, 95% CI = 1.78–2.71), bleeding (OR = 1.23, 95% CI = 1.04–1.47), Septicemia (OR = 1.87, 95% CI = 1.45–2.41), and stroke (OR = 1.18, 95% CI = 1.01–1.37) compared with controls. The estimate risk of 30-day mortality was increased in 40–59 years of age and higher in men than in women.

**Conclusions:** Surgical patients with schizophrenia had higher risk of postoperative complications and at least twice the odds of 30-day mortality than surgical patients without mental disorders.

**Abstract ID: 0221**      Specific Field: **Miscellaneous (Other)**

**Mode of pres.: Free Paper**  
**ISW 2011 Session 9.05**

#### Calculation of post-Operative Risk in Emergency Surgery (CORES)

N. Miyazaki, H. Yoshio

National Hospital Organization Kumamoto Medical Center, Kumamoto, Japan

**Introduction:** Emergency operations, regardless of the types, have considerable risks for postoperative mortality; however, there has been no prediction rule to predict postoperative mortality rates in this setting. This study was undertaken to generate a new prediction rule, CORES, to be applicable to any type of emergency operations.

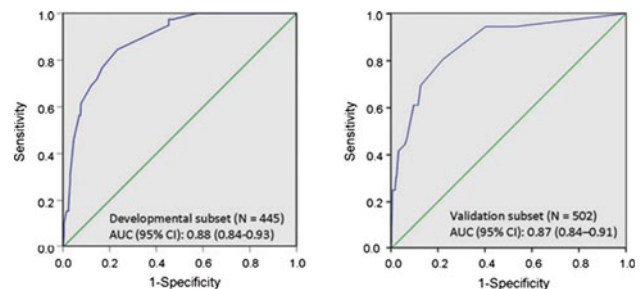
**Material and Methods:** The subjects consist of developmental and validation subsets. Developmental subset include patients over 15 years old who underwent emergency surgery in any types between August 19, 2007 and March 31, 2009 and validation subset include those between April 1, 2009 and September 5, 2010. A prediction rule was generated using logistic regression analysis. Calibration and discrimination power of the predicted in-hospital mortality rates (R) were assessed using the Hosmer-Lemeshow test and area under receiver operating characteristic curve (AUC), respectively.

**Results:** The developmental subset had 445 patients, consisting of 236 patients who underwent general surgery, 70 orthopedic surgery, 43 neurosurgery, 35 cardiovascular surgery and others, with an in-hospital mortality rate of 9.9%. The stepwise analysis selected five independent variables (Table) and provide a equation for R. R had calibration by chi-square value 2.0; df: 8;  $P = 0.99$  and discrimination by AUC (95% confidence intervals) of 0.88 (0.84–0.93) in this subset. The validation subset had 502 patients, consisting of 293 patients who underwent general surgery, 62 orthopedic surgery, 34 neurosurgery, 33 cardiovascular surgery and others, with an in-hospital mortality rate of 7.2%. In the validation subset, R had calibration by chi-square value 3.2; df: 8;  $P = 0.99$  and discrimination by AUC (95% confidence intervals) of 0.87 (0.84–0.91) (Fig. 1).

**Conclusions:** CORES, requiring only 5 variables, demonstrated a high discrimination and validation power. This rule may be helpful for medical decision making, providing informed consent and estimating quality of care in emergency surgery.

#### Logistic regression analysis to detect in-hospital mortality

	Odds ratio	95% CI	P values
Japan Coma Scale $\geq$ 30	3.1	1.0–9.1	0.043
ASA3	7.8	1.7–36.3	0.0084
ASA4	33.2	6.9–160	< 0.0001
WBC < 2500	6.2	1.3–29.4	0.023
PLT $\leq$ 150,000 or $\geq$ 300,000	2.4	1.1–5.4	0.037
BUN $\geq$ 40 mg/dl	3.5	1.3–9.2	0.012



**Fig. 1** ROC curve analysis to detect in-hospital mortality

**Abstract ID: 0222**      Specific Field: **Miscellaneous (Other)**

**Mode of pres.: Free Paper**  
**ISW 2011 Session 9.06**

#### Comparison of the outcome of laparoscopic and opened repair for incisional/ventral hernias

C. Phalanusitthepha, T. Akaraviputh, P. Wathanaoran, T. Parakonthun, A. Trakranga, J. Swangsri, A. Methasate, V. Chinswangwatanakul

Department of Surgery, Faculty of Medicine Siriraj Hospital, Bangkok, Thailand

**Introduction:** Laparoscopic incisional/ventral hernia repair is becoming a promising alternative treatment with many potential advantages, however, this procedure is still under study. Our objective was to compare the results of the laparoscopic ventral hernia repair to the conventional opened repair.

**Material and Methods:** A retrospective analysis of the prospective database of the patients who underwent incisional/ventral hernia repair at Minimally Invasive Surgery Unit, the Department of Surgery, Faculty of Medicine Siriraj Hospital, Mahidol University, Bangkok, Thailand, between August 2007 to December 2009 was performed. Patients' demographic data, perioperative outcome and early post-operative complications were recorded. There were 83 patients with incisional/ventral hernia underwent surgery. Six patients were loss follow-up. There were 2 patients converted to opened surgery because of dense adhesion which didn't include in this study. Of these, there were 75 patients was enrolled in the study, laparoscopic repair was performed in 46 patients (70.8%; group A) and conventional repair in 29 patients (29.2%; group B).

**Results:** The demographic data were not significantly different between the two groups. The overall operative time (OPT) was 78.7 min. (range 30–255). In group A, there was longer OPT (89.4 versus 68 min) but shorter length of stay (LOS) (4.8 versus 6.2 days). Three patients (6.5%) of group A got minor complications such as serosal tear and surgical site infection. Mean follow-up was 29.4 months (range 9.9–42.8). Recurrent rate was found to be not significantly different in both groups (6.8%; A versus 6.5%; B).

**Conclusions:** Laparoscopic incisional/ventral hernia repair can be safely performed with shorter LOS. This might improve quality of life and shorter recovery period of the patients. The long term follow-up is necessary to evaluate an exactly rate of hernia recurrence.

**Abstract ID: 0223**      Specific Field: **Miscellaneous (Other)**

**Mode of pres.: Free Paper**  
**ISW 2011 Session 9.07**

**Long-term outcome of Rives-Stoppa hernia repair combined with cholecystectomy**

M. Aliakbarian, M. Mehrabi Bahar, M. Asadi, M.R. Motie

Surgical Oncology Research Center, Imam Reza Hospital, Faculty of Medicine. Mashhad University of Medical Sciences, Mashhad, Iran

**Introduction:** The use of prosthetic materials in tension-free ventral hernia repairs has diminished recurrence rates markedly. Placing the prosthesis between the rectus abdominis muscle and the posterior sheath, may reduce occurrence of problems as infection, seroma and fistulae formation. Though infection still is the worst complication, frequently requiring mesh explanation. So the question is “Are we allowed to perform cholecystectomy at the same time with RIVES-Stoppa hernia repair?”

**Material and Methods:** This study recruits 20 patients with ventral hernia and cholelithiasis and planned them for both hernia repair and open cholecystectomy simultaneously. All these patients underwent Hernia repair using mesh and gall bladder was removed, they received prophylactic antibiotic and were followed up for three years.

**Results:** During the 2-year period, 12 women and 8 men with mean age of  $51.4 \pm 13.3$  years (range: 24–79 years) underwent the above-mentioned surgery. There were no complication in early post-operative period and follow up continued for 3 years. The prosthetic materials used were polypropylene, and their size ranged from  $30 \times 30$  to  $28 \times 28$  cm.

**Conclusions:** It is safe and cost effective to perform cholecystectomy simultaneously with RIVES-Stoppa. It doesn't increase infection and recurrence rate.

**Abstract ID: 0224**      Specific Field: **Miscellaneous (Other)**

**Mode of pres.: Free Paper**  
**ISW 2011 Session 9.10**

**Tissue glue versus absorbable sutures for mesh fixation in Lichtenstein hernia repair performed in local anaesthesia: a prospective randomized multi-centre trial**

H. Paajanen [1], K. Jyrki [2], T. Hakala [3]

[1] Kuopio University Hospital, Kuopio, Finland, [2] Päijät-Häme Central Hospital, Lahti, Finland, [3] Pohjois-Karjala Central Hospital, Joensuu, Finland

**Introduction:** Chronic pain may be a long-term problem related to mesh fixation and operative trauma in Lichtenstein hernioplasty. The aim of this study was to compare the feasibility and safety of tissue cyanoacrylate glue versus absorbable sutures for mesh fixation in Lichtenstein hernioplasty.

**Material and Methods:** Lichtenstein hernioplasty was performed under local anaesthesia in 302 patients as day-case surgery in three hospitals. The patients were randomized to receive either an absorbable polyglycolic acid 3-0 sutures (Dexon<sup>®</sup>, 151 hernias) or 1 ml of butyl-2-cyanoacrylate tissue glue (Glubran<sup>®</sup>, 151 hernias) for lightweight mesh (Optilene<sup>®</sup>) fixation. Wound complications, pain, patients discomfort and recurrences of hernias were followed at day 1, 7, 1 month and 1 year after surgery.

**Results:** The duration of the operation was  $34 \pm 12$  min in the glue group and  $36 \pm 13$  min in the suture group (ns). The need for analgesics was also similar during the first 24 h after surgery. Five (3.4%) wound infections and 2 (1.4%) recurrences were detected in the glue group and 2 wound infections and 2 recurrences in the suture group (ns). A feeling of a foreign object, sensation of acute and chronic pain and patient's discomfort were quite similar in both study groups. Logistic regression analysis showed that type of mesh fixation did not predict chronic pain after one year of surgery.

**Conclusions:** Mesh fixation without sutures in Lichtenstein hernioplasty is feasible without compromising postoperative outcome. Clinical trials.gov protocol record NCT00659542.

The data of patients after 12 months

	Suture fixation (n = 142) (%)	Glue fixation (n = 144) (%)	P
Recurrence	2 (1.4)	2 (1.4)	ns
VAS > 2	22 (15)	29 (20)	ns
Not satisfied	7 (4.9)	9 (6.2)	ns

**Abstract ID: 0225**      Specific Field: **Miscellaneous (Other)**

**Mode of pres.: Free Paper**  
**ISW 2011 Session 31.01**

**Transverse abdominis block through the incision site: an easy and effective technique for post operative analgesia in open appendicectomy**

W.S.M.K.J. Senanayake, P. Pitigala Arachchi

Faculty of Medicine and Allied Health Sciences Rajarata University of Sri Lanka, Sri Lanka

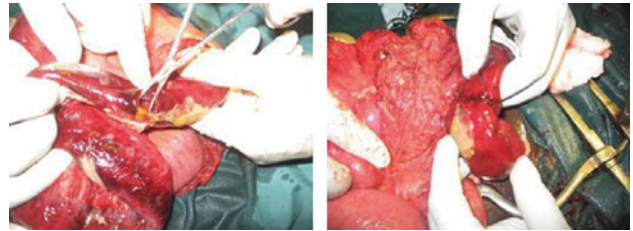
**Introduction:** Transversus Abdominis Plane (TAP) Block is a new technique, described for the pain relief in abdominal surgeries. The technique provides highly effective analgesia for the first 24 h after surgery. The injection of local anesthetic to the transversus abdominis plane is done by land mark guided technique or the ultrasound guided technique. The land mark guided technique is a blind procedure and as a result the anesthetic agent may not deposit in the correct plane. The ultrasound guided technique is operator dependent and the facility may not be available in many centers. During the Appendicectomy, the incision passes through the TAP and we used this as an opportunity to deposit the local anesthetic to TAP. The aim of this study is to evaluate the efficacy of this Intra-Operative Incision Site TAP Block in Appendicectomy as a novel technique of post operative analgesia.

**Material and Methods:** A case control study was conducted. Twenty six patients who are undergoing appendicectomy were enrolled in to

the study. Thirteen patients were given Diclofenac sodium suppository immediate post operatively and oral Diclofenac sodium 8 h for 24 h. Thirteen patients were offered TAP block through the incision site. 10 ml of 0.5% bupivacaine is used for the TAP block. Both groups were planned to give Pethidine intramuscularly, on request of the patient. The post operative pain was analyzed by the visual analog scale in 100 mm in 2, 6, 12, 24 h. Incidence of post operative nausea and vomiting is noted.

**Results:** There was no significant difference between two groups in the distribution of age, sex, and the weight. No patient demanded Pethidine within first 24 h in both groups. The post operative pain is significantly less in TAP block during 2, 6, 12 and 24 post operative h (*P*).

**Conclusions:** The TAP block through the incision site in open appendectomy is effective for the post operative analgesia in first 24 h. The current concept could be used to give post operative analgesia in any surgery that the incision opens into TAP.



**Fig. 1** Perforation with Primary Closure

**Abstract ID: 0226** Specific Field: **Miscellaneous (Other)**

**Mode of pres.: Free Paper**  
**ISW 2011 Session 31.02**

#### One stage surgical management of patients with typhoid perforation

A. Yakubu

Kazaure General Hospital, Kazaure, Jigawa State, Nigeria

**Introduction:** Management of typhoid perforation is a major challenge especially in development countries where patients are admitted late with serious complications. The affected intestine is usually managed by resection or right hemicolectomy with ileostomy. In Africa ileostomy is not acceptable by patients as it is not popular due lack of experts. In this study primary closure and resection with primary anastomosis is used in management of typhoid perforation.

**Material and Methods:** Twelve patients with typhoid perforations were evaluated prospectively and divided into three groups. Group 1; includes 6 (50%) patients with primary closure, Group 2 includes 3 (25%) patients with resection and primary anastomosis, while Group 3; includes 3 (25%) patients with right hemicolectomy and primary anastomosis (Fig. 1). Demographic information, clinical characteristics, types of surgery, operation time, postoperative hospital stay, complications and postoperative mortality were evaluated.

**Results:** The age range of patients was from 10 to 40 years The mean age incidence was 23.3 years, and the male: female ratio was 4:1 The age of 50% of all subjects was under 13 years. Headache, fever, abdominal pain, vomiting and watery stool were the common presenting symptoms. The mean admission and operation days following the onset first symptom were 7 and 8 days respectively. In all subjects the ilium was affected with number of perforations ranging from 1 to 5. The location of the perforation from ileocecal junction ranges from 10 to 18 cm. Patients' average hospital stay was 19.2 days. Eight patients had operation site infection, among them 1 (12.5%) patient developed fecal fistula and 2 (25%) cases healed with incisional hernia There was no death in the study.

**Conclusions:** The data from our study show the feasibility of primary closure, and resection with primary anastomosis in typhoid perforation.

**Abstract ID: 0227**

Specific Field: **Miscellaneous (Other)**

**Mode of pres.: Free Paper**  
**ISW 2011 Session 31.03**

**The NOTA study: non operative treatment for acute appendicitis: Study on efficacy and safety of antibiotic treatment (Amoxicillin and Clavulanic Acid) in patients with right sided lower abdominal pain trial registration: ClinicalTrials.gov Identifier: NCT01096927**

E. Giorgini, S. Di Saverio, A. Biscardi, S. Villani, F. Baldoni, G. Tugnoli

Maggiore Hospital – Bologna Local Health District, Department of Emergency and Trauma Surgery Unit, Trauma Center, Bologna, Italy

**Introduction:** Lower abdominal pain for suspicion of acute appendicitis is one of the common causes of admission in ED. Aim of this study is to evaluate safety and efficacy of conservative treatment with antibiotics in patients with suspicion of acute appendicitis as an alternative to surgery, evaluating failure and relapse rate.

**Material and Methods:** From January to December 2010, 159 patients (118 F) with suspicion of appendicitis were admitted to ED and enrolled into the NOTA Study. The patients underwent observation and not operative treatment with antibiotic therapy (amoxicillin and clavulanic acid) and were re-assessed 5 days later. Follow up at 7, 15 days, 6 and 12 months has been carried out.

**Results:** Short term failure rate of NOM was 11, 9 (19/159) and all cases were operated within 7 days since the first episode (range 2–6 days) .68.5% (13/19) pt were defined appendicitis “unlikely” and 31.5% (6/19) “possible” according to Alvarado and AIR score. At 15 days follow up (100% FUP) there were no recurrences. At 6 months followed up (96 pt FUP) there were 8 cases of recurrence episode (8.3%) were recorded, 4 of these were treated successfully with a further cycle of the same antibiotic, the 4 remaining went to OR. At 1 year (26 pt) no further recurrences have been recorded. No major side effects drug- related were observed. Minor side effects occurred in 11.9%. Median NRS was 3 at 7 days and 2 at 15 days. Mean LOS of conservatively managed patients was 0.4 days. Mean number of FUP appointments scheduled in outpatient clinic was 1.3. Mean sick leave time was 5.8 days. None of the clinical and laboratory factor forming Alvarado or AIR score was predictive of failure of NOM or of long term recurrence of episodes of appendicitis after multivariate analysis. Cost analysis showed overall costs of NOM with antibiotic reaching 316.20 € per patient.

**Conclusions:** Antibiotic therapy for suspected acute appendicitis without signs for peritonitis is safe and effective and both at short and long term. It may lower the operative rate for suspected acute appendicitis and avoid unnecessary appendectomy, surgical risks and lower the overall costs.

**Abstract ID: 0228**      Specific Field: **Miscellaneous (Other)**

**Mode of pres.: Free Paper**  
**ISW 2011 Session 31.04**

**Acute appendicitis camouflaging the carcinoid of the appendix**

Z. Demetrashvili

Tbilisi State Medical University, Tbilisi, Georgia

**Introduction:** Carcinoid of the appendix is a rare disease. It is often diagnosed on the basis of the histopathological study of appendix after the appendectomy carried out due to acute appendicitis. So that intra-operationally a surgeon is even unaware of the fact that the patient is suffering from the carcinoid of the appendix rather than acute appendicitis. Due to the very fact an inadequate operation may be implemented. Our research aims to study the following: in which cases of operations (carried out due to the diagnosis of acute appendicitis) the carcinoid of the appendix occurred and how adequate was the treatment.

**Material and Methods:** in 2003–2007 at the Surgery Department of the Central Clinic of the Tbilisi State Medical University 1348 patients underwent appendectomy for a clinical presentation consistent with acute appendicitis. There were 726 males (54%) and 622 females (46%) with the average age of 31 years (range 18–88 years). All of the operations have been carried out as open cut operations. All cut appendixes have been investigated via histopathological study.

**Results:** In 1348 cases of investigated appendixes 6 cases (0.45%) of the carcinoid of the appendix occurred. There were 6 females and one male among the very patients. The diameter of the tumor in four out of these 6 cases was less than 1, 1.2 cm in another case, and 2 cm in the last case. Focal invasion of the mesoappendix occurred in the latter case. During the process of operation, only in one out of the 6 operations did the surgeon realize the occurrence of the tumor of the appendix and carried out the right hemicolectomy. In the rest 5 cases appendectomy has been carried out though on the basis of the histopathological study of these surgical specimens it has been determined that the resection margins were tumor-free. Due to the consequent examinations one out of these 5 patients underwent the right hemicolectomy.

**Conclusions:** the carcinoid of the appendix is often camouflaged by acute appendicitis. Most frequently, a surgeon is unable to detect its occurrence intra-operationally, especially if its diameter is less than 1 cm. Therefore, all cut appendixes must be examined histopathologically. After setting a carcinoid diagnosis the further treatment tactics must be determined by a multi-disciplinary team.

**Abstract ID: 0229**      Specific Field: **Miscellaneous (Other)**

**Mode of pres.: Free Paper**  
**ISW 2011 Session 31.05**

**Combined treatment with 2-mercaptoethane sulfonate and n-3 polyunsaturated fatty acids ameliorates ulcerative colitis in rats**

I. Triantafyllidis [1], T. Poutahidis [2], I. Taitzoglou [3], M. Doulberis [2], Z. Abas [4], I. Kesiosoglou [5], C. Lazaridis [6], D. Botsios [6]

[1] Edessa General Hospital, Edessa, Greece, [2] Laboratory of Pathology, Faculty of Veterinary Medicine, Aristotle University, Thessaloniki, Greece, [3] Laboratory of Physiology, Faculty of Veterinary Medicine, Aristotle University, Thessaloniki, Greece, [4] Department of Agricultural Development, Democritus University of Thrace, Orestiada, Greece, [5] AHEPA University Hospital, Aristotle University, Thessaloniki, Greece, [6] Papanikolaou University Hospital, Aristotle University, Thessaloniki, Greece

**Introduction:** Oxidative damage is a central feature of Inflammatory Bowel Disease (IBD). Although a known antioxidative drug, 2-mercaptoethane sulfonate (MESNA) has never been considered for treating humans with IBD. Here we tested whether MESNA when administered alone or in combination with n-3 polyunsaturated fatty acids (PUFA) affects the outcome of Dextran Sodium Sulfate (DSS)-induced ulcerative colitis in rats.

**Material and Methods:** Male Wistar rats ( $n = 100$ ), 8–10 week old, were divided into 10 groups according to treatment. For the induction of colitis, DSS (5% w/v) was given in drinking water for 7 days. DSS-treated rats were further treated orally (PO), intraperitoneally (IP) or intrarectally (IR) for either 7 or 14 days with MESNA, PUFA or both. Rats were euthanized at the end of each treatment period. Disease activity index (DAI) was recorded throughout the experiment. At necropsy, colorectal gross lesions were scored. Colitis was scored histologically and the expression of myeloperoxidase, inducible nitric oxide synthase, nuclear factor  $\kappa$ B and caspase-3 in colonic tissue was assessed by immunohistochemistry.

**Results:** Statistical analysis of DAI and histopathology scores suggested that MESNA alone was sufficient to significantly reduce colorectal tissue damage. MESNA was more effective when administered PO or IP instead of IR. When each of the MESNA PO or IP administration protocols was supplemented with PUFA given PO the suppression of DSS colitis was significantly enhanced after 7 days of treatment and a remarkable recovery of colorectal mucosa was evident after 14 days of treatment.

**Conclusions:** The simultaneous administration of MESNA and PUFA is particularly effective in ameliorating DSS colitis in rats. This result suggests that antioxidants including MESNA may be considered as a complementary treatment for human patients with IBD.

**Abstract ID: 0230**      Specific Field: **Miscellaneous (Other)**

**Mode of pres.: Free Paper**  
**ISW 2011 Session 31.10**

**Hepatectomy according to depth of subserosal invasion in patients with pT2gallbladder carcinoma**

Y. Mataka, H. Shinchi, K. Maemura, H. Kurahara, S. Ueno, M. Sakoda, S. Takao, S. Natsugoe

Kagoshima University, Kagoshima, Japan

**Introduction:** In gallbladder cancer (GBC) with pathological subserosal invasion (pT2), a suitable hepatectomy is controversial. We examined whether depth of subserosal cancer invasion in GBC patients with pT2 concerns extent of hepatectomy and survival.

**Material and Methods:** Between 1987 and 2010, a total of 53 patients with GBC underwent a curative surgery at our department in Kagoshima University. Of these, subjects comprised 32 patients with pT2 GBC. We divided subserosal invasion into two categories corresponding to invasion of the shallower layer, ss1 ( $n = 19$ ) and deeper layer, ss2 ( $n = 13$ ). Relationships between subserosal classification, histopathological factors, and prognosis were examined.

**Results:** Positive rates of histopathologic findings, such as lymph node metastasis, lymphatic invasion, venous invasion, perineural invasion, hepatic invasion, and biliary infiltration, in ss1 GBC were lower than those in ss2 GBC ( $P = 0.26$ ,  $P < 0.001$ ,  $P = 0.006$ ,  $P = 0.055$ ,  $P = 0.06$ ,  $P = 0.11$ , respectively). Overall five-year survival rate in pT2 GBC was 63.8%. The five-year survival of patients with ss1 GBC was significantly better than those with ss2 GBC ( $P = 0.033$ ). Various hepatectomy for ss GBC was selected, such as cholecystectomy ( $n = 9$ ), resection of hepatic bed ( $n = 16$ ), S4a + S5 resection ( $n = 5$ ), extended right lobectomy ( $n = 2$ ) There was no significant difference in five-year survival among 4 types of



hepatic resection. Only cholecystectomy provides five-year survival for 2 cases with ss1 GBC. Meanwhile, hepatectomy greater than gallbladder bed resection provides five-year survival for 4 cases with ss2 GBC. Recurrence of hepatic metastasis occurred in 6 cases. In two cases among them, S4a, S5 hepatic metastases occurred in half-year after first resection, and by additional resection of hepatic metastases they could get five-year survival.

**Conclusions:** In compliance with the extent of depth of subserosal invasion in ss GBC, hepatectomy should be selected.

**Abstract ID: 0231**                      Specific Field: **Miscellaneous (Other)**

**Mode of pres.: Poster Discussion**  
**ISW 2011 Session 60.10**

**Partial splenectomy for non-parasitic splenic cysts**

A.B. Szczepanik [1], A.J. Meissner [1], A.M. Szczepanik [2],  
A. Misiak [1]

[1] Institute of Hematology and Transfusion Medicine, Warsaw, Poland, [2] Praski Municipal Hospital, Warsaw, Poland

**Introduction:** Due to important role of the immunologic function of the spleen, the spleen parenchyma saving procedures have recently been recommended in splenic cysts. The aim of the study was to present our experience with partial splenectomy for non parasitic splenic cysts (NPSC).

**Material and Methods:** From 2003 to 2010, 18 patients were subjected to partial splenectomy for NPSC. The study group included 11 women and 7 men, aged 17–55, 30.6 years in average. In all patients, splenic cysts were diagnosed by means of ultrasonography and confirmed by computed tomography scan. The size and location of the cyst, its relationship to hilar vessels and dimension of normal splenic parenchyma were determined. The indication for operation were a splenic cysts of diameter larger than 5 cm, and rapidly growing cysts. The criteria for partial splenectomy were cysts located in one of the splenic poles, not comprising the hilus.

**Results:** Fifteen of the 18 patients underwent successful open partial splenectomy. In one patient insufficient arterial supply to the preserved splenic remnant, found intraoperatively, resulted in total splenectomy. In two patients bleeding from transected spleen parenchyma was observed, which required laparotomy and removing of splenic remnant. All patients survived the operation. There were no other postoperative complications or deaths after surgery. In 14 patients cysts were located in the upper splenic pole, in 4 in the lower pole. The mean diameter of the operated cysts was 8.4 cm (range 7–17 cm). The mean operation time was 95 min (range 50–160). Pathological examination showed epithelial (true) cysts in 15 patients and pseudocysts in 3. The mean hospital stay was 9.7 days (range 7–19 days) after partial splenectomy.

**Conclusions:** We consider partial splenectomy as the method of choice in the management of NPSC. Total splenectomy should be performed only in centrally located and multiple cysts.

**Abstract ID: 0232**                      Specific Field: **Miscellaneous (Other)**

**Mode of pres.: Free Paper**  
**ISW 2011 Session 152.04**

**It is not anatomic bomb. It is a radiological examination**

A. AlAni, O. Sadieh, K. Al Ani

AlBashir Teaching Hospital, Amman, Jordan

**Introduction:** The use of radiological investigation is an accepted part of medical practice, but there is no known safe radiation dose. Man-made radiation accounts for 13% of the total radiation burden, 90% of it is due to diagnostic medical exposures. The most significant studies of the effects of radiation came from the lifetime study of the approximately 90000 survivors of the atomic bombs dropped over Hiroshima & Nagasaki in 1945. These studies considered survivors who receive whole body doses from photons & neutrons greater than about 0.25 Sv as population liable for excess cancers. These Survivors include people who were 900 to 1500 meters away from the “hypocenter,” just below the exploding bomb. The aim of this study is to make a comparison between the whole body doses of radiation received by the survivors of Hiroshima, Nagasaki & the dose received by patients from the diagnostic radiological examinations in the first day of admission to the ER department.

**Material and Methods:** In the period from 19th October 2008 to 25th November 2008; 273 blunt trauma patients with are vised trauma score of <4 were studied prospectively, in the emergency department of Al Bashir teaching hospital, Amman, Jordan. 188 (68.87%) were males, & 85 (31.13%) were females. Age range was 0.05 to 95 year (mean age 18.06 years).

**Results:** The range of radiological examinations received by the patients was 1–14 (with a mean of 4.63 examination for each patient). radiological examination positive findings were found in 27.83% (76 patient) only, while the findings were negative in 72.17% (197 patient) . The dose of radiation received by the patients ranges between 0.1–18.5 milisivert. With a mean of 3.52 milisivert. 41.76% (114) received >0.25 milisivert, while only 58.24% (159 patient) received <0.25 milisivert. The additional risk for cancer ranges between 0.001–0.731% with a mean of 0.060%.

**Conclusions:** Patients are receiving an unusual high dose of radiation for the diagnostic purposes. This brings an unaccepted additional risk of cancer for the patients.

**Abstract ID: 0233**                      Specific Field: **Miscellaneous (Other)**

**Mode of pres.: Free Paper**  
**ISW 2011 Session 152.06**

**Ultrasound-guided infraclavicular axillary vein puncture is effective to avoid pinch-off syndrome**

H. Osawa, K. Yamakawa, J. Hasegawa, N. Matsunami, S. Mikata,  
Y. Kim, H. Morishima, R. Nezu

Osaka Rosai Hospital, Sakai, Osaka, Japan

**Introduction:** Pinch-off syndrome (POS) is one of the critical complications in totally implantable venous access ports (TIVAPs) through subclavian vein. POS occurs when a long-term central venous catheter is compressed between the clavicle and the first rib. Ultrasound (US)-guided infraclavicular axillary vein puncture has not been common, but this technique may avoid POS because the catheter is already cannulated within the vessel as it passed over the first rib and beneath the clavicle. The purpose of this study was to evaluate the effectiveness of US-guided infraclavicular axillary vein puncture in avoiding POS as compared with anatomical landmark technique.

**Material and Methods:** A retrospective review was undertaken in consecutive 207 TIVAPs in 195 patients from April 2006 to August 2009. 100 devices were implanted following anatomical landmark technique and 107 with US-guided infraclavicular axially vein puncture. All patients underwent a close and specific clinical and instrumental follow-up to evaluate pinch-off sign and pinch-off grade

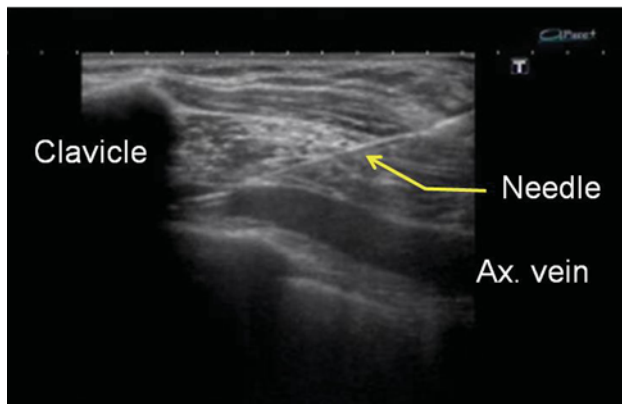
Perioperative complications in landmark technique and US-guided puncture

	Landmark-tech (%)	US-guided	<i>P</i> value
Pneumothorax	3 (3)	0	0.70
Malposition	5 (5)	0	0.53
POG $\geq$ 1	19 (19)	0	0.02

(POG) with Hinke's definition in 16 (1–51) months [landmark] and in 11 (1–37) months [US-guided].

**Results:** Using landmark technique, 19 catheters (19%) showed grade-1 (bending or deviation) deformation on the initial postoperative chest radiograph, whereas none showed with US-guided puncture ( $P = 0.02$ ). Among 100 cases of landmark technique, 4 catheters showing grade-0 (smooth and no narrowing) initially developed grade-1, 4 catheters of grade-1 developed grade-2 (luminal narrowing) in 2 and grade-3 (fracture) in 2, and 2 catheters of grade-2 developed grade 3. In contrast, there was no pinch-off grade progression in all 107 cases of US-guided infraclavicular axillary vein puncture.

**Conclusions:** US-guided infraclavicular axillary vein puncture was effective to avoid pinch-off syndrome in implanting and managing totally implantable venous access ports for longer period.



**Figure:** Real-time visualization of the needle tip into the axillary vein, using the long-axis approach

**Abstract ID: 0234**

Specific Field: **Miscellaneous (Other)**

**Mode of pres.: Free Paper**  
**ISW 2011 Session 171.07**

**Anti-disciplinary needs-based design: medical innovation fellowship as a model for healthcare innovation**

S.M. Siddiqui, D.G. Mullen, J.L. Stovall, L.L. Walz, H.J. Hensel, J.D. Geiger

University of Michigan, Ann Arbor, USA

**Introduction:** The University of Michigan Medical Innovation Center's (MIC) Fellowship Program assembles a team of talented post-graduates in medicine, engineering and business to identify needs and develop healthcare solutions. The "anti-disciplinary" nature of the program seeks to blur the boundaries, creating a team that is versed in multiple disciplines. The entire cohort is trained in a needs-based design process, creating a system primed for successful innovation.

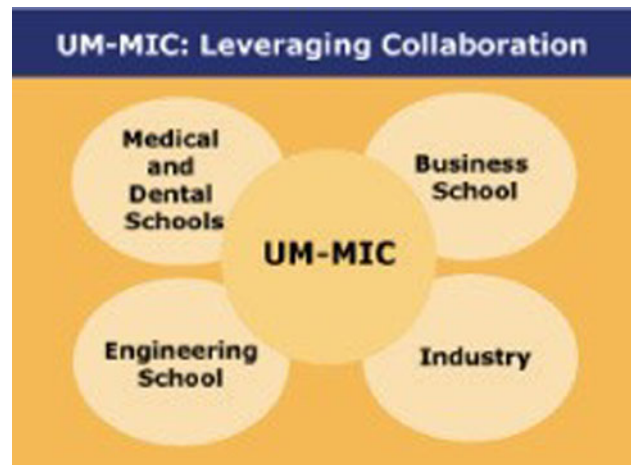**Material and Methods:** The MIC Fellowship is a full-time hands-on educational program. The curriculum is delivered in a variety of modes:

- visits to medical device companies
- formal training in observation techniques from a world-class organization
- personal interactions with industry and thought leaders
- participation in relevant conferences and seminars
- training in our Design and Prototype Lab
- direct clinical observation facilities with medical faculty
- working/communication style activities facilitated by professional team coach

The topics of these curriculum units span the broad range of issues essential to a successful medical technology innovation: regulatory approval, reimbursement strategies, intellectual property protection, marketing and distribution, animal and human subject trials, venture creation and financing.

**Results:** At a minimum, each MIC Fellow exits the program with a strong understanding of all the aspects of medical technology development and commercialization, achieving the ability to be conversant across disciplines. Each Fellow is fully trained in observation skills and need-based design. Past classes have launched companies that are now furthering product development, securing regulatory approval and marketing product ideas. Throughout the program, the Fellows develop personal relationships with industry leaders and mentors who comprise a medical technology ecosystem upon which they can draw in the future.

**Conclusions:** The MIC Fellowship Program provides a unique opportunity to train and develop the skills needed to better design solutions for some of healthcare's most significant problems.



**Figure:** The UM MIC fellowship program leverages the robust and co-located resources enjoyed by the University of Michigan

**Abstract ID: 0235**

Specific Field: **Miscellaneous (Other)**

**Mode of pres.: Free Paper**  
**ISW 2011 Session 171.08**

**Are medical students who want to become surgeons different?**

D. Baschera [1], T. Masilonyane [1], P. Isenegger [2], R. Zellweger [1]

[1] Royal Perth Hospital, Perth, Australia, [2] Kantonsspital Liestal, Liestal, Switzerland

**Introduction:** Surgery is unquestionably one of the most demanding and competitive specialties a medical graduate can choose. However, the rumour also persists that surgeons are the more simple minded, straight forward, hands on physician in the guild. Our aim was to find what characterises the medical student aiming to become a surgeon.

**Material and Methods:** In February 2010 an online survey (36 questions) was published online. It was put together using an open source survey tool Limsurvey (Version 1.85 RC3). Deans' offices of all medical schools as well as student organisations of all countries where English or German are official language were asked via e-mail to forward the link to our online survey to their students. The medical students that answered that they want to go into Surgery were analysed separately and in comparison to the others.

**Results:** In the period between February 2010 and June 2010 we received 2907 responses from 10 different countries. 2351 answered to the key question what discipline they would like to specialise after graduation. Those 385 (16.4%) who favoured surgery at this time, were on average half a year younger ( $P = 0.023^*$ ), were about 1.3 times more likely to be male ( $P = 0.01^{**}$ ) and about one fifth more often single. In their motivation to become a medical doctor they were, compared to the other respondents, much more likely to answer that they have chosen to study medicine because of the social prestige and because of the salary. They were also leading the statistics for consumption of nicotine, alcohol and marijuana. However more than the rest they were prepared to work longer h after their graduation.

**Conclusions:** Medical students who want to become surgeons are more individualistic, goal orientated and less health orientated regarding substance intake.

**Abstract ID: 0236**

Specific Field: **Miscellaneous (Other)**

**Mode of pres.: Free Paper**  
**ISW 2011 Session 171.09**

### Training program of surgery in Tokyo Metropolitan Medical Academy of Advanced Residency

T. Takahashi [1], Y. Iwasaki [2]

[1] Tokyo Metropolitan Government, Tokyo, Japan, [2] Tokyo Metropolitan Komagome Hospital, Tokyo, Japan

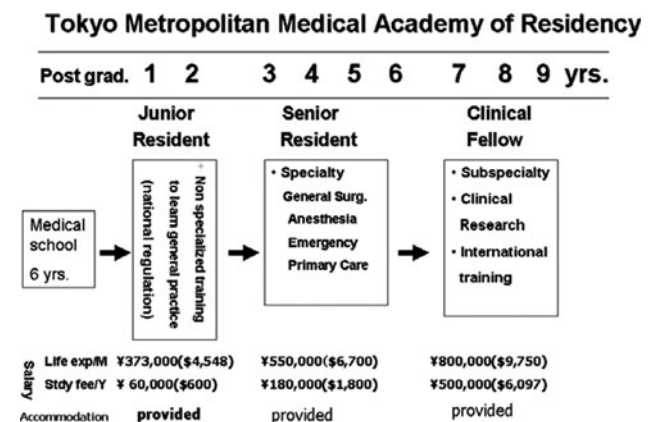
**Introduction:** Tokyo Metropolitan Government facing shortage of Hospital doctors founded the Tokyo Metropolitan Medical Academy of Advanced Residency for training of senior residents and clinical fellows in 2008. Main objective of the academy is the establishment of an updated training system of medical specialist in Tokyo.

**Material and Methods:** One hundred senior residents who graduated 6-years medical school and finished 2-years junior residency entered the academy and were distributed to 12 Tokyo Metropolitan Hospitals based on their requirements or specialty every year. The academy consists of 3 or 4 years senior residency and then 2 or 3 years clinical fellow course. The residents are trained in the specialized Hospitals and are evaluated every 3 to 6 months. Senior residents receive stipend about Yen 550,000 (US\$ 6,700)/month for life expenses and Yen 180,000 (US\$ 2,190/year) for study fee. Clinical fellows receive Yen 800,000 (\$ 9,756/month) for life expenses and Yen 500,000 (US\$ 8536 /year) for study fee.

**Results:** We present here training programs of senior residency in general surgery in the academy. The residents rotate emergency room (ER) first 3 months, then training of general surgery starts. Japan surgical society has made specific behavioral objectives (SBOs) to perform surgical techniques for certification of general surgery. Along the objectives, surgical residents experienced a settled 350 operations including 120 operators during 3 years. Surgery for gastric cancer is

the most common operation in Japan, so we present video showing D2 gastrectomy for advanced gastric cancer and laparoscopic gastrectomy for early gastric cancer performed by senior residents. In the clinical fellow course for 3 years after finishing senior residency, the fellows should experience 450 cases of gastrointestinal surgery including low to high grade operations such as pancreatico-duodenectomy for accredited qualification of specialty in gastrointestinal surgery. Forty three senior residents including 12 surgical residents completed their residency program at the end of this March. Most of residents were satisfied with the program. However, there were some problems with financial imbalance in Tokyo Metropolitan Government.

**Conclusions:** The residents trained at Tokyo Metropolitan Medical Academy of Advanced Residency are becoming skilful surgeons.



**Figure:** Tokyo Metropolitan Medical Academy of Residency

**Abstract ID: 0237**

Specific Field: **Miscellaneous (Other)**

**Mode of pres.: Free Paper**  
**ISW 2011 Session 171.10**

### General and essential surgical care in Haiti: the earthquake's influence

C. Hughes [1], B. Alkire [1], K. Nash [1], T. Pauyo [2], D. Bayne [2], C. McClain [1], S. Sullivan [3], J. Meara [1]

[1] Childrens Hospital Boston, Boston, USA, [2] Harvard Medical School, Boston, USA, [3] Brown University Medical School, Providence, USA

**Introduction:** Surgical care in resource-poor settings around the world is an essential pillar of global public health efforts. Natural disasters can exacerbate an already stressed healthcare system in developing nations. The existence of a surgical delivery network can increase the provision of essential surgical care to address acute surgical needs on a population level.

**Material and Methods:** A retrospective review of operative logbooks was conducted at five Partners in Health/Zanmi Lasante (PIH/ZL) hospitals in the Central Plateau of Haiti. All consecutive surgical cases performed in the operating theater between July 2009 and August 2010 were captured, including the time period immediately following the earthquake in January 2010.

**Results:** A total of 4748 surgical procedures were performed over the course of a year, including general surgery, obstetrics and gynecology (OBGYN), trauma, orthopedics, and multiple surgical subspecialties. 62.0% of the patients were female, and the mean age at the time of surgery was 31.1 years ( $\pm 17.7$ ). Patients seen were significantly younger post-earthquake (32.3 years vs. 30.2 years,  $P < 0.001$ ). The

most common procedural specialties were general surgery (34.0%) and OBGYN (33.5%), followed by trauma (14.0%). When assessed both before and after January 2010, 40.9% of all surgeries were performed prior to the earthquake. After the earthquake, significantly fewer procedures were performed for surgical subspecialties, including OBGYN (39.3% pre vs. 29.7% post,  $P < 0.001$ ), urology (13.5% pre vs. 5.7% post,  $P < 0.001$ ), and otolaryngology (4.2% pre vs. 1.8% post,  $P < 0.001$ ). The provision of general surgery was not significantly affected by the quake (34.5% pre vs. 33.9% post,  $P = 0.65$ ), and trauma surgery and non-trauma orthopedics volume increased significantly ( $P < 0.001$ ). Across all specialties, most returned to pre-quake volumes by March 2010, and all had normalized by June 2010.

**Conclusions:** Emergency and essential surgery constitutes a significant public health need in resource poor regions. The ability to provide surgical subspecialty care can fluctuate following a natural disaster, but the existence of a functional surgical delivery network can adequately meet the surge in demand for essential general surgical services in times of acute need.

**Abstract ID: 0238**      Specific Field: **Miscellaneous (Other)**

**Mode of pres.: Poster Exhibition only**  
**ISW 2011 Session PE 125**

#### **Rectus Sheath haematoma (RSH) in the era of anti-coagulation**

F.K. Asomah [1], S.P. Pillay [2], I.H. Jaffer [1], S. Naidu [1], J. Fenwick [3], C. Prather [3]

[1] QEII Jubilee Hospital, Brisbane, Australia, [2] QEII Jubilee Hospital, University of Queensland, Brisbane, Australia, [3] Queensland X-Ray, Brisbane, Australia

**Introduction:** RSH is a rare cause of acute abdominal pain. RSH is becoming increasingly common with the use of various anticoagulant preparations. In most cases, it manifests as an acute painful lump confined to the rectus sheath, but large haematomas causing hemodynamic instability can occur together with intra-abdominal hypertension and abdominal compartment syndrome presenting as a phenomena of “pseudosepsis”. This uncommon cause of pain must always be considered in the context of an acute abdomen particularly in medical wards from where most referrals to surgeons originate.

**Material and Methods:** A retrospective chart review of 6 patients with RSH at our centre from 2007 to 2010 were analysed to identify potential causes and outcomes.

**Table 1** Patient population with RSH

	Gender	Age	Aetiology	Co-morbidities	Hb drop	Transfusion (units)	Outcome
Patient 1	F	87	LMWH	AF, CCF	151 to 98	2	Resolved
Patient 2	F	85	LMWH, Clopidogrel	CCF, HTN	124 to 87	2	Died Day 3
Patient 3	F	60	LMWH	SLE, HTN	114 to 57	4	Resolved
Patient 4	F	63	Warfarin (INR 4.7)	PEs (multiple), COPD, HTN	115 to 80	3 and 4 FFP	Resolved
Patient 5	M	75	Spontaneous	Dementia	155	Nil	Resolved
Patient 6	M	69	Spontaneous	CCF	82	2	Resolved

**Results:** 4 patients with RSH received anticoagulation and 2 did not (spontaneous). The type of anti-coagulation therapy included 2 on Heparin or LMWH, 1 on Warfarin, 1 on Heparin and Clopidogrel. All patients with anti-coagulation related RSH were female ( $n = 4$ ). Mean age was 73.2 years. One patient was identified as being overdosed for her weight. Four patients were in hospital for symptoms associated with acute coronary syndrome. Two patients had other symptoms with spontaneous RSH. Five patients required packed red blood cell (PRBC) transfusion. Table 1 demonstrates our patient population. No patient needed surgical intervention. The anticoagulants were either ceased or doses reduced.

**Conclusions:** Anticoagulants, especially LMWHs, need to be used with caution in frail and elderly patients with appropriate adjustment of doses. RSH should be considered as a differential diagnosis in the anti-coagulated patient with abdominal pain.

**Abbreviations:** LMWH: low molecular weight heparin, AF: Atrial Fibrillation, CCF: Congestive Cardiac Failure, HTN: Hypertension, SLE: Systemic Lupus Erythematosus, PE: Pulmonary Embolism, COPD: Chronic Obstructive Pulmonary Disease, FFP: Fresh Frozen Plasma.

**Abstract ID: 0239**      Specific Field: **Miscellaneous (Other)**

**Mode of pres.: Poster Exhibition only**  
**ISW 2011 Session PE 126**

#### **The third time repair of recurrent inguinal hernia using 10 mm single port access intraperitoneal onlay mesh (SPA-IPOM) fixed with endoclose sutures: a case report**

W. Thanapongsathorn

Srinakharinwirot University, Nakron Nayok, Thailand

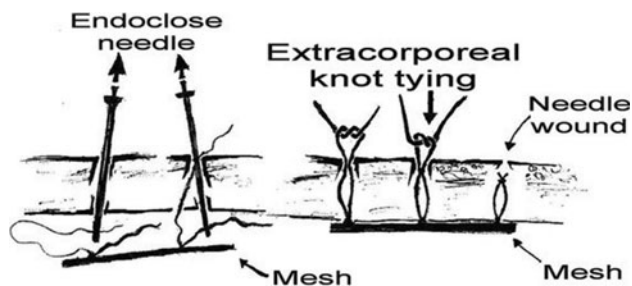
**Introduction:** To report an optional technique of laparoscopic 10 mm Single Port Access IntraPeritoneal Onlay Mesh (SPA-IPOM) using Proceed mesh (tissue separating mesh) fixed with Endoclose suture (percutaneous subcutaneous suture) in a case of the repeated recurrent inguinal hernia repair.

**Material and Methods:** Laparoscopic SPA-IPOM was done through a 10 mm trocar using one 10 mm instrument that has 5 mm optical lens with 5 mm working channel. After inserting 10 mm trocar at umbilicus using semi-open technique, the opening of recurrent inguinal hernia is identified. A 10 × 15 cm pre-tied Proceed mesh is then placed to cover hernia defect and all three potential area of indirect, direct and femoral hernia. Using Endoclose needle, each pair of pre-tied sutures are retrieved percutaneously through a needle wound and extracorporeal tied with knot in subcutaneous space. After the upper half of mesh is sutured to the posterior surface of abdominal wall, the lower half of mesh is fixed by hernia tacker to Symphysis Pubis, Cooper Ligament and Iliopubic tract.

**Results:** A 67 years old man was admitted for recurrent right inguinal hernia repair after two operation of this hernia by open technique without mesh at 20 and 5 years ago. The third time hernia repair was performed by laparoscopic 10 mm SPA-IPOM. Laparoscopic finding was recurrent right direct inguinal hernia with peritoneal fibrous adhesion. Operative time was 30 min. There was no immediate complication. The patient was discharged on the 2nd postoperative day. 3 months follow up has no recurrence.

**Conclusion:** Laparoscopic SPA-IPOM is an optional operation and is much easier to perform. Benefits include time saving, cosmesis, early discharge and early return to work. Tissue separating mesh prevents bowel adhesion, however, is much more expensive. Long term follow up study for complications and recurrence is needed (Figure).





**Figure** Endoclose suture (percutaneous subcutaneous suture)

**Abstract ID: 0240**      Specific Field: **Miscellaneous (Other)**

**Mode of pres.: Poster Exhibition only**  
**ISW 2011 Session PE 127**

**Day-case hernioplasty: experience from Paholpolpayuhasaena General Hospital, Thailand**

W. Phanthabordeekorn

Paholpolpayuhasaena General Hospital, Kanchanaburi, Thailand

**Introduction:** Inguinal hernioplasty under local anesthesia has not been popularized by most surgeons although it is safest. Objectives were to evaluate safety, feasibility, and possibility of this procedure in development into a day-case surgery.

**Material and Methods:** After having permission from the Ethical Review Board of the hospital, all out- and in-patient medical records of patients having this procedure done by the author, between March 2008–December 2010, were retrospectively reviewed about admission duration, complications, analgesia needed, before and after development into a day-case surgery.

**Results:** There were 160 male patients aged 18–97 year-old having this procedure done by the author during the mentioned period. There was no need for preoperative gastric emptying, laboratory investigation, or intravenous fluid replacement. Infection prophylaxis was done by intravenous Cefazolin injection, 30 min before doing surgical incision. In the first 30 patients, observation in the hospital was done. The mean admission duration was found to be only 1 day. Personal daily activities could be done without any limitations. Only oral analgesia was administered when needed. There was no breakthrough pain needing additional analgesia, acute retention of urine, or nausea/vomiting. After seven days of surgery, each patient could have total stitches off without severe pain. In the next 130 patients, 4 having bilateral inguinal hernia, 4 having recurrent hernia, a day-case hernioplasty was done for each patient. All patients could return home without any observation. There was no patient returning to the hospital for any complications or problems before seven days, the date of appointment.

**Conclusion:** Day-case inguinal hernioplasty under local anesthesia can be done safely, even most patients in this study had one or more underlying medical diseases such as; coronary heart disease, diabetes mellitus, hypertension, which are commonly found in the elderly. Its feasibility, possibility, and also, convenience, had been shown as there was no need for admission.

**Abstract ID: 0241**      Specific Field: **Miscellaneous (Other)**

**Mode of pres.: Poster Exhibition only**  
**ISW 2011 Session PE 128**

**Is there a role for non-operative management in obturator hernia reporting our ten-year experience**

C.S. Chong, S. Chan, A.W.C. Kow, K.H. Liao

Tan Tock Seng Hospital, Singapore, Singapore

**Introduction:** There is a paucity of reports of non-operative management of patients with obturator hernia in the literature. The rare occurrence of this condition has also posed difficulty to conduct prospective study in this subject. Obturator hernia is usually treated with surgical repair upon diagnosis in our institution. However, there were 3 patients who declined surgical intervention. We report our experience in managing obturator hernia in this study.

**Material and Methods:** A retrospective data collection was obtained for all patients who were diagnosed with obturator hernia in Tan Tock Seng Hospital between September 2002 and May 2010. The data was analyzed using SPSS (Version 17.0). Online literature review was done via Pubmed, OVID and MEDLINE search engines.

**Results:** There were 14 patients in this cohort. The median age was 87 (50–97) years old with predominantly female patients ( $n = 13$ , 92.9%). Eleven patients (78.6%) underwent surgical repair of obturator hernia while 3 patients (21.4%) were managed non-operatively in our series. All patients had CT scan proven obturator hernia and none had evidence of perforation, obstruction or bowel ischemia. All patients were discharged from hospital after being able to tolerate full enteral feeding. Of the 3 patients who were managed conservatively, one patient died within 2 weeks of discharge and one was lost to follow-up. The third patient survived 18 months from date of diagnosis. During that period of time, he was asymptomatic and able to tolerate oral diet well.

**Conclusions:** Despite our experience in this series, the role of conservative treatment for obturator hernia remains poorly understood. We advocate surgical intervention in patients diagnosed with obturator hernia in most instances. However, elderly patients with prohibitive risk of operation may choose to decline surgical intervention.

**Abstract ID: 0242**      Specific Field: **Miscellaneous (Other)**

**Mode of pres.: Poster Exhibition only**  
**ISW 2011 Session PE 129**

**Intraabdominal hypertension after large incisional hernia repair**

G. Ianosi [1], D. Neagoe [1], S. Ianosi [1],  
M.X. Calbureanu-Popescu [2]

[1] University of Medicine and Pharmacy, Craiova, Romania,

[2] University, Craiova, Romania

**Introduction:** Large incisional hernias repair is related with an important risk of developing intraabdominal hypertension. The aim of our prospective study is to evaluate this risk during the postoperative period and to detect risk factors associated with intraabdominal hypertension in order to choose the best technique for closing it.

**Material and Methods:** We included in this study 126 patients with large incisional hernias operated during a period of 5 years. Large incisional hernias were defined as hernias in which greater diameter is at least 8 cm with a surface of minimum 60 sq. cm. They were divided into two groups. In the first group (71 patients) we achieved a retrofascial mesh repair and in the second group (55 patients) we achieved a relaxing fascial technique (Chevrel, flap technique). Evaluation of intraabdominal pressure was realized indirectly by measuring intravesical pressure.

**Results:** Mean intravesical pressure in the first group was 13.4 mmHg compared with 12.6 mmHg in the second ( $P < 0.05$ ). Intraabdominal hypertension was considered for a pressure over 15 mmHg. 5 patients from the first group and only one from the second group had a pressure over the critical level, but the compartment syndrome was diagnosed only in one patient from the first group. The main factors

associated with the risk of intraabdominal hypertension after incisional hernia repairs were obesity ( $P < 0.01$ ), cardiac and pulmonary dysfunction ( $P < 0.02$ , respectively  $P < 0.01$ ), smoking ( $P < 0.1$ ).

**Conclusion:** 1. Intraabdominal hypertension is an important complication after an incisional hernia repair and could be reduced by using a tension free technique. 2. Indirect evaluation of intraabdominal pressure via intravesical manometry is a simple but efficient method for patient selection and for postoperative monitoring.

**Abstract ID: 0243**      Specific Field: **Miscellaneous (Other)**

**Mode of pres.: Poster Exhibition only**  
**ISW 2011 Session PE 130**

#### **Lichtenstein repair of inguinal hernia with self-fixating mesh**

N. Wada, T. Furukawa, M. Ueda, Y. Kitagawa

Keio University School of Medicine, Tokyo, Japan

**Introduction:** Lichtenstein repair is recommended in many clinical settings of adult inguinal hernia in European Hernia Society Guidelines published in 2009. Recently, self-fixating mesh with advanced microgrip technology is commercially available. With this mesh, fixation with the entire mesh surface may reduce the tension at the suture points and potential risk of chronic pain or uncomfortable sensation. Here we present our current technique and short term clinical results of Lichtenstein repair without suture for mesh fixation.

**Material and Methods:** Surgical repair for groin hernia was performed for 169 patients in our institution from November 2009 to December 2010. Of these patients, a total of 119 patients (70%) were treated with Lichtenstein method. A skin incision of 3.5 cm was made under local anesthesia with 0.5% lidocaine. Intravenous administration of 35 mg of pethidine and 0.6 mg of flunitrazepam was a standard protocol for conscious sedation. Prophylactic antibiotics were used during surgery. Pre-shaped polyester mesh (Parietex Progrid<sup>®</sup>, Covidien, MA, USA) was used as an on-lay mesh and overlapped on the pubic bone.

**Results:** Mean age was  $69.5 \pm 11.2$  years. Median duration of surgery was 85 min and estimated blood loss was less than 10 ml. Median hospital stay after surgery was 1 day. We observed 4 cases (3.3%) with post-operative minor complications (3 hematomas and 1 seroma) which were treated conservatively. Two cases of postoperative hematoma cases had been given aspirin for atrial fibrillation. During 196 days of median follow-up period, no patient developed recurrent disease or chronic pain.

**Conclusion:** Lichtenstein repair using self-fixating polyester mesh could be a feasible and safe method for groin hernia patients in Japan.

**Abstract ID: 0244**      Specific Field: **Miscellaneous (Other)**

**Mode of pres.: Poster Exhibition only**  
**ISW 2011 Session PE 131**

#### **A case of transmesosigmoid hernia**

M. Ushigome [1], S. Imamura [1], Y. Nagasawa [2], T. Osaku [1], M. Tsuchiya [2], K. Fnahashi [1], H. Shimada [1], H. Kaneko [1]

[1] Toho University Omori Medical Center, Tokyo, Japan, [2] Social Insurance Kawasaki Hospital, Kawasaki, Japan

**Introduction:** Transmesosigmoid hernias are one rarer form in intraabdominal hernias to be considered to be only 1% of all small bowel obstructions.

**Material and Methods:** A 67-year-old man. He was admitted to the hospital complaining of the left side abdominal pain, nausea and vomiting that were occurred suddenly. He had a history of cholecystectomy 30 years ago. Routine hematological study was showed a hyperchromic macrocytic anemia with a hemoglobin value of 7.1 g/dl, a hematocrit value of 19.3% and a red blood cell count of 1650000, and a white cell count of 10800. CRP was 0.0 mg/dl and CPK was 23 IU/l within normal limits. CT scan findings were showed the ascites fluid on the surface of the liver, and image of the small intestinal mesentery passed under the blood vessel of the mesocolon. In addition, the edematous small intestine near the sigmoid colon was observed in reduced enhancement findings. The view of the hernia sac was not seen around the edematous small intestines. The urgent laparotomy operation was performed as the strangulation of the intestine due to transmesosigmoid hernia. The proximal side of widely small intestine at the 15cm from terminal ileum was incarcerated into abnormal mesocolonic hiatus. The bowel was widely excised the necrotic small intestine (160 cm), and the sigmoid colon (60 cm) because it had caused the twist of the sigmoid colon of the overlength. The progress of the patient was uneventful, and he left the hospital on postoperative the 19th day.

**Results:** There are three subtypes of internal hernias involving the mesosigmoid. (1) Intersigmoid hernia: herniation into the intersigmoid fossa which is the lateral aspect of the mesodigmoid. (2) Transmesodigmoid hernia: herniation arises through a defecy of the mesodigmoid. No hernial sac is present. (3) Intramesosigmoid hernia: the hernia orifice is found in the right or left surface lies within the mesodigmoid itself. The present case conformed to type 2. It is known that ransmesosigmoid hernias without hernia sac suddenly reaches an intestinal tract necrosis in comparison with intersigmoid or intreamesodigmoid hernias. Because it is said that the intestinal tract resection rate is higher, more early checkup and surgery treatment is necessary.

**Conclusions:** Internal hernia is a rare but lethal condition. Prompt diagnosis is essential for a favorable outcome. We reported one case of the transmesosigmoid hernia which shows urgent lapse even in the mesosigmoid hernia.

**Abstract ID: 0245**      Specific Field: **Miscellaneous (Other)**

**Mode of pres.: Poster Exhibition only**  
**ISW 2011 Session PE 132**

#### **Maydl's hernia: report of a case**

M. Tajima, T. Uchiyama, Y. Morii

Bungo-ohono Municipal Hospital, Bungo-ohno City, Japan

**Introduction:** Maydl's hernia is a rare type of incarcerated inguinal hernia in which the hernial sac contains a double loop of intestine with the intestine in between remaining in the abdomen. In this 'W'-shaped hernia, the intra-abdominal closed loop may become gangrenous in the presence of viable loops in the hernial sac.

**Material and Methods:** A 58-years-old male was admitted to the emergency department with right groin mass and pain. The patient had been having a right inguinal hernia from a cradle. On admission the patient had a painful non-reducible mass in the right inguinal region. Plain abdominal X-ray showed no fluid-air levels, but an infant-head-sized shade in the right groin. With preoperative diagnosis of suspect incarcerated inguinal hernia, the patient was operated on under general anesthesia. Although we tried to relieve the incarceration laparoscopically, small intestine remaining in the intraperitoneal cavity became necrotic. We converted to the open procedure and relieved the incarceration manually. Hernial content was cecum and ileum without necrotic change. Resection of the gangrenous ileum and end to end anastomosis was performed. Inguinal hernia was repaired with conventional anterior approach.

**Conclusion:** Maydl's hernia should be suspected in patients with large incarcerated hernia. Manual reduction of the hernia or conventional anterior approach without intraperitoneal exploration is contra-indication as it may result in non-viable bowel being missed.

**Abstract ID: 0246**      Specific Field: **Miscellaneous (Other)**

**Mode of pres.: Poster Exhibition only**  
**ISW 2011 Session PE 133**

**Usefulness of Marcy repair of adult indirect inguinal hernias should be reconsidered**

M. Nakagawa [1], T. Nagase [1], T. Akatsu [1], S. Imai [1], O. Wada [2], N. Fujimura [1], T. Asagoe [1], T. Kanai [1]

[1] Hiratsuka City Hospital, Hiratsuka, Japan, [2] Hiratsuka City Hospital, Japan

**Introduction:** In open surgery for repair of adult indirect inguinal hernias, the European Hernia Society recommends procedures using a mesh. However, the clinical data cited differ in many respects from the situation in Japan. This study was designed as a randomized clinical trial to compare a mesh method and a non-mesh method for repair of indirect inguinal I-1 and I-2 hernias (Japanese Hernia Society Classification) of Japanese adult.

**Material and Methods:** This study included patients from 50 to less than 80 years of age who were diagnosed preoperatively with a primary unilateral inguinal hernia and who were scheduled for elective surgery under lumbar anesthesia. Patients not wishing to participate or who had specified co-existing disorders were excluded. Patients with I-1 or I-2 surgical findings were randomized to undergo a Marcy repair or a Prolene Hernia System (PHS) repair. A single designated surgeon in charge of the study was always present at surgery to encourage uniform technique. The 3 primary endpoints were recurrence, infection, and pain. Other clinical findings, laboratory data, and patient survey results were also documented, and the patients were followed for 3 years after surgery.

**Results:** Between April 2002 and March 2007, of the 479 patients underwent surgery for an inguinal hernia, 189 were deemed eligible for study participation. Of these, 130 gave their consent for study participation; 87 were diagnosed intraoperatively as I-1 or I-2 and randomly assigned to undergo Marcy repair (45 patients) or PHS repair (42 patients). The patients' characteristics did not differ between the Marcy repair and PHS repair groups. No recurrences occurred in either group, and though infection occurred in one Marcy repair patient, for the 3 primary endpoints, including pain, there were no differences between the groups. Regarding other observation parameters, postoperative wound swelling was more frequent in the PHS group than in the Marcy group ( $P = 0.015$ ).

**Conclusion:** Although the sample size was too small for statistical analysis, in this RCT targeting Japanese patients with adult inguinal I-1 and I-2 hernias, our findings over a 3-year observation period suggest that Marcy repair may not be inferior to PHS repair. A large-scale clinical trial with strict patient selection and standardized surgical technique is warranted in Japan.

**Abstract ID: 0247**      Specific Field: **Miscellaneous (Other)**

**Mode of pres.: Poster Exhibition only**  
**ISW 2011 Session PE 134**

**Sexual function after Stoppa hernia repair in patients with bilateral groin hernia**

A. Jangjoo [1], M. Mehrabi Bahar [1], M. Aliakbarian [1], A. Najib Jalali [2], M.R. Darabi [2], M. Afzal Aghaii [2]

[1] Surgical Oncology Research Center, School of Medicine, Mashhad University of Medical Sciences, Mashhad, Iran, Mashhad, Iran, [2] Surgical Oncology Research Center, Iran

**Introduction:** Inguinal hernioplasty is one of the most common surgical procedures performing by general surgeons. Among different hernioplasty techniques, there is increasing interest toward prosthetic repairs and it is estimated that 1 million of hernia repairs are performed using prosthetic materials, annually. This study was performed to evaluate the effect of Stoppa hernia repair on sexual function of the patients with bilateral inguinal hernia.

**Material and Methods:** In a prospective follow-up study, sexual function in 50 patients with bilateral inguinal hernia was evaluated before and 1 and 6 months after standardized Stoppa hernioplasty using the International Index of Erectile Function (IIEF) questionnaire. The mean scores were obtained on pre- and postoperative visits for all domains of sexual function and were analyzed using Friedman and paired-Wilcoxon tests.

**Results:** One month after surgery, the mean score of IIEF was significantly lower compared to the mean score before surgery and 6 months after surgery ( $P < 0.001$ ), but the difference between preoperative score and the score at 6 months after surgery was not significant.

**Conclusion:** Bilateral inguinal mesh repair with Stoppa technique decreased the sexual activity of the patients at one month after surgery, but the primary status was returned at 6 months after surgery. This means that hernia repair with Stoppa technique does not improve or worsen the sexual function of patients with bilateral inguinal hernia.

**Abstract ID: 0248**      Specific Field: **Miscellaneous (Other)**

**Mode of pres.: Poster Exhibition only**  
**ISW 2011 Session PE 135**

**Inguinal hernia: shouldice is not dead**

P. Chiotasso

CHU Purpan, Toulouse, France

**Introduction:** "Gold standard" of hernia surgery, "Shouldice" is today replaced by prosthesis. However, if the Shouldice technique is perfectly done, it should rival prosthesis in terms of risk of recurrence, severe chronic pain or other side effects. The aim of this presentation is to describe some particularities of the Shouldice technique.

**Material and Methods:** All the nerves found in the surgical field are resected: the ilio-inguinal nerve above the spermatic cord, the ilio-hypogastric nerve if visualized and the genital branch of the genito-femoral nerve which is posterior to the spermatic cord in the funicular pedicle. The systematic resection of this pedicle allows a better view of the transversalis fascia and a 100% of resection of the last nerve. Opening the transverse fascia allows a lot more than a simple plication of the fascia, it is above all, the best way to recognize the only two retracted fibrose structures capable of supporting the suture: at the bottom, the inguinal ligament and at the top, the abdominal arch. A running suture between these two structures seems more effective than a simple plication of the fascia which is no more than a 'sheet of cigarette paper'.

**Results:** From one thousand consecutive patients operated on between 1990 and 2010, we have evaluated the following criteria: All patients have had the technique performed except in one case (a prosthesis must be used for excessive tension). A majority of patients describe a postoperative skin hypo-esthesia in the area of the inguinal incision which disappear progressively. No patient were secondarily referred for severe chronic pain. The risk of long term recurrence must be retrospectively evaluated in the next future.

**Conclusion:** The Shouldice technique if done perfectly should rival prosthesis and keep its place for inguinal hernia surgery if we take into account the respective risk-benefits of each surgical techniques.



**Abstract ID: 0249**      Specific Field: **Miscellaneous (Other)**

**Mode of pres.: Poster Exhibition only**  
**ISW 2011 Session PE 136**

**Postoperative incidence of incarcerated hernia after implantation of Denver shunt**

I. Akari [1], Nitta Hidetoshi [1], N. Takumasa [1], Y. Shimokawa [1], M. Kimura [1], H. Baba [2]

[1] Health Insurance Hitoyoshi General Hospital, Hitoyoshi, Japan,  
[2] Department of Gastroenterological Surgery, Graduate School of Medical Sciences, Kumamoto University, Kumamoto, Japan

**Introduction:** Denver shunt placement might be useful as palliative surgery for the patients with refractory ascites. However, early complication of the palliative surgery may decrease quality of life, leading to fatal outcome. We analyze 65 cases implanted of Denver shunt in our institute and present 2 cases with postoperative incidence of incarcerated hernia after Denver shunt placement.

**Material and Methods:** Sixty-five patients underwent percutaneous placement of Denver shunts for the treatment of refractory ascites between November 2000 and August 2010. There were 32 men and 31 women aged 35–87 years (mean age, 67 years). The underlying disease was peritonitis carcinomatosa in 33 patients, liver cirrhosis with hepatocellular carcinoma in 20 patient, and liver cirrhosis without hepatocellular carcinoma in 12 patients. We analyzed these patients for their outcome and complications.

**Results:** There were no intraoperative complication for placement of Denver shunts in all patients. Fifty-two patients of 65 patients were provided symptomatic improvement and 44 patients could be discharged to home. Disseminated intravascular coagulation and subcutaneous hematoma occurred in 20 patients and 8 patients, respectively. One patient developed acute renal dysfunction. Shunt dysfunction occurred two times in one patient. Two cases occurred incarcerated hernia at early postoperative period.

Case 1 of incarcerated hernia: this patient was 61 year old man with hepatitis C cirrhosis. We underwent Denver shunt placement for his refractory ascites, and then developed right inguinal incarcerated hernia at postoperative day 6. We urgently performed inguinal hernioplasty for this patient.

Case 2 of incarcerated hernia: this patient was 70 year old woman with hepatitis C cirrhosis. We underwent Denver shunt placement for her refractory ascites, and then developed left incarcerated obturator hernia at postoperative day 8. We urgently performed obturator hernioplasty for this patient.

**Conclusion:** It may be suggested a possibility that negative pressure in abdominal cavity caused by Denver shunt occur these incarcerated hernia. There were no reports about these cases and this is the first report of incarcerated hernia caused by Denver shunt. It is a necessary to give mind to incarcerated hernia in postoperative management of Denver shunt placement.

**Abstract ID: 0250**      Specific Field: **Miscellaneous (Other)**

**Mode of pres.: Poster Exhibition only**  
**ISW 2011 Session PE 137**

**Three methods of anastomosis in esophagojejunostomy of laparoscopic trans-hiatal extended gastrectomy for type II, III esophagogastric junction cancer**

W.H. Tong [1], Q. Wang [2]

[1] The First Hospital of Jilin University, China, People's Republic,  
[2] The First Hospital of Jilin University, Changchun, China, People's Republic

**Introduction:** To explore the feasibility and safety of 3 different anastomosis methods used in laparoscopic extended gastrectomy through the transhiatal approach in patients with esophagogastric junction cancer.

**Material and Methods:** From February 2008 to December 2010, 30 cases with Siewert type II or III esophagogastric junction cancer underwent laparoscopic trans-hiatal extended gastrectomy at the first hospital of Jilin university. We used three methods for esophagojejunostomy, using circular stapler and linear stapler (overlap method and functional end to end anastomosis method FEEA). Circular stapler: we make a little hole at the stump of the distal side of the esophagus to put the head of anvil, then make a purse suture to fix the anvil and dissect the esophagus, the staple body is inserted to the jejunum and finish anastomosis; The overlap method: we use linear staple to make a side to side anastomosis between the esophagus and jejunum, the entry hole is closed by hand suture; FEEA: we put the linear stapler in holes at the stump of the distal side of the esophagus and the proximal side of the jejunum, make the end to end anastomosis then linear stapler close the hole.

**Results:** In 30 cases, Overlap method was performed in 12 cases, FEEA was in 5 cases and Circular stapler was in 13 cases. average time for anastomosis in overlap method was 36 min, FEEA was 25 min and circular stapler was 39 min. The anastomotic leakage was happened in 2 of cases, and was cured without re-operation.

**Conclusion:** 3 procedures of the esophagojejunostomy are feasible and safe for patients with esophagogastric junction.

**Abstract ID: 0251**      Specific Field: **Miscellaneous (Other)**

**Mode of pres.: Poster Exhibition only**  
**ISW 2011 Session PE 138**

**A case of adult omental cystic lymphangioma excised by laparoscopic surgery with intraoperative open MRI**

T. Ohki, Y. Kaneko, H. Kamikozuru, M. Susa, Y. Inoue, M. Yamamoto, Y. Muragaki, H. Iseki

Tokyo Women's Medical University, Tokyo, Japan

**Introduction:** Adult omental lymphangioma is comparatively rare. Here is a case of adult cystic lymphangioma of the omentum which was excised by laparoscopic surgery combined with intraoperative open MRI.

**Case:** A 41-year old man was diagnosed with a benign omental cyst in 2004, which remained benign according to subsequent follow-ups. In November 2009, an MRI showed that the tumor had grown. The patient reported a sense of abdominal pressure. He was admitted for surgery in January 2010. US, CT and MRI showed a multilobular cystic mass lesion about 12 cm in diameter in the upper right abdomen. 3D-CT showed an omental tumor with feeder from the right gastroepiploic artery. Laparoscopic surgery was performed in an intelligent operating room. Laparoscopy revealed a white cystic tumor in the right omentum. The tumor was resected using laparoscopic coagulating shears and vessel sealing system. Then immediately after the resection the patient underwent an open MRI to confirm that there was no residual tumor. The tumor consisted of chyle. Pathological findings showed omental lymphangioma.

**Discussion:** It has been reported that it is difficult to remove remnant omental lymphangioma. Because MRI easily detected cystic lymphangioma, intraoperative open MRI effectively determined whether or not the tumor remained. A combination of open MRI and laparoscopic surgery can be considered an effective technique in reducing the occurrence of remnant tumors.

**Conclusion:** The laparoscopic resection of omental lymphangioma can be more reliable with the use of intraoperative open MRI.



**Abstract ID: 0252**      Specific Field: **Miscellaneous (Other)**

**Mode of pres.: Poster Exhibition only**  
**ISW 2011 Session PE 139**

**Peptide vaccine therapy for patients with advanced pancreatic cancer**

M. Miyazawa [1], M. Tani [2], M. Kawai [2], S. Hirono [2], K. Okada [2], A. Shimizu [2], U. Nakamura [3], H. Yamaue [2]

[1] Wakayama Medical University, Japan, [2] Wakayama Medical University, School of Medicine, Wakayama, Japan, [3] The University of Tokyo, Institute of Medical Science, Tokyo, Japan

**Introduction:** Vascular endothelial growth factor receptor 2 (VEGFR2) is an essential factor in tumor angiogenesis and growth of pancreatic cancer. Immunotherapy using epitope peptide for VEGFR2 (VEGFR2-169) is expected to improve the clinical outcome. Therefore, a phase I clinical trial in a combination of VEGFR2-169 with gemcitabine was conducted for patients with advanced pancreatic cancer (ClinicalTrials.gov, number NCT 00622622).

**Material and Methods:** Patients with metastatic and unresectable pancreatic cancer were eligible for the trial. Gemcitabine was administered at a dose of 1,000 mg/m<sup>2</sup> on days 1, 8 and 15 in a 28-day cycle. VEGFR2-169 peptide was subcutaneously injected weekly in a dose-escalation manner (doses of 0.5, 1.0, 2.0 mg/body, 6 patients/1 cohort). Safety and immunological parameters were assessed.

**Results:** No severe adverse effect of grade 4 or higher was observed. Of 18 patients who completed at least one course of the treatment, 15 (83%) developed immunological reactions at the injection sites. Specific CTLs reacting to VEGFR2-169 peptide were induced in 11 (61%) of the 18 patients. The disease control rate was 67% and the median overall survival time was 8.7 months.

**Conclusion:** This combination therapy for pancreatic cancer patients was tolerable at all doses. Peptide specific CTLs could be induced by VEGFR2-169 peptide vaccine at a high rate even in the combination with gemcitabine. From an immunological point of view, the optimal dose for further clinical trial might be 2.0 mg/body. Based on the results of this Phase I clinical trial, we developed randomized, placebo-controlled, double blind, multicenter Phase II/III clinical trial. The phase II/III trial enrolled the first patient in January 2009, and completed the enrollment of 150 patients in January 2010.

Immunological response

	CTL response	Reaction at injection site
Level	3/6	3/6
Level	4/6	4/6
Level	4/6	6/6

**Abstract ID: 0253**      Specific Field: **Miscellaneous (Other)**

**Mode of pres.: Poster Exhibition only**  
**ISW 2011 Session PE 140**

**Transcatheter arterial chemoembolization treatment and surgical resection for recurrent malignant paraganglioma with long term survival: a case report**

T. Miyake, H. Abe, T. Shimizu, T. Tani

Shiga University of Medical Science, Otsu-shi, Japan

**Introduction:** A Malignant paraganglioma is known as an aggressive neoplasm arisen from chromaffin cells and poor prognosis, because of distant metastasis and recurrence in several years after resection. But the strategy of treatment for a recurrent malignant paraganglioma has not been established. Here we show that a successfully treatment of TACE and surgical resection for recurrent paraganglioma with a long term survival.

**Material and Methods:** A 50-year-old woman, having a nonfunctional tumor at the upper pole of right kidney with solitary liver metastasis, underwent a tumor excision and a partial resection of liver tumor. The pathological and immunohistological analyses, indicating positive stainings of neural cell adhesion molecule and synaptophysin, proved the adrenal tumor to be a malignant paraganglioma.

**Results:** After follow-up at a local hospital without any therapy for 7 years, she was found to liver tumors by a routine examination. Abdominal Computed tomography findings showed multiple liver tumors and a tumor at the upper pole of right kidney suspected local recurrence. Because multiple hypervascular tumors in the liver were unresectable, we performed Transcatheter arterial chemoembolization treatment for multiple liver metastases. After confirms of the reduction in the size of liver tumors, we resected a local recurrent tumor. The tumor specimens were diagnosed recurrences of malignant paraganglioma by pathological and immunohistological analyses. Moreover the immunohistological examination revealed a negative staining of Ki-67 indicating a low malignancy. Now the patient was followed by our hospital with additional Transcatheter arterial chemoembolization treatment for liver tumors.

**Conclusion:** This is a rare case in point of malignant paraganglioma with a long survival. It has some possibility that Aggressive treatment including transcatheter arterial chemoembolization treatment and surgical resection could contribute better prognosis for malignant paraganglioma with low progression.

**Abstract ID: 0254**      Specific Field: **Miscellaneous (Other)**

**Mode of pres.: Poster Exhibition only**  
**ISW 2011 Session PE 141**

**The importance of pre-compression time and waiting time after each stroke to make an ideal shape of staples in using a dual-compression type stapler**

Y. Sakai, S. Hasegawa, S. Nakayama

Kyoto University Graduate School of Medicine, Kyoto, Japan

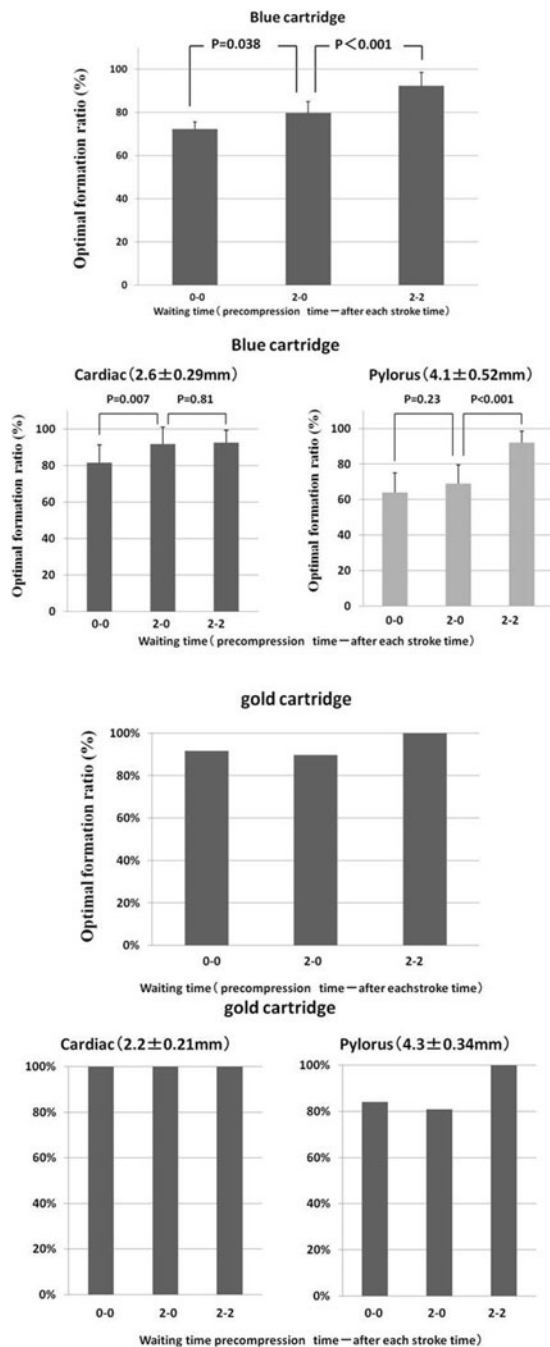
**Introduction:** One of prerequisites for the safe stapling of anastomoses is the formation of perfectly aligned B-shaped staples. In the previous study, using an animal model, we showed that pre-compression enhances secure staple formation. In this study, we investigated whether this is also applicable to dual-compression type stapler.

**Material and Methods:** A 60-mm linear stapler of dual-compression type (Echelon flex<sup>®</sup>) with a blue cartridge (staple leg length: 3.5 mm) and gold cartridge (staple leg length: 3.8 mm) was used on two portions of 9 porcine stomachs (cardia and pylorus). Staple shape was classified into optimal and suboptimal categories. The optimal staple rate (number of optimal staples/total staples) was examined according to the combination of pre-compression (2 min) and inter-stroke (2 min) waiting time (group 1: no waiting, group 2: pre-compression only, group 3: both pre-compression and waiting after each stroke).

**Results:** Regarding blue cartridge, optimal staple rate significantly improved according to the waiting time (Group 1, 2, 3; 71.2, 79.9, 92.4%). The optimal staple rate was also dependent on the wall

thickness, and unsatisfactory (<70%) when used without inter-stroke waiting time on the pylorus (thick: mean wall thickness 4.1 mm) portion. On top aspect of cartridge, worse staple formation (<60%) was observed compared with base aspect, however, was rescued by inter-stroke waiting. On the other hand, using gold cartridge, optimal formation rate was generally more satisfactory, even when used on pylorus portion, compared with using blue cartridge.

**Conclusion:** For optimal staple formation, appropriate selection of cartridge is mostly important using dual-compression type linear stapler. Not only pre-compression time but also waiting time after each stroke enhance the secure staple formation.



**Abstract ID: 0255**

Specific Field: **Miscellaneous (Other)**

**Mode of pres.: Poster Exhibition only**  
**ISW 2011 Session PE 142**

**Application of SOFA score to predict postoperative risk assessment in patients with non traumatic colorectal perforation**

G. Hoshino, H. Hasegawa, Y. Ishi, T. Endo, H. Ochiai, K. Shigeta, Y. Seo, Y. Kitagawa

Department of Surgery, Keio University School of Medicine, Tokyo, Japan

**Introduction:** The purpose of this study was to evaluate the usefulness of predictive scoring system for the postoperative mortality of patients with colorectal perforation using the Acute Physiological and Chronic Health Evaluation II (APACHE II), Sequential Organ Failure Assessment (SOFA) and Physiological and Operative Severity Score for the enUmeration of Mortality and Morbidity (POSSUM).

**Material and Methods:** First, the 3 scoring systems were applied to all the patients, and the efficacy of these systems was compared between survivors and non-survivors. Second, using receiver operating characteristics (ROC) curve analysis, optimal cut-off values were determined for each system and patients were divided into the other two groups (high score group and low score group). Then, statistical analyses were performed, respectively.

**Results:** A total of 30 patients with colorectal perforation were surgically operated in our hospital between April 2006 and May 2010. The postoperative mortality was 16.7% ( $n = 5$ ). There was no statistically significant difference among the patients' background characteristics, operative data, and procedures except the presence of Direct Hemoperfusion with Polymyxin B immobilized fiber (PMX-DHP). In the evaluation of cut-off line detected by ROC curve, all scoring systems gave significantly lower score for survivors than those of non-survivors. SOFA score was the most accurate scoring system for predicting mortality (SOFA: accuracy 93%).

**Conclusion:** SOFA may be an optimal predictor of mortality following emergency surgery for colorectal perforation.

**Abstract ID: 0256**

Specific Field: **Miscellaneous (Other)**

**Mode of pres.: Poster Exhibition only**  
**ISW 2011 Session PE 143**

**Surgical success: a view from the other side of the fence**

E. Davenport, D. Mosquera, W. Gilkison, M. Fancourt, S. Kyle, G. Farrant

Taranaki Base Hospital, New Plymouth, New Zealand

**Introduction:** Surgical quality of care has traditionally been measured from the surgeon's perspective using clinical outcomes such as morbidity and mortality. Patient-reported outcomes (PROs) have only been used rarely in surgical practice despite being used widely in other areas. The aim of this study was to report inpatient satisfaction with surgical care in the general surgical ward at Taranaki Base Hospital and identify differences between demographic groups.

**Material and Methods:** This was a prospective study conducted over 12 months from December 2009, using a patient satisfaction questionnaire based around the Code of Health and Disability Services Consumer's Rights and incorporating relevant questions from the previous literature in this area. The questionnaire was distributed once a fortnight to all general surgical inpatients on the surgical ward of Taranaki Base Hospital.

**Results:** 368 questionnaires were distributed, with a 92% response rate. Overall patient satisfaction was high. Patients were most satisfied with the professional behaviour of doctors on the ward (99%) and least satisfied with knowing what to expect in their health in the future after talking to the doctors (78%). Age showed a statistically significant correlation with satisfaction with younger patients being less satisfied than older ( $P = 0.002$ ). Ethnicity, gender and number of hospital admissions showed no correlation with patient satisfaction.

**Conclusion:** General surgical inpatients at Taranaki Base Hospital are generally satisfied with the care provided by the surgeons. Patient reported outcomes are a useful tool in assessing quality of care from a patient perspective. We plan to extend this study to report patient satisfaction in outpatients.

**Abstract ID: 0257**                      Specific Field: **Miscellaneous (Other)**

**Mode of pres.: Poster Exhibition only**  
**ISW 2011 Session PE 144**

**An interesting case of intestinal pseudo-obstruction in a HIV/AIDS patient secondary to strongyloides stercoralis enteritis**

M.O. Aung, J. Tan, S.K. Pada, CC Lee

Tan Tock Seng Hospital, Singapore, Singapore

**Introduction:** Strongyloidiasis is a chronic intestinal infection caused by the nematode *Strongyloides stercoralis* and is estimated to affect 30 to 100 million people world wide. It is widespread in tropical and subtropical countries. Hyperinfection has been described in immunocompromised patients. A rare complication is intestinal pseudo-obstruction which may present as surgical emergency.

**Material and Methods:** Literature review of the reported cases of Strongyloidiasis. Review of the case notes of the patient.

**Results:** A 54 year old Chinese man, newly diagnosed with HIV, presented with symptoms of intestinal obstruction. He had no previous history of abdominal surgery and underwent exploratory laparotomy after failure of conservative treatment. There was no mechanical obstruction found intra-operatively. Small bowel was dilated to the level of mid jejunum. Intra-operative gastroscopy revealed severe duodenitis and histology showed strongyloidiasis. He was treated with multiple courses of ivermectin and the ileus resolved after one month of conservative management. Unfortunately the patient developed pneumonia and passed away one month later.

**Conclusion:** In immunocompromised patients, strongyloidiasis remains an important pathogen causing disease. Early diagnosis and prompt treatment of this potentially fatal disease can reduce the morbidity and mortality. The clinical suspicion of strongyloidiasis causing paralytic ileus should be considered in immunocompromised patients with no other risk factors for intestinal obstruction. It is however, uncommon in HIV/AIDS, with this case being the first of its kind to be reported. Endoscopy and duodenal biopsy or duodenal aspiration should be considered prior to surgery which has its own incident morbidity and mortality.

**Abstract ID: 0258**                      Specific Field: **Miscellaneous (Other)**

**Mode of pres.: Poster Exhibition only**  
**ISW 2011 Session PE 145**

**Peritoneo-venous shunt system: the beneficial device for refractory ascites**

Y. Sakamoto, K. Furuta, H. Katagiri, K. Ishii, Y. Takahashi, Y. Kumamoto, M. Watanabe

Department of Surgery, Kitasato University School of Medicine, Sagami-hara, Japan

**Introduction:** Although peritoneo-venous shunt (PV shunt) was known as an excellent arm for treatment of refractory ascites, it is sometimes very difficult to decide the timing of operation because of its serious complications such as congestion and disseminated intravascular coagulation (DIC). Authors present a series of patients with P–V shunt operations.

**Material and Methods:** In twenty-nine patients with refractory ascites in our institute from 1993 to 2010, P–V shunt were performed by using Denver or Le Veen shunt system. The background diseases for these patients were including of liver cirrhosis with hepatocellular carcinoma (HCC) (8 cases), liver cirrhosis without HCC (10 cases), peritonitis carcinomatosa from advanced pancreatic cancer (1 case), peritonitis carcinomatosa from advanced gastric cancer (2 cases), primary biliary cirrhosis (1 case), poor nutrition after pancreatoduodenectomy (1 case), Budd-Chiari syndrome (1 case), Idiopathic portal hypertension (1 case), and liver metastasis from advanced colon cancer (4 cases; 2 cases after hepatic resection). The efficacy and patency of shunt system, and outcome after shunt operation were analyzed.

**Results:** In 26 cases, body weight and abdominal circumference were reduced after shunt treatment. 20 patients of 29 were able to discharge. In 14 cases of 29, complication was observed during clinical course. Seven cases died within 10 days after operations due to liver failure and cancer death. The average of survival period was 559 days in all patients. All these patients were suffering from unstable status of respiratory and circulating system before operations. The urine volume and excretion of the urine of sodium of all patients were gained. There was a statistically significant difference in the urine volume and excretion of the urine of sodium between the preoperative and post-operative level. The serum of aldosterone level and serum renin activity values decreased in significantly. We evaluated the preoperative the Model for End-Stage Liver Disease (MELD) score. The patients of the high MELD score range more than 18 had bad convalescence with significant difference in compared with the less than 18.

**Conclusion:** Although P–V shunt is an excellent device for treatment of intractable ascites, the timing of operations should be considered. Less than the MELD score range 18 are recommended as a the timing of P–V shunt operation.

**Abstract ID: 0259**                      Specific Field: **Miscellaneous (Other)**

**Mode of pres.: Poster Exhibition only**  
**ISW 2011 Session PE 146**

**Fish bone granuloma mimicking a small bowel tumor**

V. Viriyaraj

HRH Princess Mahachakri Sirindorn Medical Center, Nakhon-nayok, Thailand

**Introduction:** Small bowel tumors are remarkably rare, found in 3–6% of the gastrointestinal tumors. Most small bowel tumors are incidental finding at operation or autopsy.

**Results:** We report 53-year old man presented with 4-month history of left upper quadrant pain and fever. He was treated for dyspepsia but his symptoms were unimproved. Esophago-gastro-duodenoscopic examination was normal. Computed tomography (CT) scan showed soft tissue mass density at left upper quadrant mass about  $7.0 \times 7.6 \times 6.4$  cm with perilesional fat stranding and indistinguishable from adjacent small bowel thickening. Explore laparotomy was done and revealed ileal mass sized  $7 \times 7$  cm adhered and attached to transverse colon and found 1 fish bone at omentum and 2 fish bones at mesentery of small bowel. Fish bones were removed and segmental small bowel and

transverse colon resection was done. Gross pathological reported showed focal hemorrhage and necrosis and there is a fish bone, measuring 2 cm in length and 0.1 cm in diameter was revealed. Microscopic finding revealed mixed chronic, acute inflammatory cell and foamy histocyte accumulating within the mass with a few scattered multinucleated giant cell. The inflammation extended into the wall on the small intestine. The small and large intestine mucosa were unremarkable. No malignancy was seen. The patient was discharged from the hospital 14 day after operation without morbidity and mortality.

**Conclusion:** This is a case of fish bone granuloma mimicking a small bowel tumor which is a rare cause of a small bowel mass.

**Abstract ID: 0260**      Specific Field: **Miscellaneous (Other)**

**Mode of pres.: Poster Exhibition only**  
**ISW 2011 Session PE 147**

#### **Fish bone migrating into the right renal vein**

T. Iwai [1], H. Yoshida [1], T. Yokoyama [1], H. Maruyama [1], S. Suzuki [1], A. Matsushita [1], K. Sasajima [1], E. Uchida [2]

[1] Department of Surgery, Nippon Medical School Tama Nagayama Hospital, Tokyo, Japan, [2] Department of Surgery, Nippon Medical School, Tokyo, Japan

**Introduction:** Foreign body ingestion is often encountered in the clinical setting. We report a case of fish bone penetration of the duodenum migrating into the right renal vein that was successfully treated by surgery.

**Material and Methods:** The 75-year-old man was admitted to Nippon Medical School Tamagayama Hospital with right upper abdominal pain for 7 days. The medical history was not relevant to the current disorder. A plain radiography was no abnormal findings. Computed tomography (CT) showed that a linear object of high intensity revealed penetration of the duodenum extending into the right renal vein with thrombus. Low density area was detected around the linear object of high intensity, so severe inflammation was suspected. The patient had eaten fish a days before the onset of abdominal pain. We diagnosed duodenal penetration caused by an ingested fish bone. Endoscopic examination showed that erosion was detected but fish bone or ulceration was not detected in the duodenum. The patient was managed conservatively with fasting, peripheral parental nutrition, and intravenous antibiotics. Three days after admission, plane CT showed no movement of the foreign body. The patient had continuing pain, the clinical decision was made to perform surgical exploration of abdomen.

**Results:** In the surgical findings, intraoperative ultrasonography showed that the foreign body migrated completely into the right renal vein with thrombus. Severe inflammation of the right renal vein was observed. We could not remove the foreign body without major injury of the right renal vein, so we underwent right nephrectomy. Macroscopic findings of the surgical specimen confirmed the presence of a fish bone with thrombus in the right renal vein.

**Conclusion:** The patient was discharged 9 days after operation without complication.

**Abstract ID: 0261**      Specific Field: **Colon and Rectum**

**Mode of pres.: Video**  
**ISW 2011 Session 12.01**

#### **Laparoscopic rectal resection without mini-lapatomy with tieless single stapling technique using loop suture**

M. Hara, S. Takayama, M. Sato, H. Takeyama

Nagoya City University, Nagoya, Japan

**Introduction:** For laparoscopic rectal resection, mini-laparotomy has been thought to be necessary for specimen retrieval and anastomosis. However, this sometimes becomes the causes of postoperative complications. Recently, since a prolapsing technique appeared, many reports have demonstrated laparoscopic rectal resection without mini-lapatomy by retrieving specimen transanally. However, in many cases, double stapling technique (DST) or hand suture are used for intracorporeal anastomosis. The former is less reliable, and the latter is complicated especially in tying the thread intracorporeally. Thus, we herein report laparoscopic rectal resection with tieless SST anastomosis using loop suture which we think less complicated and more reliable anastomosis.

**Material and Methods:** This technique is indicated for rectal cancer patient with T1 or T2 tumor invasion. With same procedure as conventional method, proximal enterotomy will performed intracorporeally. We then pull the specimen and the rectum out transanally using Babcock grasper. With tensioned against the patient, retrieval bowel will be cut by electric cautery without hand touch to residual mesorectum. Following the extracorporeal distal bowel division and dissection of perirectal fascia, an anvil is sterilely inserted transanally through the inside-out rectum into the abdominal cavity. After proximal stump of colon is opened, the anvil will be inserted into the proximal colon intracorporeally. Then loop suture (V-Loc, COVI-DIEN) will be inserted via trocar. Purse-string suture will be performed intracorporeally to the cut end of sigmoid colon. This suture has a loop at the tail of this, thus, tying the suture is not necessary. Only pulling the suture after threading it through the loop will complete the purse-string easily and reliably. After extracorporeal purse-string suture on distal stump, single stapling technique anastomosis will be performed using circular stapler.

**Results:** This technique was performed against three rectal cancer patients without any complications. Operation time were not prolonged with this technique compared with conventional method.

**Conclusion:** This technique enable to perform purse-strings suture without tying the thread intracorporeally. We suggest this technique will be useful for reducing surgical complications and making anastomosis easier.

**Abstract ID: 0262**      Specific Field: **Colon and Rectum**

**Mode of pres.: Video**  
**ISW 2011 Session 12.02**

#### **Advanced tactics in laparoscopic low anterior resection for rectal cancer**

K. Tanaka, J. Okuda, K. Kondo, K. Asai, H. Kayano, M. Yamamoto, S. Masubuchi, N. Tanigawa

Osaka Medical College, Takatsuki, Japan

**Introduction:** Magnification and closer view of laparoscopy is really advantageous in anatomical dissection of rectum especially in the narrow and deep pelvis. In rectal cancer surgery, laparoscopy has been recognized as an excellent tool to mobilize the rectum precise to oncologic dissection, just as total mesorectal excision (TME). On the other hand, some limitations of maneuver especially in transection of the lower rectum have been pointed out. Safe anastomosis including proper transection is mandatory to achieve minimally invasive surgery.

**Material and Methods:** To overcome the difficulty in lower rectal resection, we had standardized the technique for laparoscopic low anterior resection by 2006. We recognized the following technical tips as essential. First of all, we have to completely mobilize the rectum,



just above the anal canal, which makes the lower rectum mobile and easy to transect the rectum properly. Proper dissection of mesorectum is another tip to secure the rectal resection. We prefer to use right lower port to put the stapler through, compared to suprapubic port. And we prefer to use 60 mm compression type stapler (echelon60GOLD) as gold standard for rectal resection. We routinely secure the anastomosis after DST, by suturing the anastomotic site intracorporeally. And, in addition to conventional abdominal drain around the anastomotic site, we prefer to put the 22Fr. tube transanally to actively decompress the rectal pressure around the inside of anastomosis.

**Results:** In 2005, we analyzed the past 189 patients about anastomotic leakage in low anterior resection with double stapling technique. Its leakage rate was 7.4% (14/189). Most of them (13/14) were male patients with narrow pelvis. Regarding the distance between anal verge and anastomotic site, leakage rate was highest (15.5%) in 4–5 cm. In addition, multiple firing (more than three times) in transaction of rectum was one of the major factors in high leakage rate. For latest one year after the maturity of this technique, one hundred and one patients underwent laparoscopic low anterior resection using this technique. The percentage of cases having undergone lower rectum resection in one cartridge was 98.0% (99/101), and leakage rate was 1.0% (1/101).

**Conclusion:** The step-by-step improvement of technical tips could lead to the safe anastomosis in laparoscopic low anterior resection for rectal cancer.

#### Abstract ID: 0263 Specific Field: Colon and Rectum

**Mode of pres.: Video**  
ISW 2011 Session 12.03

#### Single incision laparoscopic proctectomy with total mesorectal excision

N.L. Bertelson, T.M. Young-Fadok

Mayo Clinic, Phoenix, USA

**Introduction:** Laparoscopic proctectomy with total mesorectal excision (TME) has been well documented as an acceptable alternative to an open procedure, with evidence of decreased morbidity, length of ileus, and length of stay. The potential for further strides exists with the advent of single incision laparoscopic surgery. We present video footage of a single incision laparoscopic proctectomy (SILP) with TME.

**Material and Methods:** An 85 year old woman presented with T3 invasive adenocarcinoma 4 cm above the anorectal ring; she refused chemoradiation and elected for SILP and temporary ileostomy. After positioning, preparation, and draping, a multiport device was placed through the site of the planned ileostomy, and the abdomen was insufflated. In Trendelenberg with left side up, the attachments between the descending and sigmoid colon and the lateral abdominal wall were taken down with cautery. In reverse Trendelenberg, the lesser sac was entered medially, and the splenic flexure was taken with a vessel coagulating device in a clockwise fashion. In Trendelenberg, cautery was used to enter the presacral space from the left and dissect to the pelvic floor posterolaterally, preserving the hypogastric nerves while maintaining the mesorectal envelope. The presacral space was then entered from the right, and circumferential dissection to the pelvic floor was completed. The rectum was transected with an endoGIA stapler just above the anorectal ring. The superior rectal vessels were taken intracorporeally, and after exteriorization and resection through the port site, a side to end coloanal stapled anastomosis was fashioned. A loop ileostomy was created through the port site. A catheter was placed transanally for drainage.

**Results:** The patient tolerated a low residue diet and had ileostomy output by postop day 2; she was discharged on postop day 4. Her maximum pain on postop day 1 and on day of discharge were both 5 out of 10. Pathology showed complete TME with radial and distal margins of 3 cm. Zero of 24 lymph nodes were positive.

**Conclusion:** Laparoscopic proctectomy has been shown to be comparable to open proctectomy in oncologic outcomes with improvements in morbidity and lengths of stay. We find that SILP can be successfully applied to potentially further diminish morbidity and length of stay while maintaining the oncologic principles of TME, lymph node harvest, and adequate margins.

#### Abstract ID: 0264 Specific Field: Colon and Rectum

**Mode of pres.: Free Paper**  
ISW 2011 Session 20.01

#### Importance of adequate lymph node examination to ensure the prognostic value of lymph node ratio in patients with stage III colorectal cancer

M. Shimomura, M. Okajima, Y. Takakura, Y. Kawaguchi, M. Tokunaga, H. Egi, T. Hinoi, H. Ohdan

Hiroshima University, Hiroshima, Japan

**Introduction:** This study aimed to assess the prognostic value of lymph node ratio (LNR), estimated by dividing the number of positive lymph nodes (LNs) by the number of LNs examined, for stage III colorectal cancer in comparison to the new TNM system (7th edition) and to evaluate the relationship between the number of LNs examined and the prognostic value of LNR.

**Material and Methods:** We retrospectively reviewed clinicopathological data of a cohort of 266 patients with stage III colorectal cancer. The best LNR cut-off value was selected as 0.20 based on ROC analysis. Patients were divided into the following two groups: LNR-low (0–0.2), and LNR-high (0.21–1). We assessed the prognostic impact of LNR on the prediction of cancer recurrence in comparison to the TNM system, and the prognostic value of LNR in patients with low LN count.

**Results:** The 5-year overall survival (OS) for patients with stage IIIA, IIIB, and IIIC disease was 92.4, 71.5, and 41.7%, respectively ( $P = 0.0001$ ). According to LNR grading, the 5-year OS in the LNR-low and LNR-high groups was 81.3 and 59.7%, respectively ( $P = 0.0032$ ). In the multivariate analysis of selected variables found to be significant in the univariate analysis, LNR was found to be an independent risk factor of cancer recurrence (Table). The application of LNR in addition to the new TNM system was more predictive of survival than the TNM system alone. A prognostic separation by LNR was observed in patients with adequate LNs examined, but not in patients with low LN count (Figure).

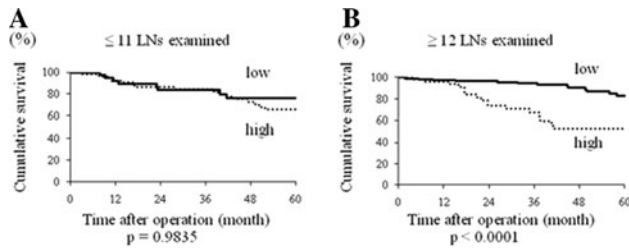
**Conclusion:** A stronger prognostic separation can be observed by using LNR together with the new TNM system. Adequate LN examination is important to ensure the prognostic value of LNR in patients with stage III colorectal cancer.

**Table** Risk factor of disease free survival: multivariate analysis

	<i>P</i> value	Hazard ratio	95% Confidence interval
Location (rectum)	0.0047	1.8933	1.219–2.9412
TNM tumor stage (T3, T4)	0.0779	1.7342	0.9158–3.2787
TNM nodal stage (N2)	0.9296	1.0231	0.6161–1.7007

**Table** Risk factor of disease free survival: multivariate analysis

	<i>P</i> value	Hazard ratio	95% Confidence interval
Lymphatic invasion (positive)	0.1080	1.7670	0.8396–0.3717
Serum CEA level (>5.0 ng/ml)	0.1048	1.4503	0.9259–2.2727
LNR (high)	0.0003	2.4247	1.4970–3.9216

**Figure** Overall survival (OS) in the LNR-low and LNR-high subgroups analyzed separately for patients with 11 or fewer LNs examined (a) and 12 or more LNs examined (b)**Abstract ID: 0265** Specific Field: **Colon and Rectum****Mode of pres.: Free Paper**  
**ISW 2011 Session 20.02****WT1 expression provides prognostic value in colonic cancers, independent of tumor stage**

T. Bejrananda [1], M. Phukaoloun [2], T. Boonpipattanapong [1], W. Wanitsuwon [1], S. Sangkhathat [3]

[1] Department of Surgery, Faculty of Medicine, Prince of Songkla University, Hat Yai, Songkhla, Thailand, [2] Department of Pathology, Faculty of Medicine, Prince of Songkla University, Hat Yai, Songkhla, Thailand, [3] Tumor Biology Research Unit, Faculty of Medicine, Prince of Songkla University, Hat Yai, Songkhla, Thailand

**Introduction:** WT1 has been proven to be a prognostic marker and molecular target in various human cancers. In this study, we aimed to investigate the prognostic role of WT1 in colorectal cancers (CRCs).**Material and Methods:** Archival tissue samples from 157 CRC cases who underwent curative surgery in our institute from February 1999 to May 2004 were subjected to WT1 expression studies using an immunohistochemistry technique. Number of positive staining per 500 tumor cells (nWT500) and staining intensities (iWT; 0–3) were analyzed against overall survival (OS).**Results:** Of 157 CRCs, 83 were colonic and 74 were rectal cancers. Mean follow-up period was 3,498 days (2,189–4,275 days). Seven- and five-year OS were 60.9 and 52.8%, respectively. WT1 immunostaining was positive in 143 cases (91%). The median nWT500 was 120 (range 0–420). Univariate analysis by Log-rank test showed that AJCC stage, tumor site (colon), nWT500 of more than 120 cells and iWT were significantly associated with poorer survival (*P* value < 0.01). Five-year survival in cases with nWT500 of <120 cells and

&gt;120 cells were 72.2 and 49.4%, respectively. Five-year survival in cases with iWT of 2 or more was 45.3%, compared with 69% in cases with iWT of less than 2. Multivariate regression analysis demonstrated that iWT was an independent factor indicating poorer survival (Table 1).

**Conclusion:** Our findings indicate that WT1 expression is a prognostic marker in colonic cancers, independent of tumor stage.**Table 1** Final multivariate survival analysis model using Cox hazard regression

	Cox hazard ratio	95% confidence interval	<i>P</i> value
AJCC stage	2.775	1.994–3.862	<0.001
Site of disease (rectum)	2.188	1.382–3.470	<0.001
WT1 staining intensity (iWT)	2.034	1.294–3.197	<0.001

**Abstract ID: 0266** Specific Field: **Colon and Rectum****Mode of pres.: Free Paper**  
**ISW 2011 Session 20.03****Increased risk for CRC in diabetic patients with the non-risk allele of SNP's at 8q24**

K. Mimori [1], H. Inoue [1], K. Yamamoto [1], S. Suzuki [2], M. Mori [3]

[1] Kyushu University, Beppu, Japan, [2] Nagoya City University, Nagoya, Japan, [3] Osaka University, Suita, Japan

**Introduction:** Colorectal cancer (CRC) oncogenesis is considered to be determined by interactions between genetic and environmental factors. Specific interacting factors that influence CRC morbidity have yet to be fully investigated.**Material and Methods:** A multi-institutional collaborative study with 1758 CRC patients and 2962 control subjects was used to compare the odds ratios for the occurrence of polymorphisms at eleven known single nucleotide polymorphisms (SNPs). TaqMan PCR and questionnaires were used to evaluate the effects of environmental exposures. Then, we performed microarray analysis of genes from cancer cells extracted from 110 primary tumors by laser microdissection.**Results:** Variants of rs6983267 on 8q24 were the most significant markers of risk for CRC (OR = 1.16 (1.06–1.27), *P* = 0.0015). Non-insulin-dependent diabetes mellitus, a higher body mass index (BMI) at age 20 and meat consumption were environmental risk factors, whereas a tuna-rich diet and vitamin intake were protective factors. The cohort of rs6983267 SNP major (T) allele at 8q24 and diabetes had a 1.66 fold higher risk ratio than the cohort of major allele patients without diabetes. Meta-analysis of gene profiles (MetaGP) provide a clue to explain the risk for CRC in major allele at rs6983267 with diabetes mellitus.**Conclusion:** We confirmed that interactions between the genetic background and environmental factors are associated with increased risk for CRC. There is a robust risk of the minor G-allele at the 8q24 rs6983267 SNP, however, a major T-allele SNP could more clearly reveal a correlation with CRC specifically when diabetes mellitus is present.

**Abstract ID: 0267** Specific Field: **Colon and Rectum**

**Mode of pres.: Free Paper**  
**ISW 2011 Session 20.04**

**The effect of glutamine and synbiotics on healing of colonic anastomosis**

N. Sapidis [1], I. Triantafyllidis [1], I. Kalaitidou [1],  
 I. Taitzoglou [2], E. Petridou [3], D. Botsios [4]

[1] Edessa General Hospital, Edessa, Greece, [2] Laboratory of Physiology, Faculty of Veterinary Medicine, Aristotle University, Thessaloniki, Greece, [3] Department of Microbiology and Infectious Diseases, School of Veterinary Medicine Aristotle University, Thessaloniki, Greece, [4] Papanikolaou University Hospital, Aristotle University, Thessaloniki, Greece

**Introduction:** Intestinal wound healing is an essential process for surgical reconstruction of the digestive tract. Many factors which may affect the success of anastomotic healing have been studied. The purpose of this study is to evaluate the possible positive effect of perioperative administration of glutamine, as well as synbiotics on the biological behavior of intestinal mucosal barrier and the healing of colonic anastomoses in rats.

**Material and Methods:** Eighty Wistar rats were randomized in five groups ( $n = 16$ ), according to treatment. Group A: Control. Group B: Mechanical bowel preparation and antibiotics. Group C: Glutamine. Group D: Synbiotic. Group E: Glutamine and Synbiotic. Eight of the animals in each group were sacrificed on 3rd postoperative day and the remaining on 7th postoperative day. The integrity of the anastomosis, the adhesion formation and the bursting pressure were recorded. Subsequently, the colon segment containing the anastomosis was sent for histological examination and the inflammatory cell infiltration (white blood cell count), fibroblast activity, neoangiogenesis and collagen deposition were also examined. The second segment of the anastomotic site was sent for measurement of hydroxyproline.

**Results:** Zero mortality and no septic complications were noted in any group. All animals decreased in weight during the experiment. After surgery on 3rd and on 7th postoperative days, a significant weight loss was observed in all groups in comparison with the preoperative weights. The bursting pressures as well as the hydroxyproline tissue content were significantly higher in group E (glutamine and synbiotic) on 3rd and on 7th postoperative days. Neoangiogenesis and fibroblast activity was significantly higher in the E group. The average inflammatory cell infiltration was significantly reduced, on 3rd postoperative day in A group compared to D and E groups. Quantitative culture of mesenteric lymph nodes was used as an indicator of bacterial movement. In our study, on both 3rd and 7th postoperative days, the largest percentage of positive cultures was observed in group A.

**Conclusion:** The administration of synbiotic in conjunction with glutamine increases the microcirculation in the mucosa, the inflammatory reaction in the region of anastomosis, and fibroblast activity and collagen deposition in colon anastomoses. These actions resulted in increasing the mechanical strength of the anastomoses.

**Abstract ID: 0268** Specific Field: **Colon and Rectum**

**Mode of pres.: Free Paper**  
**ISW 2011 Session 20.05**

**Preoperative glucocorticoid administration for elective colectomy within an enhanced recovery after surgery programme**

D.P. Lemanu, S. Srinivasa, A.A. Kahokehr, K. Zargar Shoshtari,  
 P.P. Singh, A.G. Hill

South Auckland Clinical School, Auckland, New Zealand

**Introduction:** Preoperative glucocorticoids (GC) have been shown to decrease post surgical fatigue, nausea and vomiting by attenuating the physiological stress response to surgery. However, the safety of preoperative GCs has yet to be established with regards to post operative complications, in particular, infectious complication and anastomotic leaks. A review of data was therefore performed to evaluate efficacy and safety.

**Material and Methods:** A retrospective review of prospectively collected data was conducted for all patients who had undergone major colonic surgery within an Enhanced Recovery after Surgery programme at our institution from 2006 to 2010. Demographic data, operative characteristics, glucocorticoid administration (Dexamethasone Sodium Phosphate Injection, 8 mg/ml; Hospira, Wellington, New Zealand) and clinical outcomes were recorded. Thirty day complications were recorded and graded as per the Clavien–Dindo classification. Infectious complications, anastomotic leaks and length of hospital stay (LOS) were specifically explored and included in the final analysis. Parametric and non-parametric analysis was conducted as appropriate.

**Results:** There were 141 patients included in the final analysis of which 106 received preoperative GC. There were no significant differences at baseline between patients that received GC and those that did not. There were no significant differences in clinical outcomes between patients that received GC and those that did not with regard to total complications (GC: 46 (43%); non-GC: 15 (46%);  $P = 0.85$ ), major complications (GC: 12 (11%); non-GC: 5 (17%);  $P = 0.39$ ) and infectious complications (GC: 20 (19%); non-GC: 8 (23%);  $P = 0.63$ ). There was no significant difference in the incidence of anastomotic leaks between the two groups (GC: 5 (4%); non-GC 1 (3%);  $P = 1.00$ ). The median LOS did not vary significantly between the two groups (GC: 4; non-GC: 5;  $P = 0.38$ ).

**Conclusion:** Preoperative GC administration in elective colonic resection does not increase the risk of postoperative complications and may be associated with decreased LOS.

Comparison of outcomes in patients who received preoperative glucocorticoid and those who did not

	Dex	Non Dex	<i>P</i> value
Total complications (%)	43	46	0.85
Major complications (%)	11	17	0.39
Infectious complications (%)	19	23	0.63
Anastomotic leaks (%)	4	3	1.00
Length of hospital stay (median)	4	5	0.38

**Abstract ID: 0269** Specific Field: **Colon and Rectum**

**Mode of pres.: Free Paper**  
**ISW 2011 Session 20.06**

**Primary human xenografting in human colorectal cancer**

P.J. McMurrick [1], E.J. Andrews [1], V. Dias [2], G. Hannigan [2],  
 A.L. Polglase [1], K.C. Farmer [1], P. Carne [1], S. Bell [1]

[1] Cabrini Monash Department of Surgery, Cabrini Hospital, Melbourne, Australia, [2] Centre for Cancer Research, Monash Institute of Medical Research, Clayton, Australia

**Introduction:** Primary human xenografting involves the acquisition of fresh tumour tissue during surgery and implantation directly into immuno-deficient mice. Recent studies have suggested the utility of primary cancer xenografts as a model for cancer biology and for

examining response to chemotherapy. We sought to commence a primary xenografting programme for colorectal tumours in our Department.

**Material and Methods:** Primary human colon cancer cells ( $n = 20$ ) were injected subcutaneously into NOD scid gamma mice. Mice were sacrificed when the resultant tumour measured 1cm and tumour cells were re-injected subcutaneously into BALB/c nude mice to maintain tumour growth in vivo. Xenograft tumours were also fixed in formalin, paraffin embedded and immunostained for integrin-extracellular matrix connection proteins. Mice that do not form tumours were sacrificed at 6 months post-transplantation.

**Results:** Four of the 20 primary CRCs injected into mice successfully transplanted and formed tumours. These four primary tumours and their subsequent tumour passages underwent detailed analysis comparing the xenografted tumour to the original tumour. The xenografted tumour was further examined for immunohistochemical Integrin-Linked Kinase (ILK) staining in the tumour stroma and epithelium that correlated with results of archived tumour samples.

**Conclusion:** A primary xenografting programme offers considerable benefits to individual patients, research facilities and theoretically, the pharmaceutical industry. It is feasible as part of a University Department with links to appropriate laboratory facilities, research infrastructure and finance. We have demonstrated that our ability to model human cancer in mice can be used to determine the potential application of novel anti-cancer therapies.

**Abstract ID: 0270** Specific Field: **Colon and Rectum**

**Mode of pres.: Free Paper**  
**ISW 2011 Session 20.07**

**Investigation of the efficacy of measurement of a serum anti-p53 antibody level as a preoperative screening test**

H. Iwamoto [1], T. Hotta [1], K. Takifuji [1], S. Yokoyama [1], K. Matsuda [2], Y. Oku [1], N. Yamamoto [1], H. Yamaue [1]

[1] Wakayama Medical University, Wakayama, Japan, [2] Wakayama Medical University, Japan

**Introduction:** A p53 gene mutation is very frequent in patients with colorectal cancer. And an anti-p53 antibody appears in serum frequently. On the other hand, serum CEA and CA19-9 levels have been important markers for patients with colorectal cancer. In this study, we try to clarify the efficacy of the combination of these markers for the first time.

**Material and Methods:** We measured serum anti-p53 antibody, CEA, and CA19-9 levels in 278 patients with colorectal cancer, underwent surgery in Wakayama Medical University Hospital between June, 2008 and August, 2010. We investigated an efficacy of a preoperative measurement of a serum anti-p53 antibody level, comparing with those of CEA and CA19-9 in patients with colorectal cancer. Furthermore, we examined the most efficient combination among them.

**Results:** A Positive predictive value (PPV) in measurement of a serum anti-p53 antibody level, a serum CEA level and a serum CA19-9 level were 30.4, 26.5 and 15.8%, respectively. A PPV of a serum anti-p53 antibody level was significantly higher than that of a serum CA19-9 level ( $P < 0.001$ ). A PPV in combination measurement of serum anti-p53 antibody and CEA levels, those of serum anti-p53 antibody and CA19-9 levels, those of serum CEA and CA19-9 levels, combination measurement of a serum level of all markers were 49.1, 40.9, 32.6 and 52.9%, respectively. A PPV in combination

measurement of serum anti-p53 antibody and CEA levels was significantly higher than those of serum CEA and CA19-9 levels ( $P < 0.001$ ), moreover those of serum anti-p53 antibody and CA19-9 levels was also significantly higher than those of serum CEA and CA19-9 levels ( $P = 0.043$ ). A PPV in combination measurement of a serum level of all markers was significantly higher than those of serum CEA and CA19-9 levels ( $P < 0.001$ ). However a PPV in combination measurement of a serum level of all markers was not higher than those of serum anti-p53 antibody and CEA levels ( $P = 0.350$ ).

**Conclusion:** We demonstrated that a measurement of a serum anti-p53 antibody level was as efficient as that of CEA and CA19-9, as a conventional preoperative test in patients with colorectal cancer. Furthermore, we clarified that a PPV in combination measurement of serum anti-p53 antibody and CEA levels is most effective as a preoperative screening test in patients with colorectal cancer for the first time.

**Abstract ID: 0271** Specific Field: **Colon and Rectum**

**Mode of pres.: Free Paper**  
**ISW 2011 Session 20.08**

**A comparison of the colorectal surgical research across USA, Europe and Australasia**

S. Srinivasa, R.B. D'Souza, L.S. Hill, A.G. Hill

Department of Surgery, University of Auckland, Auckland, New Zealand

**Introduction:** The annual scientific meetings of the American Society of Colon and Rectal Surgeons (ASCRS), the European Society of Coloproctology (ESCP) and the Royal Australasian College of Surgeons (RACS) are major fora for presentation of colorectal surgical research. Therefore, content at these meetings represents the health of colorectal surgical research and the current research agenda. There has previously been no appraisal of the quantity, quality or focus of colorectal surgical research.

**Material and Methods:** A critical appraisal was conducted for all published abstracts from the ASCRS, ESCP and colorectal-specific component of RACS-ASC from 2006 to 2010. Abstracts were coded by predefined categories pertaining to study type and topics.

**Results:** The number of abstracts per year varied from 173 to 411 at ASCRS, 379 to 454 at ESCP and 22 to 47 at RACS. Level 1 evidence (systematic reviews/meta-analyses) and level 2 evidence (randomised controlled trials) comprised 4% (0–10%) and 6% (3–13%) of the abstracts respectively. There was a predominance of level 4 evidence (retrospective studies) across all years (mean 52%, range 44–68%). Operative management formed the highest component of published research abstracts (mean 45%, range 39–56%). There was minimal research in peri-operative care (6%; 2–14%) and basic surgical sciences (5%; 2–11%). Research related to peri-operative care was significantly higher at the RACS compared to the ASCRS and ESCP meetings ( $P < 0.01$ ). There were no other significant regional differences noted.

**Conclusion:** The majority of colorectal surgical research consists largely of retrospective reviews exploring operative management with minimal high quality scientific content. Although the content and diversity of colorectal surgical research is largely consistent with the stated research agenda, active steps need to be taken to increase the quantity of high level evidence especially in topics other than operative management.



**Abstract ID: 0272** Specific Field: **Colon and Rectum**

**Mode of pres.: Free Paper**  
**ISW 2011 Session 20.09**

**Evaluation of modified estimation of physiologic ability and surgical stress (mE-PASS) in colorectal carcinoma surgery**

Y. Haga [1], Y. Wada [2], M. Ikenaga [3], H. Takeuchi [4]

[1] National Hospital Organization Kumamoto Medical Center, Kumamoto, Japan, [2] National Hospital Organization Himeji Medical Center, Himeji, Japan, [3] National Hospital Organization Osaka Medical Center, Osaka, Japan, [4] National Hospital Organization Iwakuni Clinical Center, Iwakuni, Japan

**Introduction:** We recently modified our prediction scoring system called Estimation of Physiologic Ability and Surgical Stress, and designated this modified version as mE-PASS (Ann Surg, in press). This estimation method uses a scoring system to preoperatively predict the postoperative mortality rates. This study evaluated its usefulness in elective surgery for colorectal carcinoma.

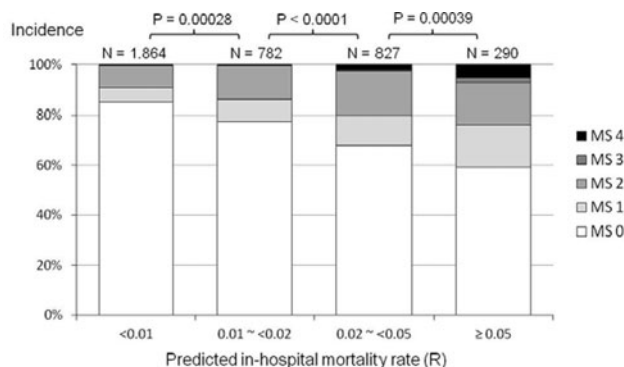
**Material and Methods:** We investigated seven variables for mE-PASS and the postoperative course in 3,763 patients who underwent elective surgery for colorectal carcinoma between October 3, 1987 and April 16, 2007. Predicted in-hospital mortality rates (R) were quantified in each patient. Calibration and discrimination power of R were assessed using the Hosmer–Lemeshow test and area under receiver operating characteristic curve (AUC), respectively. The ratios of observed-to-estimated mortality rates (OE ratio) were quantified as a measure of quality. We divided the study period into three phases; early period from 1987 to 2000, middle period from 2001 to 2004, and late period from 2005 to 2007 in order to investigate any historical change in the quality of care.

**Results:** The overall postoperative morbidity and mortality rates were 22.4 and 0.98%, respectively. R demonstrated a good power in calibration (chi-square value, 15.1; degree of freedom 8;  $P = 0.87$ ) as well as discrimination (AUC, 95% confidence interval: 0.85, 0.80–0.90). When the R increased, postoperative morbidity and mortality rates significantly increased (Figure). OE ratios between the hospitals ranged from 0 to 1.3 (Table). In total, the OE ratio seems to be improved as time goes by (OE ratio, 95% confidence interval: 0.75, 0.38–1.6 for early period; 0.59, 0.33–1.2 for middle period; 0.44, 0.26–0.87 for the late period).

**Conclusion:** mE-PASS may be useful for medical decision-making, providing informed consent and estimating quality of care in elective surgery for colorectal carcinoma.

**Table** Quality of care in colorectal carcinoma surgery between hospitals

	N	Observed deaths	Estimated deaths	OE ratio (95% CI)
Hospital A	294	2	6	0.33 (0.11–1.6)
Hospital B	302	4	3	1.3 (0.27–5.9)
Hospital C	201	0	3	0
Hospital D	440	7	9	0.78 (0.31–2.1)
Hospital E	398	5	9	0.56 (0.22–1.6)
Hospital F	268	4	5	0.80 (0.23–2.9)



MS: Morbidity score; 0, no complications; 1, mild complications; 2, moderate complications that were potentially life-threatening unless adequate treatment was performed; 3, severe organ dysfunction that usually required mechanical support; 4, in-hospital deaths due to complications

**Figure:** Relationship between Comprehensive Risk Score fixed (CRSf) and severity of postoperative complications

**Abstract ID: 0273** Specific Field: **Colon and Rectum**

**Mode of pres.: Free Paper**  
**ISW 2011 Session 20.10**

**Optimisation of in-hospital thromboprophylaxis in colorectal cancer surgery and the need for extended thromboprophylaxis**

R. Chandra, G. Melino, M. Lawrence, M. Thomas, A. Hunter, J.W. Moore

Royal Adelaide Hospital, Adelaide, Australia

**Introduction:** The use of in-hospital thromboprophylaxis for patients at risk of venous thromboembolism (VTE) has been shown to be sub-optimal. Meanwhile, the optimal duration of thromboprophylaxis in colorectal cancer surgery is unknown. This study aimed to determine the incidence of VTE in all patients undergoing colorectal cancer surgery at the Royal Adelaide and Queen Elizabeth Hospitals from 2007 to 2009 and to audit compliance with thromboprophylaxis protocols.

**Material and Methods:** Patients undergoing colorectal cancer surgery from 2007 to 2009 were identified from a prospective database. Subsequent case note review was conducted for patient demographics, VTE risk factors, types of thromboprophylaxis used, complications, and rates of VTE (including post discharge VTE within 30 days). Documented compliance with unit VTE prophylaxis protocol was calculated.

**Results:** A total of 254 patients were identified (64% male). The median age was 70. The mean body mass index (BMI) was 28.5. Metastatic disease was found in 44 (17.3%) patients. An American Society of Anesthesiology (ASA) Score greater than III was found in 103 (40.6%) patients. Fourteen (5.5%) had a past history of VTE. Four (1.6%) were on either hormone replacement therapy or the oral contraceptive pill. Only 29 (16.8%) received thromboprophylaxis at induction of anaesthesia. Post operative pharmacologic thromboprophylaxis was used on 245 (96.5%) patients. TED stockings were used on 213 (83.9%) while 135 (53.1%) had intra-operative pneumatic compression devices (PCDs) documented. A total of 3 VTE events were identified (incidence 1.2%). Only one patient was re-admitted with VTE within 30 days, a post discharge VTE rate of 1/254 (0.39%).

**Conclusion:** High rates of in hospital thromboprophylaxis are associated with a low risk of post discharge VTE. Improvement in compliance with the use of PCDs and thromboprophylaxis at induction of anaesthesia may further reduce risk without the need for extended prophylaxis.

**Abstract ID: 0274** Specific Field: **Colon and Rectum**

**Mode of pres.: Video**  
**ISW 2011 Session 32.06**

**Laparoscopic lateral pelvic lymph node dissection for advanced lower rectum**

M. Kotake, T. Yamada, H. Bando

Ishikawa Prefectural Central Hospital, Kanazawa, Japan

**Introduction:** The effect of lateral pelvic lymph node dissection for lower rectum has been controversial. Particularly the result of prophylactic lymph node dissection has been unknown. But five-year survival rate of lymph node dissection is about 40% in the case of metastatic pelvic lymph node. It is equivalent to hepatectomy for liver metastasis. Our preliminary data of laparoscopic lateral pelvic lymph node dissection (LLPLND) is reported.

**Material and Methods:** Since the beginning of 2010, we performed 13 cases of laparoscopic pelvic lymph node dissection. The LLPLND was started after anterior resection of rectum. At first the ureter was isolated by tape not to be damaged. The laparoscopic coagulating shears was useful for dissection. The dissection proceeded along common and external iliac artery downward. And the adipose tissue between external and internal was dissected from lateral to medial. It was important to grasp the tissue strictly and keep traction. This made the border between dissected tissue and pelvic wall clear. The obturator artery and vein were resected. Finally the tissue between internal iliac artery and pelvic plexus was dissected. When pelvic lateral lymph nodes were diagnosed as metastatic, pelvic plexus and internal vessels were resected.

**Results:** The patients were 6 male and 7 female. Their age was 38–73 years (average 62 years). Prophylactic dissection took about 120 min. And it took 180 min by radical dissection. Blood loss was 5–100 ml (average 24 ml). Three patients had lateral lymph node metastases and radical dissection was performed in two cases. Three needed self-catheter for neurogenic bladder. But all could terminate it.

**Conclusion:** The most serious problem of LLPLND was time-consuming. But this procedure could be performed safely with little blood loss. Permanent neurogenic bladders have never occurred in any patients.

**Abstract ID: 0275** Specific Field: **Colon and Rectum**

**Mode of pres.: Video**  
**ISW 2011 Session 32.07**

**Laparoscopic surgery for colorectal cancer: nine years experience of a single institution**

J. Tanaka, F. Ishida, S. Endo, E. Hidaka, K. Ikehara, N. Sawada, S. Kudo

Showa University Northern Yokohama Hospital, Yokohama, Japan

**Introduction:** Laparoscopy-assisted colorectal resection (LAC) has been indicated for colorectal cancer (CRC).

**Material and Methods:** Advanced T3 CRC as well as early T1 and T2 CRC were indicated to LAC. However, T4 CRC, greater than 7 cm in size, extensive lymph node metastases, active intestinal obstruction, or T3/T4 lower rectal cancer was excluded from LAC. According to medial approach, vascular dissection with lymph node dissection and bowel mobilization were carried out. Functional end to end anastomosis for the colon through the small skin incision or intracorporeal double stapling technique (DST) anastomosis for the rectum was performed.

**Results:** LAC was performed in 1119 (63.6%) patients out of 1754 primary CRC pts during recent 9 years; 709 (66.5%) out of 1066 pts with colon cancer, 407 (59.2%) out of 688 pts with rectal cancer. Conversion to open surgery (OS) was 79 pts (7.1%). Postoperative intestinal obstruction was 3.8% in LAC and 6.1% in OS, meanwhile anastomotic insufficiency was 4.5% in LAC, 3.3% in OC, respectively. As for prognosis, 5 year survival rate after LAC, 95.5, 80.4 and 75.8% for Stages I, II, and III CRC, respectively. Therefore, LAC for CRC is not inferior to OS in terms of morbidity and oncology.

**Conclusion:** LAC for CRC including T3 cancer is a feasible procedure.

**Abstract ID: 0276** Specific Field: **Colon and Rectum**

**Mode of pres.: Free Paper**  
**ISW 2011 Session 50.01**

**Impact of surgical bowel occlusion and intraluminal lavage on the presence of exfoliated malignant cells at anastomoses after colon cancer surgery**

J. Hasegawa [1], J. Nishimura [2], R. Nezu [1]

[1] Osaka Rosai Hospital, Sakai, Japan, [2] Graduate School of Medicine, Osaka University, Suita, Japan

**Introduction:** Exfoliated malignant cells present along staple lines of anastomosis may be responsible for anastomotic recurrence of colon cancer. We aimed to assess the impact of surgical bowel occlusion around the tumor and intraluminal lavage on the presence of exfoliated malignant cells at anastomosis sites in patients with colon cancer.

**Material and Methods:** In this prospective study, 32 patients with colon cancer requiring right hemicolectomy between January 2007 and September 2008 were randomly assigned to a control group (no surgical bowel occlusion; 18 patients) and a “no-touch” group that underwent surgical bowel occlusion around the tumor before tumor manipulation (14 patients). The fluid used intraoperatively to irrigate the portion of the bowel clamped distal to the tumor was examined cytologically, and exfoliated cells of cytological classes IV and V were considered malignant.

**Results:** In the control group, 2 (11.1%) and 10 (55.6%) of 18 patients had exfoliated malignant cells at the terminal ileum and distal colon anastomosis sites, respectively; however, only 1 (7.1%) of the 14 patients in the no-touch group had exfoliated malignant cells at both the sites. The frequency of exfoliated malignant cells at the distal colon anastomosis site was significantly lower in the no-touch group ( $P = 0.0024$ ). No exfoliated malignant cells were found upon saline irrigation of 400 ml or more in either group.

**Conclusion:** Measures such as surgical bowel occlusion around the tumor and intraluminal lavage can prevent or eliminate exfoliated malignant cells at anastomotic sites in patients with colon cancer.

**Abstract ID: 0277** Specific Field: **Colon and Rectum**

**Mode of pres.: Free Paper**  
**ISW 2011 Session 50.02**

**Is there any efficacy for pelvic peritoneum resection in colorectal cancer patients with peritoneal carcinomatosis?**

T. Sato [1], J. Tasiro [2], T. Ishii [2], S. Yamaguchi [2], I. Koyama [2]  
 [1] Saitama International Medical Center, Hidaka, Japan, [2] Saitama International Medical Center, Japan

**Introduction:** Peritonectomy and perioperative intraperitoneal chemotherapy with hyperthermia is one of the best modality for peritoneal carcinomatosis from colorectal cancer. Whereas, life-threatening complications sometimes occur in such therapy. We hypothesized pelvic peritoneum resection is curable method for peritoneal carcinomatosis which is limited in superficial pelvic peritoneum avoiding intraperitoneal chemotherapy.

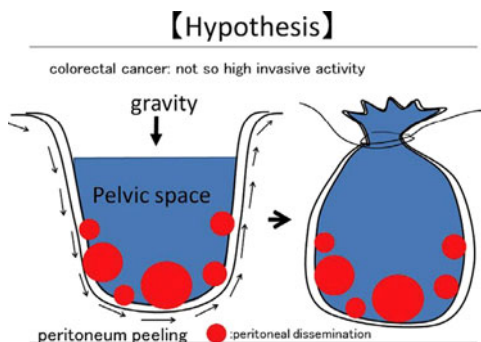
**Material and Methods:** Seven patients with synchronous localized peritoneal dissemination underwent pelvic peritoneum resection. Male/Female = 5/2. Age ranged 42–83 (Med, 66) y.o. Tumor location was sigmoid/rectosigmoid/rectum = 4/2/1-cases. Seven cases were T4 without distant metastasis other than peritoneal dissemination. Lower anterior resection/anterior resection/Miles' operation/Hartmann's operation = 3/2/1/1. This operation's features are as follows; 1. Minimizing combined resection of the other organ. 2. Reducing the postoperative dead space of pelvis. 3. No intraperitoneal chemotherapy. 4. Pelvic peritoneum resection is peeling the peritoneum.

**Results:** In all cases, R0 resection was successfully performed. Median operation time and intraoperative blood loss was 272 and 231 ml, respectively. Mortality ratio and life-threatening morbidity was 0, in both. Three-years overall survival ratio is 100%, and 3-years disease free survival ratio is 80%. Pelvic peritoneum resection improved the prognosis. Postoperatively, serum CEA level decreased significantly ( $P < 0.05$ ). No local recurrence occurred. Liver metastasis and lung metastasis developed in only one case.

**Conclusion:** Pelvic peritoneum resection is new and feasible for colorectal cancer with peritoneal carcinomatosis. Avoiding combined resection of adjacent organs, postoperative dead space could be minimized. This method is easy without life-threatening complications and very simple without intraperitoneal chemotherapy. This approach is recommendable for general hospitals as well as high volume centers. To our knowledge, this technique and concept is the first report (Figure).

**Table** Serum CEA level

	Pre-op	Post-op
Serum CEA level(Hg/ml)	8.7	1.4



**Figure** Hypothesis

**Abstract ID: 0278** Specific Field: **Colon and Rectum**

**Mode of pres.: Free Paper**  
**ISW 2011 Session 50.03**

**Doubling time of CEA is a significant prognostic factor after the surgical resection of locally recurrent rectal cancer**

S. Imada, S. Noura, M. Ohue, S. Kano, T. Shingai, K. Tanaka, M. Yano, O. Ishikawa

Osaka Medical Center for Cancer and Cardiovascular Diseases, Osaka, Japan

**Introduction:** Patients undergoing a curative rectal cancer resection have a risk of developing loco-regional recurrence. A curative resection for local recurrence is the option of improvement in prognosis. However, a curative resection is sometimes too invasive and should be considered in selected patients.

**Material and Methods:** A total of 43 patients with locally recurrent rectal cancer who had been treated by operation between 1989 and 2007 were retrospectively reviewed, and the factors including CEA-dt (doubling time of carcinoembryonic antigen) were analyzed.

**Results:** The 5-year overall survival rate after the operation for local recurrence was 50.8%. Gender, presence of distant metastasis, tumor size, CEA-dt and curability were found to be significant prognostic factors. A multivariate analysis demonstrated the presence of distant metastasis, CEA-dt and tumor size to be significant prognostic factors for overall survival. The 5-year overall survival rates of patients with the CEA-dt 150 days and a tumor size <5 cm were 76.9%.

**Conclusion:** The tumor size and CEA-dt were useful prognostic factors that were recognizable before surgery. Patients with locally recurrent rectal cancer with a CEA-dt 150 days and a recurrent tumor size <5 cm are considered to be good candidates for surgery.

**Abstract ID: 0279** Specific Field: **Colon and Rectum**

**Mode of pres.: Free Paper**  
**ISW 2011 Session 50.04**

**Factors influence on the postoperative delirium of elderly patients with colorectal surgery**

Y. Kurose, H. Idani, M. Ikeda, K. Nakano, S. Asami, S. Kubo, H. Kin, N. Takakura

Fukuyama City Hospital, Fukuyama, Japan

**Introduction:** Postoperative delirium (POD) has become one of common and crucial problems as the number of elderly patients requiring surgery has been increasing. This study evaluated the incidence of POD in patients undergoing colorectal surgery, the risk factors associated with POD and the impact of laparoscopic surgery (LS) on preventing POD.

**Material and Methods:** From January to December 2008, a total of 148 patients undergoing elective colorectal surgery in our hospital were enrolled in this study. Delirium was diagnosed by DSM-IV and data were collected prospectively.

**Results:** Patients consisted of 79 men and 69 women with a mean age of 66 years. LS was performed on 91 patients, whereas open surgery (OS) was on 57 patients. There was a tendency of longer operation time (165 vs. 148 min) but significant lower blood loss (65.5 vs. 252 g) in laparoscopic surgery. No operative death was marked. Perioperative complication rate of both surgery were comparable. Hospital stay was shorter in LS. POD occurred in 20 of 148 patients (13.5%). In univariate analysis, age (77.8 vs. 57.9 years old), length of

hospital stay, history or presence of metabolic disease, type of surgery (open vs. laparoscopic), blood loss, presence of deafness and presence of dementia were significant factors for POD. Gender and operation time were not a significant factors for POD. In multivariate analysis, age ( $P = 0.0012$ ), length of hospital stay ( $P = 0.0094$ ) and type of surgery (open:  $P = 0.0121$ ) were significant factors for POD.

**Conclusion:** Laparoscopic surgery has an advantage of preventing POD of patients with colorectal disease and should be considered even for elderly patients.

**Abstract ID: 0280** Specific Field: **Colon and Rectum**

**Mode of pres.: Free Paper**  
**ISW 2011 Session 50.05**

**Factors affecting the overall survival in patients with colorectal liver metastases: an institutional study**

Y. Seo, H. Hasegawa, Y. Ishii, T. Endo, H. Ochiai, M. Tanabe, S. Kawachi, Y. Kitagawa

Keio University School of Medicine, Tokyo, Japan

**Introduction:** Treatment of metastatic colorectal cancer to the liver is not uniform. We describe the factors affecting the prognosis of patients with colorectal liver metastases.

**Material and Methods:** Between January 2003 and December 2007, 891 colorectal cancer patients undergoing surgery in our institution were retrospectively reviewed, and patients who developed either synchronous or metachronous liver metastases were identified. Patients' demographic and data regarding the characteristics and management of primary tumors and liver metastases were assessed. Survival data were analyzed using Kaplan Meier method to identify affecting prognosis.

**Results:** Median age was 64 years (range; 29–85 years). Median follow-up was 44 months. 69 (83%) patients had synchronous liver metastases. The primary tumor was in the colon (55; 66%) and rectum (28;34%), respectively. The first treatment for liver metastases included resection in 23, ablation in 10, and chemotherapy in 42 patients. Comparing with patients who received chemotherapy, significant improvement of overall survival was seen in those who underwent hepatic resection ( $P = 0.001$ , log rank), but were not seen in those who underwent ablation. Of the 42 patients with unresectable liver metastases who received chemotherapy, 4 (10%) patients underwent resection after downsizing chemotherapy.

**Conclusion:** Systemic chemotherapy could convert 10% of patients with initially unresectable liver metastases to be rescued by liver surgery. This strategy may offer a possibility of long-term survival in unresectable liver metastases, with a use of timely hepatectomies.

**Abstract ID: 0281** Specific Field: **Colon and Rectum**

**Mode of pres.: Free Paper**  
**ISW 2011 Session 50.06**

**Gum chewing accelerates defecation after laparotomy**

T. Kobayashi, T. Masaki, H. Matsuoka, M. Sugiyama, Y. Atomi

Kyorin University Hospital, Tokyo, Japan

**Introduction:** Paralytic ileus after laparotomy is sometimes difficult to manage, and prolongs hospital stay. In the literature, several interventions such as early ambulation, early feeding, and the use of

enterokinetic agents have been attempted. Although several studies advocated gum chewing to reduce postoperative paralytic ileus, conflicting results have also been reported. Furthermore, its physiological mechanisms are not clear. The aims of this study were to examine the effects of gum chewing in a prospective randomized controlled trial, and to elucidate its mechanisms.

**Material and Methods:** Forty-eight patients undergoing open surgery for descending, sigmoid, and recto-sigmoid colon cancer were randomly allocated to either the standard postoperative management (the control group,  $n = 25$ ) or the standard postoperative management plus gum chewing (the gum group,  $n = 23$ ). The patients in the gum group chewed gum three times a day from the first postoperative day (1POD). All patients took radiopaque markers at 1POD, and had X-ray and blood tests (gastrointestinal hormones: gastrin, desacyl-ghrelin, motilin and serotonin) at pre-operation, 1POD, 3POD, 5POD, 7POD and 10POD. The time to the first passage of flatus and defecation were recorded, and colonic transit time (CTT) was calculated.

**Results:** The time to the first passage of flatus and CTT were not different significantly between the two groups. Though the time to the first passage of defecation was not different significantly, it was about 0.5 day shorter in the gum group than in the control group (109 vs. 94 h). Although all gastrointestinal hormone levels were not significantly different, gastrin level was higher in the gum group than in the control group ( $P = 0.23$ ).

**Conclusion:** Gum chewing after open surgery may enhance bowel movement through stimulation of gastrin secretion.

**Abstract ID: 0282** Specific Field: **Colon and Rectum**

**Mode of pres.: Free Paper**  
**ISW 2011 Session 50.07**

**Enhanced recovery after surgery workshop: effect on attitudes of the peri-operative care team**

A. Kahokehr, S. Srinivasa, L. Thompson, M. Soop, A.G. Hill

University of Auckland, Auckland, New Zealand

**Introduction:** Enhanced Recovery After Surgery (ERAS) or "Fast Track" surgery is based on a multidisciplinary focused peri-operative care model with all staff being equally important for successful implementation. Several institutions run an ERAS course but few data are available on their effect on attitudes and perceptions to peri-operative care principles.

**Material and Methods:** A ten item survey was designed for peri-operative care staff attending an annual ERAS workshop. The survey was administered 1 week before and 3 weeks after the workshop.

**Results:** Seventy seven eligible participants were identified. Forty four (57%) responded prior to the course. On repeat administration of the survey three weeks after the course there were 28 (36%) responses. The results of this survey indicated that the majority of peri-operative care staff were already aware of the evidence behind some of the principles applied in colectomy, with a high pre-course level of understanding shown. However the course significantly changed opinion regarding important aspects of care such as routine bowel preparation, routine nil by mouth, ileus reducing interventions and timing of urinary catheter removal to align opinion with evidence.

**Conclusion:** There appears to be a high rate of evidence agreement with some interventions but not others amongst peri-operative staff. Attending a multidisciplinary ERAS workshop seems to align opinion with evidence in important Perioperative care measures.



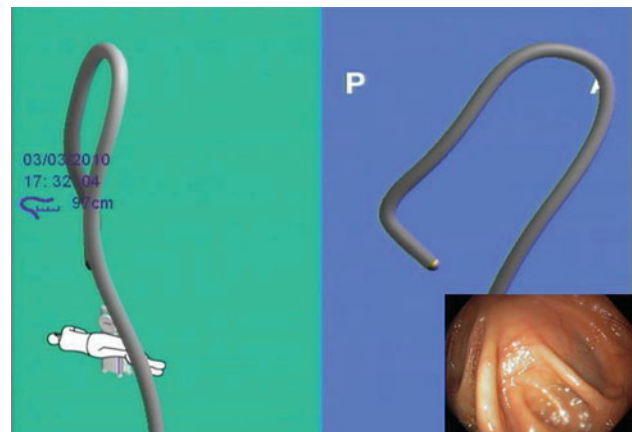
**Abstract ID: 0283** Specific Field: **Colon and Rectum****Mode of pres.: Free Paper**  
**ISW 2011 Session 50.08****Therapeutic outcome of ablation therapy with respect to the new Japanese classification system for colorectal liver metastasis**

K. Amano, S. Ogawa, S. Kameoka

Tokyo Women's Medical University, Tokyo, Japan

**Introduction:** In order to assess the efficacy of ablation therapy, we have analyzed the patients who underwent ablation therapy for the colorectal liver metastasis with respect to the new Japanese classification system for colorectal liver metastasis.**Material and Methods:** We have retrospectively analyzed 27 patients who underwent ablation therapy at our department from year 1999 to 2004. They constitute 35 cases.**Results:** Male-to-female ratio was 14–13.13 cases underwent radio-frequency ablation (RFA), 12 cases underwent microwave ablation, and 10 cases underwent combination therapy of microwave ablation and RFA. 8 cases were treated repeatedly. Recurrences at the site of therapy were found in 29 lesions (54.7%) and 3-year local recurrence free rate at the site of therapy was 40.0%. The mean maximum diameter of the ablated lesion which recurred was 33.2 mm and it was significantly larger than that of non recurrent metastatic lesion (18.1 mm). 18 lesions (64.3%) near the major intrahepatic vessels recurred, and 11 lesions (40.7%) located distal to the major vessels recurred. 3-year local recurrence free-rate of the metastasis in which the diameter is less than 3cm and distant from the major intrahepatic vessel was 71.3%. 3-year cumulative survival rate of the patients underwent ablation therapy was 38.5 and 75.0% for the patients with lesions smaller than 3cm, and without other non-curative factors. The patients were classified into the new Japanese classification system for colorectal liver metastasis, and its implication on prognosis of patients underwent ablation therapy will be discussed.**Conclusion:** The ablation therapy has the ability to inhibit the recurrence at the site of therapy depending on the tumor size and the distance from major hepatic vessels, but systemic outcome should be further established.

complete colonoscopy was performed under local anesthesia. The equipment was fitted with the option allowing three dimensions observation of instrument localization in the bowel. The patients were divided in two groups. Each group consisted of 150 cases matched by gender, age, and BMI. For the purpose of comparison 3D navigation was used in group II only. The authors compared the time of abdominal pressure, pulse rate during the examination and at the time to reach cecum by the instrument.

**Results:** Group I consisted of 87 women and 63 men at the mean age of 54.3 years, mean BMI 27.4, and group II of 89 women and 61 men, mean age 54.4 years and mean BMI 26.6. The average time to reach cecum by the instrument was 206 sec. in group I and 177 s in group II. The duration of abdominal compression made up 34% of the time to reach cecum in group I and 21% in group II. The results shown significantly shorter caecal intubation time by the instrument in group II and significantly lower pain intensity during the examination reported by the patients. No significant differences were found between both groups for the pulse measurements, however pulse curve was flatter in group II.**Conclusion:** 3D navigation during colonoscopy makes the examination easier to perform in a shorter period of time. It makes the examination better tolerated by the patients (Figure).**Figure:** 3D navigation endoscopy**Abstract ID: 0284** Specific Field: **Colon and Rectum****Mode of pres.: Free Paper**  
**ISW 2011 Session 73.01****3D scope guide in screening colonoscopy**

M. Szura, R. Solecki, A. Matyja, K. Bucki

Medicina Diagnostic and Therapeutic Centre, Krakow, Poland

**Introduction:** Colonoscopy performed on wide scale as a part of screening programs helps to detect colorectal cancer. It is performed under local anesthesia which does not eliminate all discomfort and pain related to the examination. Pain occurs mainly during the insertion of the instrument as a result of excessive colon dilation by air. Skillful insertion of the endoscope, is one of the elements contributing to a better tolerance examination by the patient. The aim of the study is evaluation the effect of three-dimensional navigation used in screening colonoscopy performed in the asymptomatic patients.**Material and Methods:** A study group consisted of 300 patients, aged 40–65 years without the symptoms of colon cancer, who underwent screening colonoscopy. The patients were not earlier operated and colonoscopy was performed for the time. In all cases**Abstract ID: 0285** Specific Field: **Colon and Rectum****Mode of pres.: Free Paper**  
**ISW 2011 Session 73.02****Clinical study on colorectal cancer surgery in patients with impaired renal function**

Y. Sawada [1], S. Fujii [1], H. Miyamoto [1], K. Watanabe [1], T. Godai [1], M. Ota [2], C. Kunisaki [1], I. Endo [2]

[1] Yokohama City University Medical Center, Yokohama city, Japan, [2] Department of Gastroenterology, Yokohama City University, Yokohama City, Japan

**Introduction:** As the number of surgical resection for elderly patients are increased, surgery for the patients with impaired renal function emerged as a significant clinical issue. We report a clinical study of colorectal cancer surgery in patients with impaired renal function.**Material and Methods:** 322 patients in the impaired renal function group (group A: CCr < 60 ml/min, patients receiving hemodialysis were excluded) and the remaining 690 patients in the normal renal group (group B: CCr < 60 ml/min) were included in this study between 2006 and 2010. We compare the treatment results in the group A with those of in the group B.

**Results:** (1) Patient characteristics: The significant differences were found in mean age (group A: 74.8, group B: 62.3  $P < 0.001$ ), BMI (group A: 21.3, group B: 23.4  $P = 0.001$ ), and prognostic nutritional index: PNI (group A: 48.8, group B: 51.9  $P < 0.001$ ). However, there were no significant differences in tumor location (colon/rectum) (group A: 173/124, group B: 387/279  $P = 0.967$ ) and stage (I + II/III + IV; group A: 175/117, group B: 405/235  $P = 0.328$ ).

(2) Intraoperative factors: The significant differences were found in operation time (group A: 176 min, group B: 203 min  $P < 0.001$ ), the incidence of D3 lymph node dissection (group A: 51.2%, group B: 62.6%  $P = 0.001$ ) and blood loss (group A: 139 ml, group B: 245 ml  $P < 0.001$ ). There were no significant differences in the incidence of intestinal anastomosis (group A: 88.2%, group B: 89.8%  $P = 0.438$ ).

(3) Postoperative morbidity: The short term morbidity rate was 30.7 and 32.6% in the group A and group B, respectively. The serious morbidity rate (more than Grade 3 of Dindo-Clavien classification) was significantly higher in the group A than in the group B (8.6 vs. 5.2%) ( $P = 0.044$ ). The leakage rate was 5.2% in the group A and 7.0% in the group B ( $P = 0.319$ ). However, the incidence of postoperative systemic complications in the group A were higher than those in the group B (pulmonary complications; 2.4 vs. 0.5%  $P = 0.005$ , cardiovascular complications; 1.1 vs. 0.3%  $P = 0.141$ ).

(4) Risk factors for postoperative morbidity: Blood loss ( $P = 0.021$ ) was risk factor for post operative complications in the group A.

**Conclusion:** The complications in patients with impaired renal function tended to be serious once when it occurred. Therefore, less invasive procedure should be considered and postoperative careful management is required.

**Abstract ID: 0286** Specific Field: **Colon and Rectum**

**Mode of pres.: Free Paper**  
**ISW 2011 Session 73.03**

#### The quality assurance of pelvic autonomic nerve preservation in rectal cancer surgery

T. Masaki, H. Matsuoka, T. Kobayashi, K. Sato, M. Sugiyama, Y. Atomi

Kyorin University, Tokyo, Japan

**Introduction:** In Japan, lateral lymph node dissection (LLND) with pelvic autonomic nerve preservation (PANP) has been advocated since late 1980's in patients with advanced lower rectal cancer. Although the extent of PANP was classified into complete, unilateral and partial, its indication has not been standardized yet. This study was conducted to compare the surgical quality with reference to the extent of PANP.

**Material and Methods:** A randomized controlled trial has been ongoing from 2000 in our institution, which compares oncologic and functional outcomes between TME + LLND + unilateral or partial PANP (Control group) and TME + LLND + complete PANP with intraoperative radiotherapy (IORT group). IORT is given to the preserved nerves. Sixty-four patients were enrolled until the end of October, 2010 (32 cases in each group). Two cases were excluded from the IORT group, and 1 case from the Control group, resulting in 30 cases in the IORT group and 31 cases in the Control group. Surgical and pathological parameters were compared statistically.

**Results:** Complete PANP was done in 27 out of 30 patients in the IORT group, whereas, unilateral or partial PANP was done in 30 out of 31 patients in the Control group ( $P < 0.001$ ), suggesting that the study protocol was strictly maintained. Patients' gender, age, tumor

height, and grade of circumference were well comparable. Pathological parameters such as differentiation, depth of invasion, venous permeation, lymph node metastasis, and lateral node metastasis were also well comparable. Lymphatic permeation was more frequent in the Control group (87 vs. 63%;  $P = 0.04$ ). As for surgical parameters, the average operation time was significantly longer in the IORT group (504 vs. 403 min;  $P < 0.001$ ), because the patient had to be transferred to the Radiology Unit. However, the rate of sphincter preservation, the amount of hemorrhage, blood transfusion, the number of harvested nodes and metastatic nodes (mesorectal and lateral) were not significantly different between the two groups. The incidence of postoperative complications such as anastomotic breakdown, intrapelvic abscess, and small bowel obstruction were also comparable.

**Conclusion:** This study suggested that LLND with complete PANP was technically feasible in patients with advanced lower rectal cancer. Oncologic and functional outcomes are awaited.

**Abstract ID: 0287** Specific Field: **Colon and Rectum**

**Mode of pres.: Free Paper**  
**ISW 2011 Session 73.04**

#### Modified FOLFOX4 as an adjuvant chemotherapy for stage III, IV colorectal cancer

K. Minamimura, A. Umemura, T. Hirata, K. Mafune

Mitsui Memorial Hospital, Tokyo, Japan

**Introduction:** Adding oxaliplatin to LV/5-FU improved 5-year disease free survival (DFS) and 6-year overall survival (OS) in the MOSAIC trial. As a result, adjuvant FOLFOX chemotherapy was approved in Japan for stage III colorectal cancer in 2009. Recently FOLFOX chemotherapy following resection of colorectal cancer metastases also demonstrated to have better outcomes than LV/5-FU. We therefore retrospectively examined the role of adjuvant FOLFOX chemotherapy after resection of stage III, IV, and recurrence of colorectal cancer.

**Material and Methods:** Adjuvant FOLFOX chemotherapy was performed for three month after resection of stage III, IV and recurrent colorectal cancer at Mitsui Memorial Hospital between 2006 and 2010. Modified FOLFOX-4 regimen with 100 mg/body L-OHP was administered every 14 days, for 6 courses. A total of 26 patients, 18 in stage III, 4 in stage IV, and 4 in metachronous metastasis were retrospectively examined. Stage IV group included 2 patients after synchronous hepatectomy and 2 patients after resection of metastases to adjacent peritoneum. Metachronous metastasis group included 2 patients with liver, 1 with lung and 1 with abdominal wall metastases. **Results:** Three-year OS rates in the groups of stage III, IV and metachronous metastasis were 94, 100 and 100%, respectively. Three-year DFS rates in the groups of stage III, IV, metachronous metastasis were 53, 25 and 50%, respectively. Cancer recurrence was observed in 13 patients and occurred within 25 months. There was no significant difference between each group in DFS. Grade 3 peripheral sensory neuropathy was observed in one patient (4%). The incidences of grade 3 neutropenia and gastrointestinal adverse effect were both 19%.

**Conclusion:** Although the MOSAIC trial recommended 12 courses for 6 month of adjuvant FOLFOX chemotherapy after resection of stage III colorectal cancer, our 6 courses of adjuvant FOLFOX4 regimen demonstrated efficacy even for stage IV and feasibility for stage III colorectal cancer. Moreover, this regimen also may have a benefit for patients who underwent resection of stage IV colorectal cancer and metachronous metastases.

**Abstract ID: 0288** Specific Field: **Colon and Rectum**

**Mode of pres.: Free Paper**  
**ISW 2011 Session 73.05**

**Response and perioperative safety after neoadjuvant mFOLFOX with Bevacizumab for synchronous liver metastases from colorectal cancers**

Y. Katayose [1], J. Yamauchi [2], M. Oikawa [2], H. Shimamura [2], K. Nakagawa [1], K. Yamamoto [2], S. Egawa [1], M. Unno [1]

[1] Tohoku Graduate School of Medicine, Department of Surgery, Sendai, Japan, [2] Miyagi-HBPCOG, Sendai, Japan

**Introduction:** Treatment options for colorectal cancer (CRC) patients with synchronous liver metastases are not determined yet. We, Miyagi-HBPCOG, tried a prospective trial of neoadjuvant chemotherapy by mFOLFOX plus Bevacizumab for resectable synchronous liver metastases (BeFORE study). Here, we assessed this trial as the interim analysis, and evaluated the safety and response.

**Material and Methods:** Eligibility criteria included CRC patients with ten or less synchronous liver metastases, which are preoperatively diagnosed as surgically resectable. 20 patients were enrolled in this interim analysis, and they received 8 courses of mFOLFOX6 with bevacizumab; but bevacizumab was omitted at the initial and the final courses, to avoid the AEs at the operations. The primary endpoint was the Response rate.

**Results:** Among the 20 enrolled patients, one patient was excluded from the study because the assumed metastasis was diagnosed to be hemangioma by CT and MRI imaging. Among the 19 patients analyzed, complete response and partial response were achieved in two (10.5%) and eleven (57.9%), respectively (RR: 68.4%); four (10.5%) were stable disease, and two (5.3%) were progressive disease. AEs after operation were the following: Hemoglobin decreased, Sensory neuropathy, Proteinuria, Organ/Space SSI and bile fistula. Grade 3 AEs were Organ/Space SSI and bile fistula of the same patients who had aplastic anemia before enrollment. Liver resections were performed in 16 cases, and R0-resection was achieved in all of the operable cases (R0 rate was 80%). Summary; Over seven cases had a response (CR + PR), then this trail is going to progress. Almost cases showed that tumors have been shrinking though the interval of chemotherapy before operation. No life-threatening adverse event (over Grade 4) in preoperative and perioperative period.

**Conclusion:** Neoadjuvant chemotherapy mFOLFOX6 combined with bevacizumab appears to be effective and well tolerated. This study was continued as scheduled, and the enrollment was completed on Nov. 30th, 2010.

**Abstract ID: 0289** Specific Field: **Colon and Rectum**

**Mode of pres.: Free Paper**  
**ISW 2011 Session 73.06**

**Transanal endoscopic microsurgery combined with endoscopic posterior mesorectum excision in the treatment of patients with t1 rectal cancer: 2 years follow up**

P.J. Walega, J. Kenig, P. Richter, W. Nowak

Jagiellonian University Collegium Medicum III Department of Surgery, Krakow, Poland

**Introduction:** Transanal Endoscopic Microsurgery (TEM), is an alternative to radical surgery in patients with early stages of the rectal

cancer. Endoscopic Posterior Mesorectal Resection (EPMR), is a rectum sparing technique, allowing to excise mesorectum using perineal endoscopic approach and allows a complete staging of the tumor. Aim of the study: To determine clinical and functional outcomes of TEM + EPMR after 2 years follow up.

**Material and Methods:** 8 patients with T1 rectal cancer were operated using TEM + EPMR as a two-stage procedure. The procedure was performed as described by Zerz et al. Patients had a rectal examination, transrectal ultrasonography, anorectal manometry and Fecal Incontinence Severity Index questionnaire performed before the TEM + EPMR procedure, and during follow-up visits: 6, 12 and 24 months after.

**Results:** The primary tumor could always be radically excised using TEM with at least 10 mm radial margin. During EPMR procedure the mean operation time was 93 (range 65–145) min. There was no intraoperative complication apart from one small rectum perforation during EPMR treated with two additional sutures. Postoperatively 1 hematoma formation which resolved without any additional treatment. There was no mortality. The median number of harvested LN was also 7 (range 4–11) with no case of metastases. After a median follow-up of 25 (range 20–42) months, there was no evidence of locoregional recurrence. There were no significant differences in manometry—BAP, SAP, HPZL and in fecal continence control assessed using FISI before, 6, 12 and 24 months after the procedure. 1 patient after EPMR suffered from sexual dysfunction.

**Conclusion:** EPMR in combination with TEM allows for local radicality and an adequate tumor staging in T1 carcinomas of the rectum. TEM + EPMR does not have influence on basic anorectal functions. However, further studies on a larger group with longer follow-up are needed.

**Abstract ID: 0290** Specific Field: **Colon and Rectum**

**Mode of pres.: Free Paper**  
**ISW 2011 Session 73.07**

**Preoperative assessment of vascular anatomy by Multidetector-row CT (MD-CT) for laparoscopic colorectal surgery**

T. Shimamura [1], N. Miyajima [2], H. Hoshino [1], K. Miura [1], H. Katagiri [1], R. Makizumi [1], S. Tukikawa [1], T. Otsubo [1]

[1] St. Marianna University School of Medicine, Kawasaki, Japan, [2] St. Marianna University School of Medicine, Toyoko Hospital, Kawasaki, Japan

**Introduction:** Recently, we have attempted an assessment of vascular anatomy around the colon by multidetector-row CT (MD-CT) angiography before laparoscopic colorectal surgery. We conducted a study to determine the accuracy of the MD-CT angiography especially for the inferior mesenteric artery (IMA) and left colic artery (LCA).

**Material and Methods:** From September 2008 to January 2010, the distribution of IMA was evaluated in 60 patients, who underwent 64-channel MD-CT angiography. The distance from root of the IMA to the branch of left colic artery (LCA) was measured on a workstation.

**Results:** IMA was detected in all patients by MD-CT angiography. The mean distance from the root of IMA to the root of the LCA was 46.73 mm (rang 25.6–71 mm). There were no differences in gender and height.

**Conclusion:** MD-CT angiography sufficiently evaluated the branching anatomy of IMA. This information is useful in safe and secure laparoscopic colorectal surgery.



**Abstract ID: 0291** Specific Field: **Colon and Rectum****Mode of pres.: Free Paper**  
**ISW 2011 Session 73.08****The usefulness of 3-D PET/CT images for hybrid laparoscopic assisted colectomy**

M. Tsubaki

Dokkyo Medical University, Tochigi, Japan

**Introduction:** Laparoscopic Assisted Colectomy has been a standard minimally invasive surgical procedure for colorectal cancer. However, laparoscopic colectomy with radical lymph node dissection for advanced cancer is difficult and stressful for a surgeon to perform.

**Material and Methods:** Purpose: To present Hybrid Laparoscopic Assisted Colectomy navigated by 3-D PET/CT video images. Material and Methods: Since June of 2005, PET/CT examination has been performed to determine the preoperative stage in colorectal cancers. 3-D PET/CT images were reconstructed to make it easy to observe the relationship between the cancer sites, the arteries and veins that feed the cancer, and the umbilicus. A minimal skin incision (6cm) covered by a MULTI-FLAPGATE was made to perform lymph node dissection based on the 3-D PET/CT images. After performing lymph node dissection, one port for a camera was inserted through the MULTI-FLAPGATE, and 2 or 3 more ports were inserted at the appropriate sites for removal of the colon. After resecting the colon, it was pulled out through the minimal skin incision to complete the colectomy with reconstruction.

**Results:** The mean operative time of 22 cases with this procedure was 112.9 min and the average bleeding loss was 37.2 ml.

**Conclusion:** We conclude that this minimally invasive technique was easier and less stressful for performing lymph node dissection for advanced colon cancer. The 3-D PET/CT Images made it easy to observe the relationship between the cancer sites, the arteries and veins that feed the cancer, and the umbilicus.

**Abstract ID: 0292** Specific Field: **Colon and Rectum****Mode of pres.: Free Paper**  
**ISW 2011 Session 73.09****Efficacy of the intraoperative 3D virtual reality navigation in the colorectal cancer with the congenital kidney urinary tract malformation**

R. Kumashiro, Y. Kakeji, Y. Maehara

Department of Surgery and Science, Graduate school of Medical Science, Kyushu University, Fukuoka, Japan

**Introduction:** It is important to distinguish the area to be operated from the area not to be touched in the laparoscopic surgery. We developed a real-time 3D virtual reality navigation system for the purpose of improving safety of the laparoscopic colectomy. Herein, we describe initial clinical experience with intraoperative navigation surgery for colorectal cancer with kidney urinary tract congenital anomaly.

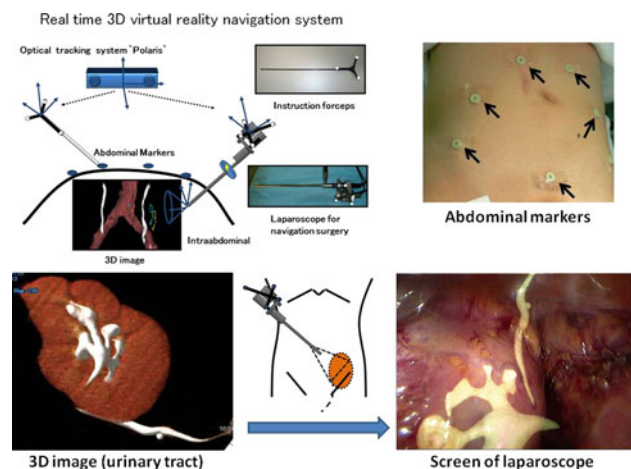
**Material and Methods:** (1) Real time 3D virtual reality navigation system: This system consists of image processing work station (AZE virtual place), laparoscope (Storz), optical tracking system 'Polaris' (Northern Digital Inc.). The Polaris-based coordinate of each skin-affixed multimodality marker on the patient's body was obtained by identifying each marker using a probe that reflects infrared light. After Measuring elevation quantity of the marker, before and after

pneumoperitoneum, we revise marker information which became the basis of the navigation surgery. We superimpose an artery and the ureteral 3D images on a screen of laparoscope. (When precision of the navigation was not enough, we used the instructions forceps and set the bifurcation of the abdominal aorta as an intraabdominal additional registration point, and improve the precision.)

(2) Patient: The patient was a 58 year-old female who had been diagnosed as colorectal cancer. She also had congenital kidney urinary tract malformation; right kidney and the urinary tract suffered a loss, and the left kidney was displaced to pelvis.

**Results:** 3D images are superimpose on a screen of laparoscope, and follow the movement of all visual fields. There was 10 mm positional error in using markers of the abdominal wall only, but was able to obtain high precision of 0.6 mm by assuming bifurcation of the abdominal aorta as an additional registration point.

**Conclusion:** The intraoperative navigation contributed to safety improvement of the laparoscopic surgery especially in the case that accompanied anatomic abnormalities in particular.

**Figure:** Real time 3D virtual reality navigation system**Abstract ID: 0293** Specific Field: **Colon and Rectum****Mode of pres.: Prize Session FP**  
**ISW 2011 Session 105.04****Intraperitoneal local anaesthetic in colon resection: a double-blinded randomised controlled trial**

A. Kahokehr [1], T. Sammour [2], K. Zargar [1], M. Taylor [1], A.G. Hill [2]

[1] University of Auckland, Auckland, New Zealand,

[2] University of Auckland, New Zealand

**Introduction:** Two wounds are created after colectomy. The insult to the intraperitoneal cavity has not been emphasised as a target for interventions. The aim was to investigate the effects of intra-operative instillation and post operative infusion of intraperitoneal local anesthetic (IPLA) on recovery within optimised enhanced recovery after surgery (ERAS) or 'fast-track' care.

**Material and Methods:** Randomised double blinded design. Ethical approval gained and data-safety monitoring board established. The intervention group (IPLA) received instillation of intraperitoneal ropivacaine (75 mg) prior to dissection and postoperative infusion of 0.2% solution at 4 ml/h for 68 h continuously. The placebo group



(NS) received 0.9% saline. All patients were cared for within an established ERAS program. Epidural thoracic infusion was stopped on day two in all patients. Patients were discharged from day 3 onwards. Primary outcomes was the surgical recovery score (SRS), a validated comprehensive measure of post surgical functional recovery. Systemic cytokines response, neuroendocrine parameters of stress, pain measures, opioid use, complications and length of stay also recorded. Patients were followed up for 60 days.

**Results:** Sixty two patients were recruited and randomised. Groups were equivalent at baseline. There were no adverse events. The complication rate was equivalent between groups. IPLA group had better SRS scores for the first 3 days postoperatively. Pain and opioid use were significantly reduced in the IPLA group. Postoperative systemic cytokine and cortisol response was consistently lower in the IPLA group.

**Conclusion:** IPLA after colectomy improves early surgical recovery, blunts post surgical systemic inflammation, reduces pain and opioid use over and above the effect of an epidural infusion.

#### Abstract ID: 0294 Specific Field: Colon and Rectum

Mode of pres.: Prize Session FP  
ISW 2011 Session 105.05

##### Faecal biomarker discovery in colorectal cancer

P.J. McMurrick [1], J. Phung [1], E. Nice [2]

[1] Cabrini Monash Department of Surgery, Cabrini Hospital, Melbourne, Australia, [2] Cabrini Monash University Department of Surgery, Cabrini Hospital, Australia

**Introduction:** Faecal biomarkers may act as an ideal screening tool for colorectal cancer, compared with occult blood. Proteomics potentially provides a rapid means of biomarker discovery in faeces. Current bottlenecks to clinical implementation as a screening tool include identification of proteins associated with CRC, rapidity and cost effectiveness of evaluation, and validation.

**Material and Methods:** Protein separation was achieved by SDS-PAGE on faecal samples, including i) colorectal cancer patients, ii) normal controls and iii) patients post curative resection. Proteomic analysis was primarily performed using a Matrix-Assisted Laser Desorption Ionisation (MALDI) based mass spectrometer. Using one sample, we also compared the proteins identified on MALDI against Electrospray-Ionisation (ESI) based mass spectrometers. MS and MS/MS data was compared against Swiss-Prot protein database using the MASCOT search engine.

**Results:** 170 proteins were identified amongst CRC patients, 187 amongst normal controls and 285 proteins were found in post CRC patients. A total of unique 476 proteins were found across all three patient groups. We further isolated 85 (of 170) proteins which were found only in CRC patients. MALDI identified 65 proteins, whilst 62 proteins were identified using ESI, however, only 5 proteins were common to both instruments.

**Conclusion:** Proteomics offers an accurate means of rapidly identifying potential biomarkers in faecal samples. Proteins identified from this study are entered into a faecal proteomic library—which includes their MS and MS/MS data (their fingerprint). The use of MALDI as a complementary tool to ESI—the more popular instrument—is demonstrated as roughly twice the number of proteins are identified from the one sample. Ultimately, using MS and MS/MS data from our library and an emerging proteomic technology called Mass Reaction Monitoring (MRM), we can target particular proteins of interest in a sample and effectively validate them in a large clinical cohort.

#### Abstract ID: 0295 Specific Field: Colon and Rectum

Mode of pres.: Free Paper  
ISW 2011 Session 113.01

##### Validity of laparoscopic lavage in managing perforated acute diverticulitis: a systematic review

A.H. Yen, G.D. Eslick, M.R. Cox

The Whiteley-Martin Research Centre, The University of Sydney, Sydney, Australia

**Introduction:** Perforated diverticulitis is a common surgical presentation in which there emerges a new trend to manage with laparoscopic lavage in order to defer resection. The evidence suggests that laparoscopic lavage is a safe diagnostic tool, and proponents use it to defer emergency resection so a primary anastomosis could be done electively or avoid resection. Our aim was to systematically review the evidence.

**Material and Methods:** Systematic literature search of Medline, PubMed and Embase was performed using the keywords: perforated diverticulitis and laparoscopic lavage. Non-English speaking studies were included.

**Results:** There were a total of 13 studies with a total of 301 patients with perforated diverticulitis that were managed with laparoscopic lavage. The mean age of patients was 58 (range 49–65), with 54% males. The average span of the studies was 6.25 years. The Hinchey severity scales consisted of—Hinchey 1 (7.6%), Hinchey 2 (24.1%), Hinchey 3 (67.5%) and Hinchey 4 (13.3%). Although the common theme was laparoscopic lavage and drains, there was inconsistency in the number of drains, usage of glue and suture. Mortality was virtually zero and the average morbidity was 15%. The average length of admission was 9.2 days. Only 8% of patients required conversion to laparotomy or resection in the acute admission and there was a 4% readmission rate. Elective resection was performed in 60% patients.

**Conclusion:** There is currently no standardized management using laparoscopic lavage for perforated diverticulitis patients. We believe that even though laparoscopic lavage may be a safer alternative to emergency resection, there is no evidence to support that it defers resection. Further studies are needed to define if laparoscopic lavage has a role. We propose that there should be randomised controlled trial to determine if laparoscopic lavage provides a benefit and how to identify patients suitable for lavage. The study design should also assess the radiological equivalent to the Hinchey classification to improve assessment and selection of patients.

#### Abstract ID: 0296 Specific Field: Colon and Rectum

Mode of pres.: Free Paper  
ISW 2011 Session 113.02

##### Coexisting diverticula with other lesions in the colon

M. Szura, R. Solecki, A. Zajac, J. Kulig

Jagiellonian University, Krakow, Poland

**Introduction:** Colonoscopy is the basic diagnostic tool used to detect colon lesions. Colonic diverticula occur most frequently in the patients over 50 years of age. Typical symptoms are flatulence, constipation, and pain in the left hypogastrium. They are not specific for colonic diverticula and may accompany other colon pathologies as well. The aim of the study is the retrospective analysis of the frequency of coexisting colonic diverticula and other pathologies visualized by colonoscopy.

**Material and Methods:** Over the last 7 years, 22 441 endoscopic examinations of colon were performed on ambulatory basis or during 1-day hospitalization. All patients data, examination findings and the images were archived in the computer data base and used for the retrospective analysis.

**Results:** A study group consisted of 13 200 women and 9 331 men. Mean age of the patients was 55.1 years ( $\pm 12.1$  years, age range 16–95). Colonoscopy visualized colonic diverticula in 5360 patients (23.9%), colon cancer infiltrations in 662 (3%), colon polyps in 6484 (28.9%), in 1814 (8%) intestinal mucosa inflammation, in 8043 (35.8%) hemorrhoids, and in 281 (1.3%) angiomas. In 64.2% of patients, colonic diverticula coexisted with other colon pathologies. Colonic diverticula coexisted with polyps in 35.8% cases, with colon cancer infiltrations in 2.5% cases, with colon mucosa inflammation in 6.2%, hemorrhoids in 33.8% and angiomas in 1.6% cases.

**Conclusion:** Colonic diverticula coexisted with other colon pathologies in over 50% of cases. In 30% of patients with colon polyps the symptoms of colonic diverticula mask the symptoms of other colon pathologies.

**Abstract ID: 0297** Specific Field: **Colon and Rectum**

**Mode of pres.: Free Paper**  
**ISW 2011 Session 113.03**

**Delayed surgery for severe ulcerative colitis is not associated with increased risk of post operative complications**

H. Ochiai [1], H. Hasegawa [1], Y. Ishii [1], Endo Takashi [1], T. Hibi [2], Y. Kitagawa [1]

[1] Keio University School of Medicine, Surgery, Tokyo, Japan, [2] Keio University School of Medicine, Gastroenterology, Tokyo, Japan

**Introduction:** Laparoscopic restorative proctocolectomy (LAP-RP) has been reported to be feasible in patients with ulcerative colitis (UC). Recent advances in the medical treatment for UC include immunosuppressant, however, the impact of immunosuppressant on the surgical outcome of LAP-RP has not been defined. The aim of this study was to evaluate the short-term outcome and the safety of LAP-RP for patients with UC on immunosuppressant.

**Material and Methods:** Our prospectively maintained database identified a consecutive series of 101 patients with UC who underwent LAP-RP ( $n = 40$ ) or hand-assisted laparoscopic (HALS-RP) ( $n = 61$ ) in our institute between 1994 and 2010. The patients were allocated to three groups: group A ( $n = 30$ ); cyclosporine was used as preoperative therapy, group B ( $n = 16$ ); cyclosporine was used within three months preoperatively, and group C ( $n = 55$ ); no immunosuppressant was used within three months preoperatively.

**Results:** There were no significant differences in the age, gender, BMI, number of previous laparotomies among the three groups. Patients associated with infection of cytomegalovirus was significantly more in group A than in the other 2 groups ( $n = 17$ , A: B: C = 10: 2: 5,  $P = 0.025$ ). In group C, the operative time was significantly longer and the blood loss was significantly more than in group A or B respectively. 18 patients developed postoperative complications, including anastomotic leakage in 7, abscess formation in 2, bowel obstruction in 1, ileus in 1 and wound infection in 7. There were no significant differences in the incidence of complications (A: B: C=4 (13.0%): 3 (18.0%): 11(20.0%),  $P = 0.741$ ). There were no differences in the conversions (A: B: C = 0: 0: 4 (7.28%),  $P = 0.1752$ ) or the length of hospital stay (A:B:C = 18:17:17 days,  $P = 0.107$ ) among the three groups.

**Conclusion:** The present study suggested that preoperative immunosuppressant does not affect on the short-term surgical outcome of LAP- or HALS-RP for UC.

**Abstract ID: 0298** Specific Field: **Colon and Rectum**

**Mode of pres.: Free Paper**  
**ISW 2011 Session 113.04**

**Mid-term outcome of restorative proctocolectomy for ulcerative colitis: is mucosectomy necessary?**

H. Hasegawa, Y. Ishii, T. Endo, H. Ochiai, K. Okabayashi, A. Hirata, A. Matsunaga, Y. Kitagawa

Keio University, Tokyo, Japan

**Introduction:** Recent advances in medical therapy have enabled many patients with ulcerative colitis (UC) in remission, however, the number of patients associated with colorectal cancer/dysplasia has also been increasing. The standard procedure for UC is restorative proctocolectomy and pouch anal anastomosis, however, mucosectomy is controversial. The aim of this study was to clarify the mid-term oncolo.

**Material and Methods:** Our database identified 98 patients with UC who underwent restorative proctocolectomy with pouch anal (canal) anastomosis between 1993 and 2010. Pouch anal canal anastomosis without mucosectomy was performed 87 patients using double stapling technique, and pouch anal anastomosis with mucosectomy was performed in 11 patients.

**Results:** Indications for surgery included failed medical therapy in 66 patients and cancer/dysplasia in 32. Laparoscopic surgery was performed in 91 patients, and open procedure in 7. The median age was 43 years, and the median follow-up period was 56 months. In patients with cancer, the tumours were located in the right colon in 6 patients, the left colon in 9, and the rectum in 21 patients, respectively. TNM stage included in stage 0 in 11, stage I in 10, stage II in 6 and stage III in 5 patients. Pouch anal anastomosis with mucosectomy was performed in 11 of the 32 patients associated with cancer/dysplasia. No patients with medical treatment failure developed cancer/dysplasia in the remnant anal canal, whereas 3 of the 21 patients with rectal cancer developed cancer in the anal canal. No patients undergoing mucosectomy developed local or distant recurrence.

**Conclusion:** Pouch anal anastomosis with mucosectomy should be performed in patients associated with rectal cancer.

**Abstract ID: 0299** Specific Field: **Colon and Rectum**

**Mode of pres.: Free Paper**  
**ISW 2011 Session 113.05**

**Initial treatment of primary Crohn's disease**

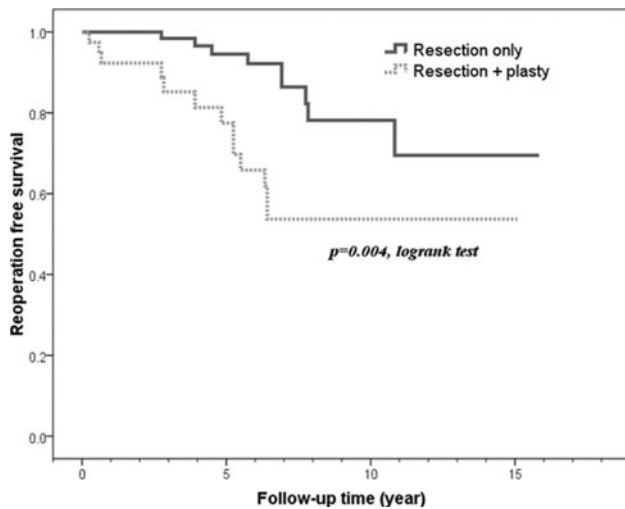
Y. Hoshino, H. Hasegawa, Y. Ishii, T. Endo, H. Ochiai, Y. Kitagawa

Keio University, School of Medicine, Tokyo, Japan

**Introduction:** Crohn's disease (CD) is an inflammatory bowel disease without identical etiology. Surgical treatment for CD accounts for about 80% of CD patients and the postoperative recurrence is one of the major problems. Recently the non-inferiority of the stricture-plasty to the intestinal resection has reported including primary and recurrent CD patients. However, the initial surgical treatment for primary CD is not sufficiently investigated. We aimed to clarify the priority of the initial surgical procedure in the primary CD patients.

**Material and Methods:** We conducted a retrospective study of consecutive patients undergoing surgical treatment for CD between September 1994 and July 2010. We analyzed the factors which affected on the surgical recurrence in CD including age, sex, body mass index, smoking, the Vienna classification, number of lesions, infliximab, steroids and surgical procedure.

**Results:** Our database identified 225 patients (179 male and 46 female). The median follow-up period was 62 months. Of these, 125 patients underwent surgery as primary CD and 100 patients as recurrent CD. In primary CD, 85 patients (68%) underwent resection alone, 39 (31.2%) resection with stricture-plasty and 1 (0.8%) stricture plasty alone. 87 Heineke-Mikulicz stricture-plasty and 10 Finney stricture-plasty were performed in primary CD patients. 23 patients (18.4%) in primary CD developed surgical recurrence. Patients with stricture-plasty had significantly higher recurrence rate than those without ( $P = 0.007$ ). The reoperation-free survival (RFS) in Kaplan–Meier curve was not different according to the number of the lesions ( $P = 0.841$ , log rank test). However, the RFS was significantly shorter in primary CD patients with stricture-plasty than those without (75% quartile RFS 130 vs.80 months, respectively;  $P = 0.004$ , log rank test). The Cox proportional hazard model showed that smoking and stricture-plasty were independent risk factors for surgical recurrence in primary CD (Hazard Ratio (HR) 3.228 [95% confidence interval(CI); 1.342–7.772]  $P = 0.009$ , HR 3.223 [95%CI; 1.378–7.582]  $P = 0.007$ , respectively). **Conclusion:** The intestinal resection may be recommended as the first procedure of choice for primary CD patients.



**Figure:** The impact of surgical treatment on surgical recurrence

**Abstract ID: 0300** Specific Field: **Colon and Rectum**

**Mode of pres.: Free Paper**  
**ISW 2011 Session 113.06**

**DGHAL with recto-anal-repair (RAR): a safe, minimally-invasive method of treatment of advanced hemorrhoidal disease—Clinical results and functional evaluation in 3-year follow-up assessment**

M. Romaniszyn, P.J. Walega, W. Nowak

Jagiellonian University Collegium Medicum III Dept of Surgery, Krakow, Poland

**Introduction:** The aim of this paper is to present clinical results and functional evaluation of Doppler Guided Hemorrhoidal Artery Ligation (DGHAL) combined with Recto-Anal Repair (RAR) procedure in the treatment of IIIrd and IVth grade hemorrhoidal disease (HD), conducted in the 3rd Department of General Surgery, Jagiellonian University. The assessment was based on 3-year follow-up.

**Material and Methods:** 30 patients underwent the DGHAL/RAR procedure in 2006–2007. Patients had a rectal examination, anorectal

manometry and Quality of Life questionnaire performed before the DGHAL/RAR procedure, and during follow-up visits: 3, 12 and 36 months after DGHAL/RAR.

**Results:** Only 25 patients with full 36-month follow-up were included into the final analysis. There were 2 cases of major intraoperative and one of early postoperative bleeding. There was one case of perianal fistula developed after the procedure and one case with occasional soiling 3 months after RAR. There were 6 cases of early (<12 months) and another 2 cases of late (>12 months) recurrence of hemorrhoids or mucosal prolapse, while only 4 of those 8 patients required further treatment. Anal pressure levels 3 months after RAR were significantly lower than before the procedure ( $P < 0.05$ ) and didn't change during 3-year follow-up in patients with no recurrence. In patients with recurrent disease, anal pressures risen again to reach pre-operative level.

**Conclusion:** DGHAL/RAR is a safe method of treatment of IIIrd and IVth grade HD with low risk of complications and low rate of recurrence. The procedure has a significant influence on resting and squeeze anal pressures, and there seems to be a correlation between anal pressures and presence of hemorrhoidal disease.

**Abstract ID: 0301** Specific Field: **Colon and Rectum**

**Mode of pres.: Free Paper**  
**ISW 2011 Session 113.07**

**A novel procedure to repair transanally a rectal prolapse using a surgical stapling device**

H. Nishimori [1], F. Hata [1], S. Ikeda [1], T. Hirama [1], J. Araya [1], T. Yajima [1], K. Tarumi [2], Y. Ishiyama [2]

[1] Sapporo Doto Hospital, Sapporo, Japan, [2] Sapporo Ishiyama Hospital, Sapporo, Japan

**Introduction:** Rectal prolapse is frequently occurred in older, especially female patients. There are many procedures to repair it, however these are time consuming and demanding advanced technique. Moreover, the recurrence rate is high. Here we report a novel, easy, and safe procedure to repair transanally a rectal prolapse using a surgical stapling device.

**Material and Methods:** [Procedure] Previously we reported a procedure to repair a stomal prolapse using a surgical stapling device (Dig Surg 2005;22:306–310). This time, we modified our procedure and applied it to rectal prolapse. Our procedure is very simple as follows. Under general anesthesia, patient was placed in a lithotomy position. The external rectal prolapse was then fully exposed by Allis clamps and examined to exclude any other intra-abdominal organs in the two redundant rectal walls. Firstly, a Proximate Linear Cutter 100 (Ethicon Endo-surgery Co. Ltd.) is introduced at 12 o'clock through the opening of the prolapsed rectal wall and fired. If the instrument is not long enough, the same device can be reloaded. Care is taken to ensure that stapler does not fire dentate line and back wall of the rectum. After firing, a stay suture is placed at the end of the staple line. Secondly, opposite side of prolapsed wall is transected using same TLC100 linear cutter in the same fashion. The prolapsed rectal wall is separated double tissues. Finally the instrument is placed at the basement of double tissues with pulling out continuously by the Alice clamps, however, approximate 1 centimeter from the dentate line should be kept not to prevent severe pain after procedure. Then, the instrument is fired and the prolapsed wall is completely resected. The stapling line is oversewn with absorbable monofilament sutures to ensure hemostasis. After making sure the hemostasis, the procedure is completed.

**Conclusion:** [Conclusions] We have employed this novel technique for 43 cases and follow-up carefully. The most important advantage

of this procedure is that it is performed easily within short time. On the other hand, the cost might be a great problem.

**Abstract ID: 0302** Specific Field: **Colon and Rectum**

**Mode of pres.: Free Paper**  
**ISW 2011 Session 153.01**

**Results of the neoadjuvant radiotherapy and lymphodissection in the treatment of rectal cancer**

E.T. Akbarov [1], S.N. Navruzov [1], S.B. Abdujapparov [1], S.S. Khudayorov [1], B.S. Navruzov [2], H.Dj. Islamov [1]

[1] National Cancer Centre, Tashkent, Uzbekistan, [2] Scientific Centre of Coloproctology, Tashkent, Uzbekistan

**Introduction:** to study the nearest and long-term results of standard and extended lymphodissection of patients with rectal cancer after neoadjuvant radiotherapy.

**Material and Methods:** On 66 patients with rectal cancer were gained the neoadjuvant high fractional hypoxiradiotherapy (13 Gy) and underwent radical surgery with lymphodissection in the amount of D2 and D3. Stage II have diagnosed in 42 patients, a standard lymphodissection have performed in 25 patients. The remaining 17 patients underwent extended lymphodissection. Stage III was diagnosed in 24 patients, including 14 patients underwent a standard, and 10—Extended lymphodissection.

**Results:** The intra-operative complications associated with radiotherapy were not observed in the near postoperative period, marked by purulent-inflammatory complications in 2 patients, which accounted for 3.03%. On stage II, 3-years overall survival was  $78.5 \pm 2.4\%$ , while the implementation of standard lymphodissection led to a 3-years survival rate of  $79.8 \pm 5.2\%$  of patients, and extended lymphodissection— $77.4 \pm 7.2\%$  of patients. In patients after a standard lymphodissection recurrence-free survival was noted in  $65.4 \pm 4.7\%$ , metastasis-free—in  $62.9 \pm 4.4\%$ . Implementation of the extended lymphodissection led to recurrence-free survival at  $63.4 \pm 6.5\%$ , and metastasis-free—at  $65.5 \pm 5.9\%$  of patients. On the stage III 3-year overall survival rate was reached  $56.4 \pm 5.3\%$ . These 5-year survival rate for the standard lymphodissection was  $51.3 \pm 7.6\%$ , and for the expanding lymphodissection was  $59.2 \pm 8.3\%$ . Indicators of recurrence-free survival after a standard lymphodissection was  $49.5 \pm 7.9\%$ , metastasis-free survival rate was  $48.4 \pm 7.6\%$ . Extension of lymphodissection led to recurrence-free survival at  $52.2 \pm 8.6\%$  and the metastasis-free survival at  $51.8 \pm 8.2\%$  of patients.

**Conclusion:** These data suggest the appropriateness of the neoadjuvant hypoxiradiotherapy with various types of lymphodissection in patients with rectal cancer II and stage III disease.

**Abstract ID: 0303** Specific Field: **Colon and Rectum**

**Mode of pres.: Free Paper**  
**ISW 2011 Session 153.02**

**Number of lymph nodes in rectal cancer is correlated with response to preoperative radiotherapy, but is not associated with patient survival**

S. Ishihara, H. Tamuro, H. Yamada, K. Nozawa, K. Matsuda, T. Watanabe

Teikyo University, Tokyo, Japan

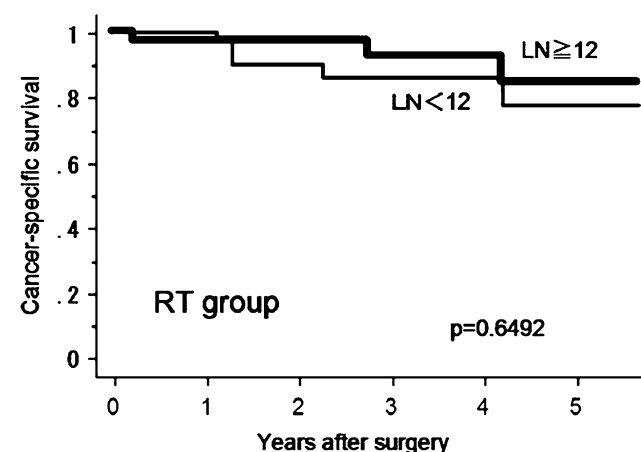
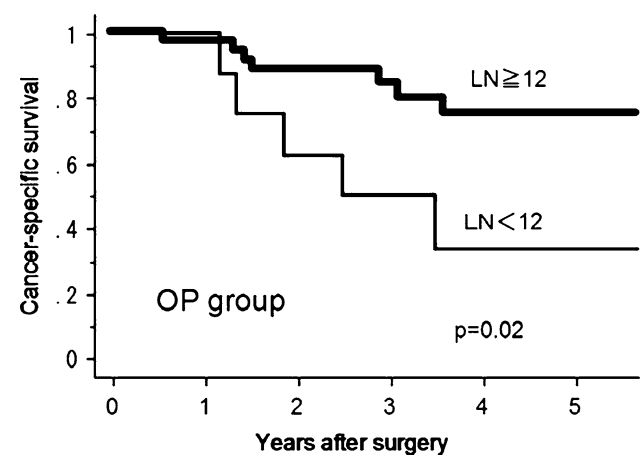
**Introduction:** Increased numbers of lymph nodes retrieved in the resected specimens are reportedly associated with improved survival

of colon cancer patients. In the present study we aimed to clarify the oncological significance of the number of lymph nodes in rectal cancer patients treated with preoperative radiotherapy and total mesorectal excision.

**Material and Methods:** We studied 126 curatively operated patients with clinical T3-T4 and M0 low rectal cancers. The number of lymph nodes and clinicopathological features were compared between the patients treated with surgery alone (OP group,  $n = 45$ ) and those treated with preoperative radiotherapy (50–50.4 Gy in 25–28 fractions with or without tegafur-uracil and leucovorin, RT group,  $n = 81$ ). Factors influencing lymph node count and its prognostic significance were analyzed.

**Results:** The RT group had significantly fewer lymph nodes than the OP group (12.4 vs. 21.1,  $P < 0.0001$ ), although the two groups had similar clinical backgrounds. High histological regression, defined as regression of more than one-third of primary rectal lesions in response to radiotherapy, was significantly correlated with decreased lymph node count in the RT group (high regression; 10.8 vs. low regression; 16.3,  $P = 0.0022$ ). In the OP group, the 5-year cancer-specific survival rate of the patients with 12 or more lymph nodes was significantly better than those with fewer than 12 lymph nodes (75.1 vs. 33.3%, respectively,  $P = 0.02$ ); in the RT group, on the other hand, these survival rates did not differ (84.5 vs. 77.5%, respectively,  $P = 0.6492$ ).

**Conclusion:** The number of lymph nodes retrieved in the resected specimen of rectal cancer was correlated with the response of primary rectal lesions to preoperative radiotherapy, and was not associated with patient survival. The prognostic significance of lymph node count in rectal patients treated with preoperative radiotherapy must be discussed differently from that in colon cancer patients.



**Figure** Cancer-specific survival stratified by the number of lymph nodes (OP and RT groups)



**Abstract ID: 0304** Specific Field: **Colon and Rectum**

**Mode of pres.: Free Paper**  
**ISW 2011 Session 153.03**

**Standardization of laparoscopic total mesorectal excision with preoperative chemoradiation and selective lateral node dissection for lower rectal cancer**

T. Konishi, M. Ueno, Y. Fukunaga, S. Nagayama, Y. Fujimoto, T. Akiyoshi, T. Yamaguchi, T. Muto

Cancer Institute Hospital, Tokyo, Japan

**Introduction:** Preoperative chemoradiation (preCRT) and lateral node dissection (LND) both contribute to decrease local recurrence in advanced lower rectal cancer as compared with total mesorectal excision (TME) alone. However, these procedures are accompanied by increased bleeding and complications. Recently, a laparoscopic approach has become feasible for rectal cancer. Laparoscopic TME with preCRT and LND would be a next promising challenge which could provide oncological benefit with minimal bleeding and complications. The present study aims to verify the feasibility of a laparoscopic approach for this procedure as compared with an open approach.

**Material and Methods:** PreCRT was introduced in 2002 for all patients with T3-4 lower rectal cancer without distant metastasis. Patients with positive pelvic lymph nodes underwent LND. Laparoscopic approach was first introduced in 2005 for this procedure, and the indication was extended with technical standardization. Short-term outcomes were compared between laparoscopic and open procedures during 2002–2010.

**Results:** A total of 138 patients underwent curative resection for T3-4 lower rectal cancer after preCRT, including 80 cases of laparoscopic approach (Group L) and 58 cases of open approach (Group O). Proportion of Group L gradually increased from 31% in 2005–2006 to 93% in 2009–2010. LND was performed in 19 cases of Group L (24%) and 20 cases of Group O (34%), and likewise, the proportion of Group L increased from 10% to 87%. There was no conversion to open surgery in Group L. Twenty-eight cases of Group L (35%) underwent combined resection of the adjacent structures including the autonomic nerves for safe circumferential resection margin (CRM). Consequently, there was no positive CRM, and urinary dysfunction occurred only in a single case. There was no difference in patient backgrounds, proportion of sphincter preservation (70 vs. 72%), duration of operation (320 min. vs. 300 min) and number of retrieved lymph nodes (17 vs. 17). Group L showed decreased bleeding (35 ml vs. 460 ml,  $P < 0.0001$ ), earlier flatus passage (1 day vs. 2 days,  $P < 0.0001$ ) and a trend towards less surgical site infections (21 vs. 34%,  $P = 0.0832$ ).

**Conclusion:** Under technical standardization, laparoscopic TME with preCRT and selective LND can be safely performed for lower rectal cancer.

**Abstract ID: 0305** Specific Field: **Colon and Rectum**

**Mode of pres.: Free Paper**  
**ISW 2011 Session 153.04**

**Metastatic lateral lymphadenectomy for lower rectal cancer patients**

S. Yamaguchi [1], T. Ishii [1], J. Tashiro [1], T. Sato [1], Y. Miyamoto [1], M. Miyazawa [1], N. Shinozuka [2]

[1] Saitama Medical University International Medical Center, Hidaka, Japan, [2] Saitama Medical University, Moroyama, Japan

**Introduction:** Lateral lymphadenectomy for rectal cancer is still controversial. In this study, patients who underwent metastatic lateral lymphadenectomy were assessed.

**Material and Methods:** Since 2007 to 2010, 118 extraperitoneal rectal cancer patients received curative resection and positive lateral nodes were resected in 14 patients (11.9%). There were twelve male and 2 female and mean age was 65.1. Frequencies of lateral node according to cancer depth of invasion were; T2 3.1% (1/32), T3 21.8% (12/55), T4 20% (1/5).

**Results:** The internal iliac vessels were often removed for combined and margin-negative resection. Operating time and blood loss of each procedures were; LAR ( $n = 3$ ) 388 min., 814 g, ISR ( $n = 5$ ) 428 min., 719 g, APR ( $n = 4$ ) 356 min., 573 g, and laparoscopic ISR ( $n = 2$ ) 341 min, 126 g, respectively. Mean overall positive node number was 8.9 (1-29), and 2.6 (1-11) of lateral node. Actual positive lateral node number was 1: 7 patients, 2: 2 pts, 3: 1 pt, 5: 2 pts, 11: 1 pt. Three of 14 (21%) patients were positive in only lateral node. Obturator node was most common part of metastasis. All patients except one were diagnosed preoperatively as lateral node positive by CT and/or MRI. Median postoperative hospital stay was 13 days, and ileus was observed in 3 and wound infection in 1. Seven patients recurred and one of them died in 23 months-mean follow-up. There were 3 local recurrences, 3 liver and 4 lung metastases.

**Conclusion:** Metastatic lateral lymphadenectomy is technically challenging, however there were not a few long survivor. This treatment should be standard for resectable lateral node positive rectal cancer patients in curative intent.

**Abstract ID: 0306** Specific Field: **Colon and Rectum**

**Mode of pres.: Free Paper**  
**ISW 2011 Session 153.05**

**Radical resection after chemoradiation therapy for local recurrence of rectal cancer (LRR)**

M. Ikeda, M. Sekimoto, J. Nishimura, I. Takemasa, T. Mizushima, H. Yamamoto, Y. Doki, M. Mori

Graduate School of Medicine, Osaka University, Suita, Japan

**Introduction:** Surgical treatment for LRR is challenging. Severe scarring tissues due to previous operation and concomitant adjacent organs such as, bladder and sacral bone resection require highly skilled surgical team. Even with experienced surgical team, local recurrence rate is very high. We have employed preoperative chemoradiation therapy (CRT) for better tumor control since 2004. The aim of this study was to evaluate the efficacy of preoperative CRT and radical surgery for the treatment of LRR.

**Material and Methods:** Forty-eight patients (pts) who underwent surgical intervention for LRR with curative intent were evaluated. Twenty-three pts (CRT group) had preoperative CRT consisted of CPT-11, UFT, and LV. Radiation therapy was given to the pelvis with daily fractions of 2.0Gy 5 days a week for 5 consecutive weeks. Twenty-five patients were treated surgery alone (Surgery group).

**Results:** Pts background: CRT group: 18 males, 5 females, median age 61, duration between primary operation and diagnosis 695 days, median tumor diameter 40 mm, Surgery group: 15 males, 10 females, median age 58, duration 583 days, tumor diameter 44 mm. CRT group had higher proportion of pts with low anterior resection for primary tumor (15 pts vs. 8pts). In the CRT group, 16 pts (70%) had concomitant sacral bone resection, and 11pts (44%) in the Surgery group. Operative time and blood loss were comparable between both groups. R0 operation was achieved in 22 pts (96%) in the CRT group

and 20 pts (80%) in the Surgery group. Mortality rate (CRT vs. Surgery group): (0 vs. 4%), and incidence of pelvic sepsis and abscess: (43 vs. 32%), respectively. Three-year overall survival, relapse free survival, local re-recurrence free survival rates were (CRT vs. Surgery group) 70 vs. 65%, 44 vs. 34%, 68 vs. 40% (Logrank test,  $P = 0.17$ ), respectively. Incidence of local re-recurrence rate and distant metastasis (CRT vs. Surgery group) were 17 vs. 53%, and 48 vs. 48%, respectively.

**Conclusion:** Radical resection after CRT for LRRC is feasible, and may provide good impact on local control. Another treatment strategy for distant metastasis is mandatory.

## Abstract ID: 0307 Specific Field: Colon and Rectum

**Mode of pres.: Free Paper**  
**ISW 2011 Session 153.06**

### Laparoscopic bowel lifting technique: a novel and standardized technique for laparoscopic low anterior resection

K. Watanabe [1], S. Fujii [1], I. Endo [2]

[1] Yokohama City University Medical Center, Gastroenterological Center, yokohama, Japan, [2] Departments of Gastro-enterological Surgery, Yokohama City University Graduate School of Medicine, yokohama, Japan

**Introduction:** Laparoscopic low anterior resection (Lap-LAR) for rectal cancer has become increasingly popular. Additionally, surgeons have tried to decrease the number of ports in order to achieve better cosmetics and less postoperative pain. However, reducing the number of ports may have an increased risk for complications. Herein, we introduce a technique, "Laparoscopic Bowel Lifting (LBL) Technique", which helps to reduce ports without additional trocars.

**Material and Methods:** A series of 140 rectal cancer patients who underwent curative Lap-LAR were enrolled between 1993 and 2009. Patients were divided into two groups: the LBL group ( $n = 94$ ) and the non-LBL group ( $n = 46$ ). A 5-trocar technique was employed in the non-LBL group. On the contrary, 3 or 4 trocars were used in the LBL group. For all patients, patient and tumor characteristics, perioperative findings and long-term results were extracted from the case records retrospectively. **SURGICAL TECHNIQUE:** The mesocolon is pierced near the line of transaction with the dissecting forceps. A 1-0 Vicryl suture is introduced into the abdominal cavity with a grasping needle and passed through the mesocolon. The colon is retracted using the suture and fixed to the abdominal wall by forceps. Then, traction is placed on the main nutrient artery. Mobilization of the rectum is performed after moving the traction to the cranial side by using a grasping needle. Since the rectal tube was pulled toward the cranial side, it is possible to identify the mesorectum with a good visual field.

**Results:** The median follow-up time in the LBL and the non-LBL group were  $36.4 \pm 27.3$  and  $25.8 \pm 25.8$  months, respectively. Number of trocars of the LBL group (3.6 trocars) was significantly reduced than that of the non-LBL group (5.0) ( $P < 0.01$ ). There was no case in which 5 trocars were used in the LBL group. There were no significant difference in patients characteristics, perioperative findings and conversion rate between two groups, and no operative complications were found by this technique. Also, there was no significant difference in the number of dissected lymph nodes between two groups. Relapse-free survival and overall survival did not differ between two groups.

**Conclusion:** LBL technique is feasible for performing Lap-LAR. This method reduces the number of ports and might help to introduce a single-incisional operation.

## Abstract ID: 0308 Specific Field: Colon and Rectum

**Mode of pres.: Free Paper**  
**ISW 2011 Session 153.07**

### Results of laparoscopic intersphincter resection for very low rectal cancer

S. Yamamoto, T. Akasu, S. Fujita, R. Inada, Y. Moriya

National Cancer Center Hospital, Tokyo, Japan

**Introduction:** For patients with rectal adenocarcinoma located within 4–5 cm from the anal verge, intersphincteric resection (ISR) was developed to avoid permanent colostomy. However, controversy still persists regarding the appropriateness of laparoscopic surgery (LS) for patients with rectal cancer because of the concerns over the safety of the procedure, and of the uncertainty of the long-term outcome. Laparoscopic rectal excision involves many procedural complexities and technical difficulties, and LS in patients with rectal cancer is still technically demanding. The aim of the present study was to evaluate the short-term surgical outcomes and mid-term oncologic outcomes of laparoscopic intersphincteric resection (Lap-ISR) for lower rectal carcinoma.

**Material and Methods:** A review was performed of a prospective registry of 26 patients who underwent curative Lap-ISR for lower rectal cancer between July 2002 and September 2010. A per anum handsewn coloanal anastomosis was performed. Patient demographics and outcomes were recorded prospectively.

**Results:** All operations were completed laparoscopically in this series. The median follow-up was 34 months. The median operative time was 369 min, and the median blood loss was 142 ml. Liquid and solid foods were started on median postoperative day 1 and 2, respectively. The median postoperative hospital stay was 8 days. A total of 9 postoperative complications occurred in 9 patients (35%), including minor anastomotic leakage in 1 and bowel obstruction in 2. Reoperation was not required in the present series. All the patients underwent ileostomy closure. One patient with pT3N2M0 developed lymph nodes and bone metastasis.

**Conclusion:** Lap-ISR for lower rectal carcinoma is technically feasible and oncologically appropriate for selected patients with lower rectal carcinoma. It remains unclear, however, whether Lap-ISR is equivalent to conventional open surgery in terms of long-term oncological outcome, and this can only be answered through the accumulation of more patients prospectively, considering the fact that the RCT with a sufficient number of patients comparing open and laparoscopic ISR is lacking.

## Abstract ID: 0309 Specific Field: Colon and Rectum

**Mode of pres.: Free Paper**  
**ISW 2011 Session 153.08**

### Handling ISR complications and time-dependent changes in post-surgical QOL at this hospital

A. Toyoshima, T. Endo, R. Akai

Japanese Red Cross Medical Center, Tokyo, Japan

**Introduction:** This hospital adopted Intersphincteric Resection (ISR) for lower rectum and anal canal malignancy in 2005. The hospital has handled 50 such cases as of June 2010. This report outlines the results of an examination of complications, handling, and post-surgical QOL in cases of ISR.

**Material and Methods:** Forty-six cases were of rectum cancer, three of GIST, and one of vagina cancer. Thirty-six patients were male and 14 female. Average patient age was 60 (26–86). In terms of the extent of rectum cancer, 15 cases (33%) were stage I, nine (20%) were stage II, 16 (34%) were stage III, and six (13%, all with liver metastasis) were stage IV. As for adjuvant therapy, preoperative irradiation was conducted in eight cases and preoperative chemotherapy in one case. Hepatectomy was performed in three cases of liver metastasis.

**Results:** Recovery: Thirty-four cases (68%) demonstrated recurrence-free survival. With regard to cases of recurrence to stage III, two cases demonstrated liver metastasis, three pelvic metastasis, two lymph node metastasis and one lung metastasis. Postoperative Complications and Countermeasures: Among the four cases of ruptured sutures, fistula closure was accomplished with Aron Alpha in two cases. Mucosectomy was performed in the six cases of mucosal prolapse. The five cases of anastomotic stenosis were ameliorated with finger bougie. Two cases of erectile dysfunction and one of ileus were also observed. Preoperative irradiation was conducted in the three cases (one case of ruptured sutures, one of sphincter incompetence, and one of intrapelvic colonic stenosis) in which stoma closure did not occur after six months or more. Postoperative Time-dependent Changes in QOL: Almost all patients demonstrated satisfaction with ISR and displayed gradual improvement in terms of soiling and limitations in everyday life one month, three months, six months and one year after closure with defecation controlled through measures including ob- stipants and enemas.

**Conclusion:** (1) While performing ISR, it is important to not only effectively deal with complications but also develop surgical methods that do not lead to complications. (2) Although the tumor reduction effects of preoperative irradiation are clear, possible exacerbation of postoperative complications must also be considered. (3) Defecation control-based outpatient follow-up is essential in post-operative QOL improvement.

#### Abstract ID: 0310 Specific Field: Colon and Rectum

Mode of pres.: Free Paper  
ISW 2011 Session 153.09

#### Postoperative bowel function following ultra-low anterior resection for low rectal cancer: comparison of J-pouch, coloplasty and straight reconstruction

H. Matsuoka

Kyorin University, Tokyo, Japan

**Introduction:** To clarify the optimal reconstruction following ultra-low anterior resection for rectal cancer.

**Material and Methods:** Period of the study was from July 1997 to December 2007. Eighty-five patients with rectal cancer were evaluated by physiologic investigation before and after stoma closure (6–12 mo: mean 9 mo.). Patients were questioned in terms of frequency, indiscrimination, soiling and urgency. Wexner's score was calculated for objective indicator for incontinence. Anorectal manometry was performed by Andorfer (StarMedical Inc.) Water perfusion type catheter was used by station pull-through method.

**Results:** Patient's age, gender, tumor stage, and postoperative complications showed no significant difference among the groups. In terms of bowel function such as frequency of bowel movement (FBM), indiscrimination between gas and stool, Wexner's score, there

was no significant difference before the operation. After the operation, FBM increased significantly from 1 to 5 per day in J-pouch and coloplasty groups. Straight anastomosis group showed significant increase up to 8 times per day of FBM, being significantly greater than those in the other groups. In terms of physiologic investigation by anorectal manometry, resting and squeezing anal canal pressures showed no significant differences before and after the operation. Furthermore, there were no significant differences among the groups postoperatively. Regarding rectal capacity, there was no significant difference before and after the operation. Although J-pouch (162 ml) and coloplasty groups (135 ml) showed no volumetric difference, straight reconstruction group (57 ml) showed significantly smaller volume.

**Conclusion:** Straight reconstruction was inferior to other modalities from functional aspects. Pouch operation such as J-pouch or coloplasty is recommended for ultra-low anterior resection for rectal cancer.

#### Abstract ID: 0311 Specific Field: Colon and Rectum

Mode of pres.: Free Paper  
ISW 2011 Session 153.10

#### Long-term functional results of colonic J-pouch reconstruction after low anterior resection for rectal cancer: a 5-year follow-up

J. Hida, T. Yoshifuji, F. Sugiura, K. Daito, K. Ueda, E. Ishimaru, T. Tokoro, K. Okuno

Kinki University School of Medicine, Osaka, Japan

**Introduction:** Few reports on the long-term functional outcome of colonic J-pouch reconstruction have been published, and data comparing J-pouch and straight reconstruction are contradictory. This prospective study compares the functional outcome of colonic J-pouch and straight anastomosis five years after low anterior resection for rectal cancer.

**Material and Methods:** Functional outcome was compared in 46 patients with J-pouch reconstruction (J-group) and 48 patients with straight anastomosis (S-group). Clinical status was evaluated with a 17-item questionnaire inquiring about different aspects of bowel function. Reservoir function was evaluated by manovolumetry. The Fisher's exact test and Wilcoxon's rank-sum test were used to compare categoric and quantitative data, respectively.

**Results:** Among patients with an ultralow anastomosis (4 cm from the anal verge), the number of bowel movements during the day (5, 4.3 vs. 29.2%;  $P = 0.028$ ) and at night (>1/week, 4.3 vs. 33.3%;  $P = 0.013$ ) and urgency (4.3 vs. 33.3%;  $P = 0.013$ ) and soiling (21.7 vs. 50.0%;  $P = 0.043$ ) were less in the J-group than in the S-group. Among patients with a low anastomosis (5 to 8 cm from the verge), patients in the J-group had fewer bowel movements at night (>1/week, 0 vs. 20.8%;  $P = 0.028$ ) and less urgency (0 vs. 20.8%;  $P = 0.028$ ). Reservoir function was better in the J-group than in the S-group in both the ultralow (maximum tolerable volume (mean), 101.7 vs. 76.3 ml;  $P = 0.004$ ; threshold volume (mean), 46.5 vs. 30.4 ml;  $P < 0.001$ ; compliance (mean), 4.9 vs. 2.5 ml/cm H<sub>2</sub>O;  $P < 0.001$ ) and low-anastomosis (maximum tolerable volume, 120.4 vs. 97.9 ml;  $P < 0.001$ ; threshold volume, 58.3 vs. 40.8 ml;  $P < 0.001$ ; compliance, 5.2 vs. 3.1 ml/cm H<sub>2</sub>O;  $P < 0.001$ ) groups.

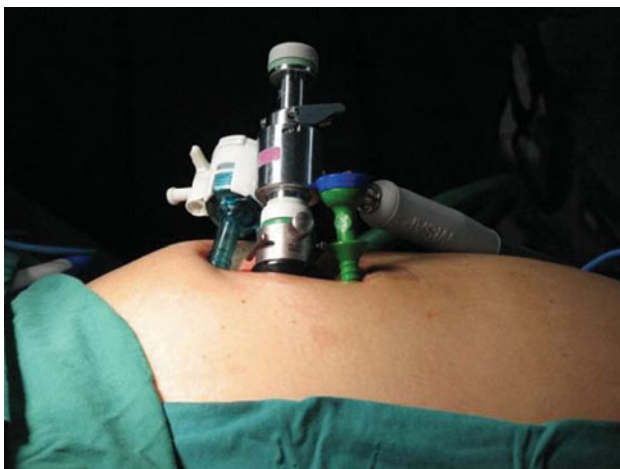**Conclusion:** J-pouch reconstruction increased reservoir function and provided better functional outcome than straight anastomosis, even five years after surgery, especially in patients whose anastomosis is less than 4 cm from the anal verge.

Abstract ID: 0312 Specific Field: Colon and Rectum

Mode of pres.: Free Paper  
ISW 2011 Session 183.01**Single incision laparoscopic colectomy without special curved instruments: an early experiences from Thailand**

P. Wathanaoran, A. Trakarnsanga, V.I. Chinswangwatanakul, A. Methasate, C. Phalanusitthepa, T. Parakonthun, T. Akaraviputh

Department of Surgery, Faculty of Medicine Siriraj Hospital, Bangkok, Thailand

**Introduction:** Single incision laparoscopic colectomy (SILC) has been developed recently using various types of special curved instruments with the benefits of reducing the number of incision and better cosmetic outcome. This study presents early results of the patients underwent SILC using standard instruments.**Material and Methods:** A retrospective analysis of the patient who underwent SILC at Minimally Invasive Surgery Unit, the Department of Surgery, Faculty of Medicine Siriraj hospital between May and December 2010 was performed. Patient's demographic data, perioperative outcomes, early postoperative complications and pathological data were recorded.**Results:** There were 14 patients underwent SILC without need special curved instruments. The median age of the patients was 60.3 years (range = 23–90). The operations were right hemicolectomy ( $n = 12$ ), left hemicolectomy ( $n = 1$ ), sigmoidectomy ( $n = 9$ ), anterior resection ( $n = 1$ ), and total colectomy ( $n = 1$ ). The technique for trocars insertion was multifascial incision ( $n = 11$ ) (Fig. 1) or GelPOINT ( $n = 3$ ). The operative time was 155 min (range = 90–280) and the blood loss was 32.1 ml (range = 10–100). No conversion was required. Anastomotic technique was created using stapler ( $n = 9$ ) or hand sewn ( $n = 5$ ). The pathological result revealed colorectal cancer ( $n = 12$ ), neoplastic polyp ( $n = 1$ ) and FAP ( $n = 1$ ). The median number of lymph nodes examined was 19.3 nodes (range = 3–34). The length of hospital stay was 9 days (range = 5–20). There was no perioperative mortality.**Conclusion:** SILC using standard instruments is a feasible and safe procedure. This technique may be an alternative to conventional laparoscopic colectomy with shorter hospital stay, quicker recovery period and comparable oncologic outcomes.**Fig. 1** The multi-fascial incision using for trocars insertion through a single incision

Abstract ID: 0313 Specific Field: Colon and Rectum

Mode of pres.: Free Paper  
ISW 2011 Session 183.02**Comparing single port laparoscopy right hemicolectomy to conventional laparoscopic colectomy**

S. Al-Sabah [1], L.S. Feldman [1], M. Wongyingsinn [1], P. Charlebois [1], B. Stein [1], F. Carli [1], G.M. Fried [1], A.S. Liberman [2]

[1] McGill University Health Center, Montreal, Canada, [2] McGill University, Canada

**Introduction:** The aim of this study is to describe our initial experience with single-port laparoscopic right hemicolectomy (SPLC) and to make comparisons with our current practice of conventional laparoscopic colectomy.**Material and Methods:** Data from 15 consecutive patients undergoing SPLC were analyzed and compared with case-matched conventional laparoscopic right hemicolectomies. Demographic, operative outcomes, and morbidity were included and analyzed. Data are presented as median and range. Comparisons between the two groups were made using either a two-tailed Student's *t* test or the Mann-Whitney U test. All statistical tests were two tailed at the significant level of 0.05.**Results:** SPLC and conventional laparoscopic groups were similar with regard to age, gender, BMI, ASA, anesthesia, pathology and location of pathology. Intra-operative outcomes and pathology see table. Post-operatively there was no difference between groups in time to pass gas, pain scores or hospital stay. Three patients developed intra-abdominal abscesses in the SPLC group; there were no deaths in either group. 47% of the operations were performed for malignancy in both groups.**Conclusion:** SPLC is feasible, has a short learning curve, and appears to have results similar to conventional right colectomy in our initial comparisons. Despite experience with conventional right colectomy and using the same approach to resection and anastomosis, there did not to be early advantages for SPLC. However, nontraditional

Intraoperative outcomes and pathology. Data are presented as median [interquartile range]

*		SPLC (N=15)	Laparoscopy P (N=15)	P value
Intraoperative	Incision/ extraction length (cm)	4 [3–4.5]	7 [7–7.5]	<0.001
	Operating time (min)	121	[115–142]	150
	[125–170]	0.034		
	Estimated blood loss (ml)	100	150	0.017
		[50–200]	[100–300]	
	Fentanyl consumption (mcg)	200	[200–250]	250
	[225–250]	0.187		
	Conversion (%)	1 (7%)	1 (7%)	1.000
Pathology	LN harvest	16 [12–29]	18 [13–31]	0.712



outcome such as body image and physical recovery may be more relevant to use as outcomes. Ongoing development in instrumentation may help to further shorten operative time and minimize complications, and may make this an equivalent or preferred method for minimally invasive colorectal surgery. Prospective randomized controlled trials should be conducted to further compare the safety and efficacy of this approach.

**Abstract ID: 0314** Specific Field: **Colon and Rectum**

**Mode of pres.: Free Paper**  
**ISW 2011 Session 183.03**

**Single incision laparoscopic surgery through the umbilicus for colorectal cancer**

I. Takemasa, M. Sekimoto, M. Mori

Graduate School of Medicine, Osaka University, Osaka, Japan

**Introduction:** Single incision laparoscopic surgery through the umbilicus is an emerging concept that could provide lesser postoperative pain and offer excellent cosmetic result. The authors reported an index case of curatively intended resection of sigmoid colon cancer with this procedure in 2009. It should be careful for both safe and radical treatment to indicate for the malignant disease, however, there were few reports of its feasibility with large samples.

**Material and Methods:** We have performed this procedure for 81 colorectal cancers since June 2009 that consist 32 right-sided colon cancers (R group) and 49 left-sided colon or rectal cancers (L group). Cases with clinical stage 0–II were indicated with exception for the case with lower rectal cancer, invasion to other organs or ileus. The entire laparoscopic procedures were performed using usual laparoscopic instruments only through the umbilical incision without any additional ports. Double stapling technique was employed for the anastomosis in L group and extracorporeal functional end to end anastomosis was employed in R group.

**Results:** The procedures were performed successfully except for the five following cases. Four rectal cancers needed an additional port because of proper transection of the rectum and one right sided-colon cancer needed small incision of open surgery because of bleeding. There were no other intraoperative complications and only two cases with ileus were observed postoperatively. The median operative time and bleeding amount of L and R group were 170 min, 50 g and 180 min 30 g, respectively. The median harvested lymph nodes and length of resected specimen of L and R group were 21, 22 cm and 19, 20cm, respectively. The scars within the umbilicus were almost invisible three months later, and almost of all patients are very satisfied with their excellent aesthetics.

**Conclusion:** Single incision laparoscopic surgery through the umbilicus for colorectal cancer can provide excellent cosmetic results with similar safety and oncological clearance compared with usual laparoscopic procedures. This procedure is feasible and may be promising in the future.

**Abstract ID: 0315** Specific Field: **Colon and Rectum**

**Mode of pres.: Free Paper**  
**ISW 2011 Session 183.04**

**Prospective randomized trial of hybrid notes colectomy versus conventional laparoscopic colectomy for left-sided colonic tumors**

Y.S. Cheung [1], T.Y. Chan [2], C.C. Chung [1], K.W. Li [1]

[1] Pamela Youde Nethersole Eastern Hospital, Hong Kong, China, People's Republic, [2] Pamela Youde Nethersole Eastern Hospital, China, People's Republic

**Introduction:** For the treatment of left-sided colonic tumor, the best treatment is surgery as it offers the only means of cure and prolonged survival. In performing conventional laparoscopic colectomy, specimen retrieval necessitates a mini-laparotomy which often is the cause and evil of postoperative pain, wound infection as well as other pain related complications. We have described a new technique of laparoscopic colectomy without abdominal incision (hybrid NOTES colectomy), where total laparoscopic transection and intra-corporeal anastomosis was performed as usual but the specimen was delivered through the anus via the use of the Transanal Endoscopic Operations (TEO) device set-up without the mini-laparotomy wound. In order to compare the short-term benefits in terms of wound pain and wound-related complications, a randomized controlled trial was undertaken to evaluate and compare the conventional laparoscopic colectomy with this hybrid technique.

**Material and Methods:** Patient and Methods: Patients diagnosed to have left-sided colonic tumor from splenic flexure to upper rectum were recruited and randomized into two groups: (1) conventional laparoscopic colectomy, and (2) hybrid NOTES colectomy. All operations were carried out by the colorectal team specialists. Operative data and complications were recorded; all patients were followed up using a structured proforma. An independent assessor was assigned to obtain postoperative pain scores.

**Results:** **Results:** From June, 2009 to December, 2010, we have recruited 50 patients with the randomization according to the computer generated number. No significant difference was observed between the two groups in operative time, blood loss and hospital stays. Patients in the hybrid colectomy group experienced significantly less pain and no wound infection.

**Conclusion:** Our initial experience indicates this hybrid approach is safe and feasible for selected patients with left-sided colonic tumors. Complications related to mini-laparotomy can be completely abolished.

**Abstract ID: 0316** Specific Field: **Colon and Rectum**

**Mode of pres.: Free Paper**  
**ISW 2011 Session 183.05**

**Effects of obesity in laparoscopic surgery for colorectal cancer**

Y. Miyamoto [1], H. Baba [2], S. Yamaguchi [1]

[1] Department of Gastrointestinal Surgery, Saitama Medical University International Medical Center, Saitama, Japan,

[2] Department of Gastroenterological Surgery, Graduate School of Medical Sciences, Kumamoto University, Kumamoto, Japan

**Introduction:** Although obesity is associated with various health risks and is considered as a risk factor for postoperative morbidity after abdominal surgery, the effect of obesity on the outcomes of laparoscopic colorectal surgery is unclear. The aim of this study was to evaluate the feasibility and safety of laparoscopic surgery for cancer in the obese patients and to assess the impact of body mass index (BMI)-defined obesity on short term outcomes. The best combination of the sensitivity and specificity for detecting subjects with multiple risk factors for metabolic disorders was a BMI of 25 kg/m<sup>2</sup> for the Japanese.

**Material and Methods:** A retrospective analysis of patients with colorectal cancer treated at Saitama Medical University International Medical Center (Japan) between April, 2007 and October, 2010 was performed. Surgical outcomes, including open conversion, operation time, postoperative complications, counted blood loss, and

postoperative hospital stay were compared in Non-obese, Obese patients. Outcomes were analyzed according to BMI: obese (BMI >25) and non-obese (BMI <25). To compare groups, Welch's ttest was applied to continuous data and the chi-square tests was applied to categorical data. A P value of less than 0.05 was considered significant.

**Results:** 561 patients were identified. Of the 421 (75%), and 140 (25%), were classified as Non-obese and Obese group, respectively. The obese patients were significantly more male patients (72.1 vs. 52.0%;  $P = 0.002$ ), had higher incidence of left colon (49.3 vs. 36.8%;  $P = 0.03$ ), and had systematic co-morbidity ( $P = 0.001$ ). Clinico-pathologic characteristics were similar among both groups. Operative time was significantly longer in obese than non-obese, respectively (220 vs. 206 min;  $P = 0.03$ ). Blood loss, conversion rate, number of harvested lymph node, and length of postoperative hospital stay was similar among both groups. There was no difference in the overall incidence of postoperative complications when comparing obese with non-obese (24.3 vs. 18.3;  $P = 0.12$ ), however surgical site infections were more common in obese patients (12.1 vs. 5.1;  $P = 0.005$ ). Obesity was not significant independent risk factor of postoperative complication (odds ratio 1.46,  $P = 0.14$ ).

**Conclusion:** Laparoscopic resection for colorectal cancer in obese patients is feasible and safe in obese patient, offering all the benefits of a minimally invasive approach.

#### Abstract ID: 0317 Specific Field: Colon and Rectum

**Mode of pres.: Free Paper**  
**ISW 2011 Session 183.06**

#### Laparoscopic resection of colorectal cancer: matched comparison in younger and elderly patients

V. Fiscon, G. Portale, F. Frigo, G. Migliorini

General Surgery, Cittadella, Italy

**Introduction:** Several studies have addressed the issue of the feasibility of laparoscopic colorectal surgery (LCR) in elderly patients, usually by choosing an arbitrary 'cutoff' age limit, retrospectively evaluating the outcomes. Aim of this study was to assess the effects of age on the outcome of LCR for cancer at a single department, by comparing younger and older patients, matched by ASA score and type of operation.

**Material and Methods:** Perioperative outcome of patients 75 years old undergoing LCR between June 2005 and January 2009 for colorectal cancer were compared with findings in younger patients, matched by ASA score and type of operation.

Operative data (tot n. pts = 100)

	<75 years old (n = 50)	>75 years old (n = 50)	P value
Operative time, min [median (IQR)]	180 (136–240)	168 (120–210)	0.32
Conversions, N (%)	2 (4)	3 (6)	>0.999
Associated surgical procedures, N (%)	9 (18)	9 (18)	>0.999
Diverting ileo/colostomy, N (%)	7 (14)	8 (16)	>0.999
Intraoperative colonoscopy, N (%)	6 (12)	4 (8)	0.74
Lymph nodes removed, N [median (IQR)]	17 (13–24)	15 (13–18)	0.17

**Results:** The analysis considered 100 patients, fifty <75 years (Group A) and fifty >75 (Group B) years old. There were 18 right hemicolectomies, 16 left hemicolectomies, 4 anterior resections, 9 low anterior resections, 2 Miles' operation and 1 segmental resection in each group. We observed a significantly higher overall morbidity rate in elderly patients (24 vs. 8%): medical morbidity rate was higher in elderly (20 vs. 2% in younger) while surgical morbidity rate was similar (4 vs. 6%) in the two groups. The reoperation rate was similar in the two groups (2 vs. 4%, respectively).

**Conclusion:** Short-term results after LCR for cancer in patients over 75 years reveal a higher postoperative risk compared to their younger counterparts, even when matched by ASA score and type of operation. It suggests that although advanced age, per se, is not a contraindication, however represents a risk for LCR for cancer. This surgery in elderly patients should be considered preferably in well experienced centers to keep postoperative risk to a minimum.

#### Abstract ID: 0318 Specific Field: Colon and Rectum

**Mode of pres.: Free Paper**  
**ISW 2011 Session 183.07**

#### Is laparoscopic surgery for colorectal cancer safe in an emergency setting?

N. Siddiqui, S. Zeidan, K. Flashman, J.S. Khan, A.C. Parvaiz

Portsmouth Hospitals NHS Trust, Portsmouth, United Kingdom

**Introduction:** Laparoscopic colorectal surgery is gaining acceptance for emergency selected benign conditions. However, risks associated with emergency presentation & oncological clearance lead to a cautious acceptance of laparoscopic surgery in this setting. This study looks at the oncological outcome of emergency laparoscopic surgery for colorectal cancer carried out in a single district general hospital.

**Material and Methods:** A prospective database identified 20 consecutive patients who underwent emergency laparoscopic surgery for colorectal cancer over a 2.5 year period (April 2008–Oct 2010). Patient demographics and surgical outcomes were analysed.

**Results:** Median age was 72 years (45–93), 40% (8) were male, and 45% (9) had ASA grade >3.65% (13) had a right sided resection, 30% (6) a left sided resection, and there was one subtotal colectomy. 40% (8) presented with an intestinal obstruction, and 10% (2) with free perforation. There were 2 conversions to open surgery (1 oncological and 1 technical difficulty). Median operating time was 180 min (120–290). Five resections were palliative and R0 resection rate for the rest was 93% (14/15). One of the postoperative deaths was due to cardiac failure. Readmission was stoma related (1) and drainable pelvic collection (1).

**Conclusion:** Laparoscopic surgery for colorectal cancer is a safe and feasible option in an emergency situation, with acceptable mortality and morbidity.

#### Surgical Outcome

	n	%
Lymph node harvest: median (range)	16 (5–26)	
Pathology T4	10	50
Length of hospital stay: median (range)	7 (2)	
Post operative mortality	2	10
Reoperation for major complication	0	0
Readmission within 30 days surgery	2	10

**Abstract ID: 0319** Specific Field: **Colon and Rectum****Mode of pres.: Free Paper**  
**ISW 2011 Session 183.08****Laparoscopic rectal surgery: what we need to teach?**A. Kanazawa, A. Nakajima, A. Arimoto, Y. Kono  
Osaka Red-Cross Hospital, Osaka, Japan**Introduction:** A correct surgical procedure to rectal cancer has to make due allowance for both improved overall survival with local control of disease and preservation of the sphincter and urinary functions. Laparoscopic approach for rectal cancer has good operative view that has obvious advantage for improvement of operative procedure and education.**Material and Methods:** From January 2007 to December 2010, 230 cases laparoscopic resection for rectal cancer was performed in our hospital. For the reproducible operation, (1) making premeditated operative field with same instruments and view angle, (2) precise role of assistant, (3) enough rectal mobilization of rectum for cutting distal side of tumor.**Results:** laparoscopic low anterior resection: 203 cases, Laparoscopic intersphincteric resection: 13 cases and laparoscopic abdominoperineal resection: 14 cases were performed. 2 cases of anastomotic leakage were observed. All patients could retain urinary function without catheterization. There was no postoperative mortality in all cases.**Conclusion:** Laparoscopic rectal surgery still is not standard. We should establish the standardized operative view for effective education.**Abstract ID: 0320** Specific Field: **Colon and Rectum****Mode of pres.: Poster Discussion**  
**ISW 2011 Session PW 01.01****Laparoscopic lateral lymph node dissection**H. Kuroyanagi, S. Matoba, S. Toda  
Toranomon Hospital, Tokyo, Japan**Introduction:** Lateral lymph node metastasis has been reported to occur in 5–10% of patients with advanced lower rectal cancer in Japan. Necessity of prophylactic lateral lymph node dissection (LLND) for the patients without the evidence of lateral lymph node metastasis on the preoperative image study has been the matter of debate even in Japan. However, surgical resection is still the only potentially curative option for those with lateral lymph node metastasis.**Material and Methods:** We have positively employed laparoscopic surgery for rectal cancer with the belief that good image obtained with laparoscope enables us to perform more precise surgery. In order to extend this idea to the patients with lateral lymph node metastasis, we have developed the technique of laparoscopic lateral lymph node dissection. It consists of following steps; (1) dissection and identification of the ureter towards the bladder. (2) dissection around the external iliac vessels. (3) identification of the obturator nerve and lymph node dissection around it and (4) dissection along the internal iliac vessels. Resection of the internal iliac artery is sometimes needed for complete lymph node dissection, on the other hand, autonomic nerve can be preserved in most cases.**Results:** We have performed this procedure in four cases in 2010. There was no conversion to open. Operative time for one side lateral lymph node dissection was approximately 90 min. Blood loss was small amount. There was no need for transfusion in all cases. Post-operative course was uneventful. Urinary function was preserved in all cases.**Conclusion:** Laparoscopic lateral lymph node dissection can be safely performed with the standardized operative steps based on the precise understanding of pelvic anatomy.**Abstract ID: 0321** Specific Field: **Colon and Rectum****Mode of pres.: Poster Discussion**  
**ISW 2011 Session PW 01.02****Significance of lateral lymph node dissection for low rectal cancer in prognosis**H. Sato [1], K. Maeda [1], T. Hanai [1], K. Masumori [1],  
Y. Koide [1], H. Matsuoka [1], K. Toyama [2][1] Fujita Health University, Toyoake, Japan, [2] Nogaki Hospital,  
Nagoya, Japan**Introduction:** This study was performed to identify patients who would benefit from lateral lymph node (LLN) dissection for advanced low rectal cancer.**Material and Methods:** This study involved 157 patients with Dukes C low rectal cancer undergoing total mesorectal excision (TME) and LLN dissection. Sharp LLN dissection was performed in areas B and C (area B: the space between the autonomic nerve and the internal iliac artery, area C: the obturator space), with preservation of the pelvic autonomic nerve after TME. The patients were divided into two groups; patients with positive nodes only in the TME area (group I,  $n = 90$ ) and patients with positive LLNs (group II,  $n = 67$ ). Group II was further divided into two groups according to the following: the number of positive LLNs (3 positive LLNs [Group IIN1,  $n = 54$ ] and  $>3$  positive LLNs [Group IIN2,  $n = 13$ ]), the side of positive LLNs (unilateral [Group IIS1,  $n = 50$ ] and bilateral [Group IIS2,  $n = 17$ ]), and the site of positive LLNs (either area B or C [Group IIA1,  $n = 44$ ] and in both areas B and C [Group IIA2,  $n = 23$ ]). Clinical outcomes were studied retrospectively among the groups in terms of survival and recurrence.**Results:** The five-year survival rate (5SR) was 71.1% in Group I and 38.1% in Group II. Survival was significantly worse in Group II than in Group I. Survivals were significantly worse in Group IIN2, Group IIS2, and Group IIA2 (high-risk group,  $n = 27$ ) than that in IIN1, IIS1 and IIA1. Survival was significantly better in patients who do not belong to any high-risk groups (low-risk group,  $n = 44$ , 5SR: 56.2%) than that in patients who belonged to the high-risk group (5SR: 13.9%). There was no significant difference in survival between Group I and low-risk group. There was no 5-year survivor in patients who belonged to equal to or more than two high risk groups. Overall recurrence rate and local recurrence rate were 36.7% and 10.0% in Group I, 45.0% and 12.5% in low-risk group, 88.9% and 55.6% in high-risk group. Overall and local recurrence rates were significantly higher in high-risk group than in low-risk group. There were no significant differences in overall and local recurrence rates between Group I and low-risk group.**Conclusion:** LLN dissection for low rectal carcinoma was effective for patients with fewer than four positive LLNs unilaterally in either area B or area C.

Abstract ID: 0322 Specific Field: Colon and Rectum

Mode of pres.: Poster Discussion  
ISW 2011 Session PW 01.03**Curative laparoscopic operation to advanced sigmoid rectal cancer with successful neoadjuvant chemoradiotherapy**

M. Fujii, S. Matoba, H. Kuroyanagi

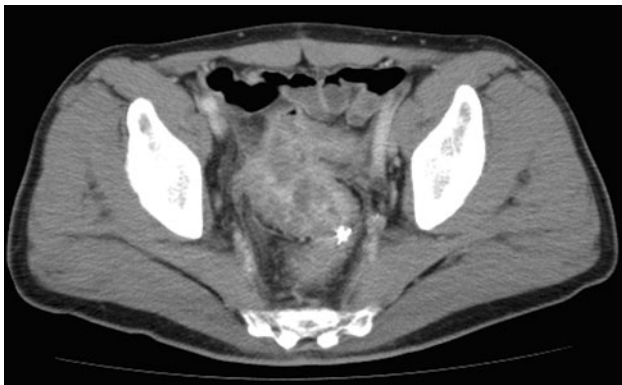Toranomon Hospital, Tokyo, Japan

**Introduction:** To the locally advanced rectal cancer, several prior studies have identified preoperative chemoradiotherapy leads to better local control of the disease. We report the experience with curative radical operation due to successful neoadjuvant chemoradiotherapy for the sigmoid rectal cancer which had infiltrated to the retroperitoneal space and couldn't be resect at the first time.

**Material and Methods:** 62 year-old-man visited a local hospital with appetite loss, diarrhea and weight loss. On a screening enhanced computed tomography (CT), there are bulky tumor 10cm in diameter, which had infiltrated to the retroperitoneal space, suspected advanced sigmoid rectal cancer. Preoperatively, we planed to perform a curative laparoscopic operation. Intraoperative findings showed no retroperitoneal metastasis but the tumor infiltrated to the retroperitoneal space with no mobility. We decided it was impossible to perform a curative operation, changed plan to perform colostomy at the sigmoid colon. Adjuvant radiotherapy was performed by a linear accelerator to the pelvic region in the dose of 56 Gy in 26 fractions. Follow-up CT was performed close before the surgery, which showed partial response.

**Results:** On May 2010, the patient underwent laparoscopic Hartmann's operation. Pathological diagnosis showed pMP, pN0, ly+, v+, fStage I, efficacy of radiation therapy was grade 2A, Cur A. He had no postoperative complications, entered hospital postoperative day 13th. He is now disease free survival without recurrence after 8 month from the operation.

**Conclusion:** We experienced a case of an advanced sigmoid rectal cancer treated by curative operation with successful neoadjuvant chemoradiotherapy. Neoadjuvant chemoradiotherapy for advanced rectal cancer is in expectation of down-staging of the tumor, decrease postoperative local recurrence and expanding feasibility of sphincter-preserving surgery. This case suggest that neoadjuvant chemoradiotherapy for advanced colorectal cancer has a feasibility to downstage tumor and to perform a curative radical operation.



**Figure:** An enhanced CT image of the pretreatment of the sigmoid rectal cancer

Abstract ID: 0323 Specific Field: Colon and Rectum

Mode of pres.: Poster Discussion  
ISW 2011 Session PW 01.04**Clinical short and middle-term outcomes of laparoscopic surgery for rectal cancer**M. Inomata, H. Shiroita, T. Etoh, K. Yasuda, T. Noguchi,  
N. Shiraishi, S. Kitano

Oita University Faculty of Medicine, Oita, Japan

**Introduction:** Laparoscopic colorectal surgery is widespread in the world, but the rate of rectal cancer has increased more slowly than that of colon cancer, because of technical difficulties. We demonstrate clinical outcomes of laparoscopic anterior resection for rectal cancer.

**Material and Methods:** In 102 patients with rectal cancer, high anterior resection (HAR) was performed in 32, low anterior resection (LAR) in 40, ultra-LAR with inner sphincter resection (ISR) in 12, abdominoperineal resection (APR) in 18. There were 25 patients in stage I, 41 in stage II, 31 in stage III, 5 in stage IV. A prior chemoradiotherapy was performed in 10 patients.

**Results:** Mean blood loss was 85 ml, and surgical time was 283 min. In 84 patients undergoing anterior resection, the complication rate was 12%, including 2% in anastomotic leakage, 1% in pulmonary inflammation, 8% in wound infection. In 18 patients undergoing abdominoperineal resection, the complication rate was 15%, including 4% in bowel obstruction, 3% in intrapelvic abscess, 8% in wound infection. Disease-free survival rate was 96.7% for stage I, 94.8% for stage II, and 79.6% for stage III disease.

**Conclusion:** Our study demonstrates that laparoscopic surgery for rectal cancer is feasible in short and middle-term outcomes. Further elucidation of long-term outcomes of laparoscopic surgery for rectal cancer will be required.

Abstract ID: 0324 Specific Field: Colon and Rectum

Mode of pres.: Poster Discussion  
ISW 2011 Session PW 01.05**Total pelvic exenteration with combined excision of the pubis and the ischium for locally recurrent rectal cancer: report of two cases**K. Uehara [1], Y. Yoshioka [1], S. Ishiguro [2], T. Ebata [1],  
Y. Yokoyama [1], T. Igami [1], G. Sugawara [1], M. Nagino [1]

[1] Nagoya University Hospital, Nagoya, Japan, [2] Aichi Cancer Center Hospital, Nagoya, Japan

**Introduction:** Locally recurrent rectal cancer (LRRC) is still common after curative resection for primary rectal cancer. Although a standard treatment for LRRC has not been established yet, complete surgical resection (R0 resection) represents the only potentially curative treatment. However, aggressive surgical treatment for LRRC is technically difficult with high morbidity rate and is still challenging.

**Material and Methods:** (Case 1) A 67-year-old male with LRRC was referred to our hospital. He had undergone abdominoperineal resection (APR) 2 years before (pT3N0M0, Stage IIA) at previous hospital. On admission, the recurrent tumor, 2 cm in diameter, was located adjacent to the right ischial tuberosity. He underwent TPE with combined resection of the right pubis and the ischium. Operative



time was 1,050 min and blood loss was 3,626 ml. (Case 2) A 58-year-old male, who had undergone APR 3 years before (pT3N0M0, Stage IIA), was diagnosed as having LRRC. At previous hospital, he underwent systemic chemotherapy (9 cycles of FOLFOX, 8 of FOLFIRI and 2 of FOLFIRI plus Bmab) and then, he visited our hospital. He had LRRC, 4 cm in diameter, invading the prostate, the urethra and the left obturator internus muscle, with two liver metastases in S4 and S7. He underwent TPE, total emasculation and combined resection of the bilateral pubis and the left ischium, and partial hepatectomy. Operative time was 1,234 min and blood loss was 2,070 ml.

**Results:** In both cases, reconstruction of the bony pelvis was not required. Histopathological findings showed that R0 resection was successfully achieved. Although postoperative hospitalization was quite long (49 and 92 days respectively) and prolonged rehabilitation was required, now they live healthy without gait disorder and are capable of being self-supporting.

**Conclusion:** Aggressive surgical resection for LRRC, although technically demanding, should be considered when R0 resection is deemed possible.

## Abstract ID: 0325 Specific Field: Colon and Rectum

Mode of pres.: Poster Discussion  
ISW 2011 Session PW 02.01

### Two cases of colonic neuroendocrine carcinoma with liver metastases successfully treated by hepatic arterial infusion

S. Yamauchi [1], H. Uetake [2], H. Kobayashi [1], T. Ishikawa [2], S. Iida [1], T. Higuchi [1], M. Enomoto [1], K. Sugihara [1]

[1] Tokyo Medical and Dental University, Department of Surgical Oncology, Tokyo, Japan, [2] Tokyo Medical and Dental University, Department of Translational Oncology, Tokyo, Japan

**Introduction:** It has been reported that neuroendocrine carcinoma (NEC) of the large intestine is rare and carries poor prognosis. We report two cases of colonic NEC with hepatic metastases, who were successfully treated by hepatic arterial infusion.

**Results:** Case 1: A 71-year-old man diagnosed as sigmoid colon cancer and undergoing sigmoidectomy was histologically determined to have NEC. Liver metastases were detected 1 month after surgery. Transcatheter arterial chemoembolization (TACE; doxorubicin and lipiodol) was initiated. Partial response (PR) was observed after 2 times of administration. Eight months after surgery, lymph node metastasis on the posterior surface of the pancreatic head was detected. Radiation therapy was performed for the metastasis and PR was observed. The patient was alive after 42 months and TACE was continued.

Case 2: A 63-year-old male was diagnosed as ascending colon cancer with severe liver dysfunction caused by multiple liver metastases. Initially, hepatic arterial infusion (HAI) chemotherapy was started to reduce the size of metastatic tumors and to prevent a liver failure. After 8 courses of HAI chemotherapy, he recovered from liver dysfunction, and underwent right hemicolectomy. Pathological examination of the resected specimen revealed the tumor was neuroendocrine carcinoma. After surgery, a systemic infusion of FOLFOX plus bevacizumab regimen was started. PR of metastatic lesions was observed. Regimen was changed to irinotecan plus cetuximab after 11 cycles of FOLFOX plus bevacizumab. He was alive for 8 months after HAI and the chemotherapy was continued.

**Conclusion:** Combined therapy including surgery, radiotherapy, and chemotherapy, although not yet standardized, is required against NEC with hepatic metastases.

## Abstract ID: 0326 Specific Field: Colon and Rectum

Mode of pres.: Poster Discussion  
ISW 2011 Session PW 02.02

### Treatment strategy of the colorectal gastrointestinal neuroendocrine tumors (GI-NETs): which is better? Local excision or radical surgery?

K. Shigeta [1], H. Hasegawa [1], Y. Ishii [1], T. Endo [1], H. Ochiai [1], M. Mukai [2], Y. Kitagawa [1]

[1] Keio University School of Medicine, Department of Surgery, Tokyo, Japan, [2] Keio University School of Medicine, Department of Pathology, Tokyo, Japan

**Introduction:** Carcinoid is a tumor which is relatively rare in colon and rectum, and known as a low malignancy tumor. However, there are some reports that carcinoids has high malignancy which could metastases in liver. Recently, many reported that the term 'carcinoid' is inappropriate to describe this tumor, it is now classified as gastrointestinal neuroendocrine tumor (GI-NETs). But the management of GI-NETs in colorectal area is still controversial. Our aim is to determine the appropriate treatment of colorectal GI-NETs and clarify the risk factor of recurrence.

**Material and Methods:** We analyzed the clinical and histopathological data of patients who were pathologically diagnosed as colorectal GI-NET and submitted to local or radical treatment over 20-year period (1990–2010).

**Results:** A total of 98 cases (69 males and 29 females) of colorectal GI-NETs were identified. We excluded one patient who complicated ulcerative colitis and adenocarcinoma. The median age was 55 years (24–86 years) and median overall survival was 33 months (1–207) and two patients died from the recurrence of colorectal GI-NETs. 46 patients (46.5%) had no symptoms when they were diagnosed, and of these 42 patients were diagnosed accidentally because they were told to take specific examination by medical checkup. 2 patients were diagnosed as synchronous liver metastasis and underwent transcatheter arterial embolization. 85 patients (87.6%) were treated by local excision and there were no recurrence seen in tumor size <15 mm, these patients were treated adequately by local excision ( $P = 0.035$ ). 10 patients (10.3%) underwent radical surgery, and of these 4 had lymph node metastasis. One patient relapsed in liver 1 year and a half after surgery. Risk factor of recurrence was tumor size <15 mm ( $P = 0.005$ ) and lymphatic invasion ( $P = 0.013$ ). Lymphatic invasion was not frequent when the tumor size is <10 mm ( $P = 0.003$ ).

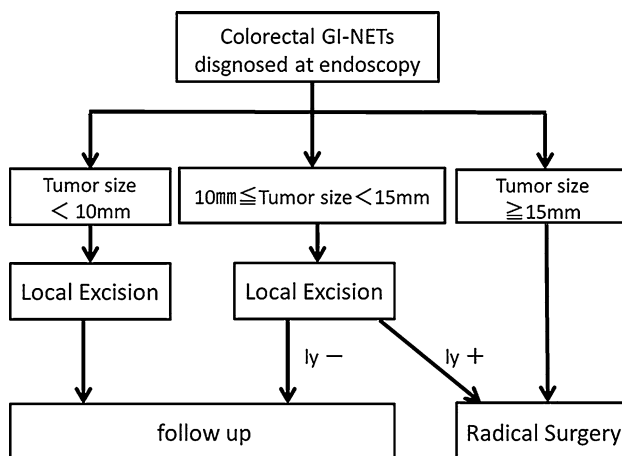


Fig. 1 Treatment algorithm for colorectal GI-NETs

**Conclusion:** Local excision should be considered when tumor size is smaller than 10 mm. Tumor size which is <10 mm, <15 mm local excision may be considered first, but radical surgery should be considered if lymphatic invasion is positive. The risk of lymph node metastasis will be greater when the tumor size is <15 mm, so that we recommend radical surgery for such patients (Fig. 1).

**Abstract ID: 0327** Specific Field: **Colon and Rectum**

**Mode of pres.: Poster Discussion**  
**ISW 2011 Session PW 02.03**

**Prolonged survival in patients with pseudomyxoma peritonei treated with oral fluoropyrimidine**

T. Ishikawa, H. Uetake, M. Ishiguro, H. Kobayashi, S. Iida, T. Higuchi, M. Enomoto, K. Sugihara

Tokyo medicaland Dental University, Tokyo, Japan

**Introduction:** The prognosis of appendiceal mucinous cystadenocarcinoma with pseudomyxoma peritonei (PMP) is poor. We report 2 cases of PMP secondary to mucinous cystadenocarcinoma (MCA) of the appendix, successfully treated with oral fluoropyrimidine.

**Results:** Case: 1 A 67-year-old woman was diagnosed as acute appendicitis and underwent appendectomy. By pathological examination, she was diagnosed as MCA of appendix with perforation. Two month later, a laparotomy was performed but we did not perform cytoreduction surgery because of the severe adhesion and the broad dissemination of the mucous malignant cells. After the operation, she received Uracil/Tegafur (UFT) plus leucovorin for 12 months. Abdominal CT and PET-CT showed complete response (CR). We continued the treatment for 3 years and stopped. She receives follow-up CT every 6 months and does not show any sign of recurrence 30 months after chemotherapy.

Case 2: A 73-year-old woman initially diagnosed as acute appendicitis and underwent appendectomy 5 years ago at other hospital. By pathological examination, she was diagnosed as MCA. Fifteen months after appendectomy, she was diagnosed as PMP by abdominal CT. The ascites slowly increased and she consulted our department. We found wide spread involvement of the small bowel by abdominal CT and started to administer UFT plus leucovorin. CT shows no change of ascites for 30 months.

**Conclusion:** We report our clinical experience regarding the use of UFT plus leucovorin for cases of pseudomyxoma peritonei secondary to MCA. This case report may suggest the new role of oral fluoropyrimidine in the treatment of pseudomyxoma peritonei.

**Abstract ID: 0328** Specific Field: **Colon and Rectum**

**Mode of pres.: Poster Discussion**  
**ISW 2011 Session PW 02.04**

**Investigation of rectal carcinoid treated in our department**

K. Matsuda, S. Ishihara, T. Watanabe

Teikyo University, Tokyo, Japan

**Introduction:** Rectal carcinoids are uncommon tumors. They are discovered either incidentally during screening colonoscopy or during an evaluation for symptoms such as rectal bleeding. Treatment approaches are still controversial because long-term outcomes for patients without metastasis are poorly described in the literature. Size

and depth of invasion are considerations when treating patients with rectal carcinoids. In the present study we sought to elucidate which patients would likely benefit from local excision, i.e., transanal excision or endoscopic resection.

**Material and Methods:** Nineteen cases of rectal carcinoid treated or followed in our department were investigated clinically and histopathologically.

**Results:** The mean patient age at diagnosis was 59 years (range, 22–84 years). Ten patients (53%) were men, and 9 (47%) were women. Size of lesions were 3–12 mm and 6 on average. As to depth of carcinoid, 18 were submucosal and only one muscularis propriae. As to treatment 13 cases underwent surgery alone, 2 endoscopic mucosal resection and surgery, 4 endoscopic resection alone. As to surgery, 10 underwent local resection alone, one local resection and low anterior resection, one hepatectomy and local resection, 2 low anterior resection for rectal cancer. The depth of beyond the muscularis mucosa was 150–6,800  $\mu$ m. Only one case with carcinoid invasion to muscularis propriae showed liver metastasis. Four cases of 19 (21%) were complicated with colorectal cancer. No cases died or recurred for carcinoid during 6 years follow-up period in average.

**Conclusion:** Local resection or endoscopic resection is recommended for rectal carcinoid less than 10 mm in diameter, limited in submucosal layer. The complication rate of rectal carcinoid and colorectal cancer is high, which suggests that we should not miss submucosal tumor in the rectum when performing colonoscopy for patients of colorectal cancer.

**Abstract ID: 0329** Specific Field: **Colon and Rectum**

**Mode of pres.: Poster Discussion**  
**ISW 2011 Session PW 02.05**

**Clinical significance of serum p53 antibodies in colorectal cancer patients**

T. Kojima [1], M. Ishimaru [1], S. Nagasawa [1], Y. Mihara [1], T. Ozawa [2], Y. Kitamura [3], A. Hidemura [1], H. Suzuki [1]

[1] Kanto Rosai Hospital, Dept Surgery, Kanagawa-ken, Japan, [2] Tokyo Univ. Grad. Sch. Med., Dept. Surgical Oncology, Tokyo, Japan, [3] Showa Univ. Fujigaoka Hospital, Dept. Surgery, Kanagawa-ken, Japan

**Introduction:** p53 Antibodies (p53-Abs) have been detected in the serum of a proportion of colorectal cancer (CRC) patients. It is not yet known at which stage during colorectal tumor progression p53-Abs appear in the serum.

**Material and Methods:** o evaluate the clinical significance of the serum p53-Abs in colorectal cancers, we preoperatively and postoperatively measured tumor markers, including the serum p53-Ads in 168 cases of colorectal cancer and compared them to patient profiles utility of these antibodies as markers for CRC prognosis remains to be clarified. Using the quantitative enzyme-linked immunosorbent assay kit that is available in Japan, we analyzed serum samples from 168 CRC patients. Levels of p53-Abs were defined as negative (<1.30 U/ml) and positive (1.30 U/ml).

**Results:** Overall, 16.0% of CRC patients had positive serum p53-Abs levels. The parameters that were associated with a greater frequency of positive p53-Abs levels were the rectum ( $P = 0.10$ ). Other parameters such as sex, age, tumor location, carcinoembryonic antigen levels, CA19-9 levels, gross findings, histologic grade, mucin production and TNM stagewere not associated with positive p53-Abs. Patients with positive p53-Abs had a shorter survival times than did those without. In some patients with recurrence, they had only positive serum p53-Abs levels but negative for CEA or CA19-9.

**Conclusion:** p53-Abs occur with tumor progression in colorectal carcinogenesis. The detection of serum p53-Abs is expected to become as a new serological marker for the early diagnosis of CRC recurrence.

**Abstract ID: 0330** Specific Field: **Colon and Rectum**

**Mode of pres.: Poster Discussion**  
**ISW 2011 Session PW 02.06**

**Inhibition of selected enzymes with specific inhibitors in the tissue homogenates from patients with colorectal cancer**

W. Kielan [1], A. Hap [1], J. Rudno-Rudzinska [1], Z. Grzebieniak [1], A. Kumar Agrawal [1], R. Tarnawa [1], W. Hap [2]

[1] Medical University Wrocław, Wrocław, Poland, [2] Medical University Wrocław, Poland, Poland

**Introduction:** Large intestine malignancy is the second most common malignancy and second leading cause of cancer mortality in Poland. This is related to late detection of these lesions, e.g. due to lack of effective screening tests. Lesions found by a surgeon are clinically advanced, making the treatment often ineffective and sometimes even completely impossible. Discovery of a substance that would be able to stop key processes for the development of malignancy could change such situation. Activity of certain enzymes was found to increase in malignant cells and invasion of malignancy could be triggered by inadequate amount of endogenous inhibitors of these enzymes in the surrounding healthy tissues. Inhibitors identical with that produced in human cells were found in egg whites.

**Material and Methods:** Immunohistochemistry and histology of tissue specimen collected from malignant lesions resected from 60 patients diagnosed with large intestine adenocarcinoma, who underwent surgical treatment in our Department between 2007 and 2009.

**Results:** Differences were found between health tissues, margins and center of the malignant lesions with regard to amount and distribution of stained cathepsin B-cystatin complexes. The above mentioned inhibitors were able to inhibit 90% of primary activity of cathepsin B and L in malignant tissues.

**Conclusion:** Cystatins obtained from egg whites could be used as substances supporting anti-cancer therapy in the future.

**Abstract ID: 0331** Specific Field: **Colon and Rectum**

**Mode of pres.: Poster Discussion**  
**ISW 2011 Session PW 03.01**

**51 cases laparoscopic colorectal surgery: 1 yr experience in NCI**

S. Khunpugdee, T. Khuaprema

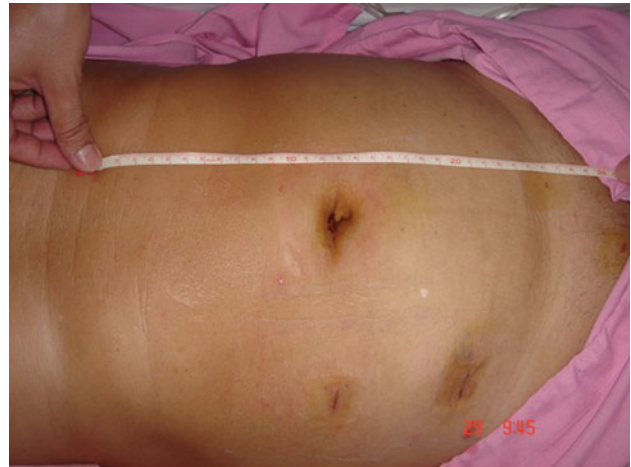National Cancer Institute, Bangkok, Thailand

**Introduction:** Since February to December 2010, 51 cases of laparoscopic colorectal surgery for cancers and tumors were operated in NCI. We will present complications and outcome?

**Material and Methods:** Every cases of colorectal cancers which use laparoscopic surgery were include in report.

**Results:** Overall cases: laparoscopic Rt colectomy, extracorporeal anastomosis = 13 cases; laparoscopic Lt. colectomy = 3; laparoscopic sigmoidectomy = 3; laparoscopic LAR = 25; laparoscopic total colectomy = 4; complication: No operative mortality: Rt. colectomy = 0; Lt. colectomy = 0; sigmoidectomy = 0; LAR = 3/25 (Ultra low anastomosis cases); total colectomy = 1/4 Early PO gut obstruction.

**Conclusion:** After learning curve period, Laparoscopic surgery is safe and can meticulous dissection for oncologic control (Figure).



**Figure:** Specimens

**Abstract ID: 0332** Specific Field: **Colon and Rectum**

**Mode of pres.: Poster Discussion**  
**ISW 2011 Session PW 03.02**

**Single-incision laparoscopic right colectomy using a EZ access and curved reusable instruments for advanced right sided colon cancer**

M. Kotake, D. Yamamoto, H. Bando, S. Tashiro, M. Yamamoto, N. Inaki, M. Kurokawa, T. Yamada

Ishikawa Prefectural Central Hospital, Kanazawa, Japan

**Introduction:** Single-incision laparoscopic colectomy (SILC) is rapidly emerging in the field of minimally invasive colon and rectal surgery. This report presents the surgical technique, safety and feasibility of performing single-incision laparoscopic right colectomy using a EZ access (Hakko) and curved reusable instruments (Richard-WOLF) for advanced right sided colon cancer. This procedure can form counter traction and instrument collision is less than another method.

**Material and Methods:** Between November and December 2010, SILC was performed for 4 patients. All patients had advanced cancer of the cecum or ascending colon. Single access to the abdomen was achieved with a 2.5-to-3.0 cm umbilical incision. EZ access was attached at the incision. Assistant retracted the tissue by the curved reusable instruments, enabling triangulation in cooperation with operator. The mesocolon was dissected using a medial to lateral approach. The roots of the vascular pedicles were isolated and divided from the superior mesenteric artery during lymph node dissection. In all cases, terminal ileum is cut off in early phase of operation, which secure a good view of the operative field, less damage of the organ. Extracorporeal anastomosis was performed. Preliminary short-term results were analyzed retrospectively.

**Results:** There were 2 men and 2 women with a median age of 70 years. Their median body mass index was 22.3 kg/m<sup>2</sup>. Pathological stage according the TNM classification was stage I, stage IIB, stage IIIB and stage IV in each 1 patient. The SILC procedure was performed with a mean incision length of 2.7 cm (range, 2.5–3.0 cm) and a mean operative time of 163 min (range 140–210 min). Surgical blood loss was slight (range 5–10 g) in all patients. The mean number of lymph nodes extracted was 22. There were no intraoperative complications, no need to add a second port, and no need to convert to open surgery. The mean postoperative stay was 12 days (range 10–19 days). There were no postoperative complications.

**Conclusion:** Our preliminary results show that single-incision laparoscopic right colectomy using a EZ access and curved reusable instruments are safe and feasible method; nevertheless larger, randomized experiences are needed to demonstrate the benefits of SILS compared with standard laparoscopic resections.

**Abstract ID: 0333** Specific Field: **Colon and Rectum**

**Mode of pres.: Poster Discussion**  
**ISW 2011 Session PW 03.03**

**Feasibility of laparoscopic surgery for stage IV colorectal cancer**

K. Ota, I. Takemasa, M. Mori

Graduate School of Medicine Osaka University, Suita City, Japan

**Introduction:** Laparoscopic surgery (LS) has been widely employed in the curative treatment of colorectal cancer based on the clinical evidence with several randomized controlled studies compared with the open surgery (OS). However, the value of palliative laparoscopic resection of the primary tumor for stage IV colorectal cancer remains controversial. LS for stage IV colorectal cancer may provide not minimally invasive treatment but better oncological result due to allowing the smooth shift to the next treatment such as chemotherapy. The aim of this study is to examine the feasibility of LC for stage IV colorectal cancer.

**Material and Methods:** A total of 53 patients with Stage IV colorectal cancer were performed palliative resection of the primary tumor in our hospital since September 2006 to December 2010. They were divided into 28 for LS (group A) and 25 for OS (group B), and their clinical outcomes were compared with each other and with those of 66 patients with stage I–III disease who had for radical LS (group C) retrospectively. Surgical factors (operative time, blood loss and open conversion rates), perioperative short-term results (hospital stay, morbidity and mortality) were evaluated.

**Results:** The group A consists of 22 liver metastasis, 4 lung metastases, 1 brain metastasis, and 1 paraaortic lymph node metastasis. The three groups of patients had similar demographic features. There were no difference in operation time and blood loss between the group A and C (group A: 195 min and 60 g; group C: 180 min and 50 g), while operation time was significantly shorter but blood loss was significantly greater in the group B. The open conversion rate was 10.7% in the group A and 1.5% in the group C, respectively. The median length of hospital stay after operation was 12.5 days in the group A and 14 days in the group B. The incidences of postoperative complications were almost similar among the three groups. No mortality was observed in this study.

**Conclusion:** Surgical factors and perioperative short-term outcomes of LS for the patients with stage IV colorectal cancer are equivalent to those for stage I–III cancers, and LS provide less invasive treatment and faster shift to next chemotherapy than OS in stage IV colorectal cancer. These results indicate that LS can be successfully performed in selected stage IV colorectal cancer patients.

**Abstract ID: 0334** Specific Field: **Colon and Rectum**

**Mode of pres.: Poster Discussion**  
**ISW 2011 Session PW 03.04**

**Is repair of mesenteric defect necessary after laparoscopic colectomy?**

K. Murata, Y. Ide

Suita Municipal Hospital, Suita, Japan

**Introduction:** In laparoscopic colectomy, mesenteric defect after anastomosis is generally not closed. This is only because of technical problem and time consuming. We experienced two complication cases due to the mesenteric defect.

**Results:** Case 1: A 70-year-old female patient had a severe small bowel obstruction two weeks after laparoscopic right hemi-colectomy for colon cancer. Emergent surgery revealed necrosis of small intestine caused by the internal hernia due to the defect of mesenteric defect of the former surgery. Case 2: A 54-year-old male patient had a small bowel obstruction after 19 days of sigmoidectomy for colon cancer. Emergent surgery revealed tight adhesion of small intestine to the plastic clips on the root of inferior mesenteric artery. This adhesion caused torsion of small intestine. The clips were not covered by the mesentery, which is usually done in conventional open surgery. After these two cases, we started to close mesenteric defect for all laparoscopic colectomy cases.

**Conclusion:** Although this type of complications is rare and reported as 0.8%, if it occurs, it needs surgery and may cause ischemic damage to long small intestine. Since we should make every effort to avoid any complication after surgery, we propose that laparoscopic colorectal surgeons re-consider closing mesenteric defect.

**Abstract ID: 0335** Specific Field: **Colon and Rectum**

**Mode of pres.: Poster Discussion**  
**ISW 2011 Session PW 03.05**

**Laparoscopic colorectal cancer surgery for bulky tumors**

T. Naitoh [1], K. Watanabe [1], M. Kinouchi [1], T. Morikawa [1], A. Oyama [2], K. Miura [1], C. Shibata [1], I. Sasaki [1]

[1] Tohoku University Hospital, Sendai, Japan, [2] Sendai City Medical Center, Sendai, Japan

**Introduction:** Laparoscopic treatment for colorectal cancer has become almost standard procedure. A favor over minimally invasive surgery encourages us to apply this procedure to advanced cases. We previously reported that the laparoscopic colorectal cancer surgery is considered as acceptable even for advanced diseases, according to their survival rate. However, the problem concerning safety to the larger tumor still remains unsettled. Unexpected tumor invasion to adjacent organs, which would not be detected by pre-operative evaluations, might exist. Above all, a bulky tumor is heavy to manipulate and manipulation of the bulky tumor with laparoscopic instruments could lead to cancer cell exfoliation. Therefore, the bulky tumor is considered unsuitable for laparoscopic procedures. The aim of this study is to evaluate the feasibility and safety of laparoscopic procedure for relatively larger colorectal cancer.

**Material and Methods:** During January 2000 and December 2009, 521 colorectal cancer cases underwent laparoscopic resection of the large bowel. Of those 26 cases in which tumor size is over 50 mm in maximum diameter were selected for this study. Procedures were carried out in medial-to-lateral approach manner with 5-port and one small incision. We reviewed the patients' record and assessed the short-term outcome of these patients, recurrence rate and prognosis.

**Results:** A median tumor size was 60 mm, and a maximum size was 90 mm. Tumor localization was as follows: 9 in the right colon, 3 in the transverse colon, 9 in the left colon, and 5 in the rectum. Two cases were converted to conventional procedure due to unexpected tumor extent. Average operation time was 171 min and estimated blood loss was 46 ml. These were not different from the smaller tumor cases. Pathological T stage was as follows: 24 cases in pT3, 2



cases in pT4. Node metastases were observed in 11 cases (42.3%) and 2 cases were classified in pN2, while only 23% cases have node metastases in less than 5cm tumor patients. No perioperative complications were observed. Two cases had recurrent disease. Both of them had liver metastases and one of them died 26 months after surgery.

**Conclusion:** Although bulky tumor is thought to be unsuitable for laparoscopic procedure, it would be treated safely without losing the oncological validity in selected cases if the tumor is less than 90 mm.

**Abstract ID: 0336**      Specific Field: **Colon and Rectum**

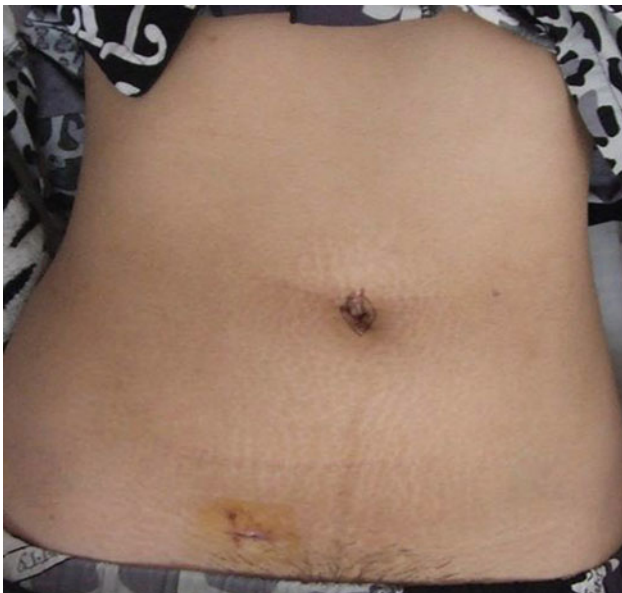**Mode of pres.: Poster Discussion**  
**ISW 2011 Session PW 03.06**

**Double incision laparoscopic restorative proctocolectomy without diverting ileostomy for familial adenomatous polyposis**

T. Ueki, T. Manabe, M. Tanaka, H. Toma

Surgery and Oncology, Kyushu University, Fukuoka, Japan

**Introduction:** A total proctocolectomy and ileal pouch anal canal anastomosis is a standard surgical treatment of familial adenomatous polyposis (FAP). A large part of the patients with FAP are twenties who usually dictate improved cosmesis. Laparoscopic surgery for colorectal disease demands several incisions and its scar sometimes reduce the cosmetic advantage as well as less trauma of the abdominal wall. Recently, single incision laparoscopic surgery (SILS) has been used to bring excellent cosmesis and is evolving rapidly in several surgical fields. But this procedure is technically demanding and its application is still limited. In this initial experience, we used transumbilical SILS ports and auxiliary 12 mm port placed on the very lower part of the right abdomen to create counter traction of tissue during operation and to cut the rectum perpendicularly within the anal canal as low as possible.



**Figure:** Abdominal scar at 15 days after surgery

**Material and Methods:** The patient was a 25-years-old female with familial adenomatous polyposis. The abdominal cavity was entered and SILS port (Covidien, MA) was inserted through the 2.5cm incision placed at the umbilicus. After insufflations of the abdomen and insertion of the other 12 mm port through a suprapubic incision placed the edge of the pubic hair, the 2 mm Mini Loop Retractor (Covidien, MA) was inserted from left side of the umbilicus to hold and tow the large bowel. A proctocolectomy was performed intracorporeally using regular laparoscopic instruments. The entire colon and rectum were delivered through the SILS port incision, then a 13 cm ileal-J pouch was made extracorporeally and the J-pouch anal anastomosis was performed 2 cm from anocutaneous verge intracorporeally. A diverting ileostomy was not created and the drain was inserted through the suprapubic incision to the anastomotic site.

**Results:** The operation was successfully accomplished. Operating time was 584 min and blood loss was 178 ml. The patient had low grade fever for several days without any clinical manifestation or wound pain except for anal pain due to anastomosis close to dentate line. She was discharged home 16 days after surgery.

**Conclusion:** Double incision laparoscopic proctocolectomy is feasible and safe, and affords good cosmesis.

**Abstract ID: 0337**      Specific Field: **Colon and Rectum**

**Mode of pres.: Poster Discussion**  
**ISW 2011 Session PW 03.07**

**Learning curve for laparoscopic colon cancer surgery: not a suitable phrase**

B. Furnes [1], K. Storli [1], K. Søndena [2]

[1] Haralds plass Deaconal Hospital, Bergen, Norway, [2] University of Bergen, Bergen, Norway

**Introduction:** Beginning in 2007, more radical open and laparoscopic surgery for colon cancer (CC) was introduced in our Department. We compared complications of these two methods with the initial 50 procedures as cut off level to see if a “learning curve” exists.

**Material and Methods:** A cohort consisting of 293 CC patients treated with colon resection from 2007 through 2010. The radical open procedure was used in 111 patients, the laparoscopic procedure in 138. Complications were classified according to modified Clavien-Dindo categories.

**Results:** Mean age was 72-years with 53.6% men and 46.4% women. 61.7% (179/290) had TNM stage I-II disease, 28.3% stage III and 10% stage IV. No differences in this or other preoperative parameters were present. A radical open procedure was used in 111 patients (38.3%) while 138 (47.6%) had a laparoscopic procedure. The rest, 44 patients (15.0%), had a modified open procedure (D2). In the first fifty of the open radical and laparoscopic groups, complications occurred as minor (1–2 grade) in 34% and 28% of patients and major (3–4 grade) complications in 16 and 14% of patients, respectively. Mortality was 4 and 2%. For the next 61 open and 88 laparoscopic procedures, the corresponding complication rate was 32.8 and 29.5% while the laparoscopic group had 22.7 and 6.8% complications. Mortality was 1.6 and 1.1%, respectively.

**Conclusion:** Laparoscopic surgery was introduced without overt differences in complications compared to the open approach. After the first 50 procedures, laparoscopic results improved. However, the phrase “learning curve” may not be appropriate and the meaning of the phrase is unfortunate.

**Abstract ID: 0338** Specific Field: **Colon and Rectum****Mode of pres.: Poster Discussion**  
**ISW 2011 Session PW 04.01****mFOLFOX6/Xelox chemotherapy plus bevacizumab for patients with unresectable stage IV colon cancer and a synchronous primary tumor**

S. Iwamoto, K. Tokuhara, S. Okazaki, H. Miki, A.-H. Kwon

Kansai Medical University, Hirakata, Osaka, Japan

**Introduction:** Surgical resection of asymptomatic primary colon tumor for patients presenting with synchronous unresectable metastatic lesion is controversial. Concerns remain about combining cytotoxic chemotherapy with bevacizumab in patients with an intact colon tumor because of risk of perforation and complications at the emergency surgery.**Material and Methods:** Patients had ECOG Performance 0–2 and an asymptomatic or improvement the symptoms by stoma surgery colon and rectum tumor with unresectable distant metastases. mFOLFOX6/Xelox plus bevacizumab were underwent as 1st line chemotherapy in our institution.**Results:** Between September 2007–July 2010, 75 patients were underwent mFOLFOX6/Xelox + bevacizumab as 1st line chemotherapy for metastatic colorectal cancer. 19 patients were with asymptomatic primary tumor and 15 patients were performed surgery for primary tumor after chemotherapy. 8 of 19 patients were required stoma surgery prior chemotherapy. The pathological effect from resected prime tumor revealed one patient of Grade 3 and 2 patients of Grade 2. One patient has anastomotic leakage in surgery for primary tumor, 2 patients were required emergency surgery during chemotherapy.**Conclusion:** mFOLFOX6/Xelox+bev.in synchronous asymptomatic primary tumor was safe, and it seemed that contribute to local control and resection for primary lesion will be improved patients QOL.**Abstract ID: 0339** Specific Field: **Colon and Rectum****Mode of pres.: Poster Discussion**  
**ISW 2011 Session PW 04.02****A study of a combination therapy using bevacizumab to metastatic colorectal cancer**

K. Nozawa, R. Shimada, A. Horiuchi, T. Hayama, H. Yamada, S. Ishihara, K. Matsuda, T. Watanabe

Teikyo University School of Medicine, Tokyo, Japan

**Introduction:** Objective: Since November 2007, we have been aggressively conducting a combination therapy using bevacizumab (BV) for unresectable, progressive recurrent colorectal cancer. This study examines its safety and efficacy in subjects who have undergone such treatment at our department.**Material and Methods:** Subjects: The study targeted 45 patients who were capable of undergoing 2 courses of BV-combination therapy for 4 or more weeks.**Results:** The subjects comprised 30 males and 15 females. Their mean age was 60 years (36–76 years); their PS was 0 in all the subjects; and their target lesions were primary (3 patient), hepatic metastasis (24 patients), lung metastasis (11 patients), lymph node metastasis (13 patients), bone metastasis (1 patient), peritoneal metastasis (8), and local recurrence (5 patients), with overlapping cases. The primary cancer sites were the appendix (2 patients), ascending colon (6), transverse colon (3), descending colon (2), sigmoid colon (14), and rectum (12). First-line treatment was administered to 29 patients,

mFOLFOX 6–25 patients, FOLFIRI to 3 patients, and sLV5FU2 to one patient. Their mean observation period was 136 days (13–228 days); their mean administration frequency was 10.3 times (2–117 times); anti-tumor effects were CR in 2 patient, PR in 14, SD in 10 and PD in 3 patient, with a 55% efficacy rate and 90% disease control rate. Second-line treatment was administered to 16 patients, mFOLFOX 6–7 patients, and FOLFIRI to 9 patients. Their mean observation period was 139 days (19–223 days); their mean administration frequency was 10.5 times (3–19 times). Anti-tumor effects were CR in 1 patient, PR in 7, SD in 7 and PD in 3 patient, giving a 50% efficacy rate and 81% disease control rate. Overall, the efficacy rate was 53% and disease control rate, 87%. As adverse events, peripheral neuropathy occurred in 52%, hypertension in 16%, nasal bleeding in 3 patients, melena in 1 patient, skin symptoms in 6 patients, and proteinuria in 32%. All the events were Grades 1 or 2. Two patients discontinued treatment because of ileus. No digestive tract perforation, thrombi or embolism was seen.

**Conclusion:** Although the observation period is too short to assess the treatment's clinical effects, requiring us to continue monitoring the course, this therapy appears to be safe and effective for first- and second-line treatments and beyond.**Abstract ID: 0340** Specific Field: **Colon and Rectum****Mode of pres.: Poster Discussion**  
**ISW 2011 Session PW 04.03****Neoadjuvant chemotherapy without radiation for locally advanced rectal cancer: retrospective case series study**

T. Matsumoto, S. Hasegawa, K. Okoshi, M. Yamada, K. Hida, K. Kawada, J. Kawamura, Y. Sakai

Kyoto University Graduate School of Medicine, Kyoto, Japan

**Introduction:** Neoadjuvant chemoradiotherapy (CRT) has been standard treatment for the patients with locally advanced rectal cancer (LARC) in the western countries. However, the long-term adverse effects of radiotherapy are not negligible. Recent progress in chemotherapy for colorectal cancer has let us conduct this study to investigate the feasibility and effectiveness of neoadjuvant chemotherapy (NAC) without radiation for LARC.**Material and Methods:** Between July 2005 and Aug 2010, we retrospectively reviewed 17 patients who received NAC (NAC group) as the initial treatment of LARC (cT3/4 or N+), and compared their clinicopathological data with 55 patients who underwent surgery without NAC (Surgery group) in the same period.**Results:** Administered chemotherapeutic regimens were IRIS (7 cases), FOLFOX (6 cases), FOLFIRI (3 cases), and IRIS followed by FOLFOX (1 case). Objective response rate was 52.9% (RECIST ver. 1.1), and 3 patients suffered grade 3 adverse events (CTC-AE ver.4). Operations performed were anterior resection (12 cases), abdominoperineal resection (2 cases), total pelvic exenteration (TPE) (2 cases) and Hartmann's operation (1 case). Of 17, 14 were performed laparoscopically. The median operative duration, blood loss, and length of post-operative hospital stay were 423.5 min, 163 ml, and 22 days, respectively. Fourteen patients (82.4%) underwent R0 resection and pathological examination revealed that number of cases with T- and N-downstaging were 5 (29.4%) and 8 (47%), respectively. But none had pathological complete response in this series. There was no chemotherapy or surgery related mortality. Two (11.8%) had post-operative complication (grade 3), including one case of anastomotic leakage (5.9%). After excluding the cases with extended surgery (ISR, TPE and combined pelvic lymph node dissection) (NAC:Surgery = 49:9), the short-term outcomes (median operative duration, blood loss, length of post-operative hospital stay, and the frequency of overall post-operative complication (grade3)) were almost equivalent between two groups.

**Conclusion:** NAC for LARC is almost safe but the local effectiveness of NAC using conventional agents alone is insufficient compared with CRT. Further prospective study employing molecular targeting drug is required.

**Abstract ID: 0341** Specific Field: **Colon and Rectum**

**Mode of pres.: Poster Discussion**  
**ISW 2011 Session PW 04.04**

**Therapeutic and adverse effects of preoperative chemoradiotherapy for rectal cancer**

S. Ishihara [1], T. Hayama [1], H. Yamada [1], K. Nozawa [1], K. Matsuda [1], T. Watanabe [2]

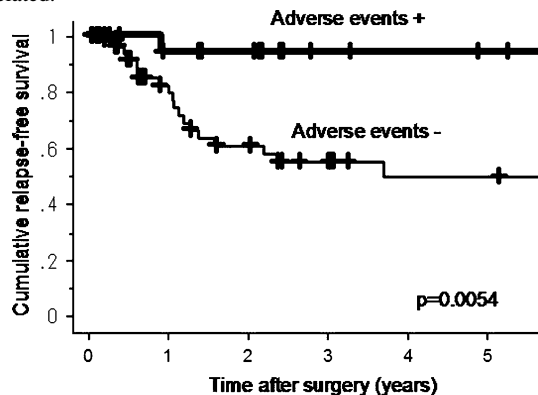
[1] Teikyo University, Tokyo, Japan, [2] Teikyo University, Japan

**Introduction:** Preoperative chemoradiotherapy for rectal cancer is shown to improve surgical outcome; however, it might also cause acute adverse events. This study aimed to clarify both the therapeutic and the adverse effects of preoperative chemoradiotherapy for rectal cancer and their impact on patient prognosis.

**Material and Methods:** Seventy-five patients with clinical T3-4 low rectal cancers curatively resected following preoperative chemoradiotherapy were studied. Thirty-one patients received radiotherapy, and 44 patients received chemoradiotherapy with tegafur-uracil and leucovorin. The total radiation dose was 50–50.4 Gy given in 25–28 fractions.

**Results:** Pathological T stage was down-staged to T0-2 in 26 patients (35%), and pathological lymph node metastasis was seen in 21 patients (28%). A high histological regression, defined as regression of more than 2/3 of the cancer, was seen in 36 patients (48%) including 6 patients (8%) with complete response. Tumor size was reduced in 54 patients (72%). Most frequent adverse events were leukocytopenia and diarrhea, observed in 9 patients (12%) and 18 patients (24%), respectively. The majority of the leukocytopenia and diarrhea was Grades 1–2 toxicity. Patients with pT0-2 (85 vs. 48%,  $P = 0.0076$ ), patients without pathological nodal metastasis (69 vs. 37%,  $P = 0.0046$ ) and patients who experienced leukocytopenia or diarrhea (94 vs. 49%,  $P = 0.0054$ , Fig. 1) showed higher 5-year disease-free survival rates than their counterpart. In multivariate analysis, only the presence of leukocytopenia or diarrhea was independently associated with improved disease-free survival (hazard ratio 0.132, 95% confidence interval 0.017–0.995).

**Conclusion:** Preoperative chemoradiotherapy for rectal cancer exerted both the therapeutic and adverse effects. Presence of adverse events was associated with improved patient survival, and this might indicate that radiosensitivities of cancer and normal cells are correlated.



**Fig. 1** Relapse-free survival of the patients with and without adverse events of preoperative chemoradiotherapy for rectal cancer

**Abstract ID: 0342** Specific Field: **Colon and Rectum**

**Mode of pres.: Poster Discussion**  
**ISW 2011 Session PW 04.05**

**Multimodal treatment in patients with peritoneal metastasis of colorectal cancer**

J. Nishimura [1], J. Hasegawa [2], M. Ikeda [1], H. Yamamoto [1], M. Sekimoto [1], R. Nezu [2], Y. Doki [1], M. Mori [1]

[1] Osaka University, Suita, Japan, [2] Osaka Rosai Hospital, Sakai, Japan

**Introduction:** Although peritoneal metastasis in colorectal cancer has been considered as a lethal disease, some reports documented that complete cytoreductive surgery improves prognosis of patients with peritoneal metastasis. However, the treatment strategies for colorectal cancer with diffuse metastasis to distant peritoneum are controversial.

**Material and Methods:** From 2001 to 2009, peritoneal metastasis with primary colorectal cancer was observed in 48 patients. Clinicopathological analyses were performed to evaluate the treatment and prognosis of these patients.

**Results:** Twenty-three males and 25 females were included. The median age was 63.4 years (range 22–93). Patients were divided into 3 groups, P1 (metastasis localized to adjacent peritoneum): 21 cases, P2 (limited metastasis to distant peritoneum): 10 cases, and P3 (diffuse metastasis to distant peritoneum): 17 cases according to Japanese Classification of Colorectal Carcinoma. Lung and/or Liver metastasis in addition to peritoneal metastasis was diagnosed in 10 (47.6%), 6 (60%), and 12 (70.5%) in P1, P2, and P3 respectively. In P1 and P2, the curability of surgical resection are CurB (no residual tumor) in 18 (58%), and CurC (macroscopic residual cancer) in 13 (42%). In P3, the resection of primary tumor was performed in 11 (64%). Chemotherapy with oxaliplatin (FOLFOX) or irinotecan-based (FOLFIRI) regimen were used in 5 (23.8%) in P1, 5 (50%) in P2, and 7 (41%) in P3 after surgical treatment. Median survival time was 23.1 months, 25.6 months, and 16.1 months in P1, P2, and P3 respectively. The overall survival (OS) in P1 and P2 was longer than that of P3 ( $P < 0.05$ ). Age, sex, and the distant metastasis did not affect the OS in each group. In P1 and P2, OS of CurB was longer than CurC ( $P = 0.005$ ). In P3, primary cancer resection improved their prognosis. The OS of cases treated with FOLFOX or FOLFIRI ( $n = 7$ ) was significantly longer than those without any chemotherapy ( $n = 4$ ) ( $P = 0.007$ ).

**Conclusion:** In P1 and P2, the prognosis could be improved by complete resection. Although the prognosis of P3 was poor, the combination therapy of primary tumor resection and treatment with FOLFOX or FOLFIRI regimen might improve their prognosis.

**Abstract ID: 0343** Specific Field: **Colon and Rectum**

**Mode of pres.: Poster Discussion**  
**ISW 2011 Session PW 04.06**

**Pathologically complete response of paraaortic lymph node metastases from sigmoid colon cancer treated with mFOLFOX6 plus bevacizumab: report of a case**

Y. Yoshioka [1], K. Uehara [1], F. Koide [1], S. Ishiguro [2], T. Igami [1], Y. Yokoyama [1], T. Ebata [1], M. Nagino [1]

[1] Division of Surgical Oncology, Department of Surgery, Nagoya University Graduate School of Medicine, Nagoya, Japan, [2] Aichi Cancer Center Hospital, Nagoya, Japan



**Introduction:** Surgical resection is generally accepted to be only a curable treatment for metastatic colorectal cancer, especially for liver or pulmonary lesion. Today, to increase the resection rate and to improve survival, aggressive surgical resection not only for resectable liver metastasis but also marginally resectable one have attempted with perioperative systemic chemotherapy with or without molecular target drugs. On the other hand, extrahepatic metastases, such as lymph node (LN) and peritoneal nodule, are indicated for resection only in limited cases. The safety and efficacy of such aggressive surgical treatment combined with systemic chemotherapy for extrahepatic metastasis has not been established yet.

**Material and Methods:** A 49-year-old male was admitted to our clinic in December 2009 because of constipation. He was diagnosed as having advanced sigmoid colon cancer with multiple paraaortic LN enlargement (cT4N2M1). The extent of the enlarged LNs was located in the paraaortic area below the renal vessels and in the left common iliac area. Although LN swelling was considered to be metastatic and curatively unresectable, stenosis of the primary lesion was severe. Thus, he underwent sigmoidectomy first and intraoperative frozen section confirmed paraaortic LN metastases. Histopathological findings showed poorly differentiated adenocarcinoma with massive lymphatic and venous invasion (pT4N2M1). Thereafter, biweekly mFOLFOX6 plus bevacizumab was started as 1st line chemotherapy. After 10 cycles of the treatment, CT showed that the remaining enlarged LNs were almost vanished and the serum carcinoembryonic antigen level became normalized. Six weeks after adding another cycle of treatment without bevacizumab, he underwent paraaortic LNs dissection in July 2010. Operative time was 421 min, and blood loss was 1,205 ml. Histologically, no cancer cells were detected in all resected specimens. Postoperative course was uneventful, and he has been well without recurrence for six months.

**Conclusion:** Bevacizumab-containing regimens may result in unexpectedly good response of tumor. Surgical resection is crucial for documentation of “pathologically” complete response. The combination of chemotherapy and aggressive surgery may offer better prognosis even for the patients with extrahepatic metastases from colorectal cancer.

**Abstract ID: 0344** Specific Field: **Colon and Rectum**

**Mode of pres.: Poster Discussion**  
**ISW 2011 Session PW 04.07**

**A case report of successful treatments in combination with chemotherapy and radical hepatectomy for ascending colon carcinoma with pulmonary and more than 40 hepatic metastases**

T. Ochiai, M. Iida, S. Yamazaki

Ohta Nishinouchi GeneralHospital, Kohriyama, Japan

**Introduction:** Colorectal cancer is a prevalent disease and it has been reported that 20–25% of patients with colorectal cancer present hepatic metastases at the time of diagnosis. Recently, a regimen consisting of 5-fluorouracil/leucovorin, oxaliplatin plus bevacizumab (FOLFOX-BV) is widely used in Japan as the first-line treatment of metastatic colorectal cancer and it improves overall survival of initially unresectable patients by allowing tumor downstaging and complete resection. Here we report a successful treatment case of ascending colon carcinoma with 43 hepatic metastases and 2 lung metastasis.

**Results:** Case presentation: A 64-year-old man was admitted to our hospital for anemia. Examinations revealed ascending colon carcinoma with multiple liver and lung metastases, therefore, right colectomy with lymph nodes dissection was performed followed by

postoperative FOLFOX-BV. After 4 courses of chemotherapy, lung metastases disappeared completely and liver metastases were stable. We proposed radical hepatectomy to the patient, but he rejected at that time, because he did not suffer from any side effects of FOLFOX-BV. After administration of 23 courses, he decided to receive hepatectomy. Extended right lobectomy and partial left and caudal lobe resection were performed. All of the macroscopic metastatic lesions were resected. Histopathologically, viable cancer cells were recognized in 7 out of 43 liver metastatic lesions. Postoperatively FOLFOX-BV restarted and the patient is doing well 10 months after hepatectomy without recurrence of cancer.

**Conclusion:** Discussion: With recent advances of chemotherapy for colorectal cancer, the indication of colorectal cancer surgery has expanded and the survival period of the patient with inoperable metastases have prolonged. Radical surgery and aggressive chemotherapy leads to prolongation of the survival periods.

**Abstract ID: 0345** Specific Field: **Colon and Rectum**

**Mode of pres.: Poster Discussion**  
**ISW 2011 Session PW 05.01**

**Endoscopic decompression using a transanal colorectal tube for acute obstruction of the rectum and left colon as a bridge to curative surgery**

A. Matsunaga, H. Hasegawa, Y. Ishii, T. Endo, H. Ochiai, H. Hoshino, Y. Hoshino, Y. Kitagawa

Keio University School of Medicine, Tokyo, Japan

**Introduction:** Acute colorectal obstruction is a potentially life-threatening emergency that requires immediate surgical treatment. Various methods for performing one stage surgery operation have been reported including decompression with self-expanding metallic stents, and transanal colorectal tube decompression. But metallic stents placement was complicated by perforation, stent migration, bleeding, reobstruction, and increasing cost. The aim of this study was to clarify the usefulness of the management of acute colorectal cancer obstruction by using a transanal colorectal tube.

**Material and Methods:** Endoscopic transanal colorectal tube was inserted into the colon proximal to the tumor under the guidance of the guide wire. 34 patients (20 males and 14 females, aged 50–91 years, median age: 67) treated between August 1996 and April 2010 for acute obstructing cancer were analyzed.

**Results:** Tube placement was successful in 32 (94%) of the 34 patients. Perforation occurred in 3 patients, one patient of unsuccessful tube placement underwent emergent operation, and 2 other patients who developed penetration after a few days of successful tube placement underwent elective operation. The site of obstruction was the rectum in 14 patients, the sigmoid colon in 17, the descending colon in 2, and the transverse colon in 1. The histological stage was as follows: II; 7, III; 14, IV; 7. Following adequate decompression of the colon, 33 patients underwent one-stage surgery after 14 days (range: 5–26 days), primary resection and anastomosis in 21 patients, Hartmann’s procedure in 2, abdominoperineal resection in 1, colostomy in 8, inserting stent in 1. 10 patients developed postoperative complications including wound infection in 8 patients, small bowel obstruction in one patient. No anastomotic leakage occurred after operation. Postoperative recurrences were seen in 6 patients (carcinomatosis; 2, liver; 2, lung; 1, lymph node; 1). The five-year disease-free survival rate was 74%.

**Conclusion:** Transanal colorectal tube was effective for the treatment of acute colonic obstruction. Emergency surgery can be converted to elective surgery, therefore, this was considered as a bridged method before surgery.



**Abstract ID: 0346** Specific Field: **Colon and Rectum**

**Mode of pres.: Poster Discussion**  
**ISW 2011 Session PW 05.02**

**Treatment of obstructing colorectal cancer: our results of treatment by colonoscopic retrograde bowel drainage (CRBD)**

K. Kishine, T. Ochiai, M. Kitajima, A. Nakatani, T. Hashiguchi, T. Watanabe, K. Nishimura, S. Hutagawa

Tobu Chiiki Hospital, Tokyo Metropolitan Health and Medical Treatment Corporation, Tokyo, Japan

**Introduction:** The results obtained at our hospital with endoanal intestinal decompression for obstructing colorectal cancer were reviewed.

**Material and Methods:** During the period from October 1992 to December 2010, 86 patients (mean age: 69.2 years) underwent colonoscopic retrograde bowel drainage (CRBD) and all of them had advanced cancer classified as Dukes B to D.

**Results:** In 70 patients (81%), a CRBD tube was successfully inserted. Of these patients, one underwent emergency surgery because of poor decompression. The CRBD tube achieved decompression in the other 69 patients and surgery was performed in 54 of them (43 had one-stage radical surgery and 11 received a colostomy). The remaining 15 patients could not undergo surgery because of advanced age or poor general condition, but 5 of them could be followed up on an outpatient basis after insertion of a stent. When the postoperative survival rate of the 54 decompressed patients who underwent surgery was compared with that of patients with nonobstructing colorectal cancer treated during a similar period, no significant difference was noted between the obstructing cancer group (22 Dukes B and 17 Dukes C) and the nonobstructing cancer group, regardless of the stage of cancer. Fifteen of the 16 patients in who insertion of a CRBD tube failed underwent emergency surgery (colostomy in 11 patients) and the remaining one was treated with a transnasal ileus tube.

**Conclusion:** If application of CRBD to colorectal cancer causing intestinal obstruction achieves successful decompression of the bowel preoperatively, safer one-stage surgery becomes possible along with improvement of the general condition. In inoperable patients, if decompression can be followed by the insertion of a stent, their quality of life can be improved. These approaches provide more options for the treatment of obstructing colorectal cancer.

**Abstract ID: 0347** Specific Field: **Colon and Rectum**

**Mode of pres.: Poster Discussion**  
**ISW 2011 Session PW 05.03**

**Usefulness of the trans-anal drainage tube for obstructive left-side colorectal cancer**

R. Makizumi [1], N. Miyajima [2], H. Hoshino [1], K. Miura [1], H. Katagiri [1], T. Shimamura [1], S. Tsukikawa [1], T. Otsubo [1]

[1] St. Marianna University School of Medicine, Kawasaki, Japan,  
 [2] St. Marianna University School of Medicine Toyoko Hospital, Kawasaki, Japan

**Introduction:** Acute malignant colorectal obstruction is an oncologic emergency, and require decompression of bowel distension before surgery for colorectal cancer. We report usefulness of the trans-anal drainage tube for obstructive left-side colorectal cancer.

**Material and Methods:** Subjects consisted of 18 cases with obstructive left-side colorectal cancer who underwent operation in our hospital between 2006 and 2010. The 18 cases consisted of 9 men and

9 women from 51 to 86 years of age, with an average age of 70.3 years. Trans-anal drainage tube was inserted for decompression of bowel distension by using colonic endoscope under the X-ray fluoroscope. After decompression with the trans-anal drainage tube, radical operation for colorectal cancer was performed.

**Results:** Placement of the drainage tube was successful in 11 (70.6%) of 17 cases. In 6 cases of unsuccessful placement of the drainage tube, an emergency operation was selected. Only naso-gastric long tube was inserted in one case. In one case of successful placement group, an emergency surgery was required because decompression of the bowel was insufficient. The postoperative hospitalization period is 16.1 days of successful group of placement the drainage tube, and 23 days of unsuccessful group of placement the drainage tube. There was no significant difference in both groups. We performed one stage operation for 11 cases, laparoscopic surgery of 7 cases and open surgery of 4 cases.

**Conclusion:** Decompression using the trans-anal drainage tube is useful for avoiding an emergency operation and allows a safe one-stage operation. And this therapy makes it possible to perform the laparoscopic surgery for obstructive left-side colorectal cancer, because of reduce the bowel distension.

**Abstract ID: 0348** Specific Field: **Colon and Rectum**

**Mode of pres.: Poster Discussion**  
**ISW 2011 Session PW 05.04**

**Results of treatments for obstructive colorectal cancer**

K. Matsuda, S. Ishihara, T. Watanabe

Teikyo University, Tokyo, Japan

**Introduction:** There have been several methods of treatments for obstructive colorectal cancer. Emergency surgery, ileus tube and transanal ileus tube are thought to be main treatments, but each has merits and demerits. In the present study we study the results of treatments for obstructive colorectal cancer and we want to clarify problems of them.

**Material and Methods:** The number of ileus cases treated in our department of the hospital since 2003 was 246. Among them, we studied 50 cases of obstructive colorectal cancer.

**Results:** As for treatment, cases of only ileus tube without transanal ileus tube were 15, that is to say, group I. Cases of transanal ileus tube were 7, which are group TA. Cases of no tube were 28, which are group N. In group I, two cases underwent no surgery, and 10 out of 13 (77%) underwent creation of stoma. In group TA, 2 out of 7 (29%) underwent creation of stoma. In group N, 93% of cases underwent creation of stoma, and most of them needed emergency surgery. In group I, all cases where the period between insertion of ileus tube and surgery was shorter than 2 weeks underwent creation of stoma, 50% of cases where it was 2–4 weeks did, and no cases where it was over 4 weeks did. Cases of death were 5, and 4 of them died of cancer. Two cases died of cancer with insertion of ileus tube and no opportunity of surgery, the other two died with insertion of ileus tube and only creation of stoma. As for the remainder, 82-years-old man was hospitalized for obstructive rectal cancer, treated by both ileus tube and transanal ileus tube, and underwent Hartmann's operation after 17 days fasting. But he died of pneumonia 11 days after surgery.

**Conclusion:** The transanal ileus tube has a merit and demerits, and the former is that the frequency of avoidance of stoma creation is high. But demerits are that patients cannot eat meals, that to improve the nutrition disorder is difficult, and that to investigate colon before surgery is hard. It is speculated that we might consider emergent surgery of stoma creation not adhering to trans anal ileus tube treatment when the patient of obstructive colorectal cancer is old and shows malnutrition.

**Abstract ID: 0349** Specific Field: **Colon and Rectum**

**Mode of pres.: Poster Discussion**  
**ISW 2011 Session PW 05.05**

**The efficacy of intraoperative colonoscopy in surgical resections of Sigmoid colon and rectum**

T. Enomoto, Y. Saida, K. Takabayashi, A. Otsuji, K. Dotai, Y. Nakamura, J. Nagao, S. Kusachi

Toho University Ohashi Medical Center, Tokyo, Japan

**Introduction:** In surgical resections of colon and rectum, preventive measures of postoperative complications are crucial for patients' QOL. To minimize possible postoperative complications associated with anastomosis, we have performed intraoperative colonoscopy for the resections of left colon and rectum.

**Material and Methods:** From January 2006 to December 2010, we performed intraoperative colonoscopy on 259 patients with sigmoidectomy or anterior resection out of total 379 such cases.

**Results:** Intraoperatively, abnormal colonoscopic findings were observed in 7 cases (2.7%) of total 259 cases. In 3 cases, disconnection and color changes of mucosa of anastomotic site were observed; 2 cases were determined to perform stoma creation; postoperatively, 2 cases developed anastomotic leak, which were managed conservatively. In one case, anastomotic haemorrhage was observed, which was intraoperatively controlled by vessel clip; there was no postoperative haemorrhage. In 3 cases, air leak test yielded positive results; reanastomosis was applied to one case; stoma creation was applied to 2 cases; though one postoperative anastomotic leak was observed, it was successfully managed conservatively. On the other hand, despite no intraoperative abnormal colonoscopic findings, 15 anastomotic leaks were found post-operatively.

**Conclusion:** In cases that abnormal colonoscopic finding were obtained intraoperatively, additional resection and/or stoma creation are required because of high risk of postoperative anastomotic leak. Intraoperative colonoscopy has been feasible to obtain abnormal colonoscopic findings to eliminate the risks of postoperative severe conditions. However, there have been some cases of postoperative anastomotic leak despite no intraoperative abnormal colonoscopic finding. Therefore, further study is needed to determine the way to prevent postoperative complications.

**Abstract ID: 0350** Specific Field: **Colon and Rectum**

**Mode of pres.: Poster Discussion**  
**ISW 2011 Session PW 05.06**

**Lymphatic invasion may predict lympho node metastasis in patients with T1 rectal cancer**

H. Hoshino, H. Hasegawa, Y. Ishii, T. Endo, H. Ochiai, Y. Hoshino, A. Matsunaga, Y. Kitagawa

Keio University, Tokyo, Japan

**Introduction:** Local excision including transanal endoscopic micro surgery (TEM) and endoscopic mucosal resection (EMR) is widely performed in patients with T1 rectal cancer. However, about 10% of T1 rectal cancer involves lymph node (LN) metastasis, and the radical resection is also performed for patients with several risk factors for LN metastasis.

**Material and Methods:** The purpose of this study was to evaluate the risk factors of lymph node metastasis in patients with T1 rectal cancer. A retrospective review was performed on 107 patients undergoing radical resection for T1 rectal cancer between January 1990 and March 2010. The following clinicopathologic variables were evaluated using univariate and multivariate analysis; sex, age, location, size of tumor, macroscopic

**Table 1** Clinico-pathological features of patients with LN metastasis

	Age	Sex	Site distribution	sm	Differentiation	ly	v	Local excision
1	55	M	Middle rectum	2	Mod	-	-	-
2	58	M	Upper rectum	2	Well	-	-	+
3	67	F	Lower rectum	1	well	+	-	-
4	50	M	Middle rectum	2	Well	+	-	+
5	55	F	Middle rectum	3	Well	+	-	-
6	47	F	Middle rectum	3	Mod	+	+	-
7	74	F	Upper rectum	3	Mod	+	-	-
8	38	M	Lower rectum	3	Mod	+	+	+

appearance, depth of submucosal invasion, lymphovascular invasion, and histologic grade. Lesions were subdivided according to the depth of submucosal invasion: sm1, submucosal invasion up to 500 micrometer from the muscularis mucosa; sm2, submucosal invasion between 500 and 1000 micrometer; sm3, submucosal invasion beyond 1,000 micrometer.

**Results:** The overall lymph node metastasis was observed in 8 patients (8.3%). Univariate and multivariate analysis showed that presence of lymphatic invasion was a significant risk factor. The clinicopathological findings of patients with lymph node metastasis is shown in Table 1.

**Conclusion:** The findings of the current study demonstrated that the significant risk factor for lymph node metastasis was the presence of lymphatic invasion. Surgery is indicated for patients with adverse factor.

**Abstract ID: 0351** Specific Field: **Colon and Rectum**

**Mode of pres.: Poster Discussion**  
**ISW 2011 Session PW 05.07**

**Clinical utility of preoperative computed tomography for the diagnosis of lymph node metastasis in patients with colorectal cancer**

Y. Hirano, M. Hattori, M. Fujita, H. Kitamura, K. Maeda, K. Douden, Y. Hashizume

Fukui Prefectural Hospital, Fukui, Japan

**Introduction:** In JSCCR Guidelines 2010 for the Treatment of Colorectal Cancer, the extent of lymph node dissection should be decided from the pre- or intra-operative findings of the lymph node or the depth of the tumor invasion. Intra-operative diagnoses of lymph node metastasis, however, tend to be subjective and effected by the surgeon's experiences. The aim of this study was to assess the clinical utility of preoperative computed tomography (CT) for the diagnosis of lymph node metastasis in patients with colorectal cancer.

**Material and Methods:** From December 2009 to November 2010 we performed elective 120 colorectal resections in 74 men and 46 women with a mean age of 68.1 years (range 34–93). Of the 120 cases of colorectal resections, 27 patients underwent right colectomy, 6 underwent partial resection of the transverse colon, 8 underwent left colectomy, 34 underwent sigmoidectomy, 41 underwent anterior resection of the rectum and 4 underwent abdomino-perineal resection of the rectum. Preoperative CT was performed for the diagnosis of lymph node metastasis, and metastatic lymph nodes were considered to be present if their diameter exceeded 5 mm. The diagnostic accuracy of CT for lymph node metastasis was assessed using histopathologic findings.

**Results:** All patients tolerated CT examinations without any complications. The overall accuracy of CT was 69.2%. The sensitivity,

specificity, positive predictive value (PPV), and negative predictive value (NPV) were calculated as 69.2, 72.9, 66.7, 59.3, and 78.7%, respectively. In the tumors located at the right colon, the sensitivity, specificity, PPV, and NPV were calculated as 78.8, 80.0, 77.8, 75.0, and 82.4%, respectively, and 65.5, 69.7, 63.0, 58.8, and 77.3%, respectively, in the tumors located at the left colon and rectum. In the cases of advanced cancer, the specificity and PPV were calculated as 52.9 and 36.8% in the sigmoid colon and 50.0 and 52.0% in the rectum. The NPV in advanced right colon cancer was 50.0%.

**Conclusion:** In the diagnosis of lymph node metastasis only with preoperative CT, there were not small numbers of false positive and negative lymph nodes. In the time to decide the extent of lymph node dissection, we should decide systematically including intra operative findings or the finding of the other modalities added with the CT.

**Abstract ID: 0352** Specific Field: **Colon and Rectum**

**Mode of pres.: Poster Discussion**  
**ISW 2011 Session PW 06.01**

**Both radical open and laparoscopic colon cancer surgery showed superior oncologic outcome compared with a historical conventional method**

K. Storli [1], B. Furnes [1], K. Søndena [2]

[1] Haraldsplass Deaconal Hospital, Bergen, Norway, [2] University of Bergen, Bergen, Norway

**Introduction:** From 2007, more radical surgery for colon cancer (CC) was introduced in our Department to improve outcome. We analyzed the short-term result with regard to 3-year disease-free survival (DFS).

**Material and Methods:** CC was resected in 235 patients between 2007 and 2009, 126 males (53.6%), with a mean age of 72-years. Of these, 60.4% (142/235) had TNM stage I-II disease, 27.7% (65/235) stage III, and 11.9% (28/235) stage IV. The open approach was used in 111 patients (47.2%) and a laparoscopic procedure in 80 (34%), while 44 patients (18.7%), had a modified open procedure (D2). CT was introduced as a routine screening and surveillance method at the same time. Follow-up was systematic with 6 months intervals, median 30 months (12–48).

**Results:** Postoperative mortality was 3.4% (8/235). Locoregional recurrences or distant metastases occurred in 14.9% (30/201) of TNM stages I–III patients. Forty-nine patients (20.9%) have died, 8.1% from other causes and 12.8% from CC. 1.4% (2/142) of patients with stage II, and 18.5% (12/65) with stage III have died from CC. DFS for stages I–II has been 91.9% and for stage III 67.7%, the corresponding OS 98.6% and 81.5%. Of stage IV patients 42.9% (12/28) are alive. Thus, OS has been 79.1% (186/235). OS for the open and laparoscopic methods were identical.

**Conclusion:** Radical surgery was introduced from 2007 with an improved OS of 79.1% compared to the conventional approach from 2000 that resulted in 58% OS. The open and laparoscopic methods achieved equal results in the new program.

**Abstract ID: 0353** Specific Field: **Colon and Rectum**

**Mode of pres.: Poster Discussion**  
**ISW 2011 Session PW 06.02**

**Comparison wound bacterial contamination between open and laparoscopic surgery for colorectal cancer patients**

Y. Saida, T. Enomoto, K. Takabayashi, A. Otsuji, K. Dotai, Y. Nakamura, J. Nagao, S. Kusachi

Toho University Ohashi Medical Center, Tokyo, Japan

**Introduction:** Purpose: Many investigators reported the advantage of laparoscopic colorectal surgery for prevention of surgical site infection (SSI). To compare wound bacterial contamination between open colorectal surgery (OC) and laparoscopic colorectal surgery (LC).

**Material and Methods:** Method: Colorectal cancer surgery with no association of ileus was evaluated between 22 OC cases and 19 LC cases. Preoperatively, only mechanical preparation was applied. And second generation cephalosporins were administered right before the operation. Soon after the surgery, wound irrigation was performed utilizing 500 ml warm saline. Subsequently, 10 ml saline was irrigated and extracted to determine viable count. The count below 20 CFU/ml was determined to be “undetected”.

**Results:** Backgrounds were similar between two groups. The bacterial detection rate before irrigation was 5/22 cases (23%) in OC and 6/19 cases (32%) in LC; no difference was found in detection rate. In addition, the rate after irrigation with 500 ml warm saline was 2/22 cases (9%) in OC and 1/19 cases (5%) in LC; no difference. In open group, detected bacteria were aerobic *Bacillus* sp., anaerobic bacteroides and anaerobic gram-positive *Bacillus* that was detected even after the irrigation. In LC, detected bacteria were aerobic *Enterococcus* and anaerobic gram-positive *Bacillus* that was detected even after the irrigation. Clinically, one wound infection was found in OC comparing to no wound infection in LC. Each group has one case of intraabdominal abscess.

**Conclusion:** Conclusion: In colorectal cancer surgery, LC demonstrated high incidence of wound contamination than OC, but LC seems to have advantage in wound infection. Some immunological advantage in LC suggested for prevention of surgical site infection (SSI). In this study, however, wound irrigation after both open and laparoscopic surgery proved higher effectiveness.

**Abstract ID: 0354** Specific Field: **Colon and Rectum**

**Mode of pres.: Poster Discussion**  
**ISW 2011 Session PW 06.03**

**Prognostic values of the number and the size of venous invasion in colorectal cancer: a prospective study**

E. Shinto, H. Ueno, Y. Hashiguchi, H. Tsuda, O. Matsubara, H. Mochizuki, J. Yamamoto, K. Hase

National Defense Medical College, Tokorozawa, Japan

**Introduction:** According to the AJCC staging system, the grade of venous invasion in colorectal cancer is classified into following 3 categories: V0, No venous invasion; V1, Microscopic venous invasion; and V2, Macroscopic venous invasion. On the other hand, it is classified in the Japanese classification of colorectal carcinoma as follows: v0, No invasion; v1, Minimal invasion; v2, Moderate invasion; v3, Severe invasion. In the present study, we used slides with elastica staining and investigated prognostic values of the number and the size of venous invasion prospectively.

**Material and Methods:** One hundred and twenty-nine pT3 colorectal carcinomas resected between 2001 and 2003 were judged to be positive for vessel invasion from pathological examination on two or three sections which include the invasive front of cancer, stained by Elastica van Gieson staining. The findings were classified according to the number of veins with carcinoma infiltration in the slide where the most frequent venous invasions were observed (V-number classification): V1, 1–3; V2, 4 or more venous vessels involved by carcinoma cells. Additionally, the findings were classified according to the maximal size of veins with carcinoma infiltration (V-size classification): V1, <1 mm; V2, 1 mm or over. The grades of venous invasion were evaluated just after surgical operations. In order to examine the prognostic significance of these classifications, comparisons of long-term outcome between two groups were performed.

**Results:** Comparisons between disease-specific survival curves revealed that V-number classification (V1 and V2, 5-year survivals of



89.8 and 71.4%, respectively;  $P = 0.0009$ ) has a significant prognostic value. However, V-size classification failed to show significance (V1 and V2, 5-year survivals of 85.0 and 81.6%, respectively; N.S.). A prognostic value of V-number classification was further evaluated by multivariate analysis, using distant metastasis and node metastasis as variables, which disclosed that distant metastasis (HR 6.0,  $P = 0.00002$ ) and V-number classification (HR 2.6,  $P = 0.039$ ) were independent prognostic indicators.

**Conclusion:** V-number classification is a prognostically useful subgrouping system for patients with venous invasion-positive pT3 colorectal cancer.

**Abstract ID: 0355** Specific Field: **Colon and Rectum**

**Mode of pres.: Poster Discussion**  
**ISW 2011 Session PW 06.04**

#### A study on patients under 40 years old with colorectal cancer

H. Katagiri [1], N. Miyajima [2], T. Matsumori [1], K. Miura [1], T. Shimamura [1], R. Makizumi [1], S. Tsukikawa [1], T. Otsubo [1]

[1] St. Marianna University School of Medicine, Kawasaki, Japan,  
[2] St. Marianna University School of Medicine Toyoko Hospital, Kawasaki, Japan

**Introduction:** Recently, cases with colorectal cancer of young patients have been increasing. We accumulated the cases of colorectal cancer under 40 years old and studied the characteristics and clinicopathological features.

**Material and Methods:** Between 2006 and 2010, we experienced 794 cases with colorectal cancer. We extracted 7 cases under 40 years old (0.88%). Ulcerative colitis was associated in one case and previous history of descending colon cancer in one case.

**Results:** Cases with colorectal cancer under 40 years old consisted of 2 cases (28.5%) in male and 5 cases (71.5%) in female. Mean age of them was 31.9 years (21–39 years old). Chief complaint of them was melena in 4 cases, diarrhea in one case, abdominal pain in one case, and no symptoms with increase of CEA in one case. Location of the tumor was ascending colon in one case, descending colon in one case, sigmoid colon in 2 cases, rectosigmoid colon in 2 cases, upper rectum in one case, and lower rectum in one case. Two cases underwent laparoscopic surgery and 5 cases underwent conventional open surgery. Histopathologically, well differentiated adenocarcinoma was seen in one case, moderately differentiated adenocarcinoma in 5 cases, and adenomatous carcinoma in one case. According to TMN classification, one case was stage I, one case was stage IIA, 2 cases were stage IIIA, 2 cases were stage IIIB, and one case was stage IV.

**Conclusion:** In our study, female patients had a majority. Stage III and stage IV cases were seen in more than half of the patients. These results were consistent with the previous reports. To get the better prognosis for younger patients, a radical operation with secure lymphadenectomy and aggressive follow up are necessary.

**Abstract ID: 0356** Specific Field: **Colon and Rectum**

**Mode of pres.: Poster Discussion**  
**ISW 2011 Session PW 06.05**

#### Suture-free anastomosis of the colon: experimental comparison of two cyanoacrylate adhesives

J. Paral [1], Z. Subrt [1], P. Lochman [1], L. Klein [1], D. Hadzi-Nikolov [2], Z. Turek [3], M. Vejbera [3]

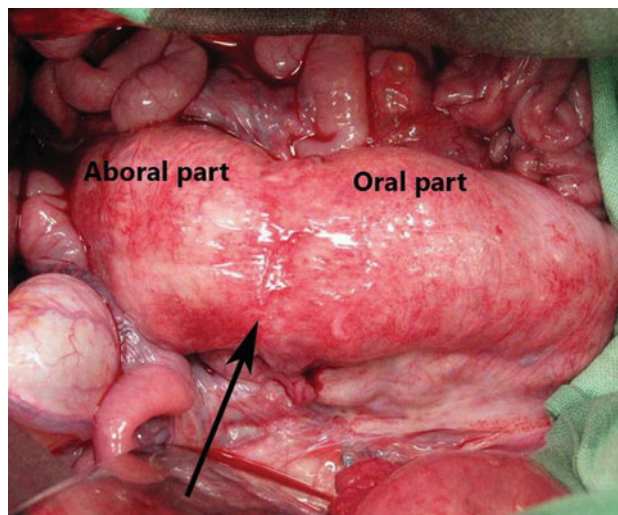
[1] Faculty of Military Health Sciences, Hradec Kralove, Czech Republic, [2] Department of Pathology, University Hospital, Hradec Kralove, Czech Republic, [3] Department of Anesthesiology, University Hospital, Hradec Kralove, Czech Republic

**Introduction:** We explored the potential of two cyanoacrylate tissue adhesives for constructing colonic anastomoses.

**Material and Methods:** The study involved 12 female domestic pigs. The animals were divided into two equal groups. In both group the sigmoid colon was transected. An intestinal anastomosis was constructed with a modified circular stapler (all staples were withdrawn) and cyanoacrylate tissue adhesives. Glubran 2<sup>®</sup> was used in Group A and Dermabond<sup>®</sup> was applied in Group B. Fourteen days after the first operation a follow-up surgery was performed in both groups. The glued section of the colon was resected, processed with the standard paraffin technique and stained with hematoxylin-eosin. The finished specimens were examined under light microscopy. Assessments were made for the presence of fibroblasts, neutrophils, giant polynuclear cells, neovascularisation and collagen deposits. Adhesions, anastomotic dehiscence, perianastomotic inflammation, and intestinal healing were assessed perioperatively.

**Results:** All anastomoses in Group A healed with no signs of pathology. In Group B fibrotic adhesions and stenoses tended to occur in areas surrounding the anastomoses. Histological examinations confirmed increased fibrosis.

**Conclusion:** The tissue adhesive Glubran 2 appears to be (under experimental conditions) the promising synthetic adhesive for colonic anastomosis construction; conversely the tissue adhesive Dermabond was unsuitable for suture-free anastomosis construction.



**Figure:** Healed anastomosis two weeks after it was glued with Glubran 2. The arrow shows the anastomosis

**Abstract ID: 0357** Specific Field: **Colon and Rectum**

**Mode of pres.: Poster Discussion**  
**ISW 2011 Session PW 06.06**

#### The impact of statins on recovery after elective colectomy

P.P. Singh, S. Srinivasa, A.A. Kahokehr, K. Zargar-Shoshtari, D.P. Lemanu, A.G. Hill

University of Auckland, Auckland, New Zealand



**Introduction:** Statins possess numerous surgically-relevant beneficial properties such as reducing peritoneal inflammation and attenuating proinflammatory cytokine release. Thus statins can potentially improve postoperative recovery. This has not been previously investigated in the context of elective colectomy.

**Material and Methods:** A retrospective review of prospectively collected data was conducted for all patients undergoing elective colonic resection within an Enhanced Recovery After Surgery programme at our institution from 2006 to 2010. Demographic characteristics and clinical outcomes were evaluated. Post-operative functional recovery was calculated using the validated Surgical Recovery Score and measured pre-operatively (baseline) and on post-operative day 3, 7, and 30. Serum cytokines—interleukin-6 (IL-6), interleukin-8 (IL-8), interleukin-10 (IL-10) and tumour necrosis factor alpha (TNF- $\alpha$ )—were measured on post-operative day one. Length of hospital stay was evaluated and thirty-day complications were recorded and graded as per the Clavien-Dindo classification.

**Results:** There were 134 patients in the final analysis with 43 patients on a statin (S) perioperatively, whilst 91 patients had no statin (NS). The statin group had significantly more males (S: 27 (63%); NS: 37 (41%);  $P = 0.03$ ) and a higher number of patients with an ASA score of 3 (S: 19 (44%); NS: 21 (23%);  $P = 0.02$ ). There were no significant differences in surgical recovery scores measured at baseline or post-operatively on day 3, 7, and 30. Serum cytokine levels were not significantly different between the two groups. There was no significant difference in total complications and complication grades between the two groups and the median length of stay was similar.

**Conclusion:** Patients on perioperative statins had greater baseline perioperative risks compared to non-users but achieved equivalent outcomes. Thus, perioperative statin use may aid recovery after elective colectomy and this warrants further investigation.

#### Abstract ID: 0358 Specific Field: Colon and Rectum

**Mode of pres.: Poster Discussion**  
**ISW 2011 Session PW 06.07**

##### Our device of management of stoma

N. Ogura, M. Watanabe

Department of Surgery Kitasato University, Sagami, Japan

**Introduction:** There is not a constant determination of indication or procedure or management for colostomy and ileostomy. In each medical facilities, the various devices have been performed. We report the management and device for colostomy and ileostomy.

**Material and Methods:** We evaluated the number of 734 cases who underwent colostomy and/or ileostomy between January 2001 and December 2010. These cases were divided into two groups and we compared the two groups; The early group (they were underwent colostomy and/or ileostomy between January 2001 and December 2005:  $n = 386$  cases) and the late group (they were underwent colostomy and/or ileostomy between January 2006 and December 2010:  $n = 348$  cases).

**Results:** In late group, ileostomy has performed more than colostomy. The reason would be considered that we changed the policies of colorectal cancer therapy from December 2005.; introduction of new chemotherapy and chemoradiotherapy and improvement of surgical technique were related matters. As device of the management of stoma, we educated patients who underwent colostomy and/or ileostomy before operation. It has contributed to patient's acceptance of stoma and improvement of stoma care post operation. Technically, we introduced laparoscopic surgery for colostomy and ileostomy from 2008 and performed safely and certainly.

**Conclusion:** Most patients were satisfied with our management of stoma.

#### Abstract ID: 0359 Specific Field: Colon and Rectum

**Mode of pres.: Poster Discussion**  
**ISW 2011 Session PW 07.01**

##### Colonic inertia has no adverse impact on the short-term functional results of laparoscopic anterior rectopexy for internal rectal prolapse causing obstructed defaecation

A.N. Ashrafi, I. Lindsey

The University of Oxford, Oxford, Australia

**Introduction:** Colonic inertia (CI) may co-exist with obstructed defaecation (OD). It is unclear if it adversely influences the results of surgery for OD. We aimed to compare the functional results of laparoscopic anterior rectopexy (LAR) for OD secondary to high-grade internal rectal prolapse (IRP) in those with normal colonic transit (NCT) and CI.

**Material and Methods:** Patients with high-grade (recto-anal) IRP were evaluated with defaecating proctography and colonic transit study. Colonic transit time (CTT) (hours) was calculated by the number of pellets remaining in the colon and rectum at 7 days  $\times$  2.4. Patients were offered surgery for significant symptoms if they failed a program of conservative management. Constipation was prospectively assessed pre-op and at 3 months using Wexner constipation scores.

**Results:** 80 patients (93% female) underwent LAR for OD and IRP. Patients with NCT gave less history of stool infrequency currently (10 versus 32%) and in their 20's (17% versus 71%). 61 patients had normal colonic transit (CTT median 17, range 0–48 hours) and 19 had CI (CTT median 79, range 50–154 hours,  $P$ ).

**Conclusion:** In the short term, colonic inertia has no adverse impact and may be disregarded when considering laparoscopic anterior rectopexy for obstructed defaecation and high-grade internal rectal prolapse.

#### Abstract ID: 0360 Specific Field: Colon and Rectum

**Mode of pres.: Poster Discussion**  
**ISW 2011 Session PW 07.02**

##### Laparoscopic suture rectopexy for complete rectal prolapse

Y. Shindo, S. Hazama, Y. Inoue, N. Hashimoto, H. Nakatsu, N. Suzuki, K. Yoshimura, M. Oka

Department of Digestive Surgery and Surgical Oncology, Yamaguchi University Graduate School of Medicine, Ube, Japan

**Introduction:** Rectal prolapse is a uncommon disease mainly seen in aged patients. Although there are a variety of surgical approaches for rectal prolapse such as abdominal or perineal procedures, we report our clinical results of laparoscopic rectopexy for complete rectal prolapse.

**Material and Methods:** Between February 2001 and June 2010, 14 patients (12 females) diagnosed as complete rectal prolapse were treated by rectopexy. The median age was 69 years, and range 30–89 years. First 3 patients underwent abdominal posterior mesh rectopexy. The other 11 patients underwent suture rectopexy. One patient

underwent open procedures because she had previously undergone rectal surgery. Ten patients had laparoscopic procedures. To evaluate surgical stress, WBC (POD 1) and CRP (1 POD) were evaluated. The rectosigmoid junction is retracted to the left and a peritoneal incision is made over the right side of the sacral promontory and extended along the rectum and over the deepest part of the pouch of Douglas. An incision is made in the peritoneal reflection close to the lateral wall of the bowel. The peritoneum is incised down to cul-de-sac on the left side. It is important that paramesorectal peritoneal incision is wide. The retrorectal space is opened down to puborectal muscle. Hypogastric nerves are identified and preserved. Denonvillier's fascia is incised and the rectovaginal septum is broadly opened. Rectum is pulled up and redundant paramesorectal peritoneum is directly stapled on presacral fascia (S1, S2) using helical stapler to fix rectum.

**Results:** No patients had recurrent prolapse. One patient treated by abdominal posterior mesh rectopexy had transient ileus. No patients became fecal incontinent after surgery. WBC (POD 1) and CRP (POD 1) of laparoscopic procedures was lower value than laparotomy ( $P < 0.05$ ).

**Conclusion:** Laparoscopic rectopexy is safe and less invasive in aged patients. There were no recurrences. This procedure may become the standard procedure for complete rectal prolapse.

#### Abstract ID: 0361 Specific Field: Colon and Rectum

**Mode of pres.: Poster Discussion**  
ISW 2011 Session PW 07.03

##### Effects of less invasive treatments including sclerotherapy with alta and pph for prolapsing internal hemorrhoids: comparison with hemorrhoidectomy

Y. Tokunaga, H. Sasaki, T. Saitou

Osaka North Japan Post Hospital, Osaka, Japan

**Introduction:** For prolapsing internal hemorrhoids, less invasive treatments such as sclerotherapy using aluminum potassium sulphate/tannic acid (ALTA), and procedure for prolapse and hemorrhoids (PPH) have been introduced recently. We compared the results of ALTA and PPH with conventional hemorrhoidectomy.

**Material and Methods:** Between January 2006 and December 2008, we performed conventional hemorrhoidectomy in 440 patients, ALTA in 863 patients, and PPH in 133 patients with second- and third-degree internal hemorrhoids according to the Goligher's classification.

**Results:** The operation duration was significantly longer ( $P < 0.01$ ) in hemorrhoidectomy ( $43 \pm 5$  min) (mean  $\pm$  SD) than in ALTA ( $13 \pm 2$  min). Volume of ALTA injected into a hemorrhoid was  $7.3 \pm 2.1$  ml. Post operative pain, which needed intravenous injection of pain killer, occurred in 62 cases (14%) in hemorrhoidectomy and 15 cases (1.7%) in ALTA ( $P < 0.01$ ). ALTA could be performed on an outpatient basis without any severe complication such as abscess, ulcer, and stenosis. Hospital stays were  $6.7 \pm 2.0$  days for hemorrhoidectomy, and  $4.1 \pm 1.5$  days for PPH. The disappearance rates of prolapse were 100% in hemorrhoidectomy, 96% in ALTA, and 98.6% in PPH respectively.

**Conclusion:** Conventional hemorrhoidectomy would be indicated for almost all cases of prolapsing internal hemorrhoids. However, it needs hospitalization, being accompanied with post-operative pain. ALTA is feasible on outpatient bases without any severe pain or complication. PPH is a useful alternative treatment with shorter period of hospitalization and less pain compared to hemorrhoidectomy. Less invasive treatments would be useful, when performed in appropriate cases, paying attention to avoid complications.

#### Abstract ID: 0362 Specific Field: Colon and Rectum

**Mode of pres.: Poster Discussion**  
ISW 2011 Session PW 07.04

##### Perforation at the blind end of ileal J-pouch during pregnancy: report of a case

H. Suzuki, H. Ogawa, K. Miura, T. Naitoh, S. Haneda, K. Watanabe, C. Shibata, I. Sasaki

Division of Biological Regulation and Oncology, Department of Surgery, Tohoku University Graduate School of Medicine, Sendai, Japan

**Introduction:** Restorative proctocolectomy with ileal J-pouch anal anastomosis is now considered a standard operation for ulcerative colitis. Perforation of the ileal pouch is one of the long-term post-operative complications. Although it is very rare, it can be life-threatening on occasions, and the cause remains obscure.

**Material and Methods:** The patient was a 40-year-old woman. She underwent restorative proctocolectomy with ileal J-pouch anal anastomosis for ulcerative colitis when she was 31 years old. She had chronic pouchitis which was sensitive to medications. She suffered from abdominal pain in the pregnancy week 33. Computed tomography showed free air in the abdomen, and we performed emergency laparotomy with the diagnosis of diffuse peritonitis.

**Results:** A cesarean section was at first performed, we found a pin-hole perforation at the blind end of ileal J-pouch. The intestinal wall around the perforation was very thin. We resected perforated blind end. Postoperative course was uneventful, and she was discharged on the 14th post operative day.

**Conclusion:** Perforation of the J-pouch was likely to occur at the blind end because of increased intraluminal pressure associated with accumulated gas and stool. Additionally, chronic pouchitis and pregnancy might have something to do with occurrence of the perforation.

#### Abstract ID: 0363 Specific Field: Colon and Rectum

**Mode of pres.: Poster Discussion**  
ISW 2011 Session PW 07.05

##### Laparoscopic appendectomy (LA) in our hospital

K. Horikoshi [1], N. Miyajima [1], T. Otsubo [2]

[1] St. Marianna University Toyoko Hospital, Kawasaki City, Japan,  
[2] St. Marianna University, School of Medicine, Kawasaki City, Japan

**Introduction:** In our hospital, laparoscopic appendectomy(LA) is performed positively for acute appendicitis in consideration of patients physical status.

**Material and Methods:** The operation is performed in the following 3 ports;First port is inserted 12 mm in the subumbilical area by open method. The other 2 ports are inserted under pneumoperitoneum, 5 mm in the left lower quadrant, and 5 mm in the lower abdominal region. We insert a 5 mm scope from lower abdominal region. The mesoappendix is treated with a supersonic wave coagulation device. The treatment of appendices root is done by the end linear stapler. The appendix is removed from subumbilical portion in bag and peritoneal lavage is done enough.

**Results:** We performed LA for 69 cases between June, 2008 to September, 2010. The average age was 41 years old. The male/female ratio was 43/26. The mean operative time was 64.1 min. The mean

postoperative hospitalization was 5.0 days. Conversion rate was 1.5%. The complications were 6 cases in total (8.7%). Details as follows, two SSI, one rectal abscess, two liver damage and one subileus. All cases were relieved conservatively.

**Conclusion:** We perform LA positively in our hospital. By an extended view effect of the laparoscope, we can perform LA safely under a good operative view. We think that laparoscopic appendectomy is useful operative method. Even in the severe inflammation case with drain, SSI decreases. And it is thought with the operative method that the shortening of the hospitalization may be expected.

**Abstract ID: 0364** Specific Field: **Colon and Rectum**

**Mode of pres.: Poster Discussion**  
**ISW 2011 Session PW 07.06**

**Five cases of anal cancer after infliximab therapy for Crohn's disease**

S. Haneda [1], H. Ogawa [1], K. Miura [1], K. Watanabe [1], Y. Funayama [2], K. Takahashi [2], C. Shibata [1], I. Sasaki [1]

[1] Tohoku University Hospital, Sendai, Japan, [2] Tohoku Rosai Hospital, Sendai, Japan

**Introduction:** In patients of Crohn's disease (CD) who has severe anal lesion for long periods, development of anal cancer are infrequently reported. Although there is an obvious concern about the effect of this treatment on the incidence of cancer, infliximab (IFX) is an effective agent in the treatment of CD.

**Material and Methods:** Five patients (2 male and 3 female) of CD developed anal cancer after IFX therapy in Tohoku University Hospital and Tohoku Rosai Hospital from 2004 to 2010. Mean age was 41.9 (25–68) years.

**Results:** All patients had severe anal lesion. Mean duration from suffering anal fistula to diagnosis of anal cancer was 14.6 (7.1–23.7) years. Four of those patients had already constructed stoma before introducing IFX therapy. Mean duration from administering IFX to diagnosis of anal cancer was 18 (4–66) months, and 4 of them were less than 9 months. Operation was performed for all patients. Total pelvic exenteration; 2, abdominoperineal resection; 2, exploratory laparotomy; 1, One patient had stage II tumors; stage IIIb; 1, stage IV; 3.

**Conclusion:** Although there is currently no definitive proof of a relationship between IFX therapy and colorectal cancer, we should lead to a careful evaluation of the possibility of increased cancer risk in introducing IFX against patients of CD who have severe anal lesion, especially if their rectoanal lesion was diverted before the therapy.

**Abstract ID: 0365** Specific Field: **Colon and Rectum**

**Mode of pres.: Poster Discussion**  
**ISW 2011 Session PW 07.07**

**Clinicopathological analysis of neoplasia associated with ulcerative colitis**

S. Uchiyama, H. Ishizaki, M. Hotokezaka, K. Chijiwa  
Miyazaki University, Miyazaki, Japan

**Introduction:** Ulcerative colitis is an inflammatory condition involving the rectum with continuous involvement of the proximal colon. Longstanding UC is known to be at higher risk for colorectal neoplasia including dysplasia and adenocarcinoma. The purpose of this study was to assess the clinicopathological findings of neoplasia associated with ulcerative colitis.

**Material and Methods:** From 1978 to 2010, sixty four patients were surgically resected for ulcerative colitis and enrolled in this study. Mean follow-up period was 18.7 years (range: 7–35 years), and annual follow-up colonoscopy was performed except for two cases before 2000.

**Results:** Eleven patients had neoplastic lesions and their operative procedures were as follows: ileoproctal anastomosis in 5, abdominoperineal resection (APR) in 5, total proctocolectomy with ileostoma in one patient. Two of 5 APR cases performed resection of the anorectal lesion after subtotal colectomy for active phase ulcerative colitis. Postoperative histologic diagnosis was dysplasia in 3 cases and carcinoma in 8 cases. There were elevated lesions in seven cases, and ulcerated lesions in four cases. Histologic examination showed that differentiated adenocarcinoma was observed in 6 cases and another two cases were signet-ring cell carcinoma and mucinous carcinoma respectively. Three cases were early carcinoma with mucosal or submucosal invasion, and five were advanced carcinoma and four among five cases had lymph node metastasis. There was no recurrence in three cases of early carcinoma and two cases of carcinoma invaded the proper muscle. However, two out of three cases invading through proper muscle died within 2 months and 15 months after operation for the primary lesion respectively, and the former case showed rapid growth after diagnosis of carcinoma.

**Conclusion:** Although colonoscopic surveillance for neoplasia in ulcerative colitis sometimes can pick up an early stage neoplasia, we should note that endoscopic and histologic diagnosis is still difficult compared with sporadic neoplasia, and careful endoscopic examination with biopsy is essential for better prognosis in cases with longstanding ulcerative colitis.

**Abstract ID: 0366** Specific Field: **Colon and Rectum**

**Mode of pres.: Poster Exhibition only**  
**ISW 2011 Session PE 149**

**Microsatellite instability status in colon cancer and adjuvant chemotherapy for Stage II disease**

T. Yatsuoka, K. Akagi, Y. Nishimura, H. Sakamoto, Y. Tanaka  
Saitama Cancer Center, Saitama, Japan

**Introduction:** Recent studies of colon cancer have identified two molecular pathways such as the pathway of high level of microsatellite instability (MSI) and the pathway of microsatellite stable (MSS) known as chromosomal instability. MSI is not only one of the most studied markers but also an important prognostic indicator in colon cancer. The aim of this study was to investigate the incidence of MSI in a Japanese single institution and the prognostic value of MSI.

**Material and Methods:** MSI testing was performed for consecutive 600 cases from 2000 to 2004. They were classifying into MSI-H, MSI-L and MSS. To identify the Lynch syndrome patients, the further testings were performed including MLH1 methylation, BRAF mutation, DNA sequencing of MMR genes and IHC evaluation of MMR proteins for MSI-H cases. Based on these retrospective data we investigated the usefulness of MSI status as a predictive marker of the benefit of adjuvant chemotherapy in stage II.

**Results:** MSI-H was found in 45 patients, MSI-L in 55, and MSS in 500. In our study we observed twenty five cases that showed unmethylated MLH1 and no BRAF mutation, so that they were highly suspected as Lynch Sx cases. The remainder though to be sporadic colon cancers. Although our retrospective analysis did not control the use or nonuse of adjuvant chemotherapy in Stage II disease, the rate of 5 year DFS in MSI-H patients was higher than that in MSS and MSI-L patients. But the statistical significance was not seen. In total MSI-H patients did not die of any cancers during a median follow-up period of 5 years. We focus on

the treatment of adjuvant Chemotherapy for MSS and MSI-L cases. In this analysis, the adjuvant chemotherapy significantly increases overall DFS in MSS and MSI-L cases.

**Conclusion:** MSI positive was found in 17% cases with colon cancer and MSI-H in 8%. MSI-H was associated with an improved outcome among the patients with stage II colon cancer. FU-based adjuvant chemotherapy benefited the patients with MSS or MSI-L tumor but not those with MSI-H. Given these data, we believe that MSI testing can be useful in clinical decision-making for adjuvant chemotherapy.

**Abstract ID: 0367** Specific Field: **Colon and Rectum**

**Mode of pres.: Poster Exhibition only**  
**ISW 2011 Session PE 150**

**Effect of the new vitamin E derivative in dextran sodium sulfate induced colitis in mice**

T. Hiratsuka, M. Inomata, Y. Kono, T. Masuda, T. Hirashita, F. Yoshizumi, N. Shiraiishi, S. Kitano

Oita University Faculty of Medicine, Yufu, Japan

**Introduction:** In ulcerative colitis, the oxidative stress is considered to be one of the exacerbation mechanisms, and application to treatment of the antioxidant for ulcerative colitis is expected. We coupled glutathione and taurine to vitamin E this time and developed new vitamin E derivative ETS-GS which overcame the fault of the existing vitamin E derivative. We evaluated effect of treatment of ETS-GS in the murine dextran sodium sulfate (DSS)-induced colitis model.

**Material and Methods:** We made ICR mice of 7 weeks of age drink 5% dextran sodium sulfate (DSS) water solution freely for five days and induced colitis. We confirmed the hematochezia onset of all cases and switch to sacrificed them on the tenth 1% DSS water solution from the sixth day and performed administration with the subcutaneous injection once a day in the ETS-GS for 4 days ( $n = 11$ ) or in the Saline for 4 days ( $n = 11$ ), and sacrificed them on the tenth day. We weighed the ETS-GS group and the Saline group (control group) about everyday weight change and Disease activity index (DAI), large intestine Weight and length, Histopathological score of large intestine. We assumed large intestine from anus to 2 cm a sample, and conducted the Histopathological examination by hematoxylin and eosin stain.

**Results:** In ETS-GS group, DAI and Shortening of large intestine length and Weight loss of large intestine were significantly lower than control group ( $1.8 \pm 1.0$  vs.  $2.1 \pm 1.1$ ,  $P = 0.03$ ), ( $92.2 \pm 8.2$  mm vs.  $74.2 \pm 5.0$  mm  $P < 0.0001$ ), ( $0.88 \pm 0.32$  g vs.  $0.58 \pm 0.14$  g,  $P = 0.0095$ ). In control group, the loss of Goblet cells and neutrophilic infiltration and destruction of the structure were higher than that of ETS-GS group. Histopathological score in ETS-GS group was significantly lower than that of control group. ( $2.5 \pm 1.3$  vs.  $3.8 \pm 0.4$ ,  $P < 0.0055$ )

**Conclusion:** This result demonstrates that new vitamin E derivative ETS-GS had an improvement effect of the murine dextran sodium sulfate-induced colitis. Application to ulcerative colitis treatment is expected.

**Abstract ID: 0368** Specific Field: **Colon and Rectum**

**Mode of pres.: Poster Exhibition only**  
**ISW 2011 Session PE 151**

**Expression of circadian genes correlate with liver metastasis and outcomes in colorectal cancer**

T. Oshima [1], S. Takenoshita [2], M. Akaike [3], M. Shiozawa [3], C. Kunisaki [1], S. Fujii [1], M. Masuda [4], T. Imada [4]

[1] Gastroenterological Center, Yokohama City University, Yokohama, Japan, [2] Department of Surgery, Fukushima Medical University, Fukushima, Japan, [3] Department of Surgery, Kanagawa Cancer Center, Yokohama, Japan, [4] Department of Surgery, Yokohama City University, Yokohama, Japan

**Introduction:** Circadian rhythms are daily oscillations in various biologic processes, generated by the feedback loops of eight core circadian genes: Period1 (Per1), Period2 (Per2), Period3 (Per3), Cryptochrome1 (Cry1), Cryptochrome2 (Cry2), Clock, Bmal1, and Casein Kinase I $\epsilon$  (CKI $\epsilon$ ). Recent studies have suggested that circadian genes participate in the growth and development of various cancers. This study examined the relations of circadian gene expression to clinicopathological factors and outcomes in patients with colorectal cancer.

**Material and Methods:** We studied surgical specimens of cancer tissue and adjacent normal mucosa obtained from 202 patients with untreated colorectal cancer. The relative expression levels of the circadian genes in the specimens were measured by quantitative real-time, reverse-transcription polymerase chain reaction.

**Results:** Expressions of the Clock gene and the CKI $\epsilon$  gene in cancer tissue were significantly higher than those in adjacent normal mucosa. Expressions of the Per1 gene and the Per3 gene in cancer tissue were significantly lower than those in adjacent normal mucosa. Analysis of the relations between clinicopathological features and expressions of the eight circadian genes in cancer tissue showed that high expression of the Bmal1 gene and low expression of the Per1 gene correlated with liver metastasis. On analysis of the relations between outcomes and gene expression, high expression of the Per2 gene was associated with significantly better outcomes than low expression of the Per2 gene.

**Conclusion:** Overexpression of the Bmal1 gene and reduced expression of the Per1 gene may thus be useful predictors of liver metastasis. Moreover, reduced expression of the Per2 gene may be a predictor of outcomes in patients with colorectal cancer.

**Abstract ID: 0369** Specific Field: **Colon and Rectum**

**Mode of pres.: Poster Exhibition only**  
**ISW 2011 Session PE 152**

**Clinical pathology examination on appearance of dipeptidase 1 in colorectal cancer**

K. Tachibana [1], M. Iwadata [1], J. Ando [1], S. Waguri [1], E. Ito [1], J. Imai [1], S. Watanabe [1], S. Takenoshita [2]

[1] Fukushima Medical University, Fukushima, Japan, [2] Hukushima Medical University, Japan

**Introduction:** There are many research projects that are searching for a tumor marker which will be an indication of diagnosis and treatment for colorectal cancer; however, there is only a few effective one. We identified DPEP1 (Dipeptidase 1) gene which highly appeared in Japanese colorectal cancer by comprehensive gene expression profiles. The DPEP1 protein is a GPI anchor protein which exists in kidney and microvilli of small intestine; moreover, its function is still unknown. The DPEP1 protein is recently reported as a peculiar protein which appears in colorectal cancer (McIever et al. 2004; Toiyama et al. 2010). Because the relationship of pathological analysis and clinical information is not has been reported in detail in literature inquire, retrospective analysis on base of pathological specimen is in need.

**Material and Methods:** We examined the relationship of appearance of DPEP1 and clinical information on 61 operative cases of colorectal cancer that we experienced by the comprehensive gene expression profiles. Moreover, we selected 20 cases from the 61 cases, in order to do the immunohistochemical staining for furthermore study.



**Results:** There was a significant difference in lymph node metastasis ( $N0/N1-2 = 2.6 \pm 1.5/3.4 \pm 1.4$ ,  $P = 0.043$ ). Moreover, the appearance of DPEP1 was low in all histological types except highly, and moderately differentiated types of adenocarcinoma ( $tub1/tub2/$  others =  $2.9 \pm 1.6/3.1 \pm 1.6/1.5 \pm 1.1$ ,  $P < 0.001$ ). The DPEP1 will not be stained by the immunohistochemical staining on the normal cells, however the DPEP1 protein exist in the membrane of the colorectal cancer cells.

**Conclusion:** This study showed that the DPEP1 is able to become a tumor marker of colorectal cancer. Since the DPEP1 significantly appears in lymph node metastasis, there is a possibility that it participates in metastasis and permeation of colorectal cancer.

#### Abstract ID: 0370 Specific Field: Colon and Rectum

**Mode of pres.: Poster Exhibition only**  
ISW 2011 Session PE 153

##### Clinicopathological differences between proximal and distal pT3 colon cancer and the clinical significance of the depth of the cancer invasion beyond the muscularis propria

T. Otani, K. Yoshimatsu, H. Yokomizo, G. Osawa, K. Ogawa

Department of Surgery, Tokyo Women's Medical University Medical Center East, Tokyo, Japan

**Introduction:** The purpose of this study was to investigate differences in clinicopathological features between proximal and distal pT3 colon cancers, and in relation to prognosis, to determine whether the depth of the cancer invasion beyond the muscularis propria (DBM) serves as an objective indicator of the depth of tumor invasion in proximal colon cancer and in distal colon cancer.

**Material and Methods:** A total of 207 patients who underwent surgery for proximal and distal pT3 colon cancer between 1996 and 2001 (proximal; 91 patients, distal; 116 patients) were included in the analysis.

**Results:** No differences were noted between proximal and distal cancers in the clinicopathological variables such as lymph node metastasis, distant metastasis, lymphatic/venous invasion, histological type, and curability of surgical resection, except that patients with proximal cancer were significantly higher in age. However, grades 2 or 3 tumor budding and INF b to c, which are commonly observed among poorly differentiated cases and vascular invasion positive cases, were more frequent in patients with proximal colon cancer, while the distal lesions were somewhat greater in tumor size. High-grade malignancy appeared to be more commonly noted in the proximal colon cancer cases, but there was no significant difference in prognosis between proximal and distal cancer patients. Regarding the correlation between DBM and prognosis, there was a significant decrease in the 5-year survival rate in patients with proximal lesions of DBM 3000  $\mu$ m or more and patients with distal lesions of DBM 5000  $\mu$ m or more. DBM is thus considered to be an objective indicator of depth of tumor invasion for both proximal and distal lesions. Furthermore, such patients with an DBM of 3000  $\mu$ m and 5000  $\mu$ m or more for the proximal and distal lesions, respectively, may be considered to be at high risk of recurrence, and DBM may be used as a guide to determining whether or not postoperative adjuvant chemotherapy should be performed. DBM also represents an independent prognostic factor for proximal colon cancer.

**Conclusion:** Based on the above findings, DBM is considered to be useful as an objective indicator of depth of tumor invasion, as a

prognostic factor, and as a guide to determining whether postoperative adjuvant chemotherapy is indicated for pT3 colon cancer cases.

#### Abstract ID: 0371 Specific Field: Colon and Rectum

**Mode of pres.: Poster Exhibition only**  
ISW 2011 Session PE 154

##### Significance of preoperative serum CEA in prognostic staging of colorectal cancer

T. Kitamura [1], K. Kotake [1], H. Ozawa [1], T. Matsui [1], The Study Group of the JSCCR on Postsurgical Surveillance of Colorectal Cancer [2]

[1] Tochigi Cancer Center, Utsunomiya, Japan, [2] Tochigi Cancer Center, Japan

**Introduction:** A number of studies have reported the prognostic significance of the preoperative serum Carcinoembryonic antigen level in colorectal cancer. To identify the significance of the serum Carcinoembryonic antigen level in staging system of colorectal cancer.

**Material and Methods:** A retrospective analysis of the records of 2,527 patients who underwent R0 resection for colorectal cancer between 1997 and 2000 at 10 member institutes of the study group was performed. The serum Carcinoembryonic antigen level was categorized into two groups by the cut-off value of 10 ng/ml (low (L)10, high (H) >10). Probabilities of survival were calculated by the Kaplan–Meier method. The prognostic influence of the serum Carcinoembryonic antigen level on survival was analyzed using the log-rank test.

**Results:** In every stage (i.e. pathological stage I to stage IIIb), the survival rates of the high groups were statistically significant lower than the low groups. (stage I: L = 98.0% H = 92.9%, stage II: L = 90.5% H = 80.9%, stage IIIa: L = 80.8% H = 70.9%, stage IIIb: L = 66.4% H = 48.1%). The survival rates of the high group of stage I and the low group of stage II, and that of the high group of stage II and the low group of stage IIIa were almost equivalent.

**Conclusion:** Prognostic significance of the serum Carcinoembryonic antigen level in colorectal cancer was evidently reconfirmed in the multi-institutional study. This prognostic parameter would be available to reassign the stage grouping, namely prognostic grouping, incorporating with anatomical TNM systems.

#### Abstract ID: 0372 Specific Field: Colon and Rectum

**Mode of pres.: Poster Exhibition only**  
ISW 2011 Session PE 155

##### Diagnosis of lymph node metastasis from rectal/anal canal cancer by CT and MRI

T. Omoto, S. Endo, E. Hidaka, K. Ikehara, F. Ishida, J. Tanaka, S. Kudo

Showa University Northern Yokohama Hospital, Yokohama, Japan

**Introduction:** Rectal/anal submucosal cancer with suspected lymph node metastasis is usually treated by bowel resection with lymph node dissection. When the rectum and anal canal are involved, even anus-preserving surgical procedures result in a decrease in QOL due to impaired rectal function. Lymph node metastasis occurs only in

10–15% of all cases of submucosal cancer requiring lymph node dissection. All metastatic cases of rectal/anal canal submucosal cancer we encountered were positive for mesorectal lymph node metastasis. We retrospectively reviewed the diagnoses of patients with mesorectal lymph node enlargement/metastasis from submucosal cancer by CT and MRI.

**Material and Methods:** We studied 96 patients with rectal/anal canal submucosal cancer who underwent bowel resection with lymph node dissection at our center between April 2001 and April 2010. The patients consisted of 35 with cancer in the upper rectum (Ra), 52 with cancer in the lower rectum (Rb) and 9 with cancer in the anal canal (P). CT (slice thickness, 6 mm) and MRI (slice thickness, 7 mm) were performed in 96 and 43 patients, respectively. Lymph nodes with a diameter 5 mm on CT or MRI were considered enlarged and compared with histologically confirmed lymph node metastases.

**Results:** 13 patients were positive for metastasis detected only in the mesorectal lymph nodes, and no metastasis spread from the mesorectal lymph nodes to other lymph nodes. The sensitivity, specificity and PPV in diagnosing pararectal lymph node metastasis compared with histological diagnoses in all cases including Ra, Rb and P were 47.8, 98.6 and 92.3% for CT and 5.7, 96.6 and 83.3% for MRI, respectively. The low sensitivity and PPV of MRI may be due to the small patient number.

**Conclusion:** CT and MRI demonstrated high levels of specificity and are considered applicable for the diagnosis of negative lymph node metastasis. Future studies need to prospectively examine the applicability of these imaging modalities for the preoperative diagnosis of lymph node metastasis to identify metastasis-negative cases and thereby avoid unnecessary operation.

#### Abstract ID: 0373 Specific Field: Colon and Rectum

Mode of pres.: Poster Exhibition only  
ISW 2011 Session PE 156

##### Prognostic factors for patients with peritoneal metastasis from colorectal cancer

S. Yamagishi [1], A. Ishibe [1], A. Nakano [1], D. Minabe [1], K. Matsuo [1], K. Misuta [2], W. Sano [1], S. Kaida [1]

[1] Fujisawa City Hospital, Fujisawa-shi, Japan, [2] Fujisawa City Hospital, Fujisawa City, Japan

**Introduction:** This retrospective study was performed to clarify the prognostic factors for patients with peritoneal metastasis from colorectal cancer.

**Material and Methods:** Peritoneal metastasis was noted in 36 (3.3%) of the 1088 colorectal cancer patients underwent surgical treatment between 2001 and 2010. Data included age, gender, presence of distant metastasis, period and degree of peritoneal metastasis, primary tumor location and presence of remnant cancer after resection. Outcomes were defined as three-year cumulative probabilities of overall survival. The mean follow-up was 20.5 months (0.1–89.2 months).

**Results:** Univariate analysis revealed that age, presence of remnant cancer after resection and degree of peritoneal metastasis were significant factors affecting the survival ( $P < 0.05$ ). Multivariate analysis showed that age ( $70 \leq$ ) [ $P = 0.005$ , 95% confidence interval (CI) = 1.658–17.080] and multiple peritoneal metastasis ( $P = 0.009$ , 95% CI=1.715–44.051) were the prognostic factors for three-year survival of patients with peritoneal metastasis from colorectal cancer.

**Conclusion:** These results suggest that the positively surgical treatment may be improved the prognosis for patients with minute peritoneal metastasis under 70 years old.

#### Abstract ID: 0374 Specific Field: Colon and Rectum

Mode of pres.: Poster Exhibition only  
ISW 2011 Session PE 157

##### Risk factors of lateral pelvic lymph node metastasis in rectal cancer: based on preoperative clinicopathological factors

T. Yamaguchi [1], Y. Kinugasa [1], A. Shiomi [1], K. Moritani [1], H. Tomioka [1], S. Tsukamoto [1], E. Bando [2], M. Terashima [2]

[1] Division of Colon and Rectal Surgery, Shizuoka Cancer Center Hospital, Shizuoka, Japan, [2] Division of Surgery, Shizuoka Cancer Center Hospital, Shizuoka, Japan

**Introduction:** The aim of this study was to reveal the risk factors of lateral pelvic lymph node (LPLN) metastasis in rectal cancer based on preoperative clinicopathological factors.

**Material and Methods:** A total 230 patients who underwent total mesorectal excision or tumor-specific mesorectal excision with LPLN dissection at the Shizuoka Cancer Center Hospital between 2002 and 2010 were retrospectively studied. Of these patients, those who with non-adenocarcinoma and with preoperative chemoradiotherapy were excluded, and finally 221 patients were enrolled. The preoperative clinicopathological factors including age, sex, CEA, tumor location, macroscopic type, tumor size, tumor annularity, histopathological grading, depth of invasion and regional lymph node and LPLN status diagnosed by computed tomography (CT) were analyzed. All the patients underwent preoperative CT. Regional lymph nodes with more than 9 mm in long-axis diameter or irregular border and LPLNs with more than 6 mm in short-axis diameter or irregular border diagnosed were considered positive lymph nodes.

**Results:** Among the 221 patients, 47 (21.2%) had pathological LPLN metastasis. Multivariate analysis showed that tumor location, CEA, macroscopic type, histopathological grading and LPLN status were significantly correlated with pathological LPLN metastasis. Among 129 patients with tumor center located below the peritoneal reflection who were LPLN status-negative and had less than two other risk factors, only 5 patients (3.9%) had pathological LPLN metastasis. On the other hand, among 37 patients with tumor center located below the peritoneal reflection who were LPLN status-positive and had at least more than one risk factor, 31 patients (83.8%) had pathological LPLN metastasis.

**Conclusion:** These results suggest that by using these factors, we may be able to select the patients at low or high risk of LPLN metastasis. These models warrant further investigation and validation in future prospective trials.

#### Abstract ID: 0375 Specific Field: Colon and Rectum

Mode of pres.: Poster Exhibition only  
ISW 2011 Session PE 158

##### The preservation of the autonomic nerve during lateral pelvic node dissection for rectal cancer does not affect survival outcomes

M. Ota, S. Fujii, H. Suwa, K. Tatsumi, K. Watanabe, Y. Ichikawa, K. Tanaka, I. Endo

Yokohama City University, Yokohama, Japan

**Introduction:** To clarify whether autonomic nerve preservation affects patient's outcomes.

**Material and Methods:** A total of 388 patients who underwent potentially curative operation with lateral pelvic node dissection for advanced rectal cancer (1992–2002) were reviewed. Patients were categorized into three groups according to the mode of pelvic plexus

preservation; 80 patients with complete preservation of the pelvic plexus (CPPP) group; 164 with partial preservation (PPPP) group; 144 with non-preservation (NPPP) group.

**Results:** There was no significant difference in clinicopathological factors in three group. The 5-year overall survival rate in CPPP, PPPP, and NPPP were 82.1, 83.6, and 65.9%, respectively. In patients with positive lateral nodes, the 5-year survival rate in CPPP, PPPP, and NPPP were 50.0, 53.3, and 43.0%, respectively ( $P > 0.05$ ). Local recurrence was found in 18.2% in patients with positive lateral node. Multivariate analysis in the patients with positive lateral nodes revealed that histological types of the tumor (well, mod vs. por) and depth of the tumor (T3 vs. T4) were significant prognostic factors, however mode of pelvic plexus preservation showed no significant impact on patients' survival. Long-term self-catheterization in CPPP, PPPP, and NPPP were 0, 24.8, and 42.3%, respectively ( $P = 0.0083$ ).

**Conclusion:** Even when lateral pelvic node dissection is necessary, autonomic nerve should be preserved to avoid urinary dysfunction.

**Abstract ID: 0376** Specific Field: **Colon and Rectum**

**Mode of pres.: Poster Exhibition only**  
**ISW 2011 Session PE 159**

#### **Inclination of the longitudinal axis of the colonic J-pouch and evacuation difficulty**

J. Hida, T. Yoshifuji, F. Sugiura, K. Daito, K. Ueda, E. Ishimaru, T. Tokoro, K. Okuno

Kinki University School of Medicine, Osaka, Japan

**Introduction:** Functional outcome after low anterior resection for rectal cancer is improved by the construction of a colonic J-pouch. One disadvantage of this type of reconstruction is evacuation difficulty, which has been associated with large pouches. The purpose of this study was to elucidate the causes of evacuation difficulty in large pouches using pouchography.

**Material and Methods:** The angle between the longitudinal axis of the pouch and the horizontal line (pouch-horizontal angle) on lateral pouchography was determined in 26 patients with 10-cm J-pouch reconstructions (10-J group) and 27 patients with 5-cm J-pouch reconstructions (5-J group). Measurement were made at three months, one year, and two years after surgery. Clinical function was evaluated using a questionnaire one year postoperatively.

**Results:** The pouch-horizontal angle in the 10-J group was significantly smaller than that in the 5-J group at all three time points. In both groups the pouch-horizontal angle at one year was significantly smaller than that at three months. There were no significant differences between the pouch-horizontal angles at one and two years. An evacuation difficulty was significantly more common in the 10-J group than the 5-J group.

**Conclusion:** The evacuation difficulty observed in patients with large colonic J-pouch reconstructions may be attributed to the development of a horizontal inclination within one year of surgery.

**Abstract ID: 0377** Specific Field: **Colon and Rectum**

**Mode of pres.: Poster Exhibition only**  
**ISW 2011 Session PE 160**

#### **Clinical evaluation of intersphincteric resection for low rectal adenocarcinoma**

T. Tokoro, K. Okuno, J. Hida, E. Ishimaru, K. Ueda, T. Yoshifuji, K. Daito, F. Sugiura

Department of Surgery, Kinki University, School of Medicine, Osaka, Japan

**Introduction:** Intersphincteric resection (ISR) that involves partial or total internal anal sphincteric resection and coloanal hand-sewn anastomosis, attempts to preserve anal function. This study investigates whether ISR can have acceptable oncological and anal functional outcomes.

**Material and Methods:** From April 2001 to August 2010, 30 patients with low rectal adenocarcinoma underwent ISR. The tumor location was less than 2.5 cm from the dentate line in all patients. The criteria for exclusion from ISR were invasion of the external sphincter or levator ani, patients in whom biopsy revealed histological G3, and patients not fully continent preoperatively. Colonic J-pouch reconstruction was performed in all but 2 patients, and diverting stoma was made in all patients. The analyses of this study were pathological evaluation of surgical margin and to assess postoperative anal function using the incontinence score of Wexner.

**Results:** One patient was pT0, 8 patients were pT1, 10 patients were pT2, and 11 patients were pT3. The morbidity rate was 33.3%. Stricture of the anastomotic site occurred in 7 patients, prolapse of the colonic J-pouch occurred in 2 patients, and 1 patient had an anovaginal fistula. In pathological examination, the distal margin and the radial margin was  $8.1 \pm 6.3$  mm,  $3.5 \pm 3.5$  mm, respectively. The radial margin was 1 mm or less in 5 patients. After a median follow-up of 51.4 M, local recurrence occurred in 6 patients: 3 occurred in the pelvic wall, 2 in the lymph nodes, and 1 was an anastomotic implantation. Five out of 6 patients who suffered local recurrence were in the pT3 stage. Eighteen patients (pISR: 9 patients out of 12, sISR: 1 patient out of 4, and tISR: 8 patients out of 14) underwent stoma closure. In all of the patients who underwent stoma closure, the Wexner score was improvement of  $13.3 \pm 3.3$  at 3 months to  $11.0 \pm 4.6$  at 6 months ( $P = 0.03$ ). Six of 12 patients who could not undergo stoma closure, exhibited anastomotic stricture or anal dysfunction, and of these 4 patients were tISR patients without anastomotic stricture.

**Conclusion:** ISR was able to achieve acceptable local control in patients with early-staged low rectal adenocarcinoma. Because patients who underwent tISR and those who underwent any type of ISR but suffered an anastomotic stricture could not undergo stoma closure, patients should be informed about the possibility of disappointing results.

**Abstract ID: 0378** Specific Field: **Colon and Rectum**

**Mode of pres.: Poster Exhibition only**  
**ISW 2011 Session PE 161**

#### **The actual situation of lateral lymph node involvement in rectal cancer**

Y. Akagi, T. Kinugasa, I. Shiratuchi, T. Yoshida, Y. Ryu, Y. Gotanda, K. Tanaka, K. Shirouzu

Kurume University, Kurume, Japan

**Introduction:** The metastases to lymph nodes of rectal cancer has both upper and lateral area. The lateral side wall lymph node dissection has been performed in some institutes in our country, but it may be possible that this treatment cause urinary and sexual disorder. On the other hand, chemoradiotherapy is general in Europe and America. A clinical practice about significance of preventive lymph node dissection is proceeding in our country now. A purpose of this study is to demonstrate characteristics of the case that developed lymph node metastasis to the lateral side pelvic wall.

**Material and Methods:** 138 cases that were performed curative operation with lymphadenectomy in bilateral lymph node of side pelvic wall for rectal cancer between 1975 and 2006 were examined. The following items were examined statistically. (1) Relationship between the lesion of lateral lymph node metastasis and primary rectal tumor. (2) The critical factors for lateral lymph node metastasis and its prognosis.

**Results:** (1) 31% of cases with lateral lymph node metastasis were found. The metastatic site was seen in order of the internal iliac artery area, the obturator nerve area, the external iliac artery area. (2) The metastasis of lateral lymph node was recognized in lower rectal cancer than upper rectal cancer  $P$  0.015. The metastasis of lateral lymph node was recognized in more deeper depth of invasion  $P$  0.048. The metastasis of lateral lymph node was recognized in poorly differentiated type  $P$  0.002. The metastasis of lateral lymph node was recognized in case with lymph node metastasis in mesorectum. As for DFS, the case with lateral lymph node positive was significantly poor in comparison with the negative case.

**Conclusion:** The high-risk group of lateral lymph node metastasis is poorly differentiated adenocarcinoma of lower rectal cancer. As a next step, we have to examine significance of preventive lymph node dissection or chemoradiotherapy for such cases.

**Abstract ID: 0379** Specific Field: **Colon and Rectum**

**Mode of pres.: Poster Exhibition only**  
**ISW 2011 Session PE 162**

**Second primary cancer in patients with colorectal cancer after a curative resection**

S. Noura, M. Ohue, T. Shingai, S. Kano, S. Imada, M. Yano, O. Ishikawa

Osaka Medical Center for Cancer and Cardiovascular Diseases, Osaka, Japan

**Introduction:** Colorectal cancer (CRC) patients have an increased risk of developing other malignancies. Understanding the characteristics of the second primary cancer is important to establish an effective surveillance program.

**Material and Methods:** This study investigated 301 CRC patients to assess the risk factors for postoperative primary cancers arising from organs distinct from the colorectal area (extracolorectal cancers). The observed/expected ratio (O/E ratio) was calculated using the Osaka Cancer Registry, to determine the rate of increase of extracolorectal cancers.

**Results:** The frequency of postoperative extracolorectal cancers was 12.6%. A logistic regression analysis showed only age to be an independent risk factor for postoperative extracolorectal cancer development. The O/E ratio of overall postoperative extracolorectal

Comparison of the observed incidence and expected incidence calculated using the Osaka Cancer regist

	Observed incidence	Expected incidence	O/E ratio	95% CI	$P$ value
Overall	40	15.4	2.6	1.857–3.542	<0.01
Lung	8	2.5	3.2	1.379–6.299	<0.01
Stomach	8	3.0	2.7	1.164–5.315	<0.05
Liver	6	2.2	2.7	0.989–5.882	NS

cancer was significantly higher than one (O/E ratio 2.6,  $P$  < 0.01). In each organ, the frequency of lung and gastric cancers were significantly higher than one with O/E ratios of 3.2 and 2.7 ( $P$  < 0.01 and  $P$  < 0.05, respectively).

**Conclusion:** The frequency of postoperative extracolorectal cancers in CRC patients was significantly higher than that in the normal population, especially for lung and gastric cancers. Clinicians should carefully follow patients for a possible recurrence of CRC and educate CRC patients with regard to the high risk of a second primary cancer.

**Abstract ID: 0380** Specific Field: **Colon and Rectum**

**Mode of pres.: Poster Exhibition only**  
**ISW 2011 Session PE 163**

**Sacral motor nerve terminal latency in patients after low anterior resection for rectal cancer**

R. Tomita [1], S. Igarashi [1], T. Ikeda [2], K. Sugito [2], S. Fujisaki [1], K. Sakurai [2], T. Koshinaga [2], M. Shibata [3]

[1] Nippon Dental University Hospital, Tokyo, Japan, [2] Nihon University School of Medicine, Tokyo, Japan, [3] Fukushima Medical University, Fukushima, Japan

**Introduction:** To assess the neurological function of the puborectalis muscles (PM) in patients with or without soiling after low anterior resection (LAR) for lower rectal cancer, we examined the sacral nerve terminal motor latency (SNTML) of the PM.

**Material and Methods:** The latency of the response in the PM following transcutaneous magnetic stimulation of the cauda equina was measured in 24 patients after LAR. They were divided into a group with soiling (10 cases; 8 men and 2 women, average 61.6 years) and one without soiling (14 cases; 10 men and 4 women, average 60.3 years), and results were compared with data obtained from 25 control subjects (16 men and 9 women, average 62.1 years). Postoperative monitoring of patients was initiated after a period of more than 10 years.

**Results:** Distance of anastomosis from the dentate line: Patients with and without soiling registered respective coloproctostomy distances of  $2.5 \pm 0.6$  and  $5.1 \pm 1.2$  cm, with the former showing a tendency ( $P$  < 0.0001) toward shorter distances. Values of the SNTML: Patients with soiling ( $6.9 \pm 2.1$  ms) exhibited significant extensions compared with patients without soiling ( $4.2 \pm 0.6$  ms), and control subjects ( $3.9 \pm 0.6$  ms) ( $P$  < 0.0001, respectively). Moreover, patients without soiling showed more extended SNTML than control subjects at all sites.

**Conclusion:** Soiling after LAR may be caused by damage to the sacral motor nerves.

**Abstract ID: 0381** Specific Field: **Colon and Rectum**

**Mode of pres.: Poster Exhibition only**  
**ISW 2011 Session PE 164**

**Is chemoradiotherapy for lower rectal carcinoma able to be a substitute for preventive lateral lymph node dissection?**

H. Miyauchi [1], H. Matsubara [1], G. Ohira [2]

[1] Chiba University Graduate School of Medicine, Chiba, Japan, [2] Chiba Graduate School of Medicine, Chiba, Japan



**Introduction:** The aim of this study is to evaluate whether preoperative chemoradiotherapy (CRT) for lower rectal carcinoma can be a substitute for preventive lateral lymph node dissection.

**Material and Methods:** 31 patients who underwent preoperative CRT for lower rectal carcinoma were examined. Indication of CRT were T3-4 and/or N1–2 lower rectal carcinoma. Radiotherapy was delivered to lesser pelvic cavity by 4 field technique with a dose of 45Gy (1.8Gy five times weekly). During the radiation treatment, concurrent chemotherapy (5-fluorouracil 350 mg/m<sup>2</sup> plus l-leucovorin 35 mg/m<sup>2</sup> a day) was delivered 5 consecutive days of each first, third, and fifth week. Effect of CRT were evaluated 4 weeks after the end of CRT, and operation was performed 6 weeks after CRT. When the lateral lymph node metastasis had seemed to be positive through pre-CRT imaging, dissection of the same side was performed systematically, and when negative, one side of lateral lymph node sampling was done.

**Results:** Response rate of the main tumor was 55%. 16 out of 22 N(+) cases could obtain downstaging of lymph node metastases after CRT. Adverse event (Grade 3) were only 2 case of liver dysfunction, one case of stomatitis and dermatitis. All cases could received curative resection. Pathological CR were observed in 5 cases (16%). All of 9 cases that had pathological lymph node metastasis had been diagnosed to have lymph node metastasis also through the pre CRT imaging. There was no pathological lymph node metastasis in the field of radiation that had not involved lymph node metastasis through the pre CRT imaging. Only one case out of 4 cases that had seemed to have lateral lymph node metastasis through the pre CRT imaging showed pathological metastasis. Complication after the operation were as follows: 3 leakage, 3 bowel obstruction, 3 perineal wound infection, 2 pelvic abscess, 1 urinary disturbance, 1 hydronephrosis. 5 cases have recurred after the operation (median follow-up period: 28.2 months), but recurrent site of these cases (lung: 3, presacral: 1, paraaortic LN: 1) were without the irradiated field.

**Conclusion:** Preoperative CRT to lesser pelvic cavity for lower rectal carcinoma can be a substitute for preventive lateral lymph node dissection. But the follow-up period is not long enough to conclude, further observation will be needed.

## Abstract ID: 0382 Specific Field: Colon and Rectum

**Mode of pres.: Poster Exhibition only**  
**ISW 2011 Session PE 165**

### A case of advanced colorectal cancer measuring 6 mm in diameter

Y. Inoue, Y. Kaneko, M. Yamamoto

Tokyo Women's Medical University, Tokyo, Japan

**Introduction:** Early colorectal cancer resection by endoscopy has become possible with recent progress in colonoscopic diagnosis and technology. Therefore, most cases of colorectal mucosal cancer and benign tumor have been resected by endoscopy. On the other hand, it is rare to diagnose small advanced colorectal cancers on colonoscopy. Here, we report a case of advanced colorectal cancer measuring 6 mm in diameter in a 63-year-old woman. The patient underwent colonoscopy for follow-up examination, which showed a type IIa+IIc lesion about 5 mm in diameter in the transverse colon. The non-lifting sign was observed after submucosal fluid injection. As the lesion was deduced to be nonresectable by endoscopy, laparoscopy-assisted colectomy was performed. The resected tumor measured 6 mm in diameter. Histopathological findings indicated a well-differentiated tubular adenocarcinoma (pMP, ly0, v0, n0). Recurrence did not occur postoperation.

## Abstract ID: 0383 Specific Field: Colon and Rectum

**Mode of pres.: Poster Exhibition only**  
**ISW 2011 Session PE 166**

### Short-term outcome of single incision laparoscopic colectomy(SILC) for colon cancer

G. Katsuno, M. Fukunaga, K. Nagakari, Y. Lee, M. Sugano, M. Suda, Y. Iida, S. Yoshikawa

Juntendo Urayasu Hospital, Juntendo University, Urayasu, Japan

**Introduction:** Transumbilical single port surgery (SPS) has been developed with the aims of further reducing the invasiveness of conventional laparoscopy. We report here the early experiences of 70 patients who were treated with transumbilical single incision laparoscopic colectomy (SILC) for colon cancer.

**Material and Methods:** A single intraumbilical 25–30 mm incision was made, and the umbilicus was pulled out, exposing the fascia with moderate subcutaneous exfoliation. Three 5-mm ports or multi-instrument access port were placed in the umbilical site. The umbilicus was the access point of entry to the abdomen for all the patients. SILC was performed using a surgical technique similar to the standard laparoscopic medial-to-lateral approach. The bowel was transected either intracorporeally or extracorporeally with lymph node dissection, and then a stapled anastomosis was performed.

**Results:** We reviewed the clinical records of 70 patients who underwent SILC for colon cancer between April 2010 and December 2010 at the Department of Surgery of Juntendo University Urayasu Hospital. SILC with lymph node dissection was feasible comparable to conventional laparoscopic colectomy. There were 33 (47%) men and 37(53%) women. The mean age of the patients was 65.9 ± 9.5 years and the mean body mass index (BMI) was 23.5 ± 2.1. Of the 70 patients, twenty-six had a tumor in the sigmoid colon, sixteen in the caecum, fifteen in the ascending colon, nine in the rectum and four in the transverse colon. As for the type of operation, the most common procedure was sigmoid colon resection performed in 22 of 70(32%). The mean skin incision was 2.74 ± 0.82 cm. The operating time was 146 ± 39 min. The volume of bleeding was 29 ± 16 ml. The mean hospital stay was 8.8 ± 1.6 days. The overall rate of postoperative complications was 4.3% (3/70); wound infection was found in two patient (2/70). There was no intraoperative complication. One patient (1.4%) was converted to the conventional laparoscopic procedure after single incision approach due to severe adhesion. The number of harvested lymph node was 18 ± 2.1, and sixteen patients had lymph node metastasis. The mean tumor-free resection margin was 11 ± 4.8 (range, 6–16) cm.

**Conclusion:** Our experience indicates SILC is feasible for selected patients with colon cancer. This technique contributed to improving patients' cosmesis.

## Abstract ID: 0384 Specific Field: Colon and Rectum

**Mode of pres.: Poster Exhibition only**  
**ISW 2011 Session PE 167**

### The prediction of difficulty of laparoscopic surgery at low rectal cancer by the pelvimetry using computed tomography

H. Nagahara, K. Maeda, E. Noda, K. Nakamoto, N. Kubo, H. Tanaka, K. Muguruma, K. Hirakawa

Osaka City University Graduate School of Medicine, Osaka, Japan

**Introduction:** Recently, adaptation of operation using a laparoscope for advanced colorectal cancer has been expanded by the progress of laparoscopic surgery. However, we often suffer from the rectal cancer operation, exfoliation around the rectum and anastomosis inside narrow pelvis. Therefore it is useful to distinguish the narrow pelvis before laparoscopic rectal operation when we ascertain operation indication and safety. So we performed pelvimetry using Computed Tomography and examined the utility and connection with the complication.

**Material and Methods:** From January, 2008 to October, 2009, 44 cases of rectal cancer have been performed laparoscopic anterior resection or abdominoperineal resection in our institution, and we measured the obstetric conjugate, sacrum length, pelvic outlet, transverse distance, and interspinous distance of the small pelvis with CT. And we examined the clinicopathologic examination in sex, Body Mass Index, tumor diameter, distance from anus, rate of conversion to open surgery, operation time, bleeding amount, number of stapling, and postoperative complication.

**Results:** Among 44 cases, male were 28 cases and female were 16 cases. As for man, the pelvic cavity was significantly deep and narrowly in comparison with woman in pelvimetry. Complications of anastomotic leakage or conversion to open surgery were 12 cases, and male were 11 cases of all. Multivariate analysis showed that sex ( $P = 0.008$ ), and tumor distance from anus ( $P = 0.0008$ ) were independently predictive of operative time. Others, interspinous distance and the number of stapling were related to anastomotic leakage.

**Conclusion:** As for the man, pelvis is narrower in comparison with the woman, and the man with narrow pelvis have higher risk of complications of anastomotic leakage and open conversion.

**Abstract ID: 0385** Specific Field: **Colon and Rectum**

**Mode of pres.: Poster Exhibition only**  
**ISW 2011 Session PE 168**

**Short-term outcomes of laparoscopic sphincter-preserving total mesorectal excision for low rectal cancer according to the type of anastomosis**

T. Akiyoshi [1], M. Ueno [1], Y. Fukunaga [1], S. Nagayama [1], Y. Fujimoto [1], T. Konishi [1], H. Kuroyanagi [2], T. Yamaguchi [1]

[1] Cancer Institute Hospital, Tokyo, Japan, [2] Toranomon Hospital, Tokyo, Japan

**Introduction:** Laparoscopic total mesorectal excision (TME) with sphincter preservation, especially with stapled anastomoses, is reportedly difficult in patients with low rectal cancer. This study aimed to evaluate the safety of laparoscopic sphincter-preserving TME.

**Material and Methods:** Two hundred and twenty-nine consecutive patients who underwent laparoscopic TME with sphincter preservation for low rectal cancer with a distal margin 8 cm from the anal verge between July 2005 and February 2010 were subdivided into three groups, according to the type of anastomosis: 153 patients with intracorporeal rectal transection and stapled anastomosis (Group A), 25 patients with a prolapse method for rectal transection and stapled anastomosis (Group B), and 51 patients with hand-sewn coloanal anastomosis (Group C). Short-term outcomes were compared between groups.

**Results:** Mean tumor distance from the anal verge differed significantly between groups A, B and C (61 vs.45 vs.34 mm). Mean

operating time and estimated blood loss were significantly shorter (267 vs.310 min) and smaller (33 vs.87 ml) in Group A than in Group C. One positive distal and one circumferential resection margin were identified in Group C and A, respectively. Conversion to open surgery was necessary in one patient (0.7%) for combined resection of the uterus because of direct invasion in Group A and one patient (2%) for bleeding in Group C. The rate of postoperative complications did not differ significantly between groups A, B and C (14 vs. 12 vs.8%). Anastomotic leakage was identified in 8 patients in Group A (5.2%) and 1 patient in Group C (4%).

**Conclusion:** Laparoscopic sphincter-preserving TME can be performed safely with acceptable short-term outcomes in carefully selected patients, irrespective of the type of anastomosis used.

**Abstract ID: 0386** Specific Field: **Colon and Rectum**

**Mode of pres.: Poster Exhibition only**  
**ISW 2011 Session PE 169**

**Laparoscopic colorectal cancer surgery for the very elderly patients**

K. Tomizawa, H. Kuroyanagi, S. Matoba, J. Moriyama, S. Toda, Y. Hanaoka, T. Sawada

Toranomon Hospital, Tokyo, Japan

**Introduction:** The incidence of colorectal cancer is increasing in Japan, and surgery for elderly patients is also increasing. Although the laparoscopic approach is accepted for the treatment of colorectal cancer, its value for the very elderly patients is unknown. The aim of this study was to evaluate the outcome of laparoscopic colorectal cancer surgery for the very elderly patients over 85 years old.

**Material and Methods:** Between 2001 and 2010, 2145 patients had been performed colorectal laparoscopic surgery in our institute, and we studied 44 patients over 85 years old on whom we operated laparoscopic surgery.

**Results:** Patients median age was 87 years old (85–93), 18 men and 26 women. Preoperative complications was observed 36(81%) patients, especially cardiovascular diseases were observed 23 patients. Preoperative performance status (PS) 0 patients was observed 31(75%) patients, and 1:five, 2:three, 3:four, and 4:one, respectively. The median operation time was 170 (50–355) min and median estimated blood loss was 44.5 (5–332) ml. Conversion to open surgery was necessary in one (2%) patient, because of the severe adhesions in the abdominal cavity, but there were no intraoperative complications. Furthermore, no pneumoperitoneum-related complications were observed in the very elderly patients required conversion to open surgery. Postoperative complications occurred in eleven (25%) patients, which consisted three cases of surgical site infection (SSI), two cases of postoperative bowel obstruction, and six cases of delirium. But there was no postoperative pulmonary infection. Thirty-eight (86%) patients were able to walk one day after operation, and the median time to flatus passage was two days and the median time to liquid diet was four days, and the median length of postoperative hospital stay was twelve days. No surgery-related death was observed.

**Conclusion:** Laparoscopic colorectal cancer surgery for the very elderly patients can be safely performed and it may have more advantages than open surgery in terms of faster gastrointestinal recovery, less pulmonary complication and shorter length of hospital stay.

**Abstract ID: 0387** Specific Field: **Colon and Rectum**

**Mode of pres.: Poster Exhibition only**  
**ISW 2011 Session PE 170**

**Laparoscopic surgery for transverse colon cancer**

K. Nagakari, M. Fukunaga, Y. Lee, M. Sugano, Y. Iida, S. Yoshikawa, M. Ouchi, G. Katsuno

Juntendo University, Urayasu Hospital, Urayasu, Japan

**Introduction:** Laparoscopic colon surgery has been widely used. However it is difficult to apply laparoscopic surgery to transverse colon cancer as variation of vascularity is complicated. In randomized trials, the outcomes of laparoscopic surgery were poor. In our hospital, we have been applying laparoscopic surgery for colon resection since 1993. Aiming at minimal invasive surgery for transverse colon cancer, we have recently introduced single port surgery. In this paper, we will report the techniques and outcomes of laparoscopic surgery for transverse colon cancer.

**Material and Methods:** We treated a total of 1,290 colon cancer patients, including 122 transverse colon cancer patients (transverse colon resection in 62 patients, right side colon resection in 52 patients and left side colon resection in 8 patients). To dissect the middle colic artery without damaging the pancreas, surgery must be carried out from both cranial and caudal sides, with the safety zone secured. In treatment for cancer in the left side, as the LCA area must be dissected after the middle colic artery is dissected. We investigated outcomes during surgery, perioperative outcomes, early and late postoperative complications and prognoses when treating cancer in the transverse colon.

**Results:** We treated a total of 1,290 colon cancer patients, including 122 transverse colon cancer patients (transverse colon resection in 62 patients, right side colon resection in 52 patients and left side colon resection in 8 patients). To dissect the middle colic artery without damaging the pancreas, surgery must be carried out from both cranial and caudal sides, with the safety zone secured. In treatment for cancer in the left side, as the LCA area must be dissected after the middle colic artery is dissected. We investigated outcomes during surgery, perioperative outcomes, early and late postoperative complications and prognoses when treating cancer in the transverse colon.

**Conclusion:** As postoperative outcomes were feasible, it is assumed that our surgical techniques were appropriate. However, as surgical techniques vary according to medical institutions and surgeons, laparoscopic surgery should be carried out carefully.

**Abstract ID: 0388** Specific Field: **Colon and Rectum**

**Mode of pres.: Poster Exhibition only**  
**ISW 2011 Session PE 171**

**A study of laparoscopic colectomy for patients with heart disease classified as class 3 patients by the American Society of Anesthesiologists**

W. Onozato, T. Nakamura, M. Watanabe

Kitasato University School of Medicine, 1-15-1, Kitasato, Sagami-hara, Kanagawa, Japan

**Introduction:** Objective: To clarify the safety and appropriateness of laparoscopic colectomy for patients with preoperative heart disease

(Class 3 patients per the American Society of Anesthesiologists' (ASA) classification system).

**Material and Methods:** Subjects: Subjects were 720 patients who underwent colon cancer surgery (405 underwent laparoscopic colectomy and 315 underwent open colectomy) from January 2004 to December 2010. Methods: Of the 405 patients who underwent laparoscopic colectomy, 52 had preoperative heart disease identifying them as ASA Class 3 patients. The surgical outcomes for these 52 patients and their risk factors for postoperative complications were compared.

**Results:** Surgical outcomes for ASA Class 3 patients were favorable, on par with those for patients without heart disease and patients with heart disease who were ASA Class 2 or better. The ASA Class 3 patients also experienced no severe cardiac complications. Class 3 patients per long operation time tended to have a higher incidence of postoperative complications.

**Conclusion:** Laparoscopic colectomy is a useful procedure for patients with preoperative heart disease (ASA Class 3). In Class 3 patients per the NYHA classification, caution is required with regard to the onset of postoperative complications.

**Abstract ID: 0389** Specific Field: **Colon and Rectum**

**Mode of pres.: Poster Exhibition only**  
**ISW 2011 Session PE 172**

**Knacks and pitfall of laparoscopic surgery for locally advanced rectal cancer after neo-adjuvant chemoradiotherapy**

K. Kondo, J. Okuda, K. Tanaka, H. Kayano, M. Yamamoto, K. Asai, S. Masubuchi, N. Tanigawa

Osaka Medical College, Takatsuki-city, Osaka, Japan

**Introduction:** Recently laparoscopy has been recognized as an excellent tool to mobilize the rectum precise to total mesorectal excision (TME) from a view point of its magnification. We have extended our indication of laparoscopic rectal cancer surgery, step by step. For bulky tumor in the rectum, neo-adjuvant chemo-radiation therapy (NACRT) seems to be a good option to shrink the tumor size and to suppress the tumor invasion, which might open the way to laparoscopy.

**Material and Methods:** We have applied NACRT for the T3/T4 adenocarcinoma mainly located in lower rectum since 2006. Our protocol of NACRT as follows: radiation 2 Gy/day 20, 40 Gy in total with 28 days of oral UFT and UZEL. In four to eight weeks after NACRT, Radical resection was performed. Before NACRT we marked the distal edge of the tumor with India Ink injected just 1cm anal to the tumor distal edge, and after NACRT we checked up the marking point.

**Results:** So far we applied NACRT for 62 patients with the bulky T3/T4 rectal cancer. 10 patients (16%) had a clinical complete response, 40 patients (65%) had a clinical partial response, 12 patients (19%) had a clinical stable disease. Rate of toxicity was 32%, but it was limited to Grade1 or Grade2. All patients completed NACRT without any major complications. After NACRT we did radical resection, rate of laparoscopic LAR or SLAR was 56.5%, rate of laparoscopic LRR (ISR or prolapsing method) was 11.3%, rate of laparoscopic Miles operation was 24.2%, rate of open Miles operation was 6.5%, rate of



TPE was 1.5%. After NACRT the marking point with India Ink moved 0.5cm on average. The rate of sphincter saving surgery was 67.8%, and the rate of laparoscopic surgery was 92%. In rectal cancer surgery after NACRT, excessive edema and fibrosis are the adverse effect. Improper dissection leads to the critical bleeding, such as massive bleeding from injured sacral vein. Our energy device system, Probe Plus 2 and VIO Monopolar Soft Coagulation might be an ideal tool to avoid the intra-operative complications. Postoperative complications were as follows: wound infection (13%) and pelvic abscess (1.6%), ileus (3.2%), urinary disturbance (3.2%), however without mortality.

**Conclusion:** With systematic approach and the step-by-step technical tips laparoscopic surgery could be a good option even for the locally advance rectal cancer.

**Abstract ID: 0390** Specific Field: **Colon and Rectum**

**Mode of pres.: Poster Exhibition only**  
**ISW 2011 Session PE 173**

**Laparoscopic treatment of adenocarcinoma of the appendix penetrating in the transverse colon**

S. Baba [1], S. Osamu [2], Y. Minagawa [2], M. Takahashi [2], C. Tono [2], T. Abe [2], A. Sasaki [1], G. Wakabayashi [1]

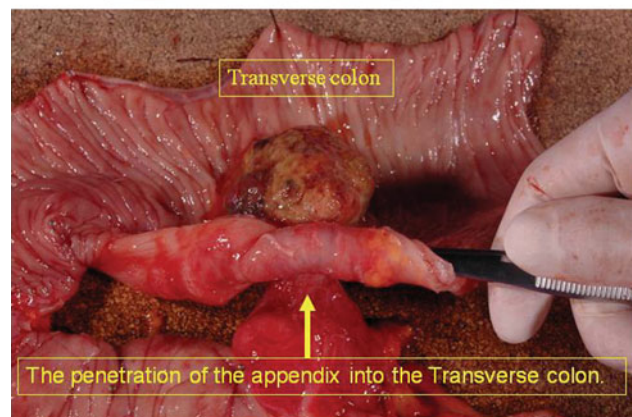
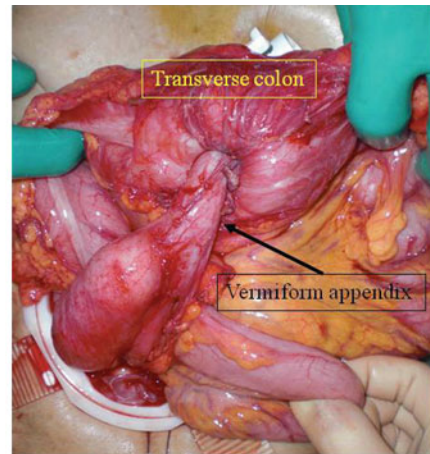
[1] Iwate Medical University, Morioka, Japan, [2] Iwate Prefectural Kuji Hospital, Kuji, Japan

**Introduction:** Adenocarcinoma of the vermiform appendix is a rare neoplasm of the gastrointestinal tract with an incidence of about 0.1–0.2%. Primary appendiceal cancer is diagnosed in 0.9% to 1.4% of appendectomy specimens. Age-adjusted incidence of cancer of the appendix is 0.12 cases per 1,000,000 per year. These rare tumors are seldom suspected before surgery, and <1/2 are diagnosed intraoperatively. The most common presentation of appendiceal malignancy is right lower abdominal pain that often mimics acute appendicitis. Right iliac fossa mass and intestinal obstruction have also been reported; these presentation reflect various stages of a locally expanding tumor causing luminal obstruction of the appendix. Presentation caused by loco-regional spread with involvement of adjacent structures is rare.

**Material and Methods:** There are other clinical presentations, and we report herein a case of appendicular adenocarcinoma found unexpectedly in a patient who presented to the gastroenterology unit with positive fecal occult blood test. The patient is a 83-year-old lady admitted with anemia and positive fecal occult blood test due to the transverse colon carcinoma. When we inserted the laparoscope in to the intraperitoneal, the vermiform appendix had already been penetrated into the transverse colon. Consequently we performed laparoscopic assisted right en block hemicolectomy.

**Results:** Operation time was 170 min, and estimated blood loss was 70 ml. The postoperative course was uneventful. First flatus was recognized on the third postoperative day, a solid diet was started on the fourth postoperative day, and the patient was discharged and went directly home on the eighth postoperative day. Histopathological examination showed well differentiated adenocarcinoma > mucinous carcinoma of the appendix with infiltration of the transverse colon of about 4 cm. Staging was T4N1M0. The patient seen 7 months after surgery was in good general condition with no complications.

**Conclusion:** Based on a review of the literature, this is the first reported case of an appendiceal malignancy presenting and being treated in this manner (Figure).



**Figure:** The penetration of the appendix into the Transverse colon

**Abstract ID: 0391** Specific Field: **Colon and Rectum**

**Mode of pres.: Poster Exhibition only**  
**ISW 2011 Session PE 174**

**Laparoscopic surgery for colon cancer in obese patients: a case-matched control study**

T. Nakamura, W. Onozato, M. Watanabe

Department of Surgery, Medical School, Kitazato University, Sagami-hara, Japan

**Introduction:** Long-term outcomes after laparoscopic surgery for colon cancer in obese patients remain unknown. We compared the results of laparoscopic surgery for colon cancer in obese patients with a body-mass index (BMI) of 25 kg/m<sup>2</sup> or higher with those in non-obese patients (BMI, less than 25 kg/m<sup>2</sup>) who were matched for clinicohistopathological factors. Our main objective was to determine whether laparoscopic colectomy is warranted in obese patients with colon cancer.

**Material and Methods:** The study group comprised patients with stage I to III colon cancer treated by laparoscopic surgery from 1995 through 2006. Oncologic outcomes were compared between 140 patients with a BMI of 25 kg/m<sup>2</sup> or higher (obese group) and 140 patients with a BMI of less than 25 kg/m<sup>2</sup> (nonobese group) who were matched for sex, tumor location, date of operation ( $\pm$  5 years), and pathological tumor-node-metastasis (pTNM) stage.



**Results:** BMI was significantly higher in the obese group than in the nonobese group ( $P < 0.001$ ). The operation time was significantly longer in the obese group than in the nonobese group ( $P < 0.001$ ). The rate of conversion to open surgery was similar in the obese group (1.4% [2/140]) and the nonobese group (2.1% [3/140]). The proportion of patients with postoperative complications was significantly higher in the obese group (15% [21/140]) than in the nonobese group (6% [9/140],  $P = 0.034$ ). Wound infections were significantly more common in the obese group than in the nonobese group ( $P = 0.035$ ). Initial sites of tumor recurrence were similar in both groups. No port site recurrence occurred in either group. In patients with stage I or II disease, the disease-free survival rate and overall survival rate were similar in the obese group (98.6% and 98.8%, respectively) and the nonobese group (97.8% and 97.8%, respectively). In patients with stage III disease, the disease-free survival rate and overall survival rate also did not differ significantly between the obese group (77.2 and 79.4%, respectively) and the nonobese group (83.4% and 84.9%, respectively).

**Conclusion:** Postoperative complications and long-term oncologic outcomes were similar in obese patients and nonobese patients who underwent laparoscopic colectomy for colon cancer in our hospital. Our results suggest that laparoscopic surgery is warranted in obese patients with colon cancer.

Table Table 1 Table 2 Table 3.

#### Abstract ID: 0392 Specific Field: Colon and Rectum

**Mode of pres.: Poster Exhibition only**  
ISW 2011 Session PE 175

#### Complete laparoscopic operation for colorectal cancer (CLOC): non-laparotomy laparoscopic surgery

S. Endo, J. Tanaka, S. Kudo, E. Hidaka, K. Ikehara, T. Omoto, K. Nakahara, F. Ishida

Showa University Northern Yokohama Hospital, Yokohama, Japan

**Introduction:** Complete Laparoscopic Operation for Colorectal Cancer (CLOC) is totally laparoscopic procedure without additional minimal laparotomy and its procedure can be performed without intra-peritoneal exposure of the intestinal lumen, where intra-abdominal bacterial contamination or cancer cells dissemination can be free. Aim of this study is to report our early clinical experience of CLOC for the patients with sigmoid colon cancer and rectal cancer.

**Material and Methods:** CLOC was introduced in 10 patients. These patients have received endoscopic mucosal resection (EMR) for T1 tumor before surgery and pathology revealed deep infiltration into submucosal layer. Additional bowel resection and lymph node dissection was indicated. Vascular dissection for lymph node dissection and bowel mobilization were performed under laparoscopy similar to the conventional Laparoscopic-assisted colectomy (LAC) procedure. Mesocolon around the proximal and distal cutting line were dissected with bipolar sealing device or ultrasonic device. Anvil head of the auto-suturing circular stapling device with a spear was gently inserted through anus by using a long laparoscopic rigid instrument into the proximal part of the colon beyond the proximal cutting line, and then proximal part of the colon was dissected with endoscopic linear stapler under laparoscopy. Distal stapling line was grasped laparoscopic forceps through the anus and prolapsed outside the body. Scar lesion after EMR was detected and distal cutting line was dissected with linear stapler under direct vision. Then distal bowel was pushed back into the pelvic space, followed intra-corporeal anastomosis with Double stapling technique.

**Results:** COLC was successfully performed on these colorectal cancer patients without postoperative complications.

**Conclusion:** CLOC was totally laparoscopic “minimal laparotomy-less” procedure without intra-peritoneal exposure of the intestinal lumen and it was feasible and safe when performed by experienced laparoscopic surgeons.

#### Abstract ID: 0393 Specific Field: Colon and Rectum

**Mode of pres.: Poster Exhibition only**  
ISW 2011 Session PE 176

#### Surgical outcome of laparoscopic surgery for colorectal cancer in Toranomon hospital

J. Moriyama, H. Kuroyanagi, S. Matoba

Toranomon Hospital, Tokyo, Japan

**Introduction:** Purpose: In our hospital, laparoscopic surgery (LS) for colorectal cancer has been performed since 1997. The total number of LS counts over 1,600. The aim of this study is to verify whether LS for colorectal cancer is not inferior to conventional open method (OM).

**Material and Methods:** Methods: We compared 1613 LS cases with 988 OM cases. We selected the cases to observe post-operative complications and long-term prognosis. Right hemicolectomy for cecum and ascending colon cancers were grouped as (C&A), sigmoidectomy for sigmoid colon cancers were grouped as (S) and anterior resection for rectum cancers were grouped as (R).

**Results:** Intra-operative accident by LS was 1.5% and conversion to OM was 1.9%. As for complication, post-operative bowel obstruction was 4.1% (LS) and 7.4% (OM). 5-year-survival rate was as follows, stage II of C&A was 95% (LS) and 93% (OM). S was 98% (LS) and 93% (OM), and R was 97% (LS) and 91% (OM). Stage III of C&A was 95% (LS) and 82% (OM), S was 94% (LS) and 85% (OM), and R was 82% (LS) and 79% (OM).

**Conclusion:** LS is acceptable according to the results of short-term prognosis. There was no apparent aggravation tendency in cumulative survival rate in LS cases as compared to OM cases.

#### Abstract ID: 0394 Specific Field: Colon and Rectum

**Mode of pres.: Poster Exhibition only**  
ISW 2011 Session PE 177

#### Short-term outcomes with open surgery and laparoscopic surgery for colon cancer in patients aged 75 years and older

S. Imai, T. Kanai, M. Nakagawa

Hiratsuka City Hospital, Hiratsuka, Japan

**Introduction:** With the aging of society, the number of elderly patients undergoing colon cancer surgery is increasing. However, in elderly patients, prolonged hospitalization due to postoperative complications or decrease in ADL can greatly impede their return to society. Recently, laparoscopic colectomy has become actively performed, and laparoscopic surgery in elderly patients is also increasing. In this study, the short-term outcomes with open surgery and laparoscopic surgery for colon cancer in elderly patients (75 years old) were investigated.

**Material and Methods:** This study included 133 elderly patients (age 75 years) who underwent elective colon cancer surgery (open surgery, group A, 111 patients; laparoscopic surgery, group B, 22 patients) at our hospital between April 2006 and September 2010.

**Results:** In group A, the median age was 81 (75–93) years; there were 57 men and 54 women. In group B, the median age was 77.5 (75–85)

years; there were 14 men and 8 women. Operative time and blood loss were 224 (78–508) min and 234.5 (0–3210) ml, respectively, in group A and 307.5 (163–594) min and 109 (0–576) ml, respectively, in group B. Postoperative complications occurred in 27 (24.3%) group A patients (wound infection 13, bowel obstruction 4, anastomotic leakage 4, pneumonia 3, cholecystitis 2, urinary tract infection 1, cardiac failure 1, and renal failure 1) and in 4 (18.2%) group B patients (wound infection 2, perineal infection 1, and anastomotic leakage 1). Complications requiring reoperation occurred in 2 (1.8%) group A patients (anastomotic leakage 1, bowel obstruction 1) and no group B patients. Postoperatively, the day that IV infusion was discontinued was day 10 (5–75) in group A and day 6.5 (5–36) in group B. The length of hospital stay was 25 (9–136) days in group A and 17.5 (11–48) days in group B.

**Conclusion:** In elderly patients (age 75 years) with colon cancer, laparoscopic surgery required longer operative time than open surgery, but blood loss was less. In addition, postoperative complications were relatively few, which may have contributed to a shorter hospital stay.

### Abstract ID: 0395 Specific Field: Colon and Rectum

**Mode of pres.: Poster Exhibition only**  
**ISW 2011 Session PE 178**

#### Indication of laparoscopic surgery for colon cancer

M. Nakanishi, Y. Kokuba, Y. Murayama, Y. Kuriu, D. Ichikawa, K. Okamoto, T. Ochiai, E. Otsuji

Kyoto Prefectural University of Medicine, Kyoto, Japan

**Introduction:** Since June 2007, our indication of laparoscopic surgery for colon cancer is stage 0 to III colon cancer. To evaluate the indication, we analyze short term result after laparoscopic surgery for colon cancer.

**Material and Methods:** The colon cancer removed by laparoscopic surgery by May, 2010 from June, 2007 was 291 cases. Location of tumors; appendix: 5, cecum: 27, ascending colon: 48, transverse colon: 26, descending colon: 14, sigmoid colon: 116, rectosigmoid colon: 55. Pathological stage was as follows. Stage 0: 24, I: 82, IIA: 65, IIB: 21, IIIA: 15, IIIB: 33, IIIC: 21, IV:30.

**Results:** The median follow-up was 578 days and there were 28 distant metastases (10.6%) during follow-up, but no port-site or local recurrence. The recurrence rate of each stage is as follows. Stage 0: 0% (0/24), I: 3.6% (3/82), IIA: 6.2% (4/65), IIB:14.3% (3/21), IIIA: 0% (0/15), IIIB: 24.2% (8/33), IIIC: 47.6% (10/21). The survival rate of each stage is as follows. Stage 0:100% (24/24), I: 97.6% (80/82), IIA: 100% (65/65), IIB: 100% (21/21), IIIA: 100% (15/15), IIIB: 90.9% (30/33), IIIC: 85.7% (18/21), IV: 73.3% (22/30). In these cases, 13 cases(4.4%) were converted to open surgery. The reason that did convert is invasion to adjacent organs (7 cases), adhesion (4 cases), peritoneal dissemination (1 case), and bleeding (1 case).

**Conclusion:** It is thought that our indication is proper from a relapse rate and a survival rate, but the examination of longer-term results is necessary.

### Abstract ID: 0396 Specific Field: Colon and Rectum

**Mode of pres.: Poster Exhibition only**  
**ISW 2011 Session PE 179**

#### Laparoscopic surgery after preoperative chemoradiation therapy for advanced rectal cancer is a safe and feasible option

T. Miyatani, M. Shimada, N. Kurita, M. Nishioka, S. Morimoto, K. Yoshikawa, H. Kashihara, C. Mikami

Tokushima University, Tokushima, Japan

**Introduction:** Preoperative chemoradiation therapy (CRT) for low rectal cancer reduces local recurrence and increases anal sphincter preservation rate. On the other hand, Laparoscopic surgery for advanced colon cancer has been widely accepted. A few studies have shown that there are advantages of laparoscopic over open TME surgery for rectal cancer. However, the feasibility of laparoscopic surgery for T3 and T4 rectal cancer has not been clearly defined specifically in cases following preoperative CRT. The aim of this study was to investigate the feasibility of laparoscopic surgery after preoperative CRT for T3 and T4 rectal cancer.

**Material and Methods:** May 2003 and July 2009, 58 patients (T3:  $n = 51$ , T4:  $n = 7$ ) who underwent preoperative CRT for rectal cancer were identified. Forty-three patients with laparoscopic surgery (Lap group) were compared with 14 patients with open surgery (Open group). Peri-operative data including post-operative morbidity were assessed between the two groups.

**Results:** Except for age there was no difference between the two groups based on gender, BMI, tumor size, tumor distance from the anal verge, T stage, N stage and procedure. All patients underwent complete laparoscopic operations and none were converted to laparotomy. Operating time was longer in the Open group (331 vs. 375 min,  $P < 0.01$ ). Blood loss during the operation decreased in the Lap group (160 vs. 316 min,  $P < 0.01$ ). Lymph node harvest (10 vs. 11) and morbidity rate (21 vs. 29) were similar in both groups. The distal tumor margin was negative in all patients. No patients had peri-operative mortality associated with surgery after CRT. Postoperative hospital stay was shorter in the Lap group (28 vs. 38 days,  $P < 0.01$ ). Laparoscopic procedures: Our video will show knock and pitfalls of laparoscopic surgery after preoperative CRT. First point is the tension between rectum and sacrum by operator's left hand for total mesorectal excision. Secondary point is the complete preservation of neurovascular bundle to avoid bleeding. Third point is the careful attention to edema and adhesion by CRT for keeping accurate dissected layer.

**Conclusion:** Laparoscopic surgery after preoperative CRT is a feasible and a safe option for T3 and T4 rectal cancer compared to conventional open surgery.

### Abstract ID: 0397 Specific Field: Colon and Rectum

**Mode of pres.: Poster Exhibition only**  
**ISW 2011 Session PE 180**

#### Short term results of laparoscopic rectal cancer resection in elderly patients

T. Ishii [1], S. Yamaguchi [1], J. Tashiro [1], T. Satou [1], M. Miyazawa [1], I. Kayama [1], N. Shinozuka [2]

[1] Saitama Medical University, International Medical Center, Hidaka, Japan, [2] Saitama Medical University, Moroyama, Japan

**Introduction:** Purpose: Since April 2007 of hospital opening, we tried to perform laparoscopic resection for elderly rectal cancer patients as young patients. This study was assessed short term results for recent 3 years.

**Material and Methods:** Patients: Sixty-six patients (46 males, 20 females, average 63.5 years old) of laparoscopic curative rectal cancer resection were included in this study. All procedures were low anterior resection (LAR). There were 49 patients younger than seventy years old (36 males, 13 females, average 59.7 years old, range 34 to 69) and 17 patients seventy years old or more (10 males, 7 females, average 74.6 years old, range 70 to 85).

**Results:** There were no motility and all patients returned to normal daily life after surgery. There was no difference in patients characteristics

(pathological stage, lymph node resection, location, body mass index) between both group. Mean operating time, blood loss count, and postoperative hospital stay were 268.2 min, 18.2 g, 10.0 days in elderly patients, 268.0 min, 34.8 g, 9.0 days in younger patients, respectively. Postoperative complication rates were 35.3% (anastomotic leakage 17.6%, anastomotic bleeding 11.8%) in elderly group, and 34.7% (anastomotic leakage 16.3%, SSI 6.1%, urinary disturbance 6.1%, anastomotic bleeding 4.1%). There were no significant differences in mean operating time, blood loss, postoperative hospital stay, postoperative complications between elderly and younger patients.

**Conclusion:** Short term results of laparoscopic LAR were similar in 70 years old or more and less patients. Laparoscopic LAR for elderly patients was feasible.

**Abstract ID: 0398** Specific Field: **Colon and Rectum**

**Mode of pres.: Poster Exhibition only**  
**ISW 2011 Session PE 181**

**Short-term outcome after introduction of the laparoscopic-assisted surgery in patients with colorectal cancer in our hospital**

K. Hosoda, M. Kojima, M. Aoki, H. Kido, H. Tamura, T. Amemiya  
Ohtawara Red Cross Hospital, Ohtawara, Japan

**Introduction:** Although laparoscopic-assisted surgery has spread quickly as a standard technique to colorectal cancer, the gap between institutions exists in an indication and postoperative outcome in regional general hospitals. We report the short-term outcome of the early days after introducing laparoscopic-assisted surgery in colorectal cancer in our hospital.

**Material and Methods:** 29 patients of colorectal cancer who underwent laparoscopic-assisted surgery during October, 2009 and December, 2010 were included. The indication of laparoscopic-assisted colorectal surgery in our hospital, is that the tumor is located from the cecum to right side of the transverse colon, and is located from distal part of the descending colon to upper part of the rectum. Exclusion criteria were intestinal obstruction, huge tumor, adjacent organ invasion. The operator and the first assistant were fixed.

**Results:** The median age of the patients was 73 years (range, 50–83). The operations were right colectomy ( $n = 10$ ), transverse colectomy ( $n = 2$ ), sigmoid colectomy ( $n = 5$ ), and anterior resection ( $n = 12$ ). The median operating time was 190 min (range 135–380), the average blood loss was 94 ml (range 0–1390), and the average length of the incision was 5.1 cm (range, 3.0–7.0). Two patients required conversion to open surgery. The median hospital stay was 12 days (range, 9–35). 7 (24%) patients had post operative complications. 1 (3%) patient died in hospital because of pulmonary embolism. The median number of lymph nodes examined was 16 (range, 7–55).

**Conclusion:** Laparoscopic-assisted surgery can be applied safely to colorectal cancer in regional general hospital. However, since 1 patient died from pulmonary embolism, we should pay attention to the prophylaxis of pulmonary embolism. And, in the early stage after introduction of laparoscopic-assisted surgery, it is important to fix the members of the surgical team

**Abstract ID: 0399** Specific Field: **Colon and Rectum**

**Mode of pres.: Poster Exhibition only**  
**ISW 2011 Session PE 182**

**Laparoscopic Intersphincteric resection for very low rectal cancer.**

H. Samura, E. Nozato, T. Nishimaki  
University of Ryukyus, Nishihara-cho, Japan

**Introduction:** We indicate laparoscopic surgery for colorectal cancer, which have no lymph node metastasis and lower rectal operative procedure was limited to Low Anterior Resection. Recently, indication of laparoscopy associated surgery for rectal cancer is developed to the very lower site of rectum. With this development, we start the operation of laparoscopic Intersphincteric resection (ISR) for very low rectal cancer.

**Material and Methods:** From 2004 to 2010, 42 patients with very low rectal cancer underwent ISR. In which, nine patients underwent laparoscopic ISR. Under lithotomy position Laparoscopic ISR was performed with using 5 ports of trockers. Extents of Lymphadenectomy depend on depth of tumor. Diverting ileostomy was made in all patients. We report the feasibility and safety of laparoscopic ISR with inspection of operative result and postoperative complication.

**Results:** Nine patients underwent laparoscopic ISR. One patient was after Endoscopic mucosal resection, and others were primary case. Six were men and mean age was 74.8 years (range, 61–87 years). The median tumor size was 30.9 mm (range, 13–52 mm) and the median distance from dentate line was 9.6 mm (range, 3–20mm). Four patients had clinical T1 tumor, 4 patients had clinical T2 tumor and one patient had clinical T3 tumor. Preoperative image study reveals no patients had obvious lymph node metastasis. No patient was converted to open surgery. The median operation time was 519 min (range, 419–612 min), and median estimate blood loss was 208 ml (range, 30–449 ml) and no patient required blood trans fusion. There was no mortality. Postoperative complication occurred in three patients, two anastomotic leakages and two neurogenic bladders. Two anastomotic leakage required trans anal repair. Eight of 9 patients had stoma closure. Three of 8 patients who underwent stoma closure had soiling, but all of them won't have colostomy. The elder patients were more with stoma less status. Although follow up period were short, there was no recurrent patient.

**Conclusion:** Laparoscopic ISR can feasibly carry out safety with favorable short-term postoperative outcomes.

**Abstract ID: 0400** Specific Field: **Colon and Rectum**

**Mode of pres.: Poster Exhibition only**  
**ISW 2011 Session PE 183**

**A new approach to laparoscopic lymph node excision in cases of transverse colon cancer**

M. Nakanishi, Y. Kokuba, Y. Murayama, Y. Kuriu, E. Otsuji,  
T. Sonoyama, T. Ochiai, K. Okamoto

Kyoto Prefectural University of Medicine, Kyoto, Japan

**Introduction:** Treatment of transverse colon cancer by laparoscopic surgery is difficult, and this surgery has been excluded in many randomized control trials. Difficulty in excising lymph nodes around the middle colonic artery has been the main factor responsible for the complexity of this surgery. Herein, we describe a new approach to overcome this difficulty in lymph node excision in cases of transverse colon cancer.

**Material and Methods:** We adopted the following steps to collect information that was otherwise difficult to obtain from two-dimensional images displayed on the monitor screen, in order to ensure safety during laparoscopic surgery.

**Results:** 1. The omental bursa was opened by directly visualizing it through a small incision created in the median epigastric region, and the cranial side of the transverse colon mesentery was freed thereafter. 2. The colonic drainage vein entering the right gastroepiploic vein was dissected, and a gauze was inserted into the freed layer. 3.

Under laparoscopic guidance, the freed layer was fixed, with the inserted gauze serving as a landmark. Then, lymph nodes were excised by making full use of the horizontal view.

**Conclusion:** Utilization of a small incision in the abdomen enables full use of the horizontal view for manipulations during laparoscopy, allowing safe manipulations for lymph node excision.

**Abstract ID: 0401** Specific Field: **Colon and Rectum**

**Mode of pres.: Poster Exhibition only**  
**ISW 2011 Session PE 184**

**A study of short-term outcomes of laparoscopic surgery for colorectal cancer in aged patients over 80 in our department**

T. Hatakeyama [1], M. Nakanishi [1], Y. Kokuba [1], Y. Kuriu [2], K. Okamoto [2], T. Ochiai [2], Y. Kokuba [2], E. Otsuji [2]

[1] Kyoto Prefectural University of Medicine, Kyoto, Japan,  
[2] Kyoto Prefectural University of Medicine, Japan

**Introduction:** Elderly patients represent a unique surgical challenge because of the associated complex comorbidity and diminished cardiopulmonary reserve. Therefore, minimally invasive surgery in the elderly may have a larger impact. However, the short-term outcomes of laparoscopy-assisted colectomy (LAC) compared to open colectomy (OC) in the elderly, especially over 80 years old, have not been fully evaluated. The aim of this study was to retrospectively evaluate the safety and benefit of LAC compared to OC in patients over 80 years of age in our department.

**Material and Methods:** 63 patients over 80 years of age with colorectal cancer were divided into two groups: OC (28 cases) and LAC (35 cases). Demographic details, operative time, blood loss, resumption to oral diet, postoperative hospital stay, postoperative complications (anastomotic leak, surgical site infection (SSI), postoperative delirium) were recorded.

**Results:** There were no significant differences between the groups with respect to age, sex, colon/rectal cancer ratio, and final stage. Mean operating time resulted  $199.8 \pm 59.5$  min in the LAC group and  $189.2 \pm 71.3$  min in the OC group ( $P > 0.05$ ). Intraoperative blood loss was significantly lower for the LAC group (42 ml) than for the OC group (174 ml,  $P = 0.0002$ ). The LAC group presented resumption to oral diet after 3 days whereas OC group after 5 days ( $P = 0.005$ ). There were no significant differences between the groups with respect to postoperative hospital stay and postoperative complications.

**Conclusion:** Our retrospective study suggests that LAC in over 80 years old patients with complex comorbidity is as safe and effective as OC.

**Abstract ID: 0402** Specific Field: **Colon and Rectum**

**Mode of pres.: Poster Exhibition only**  
**ISW 2011 Session PE 185**

**Long-term results of laparoscopic surgery for advanced rectal cancers**

E. Hidaka, F. Ishida, S. Endo, Y. Takehara, T. Omoto, N. Sawada, J. Tanaka, S. Kudo

Showa University Northern Yokohama Hospital, Yokohama, Japan

**Introduction:** Laparoscopic surgery for rectal cancers has been widely accepted by degrees, however, it was not enough clear about the long-term results for this operation, especially for advanced cases. We would like to examine the long-term outcomes after laparoscopic resection for advanced rectal cancers.

**Material and Methods:** A total forty-eight patients with advanced rectal cancers underwent laparoscopic resection were reviewed. Thirty-five patients have upper rectal cancers and thirteen have lower rectal cancers. The indication of laparoscopic surgery for lower rectal cancer was mainly T2 tumor, partly T3 tumor without laterally lymph node swelling. We analyzed concerning the clinicopathological data, the factors about surgical procedure, a recurrence and prognosis.

**Results:** There were nineteen patients with T2 tumor, twenty-eight with T3 and one with T4. The average distal margin from the tumor was 48.1mm at upper rectal cancers and 28.4mm at lower. Average operating times were 285min at upper rectal cancers, 356min at lower and mean intra-operative blood losses were 165ml at upper, 358ml at lower. The operation time and blood loss in lower rectal cancers were longer and more than in upper, significantly. Lymph nodes metastasis was detected at 51.4% of upper rectal cancers and at 23% of lower. As for the complications, it was occurred at 14.3% in upper rectal cancers, and at 46.2% in lower. These complications concerning the anastomosis, for example leakage, stenosis and bleeding of the anastomotic portion were mainly occurred in these cases. The complication was more occurred in lower rectal cancer than upper. Regarding a recurrence after operation, these rates were 28.6% at upper rectal cancers and 23.1% at lower. Local and anastomotic recurrences were rare. Five-year survival rate were 90.9% in upper rectal cancers and 83.3% in lower. Both two groups were high rate. Disease free survival rate were 63.6% at upper rectal cancers and 76.9% at lower. Therefore, the long-term results in laparoscopic surgery for rectal cancers were almost equal to in open surgery reported previously.

**Conclusion:** Laparoscopic resection for advanced upper rectal cancers and T2 lower rectal cancers were feasible.

**Abstract ID: 0403** Specific Field: **Colon and Rectum**

**Mode of pres.: Poster Exhibition only**  
**ISW 2011 Session PE 186**

**Internal hernia diagnosed of compressing portal vein flow after laparoscopy-assisted colectomy**

A. Ishibe, S. Yamagishi, S. Kaida, E. Inoue, W. Sano, K. Matsuo, K. Misuta, A. Nakano

Fujisawa City Hospital, Fujisawa, Japan

**Introduction:** We report a patient with internal hernia through the mesenteric defect after laparoscopy-assisted colectomy.

**Results:** A 82-year-old woman underwent laparoscopy-assisted transverse colectomy for transverse colon cancer. She discharged the hospital without complications. On postoperative day 92, she presented with upper abdominal pain. Plain abdominal radiography showed no bowel obstruction. The laboratory data revealed liver dysfunction, and computed tomography showed a twisting bowel and mesenteric vessel. We conducted open surgery by a diagnosis of internal hernia. The small intestine was passed in the omental bursa through the mesenteric defect which had not been closed in the



previous operation, and in the Morrison's pouch via the dorsal of hepato-duodenal ligament. The portal vein was compressed by this intestine. After drawing the small intestine from the mesenteric defect, intestine resection was avoided because the herniated intestine had no ischemic change.

**Conclusion:** Internal hernia following laparoscopy-assisted colectomy is rare, more studies are required to determine the indication for closure of the mesenteric defect causing laparoscopic surgery.

**Abstract ID: 0404** Specific Field: **Colon and Rectum**

**Mode of pres.: Poster Exhibition only**  
**ISW 2011 Session PE 187**

**Early experience of single-incision laparoscopic surgery for Crohn's disease**

K. Maeda, H. Nagahara, E. Noda, K. Muguruma, H. Tanaka, N. Kubo, M. Ohira, K. Hirakawa

Osaka City University Graduate School of Medicine Dept. of Surgical Oncology, Osaka, Japan

**Introduction:** Recently, single-incision laparoscopic surgery (SILS) offers excellent cosmetic results compared with standard multiport laparoscopic surgery. We herein report our early experience with SILA for eight patients with Crohn's disease.

**Material and Methods:** The patients were indicated for surgery by the presence of ileocolic Crohn's disease with strictures. A 3.5 mm intraumbilical incision was created and the SILS Port<sup>TM</sup> was introduced to the abdomen. Three 5-mm SILS Port trocal were introduced through the access channels. Mobilization of the cecum and the ascending colon was performed thoroughly intracorporeally. After mobilization, diseased bowel was delivered through the umbilical incision. Bowel resection and anastomosis were performed extracorporeally.

**Results:** Mean operative time and blood loss were 153 min and 87 ml, respectively. The procedures could be completed with additional ports or conversion to open operation. There was no intra- or postoperative morbidity. The operative scar was invisible in 1 month.

**Conclusion:** Single-incision laparoscopic ileocecal resection for Crohn's disease may be safe and feasible in some selected patients.

**Abstract ID: 0405** Specific Field: **Colon and Rectum**

**Mode of pres.: Poster Exhibition only**  
**ISW 2011 Session PE 188**

**A randomized phase II study of modified OPTIMOX1 or FOLFOX**

S. Morimoto, M. Shimada, N. Kurita, T. Iwata, M. Nishioka, K. Yoshikawa, T. Miyatani

University of Tokushima, Tokushima, Japan

**Introduction:** A combination of leucovorin (LV) and fluorouracil (FU) with oxaliplatin (FOLFOX) is a standard first-line regimen for advanced or unresectable colorectal cancer. Sensory neurotoxicity is its dose-limiting toxicity, but the OPTIMOX1 (stop and go) approach offers a reasonable strategy. This study evaluates a new strategy of intermittent oxaliplatin treatment that is based on FOLFOX4 or

modified FOLFOX6 ( $\pm$  bevacizumab), a simplified leucovorin and fluorouracil regimen with normal-dose oxaliplatin.

**Material and Methods:** Previously untreated patients were randomly assigned to either FOLFOX administered every 2 weeks until progression (arm FOL) or FOLFOX for six cycles, maintenance without oxaliplatin for six cycles, and continued every six cycles until progression (arm OPT).

**Results:** Sixty patients (arm FOL ( $n = 35$ ), arm OPT ( $n = 33$ )) were enrolled. The median number of treatment cycles was 10 (range, 3–28) in arm FOL and 12.5 (range, 1–32) in arm OPT. Cumulative dose of oxaliplatin was 850 mg/m<sup>2</sup> in arm FOL and 552.5 mg/m<sup>2</sup> in arm OPT. Median progression-free survival was 8.5 months in patients allocated to arm FOL compared with 15 months in patients allocated to arm OPT. Response rates evaluated by RECIST criteria were 50% with arm FOL and 64% with arm OPT. National Cancer Institute Common Toxicity Criteria grade 3 toxicity was observed in 37.1% of the patients in arm FOL and 24.0% of patients in arm OPT. Grade 3 sensory neuropathy was observed in 22.8% of the patients in arm FOL and 6% of patients in arm OPT.

**Conclusion:** Our modified OPTIMOX1 regimen may be effective and safe treatment to prevent oxaliplatin-induced neuropathy in advanced or unresectable colorectal cancer patients.

**Abstract ID: 0406** Specific Field: **Colon and Rectum**

**Mode of pres.: Poster Exhibition only**  
**ISW 2011 Session PE 189**

**Data acquisition for histoculture drug response assay in colorectal cancer using surgically resected pulmonary metastatic lesions**

T. Yoshimasu, S. Oura, F. Ohta, Y. Hirai, K. Naito, H. Nishiguchi, S. Hashimoto, Y. Okamura

Department of Thoracic and Cardiovascular Surgery, Wakayama Medical University, Wakayama, Japan

**Introduction:** Lung is a common target organ in colorectal cancer metastasis. Surgical resection of pulmonary metastasis is well known to be effective to improve prognosis of the patients. Histoculture drug response assay (HDRA) is a representative in vitro drug-response assay method used for anticancer agents. Several clinical studies involving colorectal cancer revealed that inhibition rates obtained using HDRA can predict clinical responses to chemotherapy. Pulmonary metastases might show different chemosensitivity profile from primary tumors. We investigated chemosensitivity of pulmonary metastatic lesions of colorectal cancer using HDRA.

**Material and Methods:** From 1995 to 2010, HDRA data were obtained from 34 surgically resected specimens of colorectal cancer pulmonary metastasis. We examined chemosensitivities of the tissues to cisplatin (CDDP), 5-fluorouracil (FU), doxorubicin (ADM), mitomycin C (MMC), docetaxel (DOC), paclitaxel (PTX), etoposide (VP-16), irinotecan (CPT-11), and gemcitabine (GEM). Cut-off inhibition rates of them were 50, 60, 60, 70, 50, 70, 50, 50, and 30%, respectively.

**Results:** HDRA was not successful only in 2 patients because of low viability of the tumor. Evaluability of HDRA was high at 94.1%. Inhibition rates of CDDP, FU, ADM, MMC, DOC, PTX, VP-16, CPT-11, and GEM were measured in 27, 29, 23, 25, 22, 17, 28, 21, and 17 patients, respectively. All drugs were not tested in each patient

because of the small specimens. Average inhibition rates of them were  $32 \pm 19\%$  (CDDP),  $44 \pm 23\%$  (FU),  $23 \pm 22\%$  (ADM),  $49 \pm 27\%$  (MMC),  $30 \pm 24\%$  (DOC),  $49 \pm 32\%$  (PTX),  $27 \pm 26\%$  (CPT-11),  $28 \pm 20\%$  (VP-16),  $15 \pm 12\%$  (GEM). Positive rate of each drug was 11.1%, 31.0%, 8.7%, 24.0%, 22.7%, 47.0%, 25.0%, 14.3%, and 5.9%. They were relatively low when they were compared with the HDRA results of primary colorectal cancer.

**Conclusion:** HDRA results in this study revealed that most pulmonary metastatic nodules were highly resistant for chemotherapy agents. It might be caused by adjuvant chemotherapy, which preceded pulmonary metastasectomy. However, HDRA using surgical specimens may propose some effective chemotherapy protocols in patients with colorectal cancer pulmonary metastasis.

#### Abstract ID: 0407      Specific Field: Colon and Rectum

Mode of pres.: Poster Exhibition only  
ISW 2011 Session PE 190

##### Bevacizumab combined with chemotherapy against metastatic colorectal cancer

T. Godai [1], S. Fujii [1], K. Watanabe [1], T. Oshima [1], Y. Rino [2], C. Kunisaki [1], M. Masuda [2], T. Imada [2]

[1] Yokohama City University MedicalCenter, Yokohama, Japan,  
[2] Yokohama City University, Yokohama, Japan

**Introduction:** To clarify the safety and efficacy of chemotherapies with and without Bevacizumab(BV) as first-line chemotherapy for metastatic colorectal cancer on outpatients setting.

**Material and Methods:** A series of 55 patients with metastatic colorectal cancer, who received FOLFOX±BV therapy in our hospital, were enrolled in this study. The patients were divided into the BV combination group (29 patients) and the non-BV combination group (26 patients). Response rate, progression-free survival, and overall survival were compared between the two groups.

**Results:** The response rate was 34% (CR:2, PR:8, SD:14, PD:5) in the BV combination group and 23% (PR:6, SD:11, PD:8) in the non-BV combination group. The median progression-free survival were 7.7 months in the BV combination group and 5.5 months in the non-BV combination group ( $P = 0.06$ ). The median overall survival were 32.4 months in the BV combination group and 25.0 months in the non-BV combination group ( $P = 0.37$ ). There were no significant differences in survivals between the two groups. BV-associated adverse events were proteinaceous urine (17 patients), hypertension (12 patients) and nasal bleeding (7 patients), but there was no adverse events of grade 3 or higher.

**Conclusion:** The efficacy of FOLFOX with BV as first-line chemotherapy was not admitted. To clarify the efficacy of FOLFOX with BV for advanced colorectal cancer, a comparative study should be conducted in a large number of patients.

#### Abstract ID: 0408      Specific Field: Colon and Rectum

Mode of pres.: Poster Discussion  
ISW 2011 Session PE 191

##### Two Cases of unresectable colorectal cancer with long-term survival treated by UFT/CPT-11

T. Sato, T. Nakamura, M. Naito, N. Ogura, A. Ikeda, A. Ooki, W. Onozato, M. Watanabe

Kitasato University School of Medicine, Sagami-hara, Japan

**Introduction:** Dramatic prolongation of the survival of patients with progressive or recurrent colorectal cancer has been achieved by multidrug chemotherapy, using agents such as continuous 5-FU and LV, CPT-11, L-OHP, Bevacitumab, and Cetuximab, although we could not undertake L-OHP, Bevacitumab and Cetuximab in Japan until recently. Since chemotherapy for unresectable colorectal cancer in Japan is behind from western countries.

**Material and Methods:** We performed chemotherapy in advanced cases of colorectal cancer with unresectable distant metastasis in 2002, although we could not use FOLFOX with/without biologics in that year. The methods for drug administration were as follows: oral administration of UFT 300 mg/m<sup>2</sup>/day on days 3–7, 10–14, 17–21, and continue to progression, with periods of 1 days on drug and 2 days off drug and intravenous administration of CPT-11 for 120 min on days 1, 15, and continue to Progression, at doses of 80 mg/m<sup>2</sup>/day in Cases.

**Results:** Both patients showed Partial clinical response and continued the therapeutic effect for 7 years with no evidence of new metastatic lesion. No major adverse events were observed in either case to, and the treatment was performed as per the protocol.

**Conclusion:** For the case who cannot undertake standard treatment by some reasons, this chemotherapy with a combination of UFT and CPT-11 may be one of the effective and feasible regimens treatment for advanced colorectal cancer with unresectable distant metastasis.

#### Abstract ID: 0409      Specific Field: Colon and Rectum

Mode of pres.: Poster Exhibition only  
ISW 2011 Session PE 192

##### Surgical resection of hepatic and pulmonary colorectal metastases

T. Shingai, M. Ohue, S. Noura, S. Kano, S. Imada, M. Yano, O. Ishikawa

Osaka Medical Center for Cancer and Cardiovascular Diseases, Osaka, Japan

**Introduction:** Hepatic and pulmonary colorectal metastases are common hematogenous distant metastases from colorectal carcinoma. Surgical resection is only recommended for patients with resectable metastases. However, the benefit of surgical resection is still not clear due to the limited number of reported cases. To elucidate the impact of aggressive surgical management on prognosis, we evaluated retrospectively the patients in our hospital, who underwent surgical resection of synchronous or metachronous hepatic and pulmonary colorectal metastases.

**Material and Methods:** Forty patients from 1981 to 2008 were enrolled in this study. We investigated the patients' clinicopathological features and surgical outcomes. There were 25 men and 15 women, and the median age was 60 years.

**Results:** Median overall survival after the resection of the primary colorectal tumor was 85 months, and 5-year overall survival rate was 76.5%. Survival analysis was performed using Kaplan–Meier method. The location of the primary tumor (83.4% 5-year overall survival in colonic versus 50% in rectal cancer;  $P = 0.0325$ ) significantly influenced survival in univariate analysis. Neither maximum diameter of the hepatic/pulmonary metastases nor number of hepatic/pulmonary metastases was correlated with survival. We divided 40 patients into three groups according to the detection patterns of metastases as follows; Group A: both hepatic and pulmonary metastases occurred synchronously regarding primary tumor ( $n = 6$ ), Group B: either hepatic or pulmonary metastases were

found with primary tumor ( $n = 12$ ), Group C: no metastatic site was found at the same time of primary site resection ( $n = 22$ ). There were significant difference in the 5-year overall survival rate after primary site resection between these 3 groups (0 vs. 81.8% vs. 90.9%, respectively,  $P < 0.0001$ ).

**Conclusion:** This study showed that patients with synchronous hepatic and pulmonary metastases had poor prognosis. Aggressive metastasectomy is recommended for the patients who had resectable hepatic or pulmonary metastases with primary tumor, or who had metachronous metastases.

#### Abstract ID: 0410 Specific Field: Colon and Rectum

**Mode of pres.: Poster Exhibition only**  
**ISW 2011 Session PE 193**

##### Evaluation of an inflammation-based Glasgow Prognostic Score (GPS) in patients with metastatic colorectal cancer

T. Kishiki, T. Masaki, H. Matsuoka, Y. Suzuki, N. Abe, O. Yanagida, T. Mori, M. Sugiyama

Kyorin University, Mitakasi, Japan

**Introduction:** Recent reports have indicated that the presence of a systemic inflammatory response, as revealed by an elevated concentration of circulating serum C-reactive protein (CRP), is associated with adverse outcomes in patients with advanced cancer. Moreover, there are increasing evidences that the Glasgow Prognostic Score (GPS), an inflammation-based prognostic score that includes only serum CRP and serum albumin, is one of the most useful scoring systems for the prognostication of patients with advanced cancer. However, few studies have investigated the clinical implication of GPS in patients with metastatic colorectal cancer.

**Material and Methods:** Routine laboratory measurement including serum CRP, albumin, and tumor markers such as CEA (cutoff value, 5 ng/ml) and CA19-9 (cutoff value, 37 U/ml) was carried out on the same day to exclude any inflammatory effect of preoperative invasive investigations, such as colonoscopy or barium enema. Retrospective chart review was performed for GPS calculation by using the admission data. Classification of data in this score was as follows: GPS score was 2 when both an elevated C-reactive protein (CRP:  $>10$  mg/l) and hypoalbuminemia ( $<35$  g/l) were present. Either of these biochemical abnormalities was present, GPS score was 1. When both serum CRP and albumin levels were within normal range, GPS score was 0. The associations between GPS score and patients' outcomes were examined statistically.

**Results:** Eighty-five patients were evaluated. There were 43 males and 42 females, and 44 colonic and 41 rectal cancers. Metastatic sites were the liver in 58, the lung in 28, the peritoneum in 15, and others in 5 patients, respectively. Forty-five patients had a high level of CRP, and 25 had a low level of albumin. Univariate analysis revealed that hemoglobin less than 10 g/dl, hypoalbuminemia, elevated CRP, elevated CEA more than 5 ng/ml, and high GPS were significantly associated with mortality. Multivariate analysis revealed that elevated CEA (hazard ratio, 2.755; 95% CI, 1.050–7.231;  $P = 0.004$ ) and high GPS (hazard ratio, 1.700; 95% CI, 1.077–2.682;  $P = 0.023$ ) were independent risk factors of mortality.

**Conclusion:** Preoperative GPS and CEA measurements were simple and suitable for predicting long-term outcomes in patients with metastatic colorectal cancer. GPS may be useful in selecting candidates for surgical treatment.

#### Abstract ID: 0411 Specific Field: Colon and Rectum

**Mode of pres.: Poster Exhibition only**  
**ISW 2011 Session PE 194**

##### Adjuvant surgery for unresectable metastatic colorectal cancer

T. Takahashi, K. Nonaka, A. Ikawa, S. Mizui, S. Saito, K. Yamaguchi, S. Osada, K. Yoshida

Gifu University School of Medicine, Gifu, Japan

**Introduction:** In recent years, the survival of patients with advanced colorectal cancer has been improved by the use of oxaliplatin- or irinotecan-based combination chemotherapy. Developed chemotherapeutic agents in colorectal cancer treatment, such as oxaliplatin, associated with 5FU/LV, have demonstrated the ability to reduce tumor burden such that an important fraction of patients initially judged to be inoperable can be resected with curative intent. The "Adjuvant surgery" that we remove lesion after chemotherapy for unresectable colon cancer has been performed in our department. The aims are to analyze the rate of macroscopic curative surgery after chemotherapy and to analyze a possibility of long-term survival by adjuvant surgery.

**Material and Methods:** From May 2005 till March 2010, patient's number who could be administrated active chemotherapy in our department was 147. Survival time between patients of Adjuvant Surgery and non-resectable was analyzed by Kaplan–Meier method.

**Results:** 27 cases were performed "Adjuvant surgery". 18 cases were performed surgery after FOLFOX. 3 cases were performed it after FOLFOX+BV. 3 cases performed it after FOLFOX  $\pm$  BV, following FOLFIRI  $\pm$  BV. One case was performed it after FOLFIRI+BV. One case was performed it after XELOX. One case was performed it after SOX+BV. After 3–18 (average 9.2) chemotherapy courses, "Adjuvant surgery" were performed. In surgical procedure, there were 13 patients who were performed hepatectomy, and 4 patients who were resected both liver and primary lesion. 5 cases were performed pneumectomy. The resection cases of primary lesion and local recurrence were 4, and one, respectively. Rate of "Adjuvant surgery" was 18% (27 of 147). However, it went up to be 40% in patients who had only liver metastasis. The rate of "Adjuvant Surgery" is significantly higher in patients with liver metastasis only, compared to multi organ metastasis, and in those who had good response rate for chemotherapy. The MST of all patients was 27 months. Overall survival (OS) of the patients that "Adjuvant surgery" was performed (27 cases) was extended ( $P < 0.0001$ ) compare to patients not performed (120 cases).

**Conclusion:** The rate of "Adjuvant surgery" was 18% in all patients and 40% in patients with only liver metastasis. OS was significantly extended in patients who were performed "Adjuvant surgery".

#### Abstract ID: 0412 Specific Field: Colon and Rectum

**Mode of pres.: Poster Exhibition only**  
**ISW 2011 Session PE 195**

##### A single-centered retrospective study of preoperative chemotherapy for colorectal liver metastasis

K. Kataoka, A. Kanazawa, A. Nakajima, A. Arimoto

Osaka Red-Cross Hospital, Osaka, Japan

**Introduction:** Recently, several papers have reported the advantage of neo-adjuvant chemotherapy for liver limited metastatic colorectal

cancer. However, most of them used criteria for non-resectability due to size and/or number of metastases. Our criteria for resectability of colorectal liver metastases (CLM) depends on the size of remnant liver volume (>30%) and expected function after the removal of all metastases. Then, we assessed the feasibility and potential benefits of chemotherapy administered before surgery to patients with CLM retrospectively.

**Material and Methods:** From January 2007 to November 2010, 73 chemotherapy-naïve patients were diagnosed as CLM without extrahepatic metastases. We assessed the resectability of all cases with radiological examination after chemotherapy and divided them in two groups, resected group and unresected group. Overall survival, median disease-free survival, prognostic factors and postoperative complications were analyzed.

**Results:** 69 patients received oxaliplatin-based combination regimen and 4 patients another regimen. 35 patients (resected group) received R0 resection and 36 patients (unresected group) were considered as unresectable. No serious postoperative complications was observed. Overall survival was significantly higher the resected group than unresected group (44.5 month and 28.3 month) ( $P < 0.001$ ). Median disease-free survival was 30.5 months in resected group (95% CI: 1.35 to 59.7). Liver resection, sex, preoperative tumor size >5cm, rectal primary, and lymph node-positive primary tumor were independent prognostic factors of survival.

**Conclusion:** Intensive treatment with neo-adjuvant chemotherapy for CLM is well tolerated. Curative surgery improved significantly overall survival in patients with CLM. Neo-adjuvant chemotherapy such as mFOLFOX6 may lead to increased resectability but do not increase postoperative complications. For most patients with resectable CLM, neo-adjuvant chemotherapy should be considered the standard treatment.

**Abstract ID: 0413** Specific Field: **Colon and Rectum**

**Mode of pres.: Poster Exhibition only**  
**ISW 2011 Session PE 196**

**Real-time magnetic resonance-guided microwave coagulation therapy for pelvic recurrence of rectal cancer**

T. Shimizu, Y. Endo, E. Mekata, M. Satoshi, H. Yamamoto, S. Morikawa, Y. Kurumi, T. Tani

Shiga University of Medical Science, Otsu, Japan

**Introduction:** We evaluated consecutive cases of recurrent rectal cancer in the pelvic cavity treated with microwave coagulation therapy using real-time navigation by an open magnetic-resonance system.

**Material and Methods:** Nine recurrent pelvic lesions in 8 patients after resection of rectal cancer were treated with MR-MCT as a palliative local therapy to reduce tumor volume and/or local pain. Clinical and pathological data were collected retrospectively by reviewing medical records and clinical imaging results.

**Results:** Seven patients received other treatments prior to real-time magnetic resonance-guided MCT. Six patients had distant synchronous metastases. MCT was performed percutaneously in five lesions and under laparotomy in four lesions. No fatal complications occurred. Local re-recurrence was observed in two out of nine ablated lesions. Except for 1 patient who died from chronic renal failure, the remaining 7 patients died from cancer. Median overall survival after MCT for all patients was 10 months (range, 4–37 months). Median overall survival after discovery of pelvic recurrence in all patients was 22 months (range, 9–42 months).

**Conclusion:** The benefits of using an open magnetic-resonance system in the pelvic cavity include the abilities to treat tumors that cannot be visualized by other modalities, to demonstrate internal architectural changes during treatment, to differentiate treated versus untreated areas, and to allow adjustments to the treatment plan during the procedure.

**Abstract ID: 0414** Specific Field: **Colon and Rectum**

**Mode of pres.: Poster Exhibition only**  
**ISW 2011 Session PE 197**

**A case of Meig's syndrome resulting from bilateral ovarian metastasis of ascending colon cancer**

K. Onoda [1], O. Saji [2], T. Ootubo [1], K. Iwata [2], R. Okamura [2]

[1] Digestive and General Surgery, St. Marianna University School of Medicine, Kawasaki city, Japan, [2] Department of Surgery, Kinugasa Hospital, Yokosuka City, Japan

**Introduction:** A 73-year-old woman admitted for bilateral ovarian tumor, left pleural effusion and ascites was suspected of metastatic ovarian tumor from computed tomography finding of a bilateral tumor with a mixed cystic and solid portion, ascending colon cancer was shown by colonic fiberoscopy. Chest and abdominal paracentesis was done, but both cytologic examination of pleural effusion and ascites showed no malignant cells. Primary ascending colon cancer with secondary ovarian tumors and peritoneal and pleural metastatic involvement was suspected, so we conducted surgery. Laparotomy showed a bilateral ovarian tumor 15 cm in diameter and multiple peritoneal dissemination necessitating partial colectomy and bilateral oophorectomy. Histologic examination of resected specimens confirmed moderately to poorly differentiated adenocarcinoma of the ascending colon and ovarian metastasis from the primary colon. Pleural effusion disappeared on postoperation. Based on these findings, she had Meig's syndrome from ovarian metastasis which is rare, but is important to be considered and check positively in such a case.

**Abstract ID: 0415** Specific Field: **Colon and Rectum**

**Mode of pres.: Poster Exhibition only**  
**ISW 2011 Session PE 198**

**Isolated splenic metastasis from colonic cancer: a case report**

F. Asahara, J. Matsui, M. Sato, S. Ogawa, H. Harada, S. Takayama, S. Hoshimoto, N. Ando

Tokyo Dental College Ichikawa General Hospital, Ichikawa, Chiba, Japan

**Introduction:** Splenic metastases from colonic cancer are rare and usually associated with widely disseminated disease. Moreover, isolated metastases of the spleen are exceptional. Its rareness has been hypothetically explained by several characteristics of the spleen, such as anatomical, histological and immunological features. We report the case of isolated metachronous splenic metastasis from colonic cancer treated by splenectomy with long survival.

**Material and Methods:** A 61-year-old woman underwent an extended left hemicolectomy for biopsy-proven T3N0M0 (stage IIA) adenocarcinoma of descending colon in April 2003. Preoperative carcinoembryonic antigen (CEA) levels of 8.3 ng/ml decreased postoperatively to 1.5 ng/ml. No adjuvant chemotherapy was carried out after surgery. In May 2006, there was no elevation of CEA,



however, a computed tomography scan showed a hypodense nodule, 3.5 cm in diameter, in the superior pole of the spleen. In June 2006, the patient underwent open splenectomy. Macroscopically, the lesion appeared as a white yellowish mass. Abdominal exploration detected no other sites of tumor recurrence. The histological investigations confirmed a well-differentiated splenic metastasis from colonic cancer. The tumor did not extend beyond the splenic capsule and none of the splenic hilar lymph nodes were involved. Adjuvant chemotherapy was carried out after the splenectomy. The patient is being followed up and has no relapse.

**Results:** We experienced the case of isolated splenic metastasis from colonic cancer treated by splenectomy with a long survival.

**Conclusion:** Splenic metastasis from colonic cancer is rare, and long-term survival can be achieved with splenectomy in the case of isolated splenic metastasis.

#### Abstract ID: 0416 Specific Field: Colon and Rectum

**Mode of pres.: Poster Exhibition only**  
**ISW 2011 Session PE 199**

##### A case of metachronous para-aortic lymph node metastases at six years after resection of transverse colon cancer

N. Yukawa, Y. Rino, M. Masuda

Yokohama City University, Yokohama, Japan

**Introduction:** We report a case with metachronous para-aortic lymph node metastases at six years after resection of transverse colon carcinoma.

**Material and Methods:** The patient was a 53-year-old man who received transverse colon resection with regional lymphadenectomy including group 3 lymph nodes in May 2002.

**Results:** Pathological examination revealed moderately differentiated adenocarcinoma (type3, ss, ly0, v2, n1, ow-, aw-, ew-). She did not receive adjuvant chemotherapy because of chronic hepatitis. However, in November 2008, CT revealed para-aortic lymph node swelling. PET showed high up-take at para-aortic lymph node and no up-take in another organs. CEA raised up to 9.8 ng/ml. She was diagnosed para-aortic lymph node metastasis, and received modified FOLFIRI therapy. Until now, mFOLFIRI were done 30 courses. CT revealed that lymph node metastases got smaller and another metastasis was not detected. CEA reduced till 2.0 ng/ml.

**Conclusion:** Modified FOLFIRI therapy was effective for this case.

#### Abstract ID: 0417 Specific Field: Colon and Rectum

**Mode of pres.: Poster Exhibition only**  
**ISW 2011 Session PE 200**

##### Gastrointestinal stromal tumor (GIST) of the rectum: an analysis of 13 cases

Y. Tajima, T. Lai, K. Hatakeyama

Department of Digestive and General Surgery, Niigata University, Niigata, Japan

**Introduction:** Rectal gastrointestinal stromal tumor (GIST) rarely originates in the rectum and a standardized treatment for rectal GIST has not been clearly established. The aim of this study is to examine our experience in patients with rectal GIST and to clarify the appropriate management of rectal GIST.

**Material and Methods:** The medical records of patients with rectal GIST treated in our institution between 2000 and 2010 were reviewed and clinicopathological characteristics of them were analyzed.

**Results:** There were 13 cases of rectal GIST. 10 cases were primary rectal GIST and 3 cases were local recurrence after surgical resection of rectal GIST. Five were males and eight were females with a median age of 69 (range, 40–90) years. Six of 10 patients with primary rectal GIST received neoadjuvant chemotherapy with Imatinib and the tumor size were decreased in four patients. Eight of 10 primary rectal GIST patients underwent surgery with a margin of negative resection including five low anterior resections and three transanal excisions. Seven resected tumors were positive for CD117, however one was negative for CD117 which was positive before neoadjuvant Imatinib therapy. CD34 was positive in all resected tumors. Resected primary tumors were categorized as low risk (3 cases), intermediate risk (4 cases) and high risk (1 case). The patient with high risk received adjuvant therapy with Imatinib for a year. None of resected primary tumors developed recurrence (the median follow-up period; 50 (range, 13–87) months). In the three cases of local recurrent rectal GIST, one case underwent transanal resection who had no evidence of disease for 14 months postoperatively and two patients were treated with Imatinib who had a complete response after 31 and 40 months since Imatinib onset, respectively.

**Conclusion:** Neoadjuvant therapy with Imatinib for unresectable or borderline-resectable rectal GIST is still under investigation. However, our experiences suggest that by neoadjuvant therapy anus-preserving or less invasive surgery can be indicated for some rectal GIST patients. Furthermore, multidisciplinary treatment including surgery and Imatinib may improve outcome of rectal GIST.

#### Abstract ID: 0418 Specific Field: Colon and Rectum

**Mode of pres.: Poster Exhibition only**  
**ISW 2011 Session PE 201**

##### Five cases of neuroendocrine carcinoma in large bowel

H. Sato [1], K. Maeda [1], Y. Koide [1], T. Hanai [1], K. Masumori [1], H. Katsuno [1], T. Noro [1], K. Toyama [2]

[1] Fujita Health University, Toyoake, Japan, [2] Nogaki Hospital, Nagoya, Japan

**Introduction:** Neuroendocrine carcinoma in the large bowel is a rare entity, however, poorly differentiated neuroendocrine carcinoma is known for its extremely aggressive progression. Our treatment experiences for poorly differentiated neuroendocrine carcinoma were clinically reviewed.

**Material and Methods:** We retrospectively reviewed clinical data from 5 patients (4 males and 1 female), mean age 62.6 year-old (range: 45–72) with poorly differentiated neuroendocrine carcinoma in the large bowel according to classification by the World Health Organization.

**Results:** The chief complaint was bloody stool in 3 patients and defecation difficulties in 2 patients. The mean distance between the tumor and anal verge was 7.8 cm (range: 3–20 cm). The mean interval between symptom appearance and a hospital visit was 2.2 months (range: 1–3 months). One of 5 patients had high serum levels of CEA before surgery. No patients had high serum levels of CA19-9 before surgery. Four patients had liver metastases (3 patients with multiple metastases and 1 patient with solitary metastasis). Tumor in the large bowel was removed in 4 patients, diverting colostomy was created in 1 patient (tumor was not removed). The mean diameter of tumor was 4.9 cm (range: 3.4–6.5 cm). All removed tumor had severe venous invasion. One patient did not have any lymph node and distant

metastases. However, the patient without lymph node and distant metastases had a local recurrence 12 months after surgery, and died in 28 months. All patients with multiple liver metastases died within 3 months of surgery due to the progression of carcinoma in the large bowel. However, the patient with solitary liver metastasis received partial liver resection, and is alive without any sign of recurrence.

**Conclusion:** Poorly differentiated neuroendocrine carcinoma behaves aggressively and leads to poor prognosis, especially in cases of multiple liver metastases. It is recommended to perform minimum invasive surgery in order to reduce symptoms for patients with multiple liver metastases.

**Abstract ID: 0419** Specific Field: **Colon and Rectum**

**Mode of pres.: Poster Exhibition only**  
**ISW 2011 Session PE 202**

**A case of schwannoma of the sigmoid colon showing high-uptake on FDG-PET**

Y. Yagi, T. Iiai, Y. Tajima, M. Fushiki, Y. Shimada, H. Kameyama, H. Nogami, K. Hatkeyama

Division of Digestive and General Surgery, Niigata University Graduate School of Medical and Dental Sciences, Niigata, Japan

**Introduction:** Although schwannoma are common in the neck, brain and extremities, they are relatively rare in the gastrointestinal tract. In particular, schwannomas arising in the large intestine are rare. We here present a rare case of schwannoma of the sigmoid colon showing high-uptake in FDG-PET.

**Material and Methods:** A 75-year-old Japanese woman suffering from narrow stool was referred to our department. Colonoscopy showed a submucosal tumor in the sigmoid colon. Computed tomography scan (CT) showed a mass in sigmoid colon. Endoscopic ultrasound examination (EUS) showed a hypoechoic mass arising from muscular layer. The tumor showed high-uptake on FDG-PET, so it suspected to be malignant tumor like GIST or malignant lymphoma.

**Results:** Laparoscopy assisted sigmoidectomy was underwent. Pathological examination of resected specimen demonstrated spindle cells arrayed in a fascicular fashion. Immunohistochemical staining was positive for S-100 protein, and negative for CD34, c-kit, and  $\alpha$ -SMA. The diagnosis was schwannoma and there are no sign of malignancy. The patient remains well without recurrence 12 months after surgery.

**Conclusion:** To the best of our knowledge, no such case of schwannoma of sigmoid colon with high up-take in FDG has yet been reported in the literature. FDG-PET is one method of the metabolic imaging, and become to be used to make differential diagnosis whether a known lesion is malignant or benign. However, little is known about FDG uptake in benign tumors. And there are some reports that even if a schwannomas are benign, they may show high up-take in FDG-PET so that it does not always suggest malignancy. Schwannomas are almost benign tumors, so they can be cured by local excision in many cases. So some other analysis may be required for preoperative planning in case of high up-take FDG tumors.

**Abstract ID: 0420** Specific Field: **Colon and Rectum**

**Mode of pres.: Poster Exhibition only**  
**ISW 2011 Session PE 203**

**A case of successful transanal excision in lower rectal gastrointestinal stromal tumor (GIST)**

W. Riansuwan, S. Prapasrivorakul

Faculty of Medicine Siriraj Hospital, Bangkok, Thailand

**Introduction:** Surgery is the principle treatment of resectable non-metastatic rectal GIST. Standard oncologic resection might be inappropriate especially in lower rectal GIST because skip metastases and lymphatic spread are rarely reported and some patients could not avoid from having permanent colostomy. We report a case of successful transanal excision in lower rectal GIST.

**Material and Methods:** A 54-year-old woman's chart, diagnostic imaging, endoscopic report and pathological report were reviewed. She presented with passing bright red blood per rectum for one month. Physical examination and colonoscopy demonstrated a 3 cm polypoid mass at left lateral wall of lower rectum; 5 cm above anal verge. Biopsy reported spindle cell neoplasm and immuno-histochemical study revealed the tumor cells marked with CD117 and CD34. Abdominal CT scan showed an enhancing  $3.5 \times 3.5 \times 3.6$  cm<sup>3</sup> lobulated contour soft tissue mass at left lateral aspect of lower rectum; abut to left levator ani muscle. No liver metastasis was demonstrated.

**Results:** The patient underwent transanal excision uneventfully. The operative time was 95 min and blood loss was 20 ml. Pathological report showed 3 cm. spindle cell type GIST; mitotic count > 10/50 HPF; absence of angiolymphatic invasion. The patient finally received postoperative adjuvant Imatinib Mesylate. No recurrent tumor was detected by either physical examination or CT scan after one year of follow up and she had neither incontinence nor constipation.

**Conclusion:** Short-term results both in oncologic clearance and functional outcomes of transanal excision in small lower rectal GIST (under 3 cm.) are acceptable. However, long-term follow up is still needed.

**Abstract ID: 0421** Specific Field: **Colon and Rectum**

**Mode of pres.: Poster Exhibition only**  
**ISW 2011 Session PE 204**

**Neuroendocrine carcinoma of lower rectum: a case report**

W. Riansuwan, S. Prapasrivorakul

Faculty of Medicine Siriraj Hospital, Thailand

**Introduction:** Rectal neuroendocrine carcinoma is a rare disease and prognosis is worse than rectal adenocarcinoma. Here we report a case of successful ultra-low anterior resection in well-differentiated neuroendocrine carcinoma of lower rectum.

**Material and Methods:** A 38-year-old man's chart, diagnostic imaging, endoscopic report and pathological report were reviewed. He presented with chronic constipation for 6 years. Digital rectal examination and colonoscopy demonstrated a 5 cm intramural mass with smooth mucosa at posterior aspect of lower rectum; 4 cm. above anal verge. Biopsy reported carcinoid tumor. Pelvic MRI revealed a well-defined rounded  $5.3 \times 6.2 \times 4.6$  cm<sup>3</sup> retrorectal mass with hypo-signal intensity on T1W, markedly high signal intensity on T2W, and intense enhancement after Gadolinium administration. No liver metastasis was demonstrated by abdominal CT scan.

**Results:** The patient underwent ultra-low anterior resection with double staple side to end colo-anal canal anastomosis uneventfully. The operative time was 195 min and blood loss was 310 ml. Pathological reports showed  $5 \times 4.5 \times 4.5$  cm<sup>3</sup> well-differentiated neuroendocrine carcinoma, presence of angiolymphatic invasion and metastatic carcinoma in one out of twenty six regional lymph nodes.

The patient received postoperative adjuvant radiation and chemotherapy (5-FU and Leucovorin). No recurrent tumor was detected after 14 months of follow up.

**Conclusion:** Although high recurrence rates are noted, radical oncologic resection followed by adjuvant chemo-radiation is standard treatment in lower rectal neuroendocrine carcinoma. Long-term follow up of this patient is still needed.

**Abstract ID: 0422** Specific Field: **Colon and Rectum**

**Mode of pres.: Poster Exhibition only**  
**ISW 2011 Session PE 205**

**Examination of endocrine cell carcinoma of colon and rectum: recent experience in a single institution**

Y. Gotanda, Y. Akagi, T. Kinugasa, I. Shiratuchi, Y. Ryu, K. Tanaka, K. Shirouzu

Kurume University, Kurume, Japan

**Introduction:** In late years, we experienced some endocrine cell carcinoma cases of colon and rectum in our institution. The endocrine cell carcinoma of colon and rectum is very rare. This tumor is extremely poor prognosis which clinical feature is advanced vascular invasion and highly metastases to lymph nodes and the other organ at an early stage.

**Material and Methods:** Four cases of endocrine cell carcinoma of colon and rectum are evaluated. The average age is 49 years old. Male and female are each two cases. The clinicopathological features of these cases are compared with literatures.

**Results:** The location is two cases in rectum and each one case in sigmoid colon and transverse colon. The average of tumor diameter is 6.6cm (range;2.5~12cm) and there is no typical gross type. The preoperative pathological diagnosis is moderately or poorly differentiated adenocarcinoma but not endocrine cell carcinoma. There are metastases to lymph nodes with all cases, and metastases to liver in two cases at a diagnosis, and one case developed metastases to liver after surgery for primary tumor immediately. We performed FOLFOX or FOLFIRI for metastasis, but there is not effective chemotherapeutic regimen. The condition becomes worse in a short term. Only transverse colon case is relapse free, but three other cases are extremely poor prognoses. These course is an approximately similar characteristic from literatures. As for the therapy, various chemotherapy has been tried, but continuance of an effect for a long term cannot be expected.

**Conclusion:** The surgical resection is first choice in colorectal carcinoma, but establishment of the therapy for an endocrine cell carcinoma of colon and rectum is required another new treatment such as molecular target therapy.

**Abstract ID: 0423** Specific Field: **Colon and Rectum**

**Mode of pres.: Poster Exhibition only**  
**ISW 2011 Session PE 206**

**Two cases of neuroendocrine neoplasms of the rectum**

J. Ando, S. Ooki, M. Saito, H. Sugeno, M. Sassa, S. Suzuki, I. Nakamura, S. Takenishita

Fukushima Medical University, Fukushima, Japan

**Introduction:** Neuroendocrine neoplasms is a tumor which grow as a mother cell from the immature progenitor cells of internal secretion, which exist in the multiplying area of digestive gland. Generally, it is a tumor with low malignancy. In Japan, colorectal neuroendocrine neoplasms is commonly found around lower part of rectum and appendix. Treatment is decided by the size, depth and level of vas aggression. We will report two cases of rectal neuroendocrine neoplasms which we had experienced, along with some other research reports that are already had been studied.

**Material and Methods:** First case is a 45-year-old man who had a SMT in size of 12 mm at rectal Rb area. We found it difficult to diagnose by the EUS-FNA and boring biopsy; therefore, we performed tumor resection through anus, and diagnosed it as a mucinous carcinoid. Second case is a 47-year-old man, who had a tumor in size of 20 mm at rectum. It was diagnosed as neuroendocrine neoplasms (NET G1) by the EUS-FNA, and we performed a laparo-assisted low anterior resection of rectum in order to excise the tumor.

**Conclusion:** With the size and depth of the tumor, the suitable rectal treatment strategies are decided for carcinoid tumor. It is recommended that the treatment of rectal neuroendocrine neoplasms should be chosen from the endoscopic, resection through anus or sacrum, TEM, anterior resection or laparoscopic, based on the size and invasion depth of the tumor. However as there are only limited number of examples for carcinoid tumor, when the size of tumor is at its boundary size level, it is important to provide proper treatment.

**Abstract ID: 0424** Specific Field: **Colon and Rectum**

**Mode of pres.: Poster Exhibition only**  
**ISW 2011 Session PE 207**

**Two cases of gastrointestinal stromal tumor of the rectum treated by transanal local excision**

M. Susa, Y. Inoue, M. Yamamoto

Tokyo Women's Medical University, Tokyo, Japan

**Introduction:** Gastrointestinal stromal tumor (GIST) of the rectum is relatively rare. Here, we report 2 cases of the uncommitted type of GIST in which surgery with anal preservation was performed. Case 1 was 37-year-old man who was admitted to a local hospital for anal pain. He was referred to our hospital following detection of a rectal tumor by the local hospital. Digital rectal examination showed an elastic-hard tumor in the inferior wall of the lower rectum 2 cm above the dentate line. Colonoscopy revealed an elevated submucosal tumor. Endoscopic ultrasound-guided fine needle aspiration was performed, and the histologic diagnosis of the biopsy specimen was GIST. Transanal local excision was performed as treatment. Histopathologic findings showed a mitotic index of 14/50 HPF and immunohistochemical analysis demonstrated c-kit (+) and CD-34 (+). Case 2 was 49-year-old man who was admitted to a local hospital for melena. An elastic-hard tumor in the left lower rectal wall 3 cm above the dentate line was detected by digital rectal examination. Computed tomography scan revealed a solid tumor of 7 cm diameter. Colonoscopy demonstrated an elevated submucosal tumor. The histologic diagnosis of the biopsy specimen obtained by core needle biopsy was GIST. The patient was treated with 400 mg of imatinib mesylate daily. After 15 months, the tumor size decreased to 3 cm in diameter. Thereafter, transanal local excision was performed. Histopathologic findings revealed a mitotic index of 14/50 HPF and immunohistochemical analysis demonstrated c-kit (+) and CD-34 (+). Although

surgical resection remains the primary treatment for GIST, the present cases suggest that imatinib mesylate may be useful as neoadjuvant chemotherapy. To date, both cases have shown no signs of recurrence, although a close follow-up is required.

**Abstract ID: 0425** Specific Field: **Colon and Rectum**

**Mode of pres.: Poster Exhibition only**  
**ISW 2011 Session PE 208**

**Is it possible to judge the need for operation with computed tomography in the patient with small bowel obstruction beforehand?**

S. Iida, H. Urakami, S. Seki, A. Shimada, A. Matsui, T. Oishi, Y. Isobe, S. Matsumoto

National Organization Hospital Tokyo Medical Center, Tokyo, Japan

**Introduction:** Prompt and accurate operative treatment of small bowel obstruction (SBO) should improve morbidity and mortality rates, although accurately determining which patients should undergo operation can be difficult. The aim of this study was to identify preoperative risk factors associated with the need for operative management in SBO patients.

**Material and Methods:** Between January 2007 and December 2009, a total of 109 consecutive patients with SBO in our institution, all of whom had undergone computed tomography (CT). Patients were divided into two groups: group 1 ( $n = 58$ ), who required operative management, and group 2 ( $n = 51$ ) who did not. Initially, all patients were treated conservatively. Surgery was performed in patients who developed signs of strangulation or did not improve, despite a conservative treatment. Clinicopathological factors associated with the need for operative management in SBO patients were analyzed.

**Results:** A total of 109 patients (50 men and 59 women) with the median age of 73 (22–96) years were included, and the median follow-up was 12.3 (0.2–40) months. History of previous abdominal surgery was present in 95 patients (87.2%) and history of previous SBO was present in 42 patients (38.5%). Only 3 (2.8%) of the 109 patients were dead. 18 patients (31%) in group 1 required bowel resection due to ischemia. On univariate analysis, the need for operative treatment was significantly associated with CT findings of small bowel wall thickening, mesenteric edema, whirlsign, beak sign, ascites. There was no statistically significant difference in clinical and laboratory factors between group 1 and group 2.

**Conclusion:** In conclusion, our study suggests that the six CT findings, small bowel wall thickening, mesenteric edema, whirlsign, beak sign, ascites, are predictive of requiring operative intervention. CT is recommended for the evaluation of patients with suspected SBO.

**Abstract ID: 0426** Specific Field: **Colon and Rectum**

**Mode of pres.: Poster Exhibition only**  
**ISW 2011 Session PE 209**

**Clinical analysis of colonic diverticulitis**

Y. Honda, N. Shimada, H. Kaneko, Y. Miura, T. Kaneko, Y. Urita, M. Sugimoto, H. Shimada

Toho University, Faculty of Medicine, Tokyo, Japan

**Introduction:** Colonic diverticulitis is one of common disease with acute abdomen. It is necessary for treatment of diverticulitis, we may not have invasive operation excessively, because diverticulitis is one of benign disease.

**Material and Methods:** This study was a retrospective review of medical records from 2005 to 2006 at Toho University Hospital, Department of General Medicine and Emergency Care, in Tokyo, identifying patients admitted to the medical service with the diagnosis of colonic diverticulitis. Inclusion criteria were diverticulitis confirmed at radiographic, ultrasonic or enema findings consistent with the disease. Patient demographics, history, physical findings were recorded. The data were analyzed after dividing the patients into two populations; right (ascending) colonic diverticulitis, and left (sigmoid and descending) colonic diverticulitis.

**Results:** During the interval, a total of 69 patients (male: 44, female: 25) were admitted to the medical service with the diagnosis of diverticulitis. The mean age of this population was 43.3 years (range 19–79). Right colonic diverticulitis population was 52, left was 17. Analysis of right and left colonic diverticulitis, age, treatment procedure, showed difference between the two groups. The mean age of right colonic diverticulitis population was younger than left colonic diverticulitis population. 3 patients needed surgical service, in right colonic diverticulitis patients. In left colonic diverticulitis patients, 7 patients needed surgical service. Over 90% of right colonic diverticulitis, we may treat with not operation but conservative treatment.

**Conclusion:** Right colonic diverticulitis are different from left colonic diverticulitis of some clinical character. Both of them we may check inflammatory state at radiographic, ultrasonic findings, before treatment. Operation is better for diverticulitis with perforation, identified free air at radiographic or ultrasonic findings. It gives priority to puncture for the case of abscess formation with colonic diverticulitis, if we may have a safety puncture route to the abscess.

**Abstract ID: 0427** Specific Field: **Colon and Rectum**

**Mode of pres.: Poster Exhibition only**  
**ISW 2011 Session PE 210**

**Bladder preserving surgery for enterovesical fistula complicated with benign gastrointestinal diseases**

T. Mizushima, M. Ikeda, M. Sekimoto, H. Yamamoto, I. Takemasa, J. Nishimura, Y. Doki, M. Mori

Osaka University, Suita, Japan

**Introduction:** Enterovesical fistulas are challenging clinical problems. In the case of malignant diseases, total or partial cystectomy is necessary for radical operation. On the other hand, minimally invasive and organ preserving surgery should be planned in the case of benign diseases. However, it might be controversial how to treat them surgically in the case of benign gastrointestinal diseases. The feasibility of bladder-preserving surgery for benign enterovesical fistula was not well established. Therefore, we conducted retrospective review of bladder preserving-surgery for enterovesical fistula complicated with benign gastrointestinal diseases.

**Material and Methods:** The medical records of 10 patients, who have undergone bladder-preserving surgery for benign enterovesical



fistula between Aug 2005 and Aug 2010, were reviewed and the surgical outcome was assessed.

**Results:** The patients were six men and four women. The median age of the patients was 68. The primary disease was diverticulitis of sigmoid colon in five cases, Crohn's disease in two cases, radiation enteritis following radiotherapy for cervical cancer in two cases, and complication after partial cystectomy in one case. The vesical fistula was located at bladder base and body in nine cases and at bladder trigone in one case. Meanwhile, the enteric fistula was located at sigmoid colon in six cases and at ileum in four cases. Surgical resection of enterovesical fistula was performed in all cases. Additional sutures were placed on the bladder wall in three of seven cases. In other three cases, the vesical fistula was excised and closed. Four ileocecal resection, two sigmoidectomy, and two wedge resection of sigmoid colon were performed for gastro intestinal diseases. Laparoscopic surgery was attempted in four of 10 cases, and accomplished in three cases. The median operating time was 214 min, and the median blood loss was 348 ml. The post operative complications were two wound infections and one bleeding from duodenal ulcer. The postoperative bladder function was fair in all cases.

**Conclusion:** Bladder preserving surgery for enterovesical fistula complicated with benign gastrointestinal diseases is feasible and surgical outcome is satisfactory in most cases. Furthermore, laparoscopic surgery is indicated in some selected cases.

#### Abstract ID: 0428 Specific Field: Colon and Rectum

Mode of pres.: Poster Exhibition only  
ISW 2011 Session PE 211

##### Quick and precise manufacture methods of preoperative navigation images

T. Tsuruma [1], S. Son [1], A. Konno [1], F. Hata [2]

[1] JR Sapporo Hospital, Sapporo, Japan, [2] Sapporo Doto Hospital, Sapporo, Japan

**Introduction:** In colorectal cancer operation, especially laparoscopic operation, an understanding of the blood vessel pattern is useful information to enforce the safe operation and lymph node dissection. So, in our hospital, we process preoperative navigation images by 3D-CT. We show that quick and precise manufacture methods of preoperative navigation images.

**Material and Methods:** In case of right colon cancer, superior mesenteric artery/vein (SMA/SMV) are color-coded and highlighted. In case of left colon cancer and rectal cancer, inferior mesenteric artery/vein (IMA/IMV) are highlighted in the same way. In addition, in case of cancer in left colic flexure, SMA and IMA are highlighted at one time. In order to get to know more about a positional relation between location of cancer and feeding artery, other images including some figures, such as air or stercus in the bowel, ileus tube, iliac bone, are processed. An unprocessed original image is also delivered to each PC. In our hospital, the system, which the radiologic technicians process above images according to our order, has established almost in all cases.

**Results:** At times, we cannot identify the feeding artery in the processed images. At that time, we conduct a review of the unprocessed original image, and scout out the vessels which are erased by wrong

processing. In addition, images including some figures, such as air or stercus in the bowel, ileus tube, iliac bone, can enable us to understand the precise information, such as the feeding artery, the range of resection.

**Conclusion:** According to our order without our detailed information, the radiologic technicians routinely process some kinds of preoperative navigation images corresponding to colorectal patient's state. So, we can quickly get the precise preoperative information based on the images.

#### Abstract ID: 0429 Specific Field: Colon and Rectum

Mode of pres.: Poster Exhibition only  
ISW 2011 Session PE 212

##### Influence of Dai-kenchu-to (DKT) on postoperative intestinal motility in patients who had undergone radical surgery for sigmoid colon cancer

H. Kan, E. Uchida, S. Matsumoto, T. Yamada, M. Koizumi, J. Sasaki, A. Tani, K. Furukawa

Nippon Medical School, Tokyo, Japan

**Introduction:** In Japan, Dai-kenchu-to (DKT), a Japanese traditional herbal medicine, is prescribed to improve intestinal motility in order to prevent postoperative paralytic ileus or adhesion. However, the detailed mechanism of its action still remains unknown. We investigated the influence of DKT on postoperative intestinal motility in patients who had undergone radical surgery for sigmoid colon cancer by means of measuring the bowel transit time using radiopaque markers (20 pieces in a gelatin capsule: SITZMARKS®).

**Material and Methods:** Patients consumed the SITZMARKS® 30 min before the induction of anesthesia and on postoperative days 0, 1, 3, 5, 7, and 10, a plain abdominal X-ray was taken, and the intestinal transit time was calculated. We defined the time when 80% (16 pieces) of markers passed the ileocecal valve as the ileocecal transit time (ICT) and when day passed the anus as the whole gut transit time (WGT). We administered 7.5 or 15 g of DKT per day from the first or the second postoperative day for the group administered DKT.

**Results:** An investigation at the period before the introduction of the laparoscopic surgery technique at our institution (control group:  $n = 10$ , DKT group:  $n = 3$ ) showed that after conventional open sigmoidectomy, the ICT was not significantly shortened by DKT ( $63.8 \pm 31.7$  h vs.  $39.6 \pm 27.7$  h,  $P = 0.262$ ) and there was no significant difference in the WGT ( $245.3 \pm 52.5$  h vs.  $268.2 \pm 15.9$  h,  $P = 0.485$ ). On the other hand, investigation after having introduced the laparoscopic surgery technique (control group:  $n = 5$ , DKT group:  $n = 7$ ) showed that while there was no significant difference in the ICT ( $43.1 \pm 39.6$  h vs.  $33.9 \pm 22.0$  h,  $P = 0.615$ ) the WGT was significantly extended in the patients administered DKT ( $143.9 \pm 32.4$  h vs.  $184.6 \pm 27.2$  h,  $P = 0.040$ ).

**Conclusion:** The effect of DKT on accelerating intestinal motility appears to occur mainly in the small intestine. Otherwise, there were no differences following its administration during the postoperative state after laparoscopic surgery. The reason for this lack of acceleration may be the early recovery from postoperative intestinal paralysis due to the minimally invasive surgical technique. Moreover, in the colon, DKT seemed to inhibit excessive intestinal motility after laparoscopic surgery.

**Abstract ID: 0430** Specific Field: **Colon and Rectum**

**Mode of pres.: Poster Exhibition only**  
**ISW 2011 Session PE 213**

**Postoperative administration of dai-kenchu-to in colorectal surgery**

G. Osawa, K. Yoshimatsu, K. Ogawa, H. Yokomizo, T. Otani

Tokyo Women's Medical University Medical Center East, Tokyo, Japan

**Introduction:** Administration of the Herbal medicine "Dai-kenchu-to" (DKT) 7.5 g/day for the patient has been performed after colorectal surgery for 3 days. The effects of the DKT were retrospectively analyzed on clinical course.

**Material and Methods:** One hundred twenty two patients with colorectal cancer who underwent curative surgery, were divided into a DKT group ( $n = 53$ ) and a non-DKT group ( $n = 69$ ). The differences of postoperative course were analyzed.

**Results:** The 53 out of 59 patients could completely take DKT in 3 days. In the postoperative course, significant difference was observed in the first flatus day (2.3 days in the DKT group vs. 2.8 days in the non DKT group). In the anti-inflammatory effects, significant differences were observed in the heart rate (HR) of the 3rd POD. In the change between 1st POD and 3rd POD, the increase of the HR in the DKT group was well controlled compared to the non DKT group. In the patients who had over 37.5°C of body temperature (BT) in 1st POD ( $n = 53$ ), the CRP, BT and HR of the DKT group were lower than those of the non DKT group. The change of the CRP and BT in the DKT group was well controlled compared to the non DKT group.

**Conclusion:** The postoperative administration of the DKT could be effective on the postoperative course of the colorectal surgery by influencing the bowel movement and inflammatory response.

**Abstract ID: 0431** Specific Field: **Colon and Rectum**

**Mode of pres.: Poster Exhibition only**  
**ISW 2011 Session PE 214**

**Effect of daikenchutoa, traditional herbal medicine, early period after surgery for colorectal cancer**

K. Yokoyama, J. Mitsui, H. yoshida

Yoichi Kyoukai Hospital, Yoichi-cho, Japan

**Introduction:** Traditional Japanese herbal medicine (Kampo) is used to treat various disorders of the gastrointestinal tract in Japan. Daikenchuto (TJ-100) is the most frequently prescribed traditional Japanese medicine in Japan and is a mixture of extract powders from dried Japanese pepper, processed ginger, ginseng radix, and maltose powder. Daikenchuto improves postoperative bowel motility and postoperative paralytic ileus.

**Material and Methods:** Patients after colorectal surgery (January, 2006–December, 2007  $n = 105$ ) were divided into three groups. TJ-100 group ( $n = 35$ ), 2.5 g of TJ-100 was administered orally three times a day from the first or second postoperative day. GFO group ( $n = 23$ ), 3 g of glutamine, 5 g of soluble dietary fiber and 0.5 g of oligosaccharide was administered in the same fashion. Control group ( $n = 47$ ), neither ITJ-100 nor GFO was administered.

**Results:** There was no significant difference among the groups in background. The earlier start of the water and dietary intake were observed in TJ-100 group and GFO group than control group. Also the earlier start of the postoperative defecation was observed in TJ-100 group and GFO group than control group. Postoperative hospital stay was significantly shorter in TJ-100 group than other groups. Instances of postoperative paralytic ileus were fewer in TJ-100 group than other groups. Also occurrences of diarrhea were significantly fewer in TJ-100 group than GFO group.

**Conclusion:** TJ-100 may become a more effective and safe agent than GFO in postoperative management of colorectal surgery.

**Abstract ID: 0432** Specific Field: **Colon and Rectum**

**Mode of pres.: Poster Exhibition only**  
**ISW 2011 Session PE 215**

**Relative risk factors of complication associated with diverting stoma closure after rectal cancer resection**

J. Tashiro [1], S. Yamaguchi [1], I. Toshimasa [1], T. Sato [1], Y. Miyamoto [1], M. Miyazawa [1], N. Shinozuka [2], I. Koyama [1]

[1] Saitama Medical University International Medical Center, Saitama, Japan, [2] Saitama Medical University, Saitama, Japan

**Introduction:** Diverting stoma is frequently performed to protect low anastomosis and avoid the appearance of severe complications as a result of anastomotic failure. It is necessary to undergo a defunctioning stoma surgery again. This study was assessed relative risk factors of complication associated with diverting stoma closure.

**Material and Methods:** 95 consecutive patients who received stoma closure were included since April 2007 to December 2010. Diverting stoma will be constructed in all patients of lower rectal cancer, cases of bulky tumor and unstable reconstruction. The optimum interval to stoma closure is usually 90 days after rectal cancer resection. Date was collected: age, gender, BMI, comorbidity, approach/complication of primary resection, adjuvant chemotherapy, interval between primary resection and stoma closure, ileostomy vs. colostomy, postoperative complication and mortality in the first 30 days following surgery, operative time, blood loss count, postoperative hospital stay.

**Results:** The mean age was 63 years (34–89) and consisted of 63 male (66%). The mean operative time was 70 min. The mean interval time was 162 days (35–404) and the mean hospital stay was 7.3 days (5–19). The overall morbidity/mortality rate was 25.2% ( $n = 24$ ) and 0.01% ( $n = 1$ , acute heart failure). The most frequent surgical complications were wound infection (18.9%,  $n = 18$ ) and small bowel obstruction (4.2%,  $n = 4$ ). Age ( $67 \pm 10.9$  vs.  $62 \pm 9.7$ ;  $P = 0.017$ ), male gender ( $P = 0.038$ ) were significantly higher incidence of complications. The mean interval time was significantly longer in patients with complications than in patients without them ( $206 \pm 96$  vs.  $147 \pm 75$  days;  $P = 0.002$ ). The incidence of complications in ileostomy was significantly fewer than in transverse colostomy ( $P = 0.015$ ). The mean operative time was significantly longer in patients with complications ( $78 \pm 22$  vs.  $67 \pm 23$  min;  $P = 0.038$ ). The mean postoperative hospital stay was significantly longer in patients with complications ( $8.3 \pm 3.1$  vs.  $7 \pm 1.0$  days;  $P = 0.003$ ). **Conclusion:** Relative risk factors between stoma closure and the incidence of complications were male gender and advanced age. Also, diverting colostomy closure and the prolongation of the interval time to stoma closure increased the incidence of complications. The optimization of the operative time was an important factor decreasing the incidence of complications.

**Abstract ID: 0433** Specific Field: **Colon and Rectum**

**Mode of pres.: Poster Exhibition only**  
**ISW 2011 Session PE 216**

**Covering ileostomy or colostomy in low anterior resection for rectal cancer**

S. Endo, E. Hidaka, K. Ikehara, Y. Takehara, T. Omoto, F. Ishida, J. Tanaka, S. Kudo

Showa University Northern Yokohama Hospital, Yokohama, Japan

**Introduction:** Sphincter-saving surgery for the treatment of low rectal cancer has spread considerably. In order to reduce leakage-related complications, a covering stoma is often performed. A loop ileostomy or a loop colostomy, there is no evidence on which is the better technique to adopt, so we studied this problem from a view of postoperative complication.

**Material and Methods:** Between April 2001 and August 2010, 155 patients have undergone low anterior resection with covering stoma, 120 had a loop ileostomy (group of I) and 35 had a loop colostomy (group of C). The choice of stoma type was entrusted to judgment of surgeons. There was no difference in gender and age between both groups, but many patients who had preoperative chemoradiotherapy were in group of C ( $P = 0.0958$ ). We performed retrospective study to compare the two groups about ileus, early closure, dehydration, urinary tract infection, liver dysfunction, anastomotic leakage, hospital stay after operation.

**Results:** Postoperative ileus rate was higher in group of I than in group of C (22.5 vs. 8.6%;  $P = 0.0881$ ). Early closure rate was also higher in group of I (9.2 vs. 0%;  $P = 0.0709$ ). The reasons for early closure were follows; self stoma-care: 6 cases, ileus: 3 cases and skin trouble: 2 cases. There were 5 patients who developed dehydration, 3 patients with urinary tract infection and 5 patients with liver dysfunction in group of I, but there was no patient in group of C. These states were thought related to high output volume from stoma. There was no difference about leakage (I: 7.5 vs. C: 14.3%) and postoperative hospital stay (I:  $23.2 \pm 12.9$  days vs. C:  $27.6 \pm 17.8$  days).

**Conclusion:** The results of this study showed that, in our experience, patients with a loop ileostomy require measures for postoperative ileus and dehydration. And it is necessary to consider colostomy for patients who cannot do self stoma-care.

**Abstract ID: 0434** Specific Field: **Colon and Rectum**

**Mode of pres.: Poster Exhibition only**  
**ISW 2011 Session PE 217**

**Postoperative analysis of rectal function by fecoflowmetry in patients with low rectal cancer**

Y. Ryu [1], M. Yagi [1], Y. Akagi [1], T. Kinugasa [1], I. Shiratuti [1], Y. Gotanda [1], R. Kansakar [2], K. Shirouzu [2]

[1] Kurume University, Kurume, Japan, [2] Kurume University, Japan

**Introduction:** Evacuation dysfunction is often present in patients undergoing anal preservation surgery for low rectal cancer. Most of the studies have done a subjective clinical assessment with which it may be difficult to accurately evaluate the evacuation function. There may be some differences in outcome between clinical evaluation and Manometry for evaluation of pressure. Therefore for a more objective evaluation of evacuation function the technique of Fecoflowmetry was used.

**Material and Methods:** A total of 23 patients with low rectal/anal canal cancer who underwent anal preservation surgery was studied using Fecoflowmetry following closure of temporary ileostomy. The Maximum resting pressure and Maximum squeeze pressure was measured using manometry. The Tolerance Volume (TV), Max of Flow Rate (Fmax), Evacuative Rate (ER), Fecoflow Pattern (FFP) were evaluated using Fecoflowmetry. The results of Manometry, fecoflowmetry were compared with the Wexner scoring system.

**Results:** The Median follow up period was 28 months following ileostomy closure. There was a significant negative correlation in between TV, Fmax and ER and the Wexner score. The Fecoflow pattern (FFP) of block type showed good control and flat type showed bad control in Wexner score. There was no significant correlation in between manometry and Wexner score.

**Conclusion:** Postoperative level of incontinence following surgery for low rectal cancer can be reflected by Fecoflowmetry. It can be used as a technique in adjunct to conventional clinical examination.

**Abstract ID: 0435** Specific Field: **Colon and Rectum**

**Mode of pres.: Poster Exhibition only**  
**ISW 2011 Session PE 218**

**The efficacy of intraoperative irrigation and colonoscopy for obstructed left-sided colorectal cancer**

Y. Yoneyama [1], H. Miyauchi [1], G. Oohira [1], T. Tohma [1], M. Kuboshima [1], Y. Akutsu [2], N. Hanari [1], H. Matsubara [1]

[1] Chiba University, Chiba, Japan, [2] Chiba University, Japan

**Introduction:** The aim of this study is to examine the efficacy of intraoperative irrigation and colonoscopy for obstructed left-sided colorectal cancer.

**Material and Methods:** From March 2005 to December 2010, 64 patients who underwent a resection for primary obstructed left-sided colorectal cancer were included in this study. From June, 2007, we started intraoperative irrigation and colonoscopy (IIC) for obstructed left-sided colorectal cancer. Findings of intraoperative colonoscopy, Perioperative parameters and outcome including mortality and anastomotic leak were examined.

**Results:** In 22 patients, intraoperative irrigation and colonoscopy was performed. The median operating time was significantly longer in patients with IIC than those in patients without IIC ( $P = 0.05$ ). The blood loss was not significantly different between the two group. Of the 22 patients, 7 patients had another neoplastic lesion which need additional resection beside main tumor via intraoperative colonoscopy. The morbidity rate was 31.8% in patients with ICC, 42.9% in those without IIC. In patients without IIC, there were four cases of postoperative enterocolitis but none in patients with IIC. However, there was no significant difference in two groups. Anastomotic leak rate was 17.6% (3/17) in patients with IIC and 9.7% (3/31) in patients without IIC. There was also no significant difference in two groups.

**Conclusion:** Intraoperative colonoscopy with irrigation is effective to find small another neoplastic lesion in proximal colon for obstructed left-sided colorectal cancer.

**Abstract ID: 0436** Specific Field: **Colon and Rectum**

**Mode of pres.: Poster Exhibition only**  
**ISW 2011 Session PE 219**

**Evaluation of postoperative wound infections in colon cancer surgery at our hospital**

O. Wada, S. Imai, T. Knai

Hiratsuka City Hospital, Hiratsuka City, Japan

**Introduction:** The incidence of postoperative wound infections in colon cancer surgery is relatively high, and because wound infections lead to problems such as prolonged hospital stays and increased medical costs. In this study, the short-term results of new wound infection measures instituted at our hospital since January 2010 were compared with previous results.

**Material and Methods:** Between April 2006 and September 2010, 383 patients underwent elective colon cancer surgery at our hospital (January to September 2010, group A, 55 patients; April 2006 to December 2009, group B, 328 patients). In group A, wound margin protection with a towel, high-pressure wound irrigation, insertion of a subcutaneous drain (in patients with 2.5 cm of subcutaneous fat), and dermal buried sutures with 4-0 monofilament absorbable suture were used. In group B, wound margin protection with a ring drape, wound irrigation, and skin interrupted sutures with nylon suture were used; high-pressure irrigation and a subcutaneous drain were not used.

**Results:** In group A, the median age was 72 (40–93) years; there were 32 men and 23 women. In group B, the median age was 70 (25–92) years; there were 207 men and 121 women. In group A, open surgery was performed in 34 patients, and laparoscopic surgery was performed in 21 patients. In group B, open surgery was performed in 251 patients, and laparoscopic surgery was performed in 77 patients. Operative time and blood loss were 284 (64–663) min and 128 (10–3210) ml, respectively, in group A, and 230 (49–807) min and 221.5 (10–4195) ml, respectively, in group B. Perioperative blood transfusion was required in 5 (5%) group A patients and 41 (12.5%) group B patients. There were 8 (14.5%) smokers in group A and 78 (23.7%) in group B. Postoperative wound infections occurred in 5 (9.1%) group A patients and 46 (14.0%) group B patients. The length of hospital stay was 18.5 (12–106) days in group A and 23 (9–436) days in group B.

**Conclusion:** With new wound infection prevention measures starting from January 2010, postoperative wound infections have decreased. Moreover, this decrease in postoperative wound infections has contributed to shorter hospital stays. These new measures taken at our hospital are useful in reducing the incidence of postoperative wound infections.

**Abstract ID: 0437** Specific Field: **Colon and Rectum**

**Mode of pres.: Poster Exhibition only**  
**ISW 2011 Session PE 220**

**Studies on anorectal manometry in patients after low anterior resection for rectal cancer**

R. Tomita [1], S. Igarashi [1], T. Ikeda [1], K. Sugito [2], K. Sakurai [2], S. Fujisaki [2], T. Koshinaga [2], M. Shibata [3]

[1] Nippon Dental University Hospital, Tokyo, Japan, [2] Nihon University School of Medicine, Tokyo, Japan, [3] Fukushima Medical University, Fukushima, Japan

**Introduction:** The purpose of this study is to clarify the anorectal functions in patients 5 years or more after low anterior resection (LAR) for lower rectal cancer.

**Material and Methods:** Thirty-eight patients after LAR were manometrically studied and compared with 30 controls (group C; 19 men and 11 women, average 65.5 years). Patients after LAR were divided into group A (20 patients without soiling) and group B (18 patients with soiling). The mean follow-up time from LAR was 67.2 months. Anorectal manometry was performed: Anal sphincter pressure at rest (ASPR), Maximum anal sphincter pressure during voluntary contraction (MASPVC), Minimum rectal sensory threshold volume

(MRSTV), Maximum rectal tolerated threshold volume (MRTTV), Rectal compliance (RC), Rectoanal inhibitory reflex (RAIR), and Rectal pressure (RP).

**Results:** The distance from the dentate line to the anastomosis in group B was significantly shorter than that in group A ( $P < 0.05$ ). ASPR in group B was significantly lower than that in groups A and C ( $P < 0.05$ ). MASPVC in group B was significantly lower than groups A and C ( $P < 0.05$ ). MRTTV in group B was significantly lower than that in groups A and C ( $P < 0.05$ ). RC in group B was significantly lower than that in groups A and C ( $P < 0.05$ ). The frequency rate of positive RAIR in group B was significantly lower than that in groups A and C ( $P < 0.05$ ). RP in group B was significantly higher than that in groups A and C ( $P < 0.01$ ).

**Conclusion:** Soiling after LAR may be due to anal sphincter dysfunction, rectal dysfunction and increase of the RP.

**Abstract ID: 0438** Specific Field: **Colon and Rectum**

**Mode of pres.: Poster Exhibition only**  
**ISW 2011 Session PE 221**

**Short-term outcomes with mechanical anastomosis and hand-sewn anastomosis in open colon cancer surgery at our hospital**

S. Sagae, S. Imai, T. Kanai

Hiratsuka City Hospital, Hiratsuka, Japan

**Introduction:** Recently, automated suturing devices are now actively being used even at sites where reconstruction by hand-sewn anastomosis can easily be performed. In general, a uniform anastomosis can be achieved in a short time, and no significant differences in postoperative complications have been reported compared to hand-sewn anastomosis. However, mastering hand-sewn anastomosis technique is vital for a gastroenterological surgeon. In this study, short-term outcomes with hand-sewn anastomosis and mechanical anastomosis in open colon cancer surgery at our hospital were investigated.

**Material and Methods:** This study included 141 patients who underwent elective open colon cancer surgery (hand-sewn anastomosis, group A, 55 patients; mechanical anastomosis, group B, 86 patients) between April 2006 and September 2010 at our hospital.

**Results:** The median operative time was 227 (122–400) min in group A and 204.5 (78–451) min in group B. Blood loss was 130.5 (10–573) ml in group A and 189.5 (10–1578) ml in group B. High risk cases (diabetes, dialysis, steroid administration, ileus) included 12 patients (21.8%) in group A and 28 (32.5%) in group B. Postoperative complications occurred in 12 (21.8%) group A patients (wound infection 8, bowel obstruction 1, anastomotic leakage 3, urinary tract infection 1, and pancreatitis 1) and 22 (25.5%) group B patients (wound infection 11, anastomotic leakage 3, bowel obstruction 3, intraperitoneal abscess 3, pneumonia 1, renal failure 1, chylous ascites 2, cholecystitis 1, and cardiac failure 1). A complication requiring reoperation occurred in one (1.8%) group A patient (anastomotic leakage) and no group B patients. Postoperatively, the day that IV infusion was discontinued was day 9 (6–43) in group A and day 9 (6–130) in group B. The length of hospital stay was 20 (12–90) days in group A and 23.5 (12–138) days in group B.

**Conclusion:** In our hospital, hand-sewn anastomosis, compared to mechanical anastomosis, was associated with greater postoperative wound infections and anastomotic leakage, but there were no marked differences in number of postoperative days of IV infusion or hospital stay. Understanding the respective advantages and disadvantages of hand-sewn anastomosis and mechanical anastomosis is important for selection in each individual case.



**Abstract ID: 0439** Specific Field: **Colon and Rectum**

**Mode of pres.: Poster Exhibition only**  
**ISW 2011 Session PE 222**

**Preoperative mechanical bowel preparation is not requisite for elective colorectal surgery**

A. Fukazawa, A. Uno, S. Suzuki, H. Ochiai, K. Matsumoto, Y. Itou, K. Inuzuka, O. Jindoh

Iwata City Hospital, Iwata, Shizuoka, Japan

**Introduction:** Mechanical bowel preparation (MBP) has been practiced before elective colorectal surgery as the standard method. Though several randomized studies showed MBP had no influence on the incidence of postoperative complication, many surgeons could not leave off MBP before surgery. The aim of this study is to confirm the safety of discontinuing MBP before elective colorectal surgery, and to evaluate the effect of pretreatment with mosapride citrate.

**Material and Methods:** Seventy two patients who underwent elective colorectal surgery in our department for a year from August 2009 were studied. Exclusion criteria were more than 3 day-fasting before surgery or the requirement for stoma creation. In this study, 30 patients in the group N received 2 l of polyethylene glycol solution or magnesium phosphate solution. Forty-two patients in the group R received 20 ml of 0.75% Sodium picosulfate. Those patients were randomly treated with 15 mg/day of mosaprid citrate in the day before surgery. Nineteen patients were pretreated with mosaprid citrate before surgery. End points were the occurrence of postoperative complication related to surgical sites. Secondary end points were the time to first passing gas after surgery.

**Results:** There were no significant differences between the group N and the group R in age, gender, the American Society of Anesthesiologist (ASA) score, the locations of diseases. Postoperative complications occurred in 40% of the patients in the group N, and occurred in 19.0% of the patients in the group R (Table 1). There were no significant differences in the incidence of postoperative complications between both groups. Anastomotic leakage occurred in 2 patients only in the group N, and one patient was required surgical drainage with a diverting stoma. Patients pretreated with mosaprid citrate showed significantly shorter time to first passing gas than that in patients without pretreatment with mosaprid citrate ( $1.77 \pm 0.26$  days vs.  $2.28 \pm 0.20$  days,  $P = 0.067$ ).

**Conclusion:** Discontinuing MBP before elective colorectal surgery can be safe and feasible. The treatment with mosaprid citrate before surgery might be effective in the early recovery of the normal bowel movement.

The overview of postoperative complications

	Group N ( <i>n</i> = 30)	Group R ( <i>n</i> = 42)	<i>P</i>
Overall complications	18	8	0.0645
Anastomotic leakage	2	0	NE
Surgical site Infection	6	4	0.1506
Bowel obstruction	4	2	0.2267
Others	6	2	

**Abstract ID: 0440** Specific Field: **Colon and Rectum**

**Mode of pres.: Poster Exhibition only**  
**ISW 2011 Session PE 223**

**Efficacy of covering ileostomy for rectal cancer**

T. Itabashi, K. Otsuka, T. Kimura, K. Fujisawa, M. Hakozaiki, Y. Akiyama, Y. Fujii, A. Sasaki, G. Wakabayashi

Iwate Medical University, Morioka, Japan

**Introduction:** It is considered that covering ileostomy (hereinafter referred to as CI), which is performed in combination with rectal cancer surgery, is a useful treatment for complications such as postoperative anastomotic leakage. We have retrospectively investigated the usefulness of CI.

**Material and Methods:** Between January 2004 to November 2009, 655 patients were operated for colorectal cancer in whom 169 cases for which a lower anterior resection.

**Results:** CI was performed on 29 cases (17.2%). Of the 140 cases for which CI was not performed, complications occurred in 21 cases (16.8%) (13 cases of anastomotic leakage, 6 cases of ileus (including 3 cases of enteritis) and 2 cases of secondary haemorrhage), and all the cases of anastomotic leakage required surgery. Of the 18 CI cases, complications occurred in 9 cases (50%) (3 cases of anastomotic leakage and 6 cases of ileus (including 2 cases of enteritis)), but no case required surgery. The incidence of ileus, as related to CI, was high at 44.4%. The median lengths of hospitalization were 9 days in the cases for which CI was not performed and had no complications, 49 days in the cases for which CI was not performed and had complications, 19 days in the cases for which CI was performed and had no complications, and 34 days in the cases for which CI was performed and had complications. When complications were observed, the length of hospitalization was reduced by 15 days in the CI cases. When CI was performed and complications were not observed, it required a 5-day extension in the length of stay for the purposes of educating the patient regarding the stoma and/or treatment for complications. It has been noticed that the number of rectal cancer surgery cases has increased with each passing year. Although the percentage of colostomy (permanent and temporary) has also increased, no increase has been observed in the percentage of permanent stomas.

**Conclusion:** Summary: When post-operative complications occurred, CI was useful in order to avoid repeat surgery and reduce the length of hospitalization. For the cases in which complications did not occur, CI served as an inducement to extend the length of stay as well as unnecessary complications. Conclusion: It is considered that while CI is a useful procedure, it is necessary to conduct a thorough examination when choosing cases for which CI will be performed.

**Abstract ID: 0441** Specific Field: **Colon and Rectum**

**Mode of pres.: Poster Exhibition only**  
**ISW 2011 Session PE 224**

**A case of catheter fracture of totally implantable access port implanted through right internal jugular vein**

T. Shimizu, E. Mekata, T. Tatsuta, T. Miyake, S. Murata, S. Naka, Y. Kurumi, T. Tani

Shiga University of Medical Science, Otsu, Japan

**Introduction:** Totally implantable access ports (TIAP) has been widely used for a safe delivery of chemotherapy or parenteral nutrition in patients with malignant disease and other debilitating diseases.

The complications related to TIAP were reported to be pneumothorax, hemothorax, centesis of artery, infection, obstruction or fracture of catheter and so on. The pinch-off-syndrome is reported as a catheter fracture when the catheter was inserted through subclavicular vein. We mainly employed the implantation of TIAP with catheter insertion via the right internal jugular vein to avoid the pinch-off syndrome.

**Material and Methods:** We experienced an extremely rare case of catheter fracture of TIAP implanted through right internal jugular vein. To our best knowledge, there are only two reports of this complication including present case.

**Results:** A 35-year-old male had a history of left lower lobe resection due to lung cancer (Mucinous-alveolar carcinoma, mucous cell type, T2N0M0, Stage Ib) and low anterior resection due to rectal cancer (moderately differentiated adenocarcinoma, T3, N1, M1, Stage IV). Patient was implanted TIAP through right internal jugular vein under ultrasonography guide 25 days after low anterior resection for chemotherapy. When pre-mediation was administered 785 days after TIAP implantation, patient complained of right cervical pain. The chest X-ray examination revealed that the catheter fractured on the clavicle and separated catheter tip existed in the heart. The strap of backpack contacted and compressed to the fractured part.

**Conclusion:** Although catheter fracture of TIAP implanted through right internal jugular vein is extremely rare, the caution and education for medical staff and patients should be required to avoid catheter fracture due to this kind of external factor.

**Abstract ID: 0442** Specific Field: **Colon and Rectum**

**Mode of pres.: Poster Exhibition only**  
**ISW 2011 Session PE 225**

**Mesenteric panniculitis after colon cancer surgery: five cases reports and a review of the literature in Japan**

M. Naito, M. Watanabe, T. Sato, A. Ikeda, N. Ogura, W. Onozato, T. Nakamura

Kitasato University, Sagamihara, Japan

**Introduction:** We would like to present five cases regarding mesenteric panniculitis (MP) after colon cancer surgery. The first patient, a 42-year-old male with transverse colon cancer, underwent the laparoscopic partial resection of the transverse colon and the functional end-to-end anastomosis (FEEA). On the postoperative day (POD) 14, he showed clinical signs of the bowel obstruction. The computed tomography scan (CT) revealed anastomotic inflammatory change. He was diagnosed as the MP, undergoing the subtotal colectomy and the diverting ileostomy on the same day. The second patient, a 79-year-old male, underwent the laparoscopic partial resection of the transverse colon as well as the FEEA. He indicated the symptom of ileus on the POD 12, resulting in the treatment for his ileus tube. He was diagnosed as the MP by the CT scan and the contrast study. Diverting ileostomy was operated after the operation day 23. The third patient, a 82-year-old male with transverse colon cancer, underwent the partial resection and the FEEA. He showed the symptom of ileus on the POD 9, indicating the same symptom on the day 12 as well. Diagnosed as the MP by the CT, he was treated for his ileus tube. Diverting ileostomy was conducted after the operation day 14. The fourth patient, a 62-year-old male with descending colon cancer, underwent the left-hemicolectomy and the FEEA. A hard mass was palpated in the left abdomen. Ileus appeared on the day 7. The CT revealed anastomotic inflammatory change. He was diagnosed as the MP. Conservative therapy was performed using a gastric tube. The last patient, a 71-year-old female with descending colon cancer, underwent the left-hemicolectomy and the FEEA. She showed

the symptom of ileus on the POD 6. The CT on POD 48 revealed anastomotic inflammatory change. She was diagnosed as the MP. Conservative therapy was performed by total parenteral nutrition. All patients underwent the FEEA. These anastomoses may be the causes of MP after colon surgery as well as the reasons for anastomotic tension, blood flow and so on. It is important to keep in mind the possibility of MP when you consult a patient suggesting bowel obstruction and inflammation after surgery.

**Abstract ID: 0443** Specific Field: **Colon and Rectum**

**Mode of pres.: Poster Exhibition only**  
**ISW 2011 Session PE 226**

**Utility of intraoperative ultrasound for anorectal disease**

K. Akiharu, F. Kimihiko, J. Koike, M. Satoshi, S. Hiroyuki, M. Watanabe, H. Shimada, K. Hironori

Toho University Omori MedicalCenter, Tokyo, Japan

**Introduction:** However, it still relies on the digital examination at the diagnosis. The anorectal diseases such as hemorrhoids and anal fistula also are a general surgical disease, and have a lot of cases. There were more rarely of intraoperative diagnosis. The ultrasound is simple and noninvasive examination. Furthermore, we have the objectivity for the ultrasound, too. An accurate and safety operation becomes possible by using the ultrasound.

**Material and Methods:** Diagnostic Ultrasound System Nemio (Toshiba Medical System Corporation) Probe Linear type of 5 MHz (Toshiba Medical System Corporation).

**Results:** We decide the position of appropriate drainage for the perineal sepsis. If there were deep abscess, drainage was performed by using ultrasound at real time. I confirm whether there is not residual abscess after the drainage. Radicability and sphincter preservation are enabled for an anal fistula. We measure blood flow in hemorrhoids by using Doppler ultrasound. When there is much blood flow, we use ultrasonic scalpel. As a result, we can reduce postoperative bleeding. We confirmed the sphincter damage, and accurate repair was possible. We confirm depth of the rectal cancer just before operation, and safety and reliable operation are enabled.

**Conclusion:** Intraoperative ultrasound is useful for anorectal disease.

**Abstract ID: 0444** Specific Field: **Colon and Rectum**

**Mode of pres.: Poster Exhibition only**  
**ISW 2011 Session PE 227**

**The actuarial incidence of intestinal failure in Crohn's disease: thirty-five year experience**

K. Watanabe, H. Ogawa, K. Miura, T. Naitoh, N. Yazaki, S. Haneda, C. Shibata, I. Sasaki

Tohoku University Hospital, Sendai, Japan

**Introduction:** Intestinal failure (IF) is one of the most serious complications in patients with Crohn's disease (CD). IF results from surgical resection or disease-associated loss of absorption and is characterized by the inability to maintain protein-energy, fluid, electrolyte, or micronutrient balance when on a conventionally accepted, normal diet. Patients with IF required enteral or parenteral nutrition. To date, little is known about the actuarial incidence of IF in patients with CD. The aim of the present study was to clarify the actuarial incidence of IF in patients with CD after surgery.

**Material and Methods:** Between 1970 and 2009, 268 patients with CD underwent surgery at our hospital (1970s,  $n = 7$ ; 1980s,  $n = 30$ ; 1990s,  $n = 101$ ; 2000s,  $n = 130$ ). The mean age at diagnosis of CD was 25 years and the mean age at the initial surgery was 29 years. The following period after initial surgery was  $9 \pm 7$  (0.5–35) years (mean  $\pm$  SD, range). We retrospectively reviewed the medical records of the 268 patients and analyzed the actuarial incidence of IF.

**Results:** Seventeen patients (6.3%) developed IF during the study periods. The first surgery was performed as follow periods; 1980s,  $n = 8$ ; 1990s,  $n = 9$ . All patients required home parenteral nutrition. In patients with IF, the age at diagnosis of CD was 24 years, the age at the initial surgery was 29 years, the age at IF was 42 years, and the following period after IF was 8 y years (mean). The mean number of surgery was 3.5 times and the mean length of small bowel is 155 cm at the time of IF. The actuarial incidence of IF is 0.5% at 5 years, 5.9% at 10 years, 13.4% at 15 years, and 15.7% at 20 years after initial surgery. Implanted port-catheter related sepsis was the most common complication in IF (82%).

**Conclusion:** With the long term survey, we clearly revealed the actuarial incidence of IF in patients with CD after surgery. IF was very rare (0.5%) within 5 years after the first operation, however, surprisingly, the rate of IF increased more than 10% after 10 years. The number of CD patients was rapidly increasing in Japan ( $n = \sim 10,000$  at 1993;  $n = \sim 30,000$  at 2008), therefore the number of IF patients may also increase, too. We now challenge the multiple center study in collaboration with Study Group of IBD under the sponsorship of the Japanese Ministry of Health, Labor and Welfare to establish the management of IF.

**Abstract ID: 0445** Specific Field: **Colon and Rectum**

**Mode of pres.: Poster Exhibition only**  
**ISW 2011 Session PE 228**

#### Ileal W pouch-anal anastomosis for ulcerative colitis

T. Iiai [1], H. Kameyama [1], H. Nogami [1], Y. Shimada [1], M. Fushiki [1], Y. Tajima [1], Y. Yagi [1], K. Hatakeyama [2]

[1] Niigata University, Niigata, Japan, [2] Niigata University, Japan

**Introduction:** Restorative proctocolectomy and ileal pouch-anal anastomosis (IPAA) has become the procedure of choice for majority of patients with ulcerative colitis (UC) who require surgery. In 1985 IPAA for UC was started at our institute and usually we used W-ileal reservoir for restorative proctocolectomy.

**Material and Methods:** Our standard operation for UC is IPAA with proctal mucosectomy and hand-sewn anastomosis to avoid recurrence and cancer risk. Usually pouch configuration was W-shaped for much volume and temporary diverting ileostomy was constructed. There were 157 UC patients who had undergone IPAA between 1985 and 2009 in our institute. Mean age at the time of IPAA was 36.7 (14–69). There were 81 male and 76 female. All patients underwent two or three stage procedure. W-pouch was constructed in 138 (87.9%) of 157 patients. In this study, short and long term results after IPAA with these 138 W-ileal reservoirs were analyzed.

**Results:** There was no peri-operative death. Wound infection was found in 34 cases (24.6%) and intra-abdominal abscess was found in 6 cases (4.3%). Bowel obstruction was found in 20 cases (14.5%). Pouchitis, which is the most important complication after IPAA, was found in 19 cases (13.8%) and most of them were cured by antibiotics. Pouch failure was found in two patients. One patient did not undergo closure of diverting ileostomy because of ischemic change of the pouch. One patient needed pouch excision for pouch related late abscess due to perforation. So pouch functional rate was 98.2% by

Kaplan–Meier method. Two patients could not stop steroids after surgery, because of joint pain and severe diarrhea. In 136 patients with functional pouch, mean bowel movement was about 4 to 5 times daily and soiling especially at night occurred in 30%. About 30% of patients needed antidiarrheal drugs for diarrhea. All patients returned to their schoolwork or occupations and were good in quality of life (QOL) after surgery.

**Conclusion:** Restorative proctocolectomy and IPAA with W-ileal reservoir was performed safely and provided good bowel function and QOL. W-ileal reservoir is acceptable procedure for IPAA.

**Abstract ID: 0446** Specific Field: **Colon and Rectum**

**Mode of pres.: Poster Exhibition only**  
**ISW 2011 Session PE 229**

#### Treatment of pouchitis after ileal pouch-anal anastomosis for ulcerative colitis

T. Iiai, H. Kameyama, H. Nogami, Y. Shimada, M. Fushiki, Y. Tajima, Y. Yagi, K. Hatakeyama

Niigata University, Niigata, Japan

**Introduction:** Restorative proctocolectomy with ileal pouch-anal anastomosis (IPAA) has become the procedure of choice for majority of patients with ulcerative colitis (UC) who require surgery. After surgery most patients experience a satisfactory functional outcome, however pouchitis, one of the late complications, may occur following IPAA in approximately 30% of patients. Sometimes pouchitis causes pouch dysfunction and the strategy of medical treatment for pouchitis has been not clear.

**Material and Methods:** Our standard operation for UC is IPAA with proctal mucosectomy and hand-sewn anastomosis. 157 UC patients had undergone IPAA between 1985 and 2009 in our institute. There were 81 male and 76 female. Diagnosis of pouchitis was made by Japanese criteria which consist of assessment of clinical symptoms and endoscopic findings. In this study, patients with pouchitis in our institute were analyzed.

**Results:** Patients with pouchitis were 21 cases (13.4%). 9 cases were male and 12 cases were female. Mean duration between stoma closure and onset of pouchitis was 46 (1–127) months. 17 patients (80.9%) had watery diarrhea or increase of stool frequency. 12 patients (57.1%) had abdominal pain or fecal urgency. Endoscopic examination revealed severe type in 8 patients and moderate type in 13 patients. 10 patients were transient type, 8 patients were relapse-remitting type, and 3 patients were chronic type. 2 patients were cured by symptomatic therapy and 14 patients (66.7%) were cured by antibiotics such as metronidazole, however 5 patients needed steroids for remission. There was no pouch dysfunction due to pouchitis.

**Conclusion:** Pouchitis was the most important complication after IPAA for UC. In our institute 66.7% of patients with pouchitis responded to antibiotics however some patients need steroids. To establish new treatment strategy for pouchitis further examination will be needed.

**Abstract ID: 0447** Specific Field: **Colon and Rectum**

**Mode of pres.: Poster Exhibition only**  
**ISW 2011 Session PE 230**

#### Laparoscopic surgery for Crohn's disease: predictive risk factors for conversion to open surgery

H. Ozawa [1], T. Nakamura [2], A. Ikeda [2], T. Sato [2],  
M. Naito [2], H. Matsushita [1], H. Shirakawa [1], M. Watanabe [2]

[1] Tochigi Cancer Center, Utsunomiya, Japan, [2] Kitasato  
University School of Medicine, Sagamihara, Japan

**Introduction:** This study aimed to identify risk factors that were important determinants of conversion to open surgery during laparoscopic surgery for Crohn's disease.

**Material and Methods:** We retrospectively reviewed a maintained database of 45 patients who underwent laparoscopic surgery for Crohn's disease at our institution from 1996 through 2009.

**Results:** Laparoscopic surgery was attempted 48 times in the 45 patients and was successfully completed 43 times (Group L) and converted to open surgery 5 times (Group C). The median age was 31 (range 14–80) years in Group L and 30 (range 22–54) years in Group C ( $P = 0.681$ ). Nine patients had a previous abdominal surgery in Group L, as compared with 1 patient in Group C ( $P = 0.961$ ). Surgery for recurrent disease was performed in 5 patients in Group L and 1 patient in Group C ( $P = 0.592$ ). Twelve patients in Group L and 2 in Group C had perforating-type disease ( $P = 0.573$ ). Two patients in Group L and 1 in Group C had an abscess ( $P = 0.179$ ). Small bowel dilation was present in 5 patients in Group L, as compared with 3 in Group C ( $P = 0.006$ ). The median C-reactive protein level was 0.3 (range 0.1–6.2) mg/dl in Group L and 0.8 (range 0.1–7.9) mg/dl in Group C ( $P = 0.080$ ). The median body mass index was 18.6 (range 13.2–26.1) in Group L and 16.1 (range 14.6–20.3) in Group C ( $P = 0.117$ ). The median Crohn's Disease Activity Index was 101.2 (range 0–313) in Group L and 199.6 (range 68.8–218.3) in Group C ( $P = 0.094$ ). The reason for conversion to open surgery was a narrow working space 3 times, adhesion 1 time, and duodenal fistula 1 time. Multivariate analysis found that the small bowel dilation ( $P = 0.036$ ) was independent predictors for conversion.

**Conclusion:** Important risk factor for conversion to open surgery during laparoscopic surgery for Crohn's disease was the presence of a dilated small intestine.

**Table 1** Patient characteristics

	Group L	Group C	<i>P</i> value
Surgery ( <i>n</i> )	40	5	
Male/female	37/6	3/2	0.1390
Median age at operation (years) [range]	31 [14–80]	30 [22–54]	0.6810
Previous abdominal surgery( <i>n</i> )	9	1	0.9613
Recurrent disease ( <i>n</i> )	5	1	0.5921
Perforating type ( <i>n</i> )	12	3	0.5733
Abscess ( <i>n</i> )	2	1	0.1796
Small bowel dilation ( <i>n</i> )	5	3	0.0060
Median CRP (mg/dl) [range]	0.3 [0.1–6.2]	0.8 [0.1–7.9]	0.0800
Median BMI [range]	18.6 [13.2–26.1]	16.0 [14.6–20.3]	0.1176
Median CDAI [range]	101.2 [0–313]	199.6 [68.8–218.3]	0.0940
Median IOIBD [range]	1 [0–7]	2 [1–3]	0.2652

**Abstract ID: 0448** Specific Field: **Colon and Rectum**

**Mode of pres.: Poster Exhibition only**  
**ISW 2011 Session PE 231**

**Clinicopathological study in patients with ulcerative colitis preoperatively diagnosed as dysplasia or colitic cancer**

M. Fushiki, T. Iiai, Y. Shimada, H. Kameyama, H. Nogami,  
Y. Ajioka, K. Hatakeyama

Niigata University, Niigata, Japan

**Introduction:** Ulcerative colitis (UC) is well known to be a high risk group of the colorectal cancer in western countries. Recently, the number of patients of inflammatory bowel diseases increased in Japan and it has become more important clinical problem that the UC patients complicated with dysplasia or colitic cancer also increased.

**Material and Methods:** 15 (8 males, 7 females, mean age 45.7) patients with ulcerative colitis were diagnosed as dysplasia or colitic cancer preoperatively and underwent surgical treatment in our institute. Average disease duration at operation was 16.1 years. All cases were pancolitis type. The clinical and pathological parameters were analyzed. Overall survival rates were analyzed according to Kaplan–Meier method.

**Results:** 11 patients were diagnosed as colitic cancer and four patients were diagnosed as dysplasia preoperatively, however post-operative pathological examination confirmed that cancer was in 12 patients, dysplasia was in two patients and one patient had non-neoplastic tissue. The histological type of cancer was well differentiated adenocarcinoma in seven patients, moderate differentiated adenocarcinoma in four patients and endocrine cell carcinoma in one patient. three patients presented with TNM Stage 0, five patients Stage I, two patients with Stage II, one patient with Stage III and one patient with Stage IV. 13 patients underwent total proctocolectomy and ileo-anal anastomosis, two patients with far advanced rectal cancer underwent abdominoperineal resection. All patients except one who had distant metastasis were treated with curative resection. The 5-year survival rate of colitic cancer patients was 78.6%.

**Conclusion:** In our institute, the surgical outcome of colitic cancer with UC was good, because almost patients were in early stage at cancer diagnosis. As development of colitic cancer was more likely to occur in patients with long-duration of UC, these patients should undergo surveillance colonoscopy for the early detection of colitic cancer.

**Abstract ID: 0449** Specific Field: **Colon and Rectum**

**Mode of pres.: Poster Exhibition only**  
**ISW 2011 Session PE 232**

**To determine if clinical outcome was compromised by laparoscopic procedure in rectal resections**

S. Zeidan, K. Patel, K. Flashman, J. S. Khan, A.C. Parvaiz

Portsmouth Hospitals NHS Trust, United Kingdom

**Introduction:** Laparoscopic colonic surgery has gained widespread acceptance, however its application in rectal surgery is still limited. There is concern regarding oncological and functional outcomes. We present our experience of laparoscopic rectal surgery from a high volume centre in the UK.

**Material and Methods:** Analysis of data collected prospectively of all consecutive patients who underwent elective laparoscopic surgery for rectal lesions (benign and cancer) in a single district general



hospital (October 2006–December 2010). End points included post-operative mortality, length of stay and complication rates.

**Results:** Of 201 patients who received laparoscopic rectal resection, 64% (128) were male, and median age was 69 years. Diagnosis included 198 (99%) adenocarcinoma and 3 (1%) adenoma. Operation included 160 (80%) anterior resection (AR), 32 (16%) APER, 5 (2%) Hartmanns, and 4 other. 45 (22%) had ASA grade 3 or 4. Preoperative radiotherapy was received by 43 (21%). Median operating time was 250 min. Eight (4%) were converted to open surgery.

**Conclusion:** Clinical outcome was not compromised by using a laparoscopic approach in rectal resections.

#### Outcomes

	N	%
Lymph node harvest (median, range)	12 (2)	
pT3 or pT4 tumours	121	60
R0 margins (curative intent only –167)	163	98
Length of hospital stay days (median, range)	6 (2)	
Major anastomotic leak rate (AR 160)	2	1.3
Reoperation (<31 days of surgery)*	9	4.5
Post-operative mortality**	3	1.5
Readmission (<31 days surgery)	36	18
Local recurrence	5	2.5
*2 leaks, 2 wound & 4 stoma revision; **cardiac	2	

**Abstract ID: 0450**

Specific Field: **Esophagus**

**Mode of pres.: Free Paper**  
**ISW 2011 Session 22.01**

#### What is the appropriate timing for surgery after neoadjuvant chemoradiation for esophageal cancer

D. Tong [1], S. Law [1], D.L.W. Kwong [2], S.Y. Chan [1], K.H. Wong [1]

[1] Department of Surgery, The University of Hong Kong, Queen Mary Hospital, Hong Kong, China, People's Republic,  
[2] Department of Clinical Oncology, The University of Hong Kong, Queen Mary Hospital, Hong Kong, China, People's Republic

**Introduction:** The optimal interval between neoadjuvant chemoradiation (CRT) and surgery has not been elucidated for squamous esophageal cancer (ESC). The aim of this study is to evaluate the impact of this time interval on postoperative and long-term outcomes.

**Material and Methods:** A total of 107 patients with intrathoracic ESC treated with neoadjuvant CRT between 2002 and 2009 were analyzed from a prospectively collected database. Patients were divided into three groups based on the interval between completion of CRT and surgery: group A: <40 days ( $n = 16$ ); B: 41–80 days ( $n = 60$ ); and C: > 80 days ( $n = 31$ ). Survival was also compared by dividing these patients into two groups using the median interval (64 days) as the cutoff point: group A\* ( $n = 54$ ) and B\* ( $n = 53$ ). Intraoperative parameters, postoperative outcomes, pathological data and long-term survival were investigated.

**Results:** The three groups were comparable in patient and tumor characteristics, intraoperative parameters, postoperative morbidity

and mortality. Pathological analysis showed that the median number of lymph nodes harvested was comparable. All three groups had significant rate of downstaging [A:  $n = 8$  (50%), B:  $n = 43$  (71.7%), C:  $n = 21$  (67.7%)]. For group A, the rate of R0 resection was significantly lower than the other two groups [A:  $n = 9$  (56.3%), B:  $n = 54$  (90%), C:  $n = 23$  (74.2%),  $P = 0.006$ ]. The pathological complete response (pCR) rates were comparable [A:  $n = 5$  (31.2%), B:  $n = 21$  (35%), C:  $n = 6$  (19.4%),  $P = 0.301$ ]. Overall 3-year survival were 73.4, 66.7, and 53.5% respectively,  $P = 0.23$ . After R0 resection, group A had longer 3-year survival (100%) compared to group B (73%) and C (64.4%), (log-rank test: A vs. B,  $P = 0.04$ ; A vs. C,  $P = 0.015$ ; B vs. C,  $P = 0.315$ ). Using the median interval (64 days) as the dividing point, the overall 3-year survivals of group A\* and B\* were 71.1 and 56.5%, respectively,  $P = 0.081$ . If R0 was achieved, the 3-year survival of group A\* and B\* were 83.4 and 64.3%,  $P = 0.023$ . With R0 resection, though statistically not significant, there was no tumor recurrence detected in group A, whereas 8 (14.8%) and 5 (21.7%) patients had tumor recurrence in group B and C during follow up,  $P = 0.302$ .

**Conclusion:** Interval between CRT and surgery did not affect post-operative morbidity and mortality. Although early surgery seemed to result in less R0 resection, overall survival was not compromised. In those with R0 resection, better survival was attained. Delayed surgery may compromise long-term survival.

**Abstract ID: 0451**

Specific Field: **Esophagus**

**Mode of pres.: Free Paper**  
**ISW 2011 Session 22.02**

#### The JES Consensus Meeting 2010

H. Fujita [1], Y. Kitagawa [2]

[1] Kurume University School of Medicine, Kurume, Japan, [2] Keio University School of Medicine, Tokyo, Japan

**Introduction:** This Consensus Meeting was planned as the main session of the 64th Annual Meeting of the Japan Esophageal Society (JES). Using the answer pad system, each participant chose one answer among three to five answers for a total of 33 questions concerning perioperative management, treatment strategies for esophageal cancer and others.

**Material and Methods:** Around 170 participants joined this Consensus Meeting; 89% were surgeons. The majority of the participants were working in university hospitals or cancer centers.

**Results:** Concerning perioperative management, 56% of the participants supported to cease tracheal intubation for respiratory support IPOD. 52% supported the combination of tube feeding and intravenous hyperalimentation (IVH) as preoperative nutritional support, and 50% supported the combination of tube feeding, IVH and peripheral transfusion as postoperative nutritional support. 63% supported to start tube feeding 1 to 3POD, while only 21% supported to start it within 24 h. 63% supported to start peroral intake on 7POD. As a check before peroral intake, 62% used esophagography, while 30% did not check. Concerning treatment strategies in each stage, all the participants supported endoscopic treatment for cancer at the stage of T1a-EP and LPM. 43% supported endoscopic treatment, and another 43% supported esophagectomy for cancer at the stage of T1a-MM and of T1b-SM1. 84% supported esophagectomy for cancer at the stage of T1b-SM2 and SM3. 74% supported neoadjuvant chemotherapy (CTx) plus esophagectomy for cancer at the stage II or III. Definitive chemoradiotherapy (dCRTx) plus salvage surgery for

cancer at stage cT4 (Aorta and Tracheobronchus) was supported by 70%. Concerning treatment for cStage IVb with dysphagia, CRTx was supported by 43%, and CTx was supported by 24%. Concerning treatment for cStage IVb without dysphagia, CTx was supported by 75%, and CRTx was supported only by 21%. Concerning the chemotherapy regimen as neoadjuvant CTx, standard FP (5FU/CDDP) was supported by 60%, and DFC (Docetaxel/5FU/CDDP) was supported by 19%. Concerning the CTx regimen for non-surgical cases, DFC was supported by 47%, and standard FP was supported by 40%.

**Conclusion:** The JES Consensus Meeting 2010 where 170 JES active members participated clarified the relationship between the Japanese Classification and the Guidelines, and also determined policy for the treatment strategy in practice for esophageal cancers.

**Abstract ID: 0452**

Specific Field: **Esophagus**

**Mode of pres.: Free Paper**

**ISW 2011 Session 22.03**

**A clinical study of the salvage surgery after definitive chemoradiotherapy for locally advanced esophageal cancer (cT4NxM0)**

Y. Kimura, T. Iwaya, M. Konosu, K. Koeda, H. Fujiwara, S. Nishizuka, K. Otsuka, G. Wakabayashi

Department of Surgery, Iwate Medical University, Morioka, Japan

**Introduction:** Definitive chemoradiotherapy is the most common treatment strategy for unresectable locally advanced esophageal cancer. Although the short term survival can be achieved through this strategy, both persistent and recurrent locoregional diseases are still major problems. When definitive CRT fails to achieve local control, relapse or treatment-related complication without distant metastases, salvage esophagectomy is the only treatment available that can offer a chance of long-term survival. However, the clinical significance and safety of salvage surgery has not been well established. The aim of this study was to evaluate the complications and outcomes of salvage esophagectomy following definitive chemoradiotherapy (CRT) for locally advanced esophageal cancer patients.

**Material and Methods:** We selected the records of all esophageal cancer patients ( $n = 842$ ) between January 1992 and December 2010 at Iwate Medical University and reviewed the cases of patients ( $n = 60$ ) who underwent definitive chemoradiation therapy for unresectable locally advanced esophageal cancer. Salvage surgery was performed on 16 patients for remnant or recurrent cancer following definitive chemoradiotherapy.

**Results:** Patient characteristics were as follows: median age, 58 years. Median fraction and total doses of external irradiation given were 2.0 Gy and 60 Gy, respectively. All patients received chemotherapy, most of the regimens of which included cisplatin and 5-fluorouracil. The median time between the end of CRT and surgery was 85 days. Curative resection was achieved in all patients. Complications occurred in eight cases: Severe pneumonia in four patients, open wound of abdominal wall in two cases. There is no patient of anastomotic leakage occurred and died in the hospital. The median hospitalization was 60 days. With a median follow-up period of 39.5 months, the 5-year survival calculated from the completion of salvage surgery was 61.1%.

**Conclusion:** Patients who underwent salvage esophagectomy after definitive chemo-radiotherapy had increased infection complications. However, there are long-term survivors, salvage esophagectomy is an elective therapeutic option for carefully selected patients at experienced centers.

**Abstract ID: 0453**

Specific Field: **Esophagus**

**Mode of pres.: Free Paper**

**ISW 2011 Session 22.04**

**A retrospective analysis for a relevant follow up strategy in esophageal cancer patients treated by definitive chemoradiotherapy**

K. Mori [1], H. Yamashita [1], K. Yamada [2], T. Fukuda [1], H. Ishigami [1], S. Kaizaki [1], J. Kitayama [1], Y. Seto [1]

[1] The University of Tokyo Hospital, Tokyo, Japan, [2] The Cancer Institute Hospital of Japanese Federation of Cancer Research, Tokyo, Japan

**Introduction:** Chemoradiotherapy (CRT) is increasingly indicated for esophageal cancer patients and salvage surgery would be the choice for patients who developed locoregional recurrence after CRT. However, optimal surveillance strategy after chemoradiotherapy for esophageal cancer is not known.

**Material and Methods:** We retrospectively viewed 78 consecutive esophageal patients treated by definitive chemo-radiotherapy in our hospital from 2004 to 2008. We investigated their clinical outcome, the proportion of patients who had a potential chance of cure by salvage surgery and the time interval between the identification of the local failures and their development to incurable disease for patients who avoided salvage treatments.

**Results:** 47 patients were eligible for our current analysis. 13 patients maintained the status of disease free with CRT after 1–5 years of follow up while three out of 10 patients who underwent salvage treatments were so far successfully managed. These three patients had T1N0 or T0N1 disease as the target of salvage. For seven patients who avoided salvage treatments, the interval between the recognition of recurrence and development to incurable disease ranged from one to seven months with a median of three months.

**Conclusion:** Residual disease or recurrence of esophageal cancer after CRT showed clinically aggressive behavior but not necessarily incurable. CT scan at three months' interval would be necessary to detect recurrence before growing T4 disease. Disease detection before developing to T3 by endoscopy could lead to the better outcome of salvage treatments. Survival benefit of the close follow up should be validated in a prospective study.

**Abstract ID: 0454**

Specific Field: **Esophagus**

**Mode of pres.: Free Paper**

**ISW 2011 Session 22.05**

**An enhanced recovery after surgery program after thoracic esophageal cancer surgery**

H. Sato, M. Niihara, Y. Tsubosa

Shizuoka Cancer Center, Sunto-gun, Japan

**Introduction:** Enhanced recovery after surgery (ERAS) is a multimodal program of multidisciplinary care designed to minimize post-operative organ dysfunction and return the patient to normality as soon as possible. The recent consensus review concluded that ERAS appears to reduce the primary length of hospital stay and complication rates. Data on enhanced recovery programs after thoracic esophageal cancer surgery are sparse. The aim of this study was to evaluate the impact of an enhanced recovery after surgery (ERAS) program in patients who had undergone transthoracic esophagectomy.

**Material and Methods:** Between January 2007 and May 2010, 70 patients who underwent a transthoracic esophagectomy were put enrolled into the ERAS program which included early post-operative enteral nutrition and mobilisation. The program was started on the first postoperative day (IPOD). Mobilization was initiated on IPOD and enteral nutrition was begun on IPOD. Routine postoperative bronchoscopy for toileting sputum and mechanical bowel preparation (MBP) before surgery were performed only when considered to be necessary. The outcome measures comprised the mortality rate, morbidity rate, pulmonary complication, pneumonia and length of hospital stay. This was a retrospective study.

**Results:** The mortality rate was zero. The rates of morbidity, pulmonary complications, and bacterial pneumonia were 41, 7 and 1%, respectively. The average post-operative days when the patients started walking was 1.0 day. The length of hospital stay was 21.8 days.

**Conclusion:** Implementation of the ERAS program after transthoracic esophagectomy was in fact feasible and safe without compromising patient outcomes. Especially, this program was effective for preventing pulmonary complications and bacterial pneumonia.

**Abstract ID: 0455**                      Specific Field: **Esophagus**

**Mode of pres.: Free Paper**  
**ISW 2011 Session 22.06**

**Feasibility of surgical approach and lymph node dissection for Siewert type II carcinoma at the esophagogastric junction**

K. Koyanagi, S. Tabuchi, H. Tawara, I. Koyama

Department of Gastroenterological Surgery, Saitama Medical University, International Medical Center, Hidaka, Japan

**Introduction:** A consensus on therapeutic strategies for cancer at the esophagogastric junction (EGJ) has not been achieved. The aim of the study was to assess the feasibility of surgical approach and lymph node dissection for the patients with Siewert type II carcinoma.

**Material and Methods:** The 39 consecutive patients with Siewert Type II carcinoma (31 males and 8 females; 47–92 (median: 72) years old) (6.5%) obtained from 601 cases of esophageal or gastric cancers that underwent surgical resection in our institution between 2008 and 2010 was assessed. Follow-up period was 1–32 (median: 13) months.

**Results:** There were 11 patients whose tumors invaded to thoracic esophagus. Of the 11 patients, trans-thoracic operation was performed in 7 patients (right thoracic, 5; left thoracic, 2). In other 4 patients, trans-thoracic approach was not selected, but transhiatal lower esophagectomy was performed, because of their age and other organ failures (renal and respiratory). Including these 4 patients, transhiatal lower esophagectomy was performed in 9 patients. Dissection of lymph nodes along the lower thoracic esophagus (LN station No. 110) was performed in above 16 patients who underwent lower esophagectomy and metastatic tumors were found in one (6%) patient. Of the 16 patients, dissection of supradiaphragmatic and posterior mediastinal lymph node (LN station No. 111 and 112) were performed in 8 patients and no metastatic tumors were found pathologically. Right cardiac (LN station No. 1), left cardiac (No. 2), lesser curvature (No. 3), left gastric artery (No. 7), infradiaphragmatic (No. 19), and esophageal hiatus of the diaphragm (No. 20) lymph nodes were routinely dissected in all 39 patients, and metastatic tumors were found in 7 (18%), 2 (5%), 14 (36%), 7 (18%), 1 (3%), and 1 (3%) patient, respectively. There were 15, 3, 4, 6, 4, 5, and 2 patients in pathological stages IA, IB, IIA, IIB, IIIA, IIIB, and IIIC, respectively. Only a patient suffered the relapse of the disease (bone metastasis), however, no lymph node recurrence was observed during follow-up period.

**Conclusion:** In Siewert type II carcinoma at EGJ, lymph node dissection from gastric cardia or lesser curvature to celiac artery should be performed thoroughly. To assess the significance of mediastinal lymph node dissection, long-term follow-up might be needed.

**Abstract ID: 0456**                      Specific Field: **Esophagus**

**Mode of pres.: Free Paper**  
**ISW 2011 Session 22.07**

**Cytocidal effects of hypotonic shock with distilled water on esophageal squamous cell carcinoma cells**

T. Kosuga, A. Shiozaki, D. Ichikawa, S. Komatsu, H. Fujiwara, K. Okamoto, T. Ochiai, E. Otsuji

Kyoto Prefectural University of Medicine, Kyoto, Japan

**Introduction:** The presence of exfoliated cancer cells in the pleural cavity after resection of thoracic esophageal carcinoma has been reported, and positive pleural lavage cytology before thoracic closure is recognized as a prognostic indicator of recurrence in thoracic esophageal carcinoma. Therefore, effective pleural lavage is clinically important at the time of initial surgery for thoracic esophageal carcinoma. This study aimed to investigate cytocidal effects of hypotonic shock on esophageal squamous cell carcinoma (ESCC) cell lines, and to apply pleural lavage with distilled water to surgery for ESCC.

**Material and Methods:** Three Human ESCC cell lines, TE5, TE9 and KYSE170 were exposed to distilled water, and morphological changes in ESCC cells were closely observed under a differential interference contrast microscope connected to a high-speed digital video camera. Further, serial cell volume changes after hypotonic shock were measured using a high-resolution flow cytometer. To investigate the cytocidal effects of hypotonic shock on ESCC cells, re-incubation of ESCC cells was performed after hypotonic shock. Additionally, the effects of 5-nitro-2-(3-phenylpropylamino)-benzoic acid (NPPB), a Cl<sup>-</sup> channel blocker, during hypotonic shock were analyzed.

**Results:** Video recordings by high-speed digital camera demonstrated hypotonic shock with distilled water induced cell swelling followed by cell rupture. Measurements of cell volume changes using a high-resolution flow cytometer indicated that severe hypotonicity with distilled water increased broken fragments of ESCC cells within 5 min. Re-incubation experiments demonstrated cytocidal effects of hypotonic shock on ESCC cells. Treatment of cells with NPPB increased cell volumes by the inhibition of regulatory volume decrease, which is observed during hypotonic shock, and enhanced cytocidal effects.

**Conclusion:** These findings demonstrated the cytocidal effects of hypotonic shock on ESCC cells, and clearly support the efficacy of pleural lavage with distilled water during surgery for ESCC.

**Abstract ID: 0457**                      Specific Field: **Esophagus**

**Mode of pres.: Free Paper**  
**ISW 2011 Session 22.08**

**Decrease in total lymphocyte count during neoadjuvant chemotherapy correlates with incidence of complication after esophagectomy for patients with node-positive esophageal cancer**

M. Watanabe, Y. Nagai, S. Iwagami, Y. Miyamoto, M. Iwatsuki, Y. Baba, N. Hayashi, H. Baba

Kumamoto University, Japan

**Introduction:** Although neoadjuvant chemotherapy (NAC) followed by esophagectomy has become one of the standard cares for advanced esophageal cancer in Japan, adverse effect of NAC on esophagectomy has not fully understood yet. Aim of this study is to clarify the features of postoperative complication and risk factors of the incidence in patients who underwent esophagectomy after NAC.

**Material and Methods:** From August 2008 to November 2010, 40 patients underwent esophagectomy after NAC with Docetaxel, Cisplatin and 5-FU (DCF). DCF consisted of 60 mg/m<sup>2</sup> of docetaxel on day 1, continuous infusion of 350 mg/m<sup>2</sup> of 5-FU and 6 mg/m<sup>2</sup> of cisplatin given intravenously on day 1–5. The regimen was given every 3 weeks and 2 scheduled courses has completed in all cases. The nutritional and immunologic parameters, including body weight (BW), serum total protein (TP), serum albumin (Alb) and total lymphocyte count (TLC) were evaluated before and after NAC. All patients underwent esophagectomy with lymph node dissection. Risk factors for postoperative complication were investigated with univariate and multivariate analysis.

**Results:** Postoperative complication was observed in 21 patients and the incidence was similar to that in patients who underwent esophagectomy without NAC. Among the postoperative events, more infectious complications were observed in patients after NAC than those without NAC. During NAC, significant decrease in TP and Alb was observed, although change in BW was not significant. Univariate analysis revealed that BW and body mass index (BMI) as pretreatment factors, changes in TLC as NAC-related factor were the significant factors which correlated with the incidence of complication. Operation time tended to be longer in patients with complication compared to those without. Multivariate analysis revealed that decrease in TLC during NAC, as well as high BMI, was the significant factor affecting the incidence of postoperative complication.

**Conclusion:** Decrease in nutritional parameters was observed after NAC, despite it did not affect the incidence of complication, while immunosuppression caused by chemotherapy correlated with the incidence. An adequate nutritional support during NAC may reduce the incidence of complication after esophagectomy.

**Abstract ID: 0458**

Specific Field: **Esophagus**

**Mode of pres.: Free Paper**  
**ISW 2011 Session 22.09**

**Clinical impact of serum p53 antibody titer in patients with esophageal carcinoma: systematic review of literature**

K. Kimura, H. Shimada, S. Yajima, Y. Nagashima, Y. Oshima, T. Nanami, A. Yamazaki, H. Kaneko

Department of Surgery, Toho University School of Medicine, Tokyo, Japan

**Introduction:** The p53 protein over-expression that usually results from genetic alterations induces serum antibodies against p53 in patients with esophageal carcinoma. The aim of this review was to evaluate the clinical impact of serum p53 antibodies for patients with esophageal carcinoma.

**Material and Methods:** A systematic literature search was performed in PubMed/MEDLINE using the keywords “esophageal cancer” and “serum p53 antibody” to search for relevant articles published by the end of December 2010. The clinical impact of selected articles was assessed to evaluate the following: (i) diagnostic impact, (ii) prediction of patients’ prognosis, and (iii) impact on patients’ monitoring.

**Results:** A total of 21 articles were selected, 13 articles were from Japan and 8 were from the other countries. Average positive rate was 32% (ranging from 22 to 60%) for s-p53 Abs before treatment. Serum titers were significantly reduced after treatment. High serum antibody titer was associated with advanced stage and poor prognosis. Some of early cancer, such as stage I tumors and T1 tumors occurred from Barrett’s esophagus, can be detected.

**Conclusion:** Serum p53 antibody was useful blood test to detect relatively early stage of esophageal carcinoma and was also identify high risk group for tumor recurrence and a poor prognosis in esophageal cancer patients.

**Abstract ID: 0459**

Specific Field: **Esophagus**

**Mode of pres.: Free Paper**  
**ISW 2011 Session 22.10**

**Expression level of hepatoma-derived growth factor is a novel prognostic factor for esophageal carcinoma**

S. Yamamoto [1], Y. Tomita [2], Y. Doki [3], H. Nakamura [4]

[1] Department of Surgery, Uppsala University Hospital, Uppsala, Sweden, [2] Department of Pathology, Osaka University Graduate School of Medicine, Suita, Osaka, Japan, [3] Department of Gastroenterological Surgery, Osaka University Graduate School of Medicine, Suita, Osaka, Japan, [4] Division of Hepatobiliary and Pancreatic Medicine, Department of Internal Medicine, Hyogo College of Medicine, Nishinomiya, Hyogo, Japan

**Introduction:** Esophageal carcinoma (EC) is a cancer with poor prognosis. Several clinicopathologic factors, such as tumor size and lymph node invasion, were reported to be the main factors for tumor recurrence and survival of patients with EC. The prognoses of patients are nonetheless unfavorable, even under conditions where the tumor sizes are small and lymph node invasion is unobserved at the microscopic level. Thus, new biological prognostic factors responsible for the recurrence of EC need to be investigated. Hepatoma-derived growth factor (HDGF) is thought to play an important role in the development and progression of carcinomas. In the present study, association of HDGF expression with recurrence and prognosis of EC was examined.

**Material and Methods:** HDGF expression in 111 patients with EC (101 men and 10 women) with ages ranging from 38 to 82 (median, 61) years was analyzed by immunohistochemistry. Samples in which >90% of tumor cells exhibited nuclear and cytoplasmic HDGF immunoreactivity at levels greater than or equal to what is observed in the endothelial cells were regarded as HDGF expression level 1, and others as HDGF expression level 0.

**Results:** Thirty-seven of 111 patients showed level 1 HDGF expression. There was no correlation between HDGF expression and other clinicopathologic factors. Patients with level 1 expression showed poorer disease-free and overall survival ( $P < 0.05$  for both) compared with those with level 0 expression. HDGF expression was an independent prognostic factor for patients with early (pT1-2) stage of the disease, but not for those with advanced (pT3-4) stage.

**Conclusion:** HDGF expression could be offered as a new prognostic marker for EC. The present study indicated that classification of patients according to conventional TNM staging and HDGF expression level provides a valuable tool for predicting tumor recurrence in and prognosis of patients with EC. This system may also provide a new way to explore effective treatment modalities for EC.



**Abstract ID: 0460**Specific Field: **Esophagus****Mode of pres.: Free Paper**  
**ISW 2011 Session 30.01****Newly developed thoracoscopic intrathoracic esophagogastric anastomosis using a circular stapler with trans-oral placement of the anvil**

H. Takeuchi, T. Oyama, Y. Kitagawa

Department of Surgery, Keio University School of Medicine, Tokyo, Japan

**Introduction:** Esophagogastric anastomosis in the cervical incision has been preferred for the reconstruction after thoracoscopic esophagectomy for patients with thoracic esophageal cancer in most institutions. However the intrathoracic esophagogastric anastomosis is thought to be more cosmetic and safer in terms of less frequent anastomotic leakage. Given these backgrounds, we recently developed a thoracoscopic intrathoracic esophagogastric anastomosis using a circular stapler with trans-oral placement of the anvil.

**Material and Methods:** The patients were placed in the left semi-prone position by this procedure. It was possible to perform thoracoscopic esophagectomy and intrathoracic esophagogastric anastomosis in the left lateral decubitus position or the prone position by rotating the operating table. The Orvil™, the oral-gastric tube with the attached anvil was passed transorally in the left lateral decubitus position. A small esophagotomy was performed to the edge of staple line of the esophageal stump. The oral-gastric tube was pulled through the esophagotomy by the surgical operator and withdrawn through a trocar until the anvil was positioned within the end of the esophageal stump. The shaft of a 25-mm circular stapler was inserted from the stump of the gastric conduit through a small thoracotomy (4 cm long), and the circular stapling was performed in standard manner completing the intrathoracic esophagogastric anastomosis in the prone position. The access opening on the stump of the gastric conduit was closed with the thoracoscopic linear stapler.

**Results:** To date we have performed the new anastomotic procedure for 23 patients with thoracic esophageal cancer. Our thoracoscopic intrathoracic esophagogastric anastomosis was feasible for all patients, and they were uneventful without any severe complications in the postoperative course, except for one patient who was suspicious of minor postoperative anastomotic leakage.

**Conclusion:** Our results suggest that the newly developed thoracoscopic intrathoracic esophagogastric anastomosis might be a promising procedure for the reconstruction after thoracoscopic esophagectomy.

**Abstract ID: 0461**Specific Field: **Esophagus****Mode of pres.: Free Paper**  
**ISW 2011 Session 30.02****Efficacy of laparoscopic gastric mobilization for esophagectomy: comparison with open thoracoabdominal approach**

H. Kitagawa [1], T. Namikawa [1], T. Akimori [2], J. Iwabu [1], M. Kobayashi [3], K. Hanazaki [1]

[1] Department of Surgery, Kochi Medical School, Kohasu-Okochi, Nankoku, Kochi, Japan, [2] Department of Surgery, Kochi Prefectural Hospital, Kochi, Sukumo-City, Kochi, Japan, [3] Department of Human Health and Medical Services, Kochi Medical School, Kohasu-Okochi, Nankoku, Kochi, Japan

**Introduction:** Esophagectomy for esophageal cancer using thoracoabdominal approach is associated with a high rate of morbidity and mortality. The aim of this study was to compare the surgical outcomes between laparoscopic gastric mobilization for esophagectomy (LGM) and open thoracoabdominal esophagectomy (OE).

**Material and Methods:** We retrospectively reviewed 75 patients who underwent esophagectomy using the thoracoabdominal approach in our institution between 1999 and 2009. Operation-related parameters, mortality, postoperative complications and length of surgical intensive care unit and hospital stay were evaluated in 40 patients with LGM and compared to 35 patients with OE.

**Results:** There was no significant difference in characteristics of both groups. Although the operation time was longer in LGM (560 vs. 518 min), the operative blood loss volume was smaller than OE (410 vs. 1045 ml). The incidence of postoperative infectious complication was lower in LGM (20.0 vs. 36.1%). Duration of postoperative hospital stay were significantly shorter in LGM than in OE (37 vs. 48 days,  $P = 0.018$ )

**Conclusion:** LGM for esophageal cancer is feasible and reduced the postoperative morbidity compared with OE, and shorten the duration of hospital stay.

**Abstract ID: 0462**Specific Field: **Esophagus****Mode of pres.: Free Paper**  
**ISW 2011 Session 30.03****The usefulness of triangulating stapling technique for cervical esophagogastric anastomosis after esophagectomy**

Y. Baba, M. Watanabe, K. Kosumi, Y. Nagai, S. Iwagami, M. Iwatsuki, H. Baba

Kumamoto University, Kumamoto, Japan

**Introduction:** Although the surgical technique of esophagectomy for esophageal cancer is developing rapidly, the leakage of cervical esophagogastric anastomosis (CEGA) is still a serious problem. Since November 2008, we have performed the triangulating stapling technique (TST) utilizing three linear staplers for CEGA. In this study, we retrospectively evaluated the safety and feasibility of TST for CEGA.

**Material and Methods:** This study included 124 patients who underwent transthoracic esophagectomy with lymph node dissection and reconstruction with a 3.5-cm wide gastric tube, for thoracic esophageal cancer between April 2008 and August 2010. We performed the TST for CEGA in 38 patients (TST group), hand-sewn anastomosis in 44 patients (HSA group) and functional anastomosis utilizing the circular stapler in 42 patients (CS group). In the TST group, CEGA was performed in an end-to-end fashion using three linear staplers.

**Results:** Anastomotic leakage occurred in 5 (13.1%) of 38 TST cases, in 11 (25.0%) of 44 HAS cases and in 8 (19.0%) of 42 CS cases. The frequency of anastomotic stenosis was significantly lower in TST group [5.3% (2/38)] than in HAS group [45.5% (20/44)] and CS group [33.3% (12/42)] ( $P < 0.01$ ). In additional analysis including only "leakage" cases, the time to oral intake was shorter in TST group ( $19.2 \pm 12.2$  days) than in HAS group ( $21.7 \pm 15.1$  days) and CS group ( $34.5 \pm 30.8$  days).

**Conclusion:** Cervical esophagogastric anastomosis using TST may reduce the frequency of anastomotic leakage and stenosis. This technique is a safe and reliable alternative for CEGA after esophagectomy.

**Abstract ID: 0463**Specific Field: **Esophagus****Mode of pres.: Free Paper**  
**ISW 2011 Session 30.04****Semi-mechanical esophagogastrostomy is more effective than hand-sewn or stapler in prevention of anastomotic stricture: a comparative clinical study**

K.N. Wang, Q.R. Xu, W.P. Wang, L.Q. Chen

West China Hospital, Sichuan University, Chengdu, China, People's Republic

**Introduction:** Successful anastomosis is essential in esophagogastrostomy. The application of stapler effectively reduces the leakage rate while the stricture formation has become more frequent. The aim of this study is to retrospectively review the effect of semi-mechanical esophagogastrostomy in prevention of anastomotic stricture with comparison with conventional hand-sewn or stapled esophagogastric anastomosis.

**Material and Methods:** Between October 2007 and October 2009, 340 patients with esophageal carcinoma underwent a curative esophagectomy. There were 288 men and 52 women, aged from 40 to 80 years (60.0 years on average). The esophageal reconstruction was completed in 171 patients with a semi-mechanical esophagogastrostomy (SM group), in 101 with conventional hand-sewn anastomosis (HS Group), and 68 with a circular stapler (CS Group). The results concerning operative morbidity and mortality, frequencies of anastomotic stricture and reflux at 3 months after the operation were compared among three groups. The anastomotic stricture was defined as anastomotic diameter  $\leq 0.8$  cm on esophageal barium swallowing study.

**Results:** Three groups of patients were comparable on clinical baseline characteristics. There was one operative death in HS group because of myocardial infarction. The operative complications were documented in 20 patients (7.5%), while there was no difference among 3 groups ( $\chi^2 = 5.201$ ,  $P = 0.071$ ). The follow-up rate was 94.4%. The anastomotic diameter was  $1.6 \pm 0.4$  cm in SM group,  $1.1 \pm 0.3$  cm in HS group, and  $1.0 \pm 0.4$  cm in CS group, respectively ( $\chi^2 = 98.921$ ,  $P < 0.001$ ). The anastomotic stricture rate was 3.0% (5/167) in SM group, 11.5% (11/96) in HS group, and 20.9% (14/67) in CS group, respectively ( $\chi^2 = 19.459$ ,  $P = 0.000$ ). The reflux score in SM group was lower than other 2 groups ( $\chi^2 = 7.054$ ,  $P = 0.029$ ).

**Conclusion:** The semi-mechanical esophagogastrostomy could decrease anastomotic stricture while not increasing gastroesophageal reflux. Further validation is warranted.

**Abstract ID: 0464**Specific Field: **Esophagus****Mode of pres.: Free Paper**  
**ISW 2011 Session 30.05****Intraoperative assessment of blood flow of the intestinal graft after resection of hypopharynx and cervical esophagus by ICG fluorescence angiography**

Y. Hiramatsu, K. Kamiya, S. Miyazaki, H. Kikuchi, M. Ohta, T. Sakaguchi, N. Unno, H. Konno

Hamamatsu University School of Medicine, Hamamatsu, Japan

**Introduction:** Graft of free jejunum or cecum is used as the first choice for the reconstruction after the resection of hypopharynx and cervical esophagus. Necrosis of intestinal graft due to anastomotic

vascular occlusion is one of the most serious complications. The conventional intraoperative evaluation of graft blood flow has been done by assessing the color and peristalsis of the graft or using the Doppler method. Recently, indocyanine green (ICG) fluorescence angiography (ICG-FA) has been developed and reported to be useful in the evaluation of blood flow in cases of coronary artery bypass grafting and liver transplantation. In our institute, ICG-FA has been applied to the evaluation of blood flow of free intestinal graft since 2007. In this study, we show our techniques and the usefulness of ICG-FA during operation.

**Material and Methods:** Between February 2007 and April 2010, 16 patients with hypopharyngeal carcinoma or cervical esophageal carcinoma underwent ICG-FA of free intestinal graft. Intestinal graft (free jejunum or ileocecum) was taken when finishing the cervical resection and lymphnode dissection. Using a magnifying glass or microscope, vascular anastomosis was done after the pharynx-graft anastomosis. ICG solution (1 mg/1 ml) was injected i.v. and the fluorescence in the transplanted bowel and reconstructed vessels was visualized using Photodynamic Eye (PDE; Hamamatsu Photonics, Hamamatsu, Japan). The blood flow of the graft was evaluated in real-time during operation.

**Results:** The patients consisted of 15 males and one female with median age of 66.5 years (range; 49–75 years). Fluorescence was observed in the order of reconstructed artery, transplanted bowel, and then reestablished veins. It was possible to evaluate the blood flow in both intestinal grafts and vessels. In 13 cases, fluorescence of the grafts was clearly visible in approximately 30 seconds after ICG injection and their blood flow was evaluated as good. In 3 cases for which reanastomosis of graft vessel was required due to vending of veins or obstruction of artery, fluorescence of the grafts was extremely weak or invisible and their blood flow was evaluated as poor.

**Conclusion:** ICG-FA is a useful and reliable assessment of blood flow of the intestinal graft and can be utilized for real-time evaluation during operation.

**Abstract ID: 0465**Specific Field: **Esophagus****Mode of pres.: Free Paper**  
**ISW 2011 Session 30.06****The results of video-assisted thoracoscopic surgery for esophageal cancer**

I. Ninomiya [1], I. Makino [1], T. Fujimura [1], S. Fushida [1], K. Oyama [2], J. Kinoshita [1], H. Osugi [3], T. Ohta [1]

[1] Gastroenterologic Surgery, Kanazawa University, Kanazawa, Japan, [2] Kanazawa University, Japan, [3] Department of Gastroenterological Surgery, Osaka City University, Osaka, Japan

**Introduction:** Video-assisted thoracoscopic surgery (VATS) is the minimally invasive procedure in thoracic surgery. We introduced this procedure to minimize the surgical insult in treating esophageal cancer. We demonstrate the surgical procedure of VATS and the results of our experience.

**Material and Methods:** Patient is situated in the left lateral position. Esophageal mobilization and mediastinal dissection was performed thoracoscopically. Especially, upper mediastinal lymph nodes including those around bilateral recurrent nerves were dissected completely with the identification and preservation of those nerves. Lymph node dissection was done to expose the membranous portion of trachea and bilateral main bronchus, aorta, left parietal pleura and pericardium in the middle and lower mediastinum.

**Results:** From January 2003 to November 2010, we tried to perform VATS in 105 esophageal cancer patients. Among 105 patients, we

experienced conversion to thoracotomy in 5 patients and non-curative operation in 6 patients. Therefore, we completed 94 curative VATS. The average operation time, total blood loss, duration of the thoracic procedure, and the amount of thoracic blood loss was  $613 \pm 111$  min,  $613 \pm 111$  g,  $293 \pm 83$  min, and  $243 \pm 170$  g, respectively. We experienced 19 (20.2%) pneumonia, 17 (18.0%) unilateral recurrent nerve palsy, 19 (20.2%) bilateral recurrent nerve palsy, 9 (9.5%) anastomotic leakage, and 7 (7.4%) chylothorax. Initial recurrence site was as follows: local, 3 (3.2%); lymph node, 13 (13.8%); hematological, 13 (13.8%); pleural or peritoneal dissemination, 3 (3.2%). The 5-year survival rate in each stage classified by Japanese classification of esophageal cancer was as follows: stage 0, 86.6%; stage I, 83.3%; stage II, 77.0%; stage III, 58.4%; stage IV, 0%.

**Conclusion:** Video-assisted thoracoscopic surgery is the safe and minimally invasive procedure with excellent loco-regional control in esophageal cancer treatment.

**Abstract ID: 0466**

Specific Field: **Esophagus**

**Mode of pres.: Free Paper**  
ISW 2011 Session 30.07

**Monitoring real-time esophagectomy outcomes using risk adjusted CUSUM analysis in ACS-NSQIP as compared to single center data**

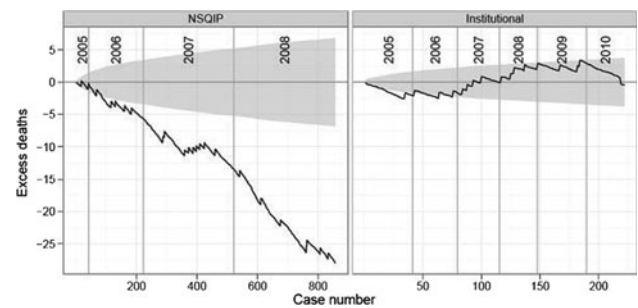
E.W. Gilbert, B.S. Diggs, J.P. Dolan, B.C. Sheppard, J.G. Hunter  
Oregon Health & Science University, Portland, USA

**Introduction:** Real-time quality assessment for high risk procedures in general surgery is evolving. The ability to follow risk-adjusted mortality as a performance measure and expeditiously identify deviations from an acceptable rate is of utmost importance. Our aim was to apply two risk-adjustment models to the ACS-NSQIP data in order to employ national standards as a comparison for our own institutional data.

**Material and Methods:** Using the 2005–2009 ACS-NSQIP Participant Use Data Files (ACS) and our 2005–2010 institutional Esophageal Cancer Research Database (ECRD) we identified 897 & 222 esophagectomies respectively. Two risk-adjustment models were used to predict mortality in each data set: POSSUM and O-POSSUM. Receiver operator curves (ROC) were created to assess the discriminatory power of each model. Risk-adjusted cumulative sum analysis (RA-CUSUM) tracked how observed deaths related to predicted mortality over time.

**Results:** The observed ACS 30-day mortality for esophagectomy was 3.54% whereas rates predicted by POSSUM AND O-POSSUM were 5.22 and 5.97%. The POSSUM and O-POSSUM models predicted a mortality rate of 5.86% and 7.39% in ECRD data in comparison to the observed 30-day mortality of 7.25%. The ability of O-POSSUM to discriminate between decedents and survivors as measured by the area under the ROC are 0.676 (ACS) and 0.581 (ERCD.) O-POSSUM showed no lack of fit against observed mortality in ERCD data ( $P = 0.338$ ) and a significant lack of fit in ACS data ( $P = 0.014$ ). RA-CUSUM curves for ACS and ECRD data using O-POSSUM are shown.

**Conclusion:** The POSSUM and O-POSSUM risk adjustment models similarly over predict mortality in ACS-NSQIP data. In our single institution data POSSUM under predicts mortality and only O-POSSUM accurately predicts mortality. Differences in RA-CUSUM curves between national ACS-NSQIP data and our single center data have led to a rigorous institutional review of esophagectomy outcomes by providing “real-time” quality assessment.



**Figure:** RA-CUSUM curves for ACS-NSQIP and ECRD data using O-POSSUM

**Abstract ID: 0467**

Specific Field: **Esophagus**

**Mode of pres.: Free Paper**  
ISW 2011 Session 30.08

**Short-term outcomes following robot-assisted thoracoscopic lymphadenectomy for esophageal cancer in the prone position**

K. Suda, Y. Ishida, K. Inaba, K. Taniguchi, J. Isogaki, S. Sato, S. Kanaya, I. Uyama

Fujita Health University, Toyoake, Japan

**Introduction:** Minimally invasive lymphadenectomy for esophageal cancer with thoracoscopic approach, which is technically demanding, has been shown to induce less surgical stress than conventional open procedure, leading to reduced blood loss and shorter ICU and hospital stay. Prone position has also been demonstrated to facilitate mediastinal dissection and minimize lung injury. Therefore, robot-assistance in the prone position may aid in the performance of thoracoscopic extended mediastinal lymphadenectomy; however, potential advantages of the robotic system have yet to be clarified. The objective of this study is to determine whether robot-assistance is feasible for thoracoscopic lymphadenectomy in the prone position.

**Material and Methods:** This study investigated 15 consecutive patients with esophageal cancer who underwent robot-assisted thoracoscopic lymphadenectomy using the Da Vinci S HD™ surgical system between May 2009 and July 2010.

**Results:** All patients were diagnosed with squamous cell carcinoma. R0 resection was achieved in a total of 13 patients (87%) and the number of retrieved mediastinal lymph nodes was  $22 \pm 9$ . The operating time for the thoracoscopic phase (robot console time) was  $318 \pm 62$  min, and the blood loss was  $250 \pm 267$  ml. Length of hospital stay was  $30 \pm 16$  days. Pulmonary complication and transient recurrent laryngeal nerve palsy occurred in 1 (8%) and 5 patients (38%), respectively. No patient died within 30 days following the operation.

**Conclusion:** Robot-assisted thoracoscopic lymphadenectomy in the prone position was found to be oncologically and technically feasible. We need to gain more experience and optimize the process to improve these outcomes.

**Abstract ID: 0468**

Specific Field: **Esophagus**

**Mode of pres.: Free Paper**  
ISW 2011 Session 30.09

**Study on the clinicopathological significance of the preoperative neutrophil–lymphocyte ratio in patients who underwent curative resection for esophageal cancer**

H. Funaki, M. Yokoi, S. Kinami, K. Omote, N. Ueda, Y. Nakano, T. Kosaka

Kanazawa Medical University, Uchinada, Ishikawa, Japan

**Introduction:** The neutrophil–lymphocyte ratio (NLR) reflects the inflammatory status of patients. The preoperative NLR also reflects the clinical stage and survival in patients with some malignant tumors. The purpose of this study was to evaluate the clinicopathological correlations with the preoperative NLR in patients who underwent curative resection for esophageal cancer.

**Material and Methods:** This study included 32 men and 8 women, with a median age of 67 years, who underwent curative resection for esophageal cancer. The preoperative NLR and clinicopathological parameters were assessed with Mann–Whitney *U* test. Survival curves were obtained using the Kaplan–Meier method and compared by the log-rank test. Differences with  $P < 0.05$  were considered statistically significant.

**Results:** The median NLR was 2.4. No correlations were found between NLR and clinicopathological factors such as gender ( $P = 0.81$ ), age ( $P = 0.32$ ), depth of tumor ( $P = 0.27$ ), lymph node metastasis ( $P = 0.65$ ), degree of histological differentiation ( $P = 0.18$ ), lymphatic invasion ( $P = 0.57$ ), or venous invasion ( $P = 0.21$ ). The survival of patients with a high NLR (3 or more) was worse than that of low NLR, but not statistically significant ( $P = 0.25$ ). As the fStage increased, the NLR increased as follows: fStage 0, NLR 1.6; fStage I, 1.8; fStage II, 3.5; fStage III, 3.6; and fStage IV, 3.9.

**Conclusion:** The preoperative NLR may be a convenient biomarker that reflects the final stage in patients who underwent curative resection for esophageal cancer.

**Abstract ID: 0469**

Specific Field: **Esophagus**

**Mode of pres.: Free Paper**  
**ISW 2011 Session 30.10**

**Clinicopathological predictive factors for early recurrence in patients with esophageal cancer after curative esophagectomy**

H. Shimizu, H. Fujiwara, A. Shiozaki, S. Komatsu, D. Ichikawa, K. Okamoto, T. Ochiai, E. Otsuji

Division of digestive surgery, Kyoto prefectural University of Medicine, Kyoto, Japan

**Introduction:** Even with combined modality treatment by chemotherapy and radiation after curative resection, esophageal cancer has been remained a poor prognostic disease with early recurrence. This study retrospectively evaluated the clinicopathological predictive factors for early recurrence in patients with curative resected esophageal cancer.

**Material and Methods:** Seventy nine consecutive patients with recurrence after curative esophagectomy, from January in 1998 and March in 2010, were analyzed. The patients were classified into two subgroups by recurrent time (in 180 days or later from surgery); early recurrence group and late recurrence group.

**Results:** Twenty seven (34.2%) patients were classified in the early recurrence group, and 52 (65.8%) patients in the late recurrence group. The recurrence-free survival time (mean  $\pm$  SD) of two groups were  $111 \pm 47$  days and  $534 \pm 514$  days, respectively. In clinicopathological factors, there were no significant differences in age, gender, tumor location, tumor macroscopic type, tumor size, histology, grade of lymphatic-venous invasion and presence of

preoperative therapy between two groups. However, patients in the early recurrence group were more likely to have deeper ( $P = 0.013$ ) tumors with lymph node ( $P = 0.047$ ) and intramural metastasis ( $P = 0.043$ ) in advanced stage ( $P = 0.031$ ) than those in the late recurrence group. Concerning the recurrent patterns of two groups, lymph node and hematogenous metastasis were found with equal frequency (52%) in the early recurrence group and on the other hand, lymph node metastasis was more frequent than hematogenous metastasis (73% and 40%, respectively) in the late recurrence group. The 1-year survival time after recurrence of early and late recurrence groups were 19.8% and 65.1%, respectively ( $P = 0.0006$ ). The logistic regression analysis revealed that the depth of tumor invasion was the independent predictive factor for early recurrence in esophageal cancer.

**Conclusion:** The depth of tumor invasion was the predictive factor for early recurrence in patients with curative resected esophageal cancer.

**Abstract ID: 0470**

Specific Field: **Esophagus**

**Mode of pres.: Video**  
**ISW 2011 Session 32.01**

**Laparoscopic calibrated fundoplication and acid suppression/duodenal diversion procedure for non obese or obese type I patients with long segment Barrett's esophagus**

I. Braghetto, O. Korn, H. Valladares, L. Gutierrez, L. Brunet

University of Chile, Santiago, Chile

**Introduction:** Laparoscopic antireflux surgery is very successful in patients with short-segment Barretts esophagus, but in patients with long-segment Barretts esophagus the results remain in discussion. In these patients, during the open era surgery, we have performed acid suppression + duodenal diversion procedure added to the antireflux procedure (fundoplication + vagotomy + antrectomy + Roux-en-Y gastro-jejunostomy), in order to obtain better results at long term follow-up. In obese patients with morbid obesity, gastric bypass has been suggested as very successful procedure controlling both obesity and reflux disease. For non obese or type I obese patients we must offer a surgical procedure with these 2 purposes: controlling acid and bile reflux and decrease adequately their overweight if they need it.

**Material and Methods:** We present our laparoscopic technique and results performed in 40 non obese or obese type I patients with LSBE with BMI between 25 and 35 kg/m<sup>2</sup> who were submitted to fundoplication or acid suppression duodenal diversion technique, (Calibrated fundoplication + Antrectomy + Roux en-Y-Gastrojejunostomy), performed by laparoscopic approach.

**Results:** Patients with long segment BE, submitted to acid suppression-duodenal diversion surgery, presented successful results regarding to recurrent symptoms and endoscopic improvement of esophagitis in more than 95% of cases. Regression of intestinal metaplasia to cardiac mucosa "was observed in 61% of patients. In non obese patients BMI decrease from  $28.2 \pm 2.7$  to  $24.8 \pm 1.7$  and in type I obese patients BMI decreased from  $33.2 \pm 2.9$  to  $26.0 \pm 1.7$  kg/m<sup>2</sup>.

**Conclusion:** In non morbid obese patients with LSBE we suggest to perform fundoplication plus acid suppression/duodenal diversion procedure due to very successful long term results regarding to GERD and obesity control, obtaining regression of intestinal metaplasia in 60% of the patients.



**Abstract ID: 0471**Specific Field: **Esophagus****Mode of pres.: Video**  
**ISW 2011 Session 32.03****Thoroscopic radical esophagectomy for cancer: according to microanatomy**

H. Osugi, S. Lee, S. Kishida

Osaka City University Graduate School of Medicine, Osaka, Japan

**Introduction:** Since 1996, Video-assisted thoroscopic esophagectomy (VATS), according the same surgical principles as the Japanese open surgery, has been completed in 360 patients with esophageal cancer, aiming at reducing the extensive invasiveness.

**Material and Methods:** Our indication for VATS is (1) no extensive pleural adhesion, (2) no contiguous tumor spread, (3) pulmonary function capable of sustaining single-lung ventilation, and (4) anti-cancer-treatment-naïve patients. We use 4 ports around a 5 cm mini-thoracotomy on 5th intercostals space. We laid emphasis on utilizing magnifying effect of video, obtained by positioning the camera at close vicinity to the dissection.

**Results:** Surgery related hospital death was two (0.8%). The number of retrieved nodes, blood loss, duration of procedure, and morbidity were 34.4 nodes, 190 g, 186 min, and 32%, respectively, which were not different from those of open surgery. However, examining our learning curve in VATS, the most remarkable difference was found between first 36 cases and the later. The learning reduced blood loss and duration of procedure significantly from 412 g and 270 min to 149 g and 183 min. The learning reduced the incidence of pulmonary complications from 28 to 5%. Multivariate analysis demonstrated that only surgical experienced predicted the risk of pulmonary complications. The reduction of vital capacity was 15% after VATS, which was significantly less than 22% after open surgery. The 5-year survival rates of the VATS patients with pT1-2, pT3 lesion and pN0, pN1 were 69, 60, and 84, 44%, respectively, which were not different from open surgery patients.

**Conclusion:** VATS can be performed with safety and efficacy comparable to those of open surgery. Morbidity decreases with the surgeon's experience. After learning, higher quality of lymph node dissection can be performed through VATS, under magnified view, than open surgery. Our technique of VATS with demonstrating the microanatomy will be presented with video.

**Abstract ID: 0472**Specific Field: **Esophagus****Mode of pres.: Free Paper**  
**ISW 2011 Session 83.01****Reflux disease in patients after surgery for esophageal cancer**

T. Nomura, M. Miyashita, H. Makino, N. Hagiwara, S. Kato, I. Fujita, I. Akagi, E. Uchida

Nippon Medical School, Tokyo, Japan

**Introduction:** Patients who have undergone surgery for esophageal cancer and whose reconstructions were performed using a gastric conduit (GC) sometimes complain of reflux symptoms. Furthermore, routine endoscopic examinations sometimes reveal the reflux esophagitis (RE) around the anastomosis site. We examined the factors that influence endoscopic RE after surgery for esophageal cancer.

**Material and Methods:** The subjects were 24 patients (17 men, 7 women; mean age, 67.6 years) who underwent a right thoracic esophagectomy and GC reconstruction. The patients' performance statuses were good, and the follow-up period was more than 12 months for all the patients. All the patients had been treated with proton pump inhibitors (PPIs) and had been followed up as outpatients regardless of their symptoms. We examined the influences of the following factors on the presence of endoscopic RE: sex, age, reconstruction route, anastomosis site, length of time since operation, neoadjuvant chemoradiotherapy (CRT), presence of residual foods in the GC, and severity of symptoms.

**Results:** Endoscopic examinations revealed RE in 8 of 24 patients. No significant differences in age, length of time since operation, anastomosis site, or CRT were observed between the RE(+) group ( $n = 8$ ) and the RE(-) group ( $n = 16$ ). Severe reflux symptoms were reported in the RE(+) group ( $P = 0.01$ ), and more residual food was observed in the GC in the RE(+) group ( $P = 0.002$ ). On the other hand, 6 of the 16 cases in the RE(-) group complained of reflux symptoms. Among these 6 cases, the anastomosis had been performed in the neck region in 5 cases ( $P = 0.048$ ), and the symptoms of these patients tended to be "regurgitation," rather than "heartburn." In 6 of the 8 RE(+) cases, residual food was observed in the GC. Among these 6 cases, the anastomosis had been performed in the chest cavity in 5 cases ( $P = 0.013$ ), and the symptoms of these patients were very severe.

**Conclusion:** While the anastomosis site did not influence the occurrence of endoscopic RE, it did influence the character and degree of reflux symptoms, suggesting that the anastomosis site has a very important effect on patients' symptoms. The presence of residual foods in the GC may reflect the clearance of food through the GC. Accordingly, the observation of food within the GC during an endoscopy examination may suggest the occurrence of reflux into the residual esophagus.

**Abstract ID: 0473**Specific Field: **Esophagus****Mode of pres.: Free Paper**  
**ISW 2011 Session 83.02****Laparoscopic antireflux surgery prevents aspiration of pepsin after lung transplantation**

C. Weber [1], C.S. Davis [2], P.W. Lundberg [2], L. Ramirez [2], J. Gagermeier [2], E.J. Kovacs [1], R. Love [1], P.M. Fischella [2]

[1] Loyola University Medical Center, USA, [2] Loyola University Medical Center, Maywood, IL, USA

**Introduction:** The purpose of this study is to determine, in lung transplant patients, if laparoscopic antireflux surgery (LARS) is an effective means to prevent aspiration as defined by the presence of pepsin in the bronchoalveolar lavage (BAL).

**Material and Methods:** Between September 2009 and June 2010, we collected BAL fluid from 37 lung transplant patients at the time of routine surveillance for rejection, or when clinically indicated by diminished pulmonary function (sustained drop of FEV1 >10% of baseline for 1 week). The BAL fluid was tested for pepsin by enzyme-linked immunosorbent assay (ELISA). Pepsin was also tested by ELISA in the BAL fluid of 11 healthy volunteers (control group). Of the 37 lung transplant patients, 25 underwent ambulatory pH-monitoring and 12 underwent LARS for gastroesophageal reflux disease (GERD). We then compared the pepsin levels in the BAL of those with GERD ( $n = 15$ ), those without GERD ( $n = 10$ ), controls ( $n = 11$ ), and those who underwent LARS ( $n = 12$ ).

**Results:** Our results show that lung transplant patients with GERD had significantly more pepsin in their BAL fluid than lung transplant patients who underwent LARS ( $P = 0.038$ ), and that pepsin was undetectable in the BAL fluid of controls (Fig. 1).

**Conclusion:** To our knowledge this is the only that has compared pepsin in the BAL fluid from lung transplant patients with and without LARS. Our data show that: (1) the detection of pepsin in the BAL fluid proves aspiration, as it is not present in healthy volunteers, and (2) that LARS appears effective as a measure to prevent the aspiration of gastroesophageal refluxate in the lung transplant population. We believe that these findings provide a mechanism for those studies that suggest that LARS may prevent nonallogenic injury to the transplanted lungs from aspiration of gastroesophageal refluxate.

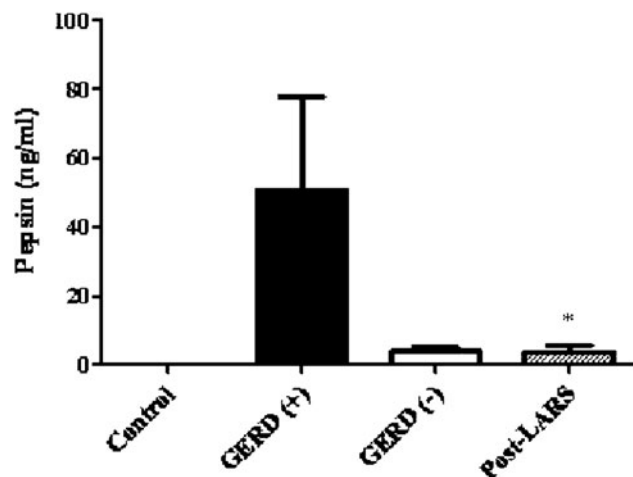


Figure 1. Pepsin concentrations in the BAL fluid of lung transplant recipients and controls  
\*  $p=0.038$  vs GERD (+) by one-way t-test.

Abstract ID: 0474

Specific Field: Esophagus

Mode of pres.: Free Paper  
ISW 2011 Session 83.03

**Persistent dual high pressure zone, oesophageal body hypomotility and abnormal response to multiple rapid swallows are associated with reflux symptoms after fundoplication**

R. Shimono, E. Yazaki, J. Jafari, P. Woodland, A. Fikree, J. Hayat, I. Bravi, D. Sifrim

Barts and the London School of Medicine and Dentistry, Queen Mary University of London, London, United Kingdom

**Introduction:** Persistent reflux symptoms occur in a subgroup of patients following anti-reflux surgery. These symptoms can be due failure of the antireflux barrier. GI physiology studies are performed to evaluate the OGJ function and anatomy in these patients. Recent studies with high resolution manometry (HRM) have shown the presence of a dual high pressure zone (HPZ) at the OGJ as an expression of persistent hiatus hernia. However, the relation between dual high pressure zone, oesophageal hypomotility and persistent symptoms is unclear. The aim of this study was to evaluate reflux

parameters and oesophageal motility patterns with HRM in a group of symptomatic patients after fundoplication.

**Material and Methods:** Ten patients (5 male, 5 female; mean age 55 year) were selected based on the presence of persistent typical reflux symptoms post-Nissen fundoplication. The patients underwent HRM and impedance-pH monitoring “off” PPI. The existence of dual HPZ, oesophageal hypomotility and amplitude of the after-contraction post multiple rapid swallowing (MRS) were evaluated together with acid and non acid reflux parameters. Increased number of reflux events (post Nissen) was considered if  $>30/24$  h (Bredenoord et al. 2008).

**Results:** Six out of 10 patients had a dual HPZ on HRM. Acid exposure time and number of acid reflux events in these patients was significantly higher than those with a single HPZ (12.7 vs. 0.5%,  $P = 0.01$ ). The patients with a dual HPZ more commonly exhibited oesophageal hypomotility and poor response to MRS compared to the patients with a single HPZ (4/6 vs. 1/4). In addition more of the patients with a dual HPZ showed impaired acid reflux clearance compared to patients with single HPZ (5/5 vs. 1/3).

**Conclusion:** HRM and impedance-pH measurement allows a precise assessment of patients with symptoms post-fundoplication. Our study suggests that the presence of a dual HPZ on oesophageal HRM is associated with impairment of oesophageal motility and impaired oesophageal acid clearance, and hence may be important in the persistence of GORD symptoms post-operatively.

Abstract ID: 0475

Specific Field: Esophagus

Mode of pres.: Free Paper  
ISW 2011 Session 83.04

**Management options in pharyngeal corrosive strictures**

V. Velayutham, J. Sathyanesan, J. Damodaran, A. Pichaimuthu, S. Perumal, R. Palaniappan, S. Rajagopal

Govt Stanley Medical College Hospital, Chennai, India

**Introduction:** Corrosive injuries of the upper aero-digestive tract are a major issue in India. Pharyngo-oesophageal corrosive stricture occurs either in isolation or in combination with strictures of the esophagus and stomach. A stricture at the pharyngo-oesophageal junction requires a specialized management approach. The objective of the study was to analyze the management options of pharyngo-oesophageal corrosive strictures.

**Material and Methods:** A retrospective analysis of 108 cases of pharyngo-oesophageal corrosive strictures identified between June 1997 and May 2010 was done. The demographic details were analyzed. The details of the injury to the pharynx either in isolation or in combination were noted and the management details recorded.

**Results:** Of the 108 patients who had pharynx and/or pharynx and esophageal involvement there were 37 men and 71 women. The mean age was 28 years. Strong acid was the most common corrosive ingested (95/108 patients). The intent was suicidal in 98 and was accidental in 10. Out of 108 patients, antegrade dilatation was successful in 45. Retrograde dilatation attempted in 30 patients the technique was successful in 18 patients. Transhiatal resection and gastric pull-through was resorted to in seven patients and retrosternal pharyngocoloplasty was done in 38 of which 7 cases developed postoperative complications.

**Conclusion:** For treatment of pharyngo-oesophageal obstruction, if antegrade dilatation is not possible due to technical reasons,

retrograde dilatation is a viable option before going in for organ replacement/bypass procedures. Surgical treatment is a good option in patients with severe strictures, and colonic interposition might be the best surgical process. Treatment should be individualized to patient needs.

**Abstract ID: 0476**

Specific Field: **Esophagus**

**Mode of pres.: Free Paper**  
**ISW 2011 Session 83.05**

**Long-term patient reported outcomes of oesophageal cardiomyotomy with anterior fundoplication in patients with achalasia of the cardia**

L. Koval, D.C. Gotley, J. Shenfine

Rockhampton Base Hospital, Rockhampton, Australia

**Introduction:** Achalasia is an idiopathic primary motility disorder characterized by impaired relaxation of the lower oesophageal sphincter (LOS) and aperistalsis of distal oesophagus. Oesophageal cardiomyotomy is increasingly performed to palliate the symptoms of this rare disorder. The aim of this study was to assess long-term patient reported outcomes following laparoscopic oesophageal myotomy with anterior fundoplication.

**Material and Methods:** All patients with manometrically proven achalasia who underwent surgery between September 2001–August 2007 in a single specialist centre: The Upper Gastrointestinal Unit, Princess Alexandra Hospital, Brisbane, Australia, were included in this retrospective analysis. Post-operative outcomes were evaluated using a patient completed questionnaire; incorporating symptom indices, patient satisfaction and post-operative side-effects.

**Results:** A total of 115 consecutive patients with a median age of 46 years (range 17–86) underwent laparoscopic myotomy during the study period. Prior to presentation, 14% of the patients had undergone Botox treatment and 70% had undergone oesophageal dilatations. The median follow up was 5.5 years (range 1–10). There were no intra-operative complications or conversions to open surgery. The median dysphagia score fell significantly 1 year following surgery ( $P < 0.001$ ) with 83 of 90 patients (92%) reporting an improvement in swallowing. This effect was maintained at all follow up assessments. The median heartburn score also fell significantly by the one year assessment ( $P < 0.001$ ) but by the 5 year assessment was no longer significantly different to the pre-operative value ( $P = 0.10$ ). The satisfaction rate was 95%. Most commonly reported sequelae were early satiety (52%), increased wind (26%), and bloating (19%) and difficulty belching (15%).

**Conclusion:** Oesophageal myotomy with anterior fundoplication is effective and safe procedure with a low incidence of troublesome side effects and high degree of patient satisfaction (Figure).

**Figure** Median DeMeester scores with time

	Pre-op (n = 115)	1 year (n = 90)	3 years (n = 58)	5 years (n = 32)
Dysphagia	3	1	1	1
Heartburn	1	0	0	1
Regurgitation	2	0	0	0

**Abstract ID: 0477**

Specific Field: **Esophagus**

**Mode of pres.: Free Paper**  
**ISW 2011 Session 83.06**

**Hiatal hernias: pathophysiologic theories and implication for research**

C. Weber, V. Shankaran, C. Davis, P.M. Fisichella

Loyola University Medical Center, Maywood, IL, USA

**Introduction:** Though diaphragmatic hernias have been recognized for centuries, their pathophysiology is still widely debated. The purpose of this study is to review the current literature regarding the pathophysiology of hiatal hernia development and outline implications for research in this field.

**Material and Methods:** We performed a systematic search of the Medline database to identify studies relating to hiatal hernias. The searches were restricted to English language citations from the database's inception to September 2010. Search terms included, "hiatal hernia", "diaphragmatic hernia", "hernia pathophysiology", and "molecular basis for hernia". Relevant papers from selected articles' reference lists were also identified and used in this review. Case reports, editorials, and pediatric studies (patients <18 years of age) were excluded.

**Results:** There appears to be three predominant theories regarding the pathogenesis of hiatal hernia: (1) increased intra-abdominal pressure forces the GEJ upwards into the thorax; (2) esophageal shortening displaces the GEJ superiorly into the thorax; and (3) widening of the diaphragmatic hiatus in response to congenital or acquired molecular and cellular changes in crural muscles or the connective tissue of the diaphragm facilitates the migration of the GEJ into the thoracic cavity. Unfortunately, evidence for these theories is hindered by deficient objectivity, inconsistency between reports, and overall lack of data. Presently, the strongest evidence for hiatal hernia formation is supported by few small studies reporting on structural changes in crural muscle or connective tissues that involve elastin, collagen, and matrix metalloproteinases.

**Conclusion:** Despite its recognition centuries ago, the pathogenesis of hiatal hernias is under-researched and poorly described. To date, no single theory proves to be the definitive cause of hiatal hernia formation, and its pathogenesis appears multifactorial. Only a handful of studies have examined the relationship between molecular and cellular changes in crural muscles or the connective tissue of the diaphragm and the pathogenesis of hiatal hernias. Based on limited evidence, further investigation into the pathogenesis of hiatal hernias is needed to identify those at risk to develop this condition, to guide its prevention, and solidify a treatment paradigm such to minimize its recurrence.

**Abstract ID: 0478**

Specific Field: **Esophagus**

**Mode of pres.: Free Paper**  
**ISW 2011 Session 83.07**

**Creation of percutaneous transesophageal gastro-tubing (PTEG) followed by insertion of the ileus tube simultaneously**

E. Bekku, T. Aramaki, M. Moriguchi, M. Endo

Shizuoka Cancer Center, Shizuoka, Japan

**Introduction:** Percutaneous transesophageal gastro-tubing (PTEG) was developed in Japan as an alternative route for gastrointestinal tract. This procedure is often performed in the case that the PEG or

jejunostomy is difficult to create because of their massive ascites, hostile abdomen, altered gastric anatomy, and so on. In this study, we evaluated the feasibility of creation of PTEG followed by insertion of the long tube (ileus tube) through the PTEG tract simultaneously.

**Material and Methods:** Between Sep.2002 and Dec.2010, we performed 136 cases of PTEG including 13 cases planned on inserting ileus tube simultaneously for gastrointestinal decompression. We evaluate the technical success rate, complications, and time of proceeding of simultaneous placement of ileus tube. The procedure was performed as follows: (1) Insert the Rupture free balloon (RFB) via nose and inflate at cervical esophagus, (2) Puncture the RFB percutaneously under ultrasonographic vision, (3) Insert a guidewire into the RFB and dilate the percutaneous rout, (4) Insert the tube into the dilated gastrointestinal loop.

**Results:** We performed 13 cases of PTEG followed by insertion of the ileus tube through the PTEG tract simultaneously. The rate of technical success of PTEG creation and insertion the ileus tube to dilated gastrointestinal loop is 100% (13/13 cases) and 84.6% (11/13 cases), respectively and no major complication was observed. The average time of procedure was 63.8 min and the median survival time after PTEG placement was 96 days.

**Conclusion:** Creation of PTEG followed by insertion of the ileus tube through the PTEG tract simultaneously is a safe and feasible method for gastrointestinal decompression.

**Abstract ID: 0479**

Specific Field: **Esophagus**

**Mode of pres.: Free Paper**  
**ISW 2011 Session 83.08**

**Lymph node dissection along the left recurrent nerve for esophageal cancer through thoracoscopic approach in prone position**

J. Isogaki, K. Inaba, Y. Ishida, K. Taniguchi, S. Sato, S. Kanaya, I. Uyama

Fujita Health University, Dengakugakubo, Kutsukake, Toyoake, Aichi, Japan

**Introduction:** Thoracoscopic esophagectomy for esophageal cancer has some benefits such as decreasing morbidity rate and shortening the hospital stay. On the other hand, technical difficulty of this operation seems to counteract its communization. One of the reasons of the difficulty is its limited view of the operative field. Recently new scheme about thoracoscopic esophagectomy in prone position is reported from some institute. Prone position provides better operative field compare to the left lateral position. The manipulation in deep mediastinal space such as the lymph node dissection along whit the left recurrent laryngeal nerve (station no. 106recL) is the one of the most difficult part in thoracoscopic esophagectomy. With the help of good vision by the prone position, we perform autonomic nerve preserving procedure in station no. 106recL lymph node dissection. We here present our procedure.

**Material and Methods:** From November 2006, we started thoracoscopic esophagectomy in prone position. When operator approaches to left upper mediastinal area, the assistant “rolls” the membranous wall of trachea to right side. The adipose tissue on the left side of the trachea is separated from the trachea and elevated to the dorsal side. This adipose tissue contains the left recurrent laryngeal nerve and station no. 106recL lymph nodes. Then the left recurrent nerve is isolated from the adipose tissue and dissected. By this manipulation, the vascular sheath covering the aortic arch is not injured and the autonomic nerves around the aortic arch (cardiac branches of the sympathetic nerve) are preserved.

**Results:** We started this procedure from October 2008 and in almost all cases the sympathetic nerves around the aortic arch are preserved.

**Conclusion:** Previously we approach to the station no. 106recL lymph nodes from dorsal side to anterior side without elevating the adipose tissue containing the lymph nodes and recurrent nerve. In this manner, the border of the adipose tissue and vascular sheath is difficult to recognize and the sympathetic nerve may lead to be damaged. Our current procedure for dissecting the station no. 106recL may be useful for preserving the sympathetic nerve around the aortic arch.

**Abstract ID: 0480**

Specific Field: **Esophagus**

**Mode of pres.: Free Paper**  
**ISW 2011 Session 83.09**

**Thoracoscopic esophagectomy in a prone position for esophageal cancer using a preceding anterior approach**

S. Ozawa, O. Chino, S. Yamamoto, M. Nakui, A. Kazuno, H. Shimada, H. Makuuchi

Tokai University School of Medicine, Isehara, Japan

**Introduction:** The rate of thoracoscopic esophagectomy for the treatment of esophageal cancer was about 20% according to the annual report made by the Japanese Association for Thoracic Surgery in 2008. This low rate may be due to the difficulty in both maintaining a good surgical field and the meticulous procedures. Here, we present our procedure for performing thoracoscopic esophagectomy in a prone position using a preceding anterior approach to make the esophagectomy easier.

**Material and Methods:** We have performed thoracoscopic esophagectomy in a prone position for 26 patients with esophageal cancer between September 2009 and December 2010. The indications for this operation were cases without severe pleural adhesion, cases with T1b to T3 cancer, and cases without preoperative chemoradiotherapy. Patients were placed in a prone position, 5 trocars were inserted into the right thoracic cavity, only the left lung was ventilated, and pneumothorax was maintained with 6 mmHg of CO<sub>2</sub> gas. The anterior pleura of the upper posterior mediastinum was incised between the esophagus and the trachea. The lymph nodes around the right recurrent laryngeal nerve and the upper esophagus were dissected. The esophagus was mobilized from the trachea in the first step and from the posterior structure in the second step. In the same manner as for the upper esophagus, the middle and lower esophagus was also mobilized; the lymph nodes around the esophagus were then dissected anteriorly in the first step and posteriorly in the second step. After the esophagus was transected, the lymph nodes around the left recurrent laryngeal nerve were dissected.

**Results:** The median operation time for the thoracoscopic procedure was 260 min, and the median blood loss was 27 g. No intraoperative incidents occurred. There were no operative deaths in this series. As postoperative complications, pneumonia occurred in 4 cases (15%), and recurrent laryngeal nerve palsy occurred in 4 cases (15%).

**Conclusion:** A thoracoscopic esophagectomy in a prone position for esophageal cancer using a preceding anterior approach is a safe and feasible procedure. The advantages of this method were that the mediastinal organs shifted downwards as a result of gravity and that the surgical fields of the posterior mediastinum eventually became wide open. This method, performed while the patient is in a prone position, seems to make the esophagectomy easier to perform.



**Abstract ID: 0481**Specific Field: **Esophagus****Mode of pres.: Prize Session FP  
ISW 2011 Session 105.01****Comparative study of different methods of laparoscopic repair of large hiatal hernias**V.V. Grubnik, A.V. Malynovskyy, V.V. Ilyashenko, O.V. Grubnik  
Odessa National Medical University, Odessa, Ukraine

**Introduction:** The use of mesh for laparoscopic repair of large hiatal hernias may reduce recurrence rates compared to primary suture repair. However, there is a potential risk of mesh-related oesophageal complications due to prosthetic erosion. The aim of this study was to compare effectiveness of different methods of crural closure.

**Material and Methods:** Prospective randomized study included a total of 286 operations in patients with large hernias. I group included 139 patients with polypropylene mesh reinforcement of crural repair, II group included 147 patients with original method of repair: first step was fixation of composite mesh to crura, the second step was suturing the crura over the mesh. Mean age was 62,5 years (range 38–79 years). Quality of life and symptoms analysis was performed using a quality of life in reflux and dyspepsia (QOLRAD) questionnaire preoperatively and 3 months, 6 months, 1 year, and 3 years postoperatively. Barium studies were performed preoperatively and 2 years postoperatively to assess hernia recurrence. After 1–3 years, endoscopy was performed to assess signs of oesophagitis. The mean follow-up was term was 32.6 months.

**Results:** 3 years postoperatively, there was significant improvement in QOLRAD score in the both groups. But, results in the group II were better than in group I (5.13 vs. 5.75,  $P < 0.05$ ). Barium studies showed recurrent hernia in 6% of patients from group I, and in 4,5% of patients from group II ( $P > 0.1$ ). Endoscopy showed signs of prosthetic erosion in 4 patients from group I, and no signs of prosthetic erosion in group II. Dysphagia score was 38.2 in group I and 35.6 in group III.

**Conclusion:** The use of mesh can improve results of laparoscopic repair in of large hiatal hernias. Best results were obtained using new method of composite mesh repair. Polypropylene mesh can cause oesophageal complications due to prosthetic erosions.

**Abstract ID: 0482**Specific Field: **Esophagus****Mode of pres.: Poster Discussion  
ISW 2011 Session PW 12.01****Transhiatal migration of the stomach following laparoscopic Heller myotomy and Dor fundoplication for achalasia**T. Shibata, N. Katada, M. Nemoto, H. Mieno, K. Yamashita,  
S. Sakuramoto, S. Kikuchi, M. Watanabe

Kitasato University, Sagamihara, Japan

**Introduction:** We report a rare case with transhiatal migration of the stomach following laparoscopic Heller myotomy and Dor fundoplication (LHD) for Achalasia. A 73-year-old man was diagnosed with Achalasia and underwent LHD in our hospital. The postoperative course was uneventful and discharged five days after surgery. Three months after the first surgery, he was referred to our hospital emergently, and complaining of severe epigastric pain. The chest X-ray revealed abnormal shadow in the lower field of the left lung, and CT revealed expanded fornix of the stomach migrated

transhiatally into the left thoracic space. We diagnosed transhiatal migration of the stomach and tried the decompression therapy of the stomach for three days, which was not effective. Thereafter, we performed the laparoscopic reduction of the migrated stomach into the abdomen through the hiatal hernia. Three days after the second surgery, the esophagography demonstrated a minor leakage from the esophagus to the left thoracic space. Then we performed thoracoscopy assisted drainage of the infectious fluid collection in the left thoracic space. Thereafter postoperative course was uneventful and he discharged forty days after the third surgery. To our knowledge, this rare complication is the first case reported in the literature.

**Abstract ID: 0483**Specific Field: **Esophagus****Mode of pres.: Poster Discussion  
ISW 2011 Session PW 12.02****Simple and practical procedure in laparoscopic Nissen fundoplication**T. Suwa [1], K. Karikome [1], N. Asakage [1], E. Totsuka [1],  
N. Nakamura [1], K. Okada [1], T. Matsumura [2][1] Kashiwa Kousei General Hospital, Kashiwa, Chiba, Japan,  
[2] Kashiwa Kousei General Hospital, Japan

**Introduction:** Anti-reflux surgery for patients with GERD is not as popular as medication. The reason might be that laparoscopic techniques in the procedure are considered complicated and time-consuming by many surgeons.

**Material and Methods:** Surgical Procedure (1) Our 5-trocar setting with patients in the reverse Trendelenburg's position for laparoscopic Nissen fundoplication is as follows. A 12 mm trocar was inserted just below the navel for a laparoscope (A). A 5 mm trocar was inserted in the upper right abdomen for a snake-retractor to pull up lateral segment of the liver, and a holder was used for a snake-retractor. A 5 mm trocar was inserted in the upper abdomen for operator's left hand. A 12 mm trocar was inserted in the upper left abdomen (B). A 12 mm trocar was inserted in the middle left abdomen (C). The operator is positioned between the patient's legs. (2) Under laparoscopic view, left part of the lesser omentum was cut. The right crura has been dissected free, and the esophagus is being recognized. The left crus of the diaphragm was recognized from the right side. (3) The branches of left gastroepiploic vessels and the short gastric vessels were divided with LCS. The left crus of the diaphragm was exposed and the window at the posterior side of the abdominal esophagus was widely opened. In this part of the procedure, laparoscope uses 12 mm trocar (A) at the beginning of dividing left gastroepiploic vessels, 12 mm trocar (C) when dividing short gastric vessels and 12 mm trocar (B) at the last part of opening the window at the posterior side of the abdominal esophagus. The assistant uses 12 mm trocar (B–C–A) to pull the stomach. (4) The right and left crus are sutured with interrupted stitches to reduce the hiatus. From the right side, the stomach is grasped from behind the esophagus, without manipulating it to avoid injury. Then the fornix of the stomach is pulled to obtain a 360 degree "stomach-wrap" around the esophagus (fundoplication). Such as taping technique is not needed. Using 2-0 nonabsorbable braided suture, stitches are placed between both gastric flaps.

**Results:** This procedure needs 2 surgeons (operator and the assistant (scopist)). The mean operation time was 70 min.

**Conclusion:** We have established a simple and practical procedure in laparoscopic Nissen fundoplication.

**Abstract ID: 0484**Specific Field: **Esophagus****Mode of pres.: Poster Discussion**  
**ISW 2011 Session PW 12.03****Single incision laparoscopic fundoplication for gastroesophageal reflux disease**H. Idani [1], S. Asami [2], K. Nakano [2], K. Kumano [1],  
T. Kubota [2], H. Sasaki [2], H. Kin [2], N. Takakura [2]

[1] Fukuyama City Hospital, Fukuyama, Japan, [2] Fukuyama City Hospital, Japan

**Introduction:** There have been few reports on surgical techniques and outcome on single incision laparoscopic fundoplication (SILF) for gastroesophageal reflux disease (GERD). We report technical aspect and preliminary results of SILF for GERD.**Material and Methods:** Under general anesthesia, a 2 cm incision was made at the umbilicus and the SILS port was inserted. The liver was retracted using Nathanson type retractor by direct insertion through the epigastrium. The gastric fundus was retracted by 1–0 nylon stitches. The short gastric vessels were divided from the lower pole of the spleen using a bipolar vessel sealing system. The esophagus was taped with the Penrose drain which was tied and retracted through the abdomen. The hiatus was approximated and fundoplication was performed intracorporeally using the SILS stitch. Between February and August 2010, six consecutive patients with GERD underwent SILF. Operation time, complications and short term prognosis were evaluated. Preoperative work up included Esophagogastroduodenoscopy, esophagogastrogram, manometry, 24 h pH and impedance test, which was also performed 2–3 months after surgery. The fundoplication was evaluated morphologically by laparoscopically and endoscopically with our newly established morphological score (M score: ML and ME 1–5, very poor to excellent).**Results:** SILF was completed on three patients and additional one port was required on three patients. Toupet fundoplication was performed on five and anterior fundoplication on one patients. Operation time was  $188 \pm$  min and blood loss was 25 g. Liquid started on the first postoperative day (POD). No complication was marked including dysphagia and the postoperative stay was 7.3 day. M scores were quite satisfactory (ML: 4.8, ME: 4.6). LES pressure was improved from 12.1 to 20.5 mmHg. Acid exposure time and DeMeester score were also improved from 7.6 to 0% and from 24.3 to 1.1, respectively. Symptom scores (0–5; none to daily) were significantly improved after surgery ( $P < 0.05$ ); heart burn: from  $3.5 \pm 0.2$  to 0, dysphagia: from  $3.2 \pm 0.7$  to  $1.2 \pm 0.4$ , regurgitation: from  $1.5 \pm 0.3$  to 0.**Conclusion:** Initial results of SILF for GERD are as safe and effective as those of standard laparoscopic fundoplication.**Abstract ID: 0485**Specific Field: **Esophagus****Mode of pres.: Poster Discussion**  
**ISW 2011 Session PW 12.04****Robot-assisted laparoscopic esophagomyotomy with posterior (toupet) fundoplication enhances efficacy and safety for surgery of achalasia**V. Chinswangwatanakul [1], S. Leelakusolwong [2],  
T. Akaraviputh [1], A. Trakamsanga [1], N. Lertakyamanee [1]

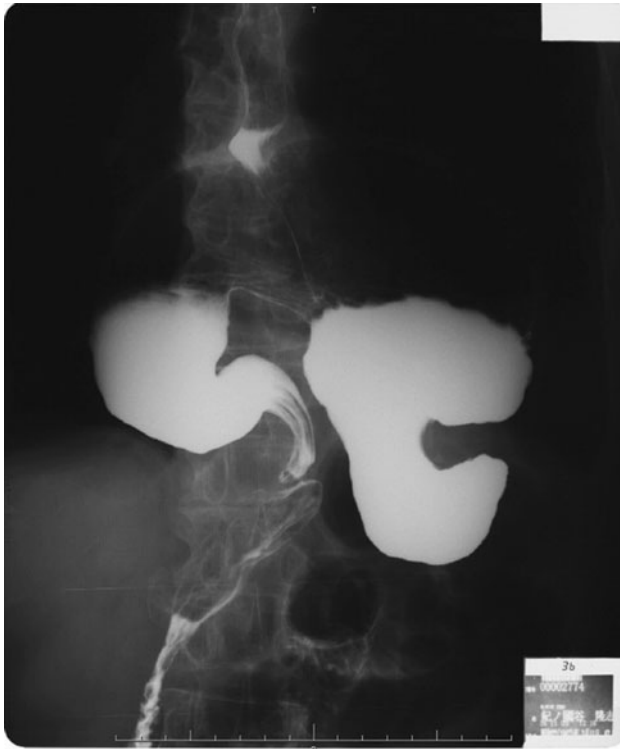[1] MIS Unit, Division of General Surgery, Department of Surgery, Faculty of Medicine Siriraj Hospital, Mahidol University, Bangkok, Thailand, [2] Division of Gastroenterology, Department of Medicine, Faculty of Medicine Siriraj Hospital, Mahidol University, Bangkok, Thailand

**Introduction:** Achalasia is a motility disorder of the esophagus which effectively treated with laparoscopic esophagomyotomy. The anterior (Dor) fundoplication (AF) is usually added as antireflux procedure to prevent gastroesophageal reflux disease (GERD). Recently, robot-assisted laparoscopic esophagomyotomy (RALE) which increases surgeon's dexterity, maneuverability, and precision has been proposed to offer better surgical outcomes. Meanwhile posterior (Toupet) fundoplication (PF) is another preferable procedure to prevent GERD.**Material and Methods:** Between January 2008 to December 2011, there were 20 patients with achalasia undergone RALE with PF in the Division of General Surgery, Department of Surgery, Faculty of Medicine Siriraj Hospital.**Results:** RALE was successfully performed in 8 males and 12 females with mean age of 44 years (ranged 13–79 years). The mean operative time was 219 min (ranged 165–280 min). PF was added in 18 out of 20 patients (90%). The other two patients were encountered with intraoperative esophagogastric mucosal injury, thus primary repair and PF were performed. Nineteen patients (95%) expressed highly satisfactory postoperative surgical outcomes. Only one patient (5%) complaint of occasional dysphagia.**Conclusion:** In conclusion, robot-assisted laparoscopic esophagomyotomy could offer the best surgical outcomes for patients. It enables superb visualization of tissue planes and probably could decrease mucosal perforation rates. However, cost-effectiveness has to be studied and judged individually.**Abstract ID: 0486**Specific Field: **Esophagus****Mode of pres.: Poster Discussion**  
**ISW 2011 Session PW 12.05****A case of hiatal hernia of upside-down stomach type appearing to be formed by vigorous vomiting**

Y. Kise [1], T. Hara [1], O. Chino [2], M. Morita [2]

[1] Samukawa Hospital, Samukawa, Japan, [2] Tokai University School of Medicine, Isehara, Japan

**Introduction:** A massive esophageal hernia of upside down stomach type was encountered, and treated successfully by operation.**Material and Methods:** A 62 year old man vomited vigorously after much drinking and food intake, became impossible for oral intake, and visited the present hospital. The patient complained no abdominal pain or discomfort, but the X-ray examination revealed the fluid-level inside the chest, which was proven to the incarcerated total stomach in the mediastinum. The stomach was fully erosive, but active bleeding was not detected by endoscopy. The patient performed screening endoscopy 1 year before the onset showed only sliding hiatal hernia, which made us consider the cause attributed to vigorous vomiting.**Results:** The operation was performed by Nissen and Hill repair. The patient was discharged uneventfully, and recurrence is not shown 1.5 years postoperatively.**Conclusion:** Open surgery seemed to be more suitable for a massive hiatal hernia because of easiness of detection of short esophagus, and easiness of orientation (Figure).



**Figure:** Incarcerated stomach in the chest

**Abstract ID: 0487**

**Specific Field: Esophagus**

**Mode of pres.: Poster Discussion**  
**ISW 2011 Session PW 12.06**

**Small bronchogenic cysts found at esophagectomy with lymph node dissection in a patient with esophageal carcinoma**

T. Okumura, Y. Shimada, R. Hori, S. Sawada, T. Yoshida, T. Nagata, H. Uotani, K. Tsukada

Department of Surgery and Science, Graduate School of Medicine and Pharmaceutical Science, University of Toyama, Toyama, Japan

**Introduction:** Bronchogenic cysts are rare congenital anomalies of foregut origin and are usually found within the mediastinum. We report here an esophageal cancer patient who underwent radical esophagectomy and found to have bronchogenic cysts during surgery.

**Results:** A 76 year old man had dysphagia and was diagnosed with middle thoracic esophageal squamous cell carcinoma. Pre operative computed tomography (CT) showed thin-wall small cystic structures with 0.8 cm diameter in upper mediastinum and the lesions were considered to be emphysematous bullae. The patient underwent video-assisted thoracoscopic esophagectomy with three-field lymph node dissection. An elastic soft cystic structure with 1cm diameter was removed along with upper thoracic paraesophageal lymph nodes. Another elastic nodule with 0.8 cm diameter was found during cervical lymph node dissection. The nodule strongly adhered to the main bronchus and was difficult to remove. Based on the intra-operative findings and the pre operative CT image, the nodule was diagnosed as

a cyst but not a metastasized lymph node, and was left without extirpation. Histological findings showed the presence of ciliated columnar epithelium in the removed cystic structure, leading a diagnosis of bronchogenic cyst. There were no components of cartilage in the cyst, finding compatible with the pre operative CT image in which no calcification was seen. The final diagnosis of esophageal cancer was T1 N1 (106LecR) M0 Stage2B. The patient recovered without post operative complications and no remnant cyst-related complication or enlargement of the cyst was observed until 10 months after surgery.

**Conclusion:** Although it is a rare case, small bronchogenic cysts need to be considered in the differential diagnosis of lymph nodes which subject to dissection in esophageal cancer surgery. Total excision of asymptomatic and uncomplicated bronchogenic cysts has been reported to be optional.

**Abstract ID: 0488**

**Specific Field: Esophagus**

**Mode of pres.: Poster Discussion**  
**ISW 2011 Session PW 13.01**

**Esophageal stripping creates a clear operative field for lymph node dissection along the left recurrent nerve in prone video-assisted thoracoscopic surgery: a case report**

H. Makino [1], T. Nomura [1], N. Hagiwara [1], Y. Nakamura [1], M. Katsuta [2], K. Yokoi [2], M. Miyashita [1], E. Uchida [1]

[1] Nippon Medical School, Tokyo, Japan, [2] Nippon Medical School, Chiba Hokusoh Hospital, Chiba, Japan

**Introduction:** Video-assisted thoracoscopic surgery of the esophagus (VATS-E) in prone position has achieved remarkable results in Japan because the lung moves below by the gravity, and a good operative field is obtained. A clear operative view of the middle and lower mediastinum has been obtained; however, the working space in the upper mediastinum is limited.

**Material and Methods:** We describe a 54-year-old man who was diagnosed with esophageal squamous cell carcinoma and underwent VATS-E in prone position. Initially, a patient is fixed in a semi-prone position, from which they can be rotated to a prone or left lateral position. Four ports are inserted into the 3rd, 5th, 7th and 9th intercostal space (ICS), and then the patient is rotated to prone position. When the patient is prone, gravity causes the lung to move downward. Next, the chest cavity is inflated using a CO<sub>2</sub> insufflation pressure of 6 mmHg. Esophagectomy was performed with dissection of the lymph nodes around the esophagus, trachea and bronchus, above the diaphragm and along the right recurrent laryngeal nerve. In the left upper mediastinum, lymph node dissection was performed after stripping of the residual esophagus with retracting the trachea using the retractor.

**Results:** 1. Esophageal stripping creates a clear operative field for lymph node dissection along the left recurrent nerve in prone position of VATS-E.

2. Estimated blood loss was less than 100 ml and operative time 5.15 h of chest procedure in prone position.

3. The temporary left recurrent laryngeal nerve paralysis was detected.

**Conclusion:** Our results indicate that esophageal stripping in prone VATS-E allows for safe and straight forward lymph node dissection along the left recurrent laryngeal nerve. Our device overcame the difficulty of the lymph node dissection along the left recurrent laryngeal nerve in prone position.

**Abstract ID: 0489**Specific Field: **Esophagus****Mode of pres.: Poster Discussion**  
**ISW 2011 Session PW 13.02****Preliminary results of prone-position esophagectomy**

Y. Shimada, T. Okumura, R. Hori, S. Sawada, K. Matsui, T. Yoshida, T. Nagata, T. Tsukada

University of Toyama, Toyama, Japan

**Introduction:** From August 2010, we started to perform prone-position esophagectomy for thoracic esophageal cancer patients. In this paper, we evaluate preliminary results of prone-position esophagectomy.**Material and Methods:** We performed prone-position esophagectomy for 10 thoracic esophageal cancer patients from August to December 2010. We used a 30 degree stiff scope with 8 mmHg positive thoracic pressure. Standard port positions are as follows. 12 mm for the 9th, 7th, and 5th intracostal space and 5 mm port for the 3th intracostal space. We compared the clinical outcome of prone-position esophagectomy (PE) to that of 25 thoracoscopic assisted esophagectomies (TAE) in lateral position and 3 hemiprone-position esophagectomies (HPE).**Results:** There was no significant difference of clinicopathological characteristics of the three groups. Operation time for thoracic procedure of TAE, HPE and PE were 269, 321 and 288 min respectively ( $P = 0.1624$ ). Average intrathoracic bleeding volumes of TAE, HPE and PE were 325, 248 and 29 ml respectively ( $P = 0.001$ ). The number of intrathoracic lymph node dissections of TAE, HPE and PE were 20, 19 and 18 respectively ( $P = 0.7967$ ). Postoperative complications of PE were 1 pyothorax, 1 recurrent nerve palsy and 1 thoracic effusion. We can remove the intubation tube in the operation room in half of the PE patients.**Conclusion:** Prone-position esophagectomy was performed safely and reduced the intrathoracic bleeding without increasing the complications.**Abstract ID: 0490**Specific Field: **Esophagus****Mode of pres.: Poster Discussion**  
**ISW 2011 Session PW 13.03****The pedicled jejunum reconstruction in thoracic esophageal cancer**

H. Sato, M. Nakagawa, M. Niihara, Y. Tsubosa

Shizuoka Cancer Center, Sunto-gun, Japan

**Introduction:** Reconstruction using the colon has been proposed as a standard procedure after esophagectomy in patients whose stomach cannot be used. However, it is more complex than gastric transposition with increased morbidity. We prefer transposition with an extended jejunum as an esophageal substitute in such cases. The aims of this study were to evaluate the effect and the safety of this method.**Material and Methods:** Seventeen patients (sixteen males) with esophageal cancer, aged 56–78 (median 68.5) years, underwent esophagectomy via right thoraco-abdominal approach. All of them had no suitable stomach for a substitute. Twelve patients had undergone gastrectomy, and five had gastric cancer simultaneously. All of them underwent reconstruction using a pedicled jejunum as an esophageal substitute via presternal route and jejunostomy for enteral feeding. Fourteen patients underwent vascular supercharge and /or superdrainage. The outcome measures were mortality rate, morbidity rate, oral intake and length of hospital stay. This was a retrospective study.**Results:** No severe complications were seen postoperatively in all patients. Hospital mortality was zero. The morbidity rate was 65%. Anastomotic leaks of esophago-jejunostomy were the most frequent complications. They were occurred in eight patients (47%). However, all of them were spontaneously cured. There was no complication in relation to microvascular procedures. All of them had enjoyed their eating habits. The median length of hospital stay was 38 days, however 25 days in the patients with no anastomotic leaks.**Conclusion:** Hospital mortality and morbidity rate of this procedure were acceptable. However the rates of the anastomotic leaks were relatively high, so the efforts to reduce anastomotic leaks were needed. Reconstruction with an extended jejunum would contribute to reducing surgical stress, because mobilization of the colon from retroperitoneum is not necessary. And early enteral feeding via jejunostomy is possible, because no anastomosis of the intestine is made in the distal portion from the entering point of enteral tubes.**Abstract ID: 0491**Specific Field: **Esophagus****Mode of pres.: Poster Discussion**  
**ISW 2011 Session PW 13.04****An intra-gastric anvil connecting technique for esophagogastrostomy using a circular stapler**S. Yoshino, S. Takeda, O. Tsutsui, Y. Watanabe, S. Hazama, M. Oka  
Yamaguchi University Graduate School of Medicine, Ube, Japan**Introduction:** A detachable circular stapler is commonly used to create esophagogastric anastomosis following thoracic esophagectomy for carcinoma of the esophagus, but sometimes it is difficult to connect the anvil shaft and the center rod due to the narrow neck surgical field. We developed an intra-gastric anvil connecting technique for esophagogastrostomy using a circular stapler.**Material and Methods:** After creation of the gastric tube, its tip is raised up to the neck incision through the retrosternal or the posterior mediastinal route. The end of the gastric tube is cut widely and the anvil shaft is penetrated at the posterior wall reversely as far as possible from the end of the stomach where the blood supply is not compromised. The anvil shaft is grasped with an anvil holder in the stomach and then the anvil is inserted into the cut end of the cervical esophagus where a purse-string suture is placed. A purse-string suture is tied around the anvil shaft and the center rod of the stapler is connected to the anvil shaft in the stomach. The instrument is closed and fired. From 2000 to 2010, one hundred and sixty three patients with esophageal cancer who underwent esophagogastrostomy were assessed.**Results:** Only 9 patients (4.9%) developed minor leakage and 32 (19.6%) developed anastomotic stricture which was easily treated with balloon dilatation.**Conclusion:** This technique is safe and simple and should become one of a standard approach for esophagogastrostomy.**Abstract ID: 0492**Specific Field: **Esophagus****Mode of pres.: Poster Discussion**  
**ISW 2011 Session PW 13.05****Cases of peptic ulcer in the gastric tube substituted for esophagus after esophagectomy**

Y. Shimada [1], T. Okumura [1], R. Hori [1], T. Yoshida [1], T. Nagata [1], H. Uotani [1], Y. Sakai [2], K. Tsukada [1]



[1] University of Toyama, Toyama, Japan, [2] Kyoto University, Kyoto, Japan

**Introduction:** We previously reported that the acid secreted from the gastric tube which was a substitution for the esophagus after an esophagectomy was enough to cause a peptic ulcer (J Am Coll Surg 1995). Based on our previous observation, we have routinely used H2 blocker after esophagectomies. However, we have experience of patients who have suffered a peptic ulcer and resulted in a serious condition.

**Material and Methods:** From 1995 to 2003, we have had 6 out of 225 patients (2.7%) with a peptic ulcer or erosion of gastric tube in Kyoto University. After that, we have had 2 out of 54 patients (3.7%) with peptic gastric tube ulcer from 2003 to 2009 in Toyama University.

**Results:** Of the 8, 5 patients took non-steroidal anti-inflammatory drugs (NSAID), another received steroid therapy, and one other patients quit taking H2 blocker at the time of examination. Two patients had penetration of a peptic ulcer into the pericardium and required drainage of the pericardium. 3 patients had tarry stool or hematemesis and only one patient had epigastric pain. Seven patients were cured using a proton pump inhibitor (PPI), and one patients was cured by re-taking H2 blocker.

**Conclusion:** The implications of peptic ulcer of the gastric tube should be more widely recognized. We recommend simultaneously prescribing PPI, when the gastric tube reconstruction patients desire to take NSAID, or must take steroids.

**Abstract ID: 0493**

Specific Field: **Esophagus**

**Mode of pres.: Poster Discussion**  
**ISW 2011 Session PW 13.06**

**A case with the fistula of reconstructed gastric tube to bronchus after esophagectomy for esophageal cancer**

M. Nemoto, N. Katada, T. Shibata, H. Mieno, K. Yamashita, S. Sakuramoto, S. Kikuchi, M. Watanabe

Kitasato University, Sagamihara, Knagawa, Japan

**Introduction:** A 66-year-old man was referred to our hospital, and was diagnosed as the squamous cell carcinoma located at the middle thirds of the esophagus. Pre-operative clinical staging was Stage I (cT1, cN0, cM0 in TNM classification). The CT revealed pulmonary bullas at the top of superior lobe of right lung. Thereafter, the right thoroscopic esophagectomy was performed with three field lymph node dissection, and the reconstruction of gastric tube through the mediastinal route. He had a fever on the 8th postoperative day (POD), and CT demonstrated serious pneumonia at the upper lobe of right lung. On the 12th POD, endoscopy revealed the fistula of reconstructed gastric tube to right bronchus near the esophago-gastric anastomosis. Conservative treatment with antibiotics and thoracic drainage tube was not effective. At the 53rd POD, surgical treatment with right re-thoracotomy was performed. Although severe adhesions were seen in the superior lobe of right lung, the fistula of the gastric tube was closed with interrupted suturing. The site of the fistula was covered with latissimus dorsi muscle flaps through the 2nd right intercostals space. On the 84th POD, the fistula was confirmed as closed, and he discharged on the 96th POD. The right pulmonary bullas may cause the fistula of reconstructed gastric tube to bronchus after esophagectomy, if the anastomotic leakage occur in the mediastinum.

**Abstract ID: 0494**

Specific Field: **Esophagus**

**Mode of pres.: Poster Discussion**  
**ISW 2011 Session PW 17.01**

**The therapeutic value of lymph node dissection for thoracic esophageal cancer**

Y. Tsubosa, H. Sato, M. Niihara

Shizuoka Cancer Center Hospital, Shizuoka, Japan

**Introduction:** The value of lymph node dissection in the surgical treatment of thoracic esophageal cancer is controversial.

**Material and Methods:** All regional lymph nodes were individually dissected from the adipose connective tissue of the specimen immediately after esophagectomy by the surgeons who performed the operation. Node numbers and locations were recorded using a lymph node map of Japanese Classification of Esophageal Cancer. Nodes found at each station were labeled and sent for histological examination. The results of 195 potentially curative resections for thoracic esophageal cancer performed at Shizuoka Cancer Center Hospital between 2002 and 2009 were studied using an approach which circumvents the stage migration phenomenon. No patient received neoadjuvant or adjuvant radiotherapy. The incidence of metastasis and the 5-year survival rate of patients with positive nodes were calculated independently for each lymph node 'station', without any reference to overall pathological nodal stage. The therapeutic value of extended lymph node dissection was estimated by multiplication of incidence of metastasis and percentage 5-year survival rate of patients with metastasis for each station.

**Results:** The incidence of metastasis ranged from 0 to 42.9% and the 3-year survival rate of affected patients from 0 to 100% in regional stations, depending on the site of the primary tumor. The index of estimated benefit from lymph node dissection at these stations was calculated. The index of right (11.67) and left (5.05) recurrent laryngeal nerves, the right (10.48) and left (8.18), and the lesser curvature (7.69) lymph node station were high. The index of upper thoracic paraesophageal (0.63), and parapancreatic lymph node (0) were very low.

**Conclusion:** In thoracic esophageal cancer, bilateral recurrent laryngeal nerve and bilateral cardiac lymph node dissection is most important for long survival. Upper thoracic paraesophageal and parapancreatic lymph node dissection may not contribute to long survival.

**Abstract ID: 0495**

Specific Field: **Esophagus**

**Mode of pres.: Poster Discussion**  
**ISW 2011 Session PW 17.02**

**Radiofrequency ablation for metastatic lung tumors from squamous cell carcinoma of the esophagus**

K. Taki, M. Watanabe, Y. Nagai, S. Iwagami, Y. Miyamoto, Y. Baba, M. Iwatsuki, H. Baba

Gastroenterological Surgery, Kumamoto University, Kumamoto City, Japan

**Introduction:** Backgrounds: Prognosis of patients with metastatic tumors from squamous cell carcinoma of the esophagus is poor. Recently, radiofrequency ablation (RFA) has become an alternative modality for primary or metastatic lung carcinomas. However, an efficacy of this treatment for metastatic lung tumors originated from esophageal cancer is still unclear.

**Material and Methods:** From September 2005 to May 2010, 4 patients with lung metastasis originated from esophageal cancer were treated with computed tomography (CT)-guided RFA. As a primary treatment, 3 of 4 patients have undergone esophagectomy and 1 patient has been treated with definitive chemoradiotherapy. Recurrence other than the lung metastasis was observed in 2 patients. All patients have undergone chemotherapy both prior to and after RFA. Efficacy and safety of RFA for metastatic lung tumors was evaluated.

**Results:** All 4 patients were male and the mean age was 57.5 years old. Nine lung tumors of 4 patients were treated with CT-guided RFA. Tumor size ranged from 5 to 26 mm and the mean size was 12.4 mm. All tumors were successfully treated with RFA and there was no local treatment failure observed during the follow up period for 1 month to 42 months (median 9.0 months). Although one patient died from metastatic brain tumor at 13 months after RFA, the other 3 patients are still alive without any active diseases at 1, 9 and 42 months after RFA, respectively. Pneumothorax was observed in 2 patients and drainage was needed in one patient. Chest pain which needed opioid during the procedure was observed in one patient.

**Conclusion:** RFA effectively controlled metastatic lung cancers from esophageal origin without severe adverse event. Long-term survival can be achieved using RFA for pulmonary disease in combination with chemotherapy. RFA is a safe and effective modality for multidisciplinary treatment for recurrent esophageal cancer.

**Abstract ID: 0496**                      Specific Field: **Esophagus**

**Mode of pres.: Poster Discussion**  
**ISW 2011 Session PW 17.03**

**A case of esophageal cancer presenting the pathologic fracture of humerus as the first clinical manifestation**

M. Kitagawa, H. Fujiwara, A. Shiozaki, S. Komatsu, D. Ichikawa, K. Okamoto, T. Ochiai, E. Otsuji

Kyoto Prefectural University of Medicine, Kyoto, Japan

**Introduction:** Patients with esophageal carcinoma usually present with progressive dysphagia and weight loss. Other clinical manifestations include retrosternal discomfort, burning sensation, regurgitation of saliva or food, hoarseness, iron deficiency anemia, or intractable coughing. The patients with esophageal cancer presenting the bone metastasis and the pathologic fracture as the first clinical manifestation are extremely rare. Here we report, to our knowledge, the first case of esophageal cancer who presented the pathologic fracture of humerus as the first clinical manifestation and no other symptoms associated with esophageal cancer.

**Results:** Case Report: A 68-year-old man visited an orthopedician, complaining of right shoulder pain which occurred suddenly during sleeping. Roentgenogram showed that there was the fracture of right proximal humerus, which appeared to be the pathologic fracture. Then, the systemic examination was performed to detect the primary lesion. Esophagoscopy revealed that he had type 3 neoplasm in the thoracic esophagus, although he had no symptoms, such as dysphagia, suggesting the presence of esophageal cancer. The pathological examination of the biopsied specimen revealed that the neoplasm was a moderately differentiated squamous cell carcinoma. He was brought to our hospital for the treatment. The FDG-positron emission tomography (PET) scans demonstrated that the intense FDG uptake was detected at the middle mediastinal region and the right humerus. No lesions suggesting lymph node metastasis were detected on the computed tomography (CT) and the PET scan. As he had an advanced esophageal cancer with distant organ metastasis, he was treated by the systemic chemotherapy, including docetaxel (60 mg/m<sup>2</sup>, i.v., day 1),

cisplatin (60 mg/m<sup>2</sup>, i.v., day 4) and 5-FU (600 mg/m<sup>2</sup>, continuous infusion, days 1–5). The radiation therapy and the intravenous administration of zoledronic acid were performed for the treatment of the metastatic lesion at the right humerus. He was effectively treated with these therapies.

**Conclusion:** This case presented the pathologic fracture of humerus due to the bone metastasis as the first clinical manifestation without any significant symptoms suggesting the presence of esophageal cancer, and was effectively treated by the multimodality therapy consisting of chemotherapy, radiotherapy and bisphosphonate.

**Abstract ID: 0497**                      Specific Field: **Esophagus**

**Mode of pres.: Poster Discussion**  
**ISW 2011 Session PW 17.04**

**A case of thoracoscopic esophagectomy for esophageal gastrointestinal stromal tumor**

M. Konosu, Y. Kimura, Y. Noda, T. Iwaya, F. Endo, M. Mizuno, A. Sasaki, G. Wakabayashi

Iwate Medical University, Morioka, Japan

**Introduction:** Esophageal Gastrointestinal stromal tumor (GIST) is a rare disease that found in 2% to 5% of all GISTs. We present a case of thoracoscopic esophagectomy for esophageal GIST.

**Material and Methods:** Patient was a 72-year-old man who complained weight loss. He underwent gastrointestinal endoscopic examination and pointed out the esophageal submucosal tumor. After observation for a year, he underwent examination with the endoscopic ultrasonography and fine needle aspiration. Histological examination showed GIST (CD34: positive, c-kit: positive,  $\alpha$ -SMA: negative, desmin: negative, S-100: negative). Because the size of tumor was over 5cm in diameter, we planned esophagectomy for this case.

**Results:** We performed thoracoscopic esophagectomy. At first, we approached 4ports from the right-sided chest with the patient in a prone position. Thoracoscopically, we performed discussion of the esophagus. Next, we performed anastomosis of the stomach to the cervical esophagus with the laparotomy and cervical incision (Operation time: 9 h 5 m, Loss of blood volume: 61 ml). He was extubated on postoperative day 1, and had a diet on postoperative day 7. He was discharged on postoperative day 25 without major complication.

**Conclusion:** In principle, surgical treatment for gastrointestinal stromal tumor (GIST) is complete resection. It is important to avoid damage to the pseudocapsule, maintain a surgically safe margin, and have a negative gross stump. For cases where tumor diameter is 5 cm or less, enucleation can also be considered, but for cases exceeding 5 cm, tumor resection accompanied by resection of the esophagus is unavoidable. Since lymph node dissection is not required during GIST resection, thoracoscopic esophagectomy may be a good alternative treatment for GIST.

**Abstract ID: 0498**                      Specific Field: **Esophagus**

**Mode of pres.: Poster Discussion**  
**ISW 2011 Session PW 17.05**

**Correlation between gp96 expression and the surgical outcome in patients with esophageal squamous cell carcinoma**

Y. Akutsu, N. Hanari, M. Mori, G. Yusup, A. Komatsu-Akimoto, N. Ikeda, S. Endo, H. Matsubara

Chiba University, Department of Frontier Surgery, Chiba, Japan

**Introduction:** Heat shock protein gp96 plays an important role in antitumor immunoreactions. Gp96 has a close relationship with antitumor immunity. This study evaluated the association between gp96 expression and the prognosis in esophageal squamous cell carcinomas (ESCC).

**Material and Methods:** Seventy-eight primarily resected ESCC were enrolled in this study and gp96 expression was evaluated by immunohistochemical staining. The association of clinicopathological factors and patients' survival was calculated by a univariate analysis using the Log-Rank test, and a multivariate analysis using Cox's proportional hazard regression method.

**Results:** Fifty-seven of 78 cases were gp96 positive (73%) and 21 were negative (27%). The survival of gp96 negative cases were significantly shorter (5-year survival: 22.9 months) than that of positive cases (45.8 month;  $P = 0.049$ ), and the multivariate analysis showed that gp96 negativity is an independent risk factor for poor survival (hazard ratio: 2.577,  $P = 0.040$ ). Gp96 negative cases had more metastatic lymph nodes in comparison to positive cases especially in T1 cases (4.8 in gp96 negative cases vs. 0.84 in gp96 positive cases;  $P = 0.064$ )

**Conclusion:** The decreased expression of gp96 expression closely correlated with the poor survival of ESCC.

**Abstract ID: 0499**

Specific Field: **Esophagus**

**Mode of pres.: Poster Discussion**  
**ISW 2011 Session PW 17.06**

#### **COX2 expression predicts resistance to chemoradiotherapy in esophageal squamous cell carcinoma**

Y. Akutsu, N. Hanari, M. Mori, Y. Yoneyama, N. Ikeda, S. Endo, A. Komtatsu-Akimoto, H. Matsubara

Chiba University, Department of Frontier Surgery, Chiba, Japan

**Introduction:** The overexpression of COX2 was correlated with carcinogenesis, tumor progression and prognosis, and increased COX2 expression was correlated with radiation resistance. However, no correlation between the COX2 expression and resistance to chemoradiotherapy for esophageal squamous cell carcinoma has so far been characterized. The purpose of the present study was to evaluate whether COX2 expression is an indicator of resistance to chemoradiotherapy in esophageal squamous cell carcinoma and the feasibility of COX2 as a biomarker for CRT.

**Material and Methods:** Fifty-eight patients who were diagnosed with esophageal squamous cell carcinoma from biopsy samples were enrolled in the present series. All patients underwent concurrent chemoradiotherapy in a neoadjuvant setting, followed by radical esophagectomy. COX2 expression was evaluated by immunohistochemical staining and statistically compared with the histopathologic findings in surgically resected specimens.

**Results:** The rate of responders was 87% for weak expression of COX2, 62% for moderate expression, and 30% for strong expression, and there was a close correlation between COX2 expression and the response rate Kendall's  $\tau_b = 0.396$ ,  $P = 0.001$ ). In the univariate analysis, negative or weak expression of COX2 was found to significantly correlate with CRT response (odds ratio 6.296, 95% CI 1.580–25.096). In the multivariate analysis, weak expression of COX2 (30% or less) was found to be an independent prognostic factor (odds ratio 6.534, 95% CI 1.535–27.803,  $P = 0.011$ ).

**Conclusion:** Conclusion: The COX2 expression predicts resistance to chemoradiotherapy in esophageal squamous cell carcinoma, and it is also a feasible biomarker for evaluating the CRT response.

**Abstract ID: 0500**

Specific Field: **Esophagus**

**Mode of pres.: Poster Discussion**  
**ISW 2011 Session PW 17.07**

#### **Clinicopathological significance of new cancer-testis antigens, URLC10 and KOC1, in patients with esophageal cancer**

T. Sakakibara, S. Ozawa, M. Nakui, S. Yamamoto, A. Kazuno, O. Chino, H. Shimada, H. Makuuchi

Tokai University School of Medicine, Isehara, Japan

**Introduction:** Cancer-testis antigens are considered to be not only a promising target for immunotherapy, but also a good biomarker for the diagnosis of cancer and the monitoring of relapse. Esophageal cancer is one of most malignant gastrointestinal cancers and is difficult to treat. The aim of this study was to clarify the clinicopathological significance of the expression of two new cancer-testis antigens, URLC10 and KOC1, in patients with esophageal cancer.

**Material and Methods:** A total of 113 formalin-fixed primary esophageal squamous cell carcinoma (ESCC) specimens were obtained from patients undergoing curative surgery at the Tokai University Hospital. These ESCC patients had undergone a trans-thoracic esophagectomy and three-field lymph node dissection. The pathologic stage was determined according to the Japanese classification for esophageal cancer. The expressions of URLC10 and KOC1 were then investigated immunohistochemically using a rabbit polyclonal antihuman URLC10 antibody (LY6K) or a mouse monoclonal antihuman KOC1 antibody (IMP3). The relationships between the URLC10 or KOC1 expression levels and the clinicopathological variables of the ESCC patients were then analyzed.

**Results:** Positive staining for URLC10 was observed in 113 of the 113 (100%) ESCC cases. URLC10 was strongly stained in 49 cases (43%, S group) and weakly stained in 64 cases (57%, W group). The S group was correlated with a higher grade of pStage ( $P = 0.003$ ), pT ( $P < 0.001$ ), pN ( $P = 0.001$ ), ly ( $P = 0.04$ ), v ( $P = 0.001$ ), and INF ( $P = 0.006$ ) and was correlated with a poor prognosis ( $P = 0.003$ ). Positive staining for KOC1 was observed in 102 of the 113 (91%) ESCC cases. The positive cases were divided into 43 cases (38%) with a marginal lesion that was strongly stained (MS) and 59 cases (52%) with a marginal lesion that was weakly stained (MW). The MS group was correlated with a higher grade of pStage ( $P = 0.048$ ) and pT ( $P = 0.016$ ) and was correlated with a poor prognosis ( $P = 0.043$ ). A positive correlation between URLC10 expression and KOC1 expression was observed ( $P = 0.035$ ). Cases classified as both S group and MS group showed the worst prognosis ( $P = 0.016$ ).

**Conclusion:** The expression intensity and pattern of URLC10 and KOC1 were correlated with the clinical malignant potential of ESCC. These new cancer-testis antigens seem to be good biomarkers for the diagnosis of cancer and the monitoring of relapse.

**Abstract ID: 0501**

Specific Field: **Esophagus**

**Mode of pres.: Poster Exhibition only**  
**ISW 2011 Session PE 233**

#### **Cholecystitis, cholelithiasis, and hyperbilirubinemia after esophagectomy**

T. Oida [1], K. Mimatsu [1], H. Kano [1], A. Kawasaki [1], Y. Kuboi [1], N. Fukino [1], K. Kida [1], S. Amano [2]

[1] Social Insurance Yokohama Central Hospital, Yokohama, Japan,  
[2] Nihon University School of Medicine, Tokyo, Japan

**Introduction:** A high incidence of hyperbilirubinemia and an increased incidence of gallbladder disorders after esophagectomy have been reported. Moreover, several studies have documented an increased incidence of gallbladder disease in patients receiving long-term total parenteral nutrition. We studied the incidence of cholecystitis and cholestasis and hyperbilirubinemia associated with total parenteral nutrition after esophagectomy.

**Material and Methods:** We retrospectively studied 42 patients who underwent esophagectomy. These patients were divided into 2 groups: the hyperbilirubinemia group and the non-hyperbilirubinemia group. The incidence of cholecystitis or cholestasis after the surgery was compared between the 2 groups.

**Results:** The mean total serum bilirubin level of the hyperbilirubinemia group ( $2.40 \pm 0.35$  mg/dl) was significantly higher than that of the non-hyperbilirubinemia group ( $1.20 \pm 0.34$  mg/dl;  $P < 0.0001$ ). No significant differences were observed between the 2 groups with respect to the mean duration for which total parenteral nutrition was required around the time of the operation (i.e., pre- and postoperatively) and the incidence rate of cholecystitis or cholestasis after esophagectomy.

**Conclusion:** Hyperbilirubinemia after esophagectomy was frequently observed; however, it may not contribute to gallbladder problems. We suggest that parenteral modalities such as tube feeding should be initiated soon surgery to prevent gallbladder problems after esophagectomy.

#### Outcomes

	HB group ( <i>n</i> = 13)	Non-HB group ( <i>n</i> = 29)	<i>P</i> value
Fields of lymphadenectomy			
2-field	0 (0%)	2 (6.9%)	1.00
3-field	13 (100%)	27 (93.1%)	1.00
Reconstruction			
Stomach	13 (100%)	28 (96.6%)	1.00
Colon	0 (0%)	1 (3.4%)	1.00
Operative time (min)	421	423	0.8210
Blood loss (ml)	557	521	0.3171
Total bilirubin (mg/dl)	2.40	1.20	0.0001#
Duration of TPN (day)			
Preoperative	4.5	4.7	0.3989
Postoperative	11.5	11.8	0.6486
Total	16.1	16.5	0.4797
Cholecystitis or cholelithiasis	1 (7.7%)	2 (6.9%)	1.00

**Abstract ID: 0502**

Specific Field: **Esophagus**

**Mode of pres.: Poster Exhibition only**  
**ISW 2011 Session PE 234**

**Treatment strategy for esophageal cancer accompanied synchronously with gastric cancer**

S. Umehara, H. Fujiwara, A. Shiozaki, S. Komatsu, D. Ichikawa, K. Okamoto, E. Otsuji

Kyoto Prefectural University of Medicine, Kyoto, Japan

**Introduction:** Esophageal cancer is often found with primary cancers of different organs from the esophagus. Among these multi-organ primary cancers, gastric cancer is found with the highest incidence. Following esophagectomy, stomach is used for esophageal reconstruction as the first choice of organ, and stage and location of gastric cancer critically influence the treatment strategy for esophageal cancer. The aim of this study was to clarify the treatment strategy for esophageal cancer accompanied synchronously with gastric cancer.

**Material and Methods:** Twenty-one patients with esophageal cancer with synchronous gastric cancer who were treated at Department of surgery, Kyoto Prefectural University of Medicine hospital between 1998 and 2010, were analyzed in this study. Decision making of the treatment strategy including operative procedures was reviewed.

**Results:** Esophageal cancers consist of superficial cancer ( $n = 9$ ) and advanced cancer ( $n = 12$ ). Superficial esophageal cancer accompanied early gastric cancer ( $n = 7$ ) and advanced gastric cancer ( $n = 2$ ). Advanced esophageal cancer accompanied early ( $n = 7$ ) and advanced ( $n = 5$ ) gastric cancer. Treatment plan was determined according to stage and location of each cancer. Esophageal cancers with indication for esophagectomy ( $n = 15$ ) accompanied early gastric cancer ( $n = 11$ ) and advanced gastric cancer ( $n = 4$ ), whereas esophageal cancers without indication for esophagectomy ( $n = 6$ ) accompanied early ( $n = 3$ ) and advanced ( $n = 3$ ) gastric cancer. In case of esophagectomy, preoperative endoscopic resection was performed for early gastric cancer ( $n = 3$ ), whereas intraoperative resection was performed for early gastric cancer without indication for endoscopic resection, consisting of the resection of lesser curvature combined with esophagectomy because of gastric lesion located at lesser curvature ( $n = 7$ ), and local resection for the lesion located at great curvature ( $n = 1$ ). In case of esophagectomy with advanced gastric cancer ( $n = 2$ ), total gastrectomy was performed with reconstruction by using ileocolon. In case of inoperable esophageal cancer, salvage surgery following chemoradiotherapy was performed in 1 case.

**Conclusion:** In the treatment of esophageal cancer with synchronous gastric cancer, optimal treatment strategy should be planned according to stage and location of each cancer.

**Abstract ID: 0503**

Specific Field: **Esophagus**

**Mode of pres.: Poster Exhibition only**  
**ISW 2011 Session PE 235**

**Early detection of postoperative pulmonary complications by the clinical pulmonary infection score (CPIS) in patients with esophageal cancer who underwent esophagectomy**

A. Furutani [1], H. Fujiwara [1], A. Shiozaki [1], N. Shime [2], S. Komatsu [1], D. Ichikawa [1], K. Okamoto [1], E. Otsuji [1]

[1] Kyoto Prefectural University of Medicine, Graduate School of Medical Science, Department of Digestive Surgery, Kyoto, Japan, [2] Kyoto Prefectural University of Medicine, Department of Anesthesiology, Kyoto, Japan

**Introduction:** Recent advances in surgical technique and perioperative managements have increased the opportunities for surgical resection of esophageal cancer in patients with high risks, however, postoperative pulmonary complications such as pneumonia or ARDS still occur most frequently. Early detection of pulmonary complications at earlier stage following esophagectomy is critical in postoperative intensive care for the patients with high risks. The purpose of this study was to clarify the usefulness of the Clinical Pulmonary Infection Score (CPIS) proposed by Pugin et al in early detection of postoperative pulmonary complications.



**Material and Methods:** Seventy-five patients with esophageal cancer who underwent esophagectomy from January 2009 to September 2010 at Kyoto Prefectural University of Medicine Hospital were subjected to this study. 17 of 75 patients had postoperative pulmonary complications. Body temperature, leukocyte count, airway secretion, P/F ratio of arterial blood gas, and chest radiographic findings in each patient were scored according to the modified CPIS and a total of scores in each patient on postoperative day 1 were compared between the groups with and without pulmonary complication.

**Results:** Two of 17 patients had pneumonia and 15 had ARDS. There were no differences in tumor stage, preoperative therapy, operative procedure and curability between the groups. The group with pulmonary complication had significantly higher CPIS than the group without pulmonary complication ( $P = 0.005$ ). Pulmonary complications were predicted by CPIS with the sensitivity of 64.7%, specificity of 72.4% and accuracy of 70.7%.

**Conclusion:** CPIS was useful for early detection of postoperative pulmonary complications. Careful management for the prevention of pulmonary complication should be considered in patients with high CPIS.

**Abstract ID: 0504**

Specific Field: **Esophagus**

**Mode of pres.: Poster Exhibition only**  
**ISW 2011 Session PE 236**

**Treatment outcome of surgery for esophageal cancer in elderly patients**

S. Okamura, H. Fujiwara, E. Otsuji

Kyoto Prefectural University of Medicine, Kyoto, Japan

**Introduction:** Recent advances in perioperative management and surgical technique have improved the safety of surgery for esophageal cancer, however, surgery in elderly patients still often causes postoperative severe respiratory complications requiring long-term respiratory support. The aim of this study was to verify the treatment outcome of surgery for esophageal cancer in elderly patients with regard to its safety and curability.

**Material and Methods:** 376 patients with esophageal cancer who underwent curative esophagectomy between 2000 and 2010 were analyzed in this study. The patients were divided into two groups consisting of the patients aged 70 years or more (elderly group,  $n = 92$ ) and those aged less than 70 years (younger group,  $n = 284$ ), and clinicopathological factors including operative procedures were compared between the groups.

**Results:** Mean age of elderly and younger groups was 73.3 and 60.2 years, respectively. Incidence of preoperative comorbidity in elderly and younger groups was 45.5 and 37.3%, respectively. No differences were observed in preoperative examinations such as FEV1.0%, PaO<sub>2</sub>, serum creatinine and albumin between the groups. Incidence of synchronous and metachronous cancers of other organ origin was 15.2 and 16.3% in elderly group, and 12.7 and 3.9% in younger group. No differences in mean number of dissected lymph nodes and pathological curability were observed between the groups. Postoperative respiratory complications were observed with the incidence of 26% in elderly group and 23% in younger group, and mean days of respirator support were not different between the groups. Incidence of anastomotic leak was 9.7% in elderly group and 13.7% in younger group. In reconstruction methods, although retrosternal route with cervical anastomosis by using stomach was adopted with the highest incidence in both groups, posterior mediastinal route and intrathoracic anastomosis were adopted with higher incidence in elderly group (32.0 and 22.8%) compared with younger group (20.1 and 10.4%).

**Conclusion:** Esophagectomy for esophageal cancer is feasible in elderly patients with the curability and safety equal to esophagectomy in younger patients.

**Abstract ID: 0505**

Specific Field: **Esophagus**

**Mode of pres.: Poster Exhibition only**  
**ISW 2011 Session PE 237**

**Risk factors influencing pulmonary complications after curative radical esophagectomy for thoracic esophageal cancer**

M. Ohira [1], H. Tanaka [1], N. Kubo [1], K. Sakurai [1], K. Muguruma [1], M. Yashiro [1], Y. Yamashita [2], K. Hirakawa [1]

[1] Osaka City University Graduate School of Medicine, Osaka, Japan, [2] Osaka Municipal General Medical Center, Osaka, Japan

**Introduction:** Although the surgical procedure and pre, peri and postoperative management for thoracic esophageal surgery has been developed, pulmonary complication, which may be fatal, is reported to be about 30%. The aim of this study is to evaluate possible risk factors for pulmonary complication after thoracic esophagectomy and applied a multivariate analysis to determine which risk factors were important.

**Material and Methods:** From 2000 to 2007, curative esophagectomy through a right thoracotomy and laparotomy (including video-assisted thoracoscopic surgery(VATS) and hand assisted laparoscopic surgery (HALS)) with gastric tube reconstruction was performed in 174 patients with thoracic esophageal cancer. Patients were divided into two groups as follows; Group I: 37 patients with pulmonary complication after operation, Group II: 137 patients without pulmonary complication. Various kinds of preoperative and operative factors which might influence to pulmonary complications were studied.

**Results:** Among the preoperative variables, age of the patient and presence of diabetes mellitus were significant factors ( $P = 0.010$  and  $P = 0.044$ , respectively). Patient's preoperative nutritional status, respiratory function and neoadjuvant therapy had no influence on pulmonary complications. Among the operative factors, patients who treated with HALS (i.e. treated with small laparotomy) in Group II were more than in Group I ( $P = 0.011$ ). The operation time and the amount of intraoperative blood loss in Group II were significantly less than in Group I.  $P$  values of these two factors were 0.011 and 0.002, respectively. Multivariate analysis of these factors identified three as significant, namely age of the patient, method of laparotomy (open vs. HALS) and operation time. Furthermore, after induction of preoperative physical training for respiration by nurses from 2004, pulmonary complications decreased significantly ( $P = 0.028$ ).

**Conclusion:** It is concluded that various kinds of factors are related to pulmonary complications after esophagectomy for thoracic esophageal cancer. Especially, age of the patients, length of the laparotomy and operation time are the most important factors. Furthermore, preoperative respiratory physical training is useful to prevent pulmonary complications.

**Abstract ID: 0506**

Specific Field: **Esophagus**

**Mode of pres.: Poster Exhibition only**  
**ISW 2011 Session PE 238**

**Prophylactic effect of cefazolin administered according to the standardized protocol on SSI in esophageal cancer surgery**

H. Hino, H. Fujiwara, A. Shiozaki, N. Shime, S. Komatsu, D. Ichikawa, K. Okamoto, E. Otsuji

Kyoto Prefectural University of Medicine, Kyoto, Japan

**Introduction:** Optimal selection or administration method of prophylactic antibiotics against surgical site infection (SSI) has not been

established in surgery for esophageal cancer. In our institution, Cefazolin (CEZ) is administered for prophylaxis against SSI according to the standardized protocol. The aim of this study was to clarify the validity of this protocol focusing on the relationship between blood concentrations of CEZ and pathogen of SSI.

**Material and Methods:** CEZ at a dose of 2.0 g was intravenously administered in drip infusion (DIV) at 9:00, 30 min before start of operation (OP), followed by 5 times administrations at a dose of 1.0 g every 6 h until 15:00 of postoperative day 1 (POD1). Blood concentrations of CEZ were measured in 16 patients among 81 patients with esophageal cancer who underwent esophagectomy between June 2009 and November 2010, at Kyoto Prefectural University of Medicine hospital. Blood concentrations were measured with high sensitive liquid chromatography at 5 time points; start of OP, 15:00 (before second DIV), end of OP, 7:00 and 9:00 (before fifth DIV) of POD1. CEZ concentrations were measured in total of protein-bound and unbound forms, and those in blood samples at 9:00 of POD1 were also measured for protein-unbound free form. Relationship between pathogenic bacteria of SSI and blood concentrations of CEZ was evaluated.

**Results:** Patients consisted of 15 males and 1 female with age of  $63 \pm 8$  years and body weight of  $61 \pm 13$  kg. OP times were  $7.0 \pm 1.0$  h and blood loss was  $405 \pm 183$  g. Blood concentrations of CEZ ( $\mu\text{g/ml}$ ) were  $307.2 \pm 63.7$  at start of OP,  $44.0 \pm 15.9$  at 15:00,  $65.5 \pm 30.0$  at the end of OP,  $44.4 \pm 19.6$  and  $22.0 \pm 9.4$  at 7:00 and 9:00 of POD1, respectively, and those of free CEZ at 9:00 of POD1 were  $4.9 \pm 2.0$  with protein bound ratio of 77.5%. In all cases, concentrations of free CEZ were above 2.0  $\mu\text{g/ml}$ . SSI occurred in 8 wounds of 6 patients (3 cervical and 5 abdominal wounds) and all cervical and 1 of abdominal SSI were deep SSI attributable to anastomotic leak. Pathogens of superficial SSI were Methicillin-resistant *Staphylococcus epidermidis*, *Serratia marcescens*, *Candida albicans*.

**Conclusion:** Blood concentrations of free CEZ were maintained with the levels higher than 0.5  $\mu\text{g/ml}$  corresponding to MIC 90% of CEZ for MSSA, indicating that our protocol may be valid to prevent superficial SSI.

**Abstract ID: 0507**                      Specific Field: **Esophagus**

**Mode of pres.: Poster Exhibition only**  
**ISW 2011 Session PE 239**

**Single incisional laparoscopic jejunal flap harvesting for the reconstruction following laryngo-pharyngo-esophagectomy**

H. Makino [1], N. Hagiwara [2], S. Matsumoto [2], T. Nomura [2], M. Nakamizo [2], K. Yokoshima [2], M. Miyashita [2], E. Uchida [2]

[1] Nippon Medical School, Japan, [2] Nippon Medical School, Tokyo, Japan

**Introduction:** We describe a minimally invasive method, single incisional laparoscopic jejunal flap harvesting to reduce the size and the pain of the wound. The jejunal free flap is a standard technique in the reconstruction of complex defects of the head and neck following laryngo-pharyngo-esophagectomy. Laryngo-pharyngo-esophagectomy is performed in the neck, but harvesting of the jejunal flap is associated with ileus, abdominal wound infection and pain, pneumonia by vomiting. Conventional harvesting of the jejunal flap is generally obtained by the open laparotomy, partial jejunal resection is sometimes more invasive for the patient.

**Material and Methods:** We everted the umbilical depression and made the 2.5 cm long skin incision of the umbilicus at the mid-line. Three 5 mm trocars were introduced intraperitoneally through each finger of a surgical glove attached to the wound protector, which was applied to a periumbilical incision. A 5-mm 30° scope, which occupies less space in the port, is introduced through a trocar, and the

abdomen is inspected. The ligament of Treitz is located by tracing the small bowel. A satisfactory portion of the jejunum with its corresponding feeding vessel is selected (approximately 30 cm from the ligament of Treitz) and withdrawn using the 2 instruments through the ports from the abdomen to the extracorporeal site. Approximately 20–30 cm long segment of jejunum is identified for harvest. Endoscopic gastrointestinal anastomosis staplers are used to section the jejunal segment, and the vascular pedicle is ligated and clipping. The complete jejunal segment is passed to the neck for inset and revascularization.

**Results:** This procedure was attempted in 3 patients (mean age 70.5 years) with no intra- or post-operative complication from 2010. All harvests were captured laparoscopically. Only one case was recaptured because the jejuna flap was short. The average operative time for the abdominal portion of the procedure was 146 min and estimated blood loss was nearly 0 ml.

**Conclusion:** To shorten the operative time only capturing the jejunum and inspection in the abdominal cavity were performed under laparoscopy. We conclude that this new technique is minimally invasive way to harvest jejunal flaps for reconstructing in the present time.

**Abstract ID: 0508**                      Specific Field: **Esophagus**

**Mode of pres.: Poster Exhibition only**  
**ISW 2011 Session PE 240**

**A respiratory rehabilitation program reduces pulmonary complications after esophagectomy for thoracic esophageal cancer**

H. Matsushita, H. Shimizu

Tochigi Cancer Center, Utsunomiya, Japan

**Introduction:** Background: Pulmonary complications are one of the most common complications after esophagectomy for thoracic esophageal cancer. To reduce the pulmonary complications, we introduced a pulmonary rehabilitation program before and after operation since December 2008. Aim: The purpose of this study was to determine the efficacy of this rehabilitation program.

**Material and Methods:** A total of 66 patients with esophageal cancer were enrolled. All patients underwent esophagectomy at Tochigi Cancer Center, Utsunomiya, Japan from April 2007 to April 2010. The median age of the patients was 68.5 years (range, 53–87 years). The rehabilitation program was conducted by a physical therapist, intensive care unit (ICU) nurse, attending doctor, and dentist. The program included guidance on prohibition of smoking, oral cavity care, incentive spirometry, walking from postoperative day 1, and swallowing rehabilitation. We define atelectasis, pneumonia and intubation of minitracs as pulmonary complication. We compared the frequency of atelectasis, pneumonia, intubation of minitracs, and pulmonary complications in 2 groups consisting of patients who had or had not undergone rehabilitation. Statistical Analysis: Fisher's exact test was used to compare all proportions. All reported P values were 2-sided. A value of  $P < 0.05$  was considered statistically significant.

**Results:** The number of patients with atelectasis, pneumonia, intubation of minitracs, and pulmonary complications in the no rehabilitation group was 9 (25%), 4 (11%), and 11 (14%), respectively, and these numbers in the rehabilitation group were 2 (7%), 2 (7%), and 0 (0%), respectively. The frequency of pulmonary complication was significantly higher in the group without rehabilitation ( $P = 0.028$ )

**Conclusion:** Respiratory rehabilitation program reduces the risk of pulmonary complications after esophagectomy for thoracic esophageal cancer.

**Abstract ID: 0509**Specific Field: **Esophagus****Mode of pres.: Poster Exhibition only**  
**ISW 2011 Session PE 241****Pneumomediastinum method for esophageal cancer**

A. Shiozaki, H. Fujiwara, S. Komatsu, D. Ichikawa, K. Okamoto, T. Ochiai, Y. Kokuba, E. Otsuji

Division of Digestive Surgery, Department of Surgery, Kyoto Prefectural University of Medicine, Kyoto, Japan

**Introduction:** Although progresses of surgical technique and post-operative management have improved the treatment outcome of esophageal cancer resection, respiratory morbidity is still the most frequent complication after esophagectomy. To avoid respiratory complication, it is important to reduce the intrathoracic operative time. We performed esophagectomy by using pneumomediastinum (PM) method for patients with esophageal cancer.

**Material and Methods:** Patients: From 2009 to 2010, 22 patients with esophageal cancer underwent subtotal esophagectomy combined with gastric tube reconstruction via a retrosternal route by using PM method. Their treatment outcome was compared with 33 patients performed same resection and reconstruction without PM method in the same period. Surgical technique: In the supine position, upper abdominal incision (70 mm) was made, and Lap Discs (regular) was set. Three 12 mm ports were inserted in both flanks and left hypochondrium. One 5 mm port for videoscope was inserted in lower abdomen. After the division of greater omentum and gastrosplenic ligament by hand assisted laparoscopic surgery, esophageal hiatus was divided and carbon dioxide was induced to mediastinum. The abruption of distal esophagus was performed with EnSeal and blunt tip dissector up to the level of the tracheal bifurcation. Thoracic paraaortic and left pulmonary ligament lymphnodes (LNs) were dissected. After the division of the abdominal esophagus, cervical LNs resection was performed. After that, reconstruction was performed via retrosternal route with the gastric tube. Finally, small thoracotomy was made, and the resection of thoracic esophagus was performed with upper and middle mediastinal LNs dissection.

**Results:** Total operative time (with PM:  $422 \pm 35$  m/without PM:  $414 \pm 66$  m) and total number of resected LNs (with PM:  $48 \pm 30$ /without PM:  $44 \pm 23$ ) were not different between two groups. Intrathoracic operative time (with PM:  $61 \pm 17$  m/without PM:  $138 \pm 19$  m) and duration of thoracic drainage (with PM:  $6.0 \pm 2.8$  days/without PM:  $9.0 \pm 3.3$  days) were significantly shortened by PM method. Total operative bleeding (with PM:  $326 \pm 146$  ml/without PM:  $426 \pm 279$  ml) and percentage of post-operative respiratory complication (with PM: 18.2%/without PM: 30.3%) tended to be reduced by PM method.

**Conclusion:** Our surgical procedure, esophagectomy by using PM method, drastically shortened the intrathoracic operative time and decreased the postoperative respiratory complication.

**Abstract ID: 0510**Specific Field: **Esophagus****Mode of pres.: Poster Exhibition only**  
**ISW 2011 Session PE 242****Successful laparoscopy assisted esophageal bypass operation for esophagobronchial fistula following migration of self-expandable metallic esophageal stent: a case report**

T. Matsutani [1], H. Yoshida [1], H. Maruyama [1], S. Suzuki [1], T. Yokoyama [1], A. Matsushita [1], A. Hirakata [1], E. Uchida [2]

[1] Department of Surgery, Nippon Medical School Tama-Nagayama Hospital, Tokyo, Japan, [2] Department of Surgery, Nippon Medical School, Tokyo, Japan

**Introduction:** We introduce a laparoscopic method to create an esophageal bypass operation in a patient with esophagobronchial fistula for advanced esophageal cancer.

**Results:** Case report: A 73-year-old Japanese man complaining of cough and bloody sputum by repeated aspiration pneumonia was referred to our hospital for the treatment of an esophagobronchial fistula. An upper gastrointestinal endoscopy and computed tomography scan of the chest revealed fistulous communication between left main bronchus and esophagus. Histopathologic findings of biopsy specimens confirmed well differentiated squamous cell carcinoma, and the clinical tumor staging was stage IVa. He underwent the endoscopic implantation of a self-expandable metallic covered stent implantation at the esophagus, and received 3 courses of chemotherapy of 5-fluorouracil, docetaxel plus cisplatin. A clinical evaluation was stable disease by the following endoscopic and radiographic examinations. On five months after stent implantation, he was readmitted to our hospital with the complaint of cough, we considered to increase the size of esophagobronchial fistula by tumor growth. Then he underwent endoscopic self-expandable metallic covered bronchial stent implantation in the left main bronchus. However, esophageal stent migrated to the stomach. We adopted less-invasive esophageal bypass surgery using laparoscopy rather than traditional method. In briefly, a laparoscopy assisted gastric mobilization was performed and a gastric tube was made as open method by the small abdominal incision. The esophagus was divided at the neck and abdomen, and proximal stump was closed. Laparoscopy assisted esophagojejunostomy was performed according to the method of Roux-en-Y anastomosis. Esophagogastrostomy was performed at the neck where the gastric tube was lifted up through the retrosternal route. The postoperative course has been uneventful. The patient was discharge from our hospital on postoperative 10 days. He has survived without repeated any sigh of aspiration pneumonia for 3 months after operation.

**Conclusion:** We consider this minimally invasive procedure as an available treatment for far-advanced esophageal carcinoma in the case of failure by the conservative therapy.

**Abstract ID: 0511**Specific Field: **Esophagus****Mode of pres.: Poster Exhibition only**  
**ISW 2011 Session PE 243****Pneumomediastinum method for resection of esophageal duplication cyst**

A. Shiozaki, H. Fujiwara, S. Komatsu, D. Ichikawa, K. Okamoto, T. Ochiai, Y. Kokuba, E. Otsuji

Division of Digestive Surgery, Department of Surgery, Kyoto Prefectural University of Medicine, Kyoto, Japan

**Introduction:** Esophageal duplication cyst is a rare congenital esophageal disorder. Although the resection is accomplished via thoracotomy traditionally, a minimally invasive approach is able to be considered recently to avoid the long hospital stay. We started to use novel surgical technique, pneumomediastinum method for esophageal tumor from 2009, and hitherto, more than 30 patients were treated by this technique. By using this method, we can perform the mediastinal surgery via abdominal approach and decrease the surgical stress. Here, we report a case with esophageal duplication cyst successfully treated by using pneumomediastinum method.

**Material and Methods:** Patient: The patient was a 68-year old male who had previously underwent renal transplantation (5 years ago). At that time, a computed tomography scan showed a tumor in the lower thoracic esophagus and the esophageal duplication cyst was suspected. During the follow-up, the tumor size increased gradually and became 3731 mm in size. Therefore, we performed the resection of esophageal duplication cyst by using pneumomediastinum method.

**Results:** Surgical technique; In the supine position, upper abdominal incision (70 mm) was made, and Lap Discs was set and used for hand assistance. Three 12 mm ports were inserted in both flanks and left hypochondrium. One 5 mm port for videoscope was inserted in lower abdomen. By hand assisted laparoscopic surgery, esophageal hiatus was divided and carbon dioxide was induced to mediastinum. After the abruption of distal esophagus with EnSeal and blunt tip dissector, the esophageal duplication cyst with smooth surface was detected. We exfoliated it carefully from surrounding tissues and extracted it via abdominal approach without injuring adventitia of esophagus. The operative time was 245 min, and 50 ml of intra-operative bleeding was observed. Postoperative course; The patient was discharged at 8 days after the operation without complications. Histopathological examination revealed duplication cyst of the esophagus.

**Conclusion:** Our surgical procedure, pneumomediastinum method, could make it possible to resect esophageal duplication cyst via abdominal approach and decrease surgical stress.

**Abstract ID: 0512**                      Specific Field: **Esophagus**

**Mode of pres.: Poster Exhibition only**  
**ISW 2011 Session PE 244**

**Radical esophageal resection with jejunal construction for advanced esophageal squamous cell carcinoma after total gastrectomy with pancreatic fistula-salvage surgery for re-growth of the tumor after definitive chemoradiation**

Y. Oizumi, K. Yamashita, N. Katada, M. Nemoto, T. Shibata, H. Mieno, S. Sakuramoto, M. Watanabe

Kitasato University School of Medicine, Sagamihara, Japan

**Introduction:** We herein report a patient who suffered from esophageal squamous cell carcinoma (ESCC) after total gastrectomy with reconstruction of jejunal pouch, accompanied by a complication of pancreatic fistula.

**Material and Methods:** The patient was diagnosed as type 3 ESCC in Lt esophagus by endoscopic examination in February, 210 15 years after total gastrectomy with reconstruction of jejunal pouch, accompanied by a complication of pancreatic fistula. Lymph node swellings were suspected in cervical para-esophageal and peri-gastric areas (7th UICC cT3N1, cStage IIIA) without distant metastasis. After careful consideration of impossible construction due to the status after pancreatic fistula, he selected dCRT (induction chemotherapy of DCF 3 course plus dCRT by RTOG regimens), and CR was once obtained. However, during the follow-up course in one year, re-growth of the primary tumors was found by endoscopy without metastasis, and additional treatment of DCF failed to reduce the tumor size. He thereafter consulted our unit for salvage surgery. Performed operation was subtotal esophagectomy plus resection of the jejunal pouch with construction of elevated jejunum with supercharge of jejunal vessels (J-4) with internal thoracic vessels and construction of Y-limb, and jejunostomy with jejunal tube for feeding. Postoperative diagnosis was the followings: SqCC mod.diff., LtAe, type5b, 1.3 cm × 2 cm, pT2, INF-b, ly0, v2, pIM0, pPM0, pDM0, pRM0, pN(+), CRT-Grade2, p53 exon5: shift band(+), K-RAS wild type, DPC-4 wild

type. In postoperative day 13, leakage was found from the cervical drain, and NPO results in no discharge in the drainage fistula soon after.

**Conclusion:** We experienced a patient who could undergo subtotal esophagectomy with construction of the elevated jejunum, accompanied by supercharge of J-4 vessels and internal thoracic vessels that had undergone total gastrectomy with complication of pancreatic fistula 15 years before this operation. This operation is a salvage operation after CR was obtained by dCRT with consideration of impossible reconstruction. Jejunal reconstruction is therefore alternate and effective for the ESCC patients who could not use either stomach or colon as a construction organ.

**Abstract ID: 0513**                      Specific Field: **Esophagus**

**Mode of pres.: Poster Exhibition only**  
**ISW 2011 Session PE 245**

**Problems of esophageal cancer treatment in the southern remote islands in Japan**

T. Owaki [1], Y. Nerome [1], S. Natsugoe [2]

[1] Education Center for Doctors in Remote Islands and Rural Areas, Kagoshima, Japan, [2] Gastrointestinal Surgery, Kagoshima University Hospital, Kagoshima, Japan

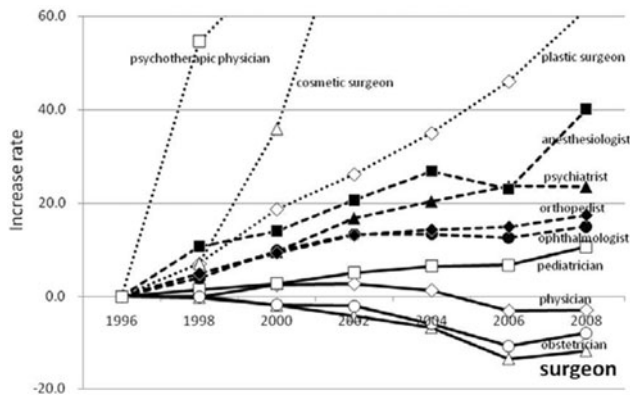
**Introduction:** More than 180,000 people (the national first place) live in Kagoshima located the south of Japan having 28 manned remote islands (the national first place). The patients from these islands gather in this hospital which is the only university hospital of the prefecture. Whereas esophageal cancer requires extensive treatment including the combined modality therapy. For the extraction of the geographical and economical problem of patients with esophageal cancer to live in the islands part, we investigated the trend.

**Material and Methods:** Among 2,358 patients admitted to our department from 2007 through 2009, 158 patients with islands residence (6.7%) and 24 patients with esophageal disease (6.5% of esophageal disease hospitalization) were targeted. We investigated a residence place, the medical treatment contents after the discharge during the hospitalization, changing hospital.

**Results:** Patient with achalasia 1, patients with esophageal cancer 23. For the hospitalized medical treatment method, surgery nine, EMR/ESD were two, chemoradiotherapy (CRT) two, esophagus stenting one, 10 patients who changed hospitals after an orientation. 23 patients change hospitals, and one patient leaves the hospital at home. As for the medical treatment after the discharge, 11 patients underwent CRT. Eight people of those are treated in the Kagoshima city. Two people are treated in Amami Oshima where the only place CRT is available in remote islands in Kagoshima prefecture. One person was treated in Osaka. Three people received the chemotherapy and performed all it in thier island. The mean annual income was 50% of Kagoshima average, national mean 38% in a worst islands. The isolated island that CRT is available for is limited to a lot of inoperable cases, and the patients with islands except Amami oshima are forced to a long stay in Kagoshima city. The chemotherapy is possible in remote islands, and the medical treatment in the hometown is provided. Except benign disease, mild medical care, the periodical consultation at the university is required, and the burden of the economic time is large.

**Conclusion:** For the treatment of patients with esophageal disease resident in remote islands, there is a geographical and economic burden, and it influences the choice of the therapy.





**Figure** Increase rate of the number of physicians according to the diagnosis and treatment department

**Abstract ID: 0514**

Specific Field: **Esophagus**

**Mode of pres.: Poster Exhibition only**  
**ISW 2011 Session PE 246**

**Fluorescence navigation with indocyanine green for detecting the site of chylothorax after esophagectomy: report of a case**

T. Matsutani [1], A. Hirakata [1], H. Maruyama [1], S. Suzuki [1], T. Yokoyama [1], M. Umakoshi [1], H. Yoshida [1], E. Uchida [2]

[1] Department of Surgery, Nippon Medical School Tama-Nagayama Hospital, Tokyo, Japan, [2] Department of Surgery, Nippon Medical School, Tokyo, Japan

**Introduction:** Chylothorax is a rare complication after an esophagectomy, but the intraoperative detection of the site of a chyle fistula is often difficult. We documents the use of imaging technique of indocyanine green (ICG) fluorescence lymphography for the intraoperative identification of the precise site of a chyle fistula after esophagectomy.

**Results:** Case report: A 70-year-old man was referred to the hospital for the management of a lower thoracic advanced esophageal squamous cell carcinoma. Computed tomography scans indicated thickened esophageal wall at the esophagus and a swollen lymph node in mid-thoracic esophageal region. The clinical tumor staging was stage III (T3N1M0). He received 1 courses of neoadjuvant chemotherapy of 5-fluorouracil, docetaxel plus cisplatin. A clinical evaluation was partial response by the following endoscopic and radiographic examinations. He underwent a thoracoscopy assisted sub-total esophagectomy with lymph node dissection in the prone position. The thoracic duct was resected in combination with the esophagus and the stump of the resected duct was clipped. On the postoperative day (POD) 5th, the more than 1,500 ml/day of drainage fluid through a chest tube turned milkywhite color, which thus confirmed the diagnosis of chylothorax. Conservative therapy with octeotide administration and thoracoscopy-assisted clipping of the thoracic on POD 10th duct failed to reduce chylorrhea. We decided to perform the open laparotomy on POD 28th. After exploration of the upper abdomen, a slowly increasing effusion in the retroabdominal space below the diaphragma was identified. However, the exact site of the lymph fistula could not be identified. On approximately 10 min after the injecting 1.5 ml of ICG (Diagnogreen 0.5%) subcutaneously at the bilateral inguinal region, the site of chyle leakage was confirmed using a near-infrared PDE camera system (Hamamatsu

Photonics). The root of thoracic duct was clipped successfully and easily at the right side of esophageal hiatus. The postoperative course was uneventful. The chyle leakage stopped completely.

**Conclusion:** The precise site of chyle leakage was successfully detected by the imaging technique of ICG fluorescence. Intraoperative ICG injecting has no adverse effects and should be considered as the treatment of option.

**Abstract ID: 0515**

Specific Field: **Esophagus**

**Mode of pres.: Poster Exhibition Only**  
**ISW 2011 Session PE 247**

**Clinical outcomes of thoracoscopic salvage esophagectomy for the cases with local failure after definitive chemoradiotherapy for esophageal cancer**

M. Takemura [1], K. Morimura [2], Y. Fujiwara [2], K. Yoshida [3]

[1] Hyogo College of Medicine, Nishinomiya, Japan, [2] Osaka City Juso Hospital, Osaka, Japan, [3] Hyogo College of Medicine, Japan

**Introduction:** Definitive chemoradiotherapy (CRT) is one of the treatment options available for locally advanced esophageal cancer. When definitive CRT fails to achieve local cancer control, salvage esophagectomy is only treatment that can offer a chance of long-term survival for patients. We have introduced salvage thoracoscopic esophagectomy after definitive CRT from January 2003. In this report, we examined clinical outcomes of thoracoscopic salvage esophagectomy for the patients with local failure after definitive CRT. **Material and Methods:** We reviewed 21 patients who were performed thoracoscopic salvage esophagectomy from January 2003 to December 2009. The intraoperative data, postoperative complications and survival rate were obtained from medical records in our hospital. **Results:** Convert to thoracotomy were needed in two cases because of pleural adhesion. The average of duration of operation and amount of blood loss was 333 min and 469 g, respectively. The most frequent postoperative complication was anastomotic leakage ( $n = 7$ , 33%). The pneumonia developed in two cases. None the case had tracheal necrosis or hospital morbidity. The recurrent disease was found in 11 cases, regional lymphnode in 7, hematogenous in 3 and disseminated disease in 1, respectively. One and 5 year survival rate was 89.5% and 53.7%, respectively. The prognosis of the cases with Stage IV or lymph node metastasis before CRT were significantly poor than the other cases.

**Conclusion:** The thoracoscopic salvage esophagectomy was safety and feasible operation. Although the rate of post-operative complications including anastomotic leakage is high, this procedure is the only established treatment for the selected patients with local failure after definitive CRT.

**Abstract ID: 0516**

Specific Field: **Esophagus**

**Mode of pres.: Poster Exhibition Only**  
**ISW 2011 Session PE 248**

**MDCT attenuation values between the tumor and aortic wall in response to induction therapy for esophageal cancer and its predictive value for aortic invasion**

H. Tsujimoto, T. Ichikura, S. Aiko, Y. Matsumoto, S. Ono, H. Mochizuki, J. Yamamoto, K. Hase

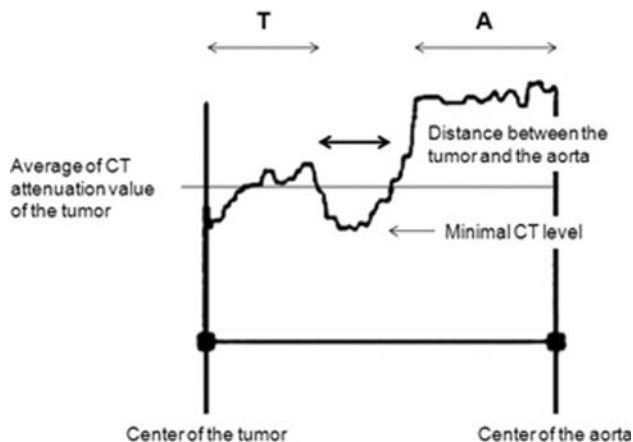
National Defense Medical College, Tokorozawa, Japan

**Introduction:** Despite remarkable advances in diagnostic modalities, preoperative assessment of pathological response and local tumor extent in esophageal cancer remains difficult. The purpose of this study is to evaluate the multidetector computed tomography (MDCT) attenuation value between the tumor and aorta in response to the induction therapy for esophageal cancer.

**Material and Methods:** MDCT attenuation values between the tumor and aorta, and the contact angle for the tumor and aorta (Picus' angle) were retrospectively evaluated in patients with esophageal cancer who underwent induction therapy in terms of predicting the pathological response, aortic invasion, and prognosis of esophageal cancer.

**Results:** The induction therapy may increase the tumor-to-aorta distance and decrease the maximum tumor size and Picus' angle. When the tumor-to-aorta cutoff value was set at less than 1.3 mm, the accuracy of this distance for aortic invasion was 94.6%. In terms of this distance, 14 of 19 patients with a tumor-to-aorta distance lesser than 1.3 mm before the induction therapy had a distance higher than 1.3 mm after therapy and underwent curative resection. Patients with a tumor-to-aorta distance lesser than 1.3 mm after the induction therapy had poor prognoses as compared to those with higher than 1.3 mm.

**Conclusions:** The assessment of the MDCT attenuation value between the esophageal tumor and the aorta is simple and can objectively assess the response to the induction therapy and aortic invasion in esophageal cancer. This method should be applied to predict the response to the induction therapy and to prevent unnecessary surgery in patients with tumors involving the aorta.



**Figure:** Measurement of the tumor to aorta distance

**Abstract ID: 0517**

Specific Field: **Esophagus**

**Mode of pres.: Poster Exhibition Only**  
ISW 2011 Session PE 250

#### Clinical utility of FDG-PET/CT for the response evaluation of neoadjuvant chemotherapy in patients with squamous cell carcinoma of the thoracic esophagus

K. Koyanagi [1], S. Tabuchi [1], K. Nagata [2], I. Koyama [1]

[1] Department of Gastroenterological Surgery, Saitama Medical University, International Medical Center, Hidaka, Japan, [2] Department of Pathology, Saitama Medical University, International Medical Center, Hidaka, Japan

**Introduction:** Neoadjuvant therapy is now widely adopted for localized esophageal cancers, however, the method and timing of the

response evaluation has been still debated. The aim of the study was to assess the usefulness of FDG-PET/CT (PET) for the evaluation of the response to neoadjuvant chemotherapy (NAC) in patients with thoracic esophageal squamous cell carcinoma (ESCC).

**Material and Methods:** The 17 patients with advanced ESCC received NAC in our institution between 2008 and 2010. There were 2 and 15 patients in clinical Stage IIB and III, respectively. NAC regimen was based on the JCOG9907 trial; preoperative two courses of chemotherapy of cisplatin (80 mg/m<sup>2</sup>, div day 1) plus 5-FU (800 mg/m<sup>2</sup>, ci day 1–5). Individual patient was checked by endoscopic examination and CT scan after each course of chemotherapy as response evaluation, and also checked by PET after 2 courses of chemotherapy. 14 patients underwent an esophagectomy with 3 fields lymph node dissection, and in other 3 patients, following surgery was not selected because of PD after NAC. Changes in SUV uptake of primary tumors and lymph nodes (LN; total of 22 areas) during NAC were compared with RECIST, CT scan, and pathological findings.

**Results:** The 7 patients with decreasing SUV uptake of primary tumors after NAC were diagnosed as PR under the RECIST criteria and the pathological evaluation confirmed the considerable effects of NAC. In other 10 patients diagnosed as SD (*n* = 6) and PD (*n* = 4), SUV uptake of primary tumors was no change or increasing during NAC. Of the 10 patients with SD and PD, 7 underwent an operation and the pathological examination showed the limited effects of NAC. There were 22 LN areas with SUV uptake before NAC. Of 9 LN in which the SUV uptake was disappeared after NAC, CT scan also showed a disappearance of LN in 4 areas and the pathological examination showed no metastatic tumors in 6 LN. In other 13 LN that had SUV uptake after NAC, CT scan detected LN in all areas and the metastatic tumors were found in almost all LN histopathologically, except two.

**Conclusion:** PET may be useful to predict the therapeutic efficacy of NAC in the patients with ESCC.

**Abstract ID: 0518**

Specific Field: **Esophagus**

**Mode of pres.: Poster Exhibition Only**  
ISW 2011 Session PE 251

#### A case of segmental arterial mediolysis occurred during neoadjuvant chemotherapy for advanced esophageal cancer

T. Arita, H. Fujiwara, A. Shiozaki, S. Komatsu, D. Ichikawa, K. Okamoto, T. Ochiai, E. Otsuji

Kyoto Prefectural University of Medicine, Kyoto, Japan

**Introduction:** Segmental arterial mediolysis (SAM) is a rare nonarteriosclerotic, noninflammatory vascular disease of unknown origin that involves the visceral arteries of the abdomen, frequently found triggered by rupture of aneurysm. SAM occurs in the elderly with no gender difference and has a mortality rate of 50%. Pathologically, the lytic process is preceded by cytoplasmic vacuolar degeneration of smooth muscle cell. Further changes include fibrin deposition at the adventitial-medial junction and granulation tissue in areas of partial mediolysis. Dissecting aneurysms and hematomas frequently develop following medial lysis.

**Material and Methods:** We report a case of 70-year-old man with sudden and severe abdominal pain on the last day of neoadjuvant chemotherapy (5-FU + CDDP) for advanced esophageal cancer (T4aN1M0, stage IIIc).

**Results:** Abdominal CT showed mesenteric hemorrhage of ascending and transverse colon. Angiographic examination revealed caliber irregularities and multiple aneurysms of the celiac artery, superior mesenteric artery and inferior mesenteric artery, while no hemorrhage was detected in angiography. Laboratory screening for collagen

disease (ANA, MPO-ANCA, PR3-ANCA) was negative, therefore SAM was diagnosed comprehensively. Abdominal symptom disappeared without aggressive medical treatment. One month later, follow-up angiography showed that findings of vascular lesion remained, therefore, we decided the operation for esophageal cancer was impossible because of perfusion of reconstruction organs. The patient underwent chemoradiation therapy, which brought partial response.

**Conclusion:** SAM occurred during chemotherapy in this case, but there were no reports which referenced the relationship between SAM and chemotherapy. On the other hand, some reports mentioned vanish of SAM was observed on several months or years after occurrence. Cautious examination of vascular lesion and consideration of therapeutic strategy for esophageal cancer were needed in the present case.

**Abstract ID: 0519**                      Specific Field: **Esophagus**

**Mode of pres.: Poster Exhibition Only**  
**ISW 2011 Session E 252**

**Multimodal treatment strategy and treatment outcome of cT4 esophageal cancer**

H. Fujiwara, A. Shiozaki, S. Komatsu, D. Ichikawa, K. Okamoto, T. Ochiai, Y. Kokuba, E. Otsuji

Kyoto Prefectural University of Medicine, Kyoto, Japan

**Introduction:** In the multimodal treatment of cT4 esophageal cancer at our institution, chemoradiotherapy (CRT) was adopted as induction therapy followed by surgery (OP) or definitive CRT until 2007, and from 2008 onward, chemotherapy (CX) has been adopted as induction therapy followed by OP or CRT. The aim of this study was to clarify the prognostic significance of CX/CRT as induction therapy and CRT/OP as local therapy.

**Material and Methods:** Eighty-five patients with cT4 esophageal squamous cell carcinoma who underwent induction therapy followed by OP or CRT between 2000 and 2010, were analyzed in this study. Pretreatment characteristics of the patients were as follows; male/female: 72/13, median age: 64, and cStage III/IVa: 17/68. Treatment factors were as follows; Induction therapy: CRT/CX: 63/22, Local therapy: definitive CRT/OP following induction CRT/OP following induction CX: 26/32/12, Induction CX: standard FP/others: 19/3. Overall survival (OS) of induction CRT was compared between definitive CRT and OP, and also compared with OS of induction CX.

**Results:** OS (median) of definitive CRT was longer than OS of induction CRT followed by OP (16.7 M vs. 12.3 M,  $P = 0.17$ ). In case of induction CRT followed by OP, OS of curative resection was longer than OS of non-curative resection (14.5 M vs. 8.8 M,  $P = 0.05$ ). In case of definitive CRT, when OS was compared according to the clinical response to CRT at 40 Gy, OS of responders was longer than non-responders (19.0 M vs. 13.6 M,  $P = 0.34$ ). Among CRT responders, OS of definitive CRT was longer than OS of induction CRT followed by OP (19.0 M vs. 12.5 M,  $P = 0.12$ ), whereas, among CRT non-responders, OS between definitive CRT and induction CRT followed by OP was not different (13.6 M vs. 10.8 M). In addition, OS of induction CX was not different from OS of induction CRT (15.0 M vs. 14.5 M,  $P = 0.67$ ). OS was not different between induction CX followed by OP and induction CX followed by definitive CRT, and between definitive CRT alone and definitive CRT following CX.

**Conclusion:** In case without induction CX, definitive CRT has superior survival benefit to induction CRT followed by OP. In case with induction CX, it is suggested that OP have survival benefit not inferior to definitive CRT, and induction CX does not compromise subsequent definitive CRT.

**Abstract ID: 0520**                      Specific Field: **Esophagus**

**Mode of pres.: Poster Exhibition Only**  
**ISW 2011 Session PE 253**

**The human epidermal growth factor receptor (HER) family as the predictor of sensitivity to chemotherapy and prognosis in esophageal squamous cell carcinoma**

Y. Yamamoto, A. Tangoku, H. Yamai, T. Minato, Y. Furukita, H. Takechi, J. Seike

Department of Thoracic, Endocrine Surgery and Oncology, Institute of Health Bioscience, The University of Tokushima Graduate School, Tokushima City, Japan

**Introduction:** HER family, Ki-67 and p53 expression are predictors of sensitivity to treatments and prognosis in several malignancies. But there are few reports about chemo-sensitivity of esophageal squamous cell carcinoma (ESCC).

**Material and Methods:** From January 2004 and December 2008, 47 patients with ESCC who received initial combination chemotherapy with docetaxel, 5-fluorouracil and cisplatin (DFP therapy) were investigated. The expressions of EGFR, HER2, HER3, Ki-67 and p53 were investigated immunohistochemically with biopsied specimen before the treatment, and were compared with sensitivity to DFP therapy and their prognosis.

**Results:** EGFR, HER2, HER3, Ki-67 and p53 expressions were 74.5, 57.4, 59.6, 46.8 and 59.6%. The clinical response rate was 63.8%. EGFR, HER2 and HER3 expressions correlated with clinical response significantly ( $P < 0.001$ ,  $=0.021$ ,  $0.011$ ). EGFR and clinical response were significant favorable prognostic factors in univariate analysis (relative risk 0.33, 0.10,  $P = 0.010$ ,  $<0.001$ ). In pretreatment factors, independent prognostic factor was EGFR (relative risk 0.34,  $P = 0.019$ ) in multivariate analysis. HER2 and HER3 expression were not significant but tended to be favorable prognosis in univariate analysis (relative risk 0.53, 0.61). Ki-67 and p53 did not correlate with clinical response and prognosis.

**Conclusion:** EGFR was a significant predictive factor for prognosis and response of DFP therapy and the role of HER2 and HER3 were considered to be similar to EGFR. ESCC patients with HER family positive should be treated by systemic chemotherapy and molecular target treatment. HER family as the predictor of esophageal squamous cell carcinoma.

**Abstract ID: 0521**                      Specific Field: **Esophagus**

**Mode of pres.: Poster Exhibition only**  
**ISW 2011 Session PE 254**

**Short-term treatment outcome of preoperative chemotherapy for non-T4 cStage II/III esophageal cancer**

H. Fujiwara, A. Shiozaki, S. Komatsu, D. Ichikawa, K. Okamoto, T. Ochiai, Y. Kokuba, E. Otsuji

Kyoto Prefectural University of Medicine, Kyoto, Japan

**Introduction:** In the multimodal treatment of non-T4 advanced esophageal cancer at our institution, postoperative chemotherapy (CX) or preoperative chemoradiotherapy (CRT) in case of suspicious T4 tumor, was adopted as adjuvant therapy for surgery until 2007, and from 2008 onward, preoperative CX has been adopted according to the results of JCOG9907. The aim of this study was to evaluate short-term treatment outcome of preoperative CX in patients with resectable advanced esophageal cancer in comparison with postoperative CX and preoperative CRT.

**Material and Methods:** 145 patients with non-T4 cStage II/III squamous cell carcinoma of the thoracic esophagus who underwent esophagectomy between 2000 and 2010, were analyzed in this study. The patients were divided into 3 groups according to the types of adjuvant therapy; postoperative CX (Post-CX), preoperative CX (Pre-CX), and preoperative CRT (Pre-CRT), and overall survival (OS) and progression-free survival (PFS) were compared among the 3 groups.

**Results:** Post-CX group consisted of 88 patients (cStage II/III: 38/50). Curative resection rates were 97.4% and 70% in Stage II and III, respectively. Pre-CX group consisted of 40 patients (cStage II/III: 10/30). Curative resection rates were 90% and 70% in Stage II and III, respectively. Pre-CRT group consisted of 17 patients (cStage II/III: 2/15). Curative resection rates were 100% and 86.7% in Stage II and III, respectively. In cStage II, 2-year OS rates of Post-CX and Pre-CX groups were 84% and 100%, respectively. In cStage III, 2-year OS rates of Post-CX, Pre-CX and Pre-CRT groups were 45.8%, 65.8% and 46.7%, respectively. Pre-CX group had higher OS compared with other groups, although not significant. In addition, 2-year PFS rates of Post-CX and Pre-CX groups were 60.4% and 46.7%, respectively, in cStage II, and 26.2% and 21.2%, respectively, in cStage III. No significant difference in PFS was observed between Pre-CX and Post-CX groups.

**Conclusion:** Despite the short-term observation, preoperative CX, as adjuvant therapy for surgery, is superior to postoperative CX and preoperative CRT with regard to the improvement of OS. Survival benefit of preoperative CX should be elucidated by case accumulation with long-term observation.

**Abstract ID: 0522**

**Specific Field: Esophagus**

**Mode of pres.: Poster Exhibition Only**  
**ISW 2011 Session PE 255**

**DWIBS positive nodes and negative of esophageal squamous cell cancer and the difference of postoperative outcome**

K. Shuto [1], H. Saito [2], T. Kono [2], T. Shiratori [2], Y. Akutsu [2], M. Uesato [2], H. Matsubara [2]

[1] Chiba University Graduate School of Medicine, Japan,  
[2] Frontier Surgery, Chiba University Graduate School of Medicine, Chiba, Japan

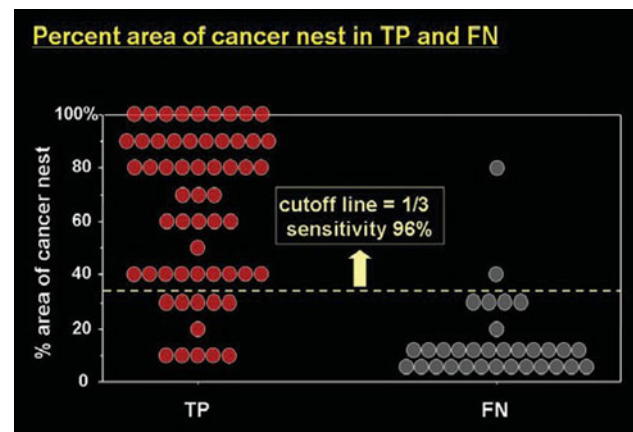
**Introduction:** In the patients of esophageal squamous cell cancer (eSCC), due to the introduction of preoperative CRT and extended three field lymphadenectomy, better results have been obtained with a prolonged 5-year survival rate over 40% recently in Japan. The purpose of this study is to evaluate the difference between true positive (TP) lymph nodes and false negative (FN) of esophageal cancer by diffusion-weighted MR Imaging (DWIBS) with histological findings and to compare the postoperative course.

**Material and Methods:** Eighty-five consecutive patients of esophageal squamous cell cancer who underwent radical esophagectomy with 3-field lymphadenectomy were enrolled. Images were acquired with following parameters: DWIBS, SENSE-STIR-EPI, TR/TE

10000/75 ms, b-values 0, 1000 s/mm<sup>2</sup>; T2WI, single-shot FSE, 3300/90 ms. Definitions as metastasis were determined using T2WI/DWIBS fused image. Dissected lymph nodes (LNs) were divided into regional LN groups according to the location. Following nodal statuses were evaluated: diameter, location, ADC value and percent area of the cancer nest in a node. We compared the difference between true positive nodes and negative with postoperative nodal recurrence.

**Results:** A total of 1079 LN groups were examined and 88 (8%) were proven metastasis. A significant difference between true positive and false negative was observed in nodal size (9.9 mm vs. 7.5,  $P = 0.013$ ), in ADCs (1.252 vs. 1.813,  $P < 0.0001$ ), and in percent area of the cancer nest (64% vs. 16%,  $P < 0.0001$ ). LNs occupied with the cancer cells over one-third area in the node, 96% were true positive. The incidence of postoperative nodal recurrence within 1 year was significantly higher in DWIBS positive patients than in negative (21% vs. 2%,  $P = 0.0039$ ).

**Conclusion:** The detectability of metastatic nodes was considered to depend on the density of cancer cells. Furthermore, patients with DWIBS positive metastatic LNs resulted in poor prognosis compared with DWIBS negative groups. In addition to N staging of esophageal cancer, DWIBS may be a valid modality to assume the malignant potential of metastatic lymph nodes and to predict early nodal recurrence after surgery.



**Figure:** Percent area of cancer nest in TP node and FN

**Abstract ID: 0523**

**Specific Field: Esophagus**

**Mode of pres.: Poster Exhibition Only**  
**ISW 2011 Session PE 256**

**Comparison between DWIBS and PET in preoperative N-staging of esophageal squamous cell cancer**

K. Shuto, T. Kono, H. Saito, K. Hayano, S. Imanishi, Y. Akutsu, H. Matsubara

Frontier Surgery, Chiba University Graduate School of Medicine, Chiba, Japan

**Introduction:** N-staging is essential in the strategy for determining the treatment of esophageal squamous cell cancer (eSCC). In preoperative clinical investigations, EUS, CT and PET are used for evaluation. However EUS is not always effective because of intraluminal tumor growth of esophageal cancer. Furthermore PET has been reported not being enough for predicting lymph node (LN) metastasis because of the widely ranges of sensitivity (8–90%). The



purpose of this study is to assess the detectability of metastatic lymph nodes (LNs) of esophageal cancer using diffusion weighted MR imaging (DWIBS) in comparison with PET.

**Material and Methods:** Forty-two consecutive patients of esophageal SCC were enrolled. All of the patients underwent radical esophagectomy with cervico-thoraco-abdominal lymphadenectomy. MR images were acquired with following parameters: T2-weighted, fast spin-echo, TR/TE 3300/90 ms; DWIBS, single shot echo planar sequence, TR/TE 10000/75 ms. The corresponding b-value were  $b = 0, 1000 \text{ s/mm}^2$ . PET imaging was performed using 370 MBq of F18-DG tracer. Definition as metastasis was made by hyperintensity nodes on T2-WI/DWI fused images and was made by  $\text{SUV} > 3$  on PET images. Surgically dissected LNs were divided into regional LN groups. We compared both imaging with nodal size and nodal location. If two or more metastatic nodes exist in one LN group, the maximum value was used for evaluation.

**Results:** A total of 490 LN groups were examined. Fifty-one (10%) were proven positive for metastasis (mean size, 8.3 mm). The sensitivity of DWIBS and PET were 71% and 53% with significant difference ( $P = 0.009$ ). The combination of DWIBS and PET yielded a better sensitivity (82%). No significant difference between true positive nodes and false negative was observed in nodal size in both imaging. In nodal location, the sensitivity of upper thoracic nodes of DWIBS and PET were 67% and 24% with significant difference ( $P = 0.005$ ).

**Conclusion:** Noninvasive DWIBS yielded a better predictive power than PET and may become one of the initial modalities to evaluate N-staging of esophageal cancer. When N staging is discussed, the nodal status of cancer cell density is not always estimated. This may be an informative research assessing detectable metastatic LNs and cancer density using by DWIBS.

Exam.	Histological Result (No. of LN groups)				Detection Rate (%)		
	Positive		Negative		Sens.	PPV	Accu.
	TP	FN	TN	FP			
DWIBS	36	19	420	15	71	65	93
PET	26	25	430	9	53	74	93
Both	42	9	412	27	82	61	92

Both = combination of DWIBS and PET  
Sens.= sensitivity, Accu.= accuracy

**Figure:** Detection rate of LN groups

**Abstract ID: 0524**

Specific Field: **Esophagus**

**Mode of pres.: Poster Exhibition Only**  
**ISW 2011 Session PE 257**

**Two-field lymphadenectomy may be enough to treat patients with cT1N0 squamous cell carcinoma of the thoracic esophagus**

S. Nakagawa, H. Yabusaki, A. Nashimoto, A. Matsuki, O. Tanaka  
Niigata Cancer Center Hospital, Niigata, Japan

**Introduction:** There has been controversy regarding surgical treatment, including extensive lymphadenectomy, for patients with cT1N0 carcinoma of the esophagus. The aim of this study was to evaluate the

results of esophagectomy with two-field (thoracic and abdominal) lymphadenectomy and also to attempt to elucidate an appropriate surgical strategy for cT1N0 squamous cell carcinoma (SCC) of the thoracic esophagus.

**Material and Methods:** Sixty-five patients with cT1N0 SCC of the thoracic esophagus who had been treated with esophagectomy and two-field lymphadenectomy without preoperative therapies were retrospectively reviewed.

**Results:** Among 65 tumors, 11 were clinically diagnosed as T1-mucosal (T1a) and 54 as T1-submucosal (T1b). The operative morbidity and in-hospital mortality rates were 48% and 2%, and the overall 1-, 3-, and 5-year survival rates were 99, 95, and 81%, respectively. Of the 65 tumors assessed pathologically, 19 (29%) were T1a, 40 (61%) were T1b, 5 (8%) were T2, and 1 (2%) were T3. Fifteen (23%) exhibited lymph node metastasis (LNM). The 1-, 3-, and 5-year survival rates for patients with LNM were 100, 85, and 66%, as compared with 98, 98, and 85%, respectively for patients without LNM ( $P = 0.13$ ). Nine (14%) patients had died of recurrent cancer. Two died of causes other than recurrence of cancer: one of malignant lymphoma, and one of heart failure.

**Conclusion:** Two-field lymphadenectomy may be enough to treat patients with cT1N0 carcinoma of thoracic esophagus because the postoperative outcome of patients underwent this procedure were by no means inferior to those underwent three field lymphadenectomy in the previous reports.

**Abstract ID: 0525**

Specific Field: **Esophagus**

**Mode of pres.: Poster Exhibition Only**  
**ISW 2011 Session PE 258**

**Therapeutic value of lymph node dissection in patients with cancer at the esophagogastric junction**

M. Niihara, H. Sato, Y. Tsubosa

Shizuoka Cancer Center, Sunto-gun, Shizuoka, Japan

**Introduction:** The optimal range of lymph node dissection has not been confirmed.

**Material and Methods:** Two hundred forty seven patients were enrolled for this study if they had cancer at esophagogastric junction that was deeper than submucosal layer. All patients had curative resection(R0) in our institution. We made a classification of anatomical locations on the basis of the definition of Siewert, regardless of histopathological type. Type I/II/III: 53/81/113 cases. The histopathological type, Squamous cell carcinoma/adenocarcinoma/adenosquamous carcinoma/ undifferentiated carcinoma/endocrine cell carcinoma/carcinosarcoma: 54/184/4/1/2/2 cases.

**Results:** Ninety seven patients had no lymph node metastasis and the 3-year survival rate of them was 93.5%. One hundred fifty patients had lymph node metastasis and the 3-year survival rate 73.8%. The lymph node station number of all cases, which index was more than 5, were #106recR, #107, #108, #110, #1, #2, #3, #7, according to Japanese classification of esophageal cancer (10th edition). In type I, #106recR, #107, #108, #110, #1, #2, #3, #7, #9. In type II, #101R, #106recR, #107, #112, #1, #3, #7, #8p, #9. In type III, #1, #2, #3, #7, #10.

**Conclusion:** This study showed that lymph nodes around the cardia, the lesser curvature and the left gastric artery had higher index and must be dissected for all cases. In Siewert type I and II cases, the thoracic lymph nodes might be dissected. Metastases in the cervical lymph nodes were relatively rare. The evaluation of the lymph nodes, that seldom have metastasis, is the future problem.

**Abstract ID: 0526**Specific Field: **Esophagus****Mode of pres.: Poster Exhibition Only**  
**ISW 2011 Session PE 259****Double stents: airway stenting after implantation of esophageal stent for esophageal cancer**T. Oida [1], K. Mimatsu [1], H. Kano [1], A. Kawasaki [1],  
Y. Kuboi [1], N. Fukino [1], K. Kida [1], S. Amano [2]**[1] Social Insurance Yokohama Central Hospital, Yokohama, Japan, [2] Nihon University School of Medicine, Tokyo, Japan****Introduction:** Implantation of self-expanding metallic stent into esophagus for the patients with malignant stricture after failure of chemoradiotherapy is effective. However, airway stenoses are sometimes present after the insertion of the stent into the esophagus. The aim of this study is to evaluate the efficacy of double stents (combined esophagus and airway) placement for patients with recurrent and unresectable esophageal carcinoma where definitive chemoradiotherapy has failed.**Material and Methods:** Between June 1997 and March 2008, we treated 35 patients using self-expanding metallic stent into the esophagus for the patients with malignant stricture due to unresectable esophageal carcinoma. Five of these patients developed dyspnea after implantation of esophageal stenting due to airway compression. Double stenting was necessitated by combined esophago-airway stenosis in 5 patients.**Results:** In all 5 patients, dyspnea and dysphagia were significantly reduced. Mean survival was 60 days (range 24–102 days).**Conclusion:** Although the placement of a self-expanding metallic stent for the patients with recurrent esophageal carcinoma after failure of chemotherapy improved their oral alimentation status, occasionally it develops the airway compression. Accurate bronchoscopic examination with special attention to the decompression of airway after implantation of esophageal stenting for the patients who have category 2b classification.**Table** Outcomes of double stenting

	Timing airway stenting after esophageal stenting (day)	Complication	Treatment after double stenting	Survival after double-stenting (day)
1	Synchronous	Pneumonia	–	24
2	8	–	Chemotherapy	58
3	24	–	Chemotherapy	102
4	18	–	Chemotherapy	84
5	14	Pneumonia	–	42

**Abstract ID: 0527**Specific Field: **Esophagus****Mode of pres.: Poster Exhibition Only**  
**ISW 2011 Session PE 260****Simultaneous resection of metastatic melanoma in the esophagus and primary cutaneous melanoma showing partial regression: report of a case**

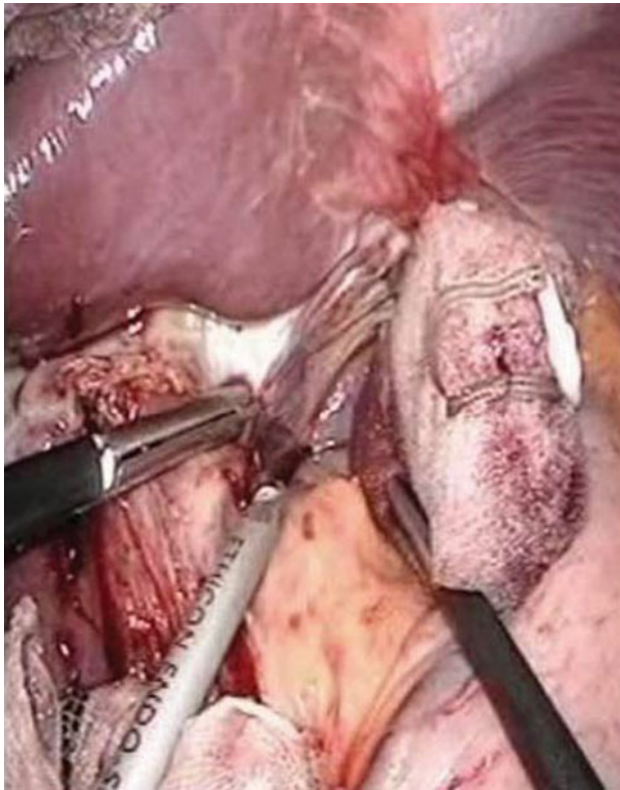
Y. Kumagai, T. Ochiai, S. Yamazaki

Ohta Nishinouchi Hospital, Kohriyama-shi, Japan

**Introduction:** A case of melanoma metastatic to the esophagus from a primary melanoma of the abdominal skin in a 40-year-old woman is described.**Material and Methods:** Esophagography and endoscopy demonstrated a 30-mm protruding mass in the proximal third of the esophagus, and this was diagnosed as malignant melanoma by mucosal biopsy. The patient also had a pigmented lesion on the abdominal skin, which was suspected to be a primary malignant melanoma. This was also totally resected and subjected to immunohistochemical studies. No other site of metastasis was detected using computed tomography and positron emission tomography.**Results:** The esophageal tumor was resected by transthoracic esophagectomy with 3-field lymph node dissection. Histopathologically, the radial growth phase of the tumor cells was not present in the esophageal lesion, which was therefore diagnosed as melanoma metastatic to the esophagus. Postoperatively, the patient received 5 courses of DAV-Feron chemotherapy consisting of DTIC, ACNU, VCR and interferon-beta. Eight months after the chemotherapy, multiple metastases developed, including the subcutis, bronchus, liver, adrenal and mediastinum. Chemotherapy with DTIC was not effective at this stage, and only radiation therapy to the site of cervical recurrence elicited a response. The patient died 21 months after initial esophagectomy because of multiple metastases.**Conclusion:** This report documents the longest surviving patient with metastatic esophageal malignant melanoma, based on a review of the world literature, and our experience indicates that esophagectomy followed by adjuvant chemotherapy can have a role to play in the treatment of metastatic esophageal melanoma if the metastatic site can be totally removed.**Abstract ID: 0528**Specific Field: **Esophagus****Mode of pres.: Poster Exhibition Only**  
**ISW 2011 Session PE 262****Laparoscopic construction of gastric conduit for esophageal cancer**T. Nomura, M. Miyashita, H. Makino, N. Hagiwara, I. Fujita,  
Y. Nakamura, S. Matsumoto, E. Uchida

Nippon Medical School, Tokyo, Japan

**Introduction:** We introduce our experience of hand-assisted laparoscopic (HALS) construction of gastric conduit and also introduce a novel device “Sponge Spacer” that is used in complete laparoscopic construction.**Material and Methods:** HALS: A 7-cm subxiphoid midline incision was made for HALS procedure. Three abdominal ports are inserted. We use Lap-Protector at the small incision and cover it by surgical glove to prevent the CO<sub>2</sub> gas leakage. The most important point is that we never grasp stomach and greater omentum near the gastroepiploic vessels by the forceps because the injury of stomach or the vessels may cause a severe complication. After drawing the stomach outside the body, tubulization of stomach is performed by linear stapler. Sponge Spacer: We use Sponge Spacer (Hogy Medical Co. Ltd.) for complete laparoscopic gastric conduit construction. We inserted sponge spacer in burusa and dissect omentum on it, or we lift stomach using it without grasping stomach by the instrument.**Results:** We had never experimented any major complications so far.**Conclusion:** The HALS construction of gastric conduit is very useful procedure that should be introduced to many institutions. A sponge spacer is also useful device for laparoscopic surgery, especially, in the cases that require gentle operation.



**Figure:** Gastric conduit formation using Sponge Spacer

**Abstract ID: 0529** Specific Field: **Esophagus**

**Mode of pres.: Poster Exhibition Only**  
**ISW 2011 Session PE 263**

**The surgical results of laparoscopic fundoplication for GERD using combined multichannel intraluminal impedance and pH monitoring**

F. Yano, K. Tsuboi, N. Omura, M. Hoshino, H. Kashiwagi, K. Yanaga

Jikei University School of Medicine, Tokyo, Japan

**Introduction:** Combined multichannel intraluminal impedance and pH monitoring (MII-pH) is the most suitable method for the diagnosis of gastroesophageal reflux (GER). By over 24 h of monitoring, it enables detection of every antegrade or retrograde movement into the esophagus. Furthermore, using a pH sensor located in the catheter, acidity of each movement can be evaluated. The aim of this study was to assess the surgical results of laparoscopic fundoplication (LF) for GERD using MII-pH.

**Material and Methods:** Ten consecutive patients, who underwent LF had MII-pH both before and after the surgical procedure were studied. Pre- and postoperative intraesophageal pH < 4 holding time (pH < 4), the numbers of acid and non-acid GER episodes were recorded and analyzed for both liquid and gas reflux.

**Results:** The average preoperative pH < 4, liquid acid reflux (LAR)/gas acid reflux (GAR), and liquid nonacid reflux (LNAR)/gas nonacid reflux (GNAR) were 6.7 (0.3–12.4)%, 43.5 (10–74)/5.1 (0–15) times, and 30.6 (3–100)/16.0 (2–47) times, respectively, while those of postoperative reflux were 0.3 (0–1.0)%, 6.2 (0–26)/0.9 (0–3) times,

and 36.8 (6–116)/10.3 (2–44) times, respectively. Postoperatively, 80% (8/10) of patients had negative symptom index (SI).

**Conclusion:** MII-pH is feasible and well tolerated. LF completely controlled both LAR and GAR, but LNAR and GNAR were detected after surgery. Further investigations are needed to scrutinize these results.

**Abstract ID: 0530** Specific Field: **Esophagus**

**Mode of pres.: Poster Exhibition Only**  
**ISW 2011 Session PE 264**

**The relationship between COX-2 expression of cancer cells and the resistance to chemoradiotherapy for esophageal cancer**

H. Okamura, H. Fujiwara, E. Otsuji

Division of Digestive Surgery, Department of Surgery, Kyoto Prefectural University, Kyoto, Japan

**Introduction:** COX-2 expression at tumor tissues has been shown to be associated with disease progression and prognosis in patients with esophageal cancer, however, the role of COX-2 itself in the sensitivity to chemoradiotherapy has not been fully understood. The aim of this study was to clarify the influence of COX-2 expression in esophageal cancer cells on the sensitivity to chemoradiotherapy.

**Material and Methods:** The patients with cT3/T4 esophageal squamous cell carcinoma who underwent preoperative chemoradiotherapy followed by surgery were analyzed for COX-2 expression of cancer cells in the resected specimens by immunohistochemical staining, and the relationship between COX-2 expression of cancer cells and the response to chemoradiotherapy and prognosis were analyzed. In addition, COX-2 overexpressing cancer cells were established by gene transfer by using esophageal cancer cell lines, KYSE170 and TE13, and the sensitivity to 5FU and CDDP and radiosensitivity, evaluated by WST-8 assay and colony assay, respectively, were compared between COX-2 transfectants and control cells. COX-2 expression was confirmed by PGE2 assay and western blotting.

**Results:** In clinicopathological study, COX-2 expression was correlated with poor response to chemoradiotherapy, and the patients with COX-2-positive cancer cells had poor prognosis compared with those with COX-2-negative cancer cells. In *in vitro* sensitivity assays, COX-2 overexpressing cells showed significantly reduced sensitivities to 5FU and CDDP in both cell lines, and inhibition of COX-2 expression by transfer of siRNA selective for COX-2 restored the chemosensitivities. In contrast, no difference in radiation sensitivity was observed between COX-2 overexpressing cells and control cells.

**Conclusion:** The present data strongly suggest that COX-2 expression of cancer cells may contribute to the resistance to chemotherapy and poor prognosis in patients with esophageal cancer.

**Abstract ID: 0531** Specific Field: **Esophagus**

**Mode of pres.: Poster Exhibition Only**  
**ISW 2011 Session PE 265**

**Prognostic significance of IL-6 expression in cancer cells in patients with advanced esophageal cancer**

M. Yoneda, H. Fujiwara, A. Shiozaki, S. Komatsu, D. Ichikawa, K. Okamoto, E. Otsuji

Kyoto Prefectural University of Medicine, Kyoto, Japan

**Introduction:** IL-6 expression in serum has been shown to be associated with tumor progression and prognosis in patients with



esophageal cancer. We recently reported that serum IL-6 levels after preoperative chemoradiotherapy were significantly high in non-responders compared with responders in patients with advanced esophageal cancer and elevated serum IL-6 levels were correlated with poor response to chemoradiotherapy and poor prognosis. The purpose of this study was to clarify the relationship between IL-6 expression in cancer cells and prognosis in patients with advanced esophageal cancer with special interest in possible influence of chemoradiotherapy on IL-6 expression in cancer cells.

**Material and Methods:** Thirty-five patients with clinical T3 or T4 esophageal squamous cell carcinoma (ESCC) who underwent induction chemoradiotherapy followed by esophagectomy (CRT group) and twenty-seven patients with clinical T3 or T4 ESCC who underwent surgery without any preoperative therapies (surgery group) between 2000 and 2010, were analyzed in this study. IL-6 expression in cancer cells in the resected tumor specimens was evaluated by immunohistochemical staining.

**Results:** IL-6-positive cancer cells were detected with the incidence of 37% and 25% in the resected tumor specimens of CRT group and surgery group, respectively. IL-6-positive group showed poor prognosis compared with IL-6-negative group. Significant difference in overall survival was observed between IL-6-positive group and IL-6-negative group in CRT group ( $P = 0.005$ ), whereas no significant difference was observed in surgery group ( $P = 0.057$ ). No significant difference in IL-6-positive rate was observed according to age, gender, clinical stage and curability.

**Conclusion:** Our results suggest that IL-6 expression in cancer cells may play a role in poor prognosis in close association with resistance to chemoradiotherapy in patients with advanced esophageal cancer.

**Abstract ID: 0532**

Specific Field: **Esophagus**

**Mode of pres.: Poster Exhibition Only**  
**ISW 2011 Session PE 266**

#### **The clinicopathological significance of xCT expression in esophageal squamous cell carcinoma**

D. Iitaka, A. Shiozaki, D. Ichikawa, S. Komatsu, H. Fujiwara, K. Okamoto, T. Ochiai, E. Otsuji

Division of Digestive Surgery, Department of Surgery, Kyoto Prefectural University of Medicine, Kyoto, Japan

**Introduction:** xCT, the functional subunit of the cystine/glutamate transporter xc-system, is Na-independent heterodimeric amino-acid transport system and functions as the exchange system cystine entry into cells in exchange for the release of glutamate. Therefore, xCT plays a critical role in the maintenance of intracellular glutathione and redox balance. xCT is an integral membrane protein with 12 transmembrane domains associated with the heavy chain CD95. Recent study reported that disruption of xCT significantly inhibits the growth of a variety of carcinomas, however, its role in esophageal squamous cell carcinoma (ESCC) is poorly understood.

**Material and Methods:** Forty-nine tumor specimens were obtained from patients with esophageal carcinoma who underwent curative esophagectomy from 1998 to 2007. They were analyzed by immunohistochemistry using antibody against xCT receptor and Ki67 receptor. The percentage of immunoreactivity was evaluated in more than 1000 carcinoma cells in each case, and they were categorized into high and low xCT expression groups. Then, correlation of xCT expression with clinicopathological features and prognosis of ESCC patients was determined.

**Results:** In all cases, expressions of xCT and Ki67 were detected in the nuclei of carcinoma cells. The expression level of xCT was high in 29

cases and low in 20 cases. Although no significant correlation was observed between xCT expression and clinicopathological parameters in terms of gender, age, depth of invasion, lymphatic invasion, venous invasion, tumor differentiation, pathological stage, a significant correlation was observed between xCT expression and lymph node metastases ( $P = 0.038$ ). The xCT expression was positively correlated with Ki67 labeling index ( $R^2 = 0.5057$ ,  $P = 0.0002$ ). Kaplan–Meier analysis showed no significant difference in the overall survival time between high and low xCT expression groups (Log Rank  $P = 0.060$ ), but the 5-year survival rate of ESCC patients with high xCT expression was lower than those with low xCT expression (high, 58.4%; low, 85.0%). In multivariate analysis, depth of invasion, lymphatic invasion and xCT expression were independent prognostic factors for patient survival (xCT expression: Hazard ratio 2.096, 95%CI, 1.036–5.156,  $P = 0.039$ ).

**Conclusion:** Expression of xCT could be a novel prognostic factor in ESCC patients.

**Abstract ID: 0533**

Specific Field: **Esophagus**

**Mode of pres.: Poster Exhibition Only**  
**ISW 2011 Session PE 267**

#### **Prognostic significance of serum CRP and SCC in recurrent esophageal cancer after curative resection**

T. Todo, F. Fujiwara, S. Shiozaki, K. Komatsu, I. Ichikawa, O. Okamoto, O. Otsuji

Kyoto Prefectural University of Medicine, Kyoto, Japan

**Introduction:** The patients with esophageal cancer who underwent curative resection have poor prognosis due to high incidence of recurrence. Therefore, early detection of recurrence followed by effective treatment is important to improve prognosis. Although elevated serum CRP levels have been shown to be associated with tumor progression and poor prognosis of esophageal cancer and preoperative elevated CRP levels have been shown to be an independent poor prognostic factor in patients with resectable esophageal cancer, prognostic significance of serum CRP at the time of recurrence has not been fully understood. The aim of this study was to clarify the prognostic significance of serum CRP levels in patients with recurrent esophageal cancer in comparison with conventional tumor markers.

**Material and Methods:** Among 233 patients with esophageal squamous cell carcinoma who underwent curative resection from January 2000 to October 2009, 182 patients who were regularly examined for serum CRP and SCC during pre- and post-operative periods, were analyzed in this study. Relationships between tumor markers (CRP and SCC) and other clinicopathological factors, and survival time were analyzed.

**Results:** The positive rates for CRP and SCC before initial treatment were 34.1% and 22.5%, respectively, and 42 of 182 patients (23.1%) had a recurrence. The patients with a recurrence had the median survival time of 29.1 months, with the 1-, 3-, and 5-year survival rates after initial treatment of 81%, 31.5%, and 20.3%, respectively. No significant differences in recurrence rate and survival time were observed between each marker-positive and negative patients before initial treatment. When analyzed in the patients with a recurrence, CRP-positive patients at the time of recurrence had significantly shorter survival time after initial treatment and recurrence, compared with CRP-negative ones, whereas no significant correlations were observed between the survival time and the levels of CRP and SCC before initial treatment, and the levels of SCC at the time of recurrence. Positive CRP at the time of recurrence and a recurrence within 1 year after initial treatment were selected as independent poor prognostic factors by multivariate analysis.



**Conclusion:** Serum CRP at the time of recurrence may predict poor prognosis of the patients with a recurrence more accurately than preexisting tumor marker.

**Abstract ID: 0534**                      Specific Field: **Esophagus**

**Mode of pres.: Poster Exhibition Only**  
**ISW 2011 Session PE 268**

**Clinicopathological significance of BMP7 expression in esophageal squamous cell carcinoma**

S. ishigami, S. Natugoe, K. Megumi

Kagoshima University, Japan, Japan

**Introduction:** Bone morphogenetic proteins (BMPs) are secreted signaling molecules belonging to the transforming growth factor- $\beta$  (TGF- $\beta$ ) superfamily of growth factors. Recent studies showed that the influence of the expression of BMP7 was altered in several tumors. The purpose of the current study was to examine the expression of BMP7 in esophageal squamous cell carcinoma, and to clarify the clinical impact of BMP7 expression in esophageal squamous cell carcinoma (ESCC). **Material and Methods:** One hundred and eighty patients with ESCC who underwent surgical resection from 1991 to 2004 were eligible for this study. The expression of BMP7 in esophageal tumor tissues was examined immunohistochemically.

**Results:** BMP7 expression was found in the cytoplasm of cancer cells. BMP7 positivity was observed in 61.6% of tumors. The BMP7-positive group had deeper progression, more advanced stages and greater venous invasion than those without BMP7 expression ( $P < 0.001$ ,  $P < 0.005$  and  $P < 0.0005$ , respectively). In addition, expression of BMP7 correlated with poorer prognosis ( $P < 0.0005$ ). Multivariate analysis showed that BMP7 expression status was an independent prognostic factor ( $P < 0.05$ ). **Conclusion:** Patients with expression of BMP7 in ESCC had high malignant potential. BMP7 could be a useful prognostic marker for patients with ESCC.

**Abstract ID: 0535**                      Specific Field: **Esophagus**

**Mode of pres.: Poster Exhibition Only**  
**ISW 2011 Session PE 269**

**Expression of carbonic anhydrase 9 (CA9) in esophageal squamous cell carcinoma**

N. Tanaka [1], S. Suzuki [1], T. Yokobori [1], T. Inose [1], M. Sohda [1], H. Kato [2], H. Kuwano [1]

[1] Department of General Surgical Science, Gunma University, Graduate School of Medicine, Maebashi, Japan, [2] Department of Surgical Oncology, Dokkyo Medical University, Mibu-Machi, Japan

**Introduction:** Hypoxic conditions in the environment of some cancers are known to be associated with resistance to chemotherapy and radiotherapy. In addition, low extracellular pH is a typical feature of the tumor microenvironment, which has an impact on cancer development. Carbonic anhydrase 9 (CA9) was induced by hypoxia, and have functions including pH regulation. In the present study, we investigated expression of CA9 in esophageal squamous cell carcinoma. CA9 is a protein to be up-regulated under exposure to hypoxic conditions. Hypoxic conditions in the environment of some cancers are known to be associated with resistance to chemotherapy and radiotherapy, and poor prognosis. The purpose of this study was to investigate the expression of CA9 in esophageal squamous cell carcinoma (ESCC) and its changes under hypoxic conditions.

**Material and Methods:** We examined CA9 expression in surgical specimens from ESCC patients ( $n = 127$ ) using immunohistochemistry and real-time RT-PCR. For in vitro assays, we used ESCC cell lines (TE-2, TE-8 and TE-15) and an immortalized human esophageal cell line (CHEK-1). We examined CA9 expression and cell proliferation using real-time RT-PCR, western blotting, ELISA and MTT assay.

**Results:** Immunohistochemistry, positive staining for CA9 was found in 71 (55.9%) of the 127 primary tumor specimens. Tumor CA9 expression was correlated with poor outcome ( $P = 0.0003$ ) and clinicopathological findings (tumor size ( $P = 0.0235$ ), tumor depth ( $P < 0.0001$ ), regional lymph node metastasis ( $P = 0.0031$ ), distant lymph node metastasis ( $P = 0.0077$ ), stage ( $P < 0.0001$ ) and blood vessel invasion ( $P = 0.006$ ). In vitro assay showed that CA9 expression was induced under hypoxic conditions, and interestingly—in view of the fact that it is a membrane protein—that its level was also significantly increased in culture medium ( $P < 0.01$ ).

**Conclusion:** CA9 is expressed by ESCC, and correlated with poor prognosis and malignant phenotype. CA9 is up-regulated in ESCC cell lines under hypoxic conditions. It is suggested that to control of CA9 expression might help to improve the effectiveness of chemotherapy and radiotherapy for ESCC.

**Abstract ID: 0536**                      Specific Field: **Esophagus**

**Mode of pres.: Poster Exhibition Only**  
**ISW 2011 Session PE 270**

**Expression of HMGB1 is associated with 5FU sensitivity in esophageal squamous cell carcinoma**

N. Ikeda, Y. Akutsu, M. Mori, N. Hanari, A. Komatsu, Y. Miyazawa, H. Matsubara

Department of Frontier Surgery, Graduate School of Medicine, Chiba University, Chiba City, Japan

**Introduction:** HMGB1 is known as an inflammatory cytokine, however, how it is expressed in esophageal squamous cell carcinoma (ESCC) is rarely reported. A few reports indicate that HMGB1 in the nucleus plays an important role with p53 for chemosensitivity (Eugene et al Cancer Research 63, 100–106, 2003). Therefore, we analyzed the expression of HMGB1 in ESCC.

**Material and Methods:** We made stable shHMGB1 vector introduced TE2 in order to analyze the role of HMGB1 in ESCC. We introduced shHMGB1 vector into TE2 by lipofection method. Control vector and shHMGB1 vector introduced TE2 were selected by puromycin. Control vector and shHMGB1 vector introduced TE2 were treated with 5FU for 72 h. Chemosensitivity was evaluated by cell counting kit-8.

**Results:** shHMGB1 vector introduced TE2 were higher resistance to 5FU than control vector introduced TE2.

**Conclusion:** Expression of HMGB1 in TE2 is associated with 5FU sensitivity.

**Abstract ID: 0537**                      Specific Field: **Esophagus**

**Mode of pres.: Poster Exhibition Only**  
**ISW 2011 Session PE 286**

**A case of 100-year-old woman successfully treated for upside down stomach with laparoscopic surgery**

M. Mori [1], Y. Akutsu [1], H. Hayashi [2], H. Kawahira [2], N. Hanari [1], T. Sadahiro [3], S. Oda [3], H. Matsubara [1]

[1] Department of Frontier Surgery, Graduate School of Medicine, Chiba University, Chiba, Japan, [2] Research Center for

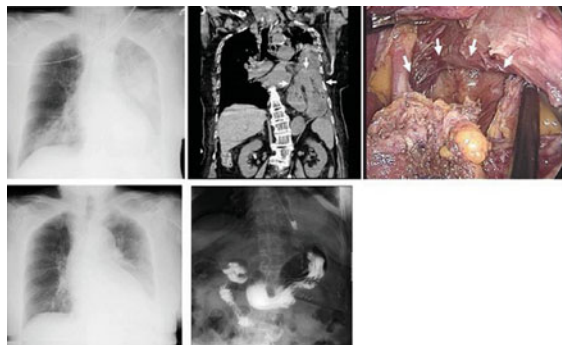
Frontier Medical Engineering, Chiba University, Chiba, Japan,  
[3] Department of Emergency and Critical Care Medicine, Graduate School of Medicine, Chiba University, Chiba, Japan

**Introduction:** Hiatal hernias (HH) is particularly thought to occur in the elderly. HH are generally classified into four distinct types. The extreme form of type III HH results in a completely inverted intrathoracic stomach, which is so-called upside down stomach. In Japan, there has been a dramatic increase in the number of the patients aged over 80 years these days. Although surgery for elderly is regarded as one of the focal points of current medical treatment, the number of cases of surgery for centenarians is still small. We report a case of a 100-year-old woman successfully treated for upside down stomach with laparoscopic surgery.

**Material and Methods:** She was admitted to our hospital because of hematemesis accompanied with acute respiratory and renal failure. Chest X-ray showed the effusion in the whole left pleural cavity and atelectasis in the left lung lobe. Abdominal computed tomography revealed the entire gastric incarceration into the left pleural cavity with esophageal hiatal hernia and with gastric volvulus. She was diagnosed as upside down stomach caused by combined esophageal hiatal hernia with organoaxial gastric volvulus.

**Results:** She underwent laparoscopic surgery to repair her herniation. After the incarcerated stomach and the greater omentum were easily reduced into her abdominal cavity, the hiatus could be directly closed, and then Toupet fundoplication was performed to prevent reflux esophagitis. Postoperative course was uneventful, and she was discharged on the 13th day after the operation.

**Conclusion:** Upside down stomach is an uncommon presentation of hiatal hernia. Traditionally, repair of upside down stomach has been performed through an open laparotomy or thoracotomy. With the advent of laparoscopy, upside down stomach is now being approached with minimally invasive techniques. With the aging of the population in Japan, the number of patients suffering from this disease will increase and laparoscopic surgery for upside down stomach may become the standard approach for elderly patients with multiple medical problems.



**Figure:** Figures of upside down stomach

**Abstract ID: 0538** Specific Field: **Hepatobiliary and Pancreas Surgery**

**Mode of pres.: Free Paper**  
**ISW 2011 Session 10.01**

**Step-by-step techniques in surgical treatment of acute necrotizing pancreatitis**

I. V. Khomyak, K. V. Kopchak

National Institute of Surgery and Transplantology, Kyiv, Ukraine

**Introduction:** Acute necrotizing pancreatitis (ANP) is a dangerous disease that could cause serious complications and death. Treatment of ANP is a challenging medical and surgical problem.

**Material and Methods:** We have analyzed the results of treatment of 569 patients with ANP, treated in our clinic in the period of 1997–2008 years. There were 108 (18.98%) female patients and 461 (81.02%) male patients, with an age, ranging from 18 to 79 years. - Main group comprised of 387 patients, treated in the period of 2002–2008 years. Control (retrospective) group comprised of 182 patients, treated in the period 1997–2001 years. Aseptic forms were diagnosed in 260 (67.18%) patients of the main group and in 107 (58.79%) patients of the control group. Infected necrosis with septic complications were diagnosed in 127 (32.82%) patients of the main group and in 75 (41.21%) patients of the control group.

**Results:** Treatment protocols in patients with ANP were individualized correspondingly to phases of the disease and peculiarities of its course. We started always with conservative treatment. Implementation of the medical treatment made it possible to treat successfully 150 (38.76%) patients of the main group with aseptic forms of ANP. Ultrasound controlled interventions were performed in 193 (49.87%) patients of the main group and 44 (24.18%) patients of the control group. Percutaneous ultrasound-guided interventions made it possible to stabilize general state of the patient in 181 (46.77%) cases and to delay laparotomy if needed. In 8 patients with septic forms of ANP percutaneous retroperitoneal necrosectomy was used. Open surgical procedures were done in 128 (33.07%) patients of the main group and in 104 (57.14%) patients of the control group. Relaparotomies were done in 15.38% patients of the main group and in 9.04% patients of the control group. Mortality was 6.78%, including 8.15% postoperative mortality in the main group of patients and 9.34% (13.28% postoperative) in the control group. All patients with percutaneous retroperitoneal necrosectomy were alive, no laparotomies were done in this subgroup of patients.

**Conclusion:** We conclude that implementation of step-by-step procedures with individualized treatment protocols correspondingly to phases of the disease and peculiarities of its course could significantly increase the results of treatment in patients with ANP.

**Abstract ID: 0539** Specific Field: **Hepatobiliary and Pancreas Surgery**

**Mode of pres.: Free Paper**  
**ISW 2011 Session 10.02**

**Early experience with laparoscopic RAMPS for distal pancreatic tumours**

F. Ngu, D. Fenton-Lee

St Vincent's Hospital, Sydney, Australia

**Introduction:** The traditional left-to-right pancreatectomy and splenectomy performed for resection of distal pancreatic malignancies has been criticised for its limitations in achieving adequate lymphadenectomy and posterior resection. Radical Anterograde Modular Pancreatosplenectomy (RAMPS) is a new right-to-left pancreatectomy and splenectomy designed to overcome these technical and oncological shortcomings. It was first described by Strasberg and colleagues [1] in 2003 as an open procedure. The aim of this study was to see whether RAMPS was amenable to a laparoscopic approach and to report our initial experience with laparoscopic RAMPS.

**Reference**

[1] Strasberg SM, Drebin JA, Linehan D (2003) Radical antegrade modular pancreatosplenectomy. *Surgery* 133:521–527

**Material and Methods:** The operative techniques of RAMPS were modified to enable a laparoscopic approach. The data of patients undergoing laparoscopic RAMPS were collected and entered into a database. Demographic data, total operative time, postoperative complications and length of stay was collected from medical records. Tumour stage, resection margins and number of nodes harvested were obtained from anatomical pathology reports.

**Results:** Six patients with distal pancreatic tumours, four with distal adenocarcinomas, underwent laparoscopic RAMPS. There were no conversions. Mean operating time was  $234 \pm 39$  min. No patients required blood transfusions. In the post-operative period two patients had pancreatic stump fistulae and one patient developed bowel obstruction. The mean length of stay was  $13 \pm 7$  days. The mean tumour size was  $35 \pm 21$  mm. Three of the four adenocarcinoma cases were T3 tumours. The mean number of nodes resected was  $8 \pm 5$  nodes overall and  $11 \pm 1$  nodes among the adenocarcinoma cases. One patient had a positive resection margin. Follow-up ranged from 4 to 48 months, two patients with adenocarcinomas died due to recurrence.

**Conclusion:** As the first report of laparoscopic RAMPS, our early results suggest that this is a safe and technically feasible operation in the management of distal pancreatic malignancies. Larger studies and long-term follow up will be required for determination of oncologic feasibility.

**Abstract ID: 0540**                      Specific Field: **Hepatobiliary and Pancreas Surgery**

**Mode of pres.: Free Paper**  
**ISW 2011 Session 10.03**

**Volumetric and morphological analysis of intraductal papillary-mucinous neoplasm of the pancreas using computed tomography and magnetic resonance imaging**

S. Murayama

Yamagata University, Yamagata, Japan

**Introduction:** The purpose of this study was to predict the malignancy of intraductal papillary-mucinous neoplasm (IPMN) based on data obtained by computed tomography (CT) and magnetic resonance imaging (MRI).

**Material and Methods:** 69 patients with IPMN underwent CT, MRI, and surgery. The tumors were classified pathologically as IPMN (adenoma), IPMN(in situ carcinoma), and invasive carcinoma derived from IPMN, and analyzed morphologically for the following characteristics: tumor size, main pancreatic duct (MPD) diameter, tumor area, MPD area, tumor volume, MPD volume, and intraductal volume (tumors volume + MPD volume).

**Results:** MPD diameter ( $P = 0.017$ ) and intraductal volume ( $P = 0.0013$ ) showed significant differences among IPMN (adenoma), IPMN (in situ carcinoma), and invasive carcinoma derived from IPMN. When IPMN(in situ carcinoma) and invasive carcinoma derived from IPMN were classified as malignant IPMN, an MPD diameter of 6 mm or more and an intraductal volume of  $10 \text{ cm}^3$  or more were set as cut-off levels predictive of malignancy using receiver operating characteristic (ROC) curve analysis. On the basis of these criteria, the sensitivity, specificity for identifying malignancy in MPD were 83%, 59%, and those for intraductal volume were 70%, 73%, respectively.

**Conclusion:** Intraductal volume ( $10 \text{ cm}^3$ ) determined by volumetric analysis is useful for diagnosis of malignant IPMN.

**Abstract ID: 0541**                      Specific Field: **Hepatobiliary and Pancreas Surgery**

**Mode of pres.: Free Paper**  
**ISW 2011 Session 10.04**

**Novel risk index is good predictor of postoperative pancreatic fistula after pancreaticoduodenectomy**

S. Ottomo, F. Motoi, Y. Katayose, T. Rikiyama, H. Yoshida, S. Egawa, M. Unno

Tohoku University, Miyagi, Japan

**Introduction:** Postoperative pancreatic fistula (POPF) is the most common major complication after Pancreaticoduodenectomy (PD). The purpose of this study is to identify the risk factor of POPF and evaluation of the new prediction risk-index for POPF.

**Material and Methods:** We retrospectively investigated 208 patients. Patient's data were divided into two groups. One of the group was perioperative parameters that to be defined as "Pre-Risk" and the other group was postoperative parameters that to be defined as "Post-Risk". Fifteen "Pre-Risk" factors were selected as follows; age, gender, body mass index (BMI), preoperative laboratory data (hemoglobin, creatinine, HbA1c, albumin, total bilirubin and amylase (S-AMY), operative time, intraoperative bleeding, pancreatic texture (soft or hard), the main pancreatic duct (MPD) diameter, invasive ductal carcinoma or not, and use of the stent tube or not."Post-Risk" were selected as follows; laboratory data of POD 1 (WBC count, S-AMY, CRP and drain amylase (D-AMY)). POPF of grade B and C were defined as clinically POPF "CPF" and others were defined "NO-CPF".

**Results:** CPF was observed in 19.7%. The univariate analysis of the "Pre-Risk" revealed six significant risk factors; BMI, hemoglobin, HbA1c, small MPD diameter, soft pancreatic texture and not invasive ductal carcinoma. When those six factors were examined using multivariate analysis, three significant "Pre-Risk" factors for CPF were indicated; HbA1c (less than 5.7%), MPD diameter (less than 3 mm) and soft pancreatic texture. The "Post-Risk" three factors were significant high risk using for CPF using The univariate analysis of "Post-Risk" revealed that there are three significant factors; D-AMY, S-AMY and CRP. Cutoff level of each factors were as follows; D-AMY 3500, S-AMY 360, CRP 10.4. In the multivariate analysis, these three "Post-Risk" were also independent significant risk factors for CPF. We defined that a number of "Post-Risk" data as risk index (R. I.) and examined correlation with onset of CPF. If R. I. is 0, 1, 2, or 3, the incident rate of CPF is increased, 4.0%, 20.6%, 51.7%, or 88.9%, respectively. Therefore, we propose that this new risk index "Post-Risk Index" consisting of D-AMI, S-AMI and CRP in POD 1 is useful for early detection for CPF.

**Conclusion:** The laboratory data of D-AMI, S-AMI and CRP in POD1 are the novel predictive tool for POPF.

**Abstract ID: 0542**                      Specific Field: **Hepatobiliary and Pancreas Surgery**

**Mode of pres.: Free Paper**  
**ISW 2011 Session 10.05**

**Introduction of a clinical pathway for patients undergoing pancreaticoduodenectomy at the university hospital**

S. Yamaki, S. Satoi, H. Toyokawa, H. Yanagimoto, T. Yamamoto, S. Hirooka, R. Yui, A. Kwon

Kansai Medical University, Hirakata-City, Japan

**Introduction:** Pancreaticoduodenectomy (PD) is still associated with high morbidity and mortality. There is little data to support the critical pathway use in this procedure. In June, 2004, the new departmental guidelines for peri-operative management of PD were introduced, and a clinical pathway (CP) for all patients undergoing PD was implemented for checking expected clinical outcomes. The objective of this study is to determine the clinical effects of critical pathway implementation.

**Material and Methods:** From January, 2000 to May, 2006, 126 consecutive patients underwent PD. Pre-CP group was consisted of 79 patients before introduction of CP and departmental guidelines (duct-to-mucosa anastomosis for pancreatojejunostomy, early removal of closed-suction drain, restrictive use of pancreatic and biliary duct stenting), and the residual 47 patients after CP implementation were included in CP group. Clinical outcome data between each group, post-operative mortality and morbidity were analyzed. Clinical outcomes included the day of nasogastric tube removal (expected on pathway outline on POD1), discontinuation prophylactic antibiotics (POD2), abdominal drainage tube removal.

**Results:** No significant differences in demographic characteristics and intraoperative parameters between two groups. Expected clinical outcomes, including the removal rate of nasogastric tube (15% in pre-CP group vs. 61% in CP group), the day of discontinuation of prophylactic antibiotics (22% in pre-CP vs. 79% in CP), drain removal (1.3% vs. 39% until POD6), and starting oral intake (14% vs. 64% on POD7), were significantly improved in CP group, relative to those in pre-CP group (*P*

**Conclusion:** Introduction of the new guideline and clinical pathway for patients undergoing PD was associated with improvement of clinical outcomes and reduced postoperative complications.

**Abstract ID: 0543** Specific Field: **Hepatobiliary and Pancreas Surgery**

**Mode of pres.: Free Paper**  
**ISW 2011 Session 10.06**

**Operative indications for IPMN and evaluation of malignant potential of them in terms of risk factors of malignancy**

M. Tori, H. Akamatsu, T. Nishida, M. Tsujimoto

Osaka Police Hospital, Osaka, Japan

**Introduction:** In considering operative indications for IPMN, main pancreatic duct type (group I) should be all true of the indication, while in branch duct type (group II), there should be 5 risk factors for malignancy in our facility, i.e. “1. Tumor marker positive (CEA, CA19-9), 2. Size of tumor >3 cm, 3. Mural nodule+, 4. Cytology of pancreatic juice (class 3–5), 5. Diameter of main pancreatic duct >5 mm”. The purpose of this study is to consider operative indications for IPMN and to evaluate malignant potentials of them in terms of risk factors of malignancy.

**Material and Methods:** For the past 9 years, we have experienced 78 IPMN cases, among which, there were 33 operative cases (group A) and 45 non-operative cases (under observation) (group B). In group A, I MPD type: *n* = 18, II branch type: *n* = 15. (a) IPMC, invasive: *n* = 13, (b) IPMC, non-invasive: *n* = 8, (c) IPMA: *n* = 12. In group B, IPMA susp. (branch type) *n* = 44, IPMC (invasive) *n* = 1.

**Results:** Percentage of malignancy was group I 88.9%, II 23.5% in each. As to risk factor in group II, the rate of malignancy was f1 100%, f2 75%, f3 50%, f4 50%, f5 50%. Operative procedures: A(a); PpPD(*n* = 6), DP(*n* = 4), TP(*n* = 3). Five cases including all TP

were dead (average survival was 3y5m). A(b)(c); PpPD(*n* = 10), DP(*n* = 10). All cases are alive (average observation period is 4y8m). Immunohistochemical examinations suggested CEA/p53 pattern should be important. Most of the specimens of non-invasive lesion showed CEA + /p53–. None of the cases except MPD type in group B showed change for malignancy.

**Conclusion:** Operative indications for IPMN in our facility could be properly designed. Risk factors are considered to be important in each, though there was no rank in those importance. CEA/p53 staining pattern might be an index of malignancy.

**Abstract ID: 0544** Specific Field: **Hepatobiliary and Pancreas Surgery**

**Mode of pres.: Free Paper**  
**ISW 2011 Session 10.07**

**Clinical presentation and modalities of surgical treatment of pancreatic pseudocysts**

A. B. Briezat, Q. S. M. Al-Ani

Al-Basher teaching Hospital, Amman, Jordan

**Introduction:** Pancreatic pseudocysts occur in up to 10% of acute pancreatitis, and in 20–40% of chronic pancreatitis. They are often single cysts but may be multiple. Despite recent developments in minimally invasive techniques, surgical drainage is still a principal method in pancreatic pseudocysts management.

**Material and Methods:** The clinical presentation, diagnosis and treatment of 16 patients presented with symptomatic pseudocysts from the period 2000 to Nov 2010 where treated surgically are presented. Open surgical internal drainage done in 13 patients and 3 patients managed with laparoscopic cystogastrostomy. Immediate and chronic results in terms of symptomatic relief and complications were evaluated.

**Results:** there were 12 men and 4 women, with age range from 23 to 64 years. Abdominal pain was the most common mode of presentation. Jaundice in 4 patients, while 2 patients had gastric outlet obstruction. History of pancreatitis was noticed in 14 patients, and one patient presented after pancreatic surgery for insulinoma, another patient after endoscopic stone removal of common bile duct.. There

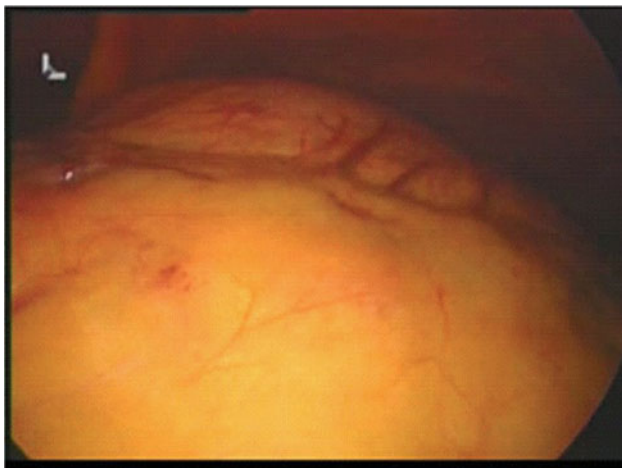**Table** Clinical and pathological characteristics

Patients characteristics	No. patients
Age range	23–64 years
History of pancreatitis	14
Pos-operative	1
PostERCP	1
Single cyst	15
Multiple cyst	1
Average size of the cyst	12 cm
Site bulge, transverse meso-colon	8
Retrogastric	6
Tail pancreas	1
Multiple	1



were single pseudocysts in 15 patients while one patient with multiple variable sizes intra-abdominal pseudocysts. The size of the cysts varied from 8 cm to 25 cm. Roux-en-Y cysto-jejunostomy done in 8 patients, cysto-gastrostomy in 4 patients, and resection of the cyst by distal pancreatectomy with splenectomy in one patient. Laparoscopic cysto-gastrostomy was done in 3 patients and followed from 12 months, to 5 years with no recurrence. There were no mortality and during the period of follow up there was one recurrence in the open group, reoperation with roux-en-Y cystojejunostomy.

**Conclusion:** Surgery still plays an important role in the management of selected cases of pseudocysts of the pancreas, and drainage must take into account the morphology and the location of the cyst. Laparoscopic approaches are considered a safe choice in the management of mature pseudocysts and can facilitate debridement of the necrotic pancreas, with accepted long term results.



**Figure:** pancreatic pseudocyst, laparoscopic approach

**Abstract ID: 0545**      Specific Field: **Hepatobiliary and Pancreas Surgery**

**Mode of pres.: Free Paper**  
**ISW 2011 Session 10.08**

**Phase I trial of preoperative intratumoral injection of immature dendritic cells and OK-432 for resectable pancreatic cancer patients**

A. Kenjo, M. Gotoh

Fukushima Medical University, Fukushima, Japan

**Introduction:** Immunotherapy for pancreatic cancer is expected to become one of key treatments for this intractable disease. To conduct new immunotherapy, we have to overcome immune-suppressive environment of pancreatic cancer. OK-432 induces the production of various cytokines, particularly T helper-1 (Th-1) cytokines and also shifts the Th-1/Th-2 balance to a Th-1 predominant status. It has been also reported that OK-432 stimulates dendritic cell (DC) maturation and stimulate T cell activation. We performed phase I clinical trial for pancreatic cancer patients under endoscopic ultrasound-guided fine-needle injection of immature DCs (iDCs) together with OK-432. This is the first report of preoperative immunotherapy for pancreatic cancer.

**Material and Methods:** Nine patients were enrolled in this trial. Adverse events of preoperative intratumoral injection and postoperative complications were assessed. Histological changes within tumor and regional lymph nodes were evaluated on immunohistochemical staining. Control group includes 15 pancreatic cancer patients without preoperative iDCs injection (non-DC group:  $n = 15$ ) who operated around the same period. The primary endpoint of this study is to evaluate the feasibility of this trial. Secondary endpoint is to evaluate histological changes and immunological response.

**Results:** Hematologic toxicities following iDCs injection were grade 1 or 2 except for one patient with transient grade 3 fever. There was no significant difference of postoperative complication between two groups. On injected sites, colliquative necrosis with lymphocyte infiltration and diffusely scattered TUNEL positive cells were observed only in DC group. CD83<sup>+</sup> cells were significantly accumulated in the regional lymph nodes of DC group. Foxp3<sup>+</sup> cells also accumulated in regional and distant lymph nodes of DC group. Two of 9 patients of DC group are currently alive over 5 years after surgery without any other adjuvant therapy, however, one of two patients had StageIV pancreatic cancer with distant lymph node metastasis.

**Conclusion:** This is the first report of preoperative immunotherapy for pancreatic cancer. The results showed the feasibility of this procedure and could suggest induction of immunological response for pancreatic cancer. Further investigations to confirm and to enhance antitumor response are warranted.

**Abstract ID: 0546**      Specific Field: **Hepatobiliary and Pancreas Surgery**

**Mode of pres.: Video**  
**ISW 2011 Session 12.04**

**Single-port laparoscopic hepatectomy**

M. Asakuma, K. Komeda, Y. Miyamoto, F. Hirokawa, T. Shimizu, Y. Inoue, M. Hayashi, N. Tanigawa

Osaka Medical College, Osaka, Japan

**Introduction:** We provide an initial report of the indications and procedures for single-port laparoscopic hepatectomy.

**Material and Methods:** Methods: Laparoscopic hepatectomy and single port laparoscopic surgery has been performed in 53 patients and 77 patients respectively at our institution. We experienced 3 cases of single port hepatectomy. (case1) A 41-year old woman who was diagnosed preoperatively hepatic tumor (S6, S7). Operation was done by single port using surgical glove method. In lateral position, a 2 cm incision was placed on right axillary line. Liver resection was done by ultrasonic dissector. (case 2) A 63-year old woman, diagnosed as metastatic liver tumor (S2), was performed single port lateral segmentectomy via umbilical 2.0 cm incision. (case 3) A 66-years old man who had metastatic liver tumor (S3), was underwent single port patitial resection of the liver.

**Results:** Result: All the procedures were successfully done by single port fashion, without any additional port. Operation time was 225 min, 270 min and 60 min and bleeding was 50 ml, 330 ml and 0 ml respectively.

**Conclusion:** Conclusion: single port surgery is a new method of laparoscopic surgery which does not establish yet. So its indications have to be strict. From our limited experiences, it is important that resection surface should be a simple plane. The specimen was extracted by extending the umbilical incision. No complications occurred. The patient was able to resume an oral diet and full mobility

free of opioid analgesia on the first postoperative day. The resection margin was clear. Thus single port hepatectomy have great potential to be a less invasive surgery.

**Abstract ID: 0547** Specific Field: **Hepatobiliary and Pancreas Surgery**

**Mode of pres.: Video**  
**ISW 2011 Session 12.05**

**Laparoscopic right trisectionectomy: videoclip**

A. Ferko, Z. Subrt, M. Lesko, F. Cecka, B. Jon

Department of Surgery, Charles University and University Hospital in Hradec Kralove, Hradec Kralove, Czech Republic

**Introduction:** Laparoscopic major resections, especially trisectionectomies, belong to the most technically demanding procedures. We would like to describe our technique of laparoscopic right trisectionectomy as a videoclip.

**Material and Methods:** Surgical technique: The procedure starts with cholecystectomy and intraoperative ultrasonography. The dissection starts with the right hepatic artery that is transected between clips. The right portal vein is isolated and a tie is passed around it. Right portal vein is transected between locked clips using Ligasure (LigasureVessel Sealing System Valleylab, Boulder, Colorado, USA). The dissection continues between retrohepatic cava and caudate lobe, short hepatic veins are isolated and interrupted by Ligasure, larger vessels are clipped with locked clips. Dissection in the retrohepatic region continues upward until the right hepatic vein. After that right hepatic vein is isolated and transected using vascular endostapler. Liver parenchyma is transected with harmonic scalpel and Ligasure using transient clamping of left portal pedicle. Tubular structures are clipped or coagulated by bipolar instrument. Right lobar bile duct is transected by endostapler. Specimen is placed into bag a removed from abdominal cavity through small incision.

**Results:** Two total laparoscopic right trisectionectomies were performed. The operative times were 420 and 290 min respectively. The average intraoperative blood loss was 300 ml and it was controlled laparoscopically in all cases. The postoperative 30-day mortality and morbidity was nil. The oncological radicality was R0 in both resections.

**Conclusion:** This approach seems to be safe and effective for the laparoscopic right trisectionectomy.

**Acknowledgement:** The work was supported by Research Project MZO 00179906 Ministry of Health Care, Czech Republic and Research Project 0FVZ0000503 of the Ministry of Defence, Czech Republic.

**Abstract ID: 0548** Specific Field: **Hepatobiliary and Pancreas Surgery**

**Mode of pres.: Video**  
**ISW 2011 Session 12.06**

**R0 pancreatoduodenectomy for borderline resectable pancreatic cancer in the presence of superior mesenteric vein invasion with neoadjuvant chemoradiotherapy and computer-assisted surgery planning**

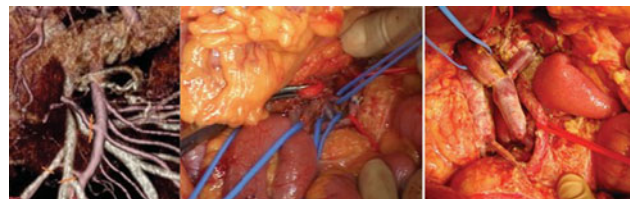Y. Abe [1], K. Takano [1], S. Kikuchi [1], O. Konno [1], M. Shimazu [2]

[1] Tokyo Medical University Hachioji Medical Center, Tokyo, Japan, [2] Tokyo Medical University Hachioji Medical Center, Japan

**Introduction:** Although surgery is still the only one that can achieve complete cure, surgery alone is not enough. Thus, we suggest that neoadjuvant therapy in combination with surgery could improve survival. We report the surgical approach in a case of locally advanced pancreatic cancer with neoadjuvant chemoradiotherapy and preoperative 3D-CT computer-assisted surgery planning (3D-CASP). **Material and Methods:** The patient was a man 62 years of age who had a locally advanced cancer that had originated in the pancreatic uncus and was found to have invaded the root of the mesentery, as well as superior mesenteric vein (SMV) and tumor abutment of superior mesenteric artery (SMA) involving one third of the circumference of the artery. He was treated with radiation (2.0 Gy  $\times$  25 Fr) and the combination chemotherapy of S-1 plus gemcitabine (S-1: 40 mg/m<sup>2</sup>/day day 1–14 and day 22–35, GEM 400 mg/m<sup>2</sup> iv, day 1, 8, 22 and 29). No adverse effect was occurred. Five weeks later from completion date, a reduction of the tumor markers and no progressive disease were observed by diagnostic imaging. 3D-CASP was performed to determine resectability and plan operative strategy.

**Results:** Pancreatoduodenectomy (PD) and resection of the transverse and ascending colons with a partial resection of SMV was undergone. 3D-CASP clarified the anatomical relationships between tumor and vessels and enabled determination of the transection line. Ileocolic vein, ileal veins, SMA and jejunal veins were exposed one by one at mesentery. A frozen section of superior mesenteric plexus was negative for cancer invasion so that R0 surgery was confirmed. Division of jejunal veins and ileal veins with reconstruction using both right external iliac vein and inferior mesenteric vein was performed according to plan by 3D-CASP. He is disease-free 6 months after surgery and undergoing adjuvant chemotherapy.

**Conclusion:** Although benefit from PD combined with SMV resection in the management of pancreatic adenocarcinoma with local venous invasion remains controversial, we suggest such an approach be considered particularly following completion of neoadjuvant therapy without systemic progression. 3D-CASP was particularly helpful in patient with borderline resectable pancreatic cancer to reduce risk for a margin-positive resection.



**Figure:** Intraoperative photograph

**Abstract ID: 0549** Specific Field: **Hepatobiliary and Pancreas Surgery**

**Mode of pres.: Video**  
**ISW 2011 Session 12.07**

**Isolated pancreatoduodenectomy with a mesenteric approach for pancreatic head cancer**

A. Nakao, A. Kanzaki, S. Yamada, T. Fujii, A. Sugimoto, S. Nomoto, Y. Kodera, S. Takeda

Nagoya University Graduate School of Medicine, Nagoya, Japan

**Introduction:** We have been performing non-touch isolation techniques in pancreatoduodenectomy with a mesenteric approach for pancreatic head cancer since 1981. In this procedure, we never manipulate the pancreas head region before treating its influent and effluent vessels by a mesenteric approach.

**Material and Methods:** First, we assess tumor infiltration to the vessels and extrapancreatic nerve plexus in accurate detail by intra-portal endovascular ultrasonography (IPEUS) for patients with suspected invasion of the portal vein (PV) or the second portion of the pancreatic head nerve plexus. The mesenteric approach enables us to perform lymph node dissection around the superior mesenteric artery (SMA) and the superior mesenteric vein (SMV) safely and to determine the feasibility of resection. In addition, this procedure makes subsequent portal vein reconstruction easier. Ligation of the inferior pancreatoduodenal artery is usually followed by dissection of the right side nerve plexus around the SMA in a mesenteric approach. Portocaval bypass is created using an antithrombogenic catheter (Anthon®) for patients suspected to require PV/SMV resection. After ligation and division of the gastroduodenal artery and PV/SMV resection, we mobilize the pancreatic head region from the retroperitoneum. PV/SMV reconstruction is conducted by two-point mounting end-to-end continuous sutures. Imanaga's procedure or modified Child's procedure is used for alimentary tract reconstruction.

**Results:** There were 220 patients with pancreatic head cancer underwent this procedure from January 2001 to December 2010, including 144 (66%) patients requiring PV/SMV resection. Operative time of 144 patients with PV/SMV resection was  $491 \pm 106$  min and estimated blood loss was  $1424 \pm 1129$  ml. Among the 144 patients underwent PV/SMV resection, 36 (25.0%) required blood transfusion. Operative time of 76 patients without PV/SMV resection was  $411 \pm 90$  min and estimated blood loss was  $966 \pm 559$  ml. Among the 76 patients without PV/SMV resection, 18 (23.7%) required blood transfusion. There were no operative deaths.

**Conclusion:** We believe this procedure is safe, ideal and effective for decreasing of blood loss during operation and prevention of scatter of tumor cells.

**Abstract ID: 0550**      Specific Field: **Hepatobiliary and Pancreas Surgery**

**Mode of pres.: Free Paper**  
**ISW 2011 Session 52.01**

**Impact of severe gastroesophageal varices on liver resection for hepatocellular carcinoma in cirrhotic patients**

C. C. Wu, S. B. Cheng, H. Z. Yeh, C. S. Chang

Taichung Veterans General Hospital, Taichung, Taiwan

**Introduction:** Liver resection for hepatocellular carcinoma (HCC) in cirrhotic patients with portal hypertension is usually not advocated. Presence of gastroesophageal varices (GEV) is a critical condition of portal hypertension, the role of liver resection for HCC in cirrhotic patients with severe GEV remains controversial.

**Material and Methods:** A retrospective review of 1073 cirrhotic patients who underwent liver resection for HCC between 1992 and 2009 was conducted. According to preoperative gastroendoscopic findings, these patients were divided into 3 groups; group A ( $n = 861$ ) no GEV, group B ( $n = 184$ ) presence of GEV with low risk (grade F1 or F2); group C ( $n = 28$ ) presence of GEV with high risk (grade F3 or presence of red-colored sign). The clinicopathological characteristics, early and long-term results of the

patients among the three groups were compared. Preoperative endoscopic ligation or sclerotherapy were performed on group C patients. Postoperative regular endoscopic surveillance was used in group B and C.

**Results:** The group B and C patients had higher incidence of thrombocytopenia and higher ICG 15-min retention rate (ICG R15) than group A patients. The ICG R15 was also higher in group C than group B. There were no differences in postoperative morbidity among the three groups. Five group A patients died of operation while no patients died in group B and C ( $P > 0.05$ ). The disease-free and overall survival rates among the three groups were also not significant.

**Conclusion:** With preoperative endoscopic ligation or sclerotherapy, liver resection for HCC remains justified in cirrhotic patients with severe GEV.

**Abstract ID: 0551**      Specific Field: **Hepatobiliary and Pancreas Surgery**

**Mode of pres.: Free Paper**  
**ISW 2011 Session 52.02**

**Ruptured liver tumors**

V. Velayutham, J. Sathyanesan, J. Damodaran, S. Perumal, R. Palaniappan, S. Rajagopal

Govt Stanley Medical College Hospital, Chennai, India

**Introduction:** Spontaneous rupture of hepatic tumors (which includes both benign and malignant liver tumors) is a life-threatening presentation, with an incidence of 3% to 14%, which carries significant morbidity and mortality. The aim of this study was to report a single center's experience of patients with ruptured liver tumors during a 10-year period.

**Material and Methods:** A retrospective review was performed of all patients who presented with ruptured HCC between 1999 and 2008. Data on clinical features, treatment strategies, and survival outcomes were collected.

**Results:** A cohort of 24 patients (18 male and 6 female) was identified. The median age at presentation was 48 years. Clinical presentations were abdominal pain in 20, distension in 10, shock in 10, worsening anemia and fall in haematocrit in 8.21 patients had malignant tumors (20 HCC, 1 angiosarcoma), 3 patients had benign lesions (2 adenomas and 1 focal nodular hyperplasia). The mean tumor size was 7.5 cm (range 4–14), and there was multifocal disease in 6 (25%) patients. Initial bleeding control was attempted by transarterial embolization (TAE) in 8 (33%) and it was successful in 7 patients. Surgery was the primary modality of management in 16 patients. The procedures performed were Rt hepatectomy in 3, Lt hepatectomy in 3 patients, Lt lateral segmentectomy in 2 cases, non anatomical resection in 2 patients and segmentectomy in 1. Hepatic artery ligation was done in 2 and perihepatic packing in 2 patients. Morbidity observed were bile leak in 2, intra abdominal sepsis in 2, pulmonary complications in 2 and posthepatectomy liver failure in 1. Mean hospital stay was 14 days. (10–28 days) .8/24 (33.3%) died. The causes of death were Coagulopathy in 4 patients, sepsis in 3 and post hepatectomy liver failure in 1. The follow up ranged from 6 months to 10 years.

**Conclusion:** Rupture of liver lesions is a life threatening event and requires a multidisciplinary approach. Primary hemostasis, followed by emergency or staged hepatic resection, is the treatment of choice. Patients who had no underlying liver disease had better prognosis than those who had cirrhosis.

**Abstract ID: 0552**      Specific Field: **Hepatobiliary and Pancreas Surgery**

**Mode of pres.: Free Paper**  
**ISW 2011 Session 52.03**

**Application of hepatectomy using forceps style vessel sealer to reduce intraoperative blood loss**

A. Nanashima, T. Abo, T. Sawai, T. Nagayasu

Nagasaki University, Nagasaki, Japan

**Introduction:** To reduce blood loss and transection time of hepatic parenchyma, the latest forceps-style vessel sealing device was applied in the present study.

**Material and Methods:** Control group was 59 cases in patients undergoing hepatectomy with crush clamp method with CUSA between 2000 and 2008. Since June 2008, forceps style vessel sealer was applied for hepatic transection in 42 cases including LigaSure precise in 35 cases and Harmonic Focus Curved sealer in 7 cases. A large hepatic vessels were cut by vascular linear stapler. Background characteristics, surgical records and patient outcomes between both groups were retrospectively compared.

**Results:** In segmentectomy or sectionectomy, injured liver disease were more significant in the LigaSure group and, however, intraoperative blood loss and use of transfusion were significantly lower in comparison with the control group (708 vs. 1579 ml, 13% vs. 41%;  $P < 0.05$ ). Transection and operative time was also lower in the vessel sealer group (33 vs. 56 min, 341 vs. 491 min;  $P < 0.05$ ). Incidence of abdominal infection was lower in the vessel sealer group (0 vs. 29%). In patients undergoing major hepatectomy, blood loss and transection time were significantly lower in the vessel sealer group (1054 vs. 2000 ml, 39 vs. 48 min;  $P < 0.05$ ). Incidence of abdominal infection and hospital stay period were lower in the vessel sealer group (0 vs. 21%, 21 vs. 36 days;  $P < 0.05$ ). In case of hepatectomy with lymphadenectomy or pancreatic resection, Harmonic Focus was quite useful.

**Conclusion:** Forceps style vessel sealer is a useful device to achieve bloodless hepatectomy, which should be associated with improvement of operative results.

**Abstract ID: 0553**      Specific Field: **Hepatobiliary and Pancreas Surgery**

**Mode of pres.: Free Paper**  
**ISW 2011 Session 52.04**

**Preoperative evaluation for liver surgery using 3D image processing software**

Y. Mise, N. Tanaka, T. Furuya, Y. Nomura, J. Matsumoto, M. Nagai, Y. Yoshida, D. Koike

Asahi General Hospital, Asahi, Japan

**Introduction:** With the advent of imaging technology, computer-assisted diagnosis and intervention have gained increasing interest. In liver surgery for malignancies, preserving a sufficient amount of liver parenchyma and yet acquiring oncological radicality are conflicting priorities. Preoperative imaging plays an important role in this regard, to assess the resectability and to choose the optimal surgical procedures. We applied recently developed software that enabled the calculation of vascular territories in each corresponding branch,

providing three-dimensional (3D) visualization of the complicated liver structure, and we assessed the efficacy of preoperative evaluation for liver surgery using this software.

**Material and Methods:** From April to December 2010, 21 consecutive patients underwent preoperative evaluation for liver surgery using 3D image processing software (Virtual hepatectomy). We used region-growing method software (Organs Volume Analysis; Hitachi Medico, Chiba, Japan), which is dedicated to research on image-based computer assistance in liver surgery.

**Results:** Virtual hepatectomy was performed to evaluate the 3D positional relationship between tumors and vasculature in 7 patients, and to predict postoperative liver remnant volume in 9 patients. In 5 patients with liver tumors invading the major hepatic vein, venous drainage volume was estimated to determine whether to sacrifice or reconstruct the involved vein. Among 19 patients, liver resection was not performed in 3 patients because of the progression of the disease. In the remaining 18 patients who underwent liver resection, no postoperative mortality occurred and the median hospital stay was 16 days.

**Conclusion:** Preoperative evaluation for liver surgery using image processing software was useful for selecting a safer procedure, enabling (1) to share the objective 3D image, (2) to predict postoperative liver remnant volume, and (3) to evaluate the need for venous reconstruction.

**Abstract ID: 0554**      Specific Field: **Hepatobiliary and Pancreas Surgery**

**Mode of pres.: Free Paper**  
**ISW 2011 Session 52.05**

**Acoustic radiation force impulse imaging predicts postoperative refractory ascites resulting from curative hepatic resection for hepatocellular carcinoma: a pilot study**

J. Muto, A. Taketomi, Y. Maehara

Graduate School of Medical Sciences, Kyushu University, Fukuoka, Japan

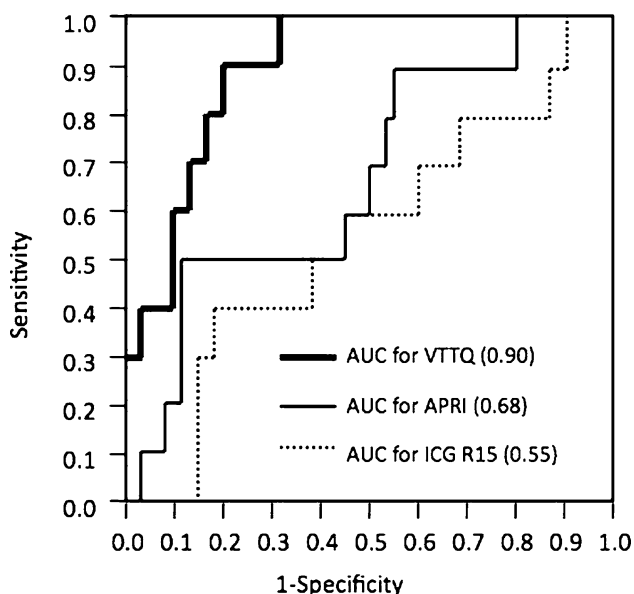
**Introduction:** Liver stiffness measurement using Virtual Touch.

**Material and Methods:** The study enrolled 50 consecutive patients between February 2008 and October 2010 whose preoperative VTTQ values were determined before they underwent curative hepatic resection for HCC. We assessed the relationship between postoperative complications and VTTQ values. The postoperative complications were defined using the Clavien classification.

**Results:** The study included 41 (82%) patients with chronic hepatitis and 9 (18%) with non-viral cirrhosis (45 and 5 patients were scored as Child-Pugh class A and B, respectively). The mean VTTQ value was 1.60 (m/s), which significantly correlated with the fibrosis stage ( $P = 0.0058$ ). The VTTQ value significantly correlated with refractory ascites only when postoperative complications occurred. Univariate and subsequent multivariate analyses revealed that the preoperative VTTQ value was the only independent risk factor for predicting the development of postoperative refractory ascites (cutoff, 1.68 cm/s;  $P = 0.007$ ; relative risk = 76.481). The area under the receiver operating characteristic curve for the diagnosis of refractory ascites using VTTQ values was 0.90, while those using APRI, and indocyanine green retention rate at 15 min values were 0.68, and 0.55, respectively.

**Conclusion:** These data suggest that the VTTQ value is a reliable surrogate marker for predicting postoperative refractory ascites before curative hepatic resection for HCC.





**Figure:** Areas under the ROC curves for predicting postoperative ascites by the VTTQ value, APRI, and ICG R15

**Abstract ID: 0555** Specific Field: **Hepatobiliary and Pancreas Surgery**

**Mode of pres.: Free Paper**  
**ISW 2011 Session 52.06**

**Adjusted aminotransferases as new serum markers for hepatocyte injury after extended liver resections—a case control study**

N. Arkadopoulos [1], K. Theodoraki [2], A. Pafiti [3], G. Kostopanagioutou [4], V. Smyrniotis [1]

[1] Athens University School of Medicine, 4th Department of Surgery, Athens, Greece, [2] Athens University School of Medicine, 1st Department of Anesthesiology, Athens, Greece, [3] Athens University School of Medicine, Pathology Laboratory, Athens, Greece, [4] Athens University School of Medicine, 2nd Department of Anesthesiology, Athens, Greece

**Introduction:** There is evidence that small-for-size liver grafts are more vulnerable to ischemia/reperfusion injury after liver transplantation. We hypothesized that ischemic injury is more pronounced in small liver remnants after major hepatectomies and that in these cases, adjusted aminotransferases would be more appropriate serum markers for evaluation of injury to the liver remnant.

**Material and Methods:** A retrospective case-control study was conducted referring to a 4 year period. Fifteen patients underwent extended hepatectomy with liver remnant mass less than 30% of standard liver weight (study group). These patients were matched 1:1 with patients subjected to minor liver resection, with liver remnants equal or more than 70% of standard liver weight, chosen from a computer database (control group). Matching criteria were warm ischemia time, intra-operative blood loss, surgical technique, comorbidities, parenchymal liver disease and Child scores. Ischemia/reperfusion injury was assessed with tissue caspase-3 activity post-operatively as well as peak aspartate aminotransferase (AST) values and a-glutathione S-transferase (a-GST) levels adjusted for liver remnant weight. In addition, caspase-3 activity and serum markers of

hepatocyte injury were correlated with the degree of postoperative portal hypertension.

**Results:** Caspase-3 activity was higher in patients with small liver remnants ( $22.66 \pm 6.57$  vs.  $12.60 \pm 4.06$  count per high power field,  $P < 0.001$ ). Serum markers of hepatocyte injury, when adjusted per g of liver remnant, were found to be higher in the study group in comparison to the control group (AST  $1.26 \pm 0.25$  vs.  $0.54 \pm 0.11$  UI g<sup>-1</sup>,  $P < 0.001$  and a-GST  $0.14 \pm 0.02$  vs.  $0.08 \pm 0.01$  UI g<sup>-1</sup>,  $P < 0.001$ ). Tissue caspase-3 expression in the small liver remnant group correlated with both AST and a-GST levels adjusted per g of liver remnant ( $r^2 = 0.51$ ,  $P = 0.005$  and  $r^2 = 0.71$ ,  $P < 0.001$ , respectively).

**Conclusion:** Liver remnants less than 30% of standard liver weight are much more susceptible to ischemia reperfusion injury than their counterparts with double size. Adjustment of aminotransferase levels to the liver remnant weight is a more accurate representation of hepatocyte injury.

**Abstract ID: 0556** Specific Field: **Hepatobiliary and Pancreas Surgery**

**Mode of pres.: Free Paper**  
**ISW 2011 Session 52.07**

**The surgical strategy for huge hepatocellular carcinoma**

T. Suehiro, K. Nomoto, T. Matsumata

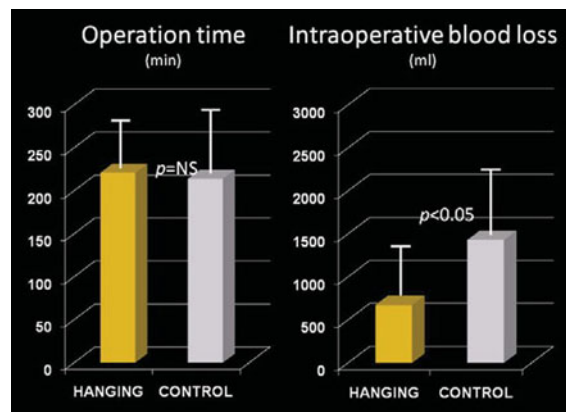
Saiseikai Yahata Hospital, Kitakyushu, Japan

**Introduction:** Liver resection for huge hepatocellular carcinoma (HCC) is difficult and high risk for intraoperative bleeding. The purpose of this study is to clarify liver hanging maneuver is safety and useful method for liver resection.

**Material and Methods:** Patients who underwent major liver resection for huge HCC (>10 cm) were studied. The patients were divided into two groups as follows; Hanging group ( $n = 14$ ), liver resection with liver hanging maneuver and a Control group ( $n = 21$ ). We performed hanging maneuver before and/or after mobilization the liver. Patient factors, intraoperative blood loss and operation time were compared between the two groups.

**Results:** The mean age of Hanging and Control group was  $65.6 + 14.0$  and  $64.6 + 12.9$ , respectively. Operation time and intraoperative blood loss of Hanging and Control group were  $221 + 47$  min,  $674 + 709$  ml and  $214 + 77$  min,  $1430 + 1445$  ml, respectively (Figure). Intraoperative blood loss and incidence of blood transfusion was significantly lower in Hanging group than Control group ( $P < 0.05$ , Figure). There was no significant difference between the groups in age, gender and operation time.

**Conclusion:** From our results, liver hanging maneuver is safety and useful method for liver resection for huge HCC. The most important point is to let tape go through surely right under the excision line of the liver.



**Figure:** Operative time and Intraoperative blood loss

**Abstract ID: 0557**      Specific Field: **Hepatobiliary and Pancreas Surgery**

**Mode of pres.: Free Paper**  
**ISW 2011 Session 52.08**

**Treatment strategy for HCC patients with advanced age 80 or more years-old**

K. Minami, S. Ueno, M. Sakoda, S. Iino, H. Kurahara, K. Ando, K. Maemura, S. Natsugoe

Kagoshima University School of Medicine and Dental Science, Kagoshima, Japan

**Introduction:** Recently, elevation of patients with hepatocellular carcinoma (HCC) in advanced age is noticed. In this study, results following several interventions in HCC patients with 80 or more years-old were compared with those with 65 or less years-old.

**Material and Methods:** Between 1990 and 2005, total of 1797 patients with primary HCC underwent to initial treatment such as hepatic resection (HR), ablation therapy, or transarterial chemoembolization (TACE) in the Kagoshima carcinoma-of-liver study group. Retrospective comparison was made between 62 patients equal to or more than 80 years-old (Elderly group) and 851 patients equal to or less than 65 years-old (Youth group).

**Results:** Total of 225 patients (Elderly  $n = 10$ ; Youth  $n = 215$ ) were treated by HR, 198 patients (Elderly  $n = 8$ ; Youth  $n = 190$ ) by ablation, and 469 patients (Elderly  $n = 42$ ; Youth  $n = 427$ ) by TACE. (1) Overall survival. In the cumulative 5-year survival rate, Elderly group showed a significantly low survival (9%) compared to Youth group (21%). (2) Comparison classified by treatment (HR, ablation, TACE). In terms of the frequency of each therapy, no differences were seen between the 2 groups. Although patients treated by TACE showed poorer survival than those received HR or ablation in Youth group, no clear difference during the 3 treatment was seen in Elderly group. When comparing both groups according to the therapy, the elderly patients showed poorer survival than the youth in HR and ablation, however, no significant difference was seen in TACE. (3) Multivariate comparisons about disease-free survival (DFS) and overall survival in each group. In DFS, size and the number of tumor were prognostic factors for Youth group; liver damage for Elderly group. HR was a good prognostic factor in both groups. On the other hand, in overall survival, size and the number of tumor, liver damage, were prognostic factors for Youth group; nothing for Elderly group. HR was necessarily not a good prognostic factor in Elderly group.

**Conclusion:** In HCC patients in Elderly group, HR might not fully contribute to overall survival as well as patients in Youth group. Taken together with complication and performance status, it should be respected to employ treatment with lower invasiveness.

**Abstract ID: 0558**      Specific Field: **Hepatobiliary and Pancreas Surgery**

**Mode of pres.: Free Paper**  
**ISW 2011 Session 52.09**

**Survival outcome of various treatment for hepatocellular carcinoma in Asia: a nationwide study**

C.-C. Yeh [1], C.-Y. Wu [2]

[1] China Medical University Hospital, Taichung, Taiwan,  
[2] Taichung Veterans General Hospital, Taichung, Taiwan

**Introduction:** Numerous hospital based studies were performed to compare efficacy between treatments for hepatocellular carcinoma

(HCC). However, effects of the treatments in survival outcomes remained undetermined in a large number of unselected patients in HCC pandemic region.

**Material and Methods:** We performed a nationwide retrospective cohort study via data from the Taiwan National Health Insurance Database. Patients with a diagnosis of HCC and receiving one of the treatments including liver transplantation, liver resection (LR), radiofrequency ablation (RFA), percutaneous ethanol injection (PEI) and trans-arterial chemoembolization (TACE) were enrolled. Cumulative overall survival and disease free survival as well as hazard ratios (HRs) were calculated.

**Results:** HCC patients receiving liver transplantation have the best overall survival, followed by RFA, LR, PEI, and TACE. As for disease free survival, liver transplantation is still the best, followed by LR, RFA, PEI, and TACE. In comparison with LR, risk of mortality is reduced by 35% in liver transplant (HR, 0.65;  $P < 0.05$ ) and 23% in RFA (HR, 0.77;  $P < 0.0001$ ). By contrast, in comparison with LR, PEI has an increased risk of mortality by 46% (HR, 1.46;  $P < 0.0001$ ) and TACE by 135% (HR, 2.35;  $P < 0.0001$ ). Regarding cancer recurrence, liver transplant has a reduced risk by 89% (HR, 0.11;  $P < 0.0001$ ) when compared to LR. Contrarily, RFA is associated with an increased risk of recurrent HCC by 43% (HR, 1.43;  $P < 0.0001$ ) and PEI by 80% (HR, 1.8;  $P < 0.0001$ ) as compared to LR.

**Conclusion:** Liver transplant has the best overall survival and disease free survival among various treatment modalities for HCC. RFA bring a better overall survival but poorer disease free survival as compared with LR.

**Abstract ID: 0559**      Specific Field: **Hepatobiliary and Pancreas Surgery**

**Mode of pres.: Free Paper**  
**ISW 2011 Session 52.10**

**Surgical strategy in the treatment of hepatolithiasis: hepatectomy is better than nonhepatectomy**

J. Dong [1], W. Lv [1], W. E. B. Z. H. I. Zhang [1], Z. Huang [1], P. Bie [2], S. Wang [2], J. Cai [2], Han [3]

[1] Hospital & Institute of Hepatobiliary Surgery, Chinese PLA General Hospital, Beijing, China, People's Republic, [2] Institute of Hepatobiliary Surgery, Southwest Hospital, Chongqing, China, People's Republic, [3] Hospital & Institute of Hepatobiliary Surgery, China, People's Republic

**Introduction:** In treating hepatolithiasis, a satisfactory result can only be obtained by employing the proper operative procedures. The aim of the present study was to identify risk factors that are responsible for poor outcomes and to select an appropriate approach to the treatment of this disorder.

**Material and Methods:** Between June 1976 and June 2009, 1951 patients with hepatolithiasis were admitted to the Institute of Hepatobiliary Surgery, Southwest Hospital (Chongqing, China), 22 (1.1%) patients with a pathologic diagnosis of cholangiocarcinoma associated with intrahepatic stones were excluded, and 1929 cases were studied. The perioperative and long-term outcomes were analyzed in patients with or without hepatic resection. The independent effect of significant variables associated stone recurrence was assessed using stepwise logistic regression.

**Results:** The hospital mortality rates were 0.3%(3/1174) and 0.1%(1/755) after hepatectomy and liver-preserving surgery, respectively ( $P = 1.000$ ); The immediate stone clearance rates after hepatectomy and liver-preserving surgery were 79.8% and 56.0%, respectively

( $P < 0.001$ ); Additional postoperative choledochoscopic lithotripsy through the T-tube tract raised the clearance rates to 89.3% and 77.1%, respectively ( $P < 0.001$ ). Recurrent stones developed in 126 (12.0%) of 1048 patients who had no final residual stones after postoperative choledochoscopic lithotripsy in hepatectomy group, while 140 (24.1%) of 582 patients in liver-preserving surgery group ( $P < 0.001$ ). Nonhepatectomy (HR = 2.590; 95% CI: 1.513–4.436;  $P = 0.001$ ), Caudate lobe stones (HR = 2.060; 95% CI: 1.044–4.064;  $P = 0.037$ ) and bile duct stricture (HR = 2.087; 95% CI: 1.169–3.724;  $P = 0.013$ ) were found to be independently correlated with the risk of developed stone recurrent.

**Conclusion:** In this long-term follow-up study, nonhepatectomy, Caudate lobe stones, biliary tricture were associated with recurrent stones after surgery. Partial hepatectomy was shown to be a safe and effective treatment.

**Abstract ID: 0560**      Specific Field: **Hepatobiliary and Pancreas Surgery**

**Mode of pres.: Free Paper**  
**ISW 2011 Session 71.01**

**Ultrasonography-guided hepatic tumor resection using a real-time virtual sonography with indocyanine green navigation**

K. Kasuya [1], B. Kyo [1], T. Matsudo [1], Y. Nagakawa [1], Y. Suzuki [1], A. Tsuchida [1], M. Shimazu [2], T. Aoki [1]

[1] Tokyo Medical University, Tokyo, Japan, [2] Hachioji Medical Center of Tokyo Medical University, Tokyo, Japan

**Introduction:** Surgical resection of hepatic tumors are determined using intraoperative US findings. To visualize hepatic tumors invisible on conventional intraoperative contrast-enhanced US, diagnostic MRI images were brought into the operating room using real-time virtual sonography (RVS). RVS allows the incorporation of CT or MRI data into a personal computer and the simultaneous visualization of multi-planar reconstruction CT or MRI images corresponding to the site of the US probe obtained using a magnetic sensor. The site of the tumor as a target was marked employing a US-guided puncture method using ICG, allowing the observation of fluorescence using an infrared camera (PDE). Surgical resection under fluorescence navigation was performed.

**Material and Methods:** A 57-year-old female. She underwent right hemicolectomy with D3 dissection for ascending colon cancer in 2009. Four months after the operation, MRI suggested metastasis in the liver S4 and S7. Preoperative chemotherapy with m-FOLFOX and bevacizumab (5 mg/kg) was performed 3 times. Contrast-enhanced US allowed the visualization of the metastatic lesion in S4 but not the lesion in S7.

**Results:** Surgical method: After general anesthesia, a 23-G PEIT needle was percutaneously inserted into the lesion in S7 visualized using MRI under the guidance of RSV with incorporated MRI image data. Subsequently, 500 ml of an ICG-ethanol mixture was injected into the liver. After laparotomy, fluorescence was observed from the liver surface using a PDE. During liver resection, the presence/absence of fluorescence on the cut liver surface was observed using a PDE to determine the presence/absence of any residual tissue in the planned resection area (fluorescent area). After hepatic resection, fluorescence in the resected specimen was confirmed. The hepatic tumor in S7 was a metastatic lesion (3 mm in diameter) containing viable cancer cells.

**Conclusion:** Advances in preoperative chemotherapy and CT or MRI for unresectable liver metastasis have presented new problems concerning the surgical techniques for the intraoperative US-guided resection of US-invisible hepatic tumors, i.e., US-guided hepatic

resection. In this study, our method of US-invisible hepatic tumor resection under RVS navigation with ICG was helpful in resecting such tumors.

**Abstract ID: 0561**      Specific Field: **Hepatobiliary and Pancreas Surgery**

**Mode of pres.: Free Paper**  
**ISW 2011 Session 71.02**

**ICG-fluorography is very useful for real time identification of hepatocellular carcinoma**

Y. Morita, T. Sakaguchi, H. Konno

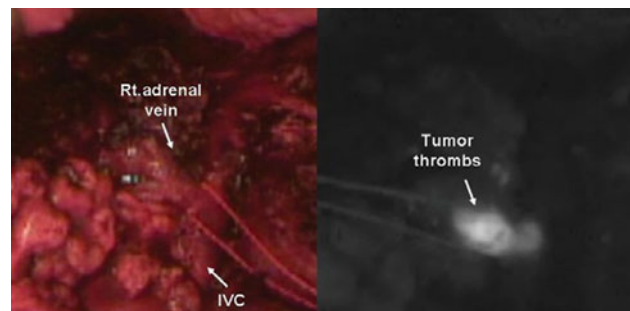
Hamamatsu University School of Medicine, Hamamatsu, Japan

**Introduction:** Hepatocellular carcinoma (HCC), including intrahepatic original tumor and extrahepatic metastasis, is sometimes missed macroscopically or under ultrasonography even after laparotomy. Indocyanine green (ICG), an agent to measure liver function, becomes fluorescent under near-infrared (NIR) light, after binding to serum proteins. We previously reported ICG-fluorography is very useful to prevent postoperative bile leak after hepatectomy or choledochojejunostomy. Moreover, the liver tumors with deposition of preoperatively administered ICG become clearly detectable under a NIR camera. We also use ICG-fluorescence imaging for intraoperative land mark and postoperative histological examination. We present two cases in which ICG-fluorography were very useful.

**Material and Methods:** ICG (Diagnogreen; Daiichi Sankyo Co., Ltd., Tokyo, Japan) (0.5 mg/kg) was injected for evaluation of hepatic function few days prior to the operation. After laparotomy, operative fields were observed with the NIR camera system (PDE<sup>TM</sup>; Hamamatsu Photonics K. K., Hamamatsu, Japan).

**Results:** Case1: The recurrent tumor of HCC beside the inferior vena cava (IVC) was found on enhanced abdominal computed tomography (CT) 2 years after right hepatectomy in a 73 year-old man. After laparotomy, we could hardly detect the tumor by visual inspection. However, a NIR camera clearly visualized the tumor around the stump of right hepatic vein. Case2: The intrahepatic recurrence in the segment 7 and metastasis of the right adrenal gland were found on enhanced abdominal CT 15 months after the partial liver resection for HCC in the segment 6 in a 58 year-old man. The venous tumor thrombus, originating from the adrenal metastasis, extended to the IVC through the right adrenal vein. We checked the ICG-fluorescence imaging (Figure) and safely performed side-clamp of IVC. The ICG-based fluorography was very useful to determine the IVC-clamping site.

**Conclusion:** ICG-fluorescence imaging clearly reveals the tumor location even in the case of the polysurgery or massive vascular infiltration. ICG-fluorography is very useful for real time identification of HCCs.



**Figure:** Visual inspection and ICG fluorography around the inferior vena cava and the right adrenal vein



**Abstract ID: 0562**Specific Field: **Hepatobiliary and Pancreas Surgery**Mode of pres.: **Free Paper**  
ISW 2011 Session 71.03**Detection of intrahepatic veno-venous shunt by three-dimensional reconstruction using multidetector-row computed tomography during angiography**

T. Sakaguchi [1], S. Suzuki [2], H. Konno [1]

[1] Hamamatsu University School of Medicine, Hamamatsu, Japan,  
[2] Iwata City Hospital, Iwata, Japan

**Introduction:** The hepatic vein (HV) could be removed during hepatectomy if an effective intrahepatic veno-venous shunt (vv-shunt) exists. We previously reported that efficient intrahepatic vv-shunt, such as right hepatic vein (RHV)-middle hepatic vein (MHV), RHV-inferior RHV (IRHV), RHV-superficial RHV, was found in 20 of 51 subjects under the occlusion venography of the right hepatic vein (Surgery 147(6):805–810, 2010). The remaining 20 and 11 subjects showed the minimal vv-shunt, such as RHV-short hepatic vein, and no shunt, respectively. In this study, we evaluated the detection rate of intrahepatic vv-shunt under three-dimensional (3D) reconstruction using multidetector-row computed tomography (MDCT).

**Material and Methods:** Hepatic veins were reconstructed using computer software in 55 patients undergoing MDCT during angiography, scheduled for hepatectomy.

**Results:** Three and 2 patients showed RHV-MHV and RHV-IRHV shunt under 3D venography, respectively. The minimal vv-shunt was undetectable in any of the patients. In total, the efficient vv-shunt was found in only 9.1% (5/55) of patients.

**Conclusion:** Although the detection rate of intrahepatic vv-shunt by 3D venography is lower than that by occlusion venography, vv-shunt, especially the efficient one, could be observed under 3D venography. Further study is needed to determine whether 3D venography is sufficient to detect the efficient intrahepatic vv-shunt.

**Abstract ID: 0563**Specific Field: **Hepatobiliary and Pancreas Surgery**Mode of pres.: **Free Paper**  
ISW 2011 Session 71.04**A novel navigation system for anatomical liver resection**M. Ueno, K. Uchiyama, M. Tani, M. Kawai, S. Ozawa,  
Y. Shigekawa, H. Yamaue

Wakayama Medical University, Wakayama, Japan

**Introduction:** In performing hepatectomy for hepatocellular carcinoma, anatomical resection is desirable to control intra-hepatic metastasis or to reduce postoperative complications.

Previously injecting indigo carmine into the portal vein or ligating the glissonian pedicle where flows tumor-bearing area has been used for liver segmentation. Although the demarcation could be clearly visualized on the liver surface, this technique could not keep the visualization nor perform re-estimation about the cut surface during resection.

Recently, near-infrared fluorescence (NIRF) imaging under indocyanine green (ICG) injection and contrast enhancement intraoperative ultrasonography (CEIOUS) were provided and progressed the intraoperative diagnosis.

Using advantages of these techniques, we aimed to develop a novel navigation system for anatomical liver resection.

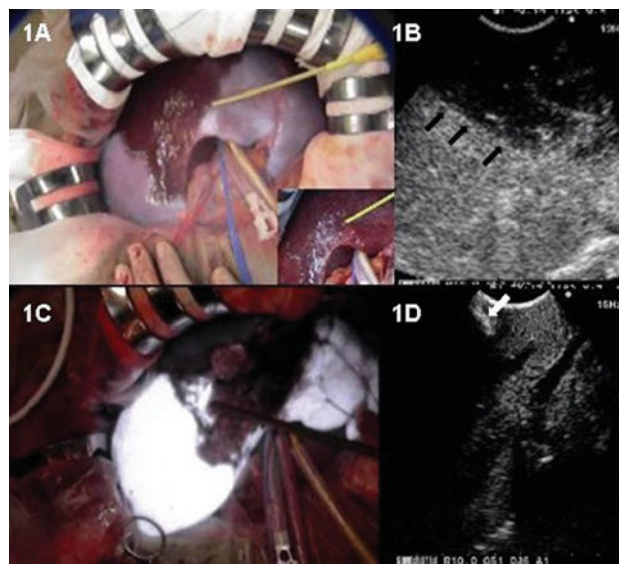
**Material and Methods:** In this preliminary study, 8 patients with HCC were administered anatomical resection with our new navigation system.

Navigation of anatomical liver resection was performed as follows: (1) under ligation of the glissonian pedicle where flows the planned liver resection area, ICG was intravenously injected and observed the demarcation area using NIRF imaging system (Hyper-eye Medical System, MIZUHO, Japan). (2) Ultrasound contrast agent (Sonazoid, Daiichisankyo, Japan) was also injected intravenously and CEIOUS was performed and observed intrahepatic demarcation. (3) During liver resection, NIRF imaging and CEIOUS were performed several times and re-estimated the accurate direction of anatomical resection.

**Results:** In this study, segmentectomy of the segment 8 ( $n = 3$ ), anterior sectionectomy ( $n = 2$ ), lobectomy ( $n = 2$ ) and posterior sectionectomy ( $n = 1$ ) were performed.

In all of the cases, the demarcation of the planned liver resection area was clearly visualized by NIRF imaging and CEIOUS (Figure a, b). This visualization was sustained during liver resection. By observing cut surface with NIRF imaging and CEIOUS, accurate direction of anatomical resection could be recognized (Figure c, d). There were no adverse effects related to our new navigation system.

**Conclusion:** We demonstrated here that the navigation system using NIRF imaging and CEIOUS is a novel and reliable technique during anatomical liver resection.



**Figure:** Surface and intrahepatic demarcation of the liver by NIRF imaging (a, c) and CEIOUS (b, d). *Black arrows*; demarcation line. *White arrow* cut surface

**Abstract ID: 0564**Specific Field: **Hepatobiliary and Pancreas Surgery**Mode of pres.: **Free Paper**  
ISW 2011 Session 71.05**Hepatectomy for HCC in non-cirrhotic liver with obstructive jaundice due to bile duct tumor thrombi: is it a reasonable primary therapeutic strategy with survival benefit?**



M. A. Johnson, C. Subramaniam

Kanyakumari Govt. Medical College Hospital, Asaripallam,  
Nagercoil, Tamilnadu, India

**Introduction:** Obstructive jaundice due to Bile Duct Tumor Thrombi is an uncommon presenting feature of Hepatocellular Carcinoma (HCC) reported in about 2–9% (Okuda & Nakashima series) and 12% (Hong Kong study group) of cases.

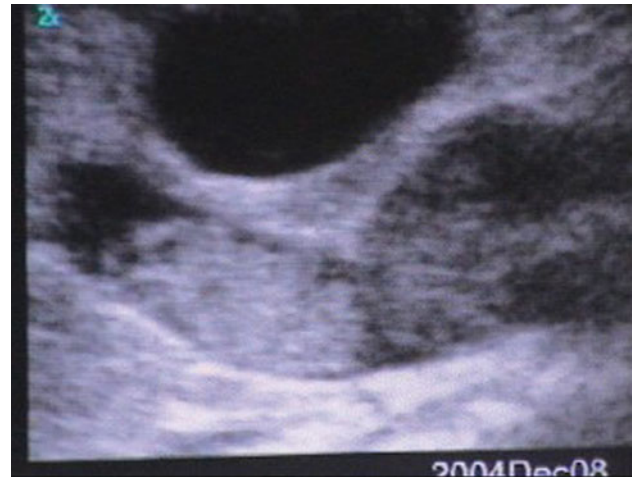**Material and Methods:** From 1995 to 2007, out of 156 HCC patients, 19 (12.1%) with non-fibrolamellar-type HCC and bile duct tumor thrombi in non-cirrhotic liver were analyzed. The operative procedures included right hepatectomy with thrombectomy through choledochotomy and T-tube drainage ( $n = 8$ ), extended right hepatectomy combined with extrahepatic bile duct excision ( $n = 3$ ), left hepatectomy ( $n = 6$ ), extended left hepatectomy ( $n = 1$ ) and left lateral segmentectomy ( $n = 1$ ).

**Results:** Biliary tumor thrombilocated in the right and left hepatic ducts in two, free floating in the common bile duct in 9, and extended across the confluence of the right and left hepatic ducts in 8 patients. Portal vein invasion found in 4 patients (right branch  $n = 1$ , left branch  $n = 1$ , right posterior branch  $n = 1$ , right branch to stem  $n = 1$ ). Postoperative morbidity was 31.5% ( $n = 6$ ), which included bile leak in 4 (21.05%) patients. One patient died of postoperative liver failure (mortality rate 5.2%). The tumor recurrence rates intrahepatic in 68.4%, extrahepatic in 21.0% and both intrahepatic and extrahepatic in 10.5%. The 1, 3 and 5-year survival rates 78.9%, 47.3% and 10.5% with a median survival time of 24.8 months.

**Conclusion:** Presence of bile duct tumor thrombi in HCC patients should not be considered as advanced disease or inoperable lesion. When technically feasible, a formal hepatic resection is the first-line treatment option in a subset of HCC patients with obstructive jaundice due to bile duct tumor thrombi in non-cirrhotic liver with large-sized tumors. It can achieve better quality of life with significant improvement in survival.

**Table** Characteristics of HCC

Parameter	Total number( $n = 19$ )
Tumor size $\geq 10$ cm	$n = 5$
Satellite lesions (+)	$n = 5$
Major liver resection	$n = 18$
Surgical margin $\geq 1$ cm	$n = 13$
Edmondson and Steiner grading	
Low grade (GrI + II)	$n = 12$
High grade (GrII + III)	$n = 7$
Tumor encapsulation/capsule formation (+)	$n = 12$
Capsule invasion (+)	$n = 4$
Macroscopic vascular invasion (+)	$N = 4$
Microscopic vascular invasion (+)	$N = 9$
Tumor rupture (+)	$N = 5$
Tumor stage (TNM)	
Stage I	$N = 6$
Stage II	$N = 4$
Stage III	$N = 9$



**Figure:** USG picture of bile duct tumor thrombus

**Abstract ID: 0565**

Specific Field: **Hepatobiliary and Pancreas Surgery**

Mode of pres.: Free Paper  
ISW 2011 Session 71.06

**Preoperative intra-arterial administration of carboplatin, adriamycin plus mitomycin (CAM) for hepatocellular carcinoma with extensive vascular invasion**

Y. Kato [1], Y. Tanahashi [1], T. Tokoro [1], J. Yoshida [1], T. Kagawa [1], C. Takeura [1], A. Sugioka [2]

[1] Department of Surgery, Fujita Health University School of Medicine, Toyoake, Aichi, Japan, [2] Fujita Health University School of Medicine, Japan

**Introduction:** Hepatocellular carcinoma (HCC) with advanced vascular invasion is rarely amenable to resection and even in resected patients the outcome is poor. We retrospectively studied the impact of preoperative hepatic arterial one-shot infusion of carboplatin, adriamycin and mitomycin (CAM) on the outcome of resection in this group of patients.

**Material and Methods:** In a total of 51 patients, we resected HCCs involving the right and/or left first branch or the main trunk of the portal vein, or those involving the major hepatic veins or the inferior vena cava (IVC). In these patients, tumors were resected by hepatectomies in conjunction with extirpation of tumor thrombi (TT). TT extending up to the second branches of the opposite-side portal vein were cored out in 5 patients. TT involving IVC were extirpated using cardio-pulmonary bypass ( $n = 2$ ) or intra-pericardial IVC cross-clamping ( $n = 4$ ) in 6. Of the resected 51 patients, 41 received CAM preoperatively and 10 did not (surgery-alone group). Of the 41, 16 were diagnosed to be CAM-effective by images and tumor markers (CAM-effective group), and in the other 25, CAM was ineffective (CAM-ineffective group). Survival and recurrence were compared among the three groups.

**Results:** CAM was well tolerated with minimal side effects. Overall 5-year survival in surgery-alone, CAM-ineffective and CAM-effective groups was 0%, 0% and 63%, and 50% survival time was 3, 6 and 69 months, respectively. Disease-free 5-year survival was 0%, 0% and 11%, and 50% disease-free survival time was 3, 2 and 20 months, respectively. These results suggest significantly better postresection outcome in CAM-effective group. Mode of recurrence was different

between CAM-effective and CAM-ineffective groups. In the former group, 4 patients had no recurrence, and 8 in the liver, 2 in distant organs, and 1 as TT. In the latter, 6 had recurrence in the liver and 14 distant organs.

**Conclusion:** Tumor response to CAM may predict oncologic outcome of resection for HCCs with extensive vascular invasion, and CAM may be a simple and safe method to potentially even improve outcome in select patients.

**Abstract ID: 0566**      Specific Field: **Hepatobiliary and Pancreas Surgery**

**Mode of pres.: Free Paper**  
**ISW 2011 Session 71.07**

**Increased liver-infiltrating CD8 + FoxP3 + regulatory T cells are associated with tumor stage in hepatocellular carcinoma patients**

Z. Yang [1], J. Dong [2]

[1] Institute of Hepatobiliary Surgery, Southwest Hospital, Chongqing, China, People's Republic, [2] Hospital & Institute of Hepatobiliary Surgery, Chinese PLA General Hospital, Beijing, China, People's Republic

**Introduction:** Background: Hepatocellular carcinoma (HCC) is the most common primary malignant tumor of the liver, and patients who are diagnosed with this tumor typically have a poor prognosis. The suppressive effects of CD4<sup>+</sup> FoxP3<sup>+</sup> regulatory T cells on anti-tumor immune response in HCC have been studied in great detail. CD8<sup>+</sup> FoxP3<sup>+</sup> regulatory T cells have recently been detected in tumors; however, the role of CD8<sup>+</sup> FoxP3<sup>+</sup> regulatory T cells in HCC is still unknown.

**Material and Methods:** 48 patients who diagnosed as primary hepatocellular carcinoma received radical resection during April 2008–December 2009 were studied. 10 liver transplantation Donors were served as controls. The frequency and phenotype of CD8<sup>+</sup> FoxP3<sup>+</sup> regulatory T cells were analyzed by multicolor flow-cytometry in liver of HCC patients and healthy donors.

**Results:** We observed that the percentage of these cells in HCC patients was significantly higher than that observed in healthy control donors ( $P = 0.0155$ ); their phenotype was close to that of CD4<sup>+</sup> regulatory T cells. Furthermore, we show that CD8<sup>+</sup> FoxP3<sup>+</sup> regulatory T cells are activated and act as effector memory cells (EM, CD45RA<sup>-</sup>CCR7<sup>-</sup>CD27<sup>+/-</sup>CD28<sup>+</sup>). Most importantly, a higher percentage of intrahepatic CD8<sup>+</sup> FoxP3<sup>+</sup> regulatory T cells was found in patients with advanced HCC than in those with early HCC in terms of tumor-node-metastasis (TNM) stage (stage I vs. III,  $P = 0.0007$ ).

**Conclusion:** These data suggest that CD8<sup>+</sup> FoxP3<sup>+</sup> regulatory T cells may contribute to HCC immune escape and disease progression.

**Abstract ID: 0567**      Specific Field: **Hepatobiliary and Pancreas Surgery**

**Mode of pres.: Free Paper**  
**ISW 2011 Session 71.08**

**MMP-9 is a key mediator in the progression of liver failure after massive hepatectomy in experimental mice model**

N. Ohashi [1], J. Nguyen [2], A. Nakao [1]

[1] Nagoya university, Nagoya, Japan, [2] Mayo Clinic Jacksonville, Jacksonville, USA

**Introduction:** Massive hepatectomy is a potential therapy for cure for huge primary and metastatic liver tumor. Preoperative evaluation and innovation of surgical procedure contribute to safer hepatectomy to reduce risks for liver failure(LF), however, the prognosis of LF, so-called small-for-size-liver (SFSL) syndrome is devastating. Nevertheless, precise mechanism of liver dysfunction in SFSL syndrome is not fully understood.

**Material and Methods:** 80% partial hepatectomy (PH) were performed in C57BL/6 mice. Survival rate after 80% PH was almost 40% and we evaluated the histology in remnant liver. To clarify the early alterations of remnant liver after 80% PH, remnant liver was harvested 6 h after surgery and separated by their histological findings. Comparison of status of cytokines and several proteins related with liver regeneration were analyzed between healthy liver and failing liver by Western blot (WB) and ELISA analysis. Activity of Matrix Metalloproteinase (MMP) was analyzed by zymography. Localization of protein was analyzed by immunohistochemical (IHC) staining. Monoclonal antibody and broadband MMP inhibitor GM6001 were administrated for blockade of MMP in animal experiment.

**Results:** Multifocal necrosis nodules were observed in liver remnant with LF, whereas little necrosis were obvious in healthy regenerating liver. Most necrosis nodules were accompanied with microhemorrhage. Necrotic change occurred in about half of the harvested remnant liver at 6 h after 80% PH, suggesting that progressive necrosis is main cause of LF after 80% PH in mice. Serum ALT level in mice with necrotic nodules in remnant liver is significantly higher than in mice without necrosis changes. There were no difference in IL-6, IL1-beta, TNF-alpha and HGF alteration in serum according to the existence of necrosis. Enhancement of MMP-9 was observed in remnant liver with necrosis by WB and zymography analysis. Expression of MMP-9 was mainly localized in infiltrated cell related with necrosis change in liver. Blockade of MMP-9 with monoclonal antibody and GM6001 attenuates the liver injury 6 hours after 80% PH.

**Conclusion:** Necrosis is a main mechanism involved in the process of LF of SFSL syndrome in mice. MMP-9 is one of the important regulators in necrosis formation after massive hepatectomy.

**Abstract ID: 0568**      Specific Field: **Hepatobiliary and Pancreas Surgery**

**Mode of pres.: Free Paper**  
**ISW 2011 Session 71.09**

**Options in the management of neuroendocrine liver metastases**

V. Velayutham, J. Sathyasesan, J. Damodaran, A. Pichaimuthu, S. Eswaran, S. Rajagopal

Govt Stanley Medical College Hospital, Chennai, India

**Introduction:** Many neuroendocrine tumors (NETs) have a tendency to metastasize to the liver. In case of limited number of metastases, liver surgery or radiofrequency ablation (RFA) may result in apparently total clearance of metastases. However, it is not clear whether such therapy will provide symptom reduction or increased survival. Our objective was to analyse the options in the management of neuroendocrine tumours with liver metastases and we also sought to determine the effect of surgical resection, ablation, embolization or combination of these modalities in patients with liver-only neuroendocrine metastases with respect to symptom relief and survival.

**Material and Methods:** Between January 2004 and May 2010, 42 Patients undergoing operations or interventions for neuroendocrine liver metastases from any primary were identified from a prospective

liver database. Recorded data and medical record review were used to analyse the type of procedure, length of hospital stay, peri-operative morbidity, tumour recurrence, progression, and survival.

**Results:** Results: The median age was 40.8 years (range 16–64 years). 48.3% of patients were female. 42 patients included 28 carcinoids, 12 islet cell tumors, 2 nonfunctioning tumors from unknown origin. Thirty-six patients underwent surgical therapy, including anatomical liver resection ( $n = 22$ ), ablation ( $n = 4$ ), or combined resection and ablation ( $n = 10$ ). Hepatic artery embolization was performed in 6 patients. No difference was noted in the percentage of liver involved with tumor between the 2 groups. An association of improved survival was noted in patients treated surgically, with a 3-year survival of 83% for patients treated by surgical resection alone or in combination, compared with 31% in patients treated with medical therapy or embolization. No difference in palliation of symptoms was noted among the 2 treatment groups.

**Conclusion:** Early and aggressive surgical management of hepatic metastases from neuroendocrine tumours is associated with significant long-term survival rates. Radiofrequency ablation either alone or in combination with surgery is a reasonable option if a lesion is unresectable.

**Abstract ID: 0569**      Specific Field: **Hepatobiliary and Pancreas Surgery**

**Mode of pres.: Free Paper**  
ISW 2011 Session 71.10

**Detection of liver metastases of pancreatic cancer: utility of combined helical computed tomography during arterial portography with biphasic computed tomography-assisted hepatic arteriography**

Y. Ikuta [1], H. Takamori [2], Y. Sakamoto [1], S. Abe [1], O. Nakahara [1], T. Beppu [1], H. Baba [1]

[1] Department of Gastroenterological Surgery, Graduate School of Medical Sciences, Kumamoto University, Kumamoto, Japan, [2] Kumamoto University, Japan

**Introduction:** Even after curative resection of pancreatic cancer, most patients suffer recurrence. A high recurrence rate of liver metastases in the early period after surgery might implicate that liver metastases are present at the time of operation, but below the threshold of detection. Therefore, more precise evaluation for hepatic lesions is necessary because accurate detection of liver metastases has major implications in guiding both appropriate treatment and defining prognosis. This study was designed to define the diagnostic advantage of computed tomography during arterial portography combined with computed tomography-assisted hepatic arteriography (CTAP + CTHA) for preoperative detection of liver metastases secondary to pancreatic cancer compared with that of multidetector computed tomography (MDCT).

**Material and Methods:** From January 2002 to August 2010, we retrospectively studied 237 consecutive patients with pancreatic cancer. MDCT was performed on 202 patients prior to preoperative visceral angiography. One hundred seventy-two patients underwent CTAP + CTHA at the time of preoperative angiography.

**Results:** There were 99 women and 138 men in this study. The average age of the patients was 65.0 years. Of 237 patients, 222 were included in extrapancreatic diseases (39 in T3, 183 in T4) according to the TNM classification. The primary lesion of the pancreas was located in the head for 146 patients, in the body for 58, and in the tail for 33 patients. Liver metastases were identified in 42 patients by means of MDCT. Of 129 patients who underwent CTAP + CTHA, 52

patients (40.3%) were diagnosed as having liver metastases, which could not be detected by MDCT. These tumors missed by MDCT ranged from 3 to 18 mm in size. The sensitivity and specificity of CTAP + CTHA versus MDCT were 92.6% versus 47.4% and 85.6% versus 98.4%, respectively.

**Conclusion:** The combination of CTAP and CTHA is useful to confirm liver metastases and can potentially offer more accurate staging of pancreatic cancer compared with MDCT.

**Table** Detection of the liver metastases

	MDCT ( $n = 202$ )	CTAP + CTHA ( $n = 172$ )
Sensitivity	47.4% (37/78)	92.6% (63/68)
Specificity	98.4% (122/124)	85.6% (89/104)
Positive PV	94.9% (37/39)	80.8% (63/78)
Negative PV	74.8% (122/163)	94.7% (89/94)
Overall accuracy	78.7% (159/202)	88.4% (152/172)

**Abstract ID: 0570**      Specific Field: **Hepatobiliary and Pancreas Surgery**

**Mode of pres.: Free Paper**  
ISW 2011 Session 81.01

**Duodenum, biliary tract and spleen preserving total pancreatectomy for pancreatic neoplasms**

T. Hatori, A. Kimijima, I. Fujita, T. Furukawa, M. Yamamoto  
Tokyo Women's Medical University, Tokyo, Japan

**Introduction:** Total pancreatectomy (TP) is sometimes performed to treat low-grade malignant neoplasms that are spreading to the entire pancreas. However, TP impairs quality of life, due to the resulting loss of pancreatic exocrine and endocrine function, and an organ preserving procedure should be chosen to minimize the impact of pancreatic dysfunction. We performed seven duodenum-preserving TPs (DPTs) including two duodenum, biliary tract and spleen preserving procedure on patients with low-grade malignant neoplasms of the entire pancreas and we introduce our operative results and technique by video.

**Material and Methods:** The biliary tract and spleen preserving DPTP is performed with the objective of preserving the arterial arcade of the posterior pancreas so as to maintain good blood flow in the duodenum and biliary tract. Care must also be taken to preserve the splenic artery and vein to protect the spleen. The biliary tract and spleen preserving DPTP was performed on two patients with the intraductal papillary mucinous neoplasm (IPMN). The bile duct and spleen preserving procedure was performed on two patients with hereditary pancreatic carcinoma with pancreatic intraepithelial neoplasia-3 (PanIN-3) and IPMN. The spleen preserving procedure was performed on two patients with IPMN and DPTP with bile duct resection and splenectomy was performed on a patient with multiple metastases of the entire pancreas from renal cell carcinoma.

**Results:** Mortality rate was zero. The delayed gastric emptying was observed in one patient and the bile duct stenosis was observed in one patient. All patients were placed on megadose of pancreatic enzyme

replacement therapy and given a daily dose of insulin of approximately 30 U. Tumor recurrence and fatty liver were not observed in all patients, and the hemoglobin A1c (HbA1c) levels have been maintained at around 7–8%.

**Conclusion:** DPTP is a useful organ-preserving procedure for low-grade malignant neoplasms spreading within the entire pancreas.

**Abstract ID: 0571**      Specific Field: **Hepatobiliary and Pancreas Surgery**

**Mode of pres.: Free Paper**  
**ISW 2011 Session 81.02**

**Factors predicting lymph node yield in patients undergoing pancreaticoduodenectomy for pancreatic and ampullary malignancy**

M. Sierzega, T. Kowalczyk, K. Figula, J. Kulig

Jagiellonian University Medical College, Krakow, Poland

**Introduction:** Several studies have recently emphasised the negative effects of inadequate lymph node yield in gastro-intestinal malignancies, including pancreatic and ampullary cancer. However, there are no well-defined factors that influence the number of lymph nodes identified in pancreaticoduodenectomy specimens of patients with suspected malignancy.

**Material and Methods:** Medical records of 332 patients who underwent pancreaticoduodenectomy for pancreatic and ampullary malignancies between 1990 and 2006 were reviewed to determine factors predicting yield of less than 10 lymph nodes in surgical specimens.

**Results:** The median number of evaluated nodes was 15 (95% CI 13–17; range 2–62) and 93 (28%) patients had less than 10 lymph nodes in their surgical specimens. The following variables were included in the regression model to identify independent predictors of inadequate lymph node count: age, gender, ASA class, body mass index, type of primary tumour, tumour diameter, infiltration of surrounding tissues, degree of differentiation, lymphovascular invasion, perineural invasion, preoperative biliary drainage, and surgical extent of lymphadenectomy. Only the presence of lymph node metastases (Odds Ratio (OR) 3.69; 95% CI 1.31–10.36;  $P = 0.013$ ), and radical lymphadenectomy (OR 7.78; 95% CI 2.24–27.03;  $P = 0.001$ ) were significant predictors of retrieving 10 or more lymph nodes.

**Conclusion:** Extent of lymphadenectomy is the only surgeon-dependent factor influencing adequate lymph node yield in pancreaticoduodenectomy specimens of patients with pancreatic and ampullary cancers.

**Abstract ID: 0572**      Specific Field: **Hepatobiliary and Pancreas Surgery**

**Mode of pres.: Free Paper**  
**ISW 2011 Session 81.03**

**Suture-assistance device for pancreaticojejunostomy**

T. Ueno, K. Sakamoto, M. Oka

Yamaguchi University Graduate School of Medicine, Ube, Japan

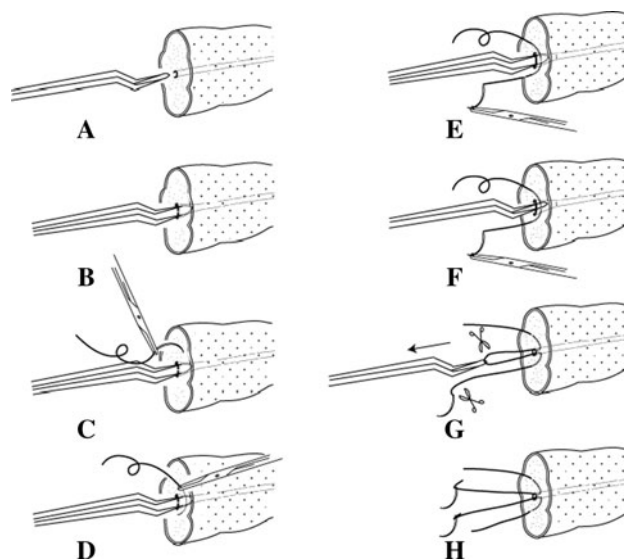
**Introduction:** Pancreatic anastomotic failure remains an unacceptable common complication and the most lethal following

pancreaticoduodenectomy (PD). Centers using duct-to-mucosa techniques in which the duct is sewn to an opening in the jejunum appear to have lower fistula rates. However, achieving accurate placement of sutures around a non-dilated main pancreatic duct (MPD) in a soft pancreas without laceration of the fragile tissue can prove difficult even for expert surgeons. We describe a breakthrough anastomotic technique (ductile-penetrating method, DPM) using a novel suture-assistance device (InnerSure Ace, ISA) that enables any surgeon to easily perform a pancreaticojejunostomy. Here, we describe the efficacy of our approach in achieving a safe and reliable pancreatocoenteric anastomosis.

**Material and Methods:** In performing pancreaticojejunostomy, suture placement around a nondilated MPD in the soft pancreas has always been problematic and still requires experienced hands. Skilled surgical technique is often helpful, but is not a complete solution. In this small study pancreaticojejunostomy was performed using the DPM with the ISA on 5 Beagle dogs. The ISA is a surgical tool resembling tissue forceps with tapered tips, both tips of which are bridged with a fine V-shaped flexible metal wire. When the ISA is inserted deeply into the MPD, an atraumatic needle passes through the MPD with an appropriate amount of pancreatic tissue. This tract of the needle is surrounded by the legs of the forceps and the V-shaped wire. The needle is exposed perpendicularly opposite to the entry point (ductile penetrating method). The ISA can then be withdrawn from the MPD together with a paired thread. Two suture threads are available for pancreaticojejunostomy by dividing the thread at the mid-point, so long as a curved needle is attached to the end of each thread.

**Results:** Eight suture threads were placed for each pancreaticojejunostomy. No anastomotic failure was detected nor was any stenosis or dilation of the MPD apparent on gross inspection, pancreaticography or microscopy.

**Conclusion:** We report a safe and reliable technique for performing a pancreaticojejunostomy using the InnerSure Ace in a canine model with a small-sized duct in a soft and fragile pancreas. Further investigation of the utility of this novel technique in the clinical setting is now warranted.



**Figure:** Ductile penetrating method



**Abstract ID: 0573**Specific Field: **Hepatobiliary  
and Pancreas Surgery****Mode of pres.: Free Paper  
ISW 2011 Session 81.04****Use of the round ligament and omental flap to prevent pancreatic fistula, sequential delayed intra-abdominal hemorrhage after pancreaticoduodenectomy-double wrapping method**

H. Takamori, H. Tanaka, O. Nakahara, S. Abe, A. Chikamoto, K. Horino, T. Beppu, H. Baba

Kumamoto University, Kumamoto, Japan

**Introduction:** Despite major advanced in pancreatic surgery, pancreatic fistula continues to be a common and potentially lethal complication after pancreaticoduodenectomy (PD). The incidence of delayed postoperative hemorrhage (DPH) after PD was reported to be 3.9%. Pancreatic fistula could potentially induce DPH. Therefore, prevention of pancreatic fistula and sequential DPH is crucial after PD.

**Material and Methods:** Patients: Between August 2008 and November 2010, forty-eight patients underwent conventional PD ( $n = 4$ ) or substomach-preserving PD ( $n = 44$ ). Technique: The round ligament was divided near the umbilicus and detached from the abdominal wall from the umbilicus to the liver at laparotomy. Pancreaticogastrostomy (PG) is conducted in end-to side anastomosis using 2 layers including duct-to-mucosa and pancreatic parenchyma-to-the gastric seromuscular layer after PD. We have introduced a new contrivance to prevent not only pancreatic fistula but also sequential delayed intra-abdominal bleeding after PD. Double Wrapping Method is composed of three steps. First, the skeletonized splanchnic arteries including the stump of the gastroduodenal artery were covered with the round ligament. Second, PG was covered with omental flap. Closed drain was placed between the round ligament and the omental flap. Analyses: Pancreatic fistula was defined according to the guideline of the International Study Group on Pancreatic Fistula Definition (ISGPF).

**Results:** Study subjects included 24 women and 24 men. The median age of the patients was 71 years, ranging from 37 to 85 years. Diagnosis included pancreatic cancer ( $n = 23$ ), bile duct carcinoma ( $n = 9$ ), intraductal papillary mucinous neoplasm ( $n = 6$ ), cancer of ampulla of Vater ( $n = 4$ ) and others ( $n = 6$ ). Twenty-one patients had soft pancreas, and twenty-seven had hard pancreas. Based upon ISGPF grading guidelines, we experienced grade A fistulas in 8 patients, and grade B in 2 (4.2%). Neither grade C fistula nor sequential DPH was observed.

**Conclusion:** This procedure is a simple and useful technique to prevent pancreatic fistula and DPH.

**Abstract ID: 0574**Specific Field: **Hepatobiliary  
and Pancreas Surgery****Mode of pres.: Free Paper  
ISW 2011 Session 81.05****Appraisal of antecolic vertical duodenojejunostomy with internal stent and omental wrapping in pylorus-preserving pancreaticoduodenectomy**

T. Shimura [1], H. Suzuki [2], K. Araki [2], T. Kobayashi [2], Y. Koyama [1], M. Shibata [1], S. Takenoshita [1], H. Kuwano [2]

[1] Fukushima Medical University, Fukushima, Japan, [2] Gunma University, Graduate School of Medicine, Maebashi, Japan

**Introduction:** Because pancreaticoduodenectomy is associated with major complications, we developed a novel reconstruction method for this procedure and examined the safety and efficacy of this method.

**Material and Methods:** Traditional pylorus-preserving pancreaticoduodenectomy was performed in Group A, while the novel procedure, an antecolic vertical duodenojejunostomy and internal pancreatic drainage with omental wrapping, was performed in Group B ( $n = 40$  each).

**Results:** The novel procedure took less time and was associated with less blood loss (both  $P < 0.0001$ ). The nasogastric tubes were removed at a mean of  $1.8 \pm 0.2$  days postoperatively in Group B, while it was a mean of  $9.7 \pm 1.5$  in Group A ( $P < 0.0001$ ). Food intake was resumed more quickly in Group B ( $5.3 \pm 0.1$  days) than in Group B ( $20.4 \pm 2.4$  days) ( $P < 0.0001$ ). Shorter hospital stays ( $14.3 \pm 0.4$  days) were required in Group B than in Group A ( $45.3 \pm 4.6$  days) ( $P < 0.0001$ ). The rate of postoperative complications was significantly higher in Group A than in Group B ( $P < 0.0001$ ).

**Conclusion:** The novel procedure appears to be a safe and effective alternative to traditional pancreaticoduodenectomy techniques.

**Abstract ID: 0575**Specific Field: **Hepatobiliary  
and Pancreas Surgery****Mode of pres.: Free Paper  
ISW 2011 Session 81.06****Influence of visceral obesity for postoperative pulmonary complications after pancreaticoduodenectomy**

A. Shimizu, M. Tani, M. Kawai, S. Hirono, K. Okada, M. Miyazawa, H. Yamaue

Wakayama Medical University, School of Medicine, Wakayama, Japan

**Introduction:** Although obesity is thought to be a risk factor for postoperative pulmonary complications (PPCs) after surgery, it was reported that Body mass index (BMI) was not associated with increasing PPCs in a systematic review. However, BMI did not reflect the distribution of fat tissue, and then, we conduct to determine whether visceral obesity is associated with PPCs after pancreaticoduodenectomy or not.

**Material and Methods:** 317 patients undergoing pancreaticoduodenectomy were enrolled in Wakayama Medical University Hospital between 2003 and 2009. Visceral fat area (VFA) was measured using a preoperative cross-sectional CT scan at the level of the umbilicus by FatScan software version 3.0 (N2 systems Inc., Japan). Clinicopathological variables, intraoperative outcomes and postoperative courses were analyzed.

**Results:** Operative time and estimated blood loss were also demonstrated significant correlation with VFA ( $P < .0001$ ,  $=.0008$ , respectively). PPCs were occurred in 14 patients (4.4%) and median VFA of patients with PPCs was  $135.7 \text{ cm}^2$ , significantly higher than those without PPCs ( $75.9 \text{ cm}^2$ ) ( $P = .0058$ ), however, there was identical in BMI ( $P = .1668$ ). Six parameters which had a  $P$  value  $< 0.20$  after univariate analysis, including gender, additional portal vein resection, BMI, VFA, operative time and estimated blood loss, were selected for multivariate analysis. Consequently, only high-VFA was predicted the independent risk factor for PPCs ( $P = .0390$ , odds ratio 4.246, 95% confidence interval 1.076–16.759), and BMI did not affect the incidence of PPCs.

**Conclusion:** Visceral obesity was the independent risk factor for the incidence of PPCs after pancreaticoduodenectomy. Preoperative VFA measurement using CT scan is a useful tool for the prediction of the development of PPCs compared to BMI calculation.

**Abstract ID: 0576**      Specific Field: **Hepatobiliary and Pancreas Surgery**

**Mode of pres.: Free Paper**  
**ISW 2011 Session 81.07**

**Usefulness of serum procalcitonin (PCT) measurement for predicting early infectious complications after pancreatoduodenectomy (PD)**

T. Asakura [1], J. Shimada [2], R. Oshima [1], K. Onoda [2], S. Kobayashi [2], S. Koizumi [2], T. Otsubo [2]

[1] St. Marianna University School of Medicine, Japan, [2] St. Marianna University School of Medicine, Kawasaki, Japan

**Introduction:** In recent years, many reports have been made demonstrating the efficacy of PCT in the diagnosis of various infectious diseases. In particular, an increasing number of reports note its efficacy regarding the diagnosis of septicemia as a fast marker with considerable specificity. PC is a peptide produced by the C-cells of the thyroid gland and a precursor of the hormone calcitonin. It is becoming known that, induced by inflammatory cytokines at the time of infection, PCT will be produced by organs other than the thyroid gland, thus elevating its serum concentration. The incidence of SSI, local infection, and inflammation associated with pancreatic fistula after highly invasive PD still remains high, despite improvements in the surgical procedure. In the current, we examined the efficacy of PCT as a serum marker for prediction of early infectious complications after PD.

**Material and Methods:** The subjected cases were 24 patients who underwent PD between November 2008 and November 2009. The cases were classified into two groups, 11 cases of PCT positive (2 ng/ml or higher) on the day following surgery and 13 PCT negative cases, to examine the relationship between PCT concentrations and WBC, CRP, drainage fluid amylase levels, operation time, intraoperative bleeding, body mass index (BMI), and duration of hospital stay. In addition, postoperative complications were classified into groups of pancreatic fistula, surgical site infection (SSI), other and infectious complications, and tests of significant difference between these subject groups were performed.

**Results:** With regard to the data inspected and data related to the operation, there were no significant differences found in any of these parameters. 5 cases of infectious complications cases had positive PCT findings on the day following surgery. The incidence of infectious complications increased significantly in the cases that had positive PCT findings on the day following surgery ( $P > 0.01$ ).

**Conclusion:** In the cases with PD, PCT measurements on the day following surgery were useful for early prediction of infectious complications.

**Abstract ID: 0577**      Specific Field: **Hepatobiliary and Pancreas Surgery**

**Mode of pres.: Free Paper**  
**ISW 2011 Session 81.08**

**Strategies for the treatment of invasive ductal carcinoma of the pancreas and how to achieve zero mortality for pancreaticoduodenectomy**

W. Kimura, I. Hirai, T. Watanabe

Yamagata University Faculty of Medicine, Yamagata City, Japan

**Introduction:** Although various therapeutic modalities are available for carcinoma of the pancreas, “curative resection” is the most

important. Thus, the aim of surgery for carcinoma of the pancreas is local complete resection of the carcinoma.

**Material and Methods:** Carcinoma of the head of the pancreas invades through the pancreatic parenchyma, following the arteries, veins and especially nerves between the parenchyma and fusion fascia, and then spreads horizontally toward the superior mesenteric artery or celiac axis. We suggest techniques for resection of the extrapancreatic nerve plexus in the head of the pancreas during a Whipple procedure for carcinoma of the pancreas from the perspective of surgical anatomy and pathology to achieve “curative resection”. We suggest that (1) en bloc resection of the right side of the superior nerve plexus and the first and second nerve of the pancreatic head should be performed. With this technique, it is possible to avoid cutting these nerves. (2) the entire cut end of the nerve plexus should be investigated during the operation using frozen specimens and confirmed to be negative for cancer. If the cut end is positive for cancer, additional resection of the nerve plexus should be performed to achieve curative resection.

**Results:** With regard to reconstruction, we perform a modified Child method with pancreatico-jejunostomy, end-to-side, choledochoduodenostomy, also end-to-side, and gastrojejunostomy with Braun’s anastomosis. The greater omentum is set behind the pancreatico-jejunostomy to prevent pancreatic juice from spreading in the abdomen. Careful management of the intraabdominal drainage tubes after the operation is very crucial. With the operative procedure and postoperative controls described above, operative mortality was zero in 165 consecutive patients in our series who underwent pancreaticoduodenectomy.

**Conclusion:** Safe operation should be needed in pancreaticoduodenectomy.

**Abstract ID: 0578**      Specific Field: **Hepatobiliary and Pancreas Surgery**

**Mode of pres.: Free Paper**  
**ISW 2011 Session 81.09**

**Thailand’s first successful series of robotic assisted laparoscopic pancreaticoduodenectomy using a team approach**

T. Akaraviputh [1], A. Trakarnsga [2], A. Yiengpruksawan [3], V. Chinswangwatanakul[2]

[1] Faculty of Medicine Siriraj Hospital, Thailand, [2] Department of Surgery, Faculty of Medicine Siriraj Hospital, Bangkok, Thailand, [3] The Valley Hospital, New Jersey, USA

**Introduction:** For pancreaticoduodenectomy (PD), this complex procedure needs a long operative time (OPT) and delicate surgical skills causing the stress and fatigue to a single surgeon. To overcome the learning curve and shorten the operative time, we have established a team approach. The surgical operator would be switched every 2 h among 3 surgeons. This study showed an initial experience of robotic surgery using a team approach for PD in patients with periampullary carcinoma.

**Material and Methods:** A series of patients who underwent robotic assisted PD using team approach at the Minimally Invasive Surgery unit, Division of General Surgery, Department of Surgery, Faculty of Medicine Siriraj Hospital, Bangkok, Thailand was reviewed.

**Results:** From October 2007 to January 2010, 6 patients underwent robotic-assisted pylorus preserving pancreaticoduodenectomy (PPPD) using the da Vinci S robotic system. Of all, 4 patients were female. The average age was 62.8 years (range 52–80). Mean OPT was 609.5 min (range 540–732) which was decreased to 6 h. for the most recent case. The mean estimated blood loss was 946.7 ml (range 400–2,000). For post-operative complications, there were 2 patients with delay gastric

emptying and one with superficial surgical site infection without any mortality. The mean length of stay was 20.5 days (range 14–30).

**Conclusion:** This is the first series of robotic assisted PPPD in Thailand. The results demonstrate that it is feasible and safe. Furthermore, the learning curve of this complex procedure can be shortened by using the team approach.

**Abstract ID: 0579**      Specific Field: **Hepatobiliary and Pancreas Surgery**

**Mode of pres.: Free Paper**  
**ISW 2011 Session 81.10**

#### **Our technique of laparoscopic pancreaticoduodenectomy**

Y. Nakamura, E. Uchida, T. Tajiri, T. Aimoto, S. Matsumoto

Nippon Medical School, Tokyo, Japan

**Introduction:** Our group has performed laparoscopic pancreatic resections in over than 60 patients since January 2004. In this congress, we would like to demonstrate our technique and resources for laparoscopic pancreaticoduodenectomy (Lap-PD) along the concept of this session.

**Material and Methods:** Each patient was placed in the supine position. Five trocars were generally inserted into the abdomen, and abdominal air pressure was set at 7–10 mmHg. After dividing the right gastroepiploic pedicle, the stomach was divided via an incision of about 2 cm proximal to the pyloric ring. The neck of the pancreas was carefully divided using laparoscopic coagulating shears (LCS). After the duodenojejunal flexure was mobilized and the jejunum was divided, the duodenum was Kocherized and the uncinate process was separated by LCS and/or LigaSure (LS) along the right aspect superior mesenteric vein and artery from inferior side, retracting the specimen to the anterior right side. All lympho-fatty tissues, including the lymph nodes, were dissected out from the peripancreatic tissues, common hepatic artery, and portal vein. The structures were skeletonized individually up to the porta hepatis. After division of the hepatic duct, the specimen was placed into an endobag and removed through a 4 cm wound positioned concordant with the pancreatic stump. Before the reconstruction, we directly carry out a local lavage along the small wound to prevent dissemination of cancer cells. Reconstruction was performed by the Child's method. Hepaticojejunostomy was constructed intracorporeally, and both pancreatojejunostomy and gastrojejunostomy were performed using the small wound which produced for removal of the specimen.

**Conclusion:** Our Lap-PD surgical procedures are characterized by using a 4-cm incision directly above the resected end of the pancreas for some parts of the situations (We consider this incision to be the minimum size feasible for easy removal of resected material from the body.). This incision is placed at the same location as the resected end of the pancreas so that pancreatic anastomosis can be visualized directly above described. However, hepaticojejunostomy cannot be conducted through this 4-cm wound, so it is necessary to acquire the necessary skills to perform that anastomosis laparoscopically.

**Abstract ID: 0580**      Specific Field: **Hepatobiliary and Pancreas Surgery**

**Mode of pres.: Prize Session FP**  
**ISW 2011 Session 105.06**

**Preoperative portal vein embolization can improve disease-free survival for patients with hepatocellular carcinoma**

T. Beppu, A. Chikamoto, H. Baba, T. Masuda, H. Okabe, K. Mima, T. Ishiko, H. Takamori

Kumamoto University, Kumamoto, Japan

**Introduction:** Survival benefits of portal vein embolization (PVE) prior to hepatectomy in patients with hepatocellular carcinoma (HCC) are unclear. The aim of this study is to identify the efficacy of PVE before right hepatectomy in HCC patients with regard to survival benefit, hepatic function, and surgical stress.

**Material and Methods:** Fifty-five consecutive HCC patients underwent right or extended right hepatectomy between 1999 and 2009. Preoperative PVE was applied in 19 patients (PVE group) and was not in 36 patients (non-PVE group). PVE was performed using a percutaneous and ipsilateral approach using ethanolamine oleate iopamidol. Hepatic resection was achieved 4 to 5 weeks after PVE. Child's status of the patients enrolled in this study was all A. Changes in liver function and volume were investigated in PVE group and clinical outcomes were compared between the two groups.

**Results:** 1. The percentage of future liver remnant (%FLR) before PVE was significantly lower (37.8%) in PVE group than in non-PVE group (58.1%) but increased remarkably after PVE (from 37.8% to 55.0%,  $P < 0.0001$ ). 2. Disease-free survival (DFS) in the PVE group was 77.7% at 1, 3, and 5 years and was significantly greater than the rates of 58.0%, 19.6%, and 0% in the non-PVE group ( $P = 0.01$ ). The 1-, 3-, and 5-year overall survival (OS) rates in the PVE group were also higher than those of the non-PVE group (89.5%, 72.3%, and 72.3% versus 88.7%, 57.2%, and 12.3%;  $P < 0.05$ ). 3. By multivariate analysis, independent prognostic factors for DFS were PVE (HR3.59), Multiple tumor (HR3.57), Fibrosis stage F3/4 (HR2.81), and protein induced by vitamin K absence or antagonists-II (PIVKA-II) 678 AU/ml (HR2.69). There were no independent prognostic factors for OS. 4. Surgical stress estimated by E-PASS scores and CRP value was not different between the groups, the postoperative value of prothrombin time activity on postoperative day 3 in PVE group was significantly better than in non-PVE group.

**Conclusion:** Preoperative portal vein embolization can improve resectability and improve disease-free survival for patients with hepatocellular carcinoma treated with right hepatectomy.

**Abstract ID: 0581**      Specific Field: **Hepatobiliary and Pancreas Surgery**

**Mode of pres.: Prize Session FP**  
**ISW 2011 Session 105.07**

**How to reconstruct following pancreaticoduodenectomy: reconstruction according to the results of randomized controlled trials in Wakayama**

H. Yamaue, M. Tani, M. Kawai

Wakayama Medical University, Japan

**Introduction:** We introduce our experiences of three RCTs regarding the reconstruction methods of pancreaticoduodenectomy (PD). First, previous retrospective studies have shown a lower incidence of DGE after antecolic duodenojejunostomy. Only a RCT could prove this hypothesis, thus the reason for our study. To determine this hypothesis, a RCT is accomplished (Ann Surg 2006). Second, a stent is often placed across the pancreatojejunostomy. However, no study has previously compared pancreatic stent types with regard to postoperative course (Am J Surg 2009). Third, we determine in a RCT whether pylorus-resecting PD (PrPD) with preservation of nearly the entire stomach reduces the incidence of delayed gastric emptying (DGE) compared to PpPD (Ann Surg, in press).

**Material and Methods:** Antecolic reconstruction for duodenojejunostomy during PpPD decreases postoperative morbidity and length of hospital stay by decreasing DGE. Forty patients were enrolled in this trial. Just before duodenojejunostomy during PpPD, the patients were randomly assigned to undergo either an antecolic or a retrocolic duodenojejunostomy. Second, we conducted a prospective randomized trial with 100 patients who underwent pancreaticoduodenectomy, and compared the effects on postoperative course (Am J Surg 2009). 130 patients were randomized to preservation of the pylorus ring (PpPD) or to resection of the pylorus ring with preservation of nearly the entire stomach (PrPD).

**Results:** PpPD with antecolic duodenojejunostomy is a safer operation, because DGE occurred in 5% of patients with the antecolic route versus 50% with the retrocolic route. Both of internal drainage and external drainage were safety devices for pancreaticojejunostomy. However, it might be suggested that internal drainage affects and simplification of postoperative managements and shortening of postoperative stay for pancreaticoduodenectomy. The incidence of DGE was 4.5% in PrPD and 17.2% in PpPD, a significant difference. DGE was classified into three categories proposed by the International Study Group of Pancreatic Surgery. Thus, PrPD significantly reduces of the incidence of DGE compared to PpPD (Ann Surg, in press).

**Conclusion:** According to the results of RCTs, the reconstruction with safe and less morbidity can be performed following PD.

**Abstract ID: 0582**      Specific Field: **Hepatobiliary and Pancreas Surgery**

**Mode of pres.: Free Paper**  
**ISW 2011 Session 163.01**

**Single port laparoscopic cholecystectomy: feasible, safe and acceptable**

S. H. Tsang, C. M. Lo, W. K. Ip, S. C. Chan, T. T. Cheung, K. S. H. Chok, W. K. Yuen, S. T. Fan

Division of Hepatobiliary, Pancreatic and Liver Transplantation Surgery, Department of Surgery, University of Hong Kong Medical Centre, Hong Kong SAR, China, People's Republic

**Introduction:** Single port laparoscopic cholecystectomy emerged in the past few years as an effort to reduce access trauma in surgery of the gallbladder. This study presents a tertiary institution's experience in single port laparoscopic cholecystectomy, and attempts to identify pre-operative and intra-operative measures which can facilitate it.

**Material and Methods:** This is a prospective study on patients with symptomatic gallstones or gallbladder polyps who underwent single port laparoscopic cholecystectomy at a tertiary institution. Patient demographic data, operative outcomes (such as operative findings, retraction technique, blood loss and operating time), and post-operative outcomes such as analgesic requirement and length of stay were recorded and analyzed.

**Results:** 36 patients underwent single port laparoscopic cholecystectomy between May 2009 and December 2010. 1 patient required an additional 5 mm port for retraction; 1 patient underwent conversion to 4 ports. No patient required conversion to open surgery. The median incision length was 24 mm (range 18–28 mm). The median age of the patients was 53 years (range 31–76 years). The median operating time was 129 min (range 55–299 min); median blood loss was 10 ml (range 0–200 ml).

The median operating time in the presence of mild adhesions in Calot's triangle (108 min) was significantly shorter than when severe adhesions were encountered (269 min) ( $P = 0.018$ ). In cases where the gallbladder was thickened the median operating time was 141 min, while the median operating time for those with normal gallbladder walls was 125 min ( $P = 0.057$ ). 12 patients (33%) had a stitch to retract the gallbladder during operation; it significantly shortened the median operating time from 136 min to 100 min ( $P = 0.039$ ). Median length of stay was 2 days (range 0–6 days). 4 patients (11.1%) had complications: myocardial ischemia, ulnar nerve palsy, common bile duct stone and a superficial wound infection, each with 1 patient (2.8%).

**Conclusion:** Single port laparoscopic cholecystectomy is a feasible, safe and acceptable alternative to conventional laparoscopic cholecystectomy for selected patients, especially patients with sonographically—normal gallbladder walls and no history of acute cholecystitis.

**Abstract ID: 0583**      Specific Field: **Hepatobiliary and Pancreas Surgery**

**Mode of pres.: Free Paper**  
**ISW 2011 Session 163.02**

**Pure laparoscopic hepatectomy for hepatocellular carcinoma patients with severe liver cirrhosis**

Z. Morise, N. Kawabe, S. Umemoto, H. Nagata, H. Oshima, J. Kawase, S. Arakawa, R. Yoshida

Fujita Health University School of Medicine, Banbuntanehoutokukai Hospital, Department of Surgery, Nagoya, Japan

**Introduction:** The patients with severe liver cirrhosis who undergo hepatectomy often develop post-operative liver failure, even if the hepatectomy is very limited. In present study, we examine perioperative course of patients with severe liver cirrhosis (Child-Pugh B/C and ICG R15 of 40% or above) who underwent pure laparoscopic hepatectomy, and discuss the specific advantages of the procedure.

**Material and Methods:** From May 2005, 30 patients with liver cancer underwent pure laparoscopic hepatectomy. Subjects of this study are 18 patients with hepatocellular carcinoma and chronic liver disease. Among them, there were 6 patients with severe liver cirrhosis (Child-Pugh B/C and ICG R15 of 40% or above). These 6 patients and the other 11 patients (Child-Pugh A and ICG R15 of 10.1–27.4 (median, 13.4)%, excluded the patient with HCC and rectal carcinoma) were compared in the parameters of perioperative course.

**Results:** Perioperative course of 6 HCC patients with severe liver cirrhosis and pure laparoscopic hepatectomy was favorable and comparable to that of the other HCC patients with mild/moderate liver cirrhosis in operating time, intraoperative blood loss, day of oral ingestion started, day of drain removal, total dose of drain discharge from the operation day to post operative day 3, postoperative hospital stay, morbidity, and mortality (Table).

**Conclusion:** Our experiences suggest that pure laparoscopic hepatectomy for severe cirrhotic patients has a specific advantage of minimal postoperative drain discharge. The procedure minimize destruction of the collateral blood and lymphatic flow caused by laparotomy and mobilization of the liver and, also, mesenchymal injury caused by compression of the liver. It restrains the complications, which lead to the postoperative serious liver failure, such as massive ascites. Severe cirrhotic patients with tumors on the surface of the liver, in case of difficult adaptation of percutaneous ablation therapy and/or local recurrence after repeat treatments, are the good



candidates for this procedure. Furthermore, the procedure could be good option of bridging therapy to liver transplantation for the patients with severe liver cirrhosis and small HCC on the surface of the liver.

	6 cases with severe liver cirrhosis (ICGR15-40% or above and Child-Pugh B/C)	11 cases with mild/moderate liver cirrhosis (ICGR15-10.1-27.4 (13.4%) and Child-Pugh A)
Operating time (min)	140-341 (232)	216-528 (295)
Intraoperative blood loss (ml)	NC-213 (58)	NC-696 (43)
Day of oral ingestion started (POD)	1-3	2-3
Day of drain removal (POD)	3-6	4-6
Drain discharge (total of 0-3POD, ml)	279-1990 (919)	141-1275 (416)
Postoperative hospital stay (day)	11-21 (17)	9-254 (20)
Morbidity	1/5	2/10
	(choleocystitis)	(leuc. refractory ascites)
Mortality	0/5	0/10

Table 1 PERIOPERATIVE COURSE AFTER PURE LAPAROSCOPIC HEPATECTOMY  
NC not countable, POD post operative day  
Numbers in ( ) indicate median value.

## Abstract ID: 0584      Specific Field: Hepatobiliary and Pancreas Surgery

Mode of pres.: Free Paper  
ISW 2011 Session 163.03

### Laparoscopic liver resection using computer-controlled low-voltage coagulation combined with the paddle electrode.

I. Koyama, M. Miyazawa, M. Aikawa, M. Okamoto, Y. Toshimitsu, K. Okada, S. Takase, S. Yamaguchi

Saitama Medical University International Medical Center, Hidaka, Saitama, Japan

**Introduction:** Soft Coagulation, low voltage coagulation, has a great potential in clinical application due to its unique characteristics with no electric sparks produced. It provides more secure hemostasis combined with the dripping saline than any other modalities. We have developed a paddle shape electrode, and used this electrode with a Soft Coagulation in laparoscopic hepatectomy and experienced less bleeding during liver dissection.

**Material and Methods:** The paddle electrode is a laterally compressed round-shaped electrode with an internal irrigation channel that can be connected to the saline via flexible tubing. This electrode can be introduced through 5 mm port. Liver parenchyma is divided by the Soft Coagulation output using the irrigating paddle electrode or bipolar forceps connected to the VIO electrical unit. This can allow the dissection of the parenchyma while leaving the small veins and Glisson's sheaths intact behind. The Glisson's sheaths and small veins left behind are coagulated with bipolar forceps. Larger Glisson's sheaths and veins are coagulated using laparoscopic BiClamp forceps. For the bleeding from perforated small hepatic vein wall, the irrigating paddle electrode can be pressed against the vessel wall allowing the current flow under the low voltage to the vein wall to shrink the perforations.

**Results:** We applied this method to 15 cases of laparoscopic partial resection of the liver. During the dividing the liver parenchyma, no ligation or no clip was used. The blood loss was  $56 \pm 89$  g. No Pringle maneuver was performed.

**Conclusion:** The low voltage coagulation mode, Soft Coagulation, is very effective in controlling the bleeding during liver resection especially in laparoscopic liver resection. No ligation or clip was needed during the hepatectomy. The simple change in the electrode shape and addition of the irrigating capability to the electro-surgical electrode enhances the characteristics and performance of the unique electro-surgical output mode of Soft Coagulation.

Abstract ID: 0585

Specific Field: Hepatobiliary and Pancreas Surgery

Mode of pres.: Free Paper  
ISW 2011 Session 163.04

### Usefulness of laparoscopic liver resection for treating recurrent hepatocellular carcinoma

A. Kanazawa, T. Tsukamoto, S. Shimizu, S. Kodai, S. Yamazoe

Osaka City General Hospital, Osaka, Japan

**Introduction:** In the conventional hepatic resection for recurrent HCC after curative hepatic resection, an extremely long incision must be made for handling abdominal postsurgical adhesion, which may increase intraoperative hemorrhage or postoperative ascitis followed by breaking the well developed collateral circulation in the abdominal wall or lymphatic circulation around the liver, and might result in a longer hospital stay and hepatic failure from several complication. With improvements in technology and equipment, laparoscopic liver resection is now considered a safe procedure even for managing liver tumor if performed by experienced surgeons. However, it is unknown whether laparoscopic liver resection is suitable for patients with recurrent HCC after curative hepatic resection.

**Material and Methods:** From January 2006 to December 2010, 264 patients underwent primary resection for HCC and 29 received a second hepatectomy for recurrent HCC. The second hepatectomy was done under laparotomy in 18 cases (laparotomy group) and under laparoscopy in 11 cases (laparoscopy group). The two groups were analyzed for surgical invasiveness and postoperative complications.

**Results:** There were no significant differences between the two groups in mean age and preoperative indocyanine green retention rate at 15 min (ICGR15). Although there were no significant difference in operating time, resected liver weight, and tumor size between the two groups, intraoperative blood loss was smaller in the laparoscopy group than that in the laparotomy group ( $P < 0.0001$ ). Postoperative morbidity rates in the laparotomy group were 55.6% (10/18) including intraabdominal abscess in six patients, whereas only one patient in the laparoscopy group experienced with postoperative bilateral pleural effusion. Neither group had a case of mortality. Mean hospital stay was 12 days in the laparoscopy group, significantly shorter than that in the laparotomy group with 25 days ( $P = 0.0002$ ).

**Conclusion:** Even in cases of recurrent HCC after curative hepatic resection, laparoscopic liver resection reduced surgical invasiveness and postoperative complications and was found effective for shortening the length of hospitalization. Laparoscopic liver resection is a safe and feasible procedure with good short-term outcomes for treating patients with HCC recurrence, and is considered as one of the new treatment choices to complement the limitations in the ablation therapy and conventional hepatectomy via laparotomy.

Abstract ID: 0586

Specific Field: Hepatobiliary and Pancreas Surgery

Mode of pres.: Free Paper  
ISW 2011 Session 163.05

### Role of laparoscopy assisted liver resection in treatment of hepatocellular carcinoma

A. Chikamoto, T. Beppu, H. Baba

Kumamoto University, Kumamoto, Japan

**Introduction:** Laparoscopic liver resection has been popular in this decade. It is classified in 3 sorts of procedures, which are pure laparoscopic, hand-assisted, and laparoscopy assisted liver resection. We study the clinical significance of laparoscopy assisted liver resection.

**Material and Methods:** Between January 1999 and December 2010, 818 liver resections were performed at Kumamoto University Hospital. Of 818 liver resections, 95 laparoscopic resections were included in this study. Our indications of laparoscopic partial liver resection are (1) smaller than 3 cm in diameter for tumor at deep site, 5 cm for tumor on liver surface, (2) no major vessels on dissection plane. Operative procedures were categorized in two groups; one consists of hand-assisted laparoscopic and pure laparoscopic resection (LH,  $n = 45$ ), and the other is laparoscopy assisted resection (LAH,  $n = 50$ ). Resected liver weight, tumor size, operation time, amount of blood loss, postoperative hospital stay postoperative morbidity, and the number of operator were compared between two groups.

**Results:** Resected liver weights were 47 g (g) for LH and 118 g for LAH, and there was statistical significance ( $P = 0.001$ ). Tumor size was nearly the same (24.1 mm for LH vs. 25.9 mm for LAH). LAH had a tendency of less blood loss, shorter operation time, and shorter postoperative hospital stay without statistical difference. Postoperative complications were observed in 3 of LH, and in 1 of LAH. During this study period, 3 surgeons performed LH, and 6 surgeons performed LAH.

**Conclusion:** Laparoscopy assisted liver resection is a safe operative procedure for hepatocellular carcinoma. In laparoscopy assisted liver resection, liver parenchyma is dissected using devices for liver resection under open laparotomy. Since the surgical technique is similar between open-laparotomy and laparoscopy assisted liver resection, laparoscopy assisted liver resection is easy to introduce.

**Abstract ID: 0587**                      Specific Field: **Hepatobiliary and Pancreas Surgery**

**Mode of pres.: Free Paper**  
**ISW 2011 Session 163.06**

**Comparison of short-term outcome and surgical stress response to laparoscopic and open hemihepatectomy**

S. Imura, M. Shimada, T. Utsunomiya, Y. Morine, T. Ikemoto, H. Mori, J. Hanaoka, H. Miyake

Department of Surgery, Tokushima University, Tokushima, Japan

**Introduction:** Laparoscopic major hepatectomy (Hx) have not been widespread due to the need of proficiency, however, basic techniques such as encircling of left Glissonean pedicle at hepatic hilum and middle + left hepatic vein (MLHV) facilitate major Hx. The potential benefits of the laparoscopic major Hx include lower surgical blood loss, rapid postoperative convalescence. In this study, we show the techniques in our laparoscopic left lobectomy (Lap-LL) and evaluated surgical stress response using each factor of the systematic inflammatory response syndrome (SIRS) criteria.

**Material and Methods:** Procedures of Lap-LL; (i) left liver mobilization including division of round, falciform and coronary ligament using vessel sealing system (VSS), (ii) encircling of hepatoduodenal ligament for Pringle method, (iii) preceding of small incision for avoiding gas embolism during parenchymal transection, (iv) control of left Glissonean pedicle at hepatic hilum and MLHV, (v) liver hanging technique, (vi) parenchymal dissection, (vii) division of Glissonean pedicle and hepatic vein by endostapler. Five patients who underwent Lap-LL were included. We evaluated surgical outcome and postoperative changes in each factor of the SIRS criteria (WBC

count, heart rate, respiratory rate, and body temperature) between laparoscopic and open left hepatic lobectomy; Open-LL group: 10 patients underwent open surgery during the same period were included.

**Results:** Compared with the open group, operative time was shorter (234 vs. 341,  $P = 0.03$ ) and blood loss was less in the laparoscopic group (82 vs. 314,  $P = 0.01$ ). The postoperative WBC in the Lap-LL group was lower than that in the Open-LL group, but the difference was not statistically significant. The heart rate in the Lap-LL group was significantly lower than that in the Open-LL group on day 1 after surgery ( $P < 0.05$ ). The frequency of SIRS was lower in the Lap-LL group than Open-LL group, especially on day 1 after surgery ( $P < 0.08$ ). Days until walking was significantly shorter in Lap-LL group than that in Open-LL group ( $P < 0.05$ ).

**Conclusion:** Lap-LL is minimally invasive procedures with safety by basic techniques in open Hx and useful devices, and can be standard procedures for selected patients.

**Abstract ID: 0588**                      Specific Field: **Hepatobiliary and Pancreas Surgery**

**Mode of pres.: Free Paper**  
**ISW 2011 Session 163.07**

**Preoperative diagnosis of macroscopic type of hepatocellular carcinoma by multi-detector-row computed tomography is useful for prediction of the occurrence of pathological progression factors in the tumor**

S. Koizumi, S. Kobayashi, T. Asakura, K. Onoda, R. Oshima, J. Shimada, R. Kyoui, T. Otsubo

St. Marianna University, School of Medicine, Kawasaki, Japan

**Introduction:** It has been reported that the extranodular growth type (ENGT) of hepatocellular carcinomas (HCCs) carry a high percentage (about 50%) of pathological progression factors around the tumor. Hence, it is very important to determine the macroscopic type of HCC preoperatively, in order to devise appropriate treatment plans. In this prospective study, we attempted to clarify whether it would be possible to predict the pathological progression factors occurring in a tumor by multi-detector-row computed tomography (MDCT).

**Material and Methods:** We prospectively studied 57 patients with a solitary HCC who underwent initial curative surgical resection from 2005 to 2009. CT was performed using the Aquilion 64 (Toshiba) machine, with Omnipaque 300 (Daichi-Sankyo) as the contrast medium. Three dimensional (coronal and sagittal) images were reconstructed at the workstation (Zio). Evaluation of the macroscopic findings of ENGT HCC by MDCT revealed the presence of an (1) irregular or incomplete corona, (2) protruding or budding of tumor, (3) satellite nodules. The macroscopic type was diagnosed based on the findings of the cut-surface of the tumors. The tumors were also subjected to histopathology, and the pathological progression factors present (such as intrahepatic metastasis <im>, invasion of vessels <vp, vv, b>) were evaluated according to the General rules for the clinical and pathological study of primary liver cancer of the Liver Cancer Study Group of Japan.

**Results:** The diagnostic usefulness of MDCT for ENGT HCC was: sensitivity, 100%; specificity, 93.3%; accuracy, 98.2%. Its usefulness for prediction of pathological progression factors was: sensitivity, 96.6%; specificity, 46.4%; accuracy, 71.9%.

**Conclusion:** Preoperative diagnosis of the macroscopic type of HCC by MDCT is particularly useful for prediction of pathological progression factors and evaluation of treatment options in patients with HCC.

**Table** Diagnostic accuracy of 3D-CT for pathological progression factors

	Preoperative diagnosis by 3D-		
	CT, PF (+)	CT, PF(-)	
Pathological diagnosis, PF (+)	28	1	29
Pathological diagnosis, PF(-)	15	13	28
	43	14	57
Sensitivity	96.6%		
Specificity	46.4%		
Positive predictive value	65.1%		
Negative predictive value	92.9%		
Accuracy	71.9%		

**Abstract ID: 0589**      Specific Field: **Hepatobiliary and Pancreas Surgery**

**Mode of pres.: Free Paper**  
**ISW 2011 Session 163.08**

#### Robotic liver resection using da Vinci surgical system

Y. Kato, Y. Tanahashi, T. Tokoro, J. Yoshida, T. Kagawa, C. Takeura, A. Sugioka, I. Uyama

Fujita Health University School of Medicine, Toyoake, Aichi, Japan

**Introduction:** Robotic surgery has increasingly been accepted as a competent operation-assisting modality in the field of abdominal surgery. Liver resection using da Vinci Surgical System (DV) has a potential to overcome limitations of conventional laparoscopic liver resection. DV consists of three individual parts: patient cart, surgeon console and vision cart. The main operator sits in the surgeon console and manipulates the master controller to control remotely three robot arms (Endowrists) on the patient, watching the three-dimensional high definition images served on the view port. Endowrist is a multi-articulated forceps with 7-degrees of freedom, and enables smooth and accurate operation with the aid of its scaling and filtering functions. We have performed 5 liver resections using DV for colorectal metastases since December 2009.

**Material and Methods:** Of the 5 resected patients, 1 had a synchronous metastasis (Segment(S) 8) and 4 had a metachronous metastasis in S5/6, S6, S7 and S7/8, respectively. One had a redo after laparoscopic left lateral sectionectomy for the first metastasis. In the synchronous case, both the primary and metastasis were resected simultaneously. In a metachronous case, an anatomical posterior sectionectomy was done, where cholecystectomy with gall bladder plate dissection is followed by encircling the glissonian pedicle of the posterior section, which was transected with ligation and stapling. The discolored posterior section was resected using CUSA, with bipolar forceps, clips and sutures applied for hemostasis.

**Results:** The mean blood loss and operating time were 1120 g and 8 h 59 min, respectively. Robotic procedures seemed to be useful particularly for hilar dissection, suturing and tying. There were no perioperative complications in all patients, who were discharged on 9–19 days postoperatively. At present, 11 to 12 months after resection, all patients are alive without recurrence except one with liver metastasis.

**Conclusion:** Robotic liver resection using DV may overcome limitations of conventional laparoscopic liver resection and potentially further offers less invasiveness and safety by improving surgical quality.

**Abstract ID: 0590**      Specific Field: **Hepatobiliary and Pancreas Surgery**

**Mode of pres.: Free Paper**  
**ISW 2011 Session 10.09**

#### Residual gallbladder: ten year experience from a tertiary care center

A. Kapoor, R. K. Singh, B. Pottakkat, A. Prakash, A. Behari, A. Kumar, V. K. Kapoor, R. Saxena

Sanjay Gandhi Post Graduate Institute of Medical Sciences, Lucknow, India

**Introduction:** A residual gallbladder, remaining after cholecystectomy may be inadvertent or intentional (e.g. Subtotal cholecystectomy). Pathology in a residual gallbladder may lead to post cholecystectomy symptoms. Studies on the clinical presentation and management of residual gallbladder are few. Here we report our experience in the surgical management of such cases.

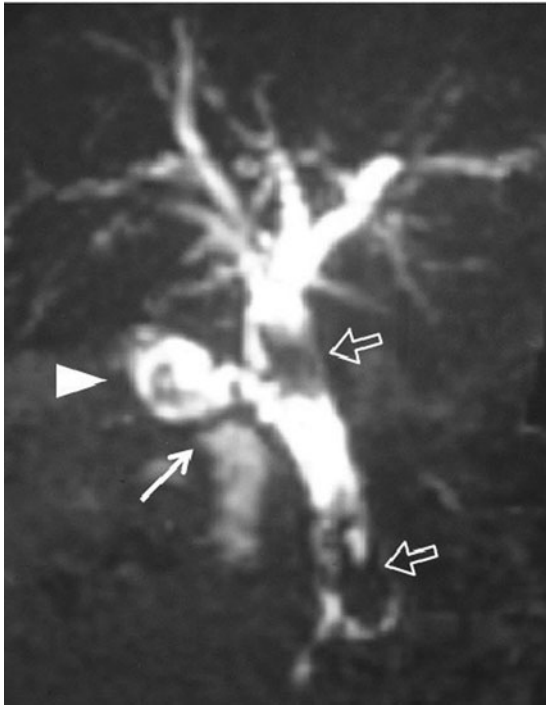**Material and Methods:** Retrospective review of patients who underwent surgery for a residual gallbladder between January 2000 and September 2010.

**Results:** All patients ( $n = 54$ ) had undergone the initial cholecystectomy at other hospitals. Post cholecystectomy symptoms developed after a median time interval of 27 months (0–204). Recurrent biliary colic was the most common symptom (74%). All patients underwent completion cholecystectomy (removal of residual gallbladder) at our hospital. This was done by open method in 29 (54%) and attempted laparoscopically in 25 (46%). Thirteen of the 25 (52%) patients undergoing laparoscopic completion cholecystectomy required conversion to open surgery. The most common pathology in residual gallbladder was stones—53 (98%), other pathologies included fistula with duodenum—3 (6%), with abdominal wall—2 (4%), and with CBD—1(2%). There was no postoperative mortality and the morbidity rate was 17%. The commonest morbidity was wound infection (15%). Forty one patients were available for follow up and 95% patients were free of their symptoms at a median follow-up of 4 months (3–108 months).

**Conclusion:** Completion cholecystectomy for residual gallbladder can be performed safely at specialist centers with low morbidity rates and excellent relief of symptoms. Laparoscopic completion cholecystectomy is feasible, but is associated with a high conversion rate.

#### Clinical presentation of residual gallbladder ( $n = 54$ )

	<i>n</i> (%)
Biliary colic	40 (74)
Obstructive jaundice	6 (11)
Cholangitis	5 (9)
Cholecystocutaneous fistula	2 (4)
Biliary pancreatitis	1 (2)



**Figure:** MRCP showing residual gallbladder with calculi (*arrowhead*), choledocholithiasis (*hollow arrows*) and residual gallbladder-duodenal fistula (*solid arrow*)

**Abstract ID: 0591**

Specific Field: **Hepatobiliary and Pancreas Surgery**

Mode of pres.: Free Paper  
ISW 2011 Session 173.01

**Time for open repair of common bile duct injuries associated with bile fistulas**

R. M. Smachylo [1], V. V. Boyko [2], A. M. Tischenko [2], A. V. Maloshtan [2], N. A. Remnyova [2]

[1] Kharkiv National Medical University, Kharkiv, Ukraine,  
[2] Institute of General and Urgent Surgery, Kharkiv, Ukraine

**Introduction:** Special difficulties are encountered in treatment of common bile duct injuries (CBDI) associated with bile fistulas and leaks.

**Material and Methods:** 76 patients with bile fistulas due to CBDI, who underwent open repair in 2002–2010 in the Institute, were analyzed. Among them there were 28 males and 48 females. Age of patients ranged from 23 to 79 years. Majority of patients (61) were transferred from other hospitals. Patients were divided into two groups. The 1st group consisted of 26 patients operated within one month from primary operation; the 2nd group consisted of the 50 patients operated after one month from initial operation. The preoperative assessment included laboratory tests, fistulography, bacterial culture of bile, ultrasound scan, ERCP if needed. Biopsies of the area of injured common bile duct were made in 37 cases (12 of group 1 and 25 of group 2). Analysis of preoperative, intraoperative and postoperative data was made.

**Results:** Cholecystectomy was primary surgical procedure in majority of cases (72), including 42 laparoscopic cholecystectomies. 1 patient underwent pancreatoduodenectomy for chronic pancreatitis, 3 patients were operated for complicated peptic ulcer. The amount of bile discharge ranged from 100 ml to 900 ml per day. There were no significant differences in severity of CBDI between groups according to Strasberg classification. Rough-en-Y hepaticojejunostomy was performed in all cases by atraumatic interrupted sutures. Histological examination revealed severe inflammatory changes with edema, infiltration and necrosis of the injured CBD in the 1st group, less inflammatory changes with clear demarcation and predominance of scarring processes was revealed in the 2nd group. Postoperative complications included: postoperative bile leak in 11 (42.3%) and 12 (24%), intraabdominal fluid collections (abscesses, bilomas) in 5 (19.2%) and 3 (6%), wound infection in 4 (15.4%) and 5 (10%), recurrent cholangitis in 8 (30.8%) and 7 (14%), stricture of hepaticojejunostomy in 6 (23.1%) and 4 (8%) patients of 1st and 2nd groups respectively. 2 (7.7%) patients died in group 1, and 2 (4%) patients—in group 2.

**Conclusion:** Obtained results showed that delayed operations for CBDI with bile leaks and fistulas has better results as compared with early interventions that can be explained by less inflammatory changes in the area of operation.

**Abstract ID: 0592**

Specific Field: **Hepatobiliary and Pancreas Surgery**

Mode of pres.: Free Paper  
ISW 2011 Session 173.02

**Enne results of the first 130 hybrid notes culdoscopic cholecystectomies**

A. R. Ferreres, A. Rond, M. Fasano, M. E. Gimenez, R. Franzosi, V. P. Guti

University of Buenos Aires, Buenos Aires, Argentina

**Introduction:** NOTES has become a surgical innovation and its feasibility for performing a hybrid cholecystectomy has been demonstrated. Nonetheless the benefits of a scarless surgery, difficulties have challenged its clinical application. The recommendations from the 4th International Conference (Boston, 2009) encouraged randomized trials to prove the advantages of this approach.

**Material and Methods:** Between August 2007 and August 2010, 130 hybrid NOTES cholecystectomies through a culdoscopic approach were performed in patients with symptomatic gallstone disease and in compliance with our IRB and Ethics Committees approval. Mean age was 42.5 years. The inclusion criteria specify: (a) Age between 18 and 65 years, (b) MMS of 14 or higher, (c) Previous pregnancy/ies, (d) Negative pregnancy tests, (e) Well documented process of informed consent and willingness to enter the trial, (f) Symptomatic gallbladder stones with an indication to perform cholecystectomy, (g) Absence of common bile obstruction, (h) Normal liver tests, (i) Body mass index below 25. The technique was: (a) placement of a 5 mm umbilical trocar, insufflation and laparoscopic visualization, (b) transvaginal insertion of a 2 channel trocar and introduction of a flexible video endoscope and long instruments, (c) dissection and clipping of the cystic elements in a laparoscopic fashion, (d) removal of the gallbladder through the vagina.

**Results:** No complications were registered and the procedure was completed as intended in 98%; 2 cases required conversion to



standard laparoscopic cholecystectomy and in 5, a 2 mm additional trocar was required. Mean operative time was 115 min in the first 40 cases, 73 in the second 40 and 56 min in the last group. Postoperative pain was in average 1.3 (maximum 5) and hospital stay, 20 h. Mean follow-up time was 20 months and no severe complications occurred. Patients satisfaction was 100%.

**Conclusion:** Though laparoscopic cholecystectomy represents the present gold standard, hybrid NOTES culdoscopy cholecystectomy is feasible, with few reported complications and can be performed following strict principles of patient safety. Additional prospective studies are required to prove benefits and disadvantages.

**Abstract ID: 0593**      Specific Field: **Hepatobiliary and Pancreas Surgery**

**Mode of pres.: Free Paper**  
**ISW 2011 Session 173.03**

**Alteration of p53-binding protein 1 expression as a risk factor for local recurrence in patients undergoing resection for extrahepatic cholangiocarcinoma**

T. Wakai, Y. Shirai, J. Sakata, P. V. Korita, M. Nagahashi, Y. Ajioka, K. Hatakeyama

Niigata University Graduate School of Medical and Dental Sciences, Niigata, Japan

**Introduction:** P53-binding protein 1 (53BP1) is an early DNA damage response-protein that is rapidly recruited to sites of DNA double-strand breaks. This study aimed to clarify the early DNA damage response mediated by 53BP1 in tumor specimens of ductal resection margins and to elucidate its predictive value for clinically evident local recurrence at ductal stumps in patients undergoing resection for extrahepatic cholangiocarcinoma.

**Material and Methods:** A retrospective of 110 patients with extrahepatic cholangiocarcinoma. The ductal resection margin status was classified as negative (85 patients), positive with carcinoma in situ (14 patients), or positive with invasive carcinoma (11 patients). The nuclear staining pattern of 53BP1 was evaluated by immunofluorescence. TUNEL analysis was used to calculate apoptotic index.

**Results:** Ductal margin status was the only independent risk factor for local recurrence ( $P = 0.001$ ). The cumulative probability of local recurrence at 5 years was 10%, 40%, and 100% in patients with negative ductal margins, positive with carcinoma in situ, and positive with invasive carcinoma, respectively ( $P < 0.001$ ). Of the 14 tumor specimens of carcinoma in situ, 10 showed diffuse localization of 53BP1 in nuclei (53BP1 inactivation) and 4 showed discrete nuclear foci of 53BP1 (53BP1 activation). All 11 tumor specimens of invasive carcinoma showed 53BP1 inactivation. Apoptotic index was markedly decreased in tumor specimens with 53BP1 inactivation compared to those with 53BP1 activation (median index, 0% vs. 22%;  $P < 0.001$ ). Among 14 patients with residual carcinoma in situ, the cumulative probability of local recurrence was significantly higher in patients with 53BP1 inactivation than in patients with 53BP1 activation (60% vs. 0% at 5 years;  $P = 0.020$ ).

**Conclusion:** After resection for extrahepatic cholangiocarcinoma, clinically evident local recurrence at ductal stumps is closely

associated with 53BP1 inactivation and decreased apoptosis. Immunofluorescence analysis of 53BP1 nuclear expression in tumor specimens of ductal resection margins may be useful to estimate the risk for local recurrence at ductal stumps in patients undergoing resection for extrahepatic cholangiocarcinoma.

**Abstract ID: 0594**      Specific Field: **Hepatobiliary and Pancreas Surgery**

**Mode of pres.: Free Paper**  
**ISW 2011 Session 173.04**

**Extent of liver resection: mode of hepatic spread from gallbladder carcinoma**

T. Wakai, Y. Shirai, J. Sakata, M. Nagahashi, Y. Ajioka, K. Hatakeyama

Niigata University Graduate School of Medical and Dental Sciences, Niigata, Japan

**Introduction:** As the mode of hepatic spread from gallbladder carcinoma remains unresolved, no consensus regarding the optimal extent of liver resection has been established. This study aimed to clarify the mode of hepatic spread from gallbladder carcinoma and to elucidate its prognostic value.

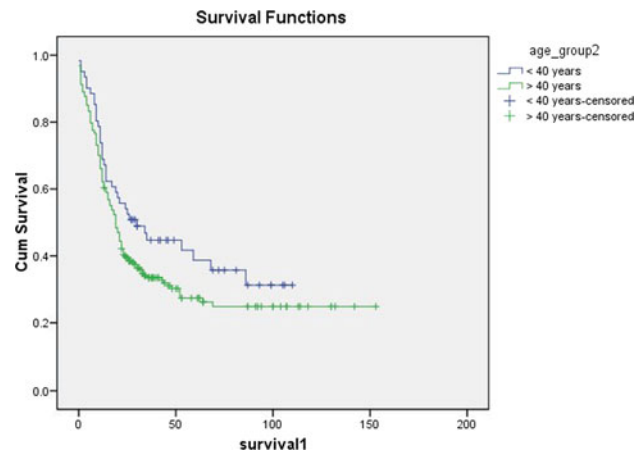
**Material and Methods:** A retrospective analysis was conducted of 42 consecutive patients who underwent resection for gallbladder carcinoma with hepatic involvement verified histologically. The mode of hepatic spread was classified into 3 patterns: direct invasion through the gallbladder bed, portal tract invasion, and hepatic metastatic nodules. Intrahepatic lymphatic invasion was declared when either single tumor cells or cell clusters were clearly visible within vessels that showed immunoreactivity for D2-40 monoclonal antibody.

**Results:** Seven, 24, and 11 patients had direct invasion alone, portal tract invasion with (22 patients) or without (2 patients) direct invasion, and hepatic metastatic nodules, respectively. Of the 24 patients with portal tract invasion, 14 had intrahepatic lymphatic invasion, 8 had neither intrahepatic lymphatic nor venous invasion, and 2 had both intrahepatic lymphatic and venous invasion. To date, 4 patients with direct invasion alone and 4 patients with portal tract invasion survived more than 5 years after resection, whereas all the patients with hepatic metastatic nodules expired within 11 months after resection, irrespective of the type of hepatectomy. The mode of hepatic spread ( $P < 0.001$ ) and residual tumor status ( $P < 0.001$ ) were independent prognostic factors. The type of hepatectomy was not significantly associated with survival after resection ( $P = 0.6700$ ).

**Conclusion:** Direct liver invasion and portal tract invasion, which features intrahepatic lymphatic invasion, are the main modes of hepatic spread from resectable gallbladder carcinoma. The mode of hepatic spread and residual tumor status, rather than the type of hepatectomy or depth of direct liver invasion, is the most important predictor of survival after resection for gallbladder carcinoma with hepatic involvement. Hepatic metastatic nodules indicate a dismal outcome after resection, and the performance of major hepatectomy is justified only if potentially curative (R0) resection is feasible.

**Abstract ID: 0595**Specific Field: **Hepatobiliary  
and Pancreas Surgery****Mode of pres.: Free Paper**  
**ISW 2011 Session 173.05****Periampullary carcinoma of the young: how do they fare?**J. R. Reddy, R. K. Singh, B. Pottakkat, A. Prakash, A. Behari,  
A. K. Gupta, V. K. Kapoor, R. SaxenaSanjay Gandhi Post Graduate Institute of Medical Sciences,  
Lucknow, India**Introduction:** Periampullary carcinoma is usually a disease of old age. In the young it is expected to be associated with genetic syndromes and behaves aggressively with poor results.**Material and Methods:** Retrospective analysis was done from a prospective database of 320 consecutive patients with periampullary carcinoma who underwent pancreaticoduodenectomy (1990–2007). Statistical tests were used appropriately using SPSS software.**Results:** There were 62 patients with age <40 years (Group A) and 258 patients with age >40 years (Group B). There was no difference in demographics (except age), presentation and operative parameters (except duration of jaundice, which was longer in young,  $P = 0.02$ ). The proportion of patients undergoing pylorus preservation was similar in both groups (50% vs. 48% respectively). Major morbidity like external pancreatic fistula, post pancreatectomy hemorrhage, hepatico-jejunostomy leak, duodeno-jejunostomy leak and intra-abdominal collection were similar as were post-operative hospital stay and tumour pathologic characteristics (Table). Survival analysis showed similar median/3-year survival in both groups (44% vs. 33%,  $P = 0.095$ ) (Figure). Multivariate analysis showed tumour differentiation ( $P = 0.001$ ) and nodal status ( $P = 0.004$ ) to be independent predictors of poor outcome in young and old age groups respectively. Though no investigations were done to test for genetic syndromes, no patient manifested with metachronous malignancies in upper or lower gastro-intestinal tract, on follow-up.**Conclusion:** Contrary to common belief, periampullary carcinoma in young is similar in presentation and outcome to that in old age. Association with genetic syndromes in this subgroup of patients needs to be further studied.**Table** Clinicopathologic and survival analysis of periampullary carcinoma in young vs. old patients

	Group A	Group B	<i>P</i> value
Gender (No.) Male/Female	47/15	183/75	0.27
Duration of jaundice (mean)	3 months	2 months	0.02
Pre op bilirubin mg/dl (mean)	4.3	4.9	0.82
Type of PD	PD-50%, PPPD- 50%	PD-52%, PPPD- 48%	0.77
EPF	19.4%	20.5%	1.00
PPH	17.7%	12.8%	0.30
DGE	10%	12.4%	0.66
Histopathology—ampullary/ distal CBD cholangiocarcinoma/duodenal carcinoma	92%/3%/5%	80%/13%/7%	0.13
Nodal positivity	30.6%	29.1%	0.87
Survival (3 year)	44%	33%	0.095

**Figure:** Kaplan Meier survival curve (young vs. old)**Abstract ID: 0596**Specific Field: **Hepatobiliary  
and Pancreas Surgery****Mode of pres.: Free Paper**  
**ISW 2011 Session 173.06****Combined endoscopic and laparoscopic therapy for acute lithiasic pancreatitis in pregnancy: a case series**A. A. Polydorou, A. Vezakis, G. P. Fragulidis, A. Melemini,  
G. Polymeneas, D. Voros

University of Athens Medical School, Athens, Greece

**Introduction:** The rarity of symptomatic biliary disease in pregnancy and the high clinical awareness about maternal and fetal outcomes, have led to numerous suggestions for the safest and most effective therapeutic approach of such patients. We present our experience of treatment in pregnant women with acute gallstone pancreatitis by applying the same basic therapeutic approach recommended to the non-pregnant patients.**Material and Methods:** Seven pregnant women (2 para null, 3 para one and 2 para two) with mild acute gallstone pancreatitis were referred to our hospital for further evaluation. All patients had obstructive jaundice and elevated serum amylase levels, gallbladder stones and dilated bile ducts. Patients had been treated conservatively over a period of time (3 days, range 2–5 days) with NPO and I.V. fluids and antibiotics. Preoperative MRCP, ERCP and next-day laparoscopic cholecystectomy (LC) were performed in all cases. That was allowed since none of the patients suffered from severe pancreatitis. We applied the same basic pattern of care on pregnant women, except two important alterations: in all cases a thorough MRCP with no use of intravenous gadolinium was performed prior to ERCP and the latter was performed without the use of radiation. The number of stones in the bile duct was clarified from the MRCP, and the procedure terminated only when all stones were retrieved into the duodenum after numerous passages of the balloon catheter.**Results:** The mean maternal age was 28.8 years (range 24–36). One patient was carrying twins. The mean age of gestation was 22.4 weeks (range 13–31). No maternal or fetal deaths were recorded. Infection of the umbilical trauma was noted in one patient, treated by drainage and oral antibiotics. The mean length of postoperative hospital stay was 3

days (range 2–5 days). All but one patient reached a no complicated natural labor term. One patient had a cesarean delivery on week 35, due to history of insulin-dependent diabetes mellitus and twin carriage.

**Conclusion:** Treating pregnant patients with mild acute lithiasic pancreatitis as non pregnant provides excellent outcomes, as long as all related procedures are conducted by highly experienced personnel. We consider of great importance the MRCP examination prior to no radiation ERCP, since that makes the performance of the latter easier and safer.

**Abstract ID: 0597**      Specific Field: **Hepatobiliary and Pancreas Surgery**

**Mode of pres.: Free Paper**  
**ISW 2011 Session 173.07**

**Synbiotics early enteral nutrition: nutrition support team program in hepato-biliary pancreas surgery**

T. Furuya, H. Kotanagi, S. Ouchi, M. Kikkawa, T. Sawada, W. Iwasaki, R. Sakai, T. Kichiraku

Akita Red Cross Hospital, Japan

**Introduction:** There are many risks of malnutrition, metabolic disorders, resulting in severe and often fatal complications in hepatobiliary and pancreas (HBP) surgery. Perioperative nutritional management by early enteral nutrition with synbiotics (S-EN)/nutrition support team (NST) thought to be effective for those problems. However, its evidence is not yet clear. Therefore, we determine the usefulness of the S-EN/NST program in HBP surgery in the different institutes.

**Material and Methods:** Twenty-three-patients from December '05 to November '10 were divided into two groups according to the admitted institute A (until September '09, with NST) or B (without NST). Pancreatico-duodenectomy (PD) was performed by ante-colic digestive reconstruction, mucosa-to-mucosa pancreatic anastomosis (no-stent or lost-stent method). Synbiotics (antibiotics-resistant Lactobacillus, L-glutamine, dietary fiber, an oligosaccharide) was given preoperatively, and semidigestion liquid diet with synbiotics was given with 20 ml/h from 6.5 Fr naso-jejunum feeding tube immediate after post-operative ICU admission. Furthermore, specialized rehabilitation for the early ambulation, and education for patients were performed. The next operative day, gait training was started, and the pedometer wearing was conducted. NST actively supported S-EN. The morbidity (MO; Clavien classification  $\geq$  IIIa, ISGPF  $\geq$  grade B in pancreas surgery), rate of surgical site infection (SSI), postoperative hospitalization period (HP) were compared between two groups.

**Results:** Although the patient's background was different between two groups; group A; 14 pylorus preserving PD, group B; 4 major hepatectomy, 2 distal pancreatectomy, 1 total pancreatectomy, 1 pylorus preserving and 1 subtotal stomach-preserving PD, MO(0.0%), SSI(0.0%) and HP (13.5 (9–30) days) of group A were better than those of group B (33.3%, 55.6% and 27.0 (12–44) days, respectively).

**Conclusion:** S-EN/NST program, especially NST, in hepato-biliary and pancreas surgery was very effective for not only perioperative nutritional and metabolic management but also improvement of the disease outcome itself.

**Abstract ID: 0598**

Specific Field: **Hepatobiliary and Pancreas Surgery**

**Mode of pres.: Poster Discussion**  
**ISW 2011 Session PW 19.01**

**Easy laparoscopic choledochotomy and choledocholithotomy using the V-shaped abdominal wall-lift method**

N. Kurauchi, I. Tsuda, A. Yoshida, H. Yokoyama, H. Kasajima, Y. Hara, S. Toyama, J. Kimura

Hakodate Municipal Hospital, Hakodate, Japan

**Introduction:** Laparoscopic common bile duct exploration (Lap CBDE) for choledocholithiasis has gradually developed for a long time. However, it is still not very popular, probably because stone removal via choledochotomy site and closure of the duct opening by fine suturing seem to be technically difficult. Our V-shaped abdominal wall-lift method with two V-shaped retractors (V-lift) can be easily set up with simple devices, and no need of gas insufflation can make Lap CBDE easier like open surgery.

**Material and Methods:** Between January 2005 and December 2010, we had 58 cases of Lap choledochotomy and choledocholithotomy among 79 cases of Lap CBDE. The surgical procedure is as follows. The abdominal wall is lifted with V-lift system and three to five open ports are placed, among which a large-diameter port is applied for the main operation in the epigastria. The Calot's triangle is developed, the cystic artery is divided with ultrasonic-activated coagulation shears, and the cystic duct is ligated and its tie is retracted to the right outside. The common bile duct is opened with a sharp scalpel usual for open surgery. Saline is irrigated in the duct to remove stones, and then a stone extract clamp or a pliant metal scoop usual for open surgery are adopted to remove stones. While a flexible choledochoscopy is performed to remove remnant stones, bile or perfusate can be continuously sucked by an assistant owing to gasless condition. With a needle holder accustomed to use for laparotomy, the choledochotomy site is sutured and terminated by extracorporeal knot-tying.

**Results:** In 58 cases of Lap choledochotomy and choledocholithotomy performed in the 5 years, median operation time was 173 min, median blood loss was 120 ml, conversion to laparotomy was necessary in 6 cases (12%), and conversion especially due to difficult stone removal was in one. The postoperative diet started at 1.5 days after operation and postoperative hospital stay was 7 days. The major adverse events of Clavien-Dindo Grade III-IV were noticed in 4 cases. Stone clearance was incomplete in one case and choledocholithiasis recurred in two. Four out of five surgeons inexperienced with Lap CBDE could complete this procedure without any special training.

**Conclusion:** We conclude that the difficulties of Lap CBDE can be reduced by using our procedure.

**Abstract ID: 0599**

Specific Field: **Hepatobiliary and Pancreas Surgery**

**Mode of pres.: Poster Discussion**  
**ISW 2011 Session PW 19.02**

**Single-incision laparoscopic cholecystectomy: single institution experience**

T. Kobayashi [1], H. Hirukawa [1], M. Soeno [1], T. Naito [1], H. Matsuoka [1], T. Tada [1], K. Hatakeyama [2]

[1] Tachikawa General Hospital, Nagaoka, Japan, [2] Niigata University Graduate School of Medical and Dental Sciences, Niigata, Japan

**Introduction:** We report our experience with single-incision laparoscopic surgery for cholecystectomy (SILSC) and perform a retrospective comparison with conventional 4-port laparoscopic cholecystectomy (CLC).

**Material and Methods:** Data were retrospectively collected for all patients undergoing SILSC at Tachikawa General Hospital, ( $n = 39$  patients between August in 2009, and November in 2010) and compared with clinical outcome for those who had undergone CLC ( $n = 40$  patients between January in 2008, and July in 2009). Indications for SILSC were chronic cholecystitis with symptomatic cholecystolithiasis in 35, asymptomatic cholecystolithiasis in three, and gallbladder polyp in one. 21 were female, median age was 62 (range, 30–85) years old, and BMI was 24.3 (range, 16.6–29.7)  $\text{kg/m}^2$  in the SILSC patients. A single, 25 mm umbilical incision was made. First 5-mm trocar was placed through an open approach, and two 5-mm ports and a loop retractor were inserted 10 mm away from the first port from the same incision for the first nine cases of SILSC. We used a multi access port (SILS port, COVIDIEN, Japan) for the tenth case of SILSC afterward. Outcome measures are operative time, blood loss, conversion to open operation or additional port requirement, postoperative complications, and length of hospital stay. All data were shown as median value (range).

**Results:** Operative time was longer with SILSC (119 min, 50–186) compared with CLC (70 min, 45–190) ( $P < .001$ ). A correlation was seen between reducing SILS operative time and increasing experience (Spearman rank correlation coefficient,  $r = -0.45$ ,  $P < 0.01$ ). Blood loss of SILSC (5 ml, 5–100) was not different from that of CLC (5 ml, 5–350). Three patients in SILSC required the addition of one extra laparoscopic port because of the gallbladder injury in one, cystic duct injury in one, and the insufficient length of laparoscopic instruments to reach the gallbladder in one patient. No patients in SILSC required conversion to open surgery compared with one patient in CLC. Patients stayed 4 days following SILSC (range, 2–7 days) and 5 days following CLC (range, 2–9 days) ( $P < .001$ ). No patient in each group had postoperative complications

**Conclusion:** SILSC may be equal to CLC in terms of safety and efficacy. Further prospective randomized studies are required to investigate any significant advantages of this new and attractive technique.

**Abstract ID: 0600** Specific Field: **Hepatobiliary and Pancreas Surgery**

**Mode of pres.: Poster Discussion**  
**ISW 2011 Session PW 19.03**

#### Microbiology of gallbladder bile in symptomatic cholelithiasis

K. A. Malik

Sultan Qaboos University Hospital, Muscat, Oman

**Introduction:** Gall bladder disease is the commonest surgical problem and laparoscopic cholecystectomy is the most frequently performed operation. Acute and chronic inflammation of the gall bladder is the most common complication of gall bladder disease. A bacterial cause of cholecystitis has been proposed and bacteria are cultured in upto 46% of patients with acute cholecystitis and in about 11–43% of cases with chronic cholecystitis.

To study the various bacterial pathogens isolated from bile obtained during surgery, a prospective study was conducted in surgical unit 1 of Sultan Qaboos University Hospital Muscat Oman from October 2010 till January 2011 comprising 80 consecutive patients undergoing

laparoscopic cholecystectomy for symptomatic cholelithiasis. The data would be analysed and presented.

**Abstract ID: 0601** Specific Field: **Hepatobiliary and Pancreas Surgery**

**Mode of pres.: Poster Discussion**  
**ISW 2011 Session PW 19.04**

#### A case of Bouveret's syndrome due to an impaction of gallstone into the duodenal bulb

R. Oshima [1], S. Kobayashi [2], R. Kishi [2], K. Onoda [2], S. Koizumi [2], T. Asakura [2], T. Otsubo [2]

[1] St. Marianna University School of Medicine, Kawasaki, Japan,  
[2] St. Marianna University School of Medicine, Japan

**Introduction:** Gastric outlet obstruction caused by impaction of a gallstone into duodenal bulb is called Bouveret's syndrome which is a rare entity. We describe a case of Bouveret's syndrome. A 62-year-old woman was admitted to the hospital because of sudden onset of recurrent vomiting. Abdominal CT scan revealed pneumobilia and a huge gallstone existing in the duodenum. Gastroduodenal endoscopy showed an impacted gallstone into the duodenal bulb. Upper gastrointestinal series revealed a cholecystoduodenal fistula. Laparotomy was performed under a diagnosis of Bouveret's syndrome. At operation, the gallstone had displaced to the jejunum, so it was extracted from the jejunum. And after the cholecystectomy, cholecystoduodenal fistula was closed. In the treatment of this disease, gastrectomy is sometimes necessary not only for the treatment of the cholecystoduodenal fistula but also for the extraction of the impacted gallstone because of the severe inflammation around the bulb. Approach of the treatment must be decided carefully according to the general condition of the patient and based on the correct preoperative diagnosis.

**Abstract ID: 0602** Specific Field: **Hepatobiliary and Pancreas Surgery**

**Mode of pres.: Poster Discussion**  
**ISW 2011 Session PW 19.05**

#### Bile duct injury: pathogenesis, identification, prevention and management—an overview

V. G. Shelat

Tan Tock Seng Hospital, Singapore

**Introduction:** Gallbladder surgery is associated with a minor but significant risk of bile duct injury. Bile duct injury reduces the quality of life, adds to perioperative morbidity, and poses a significant life long risk of biliary stricture, recurrent cholangitis, portal hypertension and biliary cirrhosis. It is also associated with mortality and litigation. While pathogenesis of biliary injury is multifactorial, the prevention begins from the pre-operative assessment of patient. I herewith review the current literature on bile duct injury with particular emphasis on preventive strategy.

**Material and Methods:** A pubmed search was done using the following terms: bile duct injury, common bile duct injury, laparoscopic cholecystectomy, biliary stricture, hepatico-jejunostomy and bile leak. The articles were limited to English language and human studies. A comprehensive review of all the abstracts was done and selected articles were short-listed for complete review. All the articles were studied and information collected is presented herewith.



**Results:** Pathogenesis of bile duct injury

Presentation  
 Role of Intra-operative cholangiogram  
 Various classifications  
 Classic injury  
 Role of diagnostic imaging  
 Goals of treatment  
 Surgical principles  
 Predictors of repair failure  
 Role of interventional radiology  
 Prevention of injury  
 Practical useful tips during dissection  
 When to do intra-operative cholangiogram?  
 Surgical heuristics  
 Future—Robotic cholecystectomy  
 Gallstone dissolution therapy  
 Gallstone lithotripsy  
 Nanosurgery

**Conclusion:** Bile duct injury is a preventable error that would continue to stigmatize surgeon of any seniority until the unforeseen future. A careful and systematic pre-operative evaluation and adherence to strict surgical principles can at least minimize its occurrence.

**Abstract ID: 0603**      Specific Field: **Hepatobiliary and Pancreas Surgery**

**Mode of pres.: Poster Discussion**  
**ISW 2011 Session PW 19.06**

**Choledochal cyst, not just a childhood problem**

A. S. Briezat, Q. S. M. Al-Ani, A. H. Al-Ani, A. Al-Dhumur, O. Sadieh, A. Ghosup, M. Al-Kufahi

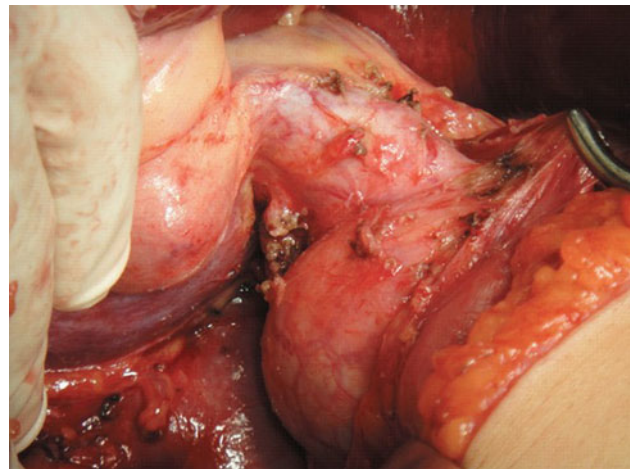
Al-Basher teaching Hospital, Amman, Jordan

**Introduction:** Choledochal disease is uncommon biliary pathology. Most choledochal cysts will present in childhood, about one quarter of patients may only present for the first time during adulthood, with a clinical course slightly differs than that in children and some of these will show malignant transformation.

**Material and Methods:** the clinical data of 12 patients with choledochal cysts were carefully studied from the period of January 2000 to December 2010.

**Results:** There were 3 males and 9 females, with age range from 19 years to 45 years. 10 of the choledochal cysts belong to Todani type IA; 1 type IB and 1 type IVB. Abdominal pain was the commonest presentation. Obstructive jaundice and a malignant change within a choledochal cyst were identified in 1 case. Cholangitis and jaundice in another patient. Anomalous pancreato-biliary junction was recognized in 2 patients. 2 patients were referred after recognition of the choledochal cyst incidentally during laparoscopic cholecystectomy. 10 patients undergoes total excision of the cyst with cholecystectomy and Roux-en-Y hepatico-jejunostomy. One patient presented with liver cirrhosis and advanced hepatic insufficiency, where cystojejunostomy done only. 8 patients remained for follow up and stayed symptom free after a mean of 36 months.

**Conclusion:** Choledochal cyst should be recognized in all patients below 45 years of age presenting with biliary pain, associated with cystic dilatation of bile duct. Cholangiocarcinoma is a dreaded complication of choledochal cyst with adverse outcome because of late diagnosis and a low possibility of resectability. Complete excision of the cyst with restoration of wide biliary-enteric communication by Roux-en-Y hepaticojejunostomy form the basis of ideal treatment.



**Figure:** Choledochal cyst dissected from within the pancreatic head

**Abstract ID: 0604**      Specific Field: **Hepatobiliary and Pancreas Surgery**

**Mode of pres.: Poster Discussion**  
**ISW 2011 Session PW 19.07**

**Value of adapted smaller incisions and video-laparoscopic in cholecystolithiasis treatment: prospective and comparative study**

P. E. Lada [1], F. Florez Nicollini [1], C. Janikow [1], A. Arias [2], E. Fornies [2], L. Gramatica [2]

[1] Hospital Nacionalde Clinicas, Cordoba, Argentina,  
 [2] HospitalNacionalde Clinicas, Argentina

**Introduction:** Laparoscopic cholecystectomy is ben considerate like the gold standard for the treatment of gallbladder stones, however, in the international literature the adapted smaller incisions is still an alternative proceedment. Compare the results of the laparoscopic cholecystectomy with the cholecystectomy by adapted smaller incisions.

**Material and Methods:** Prospective and comparative protocolized study. Between January of 1994 and Dcember 2010, we have made 3822 cholecystectomy in the General Surgic Service “Pablo Luis Mirizzi” of the National Clinic Hospital of Córdoba. In 1735 patients we made laparoscopic cholecystectomy and in 2087 we made cholecystectomy by adapted smaller incisions. This two groups are comparable in age, gender, previous surgics and preoperative diagnostic.

**Results:** We had non mortality, 115 cases (6.62%) in the laparoscopic cholecystectomy was converted to open surgery and 312 (14.94%) of the adapted smaller incisions was extend to the rectum. Postoperative complications was share in two groups, medical and surgery. Medical complications in laparoscopic cholecystectomy was 1.04%, and in cholecystectomy by adapted smaller incisions 2.49%. Surgery complications for the first one was 2.49% and for the second one 6.37%. Bilirraghe was superior and more serious in laparoscopic cholecystectomy with an incidence of 0.55%, cholecystectomy by adapted smaller incisions had 0.23% of bilirraghe.

**Conclusion:** In expert hands, laparoscopic cholecystectomy is the gold standard for the treatment of gallbladder stones. However, in place with restricted but get the cholecystectomy by adapted smaller incisions can be an alternative gold standard. Its a sure and economic proceedment, with a reasonable complexity and less index of surgical lesions.

**Abstract ID: 0605**Specific Field: **Hepatobiliary  
and Pancreas Surgery****Mode of pres.: Poster Discussion  
ISW 2011 Session PW 20.01****Laparoscopic liver resection using the Pringle maneuver  
under a surgical glove**Y. Kawano [1], N. Taniai [1], H. Yoshida [2], Y. Nakamura [1],  
S. Matsumoto [3], S. Mineta [1], M. Yoshioka [1], E. Uchida [1][1] Nippon Medical School Department of Surgery, Tokyo, Japan,  
[2] Nippon Medical School Tama-Nagayama hospital, Department  
of Surgery, Tokyo, Japan, [3] Nippon Medical School, Japan**Introduction:** Although marked development of laparoscopic surgery for liver resection has been seen in recent years, a standardized procedure has not been established. To decrease operative blood loss, we have conducted vascular control by the Pringle maneuver via a surgical glove in laparoscopic liver resection. We show our laparoscopic technique of liver transection without using pre-coagulation.**Material and Methods:** After the examination of abdominal cavity using a laparoscope, an approximately 5 cm vertical incision, is made at the epigastric region. ALEXIS wound retractor (Applied Medical) is placed at the wound and covered with a non-powdered surgical glove, through which any trocar is inserted via the finger tip. After encircle of hepatoduodenal ligament using a Nelaton catheter, a Kelly forceps is inserted via the one finger tip air-tightly and clamp the catheter as the Pringle maneuver. The liver transection was made mainly using the Harmonic scalpel or the VIO soft-coagulation system without pre-coagulation. It's so easy to put on or take off the glove that direct manipulation through the retractor could be done appropriately.**Results:** We have done laparoscopic liver resection in 4 cases with this procedure (lateral segmentectomy and partial resection of the S6 and S4 for metastatic liver tumors, partial resection of the S4 and S6 for solitary HCC of each). Average blood loss of these operations were 232.5 ml and the operative durations were 379 min. No post-operative complication were recognized in all cases.**Conclusion:** Laparoscopic liver resection using the Pringle maneuver under a surgical glove might be feasible and safe procedure.**Abstract ID: 0606**Specific Field: **Hepatobiliary  
and Pancreas Surgery****Mode of pres.: Poster Discussion  
ISW 2011 Session PW 20.02****Utilities of preoperative assessment of abdominal adhesions using  
ultrasound scan in the laparoscopic hepatectomy in patients  
with a history of abdominal surgery**Y. Otsuka, M. Tsuchiya, T. Maeda, J. Ishii, Y. Kubota, A. Tamura,  
S. Kagami, H. Kaneko

Toho University Faculty of Medicine, Tokyo, Japan

**Introduction:** In patients with a history of abdominal surgery (including loco-regional treatments for hepatic tumors), abdominal adhesions may interrupt the performance of subsequent therapy using

the laparoscopy. The purpose of this study is to assess the utility of preoperative detection of abdominal wall adhesions using an ultrasound scan, and the feasibility of laparoscopic hepatectomy (LH) in these patients.

**Material and Methods:** From April 1993 to December 2010, 138 consecutive LH's were performed in 48 patients with a history of abdominal surgery (Group A) and in 90 patients with no history of abdominal surgery (Group B). Since June 2007, the preoperative ultrasonic prediction of abdominal adhesions was attempted in 40 patients awaiting LH with a history of abdominal surgery. The adhesion was defined into 3 grades by the clearness of the gap between the peritoneum and viscera accompanying spontaneous respiration during sliding movements, and was then mapped. In the LH, following the production of the initial laparoscopic access, the actual condition of the adhesions was inspected.**Results:** Thirty-seven of 40 patients were evaluated to be eligible for LH, while 3 patients were excluded due to the extensive adhesions predicted by the ultrasound. Detection in the presence of adhesion was highly reliable with 100% of positive predictive value, 67.7% of negative predictive value, 97.4% of sensitivity and 100% of specificity. Out of 37 cases, the first trocar insertion succeeded in 36 cases except 1 patient who required a second application for the first trocar placement due to mild adhesion (success rate 97.3%). No morbidity was observed relating in creation of pneumoperitoneum in all cases. The operative outcome of Group A was comparable with Group B. There was no perioperative mortality in either group. The presence of metastatic liver tumors was also significantly higher in Group A than Group B [67.7% (32/48) vs. 10.0% (9/90);  $P < 0.01$ ].**Conclusion:** Preoperative detection of abdominal adhesions using ultrasound is considered to be non invasive, convenient and reliable. It would contribute to ensuring the safety, and to increase the number of candidates for LH in patients with a history of abdominal surgery.**Abstract ID: 0607**Specific Field: **Hepatobiliary  
and Pancreas Surgery****Mode of pres.: Poster Discussion  
ISW 2011 Session PW 20.03****Laparoscopic right portal vein ligation for metastatic liver tumors**

H. Inagaki, T. Yokoyama, M. Kikuchi, Y. Yokoyama

Yokoyama Hospital for Gastroenterological Diseases, Nagoya, Japan

**Introduction:** In the case of major hepatectomy and inadequate volume of liver remnant, it is necessary to induce hypertrophy in the future liver remnant. Then in Japan, pre operative assessment is considered to be candidates for percutaneous transhepatic portal vein embolization. In a case with giant liver tumor or multiple tumors, it is often difficult to use the transhepatic route. The aim of this paper was to assess the feasibility of laparoscopic portal vein ligation.**Material and Methods:** This paper was a retrospective review of two cases which were underwent laparoscopic portal vein ligation (LPVL) and we assess the feasibility of LPVL through this review of the data of these cases.**Results:** The cases were 43 year old woman with liver metastasis of descending colon cancer (Case1) and 65 year old man with liver metastasis of rectal cancer (Case2). Case1 was underwent LPVL

only, on the other hand Case2 was underwent low anterior resection after LPVL. The operating times of LPVL were 70 min and 30 min respectively. There was no intra- or postoperative complications, and all procedures of LPVL were completed laparoscopically. The volumetric data showed an increase from 28% to 40% and from 39% to 45%. We performed right lobectomy by laparoscopic-assisted surgery smoothly in Case1, and right lobectomy laparoscopically with partial hepatectomy as planned.

**Conclusion:** LPVL is feasible and safely performed, and induces adequate regeneration of the future liver remnant. We will accumulate more cases and examine the results of this method.

**Abstract ID: 0608**      Specific Field: **Hepatobiliary and Pancreas Surgery**

**Mode of pres.: Poster Discussion**  
**ISW 2011 Session PW 20.04**

**Laparoscopic major hepatectomy: experience from single center**

Z. Subrt [1], A. Ferko [2], B. Jon [2], F. Cecka [2]

[1] Department of Field Surgery, Faculty of Military Health Sciences, University of Defence, Hradec Kralove, Czech Republic,

[2] Department of Surgery, Charles University and University Hospital in Hradec Kralove, Hradec Kralove, Czech Republic

**Introduction:** Liver resection remains the only chance for cure in patients with colorectal cancer liver metastases. The effort to introduce minimally invasive techniques into the liver surgery is evident in recent years. Many clinical trials published recently demonstrated that liver resections performed laparoscopically are safe and feasible. According to previously published studies laparoscopic approach reduces perioperative blood loss, brings early recovery, shorter in-hospital stay and lower postoperative morbidity. Oncological results of laparoscopic liver resections seem to be comparable to open. The technique of laparoscopic liver resection is still not a standard approach for liver malignancies treatment. Laparoscopic liver resections are still performed infrequently and majority of them are left lobe liver resections or wedge resections. Laparoscopic major resections belong to the most technically demanding procedures.

**Material and Methods:** A group of major laparoscopic liver resections performed at the Department of Surgery, University Hospital Hradec Králové, was prospectively analyzed.

**Results:** 29 laparoscopic liver resections were performed. The group comprises of 13 major laparoscopic liver resections and 16 minor laparoscopic liver resections. There were 8 right hepatectomies, 2 right trisectionectomies (extended hepatectomies) and 3 left hepatectomies. The mean hospitalstay was 10.9 days (range 7–18 days). The average ICU stay was 3.2 days (range 1–8 days). The median duration of surgery was 300 min (range 170–425 min). The average blood loss was 320 ml (range 100–1200 ml). Blood transfusion was administered to two patients after right hepatectomy. The 30-day postoperative mortality was zero. We recorded a total of 7 complications in 4 (30.7%) patients. Concerning oncological results, all resections performed for malignancy (13) were with microscopically negative margin at least more than 1 cm (R0).

**Conclusion:** Our data suggest that major laparoscopic liver resections are safe and feasible with good short-term results. Nevertheless major laparoscopic hepatectomy is not an easy procedure and requires advanced technical skills in both major liver surgery and laparoscopy.

**Abstract ID: 0609**

Specific Field: **Hepatobiliary and Pancreas Surgery**

**Mode of pres.: Poster Discussion**  
**ISW 2011 Session PW 20.05**

**The results of laparoscopic liver resection in 22 patients**

K. Ishii

Kitasato University, Sagami-hara, Japan

**Introduction:** A laparoscopic approach to hepatic disease is increasingly performed although its ultimate benefit is yet to be confirmed. Laparoscopic hepatectomy is gradually gaining acceptance as an alternative to open resection in selected patients. The aim of this study is to report our initial institution experience with laparoscopic hepatectomy.

**Material and Methods:** We performed 22 hepatectomies by the laparoscopic approach. These 22 patients were included in the study with varying pre-operative diagnosis such as hepatocellular carcinoma (15 patients), hemangioma (2 patients), metastatic liver tumor (3 patients), focal nodular hyperplasia (1 patient) and hemangiomyolipoma (1 patient). The median age was 61.9 years (21–79) with a female to male ratio of 11:11. Median number (1) and maximum diameter (38 mm (10–100 mm)) were comparable in patients undergoing laparoscopic liver resection. Sixteen left lateral segmentectomy, 5 local resection and one right lobectomy were performed. **Results:** Median intraoperative blood loss was 223 (10–1950) ml. Median operation time was 180 (67–445) minutes. Of the 22 patients, two were converted to an open procedure due to an uncertain adhesion and inadequate exposure. The length of stay was 9.3 days (3–16). There were no morbidities and no mortalities. Of the patients that successfully underwent the procedure laparoscopically, and these were no morbidities. With a follow up, 18 patients with a diagnosis of malignancy have 3 patients of recurrent disease. These 3 patients have no local recurrent. In lateral segmentectomy the amount of bleeding and post operative stay in laparoscopic surgery group was significantly improved compared with those in open surgery group.

**Conclusion:** A minimally invasive approach to hepatic disease is safe and technically feasible with acceptable morbidity.

**Abstract ID: 0610**

Specific Field: **Hepatobiliary and Pancreas Surgery**

**Mode of pres.: Poster Discussion**  
**ISW 2011 Session PW 20.06**

**Laparoscopic splenectomy could make an alternative surgical treatment for HCC with impaired liver function in case of lack in liver graft for transplantation**

Y. Iimuro, T. Okada, A. Yada, Y. Kondo, N. Uyama, Y. Asano, T. Hirano, J. Fujimoto

Dept of Surgery, Hyogo College of Medicine, Nishinomiya, Japan

**Introduction:** Liver transplantation is recommended for the treatment of hepatocellular carcinoma (HCC) with severely impaired liver function, but significant number of HCC patients cannot receive liver transplantation because of shortage in donors, including living-related ones. We have experienced laparoscopic splenectomy (Lap S) in patients with hypersplenism due to HCV-related chronic hepatitis or cirrhosis for the purpose of IFN therapy, and have observed improved liver function after Lap S in many cases. In the present study, we analyzed efficacy and feasibility of Lap S in HCC patients with

hypersplenism and impaired liver function, in combination with surgical or interventional treatment.

**Material and Methods:** Fourteen HCC patients with hypersplenism and impaired liver function who underwent Lap S between 2007 and 2010 were analyzed. Preoperative platelet counts were  $54 \pm 17 \times 10^3/\mu\text{l}$ . Twelve patients received surgical resection on the same day. One patient underwent the resection 2 months after the Lap S and another received TACE after Lap S undergoing the resection against the local recurrence 7 months later. Liver function tests and peripheral blood cell counts were compared between pre- and post-Lap S. During postoperative follow-up, TACE, RFA, or resection was employed against HCC recurrence. Finally, recurrence and survival after HCC treatment were analyzed.

**Results:** No postoperative mortality was observed. The number of platelets and WBC dramatically increased after Lap S ( $P < 0.01$ ). Among liver function tests, prothrombin activity was significantly improved after Lap S (70–85%;  $P < 0.05$ ). Even though the concentrations of s-Alb did not significantly increase, improvement in Child-Pugh scores was detected after Lap S (6.8–5.7;  $P < 0.05$ ). HCC recurrence was detected in 5 out of 14 cases, and 1 patient died of HCC progression. Treatment for the recurrence was re-resection ( $n = 2$ ), TACE ( $n = 2$ ), or RFA ( $n = 1$ ). Two patients died of liver failure at 9 month. Performance status in all survivors are now 0–1.

**Conclusion:** Lap S could be safely performed even in patients with impaired liver function. Lap S in combination with hepatic resection or interventional therapy could make an alternative surgical treatment for HCC with hypersplenism and impaired liver function.

**Abstract ID: 0611**      Specific Field: **Hepatobiliary and Pancreas Surgery**

**Mode of pres.: Poster Discussion**  
**ISW 2011 Session PW 20.07**

**Biliary obstruction due to a huge simple hepatic cyst treated with laparoscopic resection**

Y. Kaneya [1], H. Yoshida [1], T. Matsutani [1], T. Yokoyama [1], S. Suzuki [1], H. Maruyama [1], K. Sasajima [1], E. Uchida [2]

[1] Department of Surgery, Nippon Medical School Tama Nagayama Hospital, Tokyo, Japan, [2] Department of Surgery, Nippon Medical School, Tokyo, Japan

**Introduction:** Most hepatic cysts are asymptomatic, but complications occasionally occur. We describe a patient with biliary obstruction due to a huge simple hepatic cyst treated with laparoscopic resection.

**Material and Methods:** A 60-year-old Japanese woman was admitted to our hospital because of a nontender mass in the right upper quadrant of the abdomen. Laboratory tests revealed the following: serum total bilirubin, 0.6 mg/dl; serum aspartate aminotransferase, 100 IU/l; serum alanine aminotransferase, 78 IU/l; serum alkaline phosphatase, 521 IU/l; and serum gamma glutamic transpeptidase, 298 IU/l. Abdominal computed tomography, ultrasonography, and magnetic resonance cholangiopancreatography revealed a huge hepatic cyst, 13 cm in diameter, at the hepatic hilum, accompanied by dilatation of the intrahepatic bile duct and obstruction of the common bile duct. We diagnosed biliary obstruction due to a huge hepatic cyst at the hepatic hilum, and laparoscopic surgery was performed.

**Results:** A huge hepatic cyst was seen at the hepatic hilum. After needle puncture of the huge cyst, the anterior wall of the cyst was unroofed, and cholecystectomy was done. Intraoperative cholangiography through a cystic duct revealed stenosis of the duct. Subsequent decapsulation of the cyst was performed in front of the

common bile duct. After this procedure, cholangiography revealed that the stenosis of the common bile duct had resolved. Histopathological examination of the surgical specimen confirmed the hepatic cyst was benign. The postoperative course was uneventful, and the results of liver function tests normalized.

**Conclusion:** The patient was discharged 7 days after operation. Computed tomography 3 months after operation revealed disappearance of the hepatic cyst and no dilatation of the intrahepatic bile duct.

**Abstract ID: 0612**      Specific Field: **Hepatobiliary and Pancreas Surgery**

**Mode of pres.: Poster Discussion**  
**ISW 2011 Session PW 21.01**

**Resection of peritoneal dissemination in patients with hepatocellular carcinoma**

M. Hashimoto, K. Sasaki, M. Matsuda, G. Watanabe  
Toranomon Hospital, Tokyo, Japan

**Introduction:** Peritoneal metastases from hepatocellular carcinoma are common at autopsy; being found in 17.6% of autopsy cases of hepatocellular carcinoma have peritoneal metastases. However, effective treatment for peritoneal metastases has not yet been established.

**Material and Methods:** We resected peritoneal metastases 12 times in 9 hepatocellular carcinoma patients. We assessed the clinical course and the prognosis of these patients to determine the effectiveness of resecting peritoneal metastases and the factors related to survival of the patients.

**Results:** The 1, 3 and 5-year survival rate was 58%, 52%, 42% respectively. Four patients survived for more than 2 years without recurrence or with controlled recurrence in the liver. Three palliative resection patients had a poor prognosis, with survival time being 4 months, 9 months and 12 months.

**Conclusion:** Surgical resection is an option for selected patients with peritoneal metastases from hepatocellular carcinoma. The complete removal of peritoneal metastases and the control of cancer in the liver can achieve a survival benefit in selected patients. Peritoneal metastases should be resected in patients with a controlled primary liver tumor, because no other treatment option for peritoneal option for peritoneal metastases.

**Abstract ID: 0613**      Specific Field: **Hepatobiliary and Pancreas Surgery**

**Mode of pres.: Poster Discussion**  
**ISW 2011 Session PW 21.02**

**Spontaneous complete necrosis of advanced hepatocellular carcinoma**

T. Hayakawa [1], H. Yoshida [1], T. Yokoyama [1], H. Maruyama [1], S. Suzuki [1], A. Hirakata [1], K. Sasajima [1], E. Uchida [2]

[1] Department of Surgery, Nippon Medical School Tama Nagayama Hospital, Tokyo, Japan, [2] Department of Surgery, Nippon Medical School, Tokyo, Japan

**Introduction:** We present a rare case of spontaneous complete necrosis of hepatocellular carcinoma (HCC) confirmed by surgical resection.



**Material and Methods:** An 80-year-old man was referred to Nippon Medical School Tama-Nagayama Hospital with HCC. Medical history was significant for hypertension managed with medication, and partial lobectomy of the lung secondary to lung schwannoma. Abdominal aortic aneurysm, 51 mm in maximum diameter, without treatments was detected. The serum concentration of PIVKA-2 was 14300 mAU/ml (normal, <40 mAU/ml), and that of alpha-fetoprotein was 184.2 ng/ml (normal, <6.92 ng/ml). The serum surface antigens for hepatitis B and anti-hepatitis C virus antibodies were negative. Computed tomography (CT) demonstrated hypervascular tumor, 68 mm in diameter, with washout of contrast medium in the left paramedian sector of the liver. Color Doppler ultrasonography revealed hyperechoic tumor with vascular flow. We diagnosed HCC in the left paramedian sector.

**Results:** After 40 days demonstrated HCC by CT, laparotomy was performed. Intraoperative ultrasonography was done, and detected HCC, 30 mm in diameter, decreased in size. After mobilization of the left lobe, left paramedian sectionectomy was performed with intermittent clamping. Pathological examination of the surgical specimen was hard mass of 30 mm in diameter, with fibrosis capsule, macroscopically. Histologically, the tumor totally replaced by a dense infiltrate of inflammatory cells and no viable tumor cells were detected. There were multiple foci hemorrhagic change, ductular proliferation and granulation tissue formation.

**Conclusion:** The patient was discharged 10 days after operation. After a month, the serum concentration of PIVKA-2 (25 mAU/ml) and alpha-fetoprotein (5.9 ng/ml) were decreased to the normal range.

**Abstract ID: 0614**                      Specific Field: **Hepatobiliary and Pancreas Surgery**

**Mode of pres.: Poster Discussion**  
**ISW 2011 Session PW 21.03**

**Combined hepatocellular and cholangiocarcinoma: report of five cases**

I. Kirino, M. Okabe, T. Ito

Kurashiki Central Hospital, Kurashiki, Japan

**Introduction:** Combined Hepatocellular and cholangiocarcinoma (cHCC-CC) is a rare primary liver malignancy. Its preoperative diagnosis is difficult and most cases have been pathologically diagnosed from surgical specimens. Their clinicopathological features, prognosis and outcomes after surgical treatment vary according to the reports.

**Material and Methods:** Five cases with pathologically diagnosed cHCC-CCC were reported. All the patients received hepatectomy from 1991 to 2009 at the Department of Surgery, Kurashiki Central Hospital.

**Results:** From 1991 to 2009, 202 patients had undergone hepatectomy for hepatocellular carcinoma. Of these, 6 cases had a diagnosis of cHCC-CCC from the specimen. One case was excluded from the report because of the separated location of hepatocellular carcinoma (HCC) and cholangiocarcinoma (CCC). Tumors of other 5 patients were diagnosed as Type CcHCC-CCC of Allen and Lisa classification. All the patients were male and average age of surgery was 64.4 years. All the cases were with hepatitis C related chronic liver disease and had well preserved liver function of Child class A. Four of them received partial hepatectomy and the other underwent lateral segmentectomy. Pathologically, 4 out of 5 tumors were expanding growth type and one had a lymph node metastasis. Four patients had developed recurrent disease and all the recurrence were intrahepatic. One patient received hepatectomy again for the recurrent tumor and the new tumor was a pure HCC.

**Conclusion:** Our cHCC-CCC cases shared some clinicopathological similarities with CCC as described in other reports. But different from pure CCC, all the cases had underlying liver diseases and recurrent tumors would not usually show the same pathological feature with the primary tumor

**Abstract ID: 0615**                      Specific Field: **Hepatobiliary and Pancreas Surgery**

**Mode of pres.: Poster Discussion**  
**ISW 2011 Session PW 21.04**

**Clinicopathological characteristics of hepatocellular carcinoma without hepatitis B and hepatitis C virus infection**

K. Takano [1], S. Kikuchi [1], O. Konno [1], Y. Abe [1], K. Kasuya [2], M. Shimazu [1]

[1] Tokyo Medical University Hachioji Medical Center, Tokyo, Japan, [2] Tokyo Medical University, Tokyo, Japan

**Introduction:** The aim of this study was to investigate clinicopathological characteristics of hepatocellular carcinoma without hepatitis B and hepatitis C virus infection in our institute.

**Material and Methods:** A total of 39 HCC patients who underwent surgical operation from November, 2006 to September, 2010 were enrolled in this study. We divided them into 2 groups: in one group, patients were positive for hepatitis B surface antigen or anti-hepatitis C virus antibody (BC-HCC group) and in another, patients were negative for both (nBnC-HCC group). Age, gender, Child-Pugh score, the retention rate of indocyanine green dye at 15 min (ICG R15), surgical procedure, pathological findings, stage, presence of recurrence, disease free survival, and overall survival were compared between these two groups.

**Results:** There were 23 BC-HCC and 16 nBnC-HCC patients, respectively. Stage I/II/III/IV were 4 (17%)/11 (48%)/7 (30%)/1 (4%) in BC-HCC group, and 0 (0%)/9 (56%)/2 (13%)/5 (31%) in nBnC-HCC group. In BC-HCC group, 6 patients had tumor recurrence after initial operation, 4 of them were disease free after additional therapy, 1 had residual tumor after additional therapy, 1 died within one year after initial operation. In nBnC-HCC group, 5 patients had tumor recurrence, 4 of them died within one year after initial operation, 1 had received additional treatment but died in 19 months after initial operation. All patients had tumor recurrence were stage III or IV.

**Conclusion:** Although patients with nBnC-HCC are generally assumed to show a better prognosis than BC-HCC patients, but they tend to be diagnosed more advanced stage. Because the prognosis of advanced stage III or IV nBnC-HCC also show poor prognosis similar to BC-HCC, early detection and treatment is very important.

**Abstract ID: 0616**                      Specific Field: **Hepatobiliary and Pancreas Surgery**

**Mode of pres.: Poster Discussion**  
**ISW 2011 Session PW 21.05**

**Preoperative tumor marker doubling time is a prognostic factor for hepatic resection of hepatocellular carcinoma**

T. Masuda, T. Beppu, H. Baba

Graduate School of Medical Sciences, Kumamoto University, Kumamoto, Japan

**Introduction:** It is important to identify prognostic factors in patients with hepatocellular carcinoma (HCC) before hepatectomy. The aim of

this study was to clarify the predictive efficacy of the preoperative doubling times of alpha-fetoprotein (AFP) and protein induced by vitaminK absence (PIVKA-II).

**Material and Methods:** HCC patients who underwent a hepatic resection between 1998 and 2006 were prospectively evaluated. Serum AFP and PIVKA-II levels were measured at least twice before surgery to calculate the doubling times. Nineteen clinical factors that can be examined preoperatively, including the doubling times of AFP and PIVKA-II were investigated to identify prognostic factors for disease-free and overall survival after hepatectomy.

**Results:** There was no relationship between preoperative levels and doubling times of AFP and PIVKA-II. In a univariate analysis, ten and 13 of 19 factors influenced disease-free survival and overall survival, respectively. With a multivariate analysis, serum PIVKA-II level (Hazard Ratio (HR): 2.22,  $P < 0.001$ ), and doubling time of AFP (HR: 1.88,  $P = 0.01$ ) and PIVKA- II (HR: 2.06,  $P = 0.003$ ) were significant prognostic factors for disease-free survival, and doubling time of AFP (HR: 2.31,  $P = 0.01$ ) and PIVKA-II (HR: 2.40,  $P = 0.006$ ) were significant for overall survival.

**Conclusion:** In HCC patients, the doubling times of preoperative serum AFP or PIVKA-II levels are useful tools to predict early postoperative recurrence and a poor prognosis.

**Abstract ID: 0617** Specific Field: **Hepatobiliary and Pancreas Surgery**

**Mode of pres.: Poster Discussion**  
**ISW 2011 Session PW 21.06**

**Treatment of advanced hepatocellular carcinoma by a novel concurrent chemoradiation therapy**

K. Mihara, M. Tanabe, M. Ueda, K. Aiura, S. Kawachi, O. Itano, M. Shinoda, Y. Kitagawa

Keio University School of Medicine, Tokyo, Japan

**Introduction:** Recently, sorafenib was demonstrated to significantly prolong the overall survival of patients with advanced hepatocellular carcinomas (HCCs); however, treatment compliance is limited and no standard regimen for HCCs with major portal vein thrombosis and extrahepatic metastasis has been established to date. Moreover, very few studies report concurrent chemoradiation therapy (CRTx) for HCCs. This study aimed to evaluate the feasibility and efficacy of novel CRTx with interferon- $\alpha$  (IFN $\alpha$ ) and 5-Fluorouracil (5-FU) for advanced HCCs.

**Material and Methods:** Patients below 75 years of age with a radiological or histopathological diagnosis of advanced HCCs with tumor thrombosis in the major branches or the main trunk of the portal vein with/without extrahepatic metastasis were eligible. Other inclusion criteria were (1) adequate hepatic, renal, and bone marrow reserve; (2) an Eastern Cooperative Oncology Group performance status (PS) 2; (3) a life expectancy 12 weeks. IFN $\alpha$  5,000,000 U was injected intramuscularly on Days 1 and 4 of each week for 4 weeks. Intraarterial/intravenous infusion of 5-FU 300 mg/m<sup>2</sup> was administered for the initial 2 weeks. Concurrent radiation therapy was targeted either the tumor thrombosis and/or extrahepatic metastasis (60 Gy in 20 fractions). Toxicity was evaluated according to the National Cancer Institute-Common Toxicity Criteria. Treatments were discontinued when adverse effects reached grade 3 toxicity or disease progression was radiologically confirmed.

**Results:** Patient age ranged from 56 to 72 years. Background liver disease, hepatitis C: hepatitis B: alcoholic cirrhosis = 6:3:2. The overall 1- and 3-year survival rates were 82% and 37%, respectively, with a median [range] survival of 18 [4–78] months. Adverse events

included grade 1 and 2 myelosuppression, renal/hepatic dysfunction, and altered mental status; however, no grade 3 toxicity or treatment-related deaths were observed.

**Conclusion:** This is the first study to describe concurrent CRTx with IFN $\alpha$  and 5-FU for advanced HCCs. It appears to be highly effective with low toxicity, therefore is a promising treatment strategy for HCCs with major portal vein thrombosis and extrahepatic metastasis.

**Abstract ID: 0618** Specific Field: **Hepatobiliary and Pancreas Surgery**

**Mode of pres.: Poster Discussion**  
**ISW 2011 Session PW 21.07**

**A case report of recurrent icteric type of hepatoma controlled by anatomical hepatic resection and hepatic arterial chemotherapy**

T. Ochiai, M. Iida, S. Yamazaki

Ohta Nishinouchi General Hospital, Kohriyama, Japan

**Introduction:** Hepatocellular carcinoma (HCC) with bile duct tumor thrombi (BDTT) is rare. It is named as “icteric type of hepatoma” and prognosis of this type of patients is very poor. Here we report a case of recurrent HCC with BDTT which was controlled by anatomical resection and hepatic arterial chemotherapy.

**Results:** Case presentation: A 71-year-old woman was admitted to Ohta Nishinouchi General Hospital for epigastralgia. She was diagnosed as HCC, 15 cm in diameter, at the lateral segment. Lateral segmentectomy combined with resection of diaphragm was performed. Postoperative course was uneventful. Six months later she came to us due to jaundice. She was diagnosed as recurrence of HCC with BDTT at the median segment. After biliary decompression and drainage by endoscopic nasobiliary drainage, median segmentectomy, choledochotomy, thrombectomy and T-tube drainage were performed. Tumor thrombus did not show invasion into the extrahepatic duct. As adjuvant chemotherapy, hepatic arterial infusion of cisplatin was performed for 6 months postoperatively. She is doing well without any evidence of recurrence for 14 months since second surgery.

**Conclusion:** Discussion: “Icteric type of hepatoma” was reported in only 1.1–1.9% of resected cases of HCC. The treatment strategy is basically anatomical resection along with removal of BDTT, however it has been controversial whether the bile duct has to be preserved or resected. Considering poor prognosis of “icteric type of hepatoma,” we performed adjuvant chemotherapy through the hepatic artery. The reason for preservation of extrahepatic duct was to prevent complications of hepatic arterial chemotherapy and to perform additional radiofrequency ablation therapy against recurrence in the future.

**Abstract ID: 0619** Specific Field: **Hepatobiliary and Pancreas Surgery**

**Mode of pres.: Poster Discussion**  
**ISW 2011 Session PW 22.01**

**Simple and safety distal pancreatectomy method using automatic suture device to prevent postoperative pancreatic fistula**

Y. Takahashi [1], K. Furuta [2], H. Katagiri [2], K. Ishii [2], Y. Kumamoto [2], Y. Nishi [1], Y. Yasogawa [1], M. Watanabe [2]

[1] Kitasato University, Kitasato Institute Medical Center Hospital, Dep. of Surgery, Kitamoto-shi, Saitama, Japan, [2] Kitasato

University, School of Medicine, Department of Surgery, Sagamiharashi, Kanagawa, Japan

**Introduction:** Postoperative pancreatic fistula (POPF) is common major and critical complication to occur after distal pancreatectomy (DP). However, pancreatic disease in pancreatic body (Pb) and tail (Pt) have been widely treated with DP. Many article reports that the frequency of POPF after DP with any pancreatic stump closure methods (e.g. suture closure method, stapler closure method) ranged from 0% to 45%. We recently use automatic suture device (Echelon®) which is linear stapler with 6-row and very slowly compress and fire the pancreas to prevent POPF. In this report, to confirm the advantage of our method, we compare the stapler closure group by international study group pancreatic fistula (ISGPF) definition with the suture and ligation of only main pancreatic duct (MPD) group in our university.

**Material and Methods:** Forty seven patients underwent DP in Kitasato university hospital between August 2003 and March 2010. The stapler group comprised 25 patients and the suture group comprised 22 patients. We examine patient background (DM, PFD, BMI, s-Alb, and final diagnosis), operative factors (blood loss and open surgery), and postoperative factors (drain-AMY (1POD and 3POD) and ISGPF grade).

**Results:** In background and operative factor, there were no significant difference between stapler group and suture group. In stapler group, grade-PF(–)/A/B/C of ISGPF comprised 8/16/1/0 patients, respectively, whereas 8/9/5/0 patients in suture group. There were significant difference in ISGPF grade B + C between stapler group and suture group [1/25 (4%) vs. 5/22 (22.7%)].

**Conclusion:** Our stapler pancreatic closure method with slow compression and fire significantly decrease ISGPF grade B + C which is may be caused of patient death. We demonstrate the procedure of our simple and safety method.

**Abstract ID: 0620**      Specific Field: **Hepatobiliary and Pancreas Surgery**

**Mode of pres.: Poster Discussion**  
**ISW 2011 Session PW 22.02**

#### **Feasibility and safety of the stapling device during distal pancreatectomy in laparoscopic era**

H. Kasugai, J. Tanaka, Y. Deguchi, H. Kida, K. Nakahara, S. Kudo  
Showa University Northern Yokohama Hospital, Yokohama, Japan

**Introduction:** The purpose of this study was to evaluate the feasibility and the safety of the stapling device during distal pancreatectomy because it was considerable that the stapling device was necessary to divide the pancreas during laparoscopic procedure.

**Material and Methods:** Twenty-six patients underwent distal pancreatectomy for pancreatic disease between January 2004 and December 2009 at our institute. A retrospective review of the medical records for the method of closure of the distal pancreatic stump and mortality and morbidity especially the incidence of a pancreatic fistula was performed.

**Results:** The patients were subdivided two groups. The staple group comprised 13 cases (6 in malignant disease, 7 in benign disease), and the hand suture group comprised 13 cases (8 in malignant disease, 5 in benign disease). In the staple group, 9 out of 13 patients underwent laparoscopic surgery whereas all patients underwent open surgery in the hand suture group. We used the stapling device with triple staggered rows, and transected the pancreas very slowly for more than 10 min. There was no mortality in both groups. According to the

ISGPF definition, the incidence of the pancreatic fistula was 92.3% (Grade A; 11, B; 1) in the staple group and 61.5% (Grade A; 7, B; 1) in the hand suture group. According to the grading of pancreas fistula, the sequential change of the mean amylase concentrations of drain fluid of each groups were as follows, on day one (S group/H group: no fistula; 206/830, A; 4878/5225, B; 12477/22424), on day 3 (S group/H group: no fistula; 45/122, A; 1183/1262, B; 10745/2788), on day 5 (S group/H group: no fistula; 8/4, A; 231/799, B; 14748/5035). According to the grading of pancreas fistula, the mean postoperative hospital stay of each group were as follows, S group/H group: no fistula; 17/16.2, A; 10.5/15.1, B; 46/20.

**Conclusion:** Though the incidence of the pancreas fistula tended to increase in the stapling group, almost all cases were classified as Grade A and required little change in management from normal pathway. Staple closure was considered acceptable and safe alternative to the hand suture technique.

**Abstract ID: 0621**      Specific Field: **Hepatobiliary and Pancreas Surgery**

**Mode of pres.: Poster Discussion**  
**ISW 2011 Session PW 22.03**

#### **Risk factors for postoperative pancreatic fistulas in distal pancreatectomy**

T. Morikawa [1], F. Motoi [2], T. Onogawa [1], T. Naitoh [1], T. Rikiyama [1], Y. Katayose [1], S. Egawa [1], M. Unno [1]

[1] Tohoku University Hospital, Sendai, Japan, [2] Tohoku University, Japan

**Introduction:** Mortality of distal pancreatectomy (DP) has declined in the past a few decades, however, the rate of perioperative complications is still high and pancreatic fistula (PF) after DP contributes to the surgical complication rate. To optimize surgical strategy and postoperative management, it is essential to validate risk factors of PF after DP. Here, we reviewed our institutional experience of DP to identify risk factors for postoperative PF.

**Material and Methods:** From January 2007 to December 2010, a total of 106 consecutive patients underwent DP in Tohoku University Hospital and clinicopathological data and perioperative parameters were recorded. Univariate and multivariate analyses of potential risk factors for the formation of PF were performed. The definition and the grading system for PF used in this study were those proposed by the International Study Group of Pancreatic Fistula (ISGPF).

**Results:** Indication for resection were malignant tumors in 48 patients (45.3%) and ductal adenocarcinoma is the largest entity in malignancy. Spleen preserving DP was performed in 6 patients, and concomitant portal vein resection (PVR) and celiac-axis resection were performed in 7 and 10 patients, respectively. Overall surgical morbidities were occurred in 77 patients (72.7%) and 53 patients (50.0%) developed PF, in which ISGPF grade A occurred in 36, grade B in 12, and grade C in 5 patients. Univariate and multivariate analyses indicated that PVR, the absence of chronic pancreatitis, and amylase concentration of drainage fluid on postoperative day 1 4000 were associated with a higher incidence of PF, and the only independent factor for development of PF grade BC was concomitant PVR.

**Conclusion:** PF is the most common complication after DP, and several factors for developing a PF were identified in this study. In the patients with these predictive factors, prophylactic use of octreotide or nafamostat mesilate might be effective.

**Abstract ID: 0622**Specific Field: **Hepatobiliary  
and Pancreas Surgery****Mode of pres.: Poster Discussion  
ISW 2011 Session PW 22.04****Risk factors for delayed gastric emptying after pylorus preserving pancreaticoduodenectomy**

N. Imamura, K. Chijiwa, J. Ohuchida, M. Hiyoshi

Miyazaki University School of Medicine, Miyazaki, Japan

**Introduction:** Pylorus preserving pancreaticoduodenectomy (PPPD) is generally accepted as a standard operation for periampullary lesions. Delayed gastric emptying (DGE), however, is reported to be the most common and specific complication after PPPD. The mechanism of DGE is not completely understood. The definition of DGE has not been consistent, hence, its reported incidence is varied. The International Study Group of Pancreatic Surgery (ISGPS) proposed the definition of DGE in 2007. The purpose of this study was to evaluate the grade of DGE after PPPD and to examine factors influencing DGE.

**Material and Methods:** From January 2005 to November 2010, 141 consecutive patients underwent pancreaticoduodenectomy at the Department of Surgical Oncology and Regulation of Organ Function, Miyazaki University School of Medicine. Thirty-nine patients who underwent conventional Whipple pancreaticoduodenectomy, total pancreatectomy, and hepato-pancreaticoduodenectomy were excluded from the present study. The remaining 102 patient who underwent PPPD were the subjects of this study. After resection, reconstruction was carried out by the modified Child method. Duodenojejunostomy was employed either by antecolic or vertical retrocolic route. The grade of DGE was classified as the following (ISGPS definition); DGE grade A is inability to tolerate a solid diet by postoperative day (POD) 7 or nasogastric tube (NGT) required for POD 4–7, grade B is inability to tolerate a solid diet by POD 14 or NGT required for POD 8–14, and Grade C is inability to tolerate a solid diet by POD 21 or NGT required for POD 14 and more.

**Results:** The overall incidence of DGE as defined by ISGPS was 17.6%. (18/102. grade A: 10/B: 1/C: 7). The patient with DGE showed significantly prolonged postoperative hospital stay than those without DGE (median 42 days vs. 35 days,  $P = 0.002$ ). Soft pancreas, postoperative pancreatic fistula, and postoperative intraabdominal abscess were significant risk factors influencing DGE by univariate analysis. The reconstruction route of duodenojejunostomy (antecolic or vertical retrocolic) was not the factor associated with DGE. The postoperative pancreatic fistula was the independent risk factor for DGE by the multivariable analysis (Odds ratio = 8.5; 95% CI 2.1–35.4;  $P = 0.003$ ).

**Conclusion:** We conclude that the postoperative pancreatic fistula is the significant risk factor for DGE.

**Abstract ID: 0623**Specific Field: **Hepatobiliary  
and Pancreas Surgery****Mode of pres.: Poster Discussion  
ISW 2011 Session PW 22.05****Evaluation of drainage fluid amylase level  
after pancreatojejunostomy using our method  
in pancreaticoduodenectomy**

N. Koike [1], Y. Ohshima [1], S. Arita [1], T. Takeuchi [1], N. Ohkohchi [2]

[1] Seirei Sakura Citizen Hospital, Sakura, Japan, [2] University of Tsukuba, Tsukuba, Japan

**Introduction:** Pancreatic fistula remains a major complication and an important cause of death following pancreaticoduodenectomy. Safe and easy pancreatoenteric anastomosis without pancreatic fistula is reliable. Postoperative amylase level in the drainage fluid is reported as one of the predictive factor of pancreatic fistula. Here, we show our pancreatojejunostomy method and change of drainage amylase level after pancreaticoduodenectomy using this method.

**Material and Methods:** This study was conducted on 15 patients undergoing pancreaticoduodenectomy in our hospital between December 2007 and October 2010. The ultrasonic dissector was used for dissection of pancreas. Pancreatic drainage tube was inserted into the pancreatic duct and fixed by a 5–0 absorbable monofilament suture. Direct anastomosis between the jejunal wall and pancreatic duct was achieved with at least 8 pieces of 5–0 absorbable monofilament sutures. The pancreatic drainage tube was placed into the jejunum in this step. The stump of the pancreas and the jejunal wall were approximated in one layer with four to six interrupted sutures with 3–0 nonabsorbable monofilament sutures like Kakita method. The flat type closed suction drainage tubes were placed at anterior and posterior portion of anastomosis. Drainage fluid amylase level was checked from day 1 to day 7. And pancreatic fistulas were defined and graded as A, B, or C according to the international study group for pancreatic fistulas (ISGPF) criteria.

**Results:** Postoperative amylase levels in the drainage fluid satisfactory decreased until day 3 (Day 1; 3215 IU/l, Day 2; 1396 IU/l, Day 3; 530 IU/l). The amylase levels of patients with a dilated pancreatic duct (+) group,  $n = 9$  (Day 1; 812 IU/l, Day2; 331 IU/l, Day 3; 167 IU/l) were significant lower than non-dilated duct (–) group,  $n = 6$  (Day 1; 6818 IU/l, Day2; 2993 IU/l, Day 3; 1075 IU/l). Grade A pancreatic fistula was found in one patient of (+) group and two patients of (–) group. Grade B was found only in one patients of (–) group. The amylase level became normal level until day 7 in Grade A. Grade B pancreatic fistula was improved under conservative management and the drainage tube was removed until 5 weeks after operation.

**Conclusion:** Although randomized trials are necessary, it appears that our pancreatojejunostomy is safety after pancreaticoduodenectomy.

**Abstract ID: 0624**Specific Field: **Hepatobiliary  
and Pancreas Surgery****Mode of pres.: Poster Discussion  
ISW 2011 Session PW 22.06****Current management protocol in peri-pancreatic  
pseudaneurysms: a critical analysis at a tertiary care referral  
center in South India**

M. A. Johnson, C. Subramaniam

Kanyakumari Govt. Medical College Hospital, Asaripallam, Nagercoil, Tamilnadu, India

**Introduction:** Haemosuccus Pancreaticus and Haemobilia are rare causes of obscure gastrointestinal bleeding that poses considerable diagnostic and therapeutic challenges. Endovascular treatment has recently been advocated as the preferred therapy.

**Material and Methods:** Prospective analysis of a cohort of 16 patients (12 men, 4 women) from 1998 to 2008. 11 patients had bleeding PAs complicating pancreatitis (chronic in 10 and acute in one), post-traumatic in two patients following blunt liver injury, and



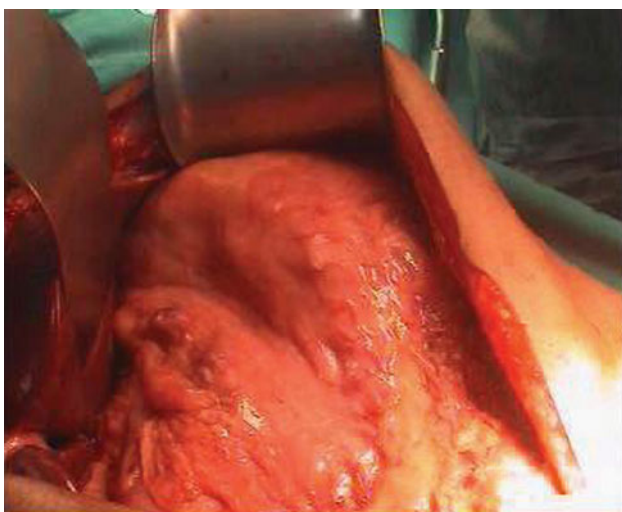
post-operative in 3 patients, following laparoscopic cholecystectomy in two and whipple's pancreatoduodenectomy in one.

**Results:** The mean (range) size of the P. A was 5.45 (2–10) cm. Angiography was undertaken in 11(68.75%) with Transcatheter angiographic embolization (TAE) attempted in 9 (81.8%) and achieving temporary hemostasis in 6(66.6%). Technical failure occurred in 3 (33.3%), secondary intra-abdominal sepsis in one (11.1%), 14 days after embolization and rebleeding in one patient, 2 days after embolization respectively, and were successfully treated by elective operation. 12 patients underwent operative therapy, 6 emergency and 6 elective. Morbidity and rebleeding in the angiographic intervention group were 11.1% each respectively. Surgical morbidity was 41.6% with no rebleeding. No mortality in either group. Follow-up data available for 14 patients without any recurrence of pseudoaneurysm or bleeding after a mean (range) follow-up of 26.3 (45–59) months.

**Conclusion:** A high index of clinical suspicion is essential for early diagnosis and prompt treatment of pseudoaneurysmal bleed with expeditious investigations in all patients with obscure G. I. bleed. TAE should be considered as the first line treatment of choice in all patients presenting with pseudoaneurysmal bleed after adequate resuscitation. Surgery should be reserved only for (i) actively bleeding lesions unsuitable for angioembolization with significant haemodynamic instability (ii) non-availability or failure of embolization (iii) secondary complications such as extrinsic compression or sepsis.

**Table** Blood vessel involved in bleeding pseudoaneurysms

Blood vessel involved	Total No. <i>n</i> = 16
Splenic artery	<i>n</i> = 6
Hepatic artery	<i>n</i> = 5
Pancreaticoduodenal artery	<i>n</i> = 2
Gastrooduodenal artery	<i>n</i> = 2
Middle colic artery	<i>n</i> = 1



**Figure:** Operative picture-splenic artery pseudoaneurysm

**Abstract ID: 0625**

Specific Field: **Hepatobiliary and Pancreas Surgery**

**Mode of pres.: Poster Discussion**  
**ISW 2011 Session PW 22.07**

**Re-operation following pancreaticoduodenectomy**

J. R. Reddy, R. Saxena, R. K. Singh, B. Pottakkat, A. Prakash, A. Behari, A. K. Gupta, V. K. Kapoor

Sanjay Gandhi Post Graduate Institute of Medical Sciences, Lucknow, India

**Introduction:** Literature on re-operation following pancreatoduodenectomy (PD) mainly focuses on early indications like post pancreatotomy hemorrhage (PPH). Data on other indications are limited. Aim: To analyze the incidence, causes and outcome of patients undergoing re-operation during index hospitalization (early) and following index hospitalization (late) after PD, and factors predicting the need for re-operation and mortality in patients undergoing early re-operations

**Material and Methods:** Retrospective analysis of 520 consecutive patients who underwent PD between May 1989 and September 2010. Statistical analysis was done using SPSS software.

**Results:** 96 patients (18.5%) were re-operated of which 72 were early, 24 were late re-operations and 6 patients had both early and late re-operations. Among early re-operations, median time to surgery was 8 days and indications were PPH (68%), pancreaticojejunostomy(PJ)leak with intra-abdominal collection (12.5%), hepaticojejunostomy(HJ) leak (2.8%), duodeno-jejunosotomy(DJ) leak (5.6%), intestinal obstruction (1.4%) and miscellaneous causes (9.7%). Median postoperative stay was 27 days and mortality was 33.3%. On multivariate analysis, jaundice  $>3$  months ( $P = 0.019$ ), PPH ( $P = 0.00$ ), intra-abdominal collection ( $P = 0.027$ ) and DJ/GJ leak ( $P = 0.04$ ) were found to predict the need for early re-operation. Age ( $P = 0.03$ ) and acute renal failure ( $P = 0.01$ ) were predictors of mortality and these patients did not fare poorly on long term follow up. Among late reoperations median time to surgery was 21 months. 13 patients were re-operated for complications of index surgery like incisional hernia ( $n = 4$ ), PJ stricture ( $n = 2$ ), adhesive sub acute intestinal obstruction (SAIO) ( $n = 2$ ), HJ stricture ( $n = 1$ ), DJ stricture ( $n = 1$ ), enterocutaneous fistula ( $n = 1$ ), gastroparesis ( $n = 1$ ) and intra abdominal collection ( $n = 1$ ). 8 patients underwent surgery for disease recurrence like peritoneal dissemination with SAIO ( $n = 4$ ), liver metastasis ( $n = 3$ ), and skin metastasis ( $n = 1$ ). Other indications were complications of radiotherapy ( $n = 2$ ) and gastrointestinal bleed ( $n = 1$ ). Mortality was 4.1%. Excluding 8 patients re-operated for disease recurrence median survival in the remaining 16 patients was 49 months.

**Conclusion:** Early re-operation is a predictor of high mortality after PD. Complications of primary surgery and radiotherapy can be successfully managed with good results on long term follow up.

**Abstract ID: 0626**

Specific Field: **Hepatobiliary and Pancreas Surgery**

**Mode of pres.: Poster Discussion**  
**ISW 2011 Session PW 23.01**

**Results of total pancreatectomy for pancreatic adenocarcinoma**

H. Shirakawa, Y. Sasakura, S. Hishinuma, T. Moriaki, I. Ozawa, Y. Ogata, S. Igarashi

Tochigi Cancer Center, Utsunomiya, Japan

**Introduction:** In recent years, it has been reported that the expected clinical advantages after total pancreatectomy (TP) were limited and it significantly decreased quality of life by resulting in some major metabolic problems. We conducted a retrospective analysis the perioperative and long-term outcome of patients undergoing TP compared with pancreaticoduodenectomy (PD) in our single institution.

**Material and Methods:** Between 1987 and 2009, patients who underwent TP ( $n = 9$ ) or PD ( $n = 67$ ) with R0 resection for pancreatic adenocarcinoma in our institution were identified and compared several data about clinicopathological factors, morbidity, mortality, and long-term outcome. All of TP patients were converted of PD due to an isolated positive neck margin.

**Results:** TP patients underwent resection with longer operative time (681 min vs. 553 min;  $P = 0.014$ ) and had lower rate of preserving pylorus (77.6% vs. 22.2%;  $P = 0.001$ ). Median tumor size (4.0 cm vs. 3.3 cm;  $P = 0.130$ ) and ratio of portal vein resection (66.7% vs. 47.8%;  $P = 0.286$ ) were similar (TP vs. PD). In pathological examination, TP patients showed tumor development along main pancreatic duct (88.9% vs. 32.8%;  $P = 0.001$ ) and had more lymph nodes harvested (63 vs. 41;  $P = 0.004$ ), but the number of lymph node metastases were not significant different (1.1 vs. 4.5;  $P = 0.130$ ). Although operative morbidity rate was similar (55.6% vs. 41.8%;  $P = 0.434$ ), postoperative infectious complication was higher following TP (22.2% vs. 0%;  $P = 0.001$ ). Mortality was none in both groups. The extent of body weight loss was also larger following TP (12.9 kg vs. 5.5 kg;  $P = 0.005$ ). All of TP patients required insulin administration. The HbA1c value was  $7.2 \pm 1.0\%$ . TP and PD patients had comparable recurrence free survival and postoperative survival period (10.9 months vs. 7.4 months;  $P = 0.737$  and 17.7 months vs. 10.0 months;  $P = 0.680$ ). The longest survivor following TP is now alive for 158 months after surgery.

**Conclusion:** Although TP can be performed safely with no mortality and approval morbidity, it would be more stressful and invasive compared with PD. Long-term out come following TP versus PD was equivalent. TP should be performed when oncologically approvable, if patient's quality of life is acceptable.

**Abstract ID: 0627**      Specific Field: **Hepatobiliary and Pancreas Surgery**

**Mode of pres.: Poster Discussion**  
**ISW 2011 Session PW 23.02**

#### Hepatectomy for liver metastases of pancreatic cancer

I. Hirai, W. Kimura, T. Watanabe, K. Tezuka, T. Fukumoto, A. Takeshita, H. Fujimoto

Yamagata University, Yamagata, Japan

**Introduction:** Liver metastases of pancreatic cancer are usually considered as terminal stage. Therefore, non-surgical treatment had been performed. Prognosis for pancreatic cancer become prolonged due to recent advance of chemotherapy.

**Material and Methods:** We will report results for four cases treated with hepatectomy for liver metastases of pancreatic cancer.

**Results:** Case 1. Three metastases were detected after laparotomy for distal pancreatic cancer. Partial resection of the liver and distal pancreatectomy and chemotherapy was performed. This patient survived 1 year and 6 months. Case 2. Distal pancreatectomy, splenectomy,

partial resection of the left kidney and transverse colon was performed for distal pancreatic cancer. Postoperative chemotherapy with gemcitabine was done. After 2 years and 6 months, solitary liver metastasis and para-aortic lymph node metastases were detected in segment 7. Resection of the segment 7 and lymph nodes dissection were done. Case 3. Distal pancreatectomy and chemotherapy was performed after 2 years and 2 months, solitary liver metastasis was diagnosed in segment 2. Left hepatectomy and postoperative chemotherapy with TS-1 was performed. Case 4. After pancreaticoduodenectomy and chemotherapy with gemcitabine, three liver metastases emerged in segment 3, 6 and 8. Hepatectomy was done. She is now doing well and chemotherapy with TS-1 continued. However several treatments were done for other cases, such as radiofrequent ablation, radiation therapy or combined chemotherapy with gemcitabine and TS-1, complete curative state is not obtained. However liver metastases of pancreatic cancer are still poor prognosis and case number is little and follow up periods is short, we summarized as follows.

**Conclusion:** 1. Even if simultaneous liver metastases cases, combined pancreatectomy and hepatectomy with post-operative chemotherapy may prolong patient's survival in some cases. 2. Period between liver metastasis and initial pancreatectomy become longer due to postoperative chemotherapy. Solitary liver metastasis which emerged more than two years after initial pancreatectomy should be considered hepatectomy.

**Abstract ID: 0628**

Specific Field: **Hepatobiliary and Pancreas Surgery**

**Mode of pres.: Poster Discussion**  
**ISW 2011 Session PW 23.03**

#### Curative surgical resection after systemic chemotherapy with gemcitabine/S-1 for locally advanced pancreatic cancer

Y. Takigawa, D. Maeda, M. Fujisaki

Ashikaga Red Cross Hospital, Ashikaga, Japan

**Introduction:** The prognosis of the unresectable pancreatic cancer (PC) is extremely poor and the treatment of PC remains a major challenge. On the other hand the surgical resection offers only opportunity for long survival, but most patients, present with advanced disease at diagnosis and are not candidates for curative resection. Recently the development of chemotherapy or chemoradiation make some effect on local control and survival of locally advanced PC. Several neoadjuvant therapies are studied for downstaging locally unresectable PC allowing for surgical resection, but still they rare lead to surgical downstage.

**Material and Methods:** Now we describe a case of locally advanced unresectable PC treated with systemic chemotherapy with Gemcitabine (GEM) and S-1 followed by curative surgical resection. A 68-year-old man was diagnosed as prostate cancer in urology. Staging computed tomography (CT) revealed pancreatic head tumor over 3 cm in diameter. Endoscopic retrograde cholangiopancreatography showed obstruction of the main pancreatic duct and sever stenosis of the common bile duct. Cytology of pancreatic juice revealed adenocarcinoma. He was diagnosed as unresectable pancreatic head cancer with the invasion of the common bile duct and superior mesenteric artery (SMA). He received systemic combined chemotherapy using GEM at a dose of  $800 \text{ mg/m}^2$  on days 1, 8 and 15, every 4 weeks and S-1 which was administrated orally at  $60 \text{ mg/m}^2$  for two weeks, followed by one-week rest.

**Results:** At the end of 4 courses of chemotherapy the tumor size reduced remarkably and tumor marker level was normalized (CEA; from 11.3 ng/ml to 3.4 ng/ml). There was no severe adverse effect during chemotherapy. After 6 courses of chemotherapy CT revealed further reduction in tumor size and no appearance of involvement with SMA. The patient underwent pancreatoduodenectomy with curative intent. A Pathological examination of the specimen demonstrated small part of well differentiated adenocarcinoma in fibrotic tissue, negative margins and no nodal involvement. During the follow-up, he has been alive without any signs of recurrence for two years since diagnosis.

**Conclusion:** Neoadjuvant systemic chemotherapy with GEM/S-1 may be useful option for treatment of locally advanced PC allowing for curative surgical resection.

**Abstract ID: 0629** Specific Field: **Hepatobiliary and Pancreas Surgery**

**Mode of pres.: Poster Discussion**  
**ISW 2011 Session PW 23.04**

**Proton therapy for pancreatic cancer is associated with a low incidence of gastrointestinal toxicity**

Z. T. Awad, R. C. Nichols, B. S. Hoppe, S. Huh, R. Zaiden, N. P. Mendehall, W. M. Mendehall, N. Xu

University of Florida College of Medicine-Jacksonville, Jacksonville, USA

**Introduction:** A prior dosimetric study from our institution demonstrated significantly reduced small bowel, gastric and right kidney exposure for pancreatic cancer patients receiving 50.40 Gy postoperative adjuvant radiotherapy when compared to patients treated with photon based Intensity Modulated Radiotherapy (IMRT). The current study reviews our clinical experience for our first 14 pancreatic cancer patients treated with protons.

**Material and Methods:** From March, 2009 through November, 2010, 14 patients received proton therapy with concomitant Capecitabine (1000 mg PO BID) for: resected (3); marginally resectable (3); and unresectable (8) biopsy proven pancreatic adenocarcinoma. Proton doses ranged from 50.40–59.40 cobalt gray equivalent. One patient with unresectable disease demonstrated clinical deterioration unrelated to treatment early on in his course and did not complete therapy. One patient died of a self inflicted gunshot wound 5 days after starting treatment. Median follow up for the remaining 12 evaluable patients is 6 months since completion.

**Results:** No patient demonstrated any grade 3 toxicity during treatment nor during the follow up period. Grade 2 toxicities were experienced by 6 patients including: Fatigue (4), Weakness (3); Vomiting (3); and Diarrhea (2). Median weight loss during treatment was 3.6 lbs or 2% of pretreatment body weight. Chemotherapy was well tolerated with a median of 98% of protocol doses delivered. With regard to efficacy: 2 patients are dead of disease; 2 are alive with disease; 8 are alive without disease progression.

**Conclusion:** Our favorable experience with protons in this setting appears to clinically validate our dosimetric study. Observed toxicities appear to be consistent with the baseline toxicities associated with the oral Capecitabine. Although longer term follow up will be needed to assess efficacy, we believe that the low rates or early toxicity will be associated with low rates of late toxicity. We believe that protons may allow for radiotherapy dose escalation, chemotherapy intensification or both.

**Abstract ID: 0630**

Specific Field: **Hepatobiliary and Pancreas Surgery**

**Mode of pres.: Poster Discussion**  
**ISW 2011 Session PW 23.05**

**The surgical and immunohistochemical characteristics of pancreatic ductal adenocarcinoma**

A. Vanags, M. Pavars, I. Strumfa, Z. Simtniece, A. Abolins, J. Gardovskis

Riga Stradins University, Riga, Latvia

**Introduction:** The pancreatic cancer (PCA) remains a significant medical problem due to poor prognosis. Here we present a surgical and extended immunohistochemical (IHC) overview study to indicate the possible targets for intervention.

**Material and Methods:** Fifty one case of potentially radically operated pancreatic ductal adenocarcinoma was retrieved from the archives of P. Stradins Clinical University hospital. The cases included 46 Whipple procedure and 5 distal pancreatectomy materials. TNGR parameters were evaluated. IHC visualisation of vimentin, p53, CD44, NCAM, bcl-2, cyclooxygenase-2(COX-2), cyclinD1 (CycD1), E-cadherin, cytokeratins (CK) 7, 19, 20 and CDX2 was performed. Microvessel density (MVD) was analysed by CD34 and counted using Nikon Eclipse55i. The proliferative activity was determined by Ki-67.

**Results:** The PCA were T3-4N0-1G1-3R0-1 and showed marked perineural growth (Table). Epithelial mesenchymal transition (EMT) by vimentin expression, frequent presence of p53 protein and widespread, intense CD44 expression was characteristic (Table). NCAM was absent in PCA but revealed additional foci of perineural and intraneural growth in 88.2%[76.6–94.5]. Bcl-2 was absent. COX-2 expression was rare and observed in small foci. CycD1 expression rarely exceeded 10%. E-cadherin expression was mostly negative (29.4%[18.7–43.0]) or focal (41.1% [28.8–54.8]). Highly heterogeneous proliferative activity was observed, ranging 6.5–82.7%, mean 23.4%[19.7–27.1]. The MVD was 22.0 [19.4–24.6]. PCA expressed CK7 and 19, focally–CK20, but almost completely lacked CDX2.

**Conclusion:** The molecular parameters as CD44 expression, epithelial mesenchymal transition, lack of COX-2, expression of p53, moderate angiogenesis and proliferation suggest limited possibilities of systemic treatment indicating that surgical intervention is the most important treatment measure at the present time. However, perineural and perivascular (T4) growth ensure the main threat of R1. The cytokeratin profile in combination with CDX2 absence can be helpful in the detection of primary cancer origin.

Characteristics of pancreatic cancer

	Frequency, %	95% confidence interval
T3	82.4	69.7–90.4
R1	52.9	39.5–65.9
N1	70.6	57.0–81.3
G1-2	76.5	63.2–86.0
Marked perineural growth	84.3	72.0–91.8
EMT	33.3	22.0–47.0
Positive p53	58.8	45.2–72.2
Intense CD44	60.8	47.1–73.0
CycD1>10%	23.5	14.0–36.8



**Abstract ID: 0631**      Specific Field: **Hepatobiliary and Pancreas Surgery**

**Mode of pres.: Poster Discussion**  
ISW 2011 Session PW 23.06

**Clinicopathological features of pancreatic invasive ductal carcinoma associated with intraductal papillary mucinous neoplasm: a report of six cases**

Y. Nasu, T. Tsuchikawa, S. Hirano, E. Tanaka, K. Kato, J. Matsumoto, T. Shichinohe, S. Kondo

Department of Surgical Oncology, Hokkaido University Graduate School of Medicine, Sapporo, Hokkaido, Japan

**Introduction:** Intraductal papillary mucinous neoplasm of the pancreas (IPMN) has been reported to be accompanied by invasive ductal carcinoma of the pancreas (PC), synchronously or metachronously, in approximately 10% of all the cases. However, little is known about their clinicopathological features. The aim of this study was to investigate the oncological behavior and the prognosis of PC associated with IPMN.

**Material and Methods:** We reviewed the clinicopathological features of 6 patients diagnosed between 1990 and 2010 as having PC associated with IPMN.

**Results:** Based on the development manner of the 2 lesions, the patients could be classified into 2 groups, synchronous diagnosis ( $n = 3$ ) and metachronous diagnosis ( $n = 3$ ). In synchronous diagnosis group, curative resections were performed by pancreatoduodenectomy (PD) in 1 patient and distal pancreatectomy (DP) in 2 patients, respectively. All the 3 patients were pathologically diagnosed as stage III (according to the UICC 7th edition published in 2009). In metachronous diagnosis group, the median follow up period of the IPMN until the onset of the PC was 156 months (204, 156 and 38 months, respectively). Each patient had regular check up every 6 to 12 months. Curative DP for the PC was performed in 2 patients (stage IIB, III, respectively). Also, PC was found unresectable in 1 patient due to the common hepatic artery involvement (stage III). The median overall survival after the detection of PC was 10 months for all the 6 pts. The survival of the patients having PC associated with IPMN was not better than those having PC alone. In terms of the type of the IPMN, all the 6 patients were with branch type. The size of the cystic lesion in 5 patients were less than 30 mm, except for 1 patient with 57 mm cyst. Besides, all patients did not have nodular lesion(s) in the cyst.

**Conclusion:** Early diagnosis of the PC associating with IPMN was often difficult, even if the check-up had been done regularly. In advanced cases, the prognosis were poor. The IPMN could be accompanied by the PC, regardless of the size or the presence of the nodular lesion(s) in the cyst.

**Abstract ID: 0632**      Specific Field: **Hepatobiliary and Pancreas Surgery**

**Mode of pres.: Poster Discussion**  
ISW 2011 Session PW 23.07

**Intraductal tubulopapillary carcinoma: case report of a new entity of pancreatic cancer**

N. Shinno, M. Tori, H. Akamatsu, T. Nishida, M. Tsujimoto

Osaka Police Hospital, Osaka, Japan

**Introduction:** Intraductal tubulopapillary neoplasm (ITPN) is considered to be a new disease entity encompassing intraductal tubular

carcinoma as a morphologic variant, which was first reported by Yamaguchi, et al. (Am J Surg Pathol. 2009). ITPNs are unusual intraductal pancreatic neoplasms with predominant tubulopapillary growth and all the features of ITPN were distinct from those of other known intraductal pancreatic neoplasms, including pancreatic intraepithelial neoplasia, intraductal papillary mucinous neoplasm, and the intraductal variant of acinar cell carcinoma. We experienced a resected case of this extremely rare new entity, and will present the case in terms of clinicopathological points of view.

**Material and Methods:** case report

**Results:** A 67-year-old man who complained of dull abdominal pain was admitted to our hospital for further examination. On admission, serum tumor markers such as CEA, CA19-9, Span-1, Dupan-2 were all normal. Although, cytology of pancreatic juice during ERCP was class IV and radiological examinations such as CT scan suggested a pancreatic malignant tumor. Namely, there was an enhanced lesion in pancreatic body and MPD was dilated at the distal lesion of this tumor. Preoperative diagnosis was pancreatic cancer and, succeedingly, Hand-assisted laparoscopic distal pancreatectomy with LN dissection (D3) was performed. As intraoperative finding, the tumor was located at the middle of the pancreatic body, white, invasive to the pancreatic capsule, and well circumscribed. Postoperative course was uneventful and adjuvant chemotherapy with TS-1 was added. Now eight months after the operation, there is no sign of recurrence and/or distant metastasis. Pathological findings were “Intraductal tubulopapillary carcinoma (ITPC) of pancreas with focal invasive component; TS4(12 cm), T2(2.1 cm), int, INF  $\beta$ , ly0, v0, ne0, mpd+, du-, ch-, s-, RP-, pv-, a-, pl-, OO-, PCM-, BCM-, DPM-, n(-)”. “Immunohistochemical finding was CK7+, CK19+, CA15-3+, MUC2-, MUC5AC-, MUC6-,  $\alpha$ 1-antitrypsin+,  $\alpha$ 1-antichymotrypsin+, trypsin-”.

**Conclusion:** An extremely rare case of ITPN was operated and closely examined by pathological methods, especially immunohistochemical staining. We report this case clinicopathologically with some consideration of literature none.

**Abstract ID: 0633**      Specific Field: **Hepatobiliary and Pancreas Surgery**

**Mode of pres.: Poster Discussion**  
ISW 2011 Session PW 23.08

**Recurrence patterns after resection of intraductal papillary-mucinous carcinoma of the pancreas**

M. Ueda [1], R. Mori [1], K. Taniguchi [2], R. Matsuyama [2], K. Takeda [2], K. Tanaka [2], C. Kunisaki [1], I. Endo [2]

[1] Yokohama City University Medical Center, Yokohama, Japan, [2] Yokohama City University, Yokohama, Japan

**Introduction:** We aimed to clarify recurrence patterns and an optimal surgical strategy for intraductal papillary-mucinous carcinomas (IPMCs) of the pancreas.

**Material and Methods:** A retrospective review was performed for 37 IPMCs resected in our department from 1992 to 2010. There were 39 cases of intraductal papillary-mucinous adenomas (IPMAs) resected in the same period, which were excluded from the present study.

**Results:** Thirty-seven IPMCs included 16 non-invasive carcinomas (NI), 8 minimally invasive carcinomas (MI), and 13 invasive carcinomas (I). All cases underwent potentially curative resection. Recurrences were seen in one case of NI (6.3%), four cases of MI (50%), seven cases of I (54%), and the five-year overall survival rates were 92.3%, 83.3%, 40.4%, respectively. Recurrence patterns in each group were observed as follows: One invasive carcinoma arising in



the remnant pancreas after resection of NI; two invasive carcinoma in the remnant pancreas, one peritoneal dissemination, and one IPMC in the remnant pancreas after resection of MI; four hematogenous metastases, two local recurrences, and one IPMC in the remnant pancreas after resection of I. Recurrences were seen within one year in nine cases (75%). On the other hand, two recurrent IPMCs were seen more than three years after the first operations. However, one of them had recurrent IPMC twice, and finally died of multiple lung metastases after eight years from the first operation.

**Conclusion:** Prognosis after resection of NI is favorable. In order to improve prognosis of IPMCs, prevention and screening of early recurrence is important, especially after resection of MI and I. Total pancreatectomy at an adequate timing may be feasible in selected patients, such as those who have recurrent invasive carcinoma or IPMCs in the remnant pancreas.

**Abstract ID: 0634**                      Specific Field: **Hepatobiliary and Pancreas Surgery**

**Mode of pres.: Poster Discussion**  
**ISW 2011 Session PW 24.01**

#### Hepatic segmentectomy using one-way method

J. Yoshida, Y. Tanahashi, T. Tokoro, T. Kagawa, C. Takeura, Y. Kato, A. Sugioka

Fujita Health University School of Medicine, Kutsukake-cho, Toyoake-shi, Aichi-ken, Japan

**Introduction:** In our department, all standard hepatic segmentectomy is performed in one direction from left to right (One-way), exposing hepatic vein from proximal to distal preserving Laennec's capsule after confirmation of demarcation line by isolating Glisson's capsule at hepatic hilum. In this method, cut surface of a liver can be kept flat, and both operator and assistant can have good operation field.

**Material and Methods:** Our S8 subsegmentectomy and central bisegmentectomy using One-way method are presented here.

**Results:** [S8 subsegmentectomy] The hilar plate is exposed by cholecystectomy with gall bladder plate dissection, and the glissonian pedicle of the anterior and the posterior segment is secured, respectively. S5 glisson and more glissonian pedicles of the head side are secured by the isolation of the anterior glisson to the distal side. S8 glisson is confirmed by the discolored area. Liver dissection is started from the root of the middle hepatic vein, keeping the Laennec's capsule preserved. Right hepatic vein is also exposed from root to inferior side. Liver dissection is proceeded in one direction from left-superior side to the right-inferior side. S8 glisson is tied and cut off at the root. [central bisegmentectomy] After the anterior and the posterior glisson is secured, glissonian pedicles of internal segment are secured by detaching the umbilical venous plate from the liver at the upper side of the round ligament, and connecting the space to the right margin of the root of UP glisson. Common trunk of middle and left hepatic vein is obtained at the superior side of Arantius plate. Anterior and Internal glisson are clamped, and discolored central bisegment are confirmed. Then hepatic right lobe is mobilized and right hepatic vein is secured. Liver dissection is started from the root of left hepatic vein, and was proceeded in one direction. Umbilical venous plate is exposed and dissected to the right side, and the root of the middle hepatic vein is obtained and cut off. The hilar plate is exposed from umbilical venous plate, and the root of the anterior glisson is revealed and cut off. The root of right hepatic vein is obtained, and exposed toward the distal side. Dissection of the borderline of anterior and posterior segment is proceeded to right inferior side.

**Conclusion:** Various hepatic segmentectomy becomes possible by this method under excellent operation field.

**Abstract ID: 0635**

Specific Field: **Hepatobiliary and Pancreas Surgery**

**Mode of pres.: Poster Discussion**  
**ISW 2011 Session PW 24.02**

#### Liver resection and arrest of bleeding from liver trauma: a novel technique (Rajasinhe technique) developed in a war setting

K. M. Kosala Somaratne [1], H. M. Thilanka Wasumathi Seneviratne [2], K. J. Senanayake [3]

[1] Teaching Hospital Peradeniya, Peradeniya, Sri Lanka, [2] Base Hospital Gampola, Gampola, Sri Lanka, [3] University of Rajarata, Mihintale, Sri Lanka

**Introduction:** During the humanitarian operations of Sri Lanka Armed forces against the terrorists of the LTTE, penetrating missile injuries of the liver were not uncommon among the military casualties. Arrest of bleeding from liver in such injuries is a daunting task; furthermore liver resection in a trauma setting is difficult and challenging. We intend to present a novel and a fast technique designed to address this issue, hitherto non-described in literature.

**Material and Methods:** Two special suture lines are placed across the liver (using a thick absorbable material) separating the damaged and non damaged parts of the liver. A purpose designed needle called the Sinhale needle (named after the first soldier who underwent this procedure) is used to place this particular suture. This effectively cuts off the blood supply to the damaged parts. Resection of the liver is carried out as an emergency or delayed (in 48 h) procedure depending on the stability of the patient.

**Results:** 13 such liver trauma patients were managed from January to May 2009 (08 at right lobe and 05 at left lobe).04 of them had liver resections done at the acute setting (03 at left lobe and 01 at right lobe) and 06 in 48 to 72 h. One patient succumbed to his injuries.

**Conclusion:** Military liver injuries are dreadfully difficult to manage. This new approach made the difficulties fairly eased out. We believe that this new technique (Rajasinhe technique) can be applied for elective liver resections also.

**Abstract ID: 0636**

Specific Field: **Hepatobiliary and Pancreas Surgery**

**Mode of pres.: Poster Discussion**  
**ISW 2011 Session PW 24.03**

#### Aberrant expression of vimentin correlates with dedifferentiation and poor prognosis in patients with intrahepatic cholangiocarcinoma

N. Nagino, T. Wakai, P. V. Korita, M. Inoue, Y. Shirai, Y. Ajioka, K. Hatakeyama

Niigata University Graduate School of Medical and Dental Sciences, Niigata, Japan

**Introduction:** Earlier reports suggested that expression of vimentin promoted cell migration and invasion in tumor cells of malignancies arising from the breast, colon, and prostate. This study aimed to elucidate the prognostic value of vimentin expression in patients with intrahepatic cholangiocarcinoma.

**Material and Methods:** A retrospective analysis of 21 patients who underwent resection for intrahepatic cholangiocarcinoma was conducted. Vimentin expression was positive when single tumor cells or cell clusters showed immunoreactivity for vimentin, whereas

vimentin-negative expression was defined as no detectable expression. The median follow-up time was 78 months.

**Results:** Of the 21 patients, 5 were classified as having tumors with vimentin-positive expression and 16 with vimentin-negative expression. Vimentin-positive expression was more frequent in tumor specimens that were poorly differentiated (4/7 [57%]) than in those that were well or moderately differentiated (1/14 [7%],  $P = 0.025$ ) and was always seen in areas with the highest histologic grade. Survival after resection was significantly worse in patients with tumors with vimentin-positive expression (cumulative 5-year survival rate, 0%) than in those with vimentin-negative expression (cumulative 5-year survival rate, 46%;  $P = 0.010$ ). Cox proportional hazards regression analysis revealed that UICC stages III-IV and vimentin-positive expression (relative risk, 8.485 and 4.294;  $P = 0.002$  and  $P = 0.047$ , respectively) were found to be significant independent risk factors associated with survival after resection.

**Conclusion:** Vimentin-positive expression correlates with dedifferentiation and predicts poor survival in patients undergoing resection for intrahepatic cholangiocarcinoma.

**Abstract ID: 0637**      Specific Field: **Hepatobiliary and Pancreas Surgery**

**Mode of pres.: Poster Discussion**  
**ISW 2011 Session PW 24.04**

**Surgical treatment for the patients of intrahepatic cholangiocarcinoma with lymph node metastases: repeat surgery and combined chemotherapy for recurrence**

Z. Morise, A. Sugioka, S. Umemoto, N. Kawabe, H. Nagata, H. Oshima, J. Kawase, S. Arakawa

Fujita Health University School of Medicine Banbuntanehoutokukai Hospital, Department of Surgery, Nagoya, Japan

**Introduction:** Intrahepatic cholangiocarcinoma (ICC) is increasing worldwide and still remains a major challenge for surgeons with around 30% of 5-year survival rate after curative resection. The results of surgical resection for ICC patients with lymph node metastases are especially poor. We herein evaluate our results of surgical resection for the patients with ICC.

**Material and Methods:** 44 patients with ICC underwent hepatectomy in our institute until 2006. They are including 13 patients with lymph node metastases. Survival rates after first hepatectomy for the patients were calculated and cases of long-term survival were examined.

**Results:** Survival rates after first hepatectomy are 51, 29, 22% for 3, 5, 10 years, respectively. Survival rates of the patients with and without lymph node metastases are 42 and 51% for 3 years, and 28 and 29% for 5 years, respectively. There is no significant difference between the survival curves from the groups. 11 out of 13 patients with lymph node metastases have recurrences after first hepatectomy (7 in residual liver; 2 in lung, lymph node, each; 1 in bone, brain, peritoneum, each). 5 patients with lymph node metastases and 11 patients without actually survived more than 3 years. 4 out of those 5 patients with lymph node metastases underwent repeat surgery for recurrences in the residual liver or the lung and 3 of them underwent adjuvant and/or neo-adjuvant chemotherapy. There is one patient who underwent 4 hepatectomy and 1 pulmonary resection, combined with chemotherapy, and survived 6 years and 9 months.

**Conclusion:** In our series, the outcome of hepatectomy for ICC patients with lymph node metastases is comparable to that for patients without. Although recurrence rate after hepatectomy is high for the patients, the residual liver and the lung are the main sites of recurrence and repeat surgery, combined with chemotherapy, is thought to benefit their survival.

**Abstract ID: 0638**

Specific Field: **Hepatobiliary and Pancreas Surgery**

**Mode of pres.: Poster Discussion**  
**ISW 2011 Session PW 24.05**

**Cystic lesions of the biliary tree**

T. G. Mofokeng, R. Barry, O. Buchel

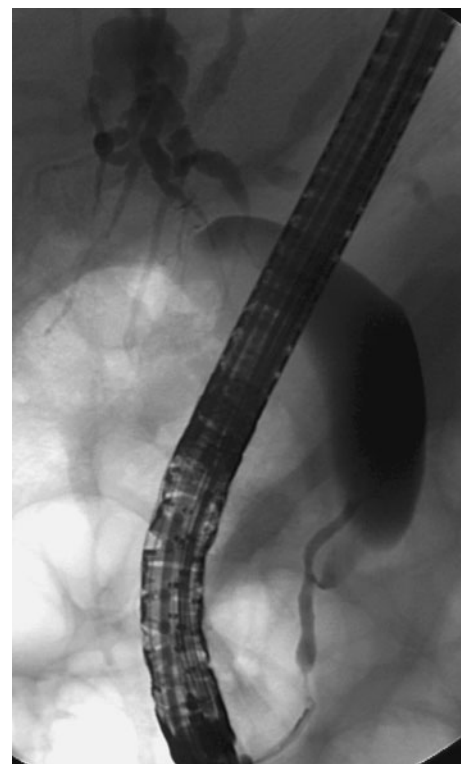
University of the Free State, Bloemfontein, South Africa

**Introduction:** A 46 year old man presented with a choledochal cyst associated with an abnormal pancreaticobiliary duct junction (APBDJ). Surgical excision of a cyst and hepaticojejunostomy were performed. The cyst was a type I according to Todani's classification. This classification (I to V) describes a heterogeneous group of conditions with separate aetiologies and different malignant potential. We therefore propose a revised classification system of cystic lesions of the biliary tree, i.e. types A to D.

**Material and Methods:** We present a case of a choledochal cyst associated with an APBDJ, which was treated by means of surgical resection.

**Results:** Type A cysts are associated with an APBDJ. An APBDJ leads to biliary cyst formation proximally, in the extrahepatic and intrahepatic biliary tract and also predisposes to malignant transformation of the biliary epithelium. Types B and C are possibly congenital duplications and type D is a ductal plate anomaly with cysts only in the intrahepatic bile ducts (Caroli's disease).

**Conclusion:** We also propose that the conditions grouped under the Todani classification be called "cystic lesions of the biliary tree", instead of "choledochal cysts", as some cysts do not involve the choledochus.



**Figure:** ERCP

**Abstract ID: 0639**Specific Field: **Hepatobiliary  
and Pancreas Surgery****Mode of pres.: Poster Discussion  
ISW 2011 Session PW 24.06****Hepatic angiomyolipoma with giant hemangioma**

Y. Kawano [1], H. Yoshida [2], N. Taniyai [1], Y. Mamada [1], S. Mineta [1], M. Yoshioka [1], J. Ueda [1], E. Uchida [1]

[1] Nippon Medical School Department of Surgery, Tokyo, Japan,  
[2] Nippon Medical School Tama-Nagayama hospital Department of Surgery, Tokyo, Japan**Introduction:** Hepatic angiomyolipoma is a rare hepatic mesenchymal tumor often misdiagnosed as hepatocellular carcinoma. We report a case of hepatic angiomyolipoma resected successfully with giant hemangioma.**Material and Methods:** A 53-year-old Japanese woman was admitted to our hospital for further examination of a liver tumor in the segment 4. The tumor in segment 4 was detected by positron emission tomography in health check. The tumor in the segment 4 did not absorb FDG on PET. She had no history of liver disease or hepatitis, and was not heavy drinker. There was no abnormality in laboratory test. The serum surface antigens for hepatitis B and anti-hepatitis C virus antibodies were negative. Tumor markers (e.g.,  $\alpha$ -fetoprotein, PIVKA-2, carcinoembryonic antigen, and carbohydrate antigen 19-9) were negative. On enhanced computed tomography, the tumor in the segment 4 was shown hyperattenuation in the early phase and hypoattenuation in the delayed phase. On magnetic resonance imaging, the tumor in the segment 4 was shown hypointensity on T1-weighted images, hyperintensity on T2-weighted images, and hyperintensity in diffusion weighted images. By imaging findings, primary hepatocellular carcinoma was suspected. Patient desired resection of the tumor in the segment 4 with the giant hemangioma in the segment 7.**Results:** These tumors were resected with free surgical margin by partial resection of the segment 4 and 7 of the liver. The cut surface of the resected specimen in the segment 4 showed a yellowish tumor consisting of mature adipose tissue. The histopathological examinations of the resected specimens were angiomyolipoma in the segment 4 and cavernous hemangioma in the segment 7 of the liver. The tumor in the segment 4 was composed of mature lipocytes with angiomatous, and small lymphocytes components but without mitosis. There was immunoreactivity to SMA and homatropine methylbromide 45, and no immunoreactivity to AE/E3. The postoperative course was uneventful, and the patient has since been doing well over the past a year after the operation.**Conclusion:** Hepatic angiomyolipoma should be suspected in liver tumor patients with normal tumor marker levels and no concomitant hepatitis. Preoperative MRI combined with percutaneous fine-needle biopsy might be the diagnostic methods of choice.**Abstract ID: 0640**Specific Field: **Hepatobiliary  
and Pancreas Surgery****Mode of pres.: Poster Discussion  
ISW 2011 Session PW 25.01****A malignant fibrous histiocytoma (MFH) of the gallbladder  
and the summary of 17 cases in the international literature**

T. Enomoto, T. Asakura, K. Miura, N. Tobe, S. Koizumi, H. Nakano, M. Odanaka, T. Otsubo

St. Marianna University School of Medicine, Kawasaki, Japan

**Introduction:** It is only 16 case reports with malignant fibrous histiocytoma (MFH) of the primary gallbladder tumor in both the Japanese and international literature, even malignant fibrous histiocytoma (MFH) is a most common soft tissue sarcoma in adult. Here, we report a new case of the MFH of the gallbladder and summarized and reviewed findings, treatment and prognosis about all 17 cases in the world.**Results:** We report a case of a 74-year old man was admitted to our hospital because of a right lower abdominal mass. Physical examination showed hard mass was palpable in the middle and lower right abdomen. Laboratory test showed inflammation status. Abdominal CT demonstrated a huge mass extending from the upper to lower quadrant abdomen on the axial view. We operated a diagnosis of soft tissue sarcoma. Histopathology of the resected specimen showed malignant fibrous histiocytoma, high grade. He died 2 months after the operation.**Conclusion:** 1. We report a case of MFH of the gallbladder. 2. Using a CT, we can diagnose primary gallbladder tumor. 3. These have been only 16 case reports of MFH of the primary gallbladder tumor in both the Japanese and international literature. 4. Although we should keep MFH in mind when treating gallbladder tumors and treat aggressively.**Abstract ID: 0641**Specific Field: **Hepatobiliary  
and Pancreas Surgery****Mode of pres.: Poster Discussion  
ISW 2011 Session PW 25.02****Number of positive lymph nodes independently determines  
the prognosis after resection in patients with gallbladder  
carcinoma**

J. Sakata, Y. Shirai, T. Wakai, T. Oohashi, T. Maruyama, K. Hatakeyama

Niigata University Graduate School of Medical and Dental Sciences, Niigata, Japan

**Introduction:** The nodal status is an established prognostic factor in patients with gallbladder carcinoma. This study aimed to compare the prognostic power of the location of positive lymph nodes with that of the number of positive lymph nodes in gallbladder carcinoma. Another aim of the current study was to evaluate the effectiveness of radical lymph node dissection for this disease.**Material and Methods:** A retrospective analysis was conducted of 133 consecutive patients who underwent an R0 radical resection for gallbladder carcinoma. A total of 2,759 lymph nodes taken from the patients were examined histologically. The location of positive regional nodes was classified according to the TNM staging system (the 7th edition). The number of positive regional nodes was recorded for each patient.**Results:** Nodal disease was found in 58 patients, of whom 21 survived for more than 5 years after resection. Univariate analysis revealed that both the location ( $P < 0.0001$ ) and the number ( $P < 0.0001$ ) of positive nodes were significant prognostic factors. Multivariate analysis revealed that the number of positive nodes was an independent prognostic factor ( $P = 0.001$ ), while the location of positive nodes failed to remain as an independent variable. The cumulative 5-year survival rates were 81% for patients without regional nodal disease, 55% for patients with 1–3 positive nodes, and 18% for patients with 4 positive nodes ( $P < 0.0001$ ).**Conclusion:** The number, not the location, of positive lymph nodes independently determines the prognosis post-resection in gallbladder carcinoma. Radical lymph node dissection is effective for selected patients with nodal disease, provided that an R0 resection is feasible.

**Abstract ID: 0642**      Specific Field: **Hepatobiliary and Pancreas Surgery**

**Mode of pres.: Poster Discussion**  
**ISW 2011 Session PW 25.03**

**A retrospective analysis of efficacy of extrahepatic bile duct resection for T2 gallbladder carcinoma**

Y. Hasegawa, H. Nitta, T. Takahara, M. Takahashi, N. Ito, A. Sasaki, G. Wakabayashi

Iwate Medical University, Morioka, Japan

**Introduction:** The efficacy of extrahepatic bile duct resection (BDR) for T2 gallbladder carcinoma is unclear. The aim of this study was to evaluate the significance of extrahepatic bile duct resection.

**Material and Methods:** The medical reports of 28 patients, who had been diagnosed with pathological T2 gallbladder carcinoma, were retrospectively reviewed. Sixteen patients of which had undergone BDR, while 12 patients had not.

**Results:** The 5-year survival rate of patients who had undergone BDR was significantly higher than that of patients who had not (77% vs. 50%, respectively), and the rate of patients with lymph node metastasis who had undergone BDR was also significantly higher than that of patients who had not (80% vs. 0%, respectively). Furthermore, 2 patients who had undergone pancreaticoduodenectomy for lymph node dissection of metastatic posterosuperior peripancreatic nodes were alive for more than 10 years post-surgery.

**Conclusion:** Extrahepatic bile duct resection may thus have prognostic significance for survival in patients with T2 gallbladder carcinoma. In addition, pancreaticoduodenectomy should be attempted for patients with positive posterosuperior peripancreatic nodes.

**Abstract ID: 0643**      Specific Field: **Hepatobiliary and Pancreas Surgery**

**Mode of pres.: Poster Discussion**  
**ISW 2011 Session PW 25.04**

**Prognostic factors for ampullary carcinoma: analysis of 31 cases resected by pancreatoduodenectomy or pylorus preserving pancreatoduodenectomy**

T. Ochiai, M. Iida, S. Yamazaki

Ohta Nishinouchi General Hospital, Kohriyama, Japan

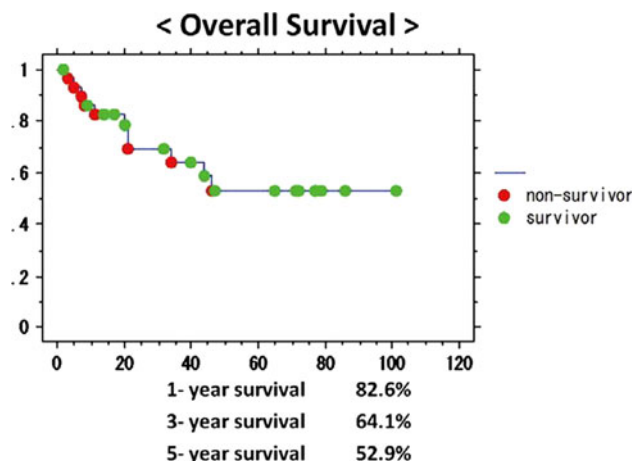
**Introduction:** The prognosis after curative resection for patients with carcinoma of the papilla of Vater is relatively better than that for the other periampullary cancer. However, prognostic factors after resection of ampullary carcinoma have not been identified.

**Material and Methods:** From January 2000 to December 2010, consecutive 31 patients with carcinoma of the papilla of Vater underwent pancreatoduodenectomy (PD) or pylorus preserving pancreatoduodenectomy (PPPD) with dissection of regional lymph nodes. We retrospectively analyzed surgical procedures, macroscopic and microscopic curability, clinicopathologic variables and survival.

**Results:** A total of 31 patients underwent PD or PPPD, aged 44 to 81 years and consisted of 19 males and 12 females. The surgical procedure was PD in 8 patients (25.8%) and PPPD in 23 (74.2%). One 30-day mortality (3.2%) was recognized. Patients were grouped according to TNM-staging as stage 0 ( $n = 3$ , 9.7%), stage IA ( $n = 3$ , 9.7%), stage IB ( $n = 6$ , 19.4%), stage IIA ( $n = 3$ , 9.7%), stage IIB ( $n = 10$ , 32.3%), stage III ( $n = 5$ , 16.1%), or stage IV ( $n = 1$ , 3.2%). No patients died in stage 0, IA and IB, and as stage increased, survival

rates worsened. The overall and disease-free 5-, 3-, 1-year survival rates were 52.9%, 64.1%, 82.6% and 49.5%, 54.5%, 76.2%, respectively. Tumor invasion to pancreas ( $P = 0.03$ ), perineural invasion ( $P = 0.01$ ), operative procedures (the prognosis of PPPD was better than PD,  $P = 0.006$ ), lymph node involvement ( $P = 0.0005$ ) and microscopic surgical margin involvement ( $P < 0.0001$ ) were significant factors affecting the overall survival for ampullary carcinomas by the longrank test.

**Conclusion:** The present data showed that PPPD was better prognosis than PD. In fact, PPPD is the first choice for ampullary carcinoma in our hospital, therefore, PD was only performed for advanced cases, in which PPPD would not have obtained surgical margin negative from cancer. As 42.9% of pT1 revealed lymph node involvement microscopically, to get microscopically resection margin free from carcinoma, the appropriate procedure with lymphadenectomy should be required.



**Figure:** Overall survival of carcinoma of the papilla of Vater

**Abstract ID: 0644**      Specific Field: **Hepatobiliary and Pancreas Surgery**

**Mode of pres.: Poster Discussion**  
**ISW 2011 Session PW 25.05**

**Independent prognostic factors of histology and preoperative value of serum CEA in extra-hepatic biliary tract carcinoma**

H. Kawamata, H. Katagiri, K. Ishii, Y. Takahashi, K. Furuta, Y. Kumamoto, M. Watanabe

Department of Surgery, Medical School, Kitasato University, Sagami-hara, Japan

**Introduction:** Biliary tract cancers require the invasive surgical procedures for cure, and it has been remains controversial for risk factors representing patient prognosis. In this current study, we aimed to disclose prognostic factors independent of stage.

**Material and Methods:** Among the 92 archives of patients who undertook resection of the extra-hepatic biliary tract tumors including papilla carcinoma from 1986 to 2008, 73 were informative for all the clinicopathological factors in a multivariate analysis.

**Results:** Five year disease specific survival (5-yr DSS) was 53.4%, and it was 80.0, 72.7, 50.0, 45.4, and 28.5% in stage I, II, III, IVa, and IVb, respectively. Prognostic factors were histology ( $P = 0.0142$ ), high preoperative CEA (preCEA) ( $P = 0.0002$ ), high preoperative



CA19-9 ( $P = 0.0039$ ), lymphatic invasion ( $P = 0.0109$ ), venous invasion ( $P = 0.0398$ ), gallbladder infiltration (Ginf) ( $P < 0.0001$ ), portal venous invasion (PV) ( $P < 0.0001$ ), lymph node metastasis (N)( $P = 0.0036$ ), perineural invasion ( $P = 0.0002$ ), distal pathological margin ( $P = 0.0098$ ), exposure margin ( $P = 0.0147$ ), residual tumor (R factor)( $P = 0.0164$ ), and postoperative value of CA19-9 (postCA19-9) ( $P = 0.0148$ ), in a univariate manner. Multivariate analysis elucidated that histology ( $P = 0.0081$ ) and preCEA ( $P = 0.0034$ ) were finally remnant independent of stage. The most dismal phenotype of histology (poorly differentiated type) showed only 12.5% in 5-yr DSS. Patients with high preCEA were exclusively included in stage IVa, the most frequent in bile duct cancers, and exhibited a significantly poorer survival than otherwise cases in stage IVa ( $P = 0.0009$ ).

**Conclusion:** We herein newly identified histology and preCEA as independent prognostic factors in extra-hepatic biliary tract cancers, and this identification would be beneficial for clinical clarification of the optimal strategies of this type of cancer.

**Abstract ID: 0645**      Specific Field: **Hepatobiliary and Pancreas Surgery**

**Mode of pres.: Poster Discussion**  
**ISW 2011 Session PW 25.06**

**A case of distal cholangiocarcinoma with high sensitivity to neoadjuvant chemoradiation therapy**

Y. Haji [1], Y. Katayose [2], M. Mizuma [1], H. Hayashi [1], F. Motoi [1], T. Rikiyama [1], S. Egawa [1], M. Unno [1]

[1] Department of Surgery, Tohoku University Graduate School of Medicine, Sendai, Japan, [2] Integrated Surgery and Oncology, Tohoku University Graduate School of Medicine, Sendai, Japan

**Introduction:** Advanced cholangiocarcinoma has a poor prognosis. We expect the neoadjuvant chemoradiation therapy with gemcitabine to improve the prognosis of cholangiocarcinoma, and determined that the recommended dose was 45 Gy in 25 daily fractions of 1.8 Gy and 600 mg/m<sup>2</sup> of gemcitabine (day 1, 8, 22, 29) from phase I study (in press). The subsequent phase II study is ongoing. We report a very effective case to the neoadjuvant chemoradiation therapy for distal cholangiocarcinoma, which reduced levels of the tumor markers, CEA and CA19-9, markedly.

**Material and Methods:** Case report: A 50-year-old man presented jaundice and general fatigue. Serum tumor markers were clearly elevated (CEA 10.2 ng/ml, CA19-9 6280.0 U/ml), and abdominal CT scan revealed an enhanced mass in the lower bile duct, the dilatation of the intrahepatic to the middle bile duct and a swollen regional lymph node measuring 16 mm in short diameter. Endoscopic ultrasonography showed invasion into the pancreatic parenchyma. Endoscopic retrograde forceps biopsy showed adenocarcinoma. After the neoadjuvant chemoradiation therapy with gemcitabine, both of CEA and CA19-9 were decreased within normal range (CEA 4.3 ng/ml, CA19-9 12.0 U/ml). Also on CT scan, the main tumor was slightly detectable, and the swollen node was reduced more than 30% in short diameter, measuring 11 mm. Therefore the effect of the neoadjuvant chemoradiation was considered partial response (PR) in RECIST guideline (version 1.1). The patient underwent subtotal stomach-preserving pancreatoduodenectomy 2 weeks after the chemoradiation therapy and had no perioperative complications. Pathological examination showed a good response, Grade 2b on Oboshi-Shimosato's classification.

**Conclusion:** In this case, the neoadjuvant chemoradiation therapy had a good effect in pathological findings as well as in the tumor markers. From our studies so far, the subsequent surgery including major hepatectomy has been performed safely (submitted data). The efficacy of the neoadjuvant chemoradiation therapy for cholangiocarcinoma will be evaluated on the ongoing phase II trial.

**Abstract ID: 0646**      Specific Field: **Hepatobiliary and Pancreas Surgery**

**Mode of pres.: Poster Discussion**  
**ISW 2011 Session PW 26.01**

**A case of the pancreatic duct stenosis at the body with focal atrophic and fatty change of the adjacent parenchyma**

G. Yoshimatsu [1], N. Sakata [1], M. Mizuma [1], K. Ishida [2], F. Motoi [1], Y. Katayose [3], S. Egawa [1], M. Unno [1]

[1] Department of Surgery, Tohoku University Graduate School of Medicine, Sendai, Japan, [2] Department of Pathology, Tohoku University Hospital, Sendai, Japan, [3] Integrated Surgery and Oncology, Tohoku University Graduate School of Medicine, Sendai, Japan

**Introduction:** Stenoses of the main pancreatic duct with diffuse atrophic changes in distal parenchyma were shown commonly in many pancreatic diseases. Recently we encountered a patient who had local narrowness of the main pancreatic duct with focal atrophic and fatty change of adjacent parenchyma.

**Material and Methods:** A 61-year-old woman was admitted to our hospital for repeated left flank pain. She had only a slight spontaneous pain. Laboratory data were as follows: CEA 2.7 ng/dl, CA19-9 2.0 U/ml. On CT examination, a low density area was shown as atrophy at the pancreatic body, but tumors were undetectable in the pancreas. Endoscopic retrograde cholangio pancreatography showed that smooth narrowness of the main pancreatic duct at the body and the dilatation of the distal duct. There were no malignant cells in pancreatic juice by cytological examinations. PET-CT showed no abnormal hot spot. Ultimately we performed distal pancreatectomy, because we could not deny malignancy. In the resected specimens, local atrophic change was detected in parenchyma of the pancreatic body. Histological findings revealed the stenosis of the main pancreatic duct with wall thickness due to fibrosis, increasing of fibroblasts and slight infiltration of neutrophil. Focal atrophy with fatty change was detected in the adjacent distal parenchyma of the stenosis. In addition, PanIN 1A-B was recognized at the margin of the stenotic duct. There was no sign of adenocarcinoma.

**Conclusion:** We considered that fatty change was caused by chronic pancreatitis involving the pancreatic duct stenosis, not by epithelial proliferation of pancreatic duct because fatty change required longer time than neoplastic changes. Epithelial proliferation was considered as secondary change. Recently autoimmune pancreatitis was noted as idiopathic duct-centric chronic pancreatitis (IDCP) and lymphoplasmacytic sclerosing pancreatitis (LPSP). Although IDCP was characterized much neutrophil infiltration around the pancreatic duct, in our case it was seen less than in typical IDCP. LPSP was characterized high level of the IgG4, but it was normal range, so our case was untypical as autoimmune pancreatitis. We experienced a case with a rare type of pancreatic duct stenosis, who underwent surgery finally for risk of malignancy, but operative indication for the similar cases might be well considered.

**Abstract ID: 0647**      Specific Field: **Hepatobiliary and Pancreas Surgery**

**Mode of pres.: Poster Discussion**  
**ISW 2011 Session PW 26.02**

**A case of secondary duodenal stenosis with partial pancreatomegaly similar to groove pancreatitis after having a long term cryptogenic backache**

K. Hirai [1], Y. Matsumoto [1], T. Kiryuu [2], H. Sakurai [1], K. Saitou [1], M. Ide [1]

[1] Sagami Kousei General Hospital, Sagamihara, Japan,  
[2] Asahi Clinic, Sagamihara, Japan

**Introduction:** Duodenal stenosis is well known as one of the complication of groove pancreatitis. It frequently occurs associated with typical symptoms or examination data. We treated such a case of duodenal stenosis with findings, which resembles those of groove pancreatitis after having a long term cryptogenic backache.

**Material and Methods:** We report the case of 40-years-old man without having a past history of drinking and smoking. The strong backache had been presented at 38-years-old according to his chief's complain. His blood tests, CT and US were not able to identify a diagnosis in at this time. He had been treated for two years by morphine for pain control. Recurrent vomiting and stomachache persisted for last 3 months. We re-examined him with blood tests, CT, gastro endoscope and hypotonic duodenography, and these tests showed the marked swelling in the head of the pancreas and duodenal stenosis, but did not show any malignant findings and abnormality in blood test.

**Results:** A gastrojejunostomy and adhesiotomy were performed for duodenal stenosis. His post operative course has been uneventful, and he has been free from morphine pharmaceutical treatment for 3 months.

**Conclusion:** The groove pancreatitis is a segmental chronic pancreatitis that affects the anatomical area among the pancreatic head, the duodenum and the common bile duct referred to as the groove area. The pathogenesis of groove pancreatitis is thought to be anatomical or functional obstruction of the minor papilla. In clinical practice, about 80% of patients complain of a symptom of duodenal stenosis. Blood tests often show a slight elevation of serum pancreatic enzymes and of serum hepatic enzymes occasionally. But a few of these articles has been reported some cases that are not appeared in amylase enzymes and bilirubin elevation caused by avoiding the main pancreas duct obstruction. This condition should be kept in mind when making the differential diagnosis of pancreatic masses and duodenal stenosis. Awareness of this disease may lead to more reliable diagnosis and help to avoid unnecessary palliative treatment.

**Abstract ID: 0648**      Specific Field: **Hepatobiliary and Pancreas Surgery**

**Mode of pres.: Poster Discussion**  
**ISW 2011 Session PW 26.03**

**A case of cyst-forming neuroendocrine tumor of the pancreas with a history observed over 11 years**

K. Ko, T. Ohta, K. Hayashi, A. Tsunoda, M. Mike, H. Kusanagi, S. Yamada, N. Kano

Kameda Medical Center, Kamogawa, Japan

**Introduction:** When a neuroendocrine tumor of the pancreas is more than 2 cm in diameter, surgical therapy is indicated. Therefore it is

rarely observed for long period. Furthermore, it is more unusual to observe cyst-forming neuroendocrine tumor of the pancreas for more than 10 years. Herein we report a rare case with a cyst-forming neuroendocrine tumor of the pancreas that had been observed over 11 years before resection. Especially when a neuroendocrine tumor with cystic lesion is found, necrosis of the solid structure is thought to be the cause of the cystic change. However, in this case, the solid structure was believed to have arisen from the margin of the sharply-demarcated cyst. This interesting finding is reported here.

**Results:** Case: A67 year-old female. Current medical history: In July 2006, a cystic lesion of 3 cm in diameter at the tail of the pancreas was detected during the detailed medical examination for the abnormal shadow in the chest region, but was not followed up. In November 2009, the patient developed ITP, and the pancreas tumor was detected again during the medical examination. The patient was referred to our department for surgery for ITP and pancreas tumor.

**Past medical history:** In 1999, the patient developed pneumonia. CT scan at that time showed a small cystic mass in the pancreatic tail, when reviewed retrospectively.

**Imaging findings:** Sharply-demarcated cystic lesion was confirmed on CT. Contrast enhancement was identified in the cyst wall and solid structure of the margin of the cyst. Compared to 2006, it had decreased in size overall but the membrane had thickened. EUS, US showed a mass with smooth and clear margin which includes multiple small round-shaped hypo-echoic areas within it. The patient was diagnosed as having a solid and pseudo-papillary tumor, and laparoscopic distal pancreatectomy with splenectomy was performed. Pancreatography of the resected pancreas suggested no communication between the pancreatic duct and the cystic lesion.

**Histopathological findings:** Tumor cells showed solid papillary proliferation with hyper-vascular extra-cellular matrix. Other examinations showed Chromogranin A(+), synaptophysin(+), Insulin(-), gastrin(-) MIB-1 labelling index 0.58%. These results established the diagnosis of well-differentiated endocrine tumor.

**Abstract ID: 0649**      Specific Field: **Hepatobiliary and Pancreas Surgery**

**Mode of pres.: Poster Discussion**  
**ISW 2011 Session PW 26.04**

**Amylase and alanine transaminase levels as discriminators of aetiology in an urban South African population with acute pancreatitis**

Z. Moolla, F. Anderson, S. R. Thomson

University of Kwazulu Natal, Durban, South Africa

**Introduction:** In acute pancreatitis (AP), serum elevations of amylase and alanine transaminase (ALT) have been shown in western series to be predictive of aetiology. We analysed these concepts in the context of a South African cohort which includes anti-retroviral therapy and hypertriglyceridemia.

**Material and Methods:** A prospectively collected database of 386 AP patients admitted to Addington Hospital, Durban between 2001 to 2008 were analysed. The relationship between admission Amylase or Alanine Transaminase (ALT) and aetiology based on history, abdominal ultrasound and serum triglycerides were studied. 238 patients (17 females) were admitted with acute alcoholic pancreatitis (AAP), 76 patients (21 males) with acute gallstone pancreatitis (GSAP), 42 patients (15 males) with pancreatitis secondary to anti-retroviral therapy (ARVAP) and 30 patients (4 males) with AP due to hypertriglyceridemia (HAP).

**Results:** Patients with GSAP had significantly higher ( $P < 0.001$ ) mean (range) serum amylase levels than those with non-biliary causes (1888 U/l [153–7500 U/l] vs. 811 U/l [60–7576 U/l] in AAP, 1058 U/l [25–3040 U/l] in HAP and 705 U/l [58–2838 U/l] in ARVAP. Patients with GSAP also had significantly higher ( $P < 0.001$ ) mean (range) serum ALT levels than those with non-biliary causes (171 U/l [6–673 U/l] vs. 43 U/l [8–404 U/l] in AAP, 42 U/l [10–206 U/l] in HAP and 47 U/l [6–200 U/l] in ARVAP. No statistically significant difference in Amylase or ALT was found amongst the non-biliary aetiologies ( $P > 0.05$ ). An ALT level of  $>56$  U/l had a sensitivity of 71%, specificity of 80% and a negative predictive value of 91% for gallstones.

**Conclusion:** GSAP average amylases were double that of other aetiologies. A normal ALT was highly predictive of non gallstone aetiology. Neither amylase nor ALT could help differentiate the other aetiologies.

Amylase and ALT: mean and standard deviation values (units/l) for respective aetiology

	Gallstones	Alcohol	ARV	Hypertri-glyceridemia
Amylase mean (sd)	1888 ( $\pm$ 1606)	811 ( $\pm$ 861)	705 ( $\pm$ 683)	1058 ( $\pm$ 952)
ALT mean (sd)	171 ( $\pm$ 165)	43 ( $\pm$ 42)	47 ( $\pm$ 44)	42 ( $\pm$ 42)

**Abstract ID: 0650** Specific Field: **Hepatobiliary and Pancreas Surgery**

**Mode of pres.: Poster Discussion**  
**ISW 2011 Session PW 26.05**

**Postoperative hematological significance after spleen-preserving distal pancreatectomy with conservation of the splenic artery and vein for pancreatic benign or borderline malignant lesions.**

K. Tezuka, W. Kimura, I. Hirai, T. Watanabe, T. Fukumoto, T. Moriya, S. Murayama, A. Takeshita

Yamagata University Faculty of Medicine, Yamagata, Japan

**Introduction:** Spleen-preserving distal pancreatectomy with conservation of splenic artery and vein (SpDP) has been performed worldwide for the benign or low-grade malignant lesions of the pancreas. The early postoperative significance of this procedure is still unclear. The aim of this study is to reveal the early postoperative hematological significance in SpDP.

**Material and Methods:** We retrospectively reviewed 53 consecutive patients who underwent distal pancreatectomy with or without splenectomy for pancreatic benign or borderline malignant lesions from July 1998 to June 2010. Twenty-one patients underwent SpDP. Thirty-two patients underwent distal pancreatectomy with splenectomy (DPS). Laboratory values (red and white blood cell counts, platelet counts, serum hemoglobin, hematocrit, C-reactive protein and albumin levels) in the 1st, 2nd and 3rd postoperative day, 1st and 2nd postoperative week, 1st and 3rd postoperative month and clinical factors were compared between the SpDP and the DPS group.

**Results:** There were no significant differences in the clinical factors including the postoperative systemic inflammatory response syndrome (SIRS) and the C-reactive protein (CRP) levels in the early postoperative phase between the two groups, which indicated that surgical invasion of the two groups were almost the same. The serum hemoglobin and hematocrit levels on 1st postoperative month were

significantly higher in the SpDP group than the DPS group ( $P < .05$ ). White blood cell counts (WBC) on 3rd postoperative day (POD) and platelet counts on 1st postoperative week were significantly higher in the DPS group than the SpDP group and these significant difference continued to 3rd postoperative month. WBC counts of the DPS group on 1POD had a higher tendency than the SpDP group ( $P = .059$ ), but not significantly.

**Conclusion:** The hematological significances of the splenic preservation in distal pancreatectomy are the good recovery of serum hemoglobin and hematocrit levels at the 1st postoperative month and to reduce the postoperative hematological abnormality such as an elevation of serum platelet and white blood cell counts, which occur at early postoperative phase.

**Abstract ID: 0651** Specific Field: **Hepatobiliary and Pancreas Surgery**

**Mode of pres.: Poster Discussion**  
**ISW 2011 Session PW 26.06**

**Pancreatectomy monitoring hepatic arterial flow with transonic flowmetry during operation for safely**

M. Ito, M. Shimura, A. Horiguchi, S. Miyakawa

Fujita Health University, Toyoake, Japan

**Introduction:** The matters that require attention are hepatic blood flow when it enforces pancreatectomy for the progress pancreas cancer. We reported it as the blood flow confirmation safely before by monitoring hepatic venous oxygen saturation (ShvO<sub>2</sub>) to prevent hepatic ischemia caused by occlusion of common hepatic artery. However, there were difficult to insertion technically and it takes a long time to insert a catheter before an operation, without this method, it not start an operation. This time we use a hepatic arterial flow with transonic flowmetry hepatic artery during operation. It is simpler and easier and, in addition, it is effect for safely for the operation.

**Material and Methods:** The medical records of all patients undergoing resection of pancreatic head from January 2010 to December 2010 were performed. Pancreatoduodenectomy (PD) were 24 patients, distal pancreatectomy with en bloc celiac axis resection (DP-CAR) were two patients. Data are expressed as mean standard deviation.

**Results:** When it measured a common hepatic artery (CHA), a peculiar hepatic artery (PHA), the blood stream of the gastroduodenal artery (GDA) using a hepatic artery monitoring hepatic arterial flow with flowmetry during operation. It was  $2.1 + 0.21$  ml/s,  $1.4 + 0.7$  ml/s,  $1.7 + 0.35$  ml/s. When CHA was exposed to clamped it, CHA  $2.1 \pm 0.1$  ml/sec, PHA  $1.3 \pm 0.2$  ml/sec, GDA  $0.01$  ml/sec to rise afterwards. Operation time was  $356 \pm 32$  min, blood loss was  $359 \pm 224$  ml, hospital stay was  $25.4 \pm 8.8$  days. DP-CAR: CHA  $2.0$  ml/sec, PHA,  $1.2$  ml/sec, GDA,  $1.6$  ml/sec, when CHA was exposed to clamped it, PHA was  $1.8$  ml/sec, GDA was  $2.0$  ml/sec. Operation time was  $357$  min, GOT/GPT  $102/82$ , blood loss was  $552$  ml. Hepatic blood flow confirms that it is supplied stability in this. The postoperative course was uneventful in all patients.

**Abstract ID: 0652** Specific Field: **Hepatobiliary and Pancreas Surgery**

**Mode of pres.: Poster Discussion**  
**ISW 2011 Session PW 26.07**

**The safety of using mechanical stapler in distal pancreatic resection**



Y. Kumamoto, K. Furuta, H. Katagiri, K. Ishii, H. Kamata, M. Watanabe

Kitasato University, Sagamihara, Japan

**Introduction:** The appropriate management of the pancreatic remnant following distal pancreatic resection remains a clinically relevant problem. We carried out a retrospective analysis which focused on this point and compared the two methods (main pancreatic duct ligation and stapler closure).

**Material and Methods:** Before 2007, distal pancreatic resection was simply done by the ligation of main pancreatic duct following cutting the pancreas sharply in our institute. After 2007, we introduced stapler (Echelon60<sup>®</sup>) in cutting the distal pancreas. We have performed 57 distal pancreatic resection from 2005 to 2010. According to the methods of pancreatic resection, we divide into 2 groups: Group A (main pancreatic duct ligation group,  $n = 27$ ), Group B (stapler resection group,  $n = 30$ ). The morbidity, mortality, incidence of pancreatic fistula, drain amylase, serum amylase, operation time, blood loss between 2 groups were compared. Pancreatic fistula was considered according to the novel international standard definition (ISGPF).

**Results:** Overall, postoperative morbidity due to pancreatic fistula occurred in six patients (22.2%) in group A and in four patients (13.3%) in group B ( $P = 0.54$ ), with no deaths. Drain amylase on day 1 was 3366 IU/l in group A and 3366 IU/l in group B, drain amylase on day 3 was 2327 IU/l in group A and 2190 IU/l in group B (NS). Serum amylase on day 1 was 465.8 IU/l in group A and 467.5 IU/l in group B (NS). Operation time was 290 min in group A and 309 min in group B (NS). Blood loss was 689 ml in group A and vs. 852 ml in group B ( $P = 0.34$ ).

**Conclusion:** According to the data, no significant difference for either main pancreatic duct ligation or stapler closure was observed, with the tendency for stapler to be superior.

**Abstract ID: 0653**      Specific Field: **Hepatobiliary and Pancreas Surgery**

**Mode of pres.: Poster Discussion**  
ISW 2011 Session PW 27.01

**ERCP vs. long-term external biliary drainage after surgery of hydatid liver cysts**

M. Mehrabi Bahar, A. Jangjoo, M. Asadi, M. Noory

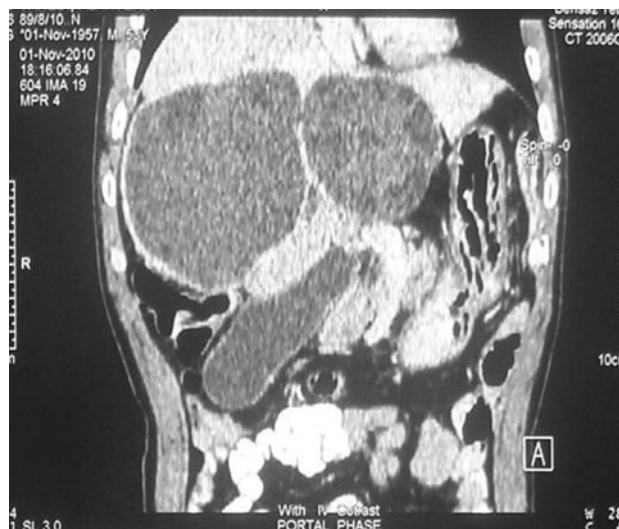Surgical Oncology Research Center, Imam Reza Hospital, Faculty of Medicine. Mashhad University of Medical Sciences, Mashhad, Iran

**Introduction:** Human cystic echinococcosis, a zoonotic infection caused by *Echinococcus granulosus*, is still a significant public health problem in certain endemic regions (Including Middle East, Mediterranean region and Russia). Primary disease may develop in almost any organ, but the liver is the most frequently involved organ. This paper compares the efficacy and safety of ERCP and long-term external biliary drainage after surgery of liver hydatid cysts.

**Material and Methods:** A retrospective review of 9 open surgery and one percutaneous drainage on 10 patients was performed. These patients were selected from 55 cases of liver hydatid cyst who had undergone open or percutaneous drainage and led to biliary fistulae through a previously inserted drain. All these patients were followed up for at least one month without any sign of improvement. ERCP and sphincterotomy performed in all of them to evaluate the efficacy of this method on cessation of biliary drainage.

**Results:** Mean patient age and liver cyst size for the 10 patients was 53.5 years and 12.6 cm respectively. Patients had various number of cysts from 1 to 3. All biliary fistulae stopped in a week or less. There were no significant complication after ERCP other than a mild and transient pain.

**Conclusion:** This study suggests that ERCP and sphincterotomy effectively controls biliary leakage after open or percutaneous drainage of liver hydatid cysts. This procedure should be considered soon in the post-operative phase of liver hydatid cysts complicated with biliary fistulae.



**Figure:**

**Abstract ID: 0654**      Specific Field: **Hepatobiliary and Pancreas Surgery**

**Mode of pres.: Poster Discussion**  
ISW 2011 Session PW 27.02

**Is preoperative biliary drainage for obstructive jaundice in patients with cancer of the head of the pancreas justified?**

K. Kosumi, H. Takamori, H. Baba

Kumamoto University Hospital, Kumamoto-city, Japan

**Introduction:** Preoperative biliary drainage for cancer of the head of the pancreas was reported to increase the risk of biliary infection. Therefore, preoperative biliary drainage is usually not performed in Europe and the United States. In Japan, preoperative biliary drainage for obstructive jaundice is performed to intent prevention of liver dysfunction after surgery.

**Material and Methods:** Between April 2005 and September 2010, 62 patients with cancer of the head of the pancreas underwent pancreaticoduodenectomy. We performed preoperative biliary drainage in 25 patients, including PTBD (percutaneous transhepatic biliary drainage) or PTGBD (percutaneous transhepatic gall bladder drainage) in 10 pts, ERBD (endoscopic retrograde biliary drainage) in 14 pts, and ENBD (endoscopic nasobiliary drainage) in 1 pt. We compared preoperative factors (age, sex, Hb, Plt, Alb, T-Bil, AST, ALT, Amy, past history), operative factors (operative time, blood loss, transfusion), and postoperative complications (pancreatic fistula, SSI, biliary culture, respiratory complication, circulatory complication, other complication) of preoperative drainage group (POD group) and non-preoperative drainage group (N-POD group).



**Results:** Study subjects included 27 men and 35 women. The median age was 67.7 years. Median time of drainage was 45.4 days. Preoperative drainage made to decrease average serum T-Bil levels from 8.4 mg/dl to 1.2 mg/dl. No significant difference of serum T-Bil level at operation was observed between POD group (1.2 mg/dl) and N-POD group (0.8 mg/dl). There was no significant difference of the other preoperative factors and operative factors between two groups. Biliary bacterial positive rate was significantly higher in POD group (100%) than N-POD group (14.3%), but no significant difference was observed about postoperative complications.

**Conclusion:** Preoperative biliary drainage for cancer of the head of the pancreas made to increase biliary infection after pancreaticoduodenectomy, but there was no significant clinical disadvantage.

**Abstract ID: 0655**      Specific Field: **Hepatobiliary and Pancreas Surgery**

**Mode of pres.: Poster Discussion**  
**ISW 2011 Session PW 27.03**

**Complications of percutaneous metallic biliary stents in the ERCP era: a single center experience**

K. Wong [1], J. Hyde [1], J. Tronijaya [1], T. Wright [2], D. Gilles [1], K. Ip [2]

[1] John Hunter Hospital, Newcastle, New South Wales, Australia,  
[2] John Hunter Hospital, Australia

**Introduction:** Percutaneous transhepatic cholangiography (PTC) and palliative self-expanding metal stent insertion for malignant biliary obstruction is regarded as safe and effective with low morbidity and mortality. This is due to studies of diagnostic PTCs in the 1970s to 90s. Advances in endoscopic management of biliary obstruction has changed the patients presenting for PTCs. Few studies have evaluated the complications of percutaneous stenting in this new population. Plastic biliary drains are associated with increased complication rates compared with diagnostic PTCs. This retrospective study investigates whether metal stent insertion is associated with increased complications.

**Material and Methods:** From May 2003 to May 2010, 109 patients underwent PTC with insertion of self-expanding metal stents for obstructive jaundice in our radiology department, 100 for inoperable malignant obstruction, 10 with previous biliary surgery (age range 37–97 years, mean age 71 years). 88(81%) had a previous failed ERCP. Success was defined as the successful deployment of a functioning stent. Obstruction was classified into proximal, middle and distal. 163 procedures were performed (range 1–4 per patient). In 33(20%) ultrasound was used to aid access. 5 proceeded to surgical bypass. Complications were divided in sepsis, bile leak, bleeding and technical groups.

**Results:** Improvement evidenced by a decrease in serum bilirubin was achieved in 104 patients(95%). Major bile leak occurred in 3 patients (2.8%), major new sepsis needing icu in 4(3.7%). Inpatient mortality was 5.5% (bleeding in 3 and new sepsis in 3). In 22 of 64 patients (34%) requiring more than 1 PTC, initial failure reason was insufficient biliary access. Survival range was 0 to 705 days (mean, 147 days). Complications were associated with a mean survival of 88 days. The type of malignancy, position of obstruction and use of ultrasound did not influence complication rates. Coagulation studies were normal in bleeding complications. 100 had 2 PTCs (major:minor complications = 14%:20%), 9 had 3 PTCs (0%:58%). 76(86%) of failed ERCPs were due to inability to cannulate the CBD or to pass a guidewire proximally.

**Conclusion:** Percutaneous transhepatic metallic stenting is associated with higher complication rates than accepted guidelines for diagnostic PTCs as well as recent retrospective studies of transhepatic plastic stents.

**Abstract ID: 0656**      Specific Field: **Hepatobiliary and Pancreas Surgery**

**Mode of pres.: Poster Discussion**  
**ISW 2011 Session PW 27.04**

**Natural history of abdominal fluid collections following pancreatic resection**

M. Sierzega, T. Kowalczyk, K. Figula, J. Kulig

Jagiellonian University Medical College, Krakow, Poland

**Introduction:** Rates of intra-abdominal complications in pancreatic surgery remain relatively high despite marked progress in the surgical technique and perioperative care. However, data related to the natural history of abdominal fluid collections (AFC) following pancreatic resections are scarce.

**Material and Methods:** Medical records of patients who underwent pancreatic resections between 1995 and 2005 were reviewed to evaluate the incidence and specific therapy of AFC. Abdominal ultrasound was routinely performed on postoperative day 3 to 5 in all patients, including asymptomatic cases, based on a training programme in ultrasound for surgical residents. Additional tests (ultrasound, CT, biopsy and/or drainage) were performed as required.

**Results:** Four hundred and nineteen patients with all required data were identified. AFC were diagnosed in 126 (30%) patients, including intra-abdominal abscess in 32 (7.6%), symptomatic sterile collections in 38 (9%) and asymptomatic collections in 56 (13%) cases. Twelve patients with abdominal abscess underwent percutaneous drainage and 20 required reoperation. All symptomatic sterile collections were successfully drained percutaneously, while asymptomatic collections regressed spontaneously without specific treatment. Among various clinical and demographic parameters, only hypoalbuminaemia (relative risk (RR) 3.66; 95% CI 1.02–13.08;  $P = 0.046$ ), pancreatic fistula (RR 5.15, 95% CI 1.49–17.76;  $P = 0.009$ ), and biliary fistula (RR 23.46, 95% CI 6.30–87.30;  $P = 0.001$ ) were the independent factors predicting the need for interventional treatment of AFC.

**Conclusion:** Intra-abdominal fluid collections are relatively common in pancreatic surgery, but most require no special treatment.

**Abstract ID: 0657**      Specific Field: **Hepatobiliary and Pancreas Surgery**

**Mode of pres.: Poster Discussion**  
**ISW 2011 Session PW 27.05**

**The effect of administration of hochuekkito, Japanese herbal medicine, kampo, after PHRSD or PpPD with pancreatogastrostomy**

S. Nomoto, A. Nakao

Nagoya Graduate School of Medicine, Nagoya, Japan

**Introduction:** [Background and Aim] Pylorus-preserving pancreaticoduodenectomy (PpPD) or pancreas head resection with segmental duodenectomy (PHRSD) is today considered the treatment of choice for various types of periampullary or pancreas head tumors. Delayed

gastric emptying (DGE) comprised one of the most troublesome complications of this operation. In this study, we aimed to examine the clinical effects of Hochuekkito, one of the traditional herbal medicine, Kampo (Japanese for herbal), on patients who were undergoing PHRS or PpPD with pancreatogastrostomy.

**Material and Methods:** [Patients and Methods] Forty-two patients were undergoing PHRS or PpPD with pancreatogastrostomy in Nagoya University Hospital between January 2003 and March 2009. Thirteen of 42 cases were administered to take 7.5 g of Hochuekkito three times a day (2.5 g/time) after the 4th post-operative day. Regarding the effects on nutritional status and systemic inflammation, we compared two groups: Group A was administered the Hochuekkito (13 cases) and Group B, was not given Hochuekkito (29 cases).

**Results:** [Results] The interval period to start oral intake after surgery was significantly decreased in Group A,  $12.7 \pm 5.70$  days, as compared with Group B,  $27.7 \pm 14.71$  days ( $P = 0.0011$ ). There was a significant decrease in the amount of time required to remove CV catheter in the Group A  $23.30 \pm 8.91$  days after operation compared with  $37.85 \pm 17.23$  in Group B ( $P = 0.068$ ). Body temperature values were not significantly different in both groups during postoperative days 1 to 3,  $38.430 \pm 225.00$  in group A and  $484.28 \pm 212.16$  in group B. However, the value was significantly smaller in Group A  $77.53 \pm 59.92$  between postoperative days 4 to 14, as compared with Group B  $186.42 \pm 185.31$  ( $P = 0.0464$ ). In addition, the hemoglobin values significantly recovered three months after operation in group A,  $2.13 \pm 1.73$  (g/dl), as compared with in group B,  $0.58 \pm 1.35$ , ( $P = 0.0035$ ).

**Conclusion:** [Conclusion] The administration of Hochuekkito helps to improve disorders after PHRS or PpPD operation. It is recommended to administer the Hochuekkito after surgery.

**Abstract ID: 0658**      Specific Field: **Hepatobiliary and Pancreas Surgery**

**Mode of pres.: Poster Discussion**  
**ISW 2011 Session PW 27.06**

#### Utility of a critical pathway for pancreaticoduodenectomy

K. Horino, H. Takamori, O. Nakahara, A. Chikamoto, H. Tanaka, T. Ishiko, T. Beppu, H. Baba

Kumamoto University, Kumamoto, Japan

**Material and Methods:** Between July 2006 and November 2010, 95 consecutive patients underwent PD for periampullary diseases in Kumamoto University Hospital, 68 before implementation of a critical pathway on July 2009 (prepathway group), and 27 after (postpathway group). We compared pre-operative factors (age, gender, DM, coexistence disease, smoking, Hb, Platelets, serum albumin, serum total bilirubin, AST, ALT, amylase, preoperative bile drainage), intra-operative factors (disease, operative methods, operative time, bleeding amount, blood transfusion), post-operative complications (pancreatic fistula, SSI, heart or respiratory complications) period of drain insertion, and postoperative hospital stay between the two groups, retrospectively.

**Results:** This study included 48 men and 47 women. The median age was 71 (32–85). Pancreatic cancer was in 42, bile-duct cancer in 33, and others in 20. We performed conventional PD in 8, pylorus preserving PD in 13 and sub-stomach preserving PD in 74. After resection we reconstructed by the Billroth II method with pancreatogastrostomy. No significant difference of pre-operative factors, intra-operative factors and post-operative complications between the two groups. Average period of drain insertion was 8.5 days in postpathway group, significantly shorter than 20.2 in prepathway group. Average postoperative hospital stay was 24.5 days in postpathway group, significantly shorter than 35.2 in prepathway group.

**Conclusion:** Implementation of a critical pathway for PD can be demonstrated to diminish period of drain insertion and postoperative hospital stay without increase of complications.

**Abstract ID: 0659**      Specific Field: **Hepatobiliary and Pancreas Surgery**

**Mode of pres.: Poster Discussion**  
**ISW 2011 Session PW 27.07**

#### Transarterial angioembolisation in the management of ruptured hepatocellular carcinoma

D. Yeo

Tan Tock Seng Hospital, Singapore, Singapore

**Introduction:** Spontaneous rupture of hepatocellular carcinoma (HCC) is a complication of HCC with high morbidity and mortality. There are many treatment modalities, with liver resection and transplantation offering the best chance of cure. This study aims to assess the outcome of the management of acutely ruptured hepatocellular carcinoma using transarterial angioembolisation.

**Material and Methods:** Medical records of 22 patients who had undergone transarterial angioembolisation for spontaneously ruptured hepatocellular carcinoma between January 2005 and December 2010 were identified and retrospectively analysed. A variety of factors were examined, including initial clinical presentation, type of angioembolisation used, post-procedure complications, 30 day mortality, need for re-intervention and eventual operative treatment.

**Results:** The most common clinical presentation was epigastric pain in 20 patients (90.9%), while 10 patients (45.4%) had hypotension at time of presentation. All transarterial angioembolisation were performed in and emergency setting. 13 patients (59%) that presented with acute rupture of hepatocellular carcinoma had a Child-Pugh score  $>10$ . In the acute phase, transarterial chemoembolisation achieved haemostasis successfully in 19 patients (86.3%). Gelfoam was used in 10 patients (45.5%), coil was used in 8 patients (36.6%). Median time taken for transarterial angioembolisation was 40 min (27–54 min). Post-procedure complications were analyzed, with transaminitis being the most common in 8 patients (36.6%), and re-bleeding occurring in 2 patients (9%). 14 patients (63.6%) successfully underwent staged liver resection, of which definitive resection was performed in 8 patients (57%). Median length of hospital stay was 4 days (2–8 days). 30-day mortality after transarterial angioembolisation was 4.5% (1 patient). (data is preliminary)

**Conclusion:** The aim in the management of an acutely ruptured HCC is to achieve haemostasis. Regardless of stage of liver cirrhosis at time of presentation, transarterial angioembolisation is a safe and effective modality to achieve haemostasis in acutely ruptured HCC, and serves as a bridge to curative liver hepatic resection at a later date in an elective setting.

**Abstract ID: 0660**      Specific Field: **Hepatobiliary and Pancreas Surgery**

**Mode of pres.: Poster Exhibition only**  
**ISW 2011 Session PE 324**

#### Study of appropriate surgical timing for liver metastasis of colon cancer: from tumor reducing speed by chemotherapy

Y. Sasaki, S. Osada, K. Yoshida, K. Yamaguchi, T. Takahashi, K. Nonaka, N. Okumura

Department of Surgical Oncology, Gifu University, Graduate School of Medicine, Gifu, Japan

**Introduction:** Development of chemotherapy has changed treatment strategy for liver metastasis of colon cancer. Surgical treatment for liver metastasis is the best effective and the high radical therapy, but on the other hand, the surgical timing or method is controversial.

**Material and Methods:** The subjects are 50 cases of liver metastasis of colon cancer from 2006 to 2010. The major axis of liver tumors is measured on 5 mm slice contrast computed tomography (CT). In the case of multiple liver metastases, five larger tumors are selected. The numbers of 144 liver tumors are poked up. The tumor reducing speed is calculated from divided the variation of the major axis by duration days of the images. We study appropriate surgical timing and chemotherapy effect from the duration of the reducing tumors is re-growth, therapy for the re-growth tumors and appearance ratio of diminished tumors.

**Results:** Reducing average speed of 35 cases/101 tumors (the other tumors don't reduce) is 0.57%/day at day 14; the speed is gradually falling, 0.36%/day at day 70, 0.26%/day at day 112, 0.09%/day at day 126 respectively. The most reducing ratio of all tumors is 2.17%/day and the duration is day 27 from 14. The numbers of once reduced but re-growth tumors are 61(60.4%) and reducing average duration is  $188.20 \pm 104.53$  days. Surgical therapy was performed on 13 cases/30 tumors (20.8%). The numbers of 7 cases/18 tumors in 11 cases/36 tumors changed chemotherapy resume were reduced once again. In recurrence 6 cases (46.2%) after surgical therapy, preoperative period was  $240 \pm 198.84$  days, but it was  $343.14 \pm 210.25$  days in no recurrence cases. Eighteen tumors (54.5%) in diminished 33 tumors on CT were pointed out once again and the period from diminished to re-growth was  $270.07 \pm 205.11$  days. On the other hand, 15 tumors was not recurrence for  $311.56 \pm 319.66$  days.

**Conclusion:** Because the reducing speed of tumors by chemotherapy is gradually falling, we should consider surgical therapy for the patient at six month from start of chemotherapy. And diminished tumors by chemotherapy have high potential ratio of recurrence, we will be carefully followed up for ten months.

**Abstract ID: 0661** Specific Field: **Hepatobiliary and Pancreas Surgery**

**Mode of pres.: Poster Exhibition only**  
**ISW 2011 Session PE 325**

**Role of chemotherapy before and after hepatectomy for patients with liver metastasis of colorectal cancer**

H. Imai, S. Osada, Y. Sasaki, N. Okumura, K. Nonaka, T. Takahashi, K. Yamaguchi, K. Yoshida

Gifu University Graduate School of Medicine, Gifu, Japan

**Introduction:** Recent advancement of chemotherapy for colorectal cancer (CRC) has an influence on treatment strategy for liver metastasis of CRC. In the present study, we retrospectively investigated the role of chemotherapy before and after hepatectomy in patients with liver metastasis of CRC.

**Material and Methods:** From April 2005 to March 2010, patients who underwent hepatectomy for liver metastasis of CRC were included in this study. Patients were classified according to the presence or absence of chemotherapy before and after hepatectomy, synchronous or metachronous hepatectomy, treatment regimen, and

recurrence-free survival time and survival time after hepatectomy were compared.

**Results:** Total 50 hepatectomy for liver metastasis of CRC were performed in 40 patients. Median survival time was 24.0 and 26.6 months in patients with synchronous and metachronous hepatectomy, respectively. In 39 metachronous hepatectomy, chemotherapy was performed before 32 hepatectomy and after 31 hepatectomy. Median period between colorectal surgery and hepatectomy in patients with chemotherapy before hepatectomy (14.7 months) was slightly longer than that in patients without chemotherapy (9.0 months). Although median survival time in patients with chemotherapy after hepatectomy was longer than that in patients without chemotherapy, the difference was not statistically significant (28.6 vs. 18.9 months;  $P = 0.07$ ). In 5 patients who treated with FOLFOX or FOLFIRI plus bevacizumab (BV) before hepatectomy, the period between colorectal surgery and hepatectomy was longer than that in 15 patients who treated with FOLFOX or FOLFIRI only (24.4 vs. 8.9 months;  $P < 0.01$ ). In 7 patients who was treated with FOLFOX or FOLFIRI plus BV after hepatectomy, median recurrence-free survival time was 4.7 months, which was shorter than that in 14 patients who was treated with FOLFOX or FOLFIRI only (12.4 months). On the contrary, median survival time was slightly longer in patients with BV administration after hepatectomy (32.6 vs. 24.4 months).

**Conclusion:** Chemotherapy before and/or after hepatectomy has a possibility of improving survival after hepatectomy and further investigation and follow-up survey are necessary to clarify the effectiveness of chemotherapy and molecular-targeted therapy in patients with liver metastasis of CRC.

**Abstract ID: 0662** Specific Field: **Hepatobiliary and Pancreas Surgery**

**Mode of pres.: Poster Exhibition only**  
**ISW 2011 Session PE 326**

**Assessment of expanded indication of hepatic resection for liver metastasis from colorectal cancer**

H. Shiba, Y. Ishida, S. Wakiyama, T. Gocho, K. Furukawa, K. Haruki, T. Misawa, K. Yanaga

Jikei University School of Medicine, Tokyo, Japan

**Introduction:** Liver metastasis is one of the most important prognostic factors for digestive cancers. Hepatic resection is the most effective therapy for metastases liver cancer and is potentially curative. We expanded indication of hepatic resection for liver metastasis from colorectal cancer since 2004. In this report, we retrospectively assessed changes in our therapeutic strategy for liver metastasis.

**Material and Methods:** Subjects were 76 patients who underwent hepatic resection for liver metastasis from colorectal cancer at Jikei University Hospital. Before 2003, indications of hepatic resection for metastatic liver cancer from colorectal cancer was a single or multiple metastatic liver cancer(s) confined to either the left or right hepatic lobe. Since 2004, we changed indications for hepatic resection to the extent hepatic failure is not expected after hepatic resection. Patients were classified into 2 groups; early period (1996–2003,  $n = 52$ ), and late period (2004–2006,  $n = 24$ ). The following parameters were analyzed; peri-operative findings including age, gender, synchronous or metachronous, the H-number of General Rules for Japanese Clinical and Pathologic Studies on Cancer of the Colon, Rectum and Anus in 2006, and overall survival.

**Results:** Peri-operative findings were comparable between the two groups. In late period, the ratio of H2 or H3 (20.8%) increased as compared to early period (9.6%), but not statistically significant. Overall survival was comparable between the two groups.

**Conclusion:** Despite expanded indications for hepatic resection, overall survival was comparable between early and late periods. Expanded indication of hepatic resection for liver metastasis may contribute to improvement of prognosis of patients with liver metastasis from colorectal cancer.

**Abstract ID: 0663**      Specific Field: **Hepatobiliary and Pancreas Surgery**

**Mode of pres.: Poster Exhibition only**  
**ISW 2011 Session PE 327**

**The diagnostic value of preoperative fluorodeoxy-glucose positron emission tomography in patients with colorectal cancer liver metastasis**

K. Fukumoto [1], T. Sakaguchi [1], H. Konno [1], Y. Shibasaki [1], Y. Morita [1], A. Suzuki [1], K. Inaba [1], S. Suzuki [2]

[1] Hamamatsu University School of Medicine, Hamamatsu, Japan, [2] Iwata City Hospital, Iwata, Japan

**Introduction:** Hepatectomy is considerable therapeutic strategy for the patients with colorectal cancer liver metastasis (CRCLM). <sup>18</sup>F-fluorodeoxyglucose positron emission tomography (FDG-PET) is useful for detection of extrahepatic disease in at least some of the patients with CRCLM; however, it remains unclear whether all of these patients had better undergo FDP-PET preoperatively. In this study we analyzed the effect of FDG-PET on preoperative diagnosis and prognosis of the patients with CRCLM, and sought to establish novel criteria for the selection of those patients in whom FDG-PET screening is appropriate.

**Material and Methods:** Forty-two patients with CRCLM, of which 21 each underwent preoperative workup with (PET group) or without (Control group) FDG-PET, were retrospectively analyzed. Clinical risk score (CRS) were calculated by the total points assigned one point each; primary node positive, multiple liver foci, disease free interval <1 year, largest liver focus >5 cm, and carcinoembryonic antigen (CEA) >200 ng/ml. The relationships between CRS and clinical course were evaluated. We defined poor prognosis patients as patients with extrahepatic lesion at the pre-operative examination or patients who were found unresectable recurrence in early period (within 1 years) after post-hepatectomy.

**Results:** Hepatectomy was not performed in 5 of 21 patients in PET group due to extrahepatic lesions detected by PET. There was no significant difference on clinical course (5 year-survivals rate; with 16 patients underwent hepatectomy in PET group vs. 21 patients in control group, 63.2% vs. 51.1%,  $P = 0.62$ ). Three of 21 patients in control group and three of 16 patients who underwent hepatectomy in PET group were detected unresectable recurrence within 1 year after hepatectomy. Unresectable recurrent site were 4 liver metastases and 2 lung metastases. All of 5 inoperable patients in PET group showed  $\geq 3$  CRS. The cut off value for detecting poor prognosis patients by the Receiver-Operating-Characteristic (ROC) Curve analysis was  $\geq 3$ CRS.

**Conclusion:** The poor prognosis patients with CRCLM were detected by criteria; 3CRS. If the Fong's CRS 3 of patients with colorectal cancer liver metastasis scheduled hepatectomy, Preoperative FDG-PET scan should be performed to detect unexpected extra-hepatic metastasis.

**Abstract ID: 0664**      Specific Field: **Hepatobiliary and Pancreas Surgery**

**Mode of pres.: Poster Exhibition only**  
**ISW 2011 Session PE 328**

**Laparoscopic treatment of the focal nodular hyperplasia originating from left triangular ligament of the liver: a case report**

N. Yabe [1], S. Murai [2], H. Shimizu [2]

[1] Ogikubo Hospital, Tokyo, Japan, [2] Ogikubo Hospital, Japan

**Introduction:** A 35-year-old female came to our hospital complaining of a submucosal tumor in the cardia of the stomach which was detected by the upper gastrointestinal (GI) series and gastrointestinal endoscopy performed during the medical checkup in the summer of 2008. The abdominal enhanced computed tomography (CT) scan revealed a slightly enhanced tiny tumor. The feeding artery of the tumor diverged from the hepatic artery. On the abdominal ultrasound (US), an isoechoic mass was seen between liver and stomach. The magnetic resonance imaging (MRI) scan revealed the mass of iso-intensity on the T2-weighted image. Based on the gastrointestinal endoscopy and radiological examinations, the lesion was diagnosed as a gastrointestinal stromal tumor (GIST), but could not be ruled out as a hepatoma because of the feeding artery. The operative plan was laparoscopic wedge resection for the GIST of the gastric cardia. A solitary mass arising from the left triangular ligament of the liver was found at the laparoscopic examination. She was treated by laparoscopic partial hepatectomy including the hepatic tumor using an ultrasonic laparoscopic coagulation shears (LCS). Pathological examination showed a hepatic focal nodular hyperplasia (FNH). For such a case, although we could not make a correct diagnosis preoperatively, laparoscopic procedure was very useful for diagnosis and treatment. FNH originating from the left triangular ligament of the liver has not been reported in the literature, and we therefore reported this rare case.

**Abstract ID: 0665**      Specific Field: **Hepatobiliary and Pancreas Surgery**

**Mode of pres.: Poster Exhibition only**  
**ISW 2011 Session PE 329**

**Laparoscopic hemi-hepatectomy: pure or hybrid?**

T. Tsukamoto, A. Kanazawa, S. Shimizu, S. Kodai, S. Yamazoe, S. Yamamoto

Department of Hepato-Biliary-Pancreatic Surgery, Osaka City General Hospital, Osaka, Japan

**Introduction:** We have performed 118 laparoscopic liver resections since 2000. Of the 118 cases of laparoscopic liver resection, 76 cases were performed limited resection of the liver, 20 cases were performed sectionectomy of the liver, 9 cases were performed subsegmentectomy of the liver, and 13 cases were hemi-hepatectomy. Of the 13 cases of hemi-hepatectomy, 3 cases were underwent resection of extrahepatic bile duct and hepaticojejunostomy through a small laparotomy. Of 10 cases of hemi-hepatectomy without biliary reconstruction, the first 7 cases were performed hybrid procedure of laparoscopic liver resection and 3 cases were performed pure laparoscopic procedure. This paper mentions about the usefulness and safety of pure laparoscopic hemi-hepatectomy compared with hybrid procedure or conventional open procedure.



**Material and Methods:** We focused the 10 cases of hemi-hepatectomy of the liver without biliary reconstruction. Seven cases were performed hybrid procedure that is also named laparoscopy-assisted hepatectomy. Liver parenchymal transection is performed through a small upper midline or subcostal laparotomy with conventional surgical maneuvers and instruments assisted with laparoscope after pure laparoscopic mobilization of the liver with pneumoperitoneum. Of the 7 cases of hybrid procedure, 5 cases were left hemi-hepatectomy and 3 were right hemi-hepatectomy. Of the 3 cases of pure laparoscopic procedure, 2 case was right hemi-hepatectomy and 1 was left.

**Results:** Of all cases, there was no mortality case. There were no complication but one case of pure laparoscopic left hemi-hepatectomy with post operative delayed gastric emptying (DGE) because of adhesive gastric deformity. Blood loss during surgery was 850–3500 ml (mean, 1784 ml) in hybrid procedure group and 540–710 ml (mean, 633 ml) in pure laparoscopic group. Operating time was 580 min (mean) in hybrid group and 539 min in pure laparoscopic group. Postoperative hospital stay was 10–21 days (mean, 13 days) in hybrid cases and 8 days in two cases of pure laparoscopic group without DGE case.

**Conclusion:** Pure laparoscopic hemi-hepatectomy was performed safely and with less blood loss compared with hybrid procedure although the operating time was not deferent between two groups. The postoperative course was better in pure laparoscopic group than hybrid group.

**Abstract ID: 0666**      Specific Field: **Hepatobiliary and Pancreas Surgery**

**Mode of pres.: Poster Exhibition only**  
**ISW 2011 Session PE 330**

#### **Surgical benefits of liver hanging maneuver for hepatectomy of huge liver tumor**

M. Meguro, T. Mizuguchi, K. Hirata, M. Kawamoto, M. Imamura, K. Okita, Y. Kimura, T. Furuhashi

Sapporo Medical University School of Medicine, Sapporo, Japan

**Introduction:** In hepatic surgery, it is very important to control bleeding during liver resection. However, in hepatectomy for a huge liver tumor it is often difficult to reduce bleeding volume and maintain an excellent surgical view. The anterior approach, which is hepatectomy done using the liver hanging maneuver, has beneficial effects reducing bleeding volume and preventing scattering of cancer cells from huge liver tumors. We investigated the surgical benefits of the liver hanging maneuver during hepatectomy for huge liver tumors in our department.

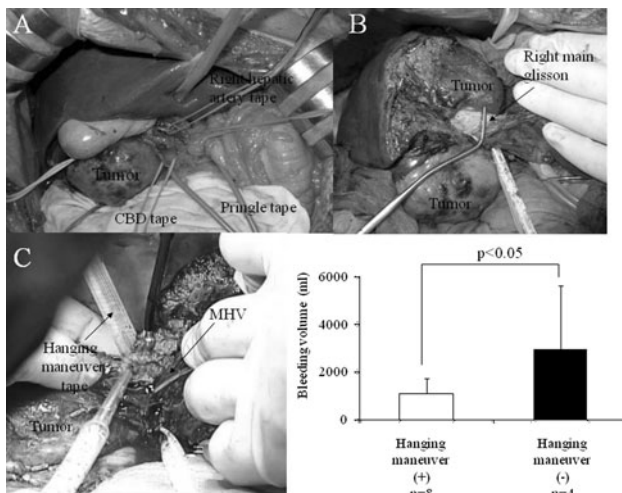
**Material and Methods:** Between April 2003 and August 2008, we reviewed 182 patients who had to undergo liver resection in our department. The diagnoses of these patients were 114 cases of hepatocellular carcinoma, 48 of colorectal metastasis, 6 of echinococcus, 5 of hemangioma, 5 of cholangiocellular carcinoma, 2 of focal nodular hyperplasia, 1 of angiomyolipoma, and 1 of embryonal sarcoma. In the huge-tumor group, with tumor diameters of 10 cm or more, 20 patients underwent liver resection. In the small and medium-sized tumor groups, in which the tumors were 5 cm or less and between 5 and 10 cm in diameter, respectively, 124 and 38 patients underwent liver resection, respectively. Twelve patients underwent right or left lobectomy in the huge-tumor group. Of these, 8 patients underwent liver resection using the hanging maneuver. We usually perform hepatic parenchymal transection with intermittent clamping of the hepatic pedicle (Pringle maneuver) via irrigated monopolar coagulation using Dissecting Sealer 3.5c® (TissueLink Medical,

USA) and an ultrasonic surgical aspirator (CUSA EXcel™) (Integra LifeSciences Corporation, USA). We suspended the drain tape during the hepatic transection. This liver hanging maneuver technique helps to reduce venous back flow bleeding, especially during deeper parenchymal transection. Before the liver resection, we performed dissection of a coronary and triangle ligament of the liver. However, it is very difficult to obtain a view for the dissection of these ligaments because a huge tumor prevents a surgical view. We often perform the parenchymal transection before the dissection of these ligaments in the case of a huge tumor.

**Results:** The mean maximum tumor diameter, operation time, and amount of bleeding volume in the huge-tumor group were significantly larger, longer, and larger, respectively, than those of the small and medium groups. We found that the intraoperative bleeding volume of the group in which the hanging maneuver was used was significantly smaller than that of the group in which it was not for patients who underwent right or left lobectomy in the huge-tumor group. Subsegmentectomy and partial hepatectomy were not performed in the huge-tumor group (Table). Major hepatectomy in which a bisegment or more of the liver was resected was significantly frequent in the huge-tumor group ( $P < 0.05$ ) (Table). We found that the intraoperative bleeding volume ( $1,094 \pm 636$  ml) of the group ( $n = 8$ ) with the hanging maneuver was significantly less than that ( $2,950 \pm 2,683$  ml) of the group ( $n = 4$ ) without the hanging maneuver ( $P < 0.05$ ) (Figure).

**Conclusion:** The liver hanging maneuver is useful when liver tumors are 10 cm or more in diameter because it can reduce the intraoperative bleeding volume. However, the hanging maneuver must be conducted carefully to prevent bleeding in the retrohepatic IVC areas.

	Small group (<5 cm)	Median group (5–10 cm)	Huge group (10 cm <)	<i>P</i> values
Numbers of patients	124	38	20	
Age, mean (range) (years)	63.7 (34–86)	64.0 (22–80)	56.0 (29–79)	N. S.
Sex, male: female	87 : 37	26 : 12	12 : 8	N. S.
Remnant liver, NL:CH:LC	47 : 33 : 44	11 : 15 : 12	13 : 4 : 3	$P < 0.05$
Diagnosis				
HCC	82	23	9	N. S.
Colorectal metastasis	35	10	3	N. S.
Hemangioma	1	1	3	N. S.
Echinococcus	3	1	2	N. S.
CCC	2	2	1	N. S.
Angiomyolipoma	0	0	1	N. S.
Embryonal sarcoma	0	0	1	N. S.
FNH	1	1	0	N. S.
Type of liver resection (%)				
Right lobectomy	6 (4.8%)	6 (15.8%)	9 (45.0%)	$P < 0.05$
Left lobectomy	3 (2.4%)	4 (10.5%)	3 (15.0%)	
Right trisegmentectomy	1 (0.8%)	1 (2.6%)	2 (10.0%)	
Left trisegmentectomy	1 (0.8%)	2 (5.3%)	0	
Segmentectomy	32 (25.8%)	9 (24.7%)	6 (30.0%)	
Subsegmentectomy	33 (26.6%)	6 (15.8%)	0	
Partial hepatectomy	40 (32.3%)	10 (26.3)	0	
Enucleation	8 (6.5%)	0	0	



**Figure:** Benefits of liver hanging maneuver in the bleeding volume during hepatectomy for the huge liver tumor

**Abstract ID: 0667** Specific Field: **Hepatobiliary and Pancreas Surgery**

**Mode of pres.: Poster Exhibition only**  
**ISW 2011 Session PE 331**

**Successful treatment by balloon dilatation under venography for liver failure due to stenosis of left hepatic vein after right tri-segmentectomy for massive hepatocellular carcinoma**

R. Ito, S. Wakiyama, H. Shiba, T. Gocho, T. Sakamoto, Y. Ishida, T. Misawa, K. Yanaga

Jikei University School of Medicine, Tokyo, Japan

**Introduction:** Outflow block due to hepatic vein stenosis is one of the causes of postoperative liver failure, especially in liver transplantation. We herein report a case of successful treatment by balloon dilatation under venography for liver failure due to stenosis of the left hepatic vein after right tri-segmentectomy for massive hepatocellular carcinoma (HCC).

**Material and Methods:** A 41-year-old male with hepatitis B patients underwent right tri-segmentectomy and total caudate lobectomy for huge HCC with thrombosis in intrahepatic inferior vena cava due to tumor compression, in March 2010. The patient made a satisfactory recovery without complications, and remained well for 3 months. When ascites and hyperbilirubinemia developed gradually, and the patient was re-admitted to our hospital. Venography revealed stenosis and tortuosity of the left hepatic vein and the inferior vena cava. Because of liver failure with the serum total bilirubin of 11.7 mg/dl and prothrombin time-international ratio of 1.5, the patient was judged high risk to undergo venoplasty of the left hepatic vein and the inferior vena cava by laparotomy under general anesthesia.

**Results:** Therefore, balloon dilatation of the left hepatic vein and the inferior vena cava under venography was performed. The left hepatic venous pressure decreased from 65 mmHg to 25 mmHg after balloon dilatation using an 8 mm balloon. The inferior vena cava was dilated using a 10 mm balloon. The patient suffered from temporary right heart failure immediately after treatment, which subsided conservatively. The patient made a satisfactory recovery thereafter, and remains well.

**Conclusion:** Balloon dilatation under venography may be a useful therapeutic strategy for liver failure due to hepatic vein stenosis after hepatic resection.

**Abstract ID: 0668**

Specific Field: **Hepatobiliary and Pancreas Surgery**

**Mode of pres.: Poster Exhibition only**  
**ISW 2011 Session PE 332**

**The usefulness of right hemihepatectomy preserving ventral anterior section**

R. Mori [1], K. Tanaka [2], T. Kumamoto [2], K. Nojiri [2], K. Takeda [2], M. Ueda [2], C. Kunisaki [1], I. Endo [2]

[1] Yokohama City University Medical Center, Yokohama, Japan,  
[2] Yokohama City University Graduate School of Medicine, Yokohama, Japan

**Introduction:** To clarify the usefulness of right hemihepatectomy preserving ventral anterior section (VAS) for maintaining the capacity of residual liver after hepatectomy.

**Material and Methods:** Thirty patients without any liver disease were enrolled and was performed computed tomography (CT) scan of 4 phases (plain, arterial, portal, venous phase). These were analyzed by MeVis Liver Analyzer and three-dimensional CT was made. This analysis revealed the liver area perfused by each portal vein branch and that drained by each hepatic vein branch. These portal vein areas and hepatic vein areas were fused and their association was analyzed.

**Results:** The median volume of VAS which was perfused by ventral anterior portal branch was 230 ml, and  $18 \pm 5\%$  of the whole liver volume. The VAS was drained predominantly (91%) by the branch of the middle hepatic vein (MHV). Based on the fusion image of the area of VAS and the area drained by MHV, patients were classified into 3 types as follows; type I, MHV area lie outside the VAS area; type II, MHV area corresponds with the VAS area; and type III, a part of VAS area were drained to MHV, otherwise drained to RHV. The frequency of each type was 10% in Type I, 63% in type II, and 27% in type III. Intersectional hepatic vein (IHV) was observed in all patients, however, only 47% of IHV was located at the border between ventral and dorsal portion of the anterior section.

**Conclusion:** Approximately 20% of liver volume could be preserved by the right hemihepatectomy preserving VAS. The border of the drainage area by hepatic veins can be used as the land mark of the ventral-dorsal border of the anterior section instead of the IHV.

**Abstract ID: 0669**

Specific Field: **Hepatobiliary and Pancreas Surgery**

**Mode of pres.: Poster Exhibition only**  
**ISW 2011 Session PE 333**

**Surgery for hepatocellular carcinoma located in the caudate lobe**

M. Sakoda, S. Ueno, S. Natsugoe, S. Iino, K. Minami, K. Andou, H. Kurahara

Kagoshima University, Kagoshima, Japan

**Introduction:** Surgery remains difficult for hepatocellular carcinoma originating in the caudate lobe. Our objective was to evaluate the safety and problems associated with caudate lobectomy combined with other types of hepatectomy.

**Material and Methods:** We performed caudate resection for primary hepatocellular carcinoma (HCC) in twelve patients. Clinical and operative characteristics and survival were analyzed.

**Results:** Tumors were located in the Spiegel lobe in three patients, the caudate process in six and the paracaval portion in three. The procedure performed most was isolated partial caudate lobe

resection (6 patients). Three patients underwent partial caudate lobe resection combined with other hepatectomy and the remainder underwent total caudate lobe resection combined with other hepatectomy. Tumors of those patients who underwent combined total caudate lobe resection were mainly in the paracaval portion. The median operation time of the six patients who underwent combined resection was 400 min and their median intraoperative blood loss was 1,683 ml. There was no postoperative complication in patients who underwent combined total caudate lobe resection, except one case of total resection combined with central bisegmentectomy; the remaining right posterior sector was twisted after liver extraction, causing blockage of the outflow of the right hepatic vein. The overall and the recurrence-free survival rates did not differ between isolated and combined resection.

**Conclusion:** For removal of HCC located in the caudate lobe, especially the paracaval portion, partial or total caudate lobe resection with other types of hepatectomy contributes to safe and curative surgery, if the liver functional reserve and complications associated with surgery are well understood (World J Surg 33:1922–1926, 2009)

**Abstract ID: 0670**                      Specific Field: **Hepatobiliary and Pancreas Surgery**

**Mode of pres.: Poster Exhibition only**  
**ISW 2011 Session PE 334**

**The diagnostic value of procalcitonin for major hepatectomy with biliary reconstruction**

K. Itatsu, Y. Yokoyama, T. Ebata, T. Igami, G. Sugawara, M. Fukaya, Y. Takahashi, M. Nagino

the Division of SurgicalOncology, Department of Surgery, Nagoya University, Graduate School of Medicine, Nagoya, Japan

**Introduction:** Serum procalcitonin (PCT) has been reported as a useful marker of severe bacterial infection. Some reports show that the increased PCT level after surgery is associated with postoperative infectious complications. We prospectively investigated the diagnostic value of postoperative PCT for the infectious complications in major hepatectomy with biliary reconstruction.

**Material and Methods:** From January 2010 to October 2010, 39 patients were enrolled. PCT levels were determined on the 1, 3, 5, and 7 postoperative days.

**Results:** 35 patients had hilar cholangiocarcinoma, 2 gallbladder cancer, 1 hepatocellular carcinoma, and 1 hepatolithiasis. Preoperative biliary drainage was performed in 34 patients (87%). Preoperative cholangitis was observed in 12 patients. Types of liver resection included left hepatectomy in 5 patients, right hepatectomy in 15, left trisegmentectomy in 10, right trisegmentectomy in 8, and central bisegmentectomy in 1. Caudate lobectomy and extrahepatic bile duct resection were also performed in all patients. Combined resection and reconstruction of the portal vein and hepatic artery were performed in 7 patients (18%). Combined pancreatoduodenectomy was performed in 10 patients (27%). Mean operative time and blood loss were 583 min and 1660 ml, respectively. Postoperative infectious complication was observed in 23 patients (59%). Superficial and deep incisional surgical site infection (SSI) was observed in 6 patients (16%), organ/space SSI in 18 (46%) cholangitis in 8 (21%), bacterial enteritis in 3 (8%), pneumonia in 3 (8%). Mean values of postoperative PCT in 1, 3, 5, and 7 were 8.0, 5.3, 1.9, and 0.9 ng/ml, respectively. Statically, PCT values had no significant association with gender, type of hepatectomy, operative time, blood loss, all infectious complications.

**Conclusion:** This study failed to demonstrate clinical value of PCT, probably due to limited number of patients. Further accumulation of patients is necessary.

**Abstract ID: 0671**                      Specific Field: **Hepatobiliary and Pancreas Surgery**

**Mode of pres.: Poster Exhibition only**  
**ISW 2011 Session PE 335**

**Risk factors for postoperative recurrence of hepatocellular carcinoma in patients with nonalcoholic fatty liver disease**

K. Kaneda, T. Uenishi, S. Takemura, S. Kiyota, H. Shinkawa, Y. Urata, M. Sakae, S. Kubo

Department of Hepato-Biliary-Pancreatic Surgery, Osaka City University Graduate School of Medicine, Osaka, Japan

**Introduction:** Risk factors for hepatocellular carcinoma (HCC) recurrence in patients with nonalcoholic fatty liver disease (NAFLD) who underwent hepatic resection have not yet been evaluated. We investigated the risk factors for HCC recurrence after hepatic resection in patients with NAFLD in order to determine the appropriate surgical management of these patients.

**Material and Methods:** A total of 34 NAFLD patients who underwent curative hepatic resection for HCC were studied. We investigated the risk factors for HCC recurrence by univariate and multivariate analyses.

**Results:** The univariate analysis showed that increased aspartate aminotransferase serum activity, alpha-fetoprotein serum concentrations, multiple tumors, poorly differentiated HCC, portal invasion, cirrhosis, and positive surgical margins (cancer cells <5.0 mm) were associated with significantly lower tumor-free survival rates. Multivariate analysis showed that multiple tumors, poorly differentiated HCC, portal invasion, and positive surgical margins were independent risk factors for postoperative HCC recurrence.

**Conclusion:** Curative resection with an adequate surgical margin (>5.0 mm) is recommended for HCC in patients with NAFLD.

**Abstract ID: 0672**                      Specific Field: **Hepatobiliary and Pancreas Surgery**

**Mode of pres.: Poster Exhibition only**  
**ISW 2011 Session PE 336**

**High value of serum liver enzymes after hepatic resection**

M. Aoki, T. Takayama, H. Nakayama, S. Yamazaki, T. Higaki, O. Aramaki

Nihon University School of Medicine, Digestive Surgery, Tokyo, Japan

**Introduction:** After hepatic resection, some patients shows high value of serum transaminase. The aim of this study is to investigate the clinical features of the patient that affects extremely highly elevation liver enzymes after hepatic resection.

**Material and Methods:** The study population comprised 179 patients who had undergone hepatic resection. The patients were classified two groups. Post operative day 1 aspartic aminotransferase (AST) elevated more than 1000 IU/l classified “High elevation”, and less than 1000 IU/l classified “Control”. The relationship between the perioperative factors and “high elevation”, “Control” were analyzed. The perioperative factors parameters, i.e., intraoperative blood loss, number

of inflow occlusion, inflow occlusion time and operation time were analyzed.

**Results:** “High elevation” was 9 patients and “Control” was 170 patients. The median serum AST levels: High elevation 1183(1054–2899) IU/l vs. Control 209(28–1054) IU/l. The median intraoperative blood loss: High elevation 645 (97–5682) ml vs. Control 250 (5–1494) ml ( $P = 0.02$ ). The median number of inflow occlusion: High elevation 6(3–9) vs. Control 4(4–12) ( $P = 0.006$ ). The median inflow occlusion time: High elevation 117.5(60–172) min vs. Control 65(0–202) min ( $P = 0.014$ ). The median operation time were High elevation 552(340–892) min vs. Control 358 (48–712) min ( $P = 0.014$ ). Post operative complications has occurred 4 vs. 40. Re-operation has performed 0 vs. 10.

**Conclusion:** Both Inflow occlusion time and operation time was the most important factor that affects extremely highly elevation liver enzymes after hepatic resection.

Clinical features in 179 patients

	High elevation ( $n = 9$ )	Control ( $n = 170$ )	$P$ value
Intraoperative blood loss	645	250	0.02
Number of inflow occlusion	6	4	0.006
Inflow occlusion time	117.5	65	0.0014
Operation time	552	358	0.0014
Complication	4	40	
Re-operation	0	10	

**Abstract ID: 0673** Specific Field: **Hepatobiliary and Pancreas Surgery**

**Mode of pres.: Poster Exhibition only**  
ISW 2011 Session PE 337

**Fas/FasL polymorphisms are associated with presence of hepatitis C related cirrhosis and serum alpha-fetoprotein level with hepatocellular carcinoma patients**

G.-S. Liao, C.-B. Hsieh, J.-C. Yu, T.-W. Chen, H.-C. Lai

Tri-Service General Hospital, Taipei, Taiwan

**Introduction:** Host genetic factors that may confer the susceptibility of chronic hepatitis and the progression of hepatocellular carcinoma (HCC) are largely unknown. Apoptosis is an important fail-safe check for virus hepatitis and HCC development, in which Fas/FasL hepatocyte expression contributes substantially. Our aim is to determinate whether the Fas/FasL gene promoter polymorphism at Fas-670, Fas-1377 and Fas-L844 associated with the risk of virus hepatitis or the prognosis of HCC patients.

**Material and Methods:** A hospital-based case-control study was conducted, in which 141 patients of HCC, Hepatitis B hepatitis with lamivudine treatment ( $N = 107$ ), Hepatitis C hepatitis with interferon treatment ( $N = 50$ ) and 300 non-HCC patients were control group. In these 110 of 141 HCC underwent liver resection patients, there were 59 patients with early recurrence (400 ng/ml. All of this group were tested for Fas/FasL polymorphism by PCR-RFLP. The frequency of allele and genotype were compared between each groups. The significant SNP correlated with clinical characteristics was a surrogate for recurrence or survival analysis.

**Results:** In control group, the C/T ratio in FasL are 71.4/28.57, the A/G ratio in Fas 670 are 55.28/44.72, and the A/G ratio in Fas1377 are 41.31/58.69 and there all are no significant different to HCC, HBV, HCV or surgical group. In genotype pattern of Fas670, the A/A to A/G + G/G ratio are 30.28/60.76 and there are significant to HCV hepatitis group 16.0/84.0. (The  $P$  value = 0.026); in Fas1377, the A/A + A/G to G/G ratio are 66.67/33.33 and there are significant to HCV hepatitis group 16.0/84.0 ( $P$

**Conclusion:** Apoptosis mechanism of Fas/FasL interaction may contribute to HCV related hepatitis and late stage (CLIP score 2–6) of surgical HCC group. The genetic polymorphisms of Fas1377 maybe play a role of HCV infection transforming to liver cirrhosis. The genetic polymorphisms of FasL may correlate to the prognosis and serum AFP level in patients with HCC.

**Abstract ID: 0674** Specific Field: **Hepatobiliary and Pancreas Surgery**

**Mode of pres.: Poster Exhibition only**  
ISW 2011 Session PE 338

**Shunting and nonshunting procedures for the treatment of esophageal varices in patients with idiopathic portal hypertension**

H. Yoshida [1], Y. Mamada [2], N. Taniai [2], S. Mineta [2], M. Yoshioka [2], A. Hirakata [1], Y. Kawano [2], E. Uchida [2]

[1] Department of Surgery, Nippon Medical School Tama Nagayama Hospital, Tokyo, Japan, [2] Department of Surgery, Nippon Medical School, Tokyo, Japan

**Introduction:** We evaluated the results of shunting and nonshunting procedures for the treatment of esophagogastric varices in patients with idiopathic portal hypertension (IPH).

**Material and Methods:** Between 1981 and 2008, surgery was performed in 9 patients with IPH. Three patients had bleeding before operation, and the other 6 were treated prophylactically. Patients were divided into 2 groups, a shunting group (4 underwent distal spleno-renal shunt) and a nonshunting group (3 underwent esophageal transection and 2 underwent Hassab’s procedure).

**Results:** Esophagogastric varices were completely eradicated in 3 (75.0%) patients in the shunting group and 4 (80.0%) in the nonshunting group. Additional endoscopic treatment (one session) was performed in 2 patients with incompletely eradicated varices. There was no recurrence in the shunting group. In the nonshunting group, esophagogastric varices recurred in all 4 patients with completely eradicated varices. All recurrent esophageal varices were completely eradicated. Postoperative platelet counts ( $10^4/\mu\text{L}$ ) were significantly lower in the shunting group ( $10.0 \pm 2.6$ ) than in the nonshunting group ( $42.0 \pm 14.0$ ) ( $P = 0.0029$ ). The increase in the platelet count after operation was significantly lower in the shunting group ( $1.7 \pm 0.2$  times) than in the nonshunting group ( $5.8 \pm 2.9$  times) ( $P = 0.0267$ ). No patient received anticoagulants postoperatively. Portal venous thrombus did not develop in the shunting group, but appeared in 4 patients (80.0%) in the nonshunting group. No patient had loss of shunt selectivity or portal-systemic encephalopathy. One patient in the nonshunting group died of cerebral hemorrhage; all others are alive.

**Conclusion:** Shunting procedure, distal spleno-renal shunt, was suggested to be useful for the management of esophagogastric varices in patients with IPH.



**Abstract ID: 0675**      Specific Field: **Hepatobiliary and Pancreas Surgery**

**Mode of pres.: Poster Exhibition only**  
**ISW 2011 Session PE 339**

**Liver resection for hepatocellular carcinoma in cirrhotic patients with severe thrombocytopenia**

S. Tanaka, T. Yamamoto, K. Ishihara, C. Watanabe, Y. Nakamura, Y. Kurashima, K. Ohno

Department of Surgery, Ishikiriseiki Hospital, Higashiosaka, Japan

**Introduction:** Hepatic resection for hepatocellular carcinoma (HCC) is risky for cirrhotic patients with severe thrombocytopenia.

**Material and Methods:** Among 23 patients with histologically proven cirrhosis who underwent hepatic resection for HCC at our hospital since 2006, 7 had severe thrombocytopenia (platelet count  $<510^4/\text{mm}^3$ ). The clinical background and surgical outcomes of these 7 patients were retrospectively evaluated and compared to those of the 16 cirrhotic patients without severe thrombocytopenia.

**Results:** All 7 patients had hepatitis C virus-related liver cirrhosis. The median preoperative platelet count was  $4.310^4/\text{mm}^3$  (range,  $3.9\text{--}4.910^4/\text{mm}^3$ ) and the median operative time and intraoperative bleeding were 77 min and 193 cc, respectively. Postoperative complications were observed in 4 patients (57%) and all were managed conservatively. Four patients received an intraoperative platelet-rich transfusion, but this had no beneficial effect on intraoperative bleeding or postoperative changes in platelet counts. The cirrhotic patients with severe thrombocytopenia were significantly younger and had a significantly shorter operative time compared to those without severe thrombocytopenia. There were no other differences between the groups.

**Conclusion:** Our results suggest that the indication for hepatectomy in cirrhotic patients should not be based on platelet counts alone. However, we note that the younger age and shorter operative time for the patients with severe thrombocytopenia might have contributed to the safety of hepatectomy.

**Abstract ID: 0676**      Specific Field: **Hepatobiliary and Pancreas Surgery**

**Mode of pres.: Poster Exhibition only**  
**ISW 2011 Session PE 340**

**Comparison of hepatocellular carcinoma with cirrhosis undergoing hepatic resection between hepatitis B and C infection**

H. Shiba, S. Wakiyama, Y. Fujiwara, T. Gocho, R. Ito, Y. Ishida, T. Misawa, K. Yanaga

Jikei University School of Medicine, Tokyo, Japan

**Introduction:** Type B and type C hepatic cirrhosis are main causes of hepatocellular carcinoma (HCC). In resected cases of HCC, residual liver function of type B cirrhotic patients tend to be better compared to those of type C cirrhotic patients. We compared clinical data of patients with type B hepatic cirrhosis with that of type C hepatic cirrhosis who underwent hepatic resection for HCC.

**Material and Methods:** Subjects were 16 patients with type B hepatic cirrhosis and 20 patients with type C hepatic cirrhosis who underwent hepatic resection for HCC at Jikei University Hospital. Peri-operative findings including age, gender, preoperative laboratory data including ICGR15, Child's classification, model for end-stage liver disease (MELD) score, tumor factor, type of resection, duration of operation, blood loss and incidence of post-operative complications, as well as disease-free and overall survival were analyzed.

**Results:** In type B cirrhotic patients, pre-operative ICGR15 ( $P = 0.004$ ), hemoglobin ( $P = 0.032$ ), albumin ( $P = 0.006$ ), Child's classification ( $P = 0.008$ ), and MELD score ( $P = 0.011$ ) were better, incidence of postoperative pulmonary complications were fewer ( $P = 0.039$ ), and the age was younger.

**Conclusion:** Residual liver function of type B cirrhotic patients were better than those in type C cirrhotic patients.

**Abstract ID: 0677**      Specific Field: **Hepatobiliary and Pancreas Surgery**

**Mode of pres.: Poster Exhibition only**  
**ISW 2011 Session PE 341**

**Clinicopathologic features and risk factors of hepatocellular carcinoma with macroscopic ductal infiltration after operative removal**

T. Ochiai, H. Ikoma, D. Ichikawa, H. Fujiwara, K. Okamoto, T. Sonoyama, Y. Kokuba, E. Otsuji

Surgery, Kyoto Prefectural University of Medicine, Kyoto, Japan

**Introduction:** The aim of this study was to clarify the clinicopathologic features of hepatocellular carcinoma (HCC) patients with macroscopic ductal infiltration and the prognostic risk factors.

**Material and Methods:** Clinicopathologic data were available for 339 HCC patients who underwent an R0 resection for HCC. Twenty patients who associated with macroscopic ductal infiltration (Vp2 and/or Vv2 and/or B2) (Hi group) were compared with the patients who remained free from ductal infiltration ( $n = 246$ ) (Cont group) or with only microscopic ductal infiltration ( $n = 73$ ) (Lo group). We also estimated the risk factors of recurrence and survival in Hi group.

**Results:** There were significant differences in proportions of primary tumor size, capsule formation, macroscopic type, hepatic involvement, lobectomy and prognosis between Hi and the other groups. Moreover, there were significant differences in proportions of patient's age, platelet cell count, HBsAg positive, serum alpha fetoprotein value, intrahepatic metastasis, anatomic wide hepatectomy and curability between Hi and Cont groups. Presence of intrahepatic metastasis was the only risk factor of survival of Hi group. Cumulative 5-year survival rate of Hi group is 25.5%.  
**Conclusion:** HCC patients with macroscopic ductal infiltration had primary tumors of advanced stage and poor prognosis. However, operative removal for macroscopic tumor thrombi may improve the prognosis of HCC patients with macroscopic ductal infiltration.

**Abstract ID: 0678**      Specific Field: **Hepatobiliary and Pancreas Surgery**

**Mode of pres.: Poster Exhibition only**  
**ISW 2011 Session PE 342**

**Experiences of hepatectomy and splenectomy for hepatocellular carcinoma patients associated with thrombocytopenia**

T. Ochiai, H. Ikoma, D. Ichikawa, H. Fujiwara, K. Okamoto, Y. Kokuba, T. Sonoyama, E. Otsuji

Surgery, Kyoto Prefectural University of Medicine, Kyoto, Japan

**Introduction:** The purpose of this study is to clarify the clinicopathologic features of hepatocellular carcinoma (HCC) patients with thrombocytopenia undergone hepatectomy with splenectomy and the significance of this procedure.

**Material and Methods:** From 1989 to 2006, 40 HCC patients whose platelet cell counts were less than 110,000/ $\mu$ l underwent hepatectomy in our department. Among them, 20 patients underwent splenectomy additionally (Sp group). We evaluated risk factors of HCC recurrence in 40 patients with thrombocytopenia. And we compared between Sp group and the other patients (C group) clinico-pathologically.

**Results:** HCC recurrence in patients with thrombocytopenia was significantly associated with two risk factors by multivariate analyses: hypoalbuminemia (less than 3.5 mg/dl), and operative blood transfusion. Additional splenectomy was marginal significant risk factors of HCC recurrence ( $P = 0.053$ ). With regard to operation time, operative blood loss, post operative hospital stay, there were no significant differences between Sp and C groups, though Sp group included 6 cases with severe thrombocytopenia less than 50,000/ $\mu$ l. However, platelet cell and monocyte count one month after operation, and histologic intrahepatic metastasis of Sp group was significant more than these of C group. There was no significant differences in cumulative survival between Sp and C groups. However, cumulative disease-free survival of Sp group was worse than those of C group ( $P = 0.041$ ).

**Conclusion:** Additional splenectomy for HCC patient with thrombocytopenia made increase of platelet and monocyte one month after operation. However, there were no benefits of operation and postoperative course within one month. Immunologic demerits of this procedure should be studied.

**Abstract ID: 0679** Specific Field: **Hepatobiliary and Pancreas Surgery**

**Mode of pres.: Poster Exhibition only**  
**ISW 2011 Session PE 343**

**Surgical treatment for hepatocellular carcinomas with non-B non-C chronic hepatitis**

T. Yamamoto [1], S. Tanaka [1], T. Uenishi [2], K. Ishihara [1], T. Tsukamoto [2], S. Kubo [2], K. Hirohashi [2], K. Ohno [1]

[1] Ishikiri-Seiki Hospital, Higashi Osaka city, Japan, [2] Hepato-Biliary-Pancreatic Surgery, Osaka City University Graduate School of Medicine, Osaka City, Japan

**Introduction:** We usually see high incidence of hepatocellular carcinoma (HCC) with chronic hepatitis B or C in Japan. Recently, the incidence of HCC originated from non-B non-C (NBNC) hepatitis also has been increasing. We here studied difference between HCC from B/C hepatitis and NBNC hepatitis on the viewpoint of surgical treatment.

**Material and Methods:** During recent six years, we treated liver resection for forty three patients with HCC. We divided the cases into group of chronic viral hepatitis (Group B/C) and group non-B non-C hepatitis (Group NBNC), and studied on the viewpoints of stage of HCC, liver function, method of liver resection, and prognosis. Twenty five patients with chronic hepatitis C and six with chronic hepatitis B were included in Group B/C, and twelve patients with chronic hepatitis due to unknown were included in Group NBNC. Seven patients in Group NBNC accompanied diabetes, and five patients were positive for HBcAb (and negative for DNA of HBV in serum).

**Results:** Group NBNC consists of ten men and two women. Six cases were liver cirrhosis, nine were steatohepatitis, and six were positive for serum alpha feto-protein. Cases of Child-Pugh A were 9, and B were three. Of Group NBNC, An average of serum pro-collagen peptide type III (PIIIP) was 1.00 U/ml, 7 s collagen type IV (type IV) was 6.02 ng/ml. Ten cases were stage I (NCI stage), two were stage II, and an average of tumor diameter was 3.5 cm. Partial/segmental resections

was performed in seven cases, plural segmentectomy in two, lobectomy in three. One-year and three-year survival rate of Group NBNC was 90%, and of Group B/C was 80%. Statically, a serum average of PIIIP and type IV were lower, and incidence of steatohepatitis was higher in Group NBNC than Group B/C. There was tend to better prognosis in Group NBNC than Group B/C, and no significant difference was shown between the groups on the other factors.

**Conclusion:** The present study suggests that surgical treatment would contribute good prognosis for patients with HCC and NBNC, and that HCC originated from NBNC recently might be precipitated by metabolic disorder to the liver like steatohepatitis in Japan. We believe that patients with HCC and NBNC hepatitis could be treated quite hepatic resection because they fairly keeps liver function due to previous adequate treatment for hepatitis and other associated complications.

**Abstract ID: 0680** Specific Field: **Hepatobiliary and Pancreas Surgery**

**Mode of pres.: Poster Exhibition only**  
**ISW 2011 Session PE 344**

**A case report: a giant liver cell adenoma in a man**

T. Tokoro [1], A. Sugioka [1], T. Kagawa [1], C. Takeura [1], Y. Tanahashi [1], J. Yoshida [1], Y. Kato [2]

[1] Fujita Health University, Toyoake, Japan, [2] Fujita Health University, Japan

**Introduction:** 46-year-old man was referred to the institute due to a large liver tumor with right hypochondralgia. He had a history of epilepsy treated with anticonvulsants (sodium valproate, phenytoin, carbamazepine) for more than 30 years. An enhanced CT scan showed a large hypervascular liver tumor, 9 cm in diameter, in the right posterior section with delayed enhancement. Super mesenteric artery angiography revealed the dilated left gastric vein flowing into the left renal vein in portal phase. Although these findings suggested a liver cell adenoma, malignant transformation could not be precluded due to elevated serum PIVKA-II level (867 IU/ml). The patient therefore underwent right posterior sectionectomy and the spleno-renal shunt was ligated and divided to prevent post-operative liver encephalopathy. The gross findings showed a brownish elastic soft tumor associated with hemorrhages. The pathological diagnosis was a liver cell adenoma. Post operative course was uneventful and serum PIVKA-II level decreased within normal range. Here we report a rare case of simultaneous resection of liver cell adenoma in a man treated with anticonvulsants and spleno-renal shunt without liver cirrhosis.

**Abstract ID: 0681** Specific Field: **Hepatobiliary and Pancreas Surgery**

**Mode of pres.: Poster Exhibition only**  
**ISW 2011 Session PE 345**

**143 donor hepatectomies for living donor liver transplantation as a single center experience**

S. Marubashi, H. Nagano, H. Wada, S. Kobayashi, H. Eguchi, M. Tanemura, Y. Doki, M. Mori

Osaka University Graduate School of Medicine, Suita, Japan

**Introduction:** Complications associated with live liver donor surgery should be minimized. There is little information on the impact of team experience and learning on the surgical outcome. In this study, we aimed to evaluate the importance of the team experience on the outcome of LDLT by evaluating various operative parameters, morbidity graded by Clavien Dindo classification and their improvement with our experience as a single center experience.

**Material and Methods:** We analyzed the results of 143 consecutive LDLT performed between 1998 and November 2009 at Osaka University. The donors were 98 males and 45 females, with a mean age of  $38.6 \pm 11.7$  years ( $\pm$ SD). Graft livers consisted of 56 right lobes, 40 left lobes with/without caudate, 36 left lateral section (LLS), and 11 right posterior section (RPS). Surgeries were divided according to the time of execution; Era I ( $n = 50$ ), Era II ( $n = 50$ ) and Era III ( $n = 43$ ). Differences in the clinical background of living donors, operation time, blood loss during surgery, graft types and postoperative morbidities according to graft type and throughout the postoperative course were compared. The time course was divided into three bins of eras. Era I; Case No.1–50 (1998–2003), Era II; Case No.51–100 (2004–2006), and Era III; Case No.100–143 (2006–2009).

**Results:** No postoperative mortality was recorded, and all donors are alive in healthy conditions. Blood loss steadily decreased and operation time decreased after Era II ( $P < 0.0001$ ). The incidence of postoperative morbidities including Clavien grade I was 30.8% ( $n = 44$ ) for all donors, 42.9% ( $n = 24$ ) for right lobe, 27.5% ( $n = 11$ ) for left lobe, 36.4% ( $n = 4$ ) for right posterior section, and 13.9% ( $n = 5$ ) for donors of the left lateral section. There was no significant difference in the incidence of morbidities according to graft type, except that they were significantly higher in right lobe graft donors than in left lateral section graft donors ( $P = 0.009$ ). Multivariate risk factor analyses showed that donors in recent years were at low risk of morbidity and bile leakage ( $P = 0.025$ , 0.010 respectively). There was less impact for team experience on the outcome in LLS graft than other types of grafts.

**Conclusion:** Our analysis demonstrated several learning steps in live liver donor surgery and confirmed their positive impact on surgical outcome.

**Abstract ID: 0682**                      Specific Field: **Hepatobiliary and Pancreas Surgery**

**Mode of pres.: Poster Exhibition only**  
**ISW 2011 Session PE 346**

**Outcomes of patients with spontaneous rupture of hepatocellular carcinoma**

A. Miyoshi, T. Ide, K. Kitahara, K. Miyazaki, H. Noshiro  
Saga University, Saga, Japan

**Introduction:** The prognosis of ruptured hepatocellular carcinoma (HCC) has been reported to be poor, but some studies have reported better survival with staged hepatectomy. The aim of this study was to elucidate the clinical features of ruptured HCC.

**Material and Methods:** Among 305 patients with HCC who underwent hepatic resection between 1990 and 2008 in our institution, 10 patients had ruptured HCC. Ruptured group (Group R;  $n = 10$ ) were compared with those of patients with unruptured HCC group (Group UR;  $n = 295$ ), concerning hepatic reserve, tumor extent and outcome.

**Results:** Ruptured group had extremely large tumor than unruptured group ( $94 \pm 43$  mm vs.  $45 \pm 32$  mm,  $P < 0.001$ ). The proportions

of multiple nodules and poorly tumor grade were significantly higher in Group R than in Group UR. The populations of extrahepatic recurrence and early mortality ( $<1$  year) were significant higher in Group R than Group NR. The median survival time of Group R was shorter than Group NR. The tumor rupture was independent prognostic factors that had the most serious effect on the survival of patients with HCC among the patients with HCC underwent hepatic resection.

**Conclusion:** The patients with spontaneously ruptured HCC had advanced disease, and poor prognosis. Hepatic resection might improve the survival, but a new therapeutic strategy is necessary for the long-term survival of patients with ruptured HCC.

**Abstract ID: 0683**                      Specific Field: **Hepatobiliary and Pancreas Surgery**

**Mode of pres.: Poster Exhibition only**  
**ISW 2011 Session PE 347**

**Impact of interferon therapy on first and second recurrence of hepatitis C virus-related hepatocellular carcinoma**

M. Sakae, T. Uenishi, S. Kubo, S. Takemura, S. Kodai, H. Shinkawa, Y. Urata, K. Kaneda

Department of Hepato-Biliary-Pancreatic Surgery, Osaka City University, Osaka, Japan

**Introduction:** Interferon therapy can reduce the hepatocarcinogenesis in patients infected with hepatitis C virus (HCV), especially among sustained virological or biochemical responders. We investigate the effect of IFN therapy on the outcome after the resection of HCV-related HCC.

**Material and Methods:** Subjects included 166 patients who underwent curative resection for a single HCV-related HCC no larger than 5 cm in diameter. Among these 166 patients, 67 patients underwent interferon therapy. A sustained virological or biochemical response was achieved in 39 patients (SVR/BR group). Twenty eight no responders and 99 patients who had not received interferon therapy were classified as the NR/non-IFN group. We analyzed the postoperative outcome, the characteristics of the first HCC recurrence, and the outcome after the first recurrence between these groups.

**Results:** The tumor-free survival rates after the first operation in the SVR/BR group were significantly higher than those in the NR/non-IFN group. The proportion of single tumor recurrence tended to be higher in the SVR/BR group than in the NR/non-IFN group. The results of the liver function test at the detection of the first recurrence were better in the SVR/BR group than in the NR/non-IFN group. For this reason, the proportion of curative treatment (surgery, RFA, MCT, and PEIT) for the first HCC recurrence tended to be higher in the SVR/BR group than in the NR/non-IFN group. The cumulative survival rates after the treatment for the first recurrence in the SVR/BR group were significantly higher than those in the NR/non-IFN group. In additionally, the curative treatment for the first HCC recurrence was an independent good predictor for the suppression of second recurrence.

**Conclusion:** IFN therapy preserved liver function after the first operation and might suppress multiple recurrences. Curative treatment could be done to the first recurrence resulted in the suppression of the second recurrence. IFN therapy improves the outcome of the liver resection for HCV-related HCC.

**Abstract ID: 0684**Specific Field: **Hepatobiliary  
and Pancreas Surgery**Mode of pres.: **Poster Exhibition only**  
ISW 2011 Session PE 348**Effect of pancreatic stent-removal time on the patency  
of the remnant pancreatic duct in patients with soft pancreas**T. Oida [1], K. Mimatsu [1], H. Kano [1], A. Kawasaki [1],  
Y. Kuboi [1], N. Fukino [1], K. Kida [1], S. Amano [2][1] Social Insurance Yokohama Central Hospital, Yokohama, Japan,  
[2] Social Insurance Yokohama Central Hospital, Japan

**Introduction:** Patency of the pancreaticoenteric anastomosis is one of the most important factors affecting the function of the remnant pancreas and quality of life of the patients. Anastomotic stenosis after pancreaticoduodenectomy (PD) along with pancreaticogastrostomy (PG) is observed in some patients after approximately 1 to 2 post-operative weeks, and the stenosis is attributed to acute inflammation and fibrosis around the anastomosis. Therefore, we evaluated the early post-PG changes in the diameter of the remnant pancreatic ducts in patients with soft pancreas in terms of the time of removal of the pancreatic stents.

**Material and Methods:** We retrospectively studied 44 patients with soft pancreas who has undergone PD along with PG. They were divided into 2 groups depending on the time of removal of the pancreatic stents: early removal group (Group E) and late removal group (Group L).

**Results:** The pancreatic ducts of the remnant pancreas were dilated in all the patients in the both groups, and the mean diameter of the duct did not differ between the 2 groups.

**Conclusion:** Development of post-PG pancreatic anastomotic strictures in patients having soft pancreas and a pancreatic duct with a small diameter is independent of the time of removal of the pancreatic stents.

## Outcomes

	E group (n = 19)	L group (n = 25)	P value
Operative time (min)	405	400	0.7026
Blood loss (ml)	507	502	0.7971
Complications			
Pneumonia	2 (10.5%)	2 (8%)	1.00
Wound infection	2 (10.5%)	1 (4%)	0.5696
Cholangitis	2 (10.5%)	1 (4%)	0.5696
Endoscopic findings			
A	7 (36.8%)	14 (56%)	0.2076
B	12(63.2%)	11 (44%)	0.2076
Diameter of pancreatic duct of the remnant of pancreas (mm)	5.15	4.82	0.3316
Changing diameter of pancreatic duct (mm)			
Increase	19 (100%)	25 (100%)	1.00
No change	0 (0%)	0 (0%)	1.00
Decrease	0 (0%)	0 (0%)	1.00

**Abstract ID: 0685**Specific Field: **Hepatobiliary  
and Pancreas Surgery**Mode of pres.: **Poster Exhibition only**  
ISW 2011 Session PE 349**Hepaticoduodenostomy in hepatectomy for perihilar  
cholangiocarcinoma: a preliminary report**H. Yoshida [1], Y. Mamada [2], N. Taniai [2], S. Mineta [2],  
M. Yoshioka [2], A. Hirakata [1], Y. Kawano [2], E. Uchida [2]

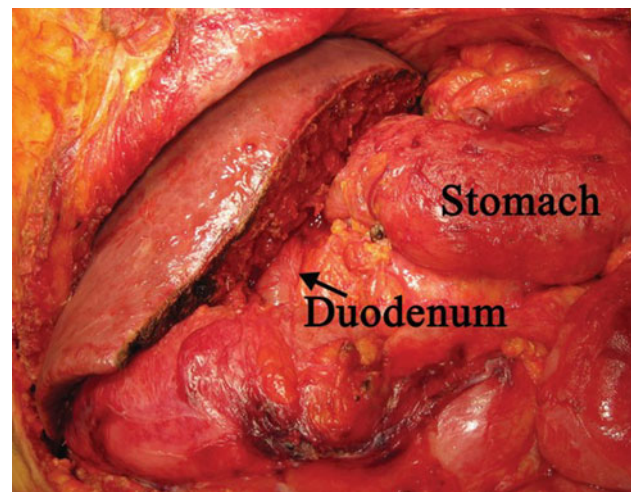
[1] Department of Surgery, Nippon Medical School Tama Nagayama Hospital, Tokyo, Japan, [2] Department of Surgery, Nippon Medical School, Tokyo, Japan

**Introduction:** A Roux-en-Y anastomosis fashioned from the jejunum (i.e., hepaticojejunostomy) is usually used to reconstruct the biliary system in hepatectomy. In this study, we review our experience with hepaticoduodenostomy (HD) as an alternative to Roux-en-Y biliary anastomosis in patients undergoing hepatectomy for perihilar cholangiocarcinoma, report our preliminary findings in 2 patients, and speculate on future applications.

**Material and Methods:** Two patients who received extended left hepatectomy with HD at Nippon Medical School Hospital in 2009 were studied. Laparotomy is performed using a Kent retractor. After Kocherization of the duodenum to provide a tension-free anastomosis to the hepatic duct, an extended left hepatectomy with excision of the common bile duct and lymph-node dissection is performed. In a case with several lumens of the bile ducts, hepaticoplasty is performed. The Kent retractor is released transiently, and the anastomosis is confirmed to be tension-free. As an internal stent, a 10-Fr silicon drain with channels along the sides, approximately 20 mm in length, is used. Anastomoses of the intrahepatic bile ducts to the duodenum are established by means of a single-layer anastomosis with continuous sutures.

**Results:** The patients drank water from next day and had a meal on postoperative day 2. No serious complications occurred with this technique. The postoperative course was uneventful, and the patients were discharged on postoperative day 10 and 12. After discharge, upper gastrointestinal endoscopy revealed no duodenogastric bile reflux.

**Conclusion:** Our initial experience suggests that HD may be a viable alternative to Roux-en-Y biliary anastomosis in patients undergoing hepatectomy for perihilar cholangiocarcinoma.





**Abstract ID: 0686**Specific Field: **Hepatobiliary  
and Pancreas Surgery****Mode of pres.: Poster Exhibition only  
ISW 2011 Session PE 350****Preoperative cholangitis independently increases in-hospital mortality after combined major hepatic and bile duct resection for hilar cholangiocarcinoma**

T. Oohashi [1], J. Sakata [1], T. Wakai [1], Y. Shirai [1], Y. Tsuchiya [2], T. Nomura [2], K. Hatakeyama [1]

[1] Division of Digestive and General Surgery, Niigata University Graduate School of Medical and Dental Sciences, Niigata, Japan, [2] Department of Surgery, Niigata Cancer Center Hospital, Niigata, Japan

**Introduction:** This study evaluated the impact of ductal bile bacteria (bactibilia or cholangitis) on the development of surgical site infection (SSI) or in-hospital mortality in patients undergoing combined major hepatic and bile duct resection for hilar cholangiocarcinoma.**Material and Methods:** A retrospective analysis was conducted on 81 patients who underwent a combined major hepatic and bile duct resection for hilar cholangiocarcinoma. Major hepatectomy was defined as hemihepatectomy or more extensive hepatectomy. Ductal bile was submitted for bacterial culture before or during the operation. Factors influencing SSI and in-hospital mortality were assessed by univariate and multivariate analyses.**Results:** Overall cumulative survival rates after resection were 37% at 5 years and 24% at 10 years with a median survival time of 31 months in all 81 patients. A total of 78 SSIs developed in 61 (75%) of the 81 patients. Overall, nine patients died post-resection during their hospital stay, giving an in-hospital mortality rate of 11%. The incidence of SSI was significantly higher in patients with preoperative bactibilia (83%) than in patients without (52%;  $P = 0.008$ ). Preoperative bactibilia was an independently significant variable associated with SSI (relative risk 9.003;  $P = 0.002$ ). The incidence of in-hospital mortality was significantly higher in patients with preoperative cholangitis (33%) than in patients without (6%;  $P = 0.009$ ). Preoperative cholangitis was the only independently significant variable associated with in-hospital mortality (relative risk 9.115;  $P = 0.006$ ). In 32 of the 50 patients with preoperative bactibilia and subsequent SSI, one or more common microorganisms were isolated in both the preoperative ductal bile and the sites of SSI.**Conclusion:** Preoperative cholangitis independently increases the incidence of in-hospital mortality after combined major hepatic and bile duct resection for hilar cholangiocarcinoma, whereas preoperative bactibilia independently increases the incidence of SSI.**Abstract ID: 0687**Specific Field: **Hepatobiliary  
and Pancreas Surgery****Mode of pres.: Poster Exhibition only  
ISW 2011 Session PE 351****Frozen section examination of bile duct margins in hilar cholangiocarcinoma**

M. Nakajima, M. Ohtsuka, M. Miyazaki

Chiba University, Chiba, Japan

**Introduction:** In surgical treatment of hilar cholangiocarcinoma, disease-positive surgical margin is one of the important prognostic

factors. To achieve a cancer-negative ductal margin, intraoperative frozen section examination is often used for the guidance of the extent of surgical resection. However, reliability and significance of this examination is not clarified.

**Material and Methods:** 80 patients with hilar cholangiocarcinoma were retrospectively reviewed. The ductal margin status was assessed histologically by both frozen section examination and permanent section examination. N**Results:** The status of 238 ductal margins (151 proximal and 87 distal margins) of the 80 patients was evaluated by frozen section examination. The accuracy, sensitivity and specificity of this examination were 97%, 98% and 94%, respectively. Six of 7 frozen sections, whose status was changed by permanent section, showed in-situ lesion. In the 21 patients with cancer-positive proximal ductal margin, additional resection was performed in 9. With additional resection, a negative margin was achieved in 5 patients, whose initial ductal margin showed invasive carcinoma. In none of patients with positive ductal margin with carcinoma in situ, cancer-negative margin was obtained by additional resection. In the 12 patients with cancer-positive distal ductal margin, additional resection was performed in 9. With additional resection (not pancreatoduodenectomy), a negative margin was achieved in 5 patients. In 3 of these 5 patients, initial ductal margin showed invasive carcinoma. The survival rate for patients, who had initially positive ductal margin with invasive carcinoma and a negative margin was achieved after additional resection, was better than that for patients, who had initially positive ductal margin with invasive carcinoma and a negative margin was not achieved after additional resection, and was similar to that for patients with a negative margin.**Conclusion:** Frozen section examination of bile duct margins in hilar cholangiocarcinoma is reliable. Additional resection on the basis of the results of frozen section examination contributes to the achievement of cancer-negative margin and the improvement of the survival in some patients with initial ductal status of invasive carcinoma.**Abstract ID: 0688**Specific Field: **Hepatobiliary  
and Pancreas Surgery****Mode of pres.: Poster Exhibition only  
ISW 2011 Session PE 352****Role of systematic lymph node dissection for hilar cholangiocarcinoma**

E. Tamoto, S. Hirano, S. Kondo

Hokkaido University Graduate School of Medicine, Sapporo, Japan

**Introduction:** Although the prognosis of hilar cholangiocarcinoma with nodal involvement is poor, some authors have reported a benefit of lymph node dissection. However, the suitable procedure of node dissection is controversial. We have routinely performed systematic dissection of the lymph nodes in the hepatoduodenal ligament, and peripancreatic nodes, such as the nodes along with the common hepatic artery, and dorsal of the pancreatic head for hilar cholangiocarcinoma. The aim of this study is to evaluate the efficacy of the systematic lymph node dissection.**Material and Methods:** This study enrolled 138 patients who underwent surgical resection for hilar cholangiocarcinoma with systematic lymph node dissection. Nodal status, recurrence, and survival rate were analyzed. Nodal status was defined by histopathologic findings as follows: no metastatic nodes as N0; positive nodes in the hepatoduodenal ligament as N1; and positive nodes in peipancreatic region as N2.**Results:** Of the 138 patients, 89 (65%) were classified in N0 disease, whereas 35 (25%) and 14 (10%) were N1 and N2, respectively. No patient was diagnosed with paraaortic node metastasis. The

recurrence rate after surgery did not differ according to nodal status. Meanwhile, lymph node recurrence was significantly more frequent in the patients with N2 than those with N0 and N1; nodal recurrence rate was 3, 0, and 36% in the N0, N1 and N2 patients, respectively ( $P < 0.0001$ ). The patients with N1 or N2 survived for a significantly shorter time than those with N0; the 5-year survival rate of patients with N0, N1, and N2 were 48, 27 and 21%, respectively ( $P = 0.0004$ ). Among the patients undergoing R0 resection, there was no difference in 3-year survival rate between the patients with N0 and N1 (68 vs. 44%,  $P = 0.113$ ). Even if the patients with N2 underwent R0 resection, they were significant shorter survivor than those with N0; the 3-year survival rate of the patients with N0 and N2 were 68 and 30%, respectively ( $P = 0.0172$ ).

**Conclusion:** The systematic lymph node dissection including peripancreatic nodes for hilar cholangiocarcinoma was beneficial in patients without lymph node metastasis or with positive nodes limited in hepatoduodenal ligament. R0 resection with the systematic lymph node dissection gave a good chance for prolonged survival in those patients. The patients with positive peripancreatic node might need some other treatment strategies.

**Abstract ID: 0689**                      Specific Field: **Hepatobiliary and Pancreas Surgery**

**Mode of pres.: Poster Exhibition only**  
**ISW 2011 Session PE 353**

**Long-term survival after hepatectomy with multimodal treatment for advanced Intrahepatic cholangiocarcinoma**

Y. Tanahashi, A. Sugioka, Y. Kato, T. Tokoro, J. Yoshida, T. Kagawa, C. Takeura

Fujita Healthy University School of Medicine, Toyoake, Japan

**Introduction:** Intrahepatic cholangiocarcinoma (ICC) is known for poor prognosis even after hepatectomy. However, we experienced some long-term survivors of far-advanced ICC treated by multimodal approach with surgery and chemotherapy.

**Material and Methods:** Herein we report 2 cases. Patient 1 is a 57-year-old female with a giant ICC occupying the entire left lobe associated with multiple intrahepatic metastases and regional lymph node metastases. Patient 2 is a 58-year-old female with a large ICC occupying the right lobe with intrahepatic metastases. In addition, multiple lung metastases and extensive lymph node metastases including Virchow's node and paraaortic region were diagnosed.

**Results:** In case 1, the patient underwent an extended left hepatectomy (Segment 1, 2, 3, 4, 5, 6) with bile duct resection. Afterwards, she underwent hepatic arterial infusion chemotherapy using CPT-11, 3 additional hepatectomies for hepatic recurrence and one pulmonary resection for lung metastases. Until just before death due to multiple lung metastases, she was able to live cheerfully for 6 years and 11 months after first hepatectomy. In case 2, the patient was started with systemic chemotherapy using S-1 plus cisplatin at first, which brought PR response as necrosis of intrahepatic metastases, reduction of Virchow's node and lung metastases. The patient underwent an extended right hepatectomy after the portal embolization. She underwent the second hepatectomy for recurrence and pulmonary resection for lung metastases, followed by systemic chemotherapy using S-1. Until just before death due to multiple lung metastases, she was able to enjoy favorable quality of life for 4 years and 3 months after the first chemotherapy.

**Conclusion:** These 2 cases suggest that multimodal approach with aggressive surgery and chemotherapy offers the best chance of long-term survival for patients with advanced ICC.

**Abstract ID: 0690**                      Specific Field: **Hepatobiliary and Pancreas Surgery**

**Mode of pres.: Poster Exhibition only**  
**ISW 2011 Session PE 354**

**Surgical outcome and prognostic factors in intrahepatic cholangiocarcinoma: single-institution experience of 82 patients**

T. Hirano, Y. Iimuro, N. Kuroda, T. Okada, N. Uyama, J. Yamanaka, J. Fujimoto

Hyogo College of Medicine, Nishinomiya, Japan

**Introduction:** Intrahepatic cholangiocarcinoma (ICC) is a rare primary liver cancer. Hepatectomy is the only cure for ICC, however, surgical outcomes and prognostic factors after liver resection for ICC are not fully understood. We retrospectively studied the records of ICC patients to clarify its clinical features, and to discuss treatment strategies.

**Material and Methods:** Eighty-two patients with ICC who were underwent hepatectomy at Hyogo College of Medicine and 26 patients who were not underwent resection between January 1986 and June 2010 was retrospectively analyzed. Univariate and multivariate analyses were conducted for several variables to evaluate their influence on the outcome.

**Results:** After resection, the calculated 1-, 3-, and 5-year-survival rates were 57%, 33%, and 27%, respectively. There was a significant difference in survival between resection and non-resection ( $P < 0.001$ ). Lymph node metastasis was found in 40 cases of 82 cases (49%). Survival rate was significantly poor compared with no lymph node metastasis. Univariate analysis showed that vessel invasion, lymph node metastasis was significantly associated with poor survival. Multivariate analysis confirmed that vessel invasion, lymph node metastasis were significant and independent prognostic indicator after surgical resection for ICC ( $P < 0.01$ ). Among lymph node positive cases, two patients lived over two years.

**Conclusion:** Vessel invasion and lymph node metastasis was the predictor of poor survival in ICC. However, long survivor was found in patients who have vessel invasion and lymph node metastasis though few cases. Complete resection and adjuvant therapy are required to prolong survival.

**Abstract ID: 0691**                      Specific Field: **Hepatobiliary and Pancreas Surgery**

**Mode of pres.: Poster Exhibition only**  
**ISW 2011 Session PE 355**

**A case of intrahepatic cholangiocellular carcinoma with portal vein tumor thrombus treated with surgery after hepatic arterial infusion chemotherapy**

S. Suzuki [1], H. Ochiai [1], K. Inuzuka [1], G. Tatsuno [2], O. Jindo [1], H. Kitamura [1]

[1] Iwata City Hospital, Iwata, Japan, [2] Omaezaki Municipal Hospital, Omaezaki, Japan

**Introduction:** We herein report a case of intrahepatic cholangiocellular carcinoma with portal vein tumor thrombus successfully treated with a combination of preoperative hepatic arterial infusion chemotherapy using 5-FU and surgery.

**Material and Methods:** A 62 year-old woman visited our hospital for further evaluation of a liver tumor detected by abdominal

ultrasonography in annual medical examination. Hepatitis B and C virus markers were negative. Serum CA19-9 level was elevated to 281.9 U/ml. Abdominal computed tomography showed an inhomogeneous in diameter with bile duct dilatation in the left lateral segment of the liver and the presence of tumor thrombus in the left portal vein. Hepatic tumor was slightly enhanced in the arterial phase, but distinct marginal enhancement was observed in the portal phase. This hepatic mass was accompanied by tumor thrombus extending from the left portal vein to the bifurcation of the portal vein. Her disease was highly suspicious of intrahepatic cholangiocellular carcinoma or combined hepatocellular and cholangiocarcinoma. Hepatic arterial infusion chemotherapy (HAIC) by weekly high dose administration of 5-FU (1000 mg/one time) was performed 10 times prior to surgery.

**Results:** Hepatic tumor was reduced to 3 cm in size with regression of portal tumor thrombus regression. The extended left hepatectomy with biliary tract reconstruction, lymph node dissection, and portal vein reconstruction was performed 1 month after the last HAIC. Histological examination showed that necrotic changes with calcification in most parts of portal vein tumor thrombus as well as hepatic tumor. Viable tumor tissues composed of well-differentiated adenocarcinoma cells were observed at the marginal site. Histopathologically, her disease was diagnosed as intrahepatic cholangiocellular carcinoma with portal vein tumor thrombus. Two years after the surgery, the patient is doing well without recurrent disease.

**Conclusion:** HAIC using 5-FU may be useful as a strategy for patients of intrahepatic cholangiocellular carcinoma with portal vein tumor thrombus prior to surgery.

**Abstract ID: 0692**      Specific Field: **Hepatobiliary and Pancreas Surgery**

**Mode of pres.: Poster Exhibition only**  
**ISW 2011 Session PE 356**

**Phase I study of adjuvant chemotherapy: combination of gemcitabine and S-1 in patients with advanced biliary cancer**

T. Takahara, H. Nitta, Y. Hasegawa, N. Itou, M. Takahashi, G. Wakabayashi

Iwate Medical University School of Medicine, Morioka, Iwate, Japan

**Introduction:** Among 188 patients with advanced biliary cancer who underwent curative resection in our institute from January, 2000 to August, 2009, the presence or absence of lymph node metastasis were considerably associated with their prognosis. Because the patients with positive lymph nodes have a higher recurrence rate, postoperative adjuvant chemotherapy should be considered.

**Material and Methods:** To determine the maximum-tolerated dose (MTD) and the recommended dose (RD) and to evaluate the efficacy and toxicity of the regimen in these curatively resected patients with biliary cancer, we conducted a phase I study for adjuvant chemotherapy of Gemcitabine (GEM) plus S-1. 34 patients with adequate organ functions, ECOG PS 0–1, under 80 years old, who had curative resection after August, 2007, were enrolled. They received GEM on day 1 and day 15; and S-1 from day 1 to day 14. At each level of four different combination doses, a cohort of 3 patients, which could be expanded to 6 patients was studied. Dose-limiting toxicities (DLT) were determined during first two treatment cycles. After determining RD, feasibility study was continued in the following four treatment cycles.

**Results:** Recommended dose after pancreatoduodenectomy is GEM 1000 mg/m<sup>2</sup> + S-1 80 mg/m<sup>2</sup>, and RD after hemihepatectomy is GEM 800 mg/m<sup>2</sup> + S-1 60 mg/m<sup>2</sup>. 31 patients finished the full-dose,

but 3 patients were dropped out by adverse effects, mainly general fatigue. 11 patients out of 14 patients with positive lymph nodes have shown no evidence of recurrence by now.

**Conclusion:** From the viewpoint of the pharmacokinetics of GEM and S-1, it is reasonable to change the dose of adjuvant chemotherapy, according to the operation method for biliary cancers. We are planning to start the Phase II study (GEM alone VS GEM plus S-1 by this RD) and believe that this regimen will be established in the future as one of effective adjuvant chemotherapies for biliary cancer.

**Abstract ID: 0693**      Specific Field: **Hepatobiliary and Pancreas Surgery**

**Mode of pres.: Poster Exhibition only**  
**ISW 2011 Session PE 357**

**A case of the extrahepatic cholangiocarcinoma alive 6 years after resection of the hepatic metastasis**

K. Doi, Y. Hirose

Japanese Red Cross Fukui Hospital, Fukui, Japan

**Introduction:** Optimal treatment for the liver metastasis of cholangiocarcinoma remains controversial. We present a rare case of long-term survival in patient involved extrahepatic cholangiocarcinoma that metastasized to the liver.

**Material and Methods:** The patient is a 67-year-old woman. She underwent pancreatoduodenectomy for extrahepatic cholangiocarcinoma in June 2003. The pathological diagnosis of moderately differentiated adenocarcinoma with regional lymph node metastasis. Ten months after surgery, the serum carcinoembryonic antigen and carbohydrate antigen 19-9 level increased and computed tomography revealed liver metastasis in the right lobe, 4 cm in size. The right lobe was resected in June 2004. Cisplatin and 5-FU was selected by chemosensitivity test. The 6 course of low dose FP as adjuvant chemotherapy was performed by hepatic arterial infusion.

**Results:** She remains alive without recurrence 6 years after resection of liver metastasis.

**Conclusion:** Though the prognosis after liver metastasis of cholangiocarcinoma is poor, in solitary cases, suggesting that long-term survival could be obtained by hepatectomy and prophylactic hepatic arterial infusion chemotherapy.

**Abstract ID: 0694**      Specific Field: **Hepatobiliary and Pancreas Surgery**

**Mode of pres.: Poster Exhibition only**  
**ISW 2011 Session PE 358**

**Significance of serum transforming growth factor  $\beta$ 1 levels in estimating bilirubin decrease following biliary drainage in patients with obstructive jaundice caused by biliary tract carcinoma**

T. Fukada, H. Shimizu, S. Kuboki, F. Kimura, M. Ohtsuka, H. Yoshidome, A. Kato, M. Miyazaki

Graduate School of Medicine, Chiba University, Chiba, Japan

**Introduction:** Biliary drainage is generally performed in patients with obstructive jaundice (OJ) before major hepatectomy for biliary tract

carcinoma. However, estimating the rate of decrease in bilirubin levels after biliary drainage is often difficult. In this study, we investigated a useful biochemical marker for estimating the period for bilirubin decrease, and studied the mechanisms responsible for delayed bilirubin reduction.

**Material and Methods:** Peripheral blood samples were taken from 22 patients with OJ caused by biliary tract carcinoma before and after biliary drainage. Serum transforming growth factor  $\beta 1$  (TGF- $\beta 1$ ) and platelet-derived growth factor BB (PDGF-BB), as well as bilirubin decrease rates (b value), were investigated. Expression of desmin and  $\alpha$ -smooth muscle actin ( $\alpha$ -SMA) in surgically resected liver specimens was also investigated using immunohistochemical staining in 12 patients who underwent radical surgery to evaluate hepatic stellate cell (HSC) status.

**Results:** Serum TGF- $\beta 1$  and PDGF-BB levels were significantly higher in patients with OJ than in controls ( $P < 0.01$ ). Serum levels of TGF- $\beta 1$  decreased significantly following biliary drainage. However, bilirubin reduction in patients with high serum TGF- $\beta 1$  was significantly slower than in those with low serum TGF- $\beta 1$ , irrespective of serum bilirubin levels before drainage. Immunohistochemical studies revealed increased numbers of HSCs (desmin-positive cells) and activated HSCs ( $\alpha$ -SMA-positive cells) in portal areas of the liver in patients with high serum TGF- $\beta 1$  at surgery.

**Conclusion:** Serum TGF- $\beta 1$  is mostly produced by activated HSCs, reflecting hepatic damage by cholestasis, and may be a useful biochemical marker for predicting the period of bilirubin reduction in patients with OJ.

**Abstract ID: 0695**      Specific Field: **Hepatobiliary and Pancreas Surgery**

**Mode of pres.: Poster Exhibition only**  
**ISW 2011 Session PE 359**

**A case report of carcinoma of the papilla of Vater showing an extensive superficial spread to the bile duct**

S. Hoshimoto, J. Matsui, F. Asahara, S. Takayama, H. Harada, S. Ogawa, M. Sato, N. Ando

Department of Surgery, Tokyo Dental College Ichikawa General Hospital, Ichikawa, Japan

**Introduction:** We present a very unusual case of carcinoma of the papilla of Vater that showed an extensive superficial spread to the upper common bile duct.

**Material and Methods:** A 69-year-old man was referred to our hospital for further evaluation of the obstructive jaundice. Abdominal computed tomography demonstrated two tumorous lesions, an 18-mm-diameter tumor in the papilla of Vater and a stricture in the common bile duct (CBD). Dilatation of the intrahepatic bile duct and the main pancreatic duct were also shown. Endoscopic retrograde cholangiography showed a 2-cm-diameter filling defect in the terminal of the distal bile duct and a severe stricture in the CBD as well. The duodenoscopy showed enlarged and deformed papilla with ulceration. Biopsy of the papilla revealed well differentiated adenocarcinoma and cytologic evaluation of biliary brush specimens in the CBD stricture was class V. Under the diagnosis of synchronous double cancer involving the papilla of Vater and the bile duct, pancreaticoduodenectomy with dissection of the lymph nodes was conducted.

**Results:** Macroscopically, two lesions were found in the resected specimens. An ulcerated tumor, measuring  $27 \times 23$  mm, was observed in the papilla of Vater and circumferential wall thickening with epithelial erosion was apparent in the middle bile duct. However, pathological examination of the resected specimens demonstrated

well-differentiated tubular adenocarcinoma in the papilla of Vater with lymph node metastasis and the tumor had spread extensively from the papilla of Vater to the upper bile duct. The invasion of the tumor was limited to the mucosa in the most part of CBD, however, subserosal invasion was observed in the stricture of the bile duct. The postoperative course was not eventful. At present, seven months after the surgery, the patient remains alive without any evidence of relapse.

**Conclusion:** We discuss the clinicopathological features of this very rare variant of carcinoma of the papilla of Vater.

**Abstract ID: 0696**      Specific Field: **Hepatobiliary and Pancreas Surgery**

**Mode of pres.: Poster Exhibition only**  
**ISW 2011 Session PE 360**

**Long-term outcome of surgical treatment for ampullary carcinoma**

S. Kubo, H. Shinkawa

Osaka City University, Osaka, Japan

**Introduction:** Few studies have described the follow-up findings for more than 10 years after surgery for ampullary carcinoma. We aimed to clarify the surgical indication and describe the long-term surgical outcome for ampullary carcinoma.

**Material and Methods:** The long-term outcomes of 23 patients who underwent pancreaticoduodenectomy were retrospectively reviewed. The prognostic factors for cancer-specific survival and overall survival after surgery were investigated.

**Results:** The cancer-specific 5-, 10-, and 20-year survival rates after resection of the ampullary carcinoma were 52%, 43%, and 43%, respectively, while the corresponding overall survival rates were 52%, 32%, and 24%, respectively. Ten of the 11 patients with recurrent ampullary carcinoma died within 5 years after surgery. Five years after the surgery, 4 patients died because of pancreatic cancer, colon cancer, old age after curative resection of gastric cancer, and pneumonia. Two patients with regional lymph node metastasis and no pancreatic invasion survived for more than 10 years after the surgery. The risk factors for the short cancer-specific survival period were pancreatic invasion and lymph node metastasis, while those for the short overall survival period were pancreatic invasion and the tumor grade.

**Conclusion:** Our study indicates that recurrence of ampullary carcinoma within 5 years after its resection, especially in patients with pancreatic invasion or lymph node metastasis, and development of other diseases after more than 5 years after the surgery should be carefully investigated. Pancreaticoduodenectomy with resection of the regional lymph node metastasis is warranted even if patients have only regional lymph node metastasis.

**Abstract ID: 0697**      Specific Field: **Hepatobiliary and Pancreas Surgery**

**Mode of pres.: Poster Exhibition only**  
**ISW 2011 Session PE 361**

**A 1.3-cm carcinoid tumor of the minor duodenal papilla with superior mesenteric lymph node metastases**

T. Maruyama [1], Y. Shirai [1], J. Sakata [1], T. Wakai [1], M. Iwafuchi [2], K. Hatakeyama [1]



[1] Niigata University Graduate School of Medical and Dental Sciences, Niigata, Japan, [2] School of Health Sciences, Faculty of Medicine, Niigata University, Niigata, Japan

**Introduction:** Carcinoids of the minor duodenal papilla are extremely rare, and the optimal extent of surgical treatment for these tumors remains uncertain. We herein report a case of a 1.3-cm carcinoid tumor of the minor duodenal papilla with lymph node metastases, and provide data regarding the management of these tumors by reviewing cases reported in the literature.

**Material and Methods:** A 52-year-old man presented with a 2-week history of epigastric discomfort. Upper gastrointestinal endoscopy revealed a 1.3-cm submucosal tumor at the minor papilla of the duodenum. Biopsy specimens revealed a carcinoid tumor. After confirming the diagnosis of carcinoid tumor of the minor duodenal papilla, a pylorus-preserving pancreaticoduodenectomy was performed. Immunohistochemical examination of the resected specimen revealed that the tumor was positive for chromogranin A and synaptophysin. Of the 26 dissected lymph nodes, 2 superior mesenteric nodes contained a metastatic carcinoid. After confirming that an R0 resection was accomplished, he was given no adjuvant chemotherapy or radiotherapy, and he remains alive and well with no evidence of disease 62 months after resection.

**Results:** In the English-language literature, we found only 4 patients with carcinoid of the minor duodenal papilla. Although 3 patients underwent transduodenal or endoscopic local excision alone, the other patient underwent pancreaticoduodenectomy for a 1.5-cm tumor with lymph node metastasis. In reviewing the Japanese-language literature, we collected 19 additional cases (including our case) of patients who underwent a pancreaticoduodenectomy for carcinoid of the minor duodenal papilla. Of these patients, 15 (79%) had nodal disease: 1 of 2 patients with a tumor 1.0 cm, 12 of 14 with a tumor measuring 1.0 to 2.0 cm, and 2 of 3 with a tumor >2.0 cm had regional nodal involvement. Most patients with tumors measuring 1.0 to 2.0 cm (including our patient, who had a 1.3-cm tumor) had nodal disease.

**Conclusion:** Considering the high prevalence of nodal disease in carcinoids of the minor duodenal papilla measuring 1.0 to 2.0 cm, such lesions are not good candidates for transduodenal or endoscopic local excision. Pancreaticoduodenectomy seems to be a wiser option for such lesions if the patient is medically fit for operative therapy.

**Abstract ID: 0698**      Specific Field: **Hepatobiliary and Pancreas Surgery**

**Mode of pres.: Poster Exhibition only**  
**ISW 2011 Session PE 362**

**Lymph node involvement is a prognostic factor of ampullary cancer following radical resection**

K. Takeshima, K. Yamafuji, J. Kubochi

Department of Surgery, Saitama Municipal Hospital, Saitama City, Japan

**Introduction:** The aim of this study is to evaluate the impact of clinicopathological factors upon the survive of the patients with ampullary cancer following pancreaticoduodenectomy.

**Material and Methods:** Patients were identified from a prospective database between January 1988 and December 2010 undergoing pancreaticoduodenectomy for primary ampullary cancer. The staging is according to UICC TNM classification (6th edition). Clinicopathological findings (invasion to duodenum, invasion to pancreas, lymph

node involvement, vessel invasion, lymphatic invasion and perineural invasion) was assessed. Survival curves were calculated by Kaplan–Meier analysis. Multivariate analysis was performed using a Cox proportional hazard model with stepwise regression. The statistical analysis was performed by Dr. SPSS II for windows.

**Results:** Fourteen of 36 patients died and median survival was 41 months (1–253). The cumulative survival rate of 5 years and 10 years was 68.6% and 51% respectively. Lymph node involvement was a significant factor of shorter 5-year survival (47.3% vs 90%;  $P = 0.0007$ ). Invasion to pancreas significantly affected 5-year survival (51.9% vs 87.2;  $P = 0.0159$ ). But invasion to duodenum, vessel invasion, lymphatic invasion and perineural invasion were not significantly associated with survival. Multivariate analysis showed lymph node involvement was the strongest prognostic factor ( $P = 0.006$ ).

**Conclusion:** For patients with ampullary cancer following pancreaticoduodenectomy, lymph node involvement was an independent prognostic factor.

**Abstract ID: 0699**      Specific Field: **Hepatobiliary and Pancreas Surgery**

**Mode of pres.: Poster Exhibition only**  
**ISW 2011 Session PE 363**

**A case of incidental gallbladder carcinoma diagnosed after single incision laproscopic cholecystectomy**

Y. Tokunaga, S. Matueda, H. Sasaki

Osaka North Japan Post Hospital, Osaka, Japan

**Introduction:** Single incision laparoscopic cholecystectomy (SILC) has been introduced from 2007 in western countries and performed worldwide recently. We report here a case of incidental gallbladder carcinoma diagnosed after SILC.

**Material and Methods:** A 78-year-old female was pointed out the elevation of liver enzyme values without any abdominal symptom, in the periodical follow-up of hypertension. She was diagnosed as cholecystolithiasis by ultrasound examination. Endoscopic retrograde cholangiopancreatography (ERCP) and magnetic resonance imaging cholangiopancreatography (MRCP) showed cholecystolithiasis, choledocholithiasis, and partly irregular gallbladder wall. Choledocholithiasis was removed after endoscopic sphincterotomy and balloon dilation. SILC was performed without any trouble including the bladder injury, bleeding, or bile leak.

**Results:** Macroscopic examination showed a small ulcerative lesion about  $2 \times 1.3$  cm in the free wall of the bladder fundus. Pathological findings revealed a well differentiated adenocarcinoma, ss, INF $\beta$ , pHinf0, pBinf0, pEM0, pHM0, ly2, v0, pn0, curative resection, according to the Japanese classification of gallbladder carcinoma. She was discharged from the hospital without any complication. She received an adjuvant chemotherapy with oral fluoropyrimidine, S-1 (2 weeks on and 1 week off) for 6 months, though she was not willing to undergo additional hepatic resection. She has been well without recurrence of the cancer for 2 years after surgery.

**Conclusion:** SILC has been reported as a safe and effective alternative to standard laparoscopic cholecystectomy. It can provide patients with minimal scarring. SILC should be performed paying attention not to cause the organ injury and bile leak, since there has been several reports of port site recurrence from incidental gallbladder carcinoma after laparoscopic cholecystectomy.

**Abstract ID: 0700**      Specific Field: **Hepatobiliary and Pancreas Surgery**

**Mode of pres.: Poster Exhibition only**  
**ISW 2011 Session PE 364**

**Adenoendocrine cell carcinoma of the cystic duct: a case report**

J. Ishii, Y. Otsuka, M. Tsuchiya, Y. Kubota, T. Maeda, A. Tamura, H. Shimada, H. Kaneko

Department of Surgery [Omori], Toho University Omori Medical Center, Tokyo, Japan

**Introduction:** Adenoendocrine cell carcinoma rarely affects the biliary tract, especially cystic duct.

**Material and Methods:** We report a case of adenoendocrine cell carcinoma of the cystic duct in a 62-year-old Japanese man.

**Results:** The patient underwent laparoscopic cholecystectomy for cholecystitis, preoperative imaging showed no tumors in the cystic duct. Histopathologic examination revealed a tumor that consisted of two components in the cystic duct, poorly differentiated tubular adenocarcinoma and endocrine cell carcinoma. An immunohistochemical analysis showed positive staining for chromogranin A, synaptophysin, and CD56. The final diagnosis was an adenoendocrine cell carcinoma. Then resection of the extrahepatic proximal bile ducts was performed with lymph node dissection, and converted to pancreaticoduodenectomy because diagnosed metastasis of a posterior pancreaticoduodenal lymph node during the operation. The man suffered from recurrent multiple liver metastases resistant to chemotherapy, dying 1 year after the operation.

**Conclusion:** Adenoendocrine cell carcinoma is considered high-grade malignancy with a dismal prognosis.

**Abstract ID: 0701**      Specific Field: **Hepatobiliary and Pancreas Surgery**

**Mode of pres.: Poster Exhibition only**  
**ISW 2011 Session PE 365**

**Xanthogranulomatous cholecystitis mimicking advanced gallbladder carcinoma with vascular involvement**

S. Suzuki, H. Ochiai, O. Jindo, A. Uno, A. Fukazawa, K. Matsumoto, H. Kitamura

Iwata City Hospital, Iwata, Japan

**Introduction:** Xanthogranulomatous cholecystitis is a rare, destructive, inflammatory disease of the gallbladder. This disease occasionally infiltrates into the surrounding tissues and clinically resembles advanced gallbladder carcinoma.

**Material and Methods:** We herein report a case of xanthogranulomatous cholecystitis mimicking advanced gallbladder carcinoma with the involvement of adjacent major vessels, as well as the liver, common hepatic duct, and duodenum.

**Results:** This patient was successfully treated with extended right hepatic lobectomy en-bloc with cholecystectomy and lymphadenectomy, removal of the portal bifurcation and extrahepatic bile duct, and partial resection of the inferior vena cava and duodenum. Postoperative histopathology indicated the presence of xanthogranulomatous

cholecystitis spread to the portal vein, right hepatic artery, and inferior vena cava. The postoperative course was uneventful, and the patient was discharged on the 29th postoperative day. She has remained asymptomatic and in good health for 30 months after surgery.

**Conclusion:** The differentiation between xanthogranulomatous cholecystitis with biliary and vascular involvement and advanced gallbladder carcinoma is difficult. Appropriate surgery based on the extent of xanthogranulomatous cholecystitis should be carefully attempted with a sound anatomical knowledge and surgical skills.

**Abstract ID: 0702**      Specific Field: **Hepatobiliary and Pancreas Surgery**

**Mode of pres.: Poster Exhibition only**  
**ISW 2011 Session PE 366**

**Bacteriological analysis in bile for acute cholecystitis according to Tokyo guidelines**

K. Asai, M. Watanabe, H. Matsukiyo, A. Osawa, T. Saito, Y. Saida, J. Nagao, S. Kusachi

Toho University Ohashi Medical Center, Tokyo, Japan

**Introduction:** Acute cholecystitis (AC) is one of the high risk factors for bactibilia and post operative infectious complications in patients who are going to cholecystectomy. However, there are relatively small data on the bacteriological analysis in patients undergoing cholecystectomy for AC. In this study we focused on the bacteriological analysis in bile for AC according to Tokyo guidelines, and analyzed about the risk factor for bactibilia.

**Material and Methods:** At the Department of Surgery, Toho University Ohashi Medical Center, 163 patients who underwent cholecystectomy for AC with preformed bacteriological analysis in bile between January 1998 and September 2010 were admitted to the study. In these cases, the bactibilia was revealed 96 cases (58.6%), and bacteria absent was revealed 67 cases (41.1%).

**Results:** The cases distribution was followed; Grade I (mild) was 64 cases (39.3%), Grade II (moderate) was 97 cases (59.5%), and Grade III (severe) was only 2 cases (1.2%). Age, body temperature (BT), white blood cell count (WBC), and C-reactive protein (CRP) showed significant difference compared Grade I with Grade II. In addition, the bactibilia was revealed significant difference between Grade I and Grade II. There was no significant difference about the type of bacteria in both groups. Antimicrobial resistance and polymicrobial present were also revealed no significant difference in both groups. The risk factor influencing bactibilia was also analyzed. Severity grading, age, BT, CRP, and marked local inflammation were significant risk factor influencing the bactibilia. High CRP and an advanced age revealed as significant independent risk factor about the bactibilia in multivariate analysis.

**Conclusion:** In conclusion, we analyzed the bacteriological analysis in bile for AC cases according Tokyo guidelines. Compared Grade I with Grade II, there was significant difference about the bactibilia, however, there was no significant difference about the type of bacteria, antimicrobial resistance rate, and polymicrobial rate. In the Grade I cases according to Tokyo guidelines, the sufficient antimicrobial therapy perioperatively should not be avoided. More precise severity grading need to construct, especially CRP and advanced age should be included.

**Abstract ID: 0703**      Specific Field: **Hepatobiliary and Pancreas Surgery**

**Mode of pres.: Poster Exhibition only**  
**ISW 2011 Session PE 367**

**Adoption of a single-incision laparoscopic cholecystectomy**

I. Hisashi [1], Kokuba Yukihito [1], Otsuji Eigo [2], Y. Kuriu [1], M. Nakanishi [1], D. Ichikawa [1], K. Okamoto [1], T. Ochiai [1]

[1] Kyoto Prefectural University of Medicine, Kyoto, Japan,  
[2] Kyoto Prefectural University of Medicine, Japan

**Introduction:** A single-incision laparoscopic cholecystectomy, which is performed by making an incision into the belly button, is expected to lead to reduced pain and scarring and a shortened time required for recovery and it is now becoming more widely used. At our institution, we have also adopted this surgical technique and are safely operating and implementing this technique, and we herein report the conditions associated therewith and describe the adjustments made regarding this treatment modality.

**Material and Methods:** Since July 2009, we performed single-incision laparoscopic cholecystectomy for 20 patients with Cholelithiasis patients or cystic adenomyosis patients with no history of fever, jaundice, or colic attacks.

**Results:** The cases comprised 30 patients, including 14 male and 16 females, wherein the average surgery time was 117 min, the average amount of bleeding was low, and there were no cases involving the addition of ports, cases shifted to laparotomy, or cases involving intraoperative gallbladder perforations and there were no postoperative complications without one SSI.

**Conclusion:** We safely adopted the surgical technique known as single-incision laparoscopic cholecystectomy. With a single-incision laparoscopic cholecystectomy of the umbilical region, it was possible to secure a field of view comparable with that obtained in a conventional laparoscopic cholecystectomy using four incisional wounds. Moreover, no special forceps or procedures are required and the surgery can be performed safely.

A safe port insertion method using a 5-mm flexible fiberscope

**Abstract ID: 0704**      Specific Field: **Hepatobiliary and Pancreas Surgery**

**Mode of pres.: Poster Exhibition only**  
**ISW 2011 Session PE 368**

**Our novel techniques of single-incision laparoscopic cholecystectomy using a sponge spacer**

Y. Nakamura, S. Matsumoto, T. Tajiri, Y. Arima, E. Uchida

Nippon Medical School, Tokyo, Japan

**Introduction:** Single-incision laparoscopic surgery has been developed as a novel scarless minimally invasive procedure. Although it has certainly superior cosmetic advantage, other benefits of the short-term operative outcomes and postoperative complications remain obscure. It surely exist technical difficulties and economic matters. In our institution, single-incision transumbilical laparoscopic cholecystectomy has been introduced for eligible patients with a cholelithiasis since 2009. Our presentation shows economical procedure with good handling in this operation.

**Material and Methods:** Surgical technique

The essential points are as follows. (1) A multichannel single port is created using a surgical glove; three small 5 mm trocars and two tubes for insufflations and exhausting of the gas are attached to each finger portion. (2) Approximately 2.5 cm incision is made on the umbilicus. The wound retractor (Applied Alexis TM) is placed and a new surgical device, a sponge spacer by the name of SECUREA TM, is inserted in the abdominal cavity. This novel device has various utilities such as gentle retraction of organs, absorption bodily fluid and protection from the burn caused by some kinds of the energy devices. (3) A flexible or a rigid 30°5 mm laparoscope is used. (4) A gall bladder is separated using an electrocautery. Neither other energy devices nor the roticator forceps are used in this operation. (5) Double ligation is made on the cystic duct by the Roeder's knot extracorporeal tying. (6) The resected specimen is inserted in the glove and removed with the wound retractor.

**Abstract ID: 0705**      Specific Field: **Hepatobiliary and Pancreas Surgery**

**Mode of pres.: Poster Exhibition only**  
**ISW 2011 Session PE 369**

**Results of repeated reconstructive surgery for bile duct strictures following cholecystectomy**

J. V. Kolosovsky, S. I. Galeev

Saint-Petersburg State Medical Academy n.a. Mechnikov,  
Saint-Petersburg, Russian Federation

**Introduction:** We summarize our experience of secondary reconstructive operations for biliary duct strictures and outline factors contributed to unsatisfactory results of treatment.

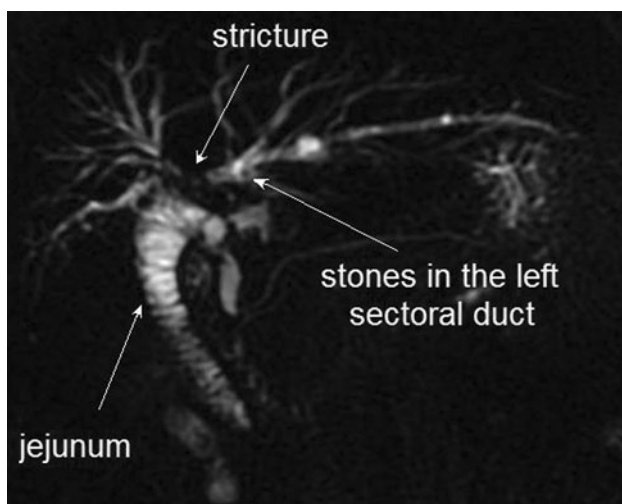
**Material and Methods:** From 1998 to 2010 there were 49 patients referred for surgical management of biliary strictures. According to the level of primary stricture they were classified as Bismuth type I—7 (14.3%), type II—25 (51%), type III—16 (32.7%), type IV—1 (2%). 21 patient previously underwent hepaticojejunostomy (HJ), 7—multiple reconstructive operations, 9—drainage of peritoneal cavity, 6—transcutaneous biliary drainage.

**Results:** In our department 34 patients (69.4%) underwent HJ, 10 (20.4%)—HJ with prolonged changing stents, 5 (10.2%)—HJ with wide exposure of hilar plate and partial liver resections (according to Hepp and Strasberg). There were no operative deaths. 20 patients (40.8%) presented different complications including abdominal abscesses, intestinal fistulas. In this series with 25, 3 month of follow-up, 25 patients (51%) subsequently developed restructure, cholangitis or biliary cirrhosis. Failure of reconstruction was closely associated with severity of primary injury (III-IV class according to Bismuth),  $P < 0.01$  and type of operation,  $P < 0.05$  (Table). Unsuccessful primary reconstruction usually led to stenosis of anastomosis resulting additional loss of biliary tissue and more proximal character of stricture (Picture: MRI cholangiogram of patient underwent HJ for initial biliary injury assessed as E3, and subsequent restructure expanding to lobar ducts with intraductal stones formation and cholangitis). Best results were achieved when good exposure of bile ducts were obtained.

**Conclusion:** Our data suggest: repeated reconstructive surgery for bile duct strictures is associated with high morbidity and failure rates. Good exposure of bile ducts guarantees precise biliodigestive anastomosis precluding recurrence of stricture.

## Type of procedure and outcome of repeated surgery

Type of surgery	Outcome (number of patients)	Outcome (number of patients)
Type of surgery good	16	18
Hepaticojejunostomy and rehepaticojejunostomy		
Hepaticojejunostomy and rehepaticojejunostomy with prolonged changing stents	3	7
Rehepaticojejunostomy with wide hilar plate exposure (Hepp, Strasberg procedures)	5	0



Abstract ID: 0706

Specific Field: **Hepatobiliary and Pancreas Surgery**Mode of pres.: Poster Exhibition only  
ISW 2011 Session PE 370**The effect of BETA-glucan on acute lung injury in experimental obstructive jaundice**

O. Kordon [1], H. Erkol[1], N. Kahramansoy [1], A. Kukner [2], O. Buyukasik [1], E. Serin [3]

[1] Abant Izzet Baysal University Medical Faculty General Surgery Department of Bolu, Turkey, [2] Abant Izzet Baysal University Medical Faculty, Department of Histology and Embryology, Bolu, Turkey, [3] Abant Izzet Baysal University, Faculty of Medicine, Department of Biochemistry, Bolu, Turkey

**Introduction:** The aim of this study was to investigate the effects of beta glucan on the lung damage caused by obstructive jaundice.**Material and Methods:** In our study, 35 Wistar Albino rats were divided into five groups which were 7 rats in each group randomly. Only bile duct exploration by laparotomy was performed in group I.

Bile duct ligation was performed by laparotomy in group II. The rats in group III were treated with beta-glucan for 10 days after bile duct ligation. The rats in group IV were treated with beta-glucan for 10 days before and after bile duct ligation. The rats in group V were treated with beta-glucan for 10 days before bile duct ligation. All rats in each group were sacrificed and blood and tissue samples were collected at eleventh day after bile duct ligation. Superior lobe of the right lung was taken out for histopathologic evaluation. Tissue malondialdehyde (MDA), lipid peroxidase (LPO), glutathione (GSH) levels were measured by spectrophotometry method in the homogenate of median and inferior lobe of the right lung. Myeloperoxidase (MPO) and superoxide dismutase (SOD) levels measured in serum. Bronchoalveolar lavage (BAL) was performed in the left lung and trachea. After centrifuge procedure of the BAL liquid, spreading and painting with giemsa realized for histopathologic evaluation. LDH measured in the other part of the centrifuged liquid. Results were analysed by SPSS 15, 0 package program. Statistical analysis realized by using Mann-Whitney U test.

**Results:** Results showed that beta-glucans were found to have positive effects on the lung functions in obstructive jaundice. MDA and LPO, serum MPO values increased and tissue GSH and serum SOD values were found to decrease as an indicator of lipid peroxidation, oxidative stress and neutrophil infiltration in group II. Tissue MDA and LPO, serum MPO values decreased and tissue GSH and serum SOD were found to increase in treatment groups. Histopathological evaluation showed that groups treated with beta-glucan were found to be less damage in the lung. The level of LDH in centrifuged BAL liquid was meaningful low in all treatment groups. The highest number of PNL was in the control group.

**Conclusion:** The results of this study showed that beta-glucan has a strong antioxidant agent effect in obstructive jaundice and a protective effect in the lung tissue against oxidative damage.

Abstract ID: 0707

Specific Field: **Hepatobiliary and Pancreas Surgery**Mode of pres.: Poster Exhibition only  
ISW 2011 Session PE 371**Antecolic and retrocolic route on delayed gastric emptying after modified subtotal stomach-preserving pancreaticoduodenectomy**

T. Oida [1], K. Mimatsu [1], H. Kano [1], A. Kawasaki [1], Y. Kuboi [1], N. Fukino [1], K. Kida [1], S. Amano [2]

[1] Social Insurance Yokohama Central Hospital, Yokohama, Japan, [2] Nihon University School of Medicine, Tokyo, Japan

**Introduction:** Previously, we developed a modified subtotal stomach-preserving pancreaticoduodenectomy for preventing delayed gastric emptying achieved a decrease in the incidence of delayed gastric emptying. In this study, we compared the antecolic and retrocolic routes to determine which reconstruction route is better for decreasing the incidence of delayed gastric emptying in modified subtotal stomach-preserving pancreaticoduodenectomy.

**Material and Methods:** We retrospectively analyzed 42 patients who underwent modified subtotal stomach-preserving pancreaticoduodenectomy with pancreaticogastrostomy. The patients were divided into 2 groups based on type of reconstruction: the antecolic reconstruction group (AC group) and the retrocolic reconstruction group (RC group). The incidence of delayed gastric emptying was determined and compared between the 2 groups.



**Results:** The mean time during nasogastric suction and before initiation of a diet after surgery was shorter in the retrocolic reconstruction group (without significant difference); however, the mean time before oral ingestion of solid food could be safely resumed was significantly shorter in the RC group ( $9.7 \pm 1.2$  days) than in the AC group ( $11.4 \pm 3.0$  days;  $P < 0.0112$ ).

**Conclusion:** We consider retrocolic reconstruction preferable to antecolic reconstruction for preventing delayed gastric emptying in patients who have undergone modified subtotal-stomach-preserving pancreaticoduodenectomy with pancreaticogastrostomy.

#### Outcomes

	AC group (n = 14)	RC group (n = 28)	P value
Operative time (min)	408	418	0.3887
Blood loss (ml)	567	549	0.7536
N-G removal (d)	1.7	1.5	0.2844
Initial diet (d)	5.2	4.8	0.0519
Days after which solid diet could be resumed (d)	11.4	9.7	0.0112#
Delayed gastric emptying			
A	0 (0%)	0 (0%)	1.00
B	12 (85.7%)	28 (100%)	0.1057
C	2 (14.3%)	0 (0%)	0.1057
Complications			
Pneumonia	1 (7.1%)	1 (3.6%)	1.00
Wound infection	1 (7.1%)	2 (7.1%)	1.00
Cholangitis	1 (7.1%)	1 (3.6%)	1.00
Postoperative serum albumin 3.8 (g/ml)	3.8	0.8758	
Duration of hospitalization (d) 26.1	24.2	0.1064	

**Abstract ID: 0708**      Specific Field: **Hepatobiliary and Pancreas Surgery**

**Mode of pres.: Poster Exhibition only**  
**ISW 2011 Session PE 372**

**Protection of skeltized vessels and pancreaticogastrostomy using with the falciform ligament and omental flap to prevent pancreatic leakage after pancreaticoduodenectomy in soft pancreas**

K. Mimatsu [1], T. Oida [1], H. Kano [1], A. Kawasaki [1], N. Fukino [1], K. Kida [1], Y. Kuboi [1], S. Amano [2]

[1] Social Insurance Yokohama Central Hospital, Yokohama, Japan,  
[2] Nihon University School of Medicine, Tokyo, Japan

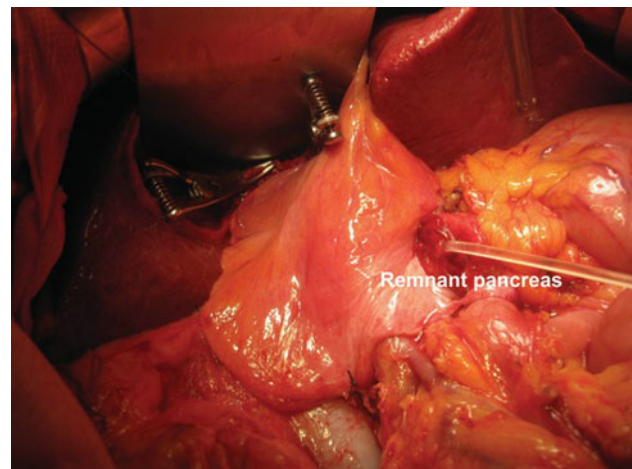
**Introduction:** Pancreatic fistula is one of the major morbidity in patients undergoing pancreaticoduodenectomy. Protection of the skeletonized vessels and the anastomotic site of pancreaticoenterostomy is one of the surgical options to prevent the development of a pancreatic fistula. The aim of this study was to describe an operative

technique to protect the vessels and anastomotic site by wrapping them with the falciform ligament and the greater omentum.

**Material and Methods:** After a modified subtotal stomach-preserving pancreaticoduodenectomy reconstruction with pancreaticogastrostomy was performed, the falciform ligament and greater omentum was used on the skeletonized major vessels, and wrapped around the anastomotic site of pancreaticogastrostomy. Twenty consecutive patients were enrolled in this prospective study.

**Results:** The entire procedure did not result in any operative complications. Postoperative pancreatic fistula developed in 2 cases (10%). According to the international postoperative pancreatic fistula criteria, grade A and grade B was observed in 1 case each. No intra-abdominal hemorrhage and late intra-abdominal abscess were observed.

**Conclusion:** This procedure is a convenient and safe technique, and may be helpful in preventing major complications caused by pancreatic fistula.



**Figure:** Protection of vessels with falciform ligament

**Abstract ID: 0709**      Specific Field: **Hepatobiliary and Pancreas Surgery**

**Mode of pres.: Poster Exhibition only**  
**ISW 2011 Session PE 373**

**Prospective analysis of technique for closure of the pancreatic remnant after distal pancreatectomy**

K. Okada, M. Kawai, H. Yamaue, M. Tani, S. Hirono, M. Miyazawa, A. Shimizu, K. Uchiyama

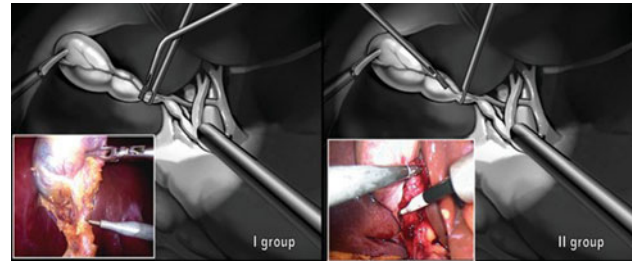
Wakayama Medical University, Wakayama, Japan

**Introduction:** Distal pancreatectomy (DP) can be performed with low mortality and acceptable morbidity rates. Pancreatic fistulas (PF), occurring in 10% to 20% of cases, remain a problem that contributes significantly to morbidity, length of stay, and overall costs.

**Material and Methods:** From 1991 to 2010, 130 consecutive patients underwent DP at Wakayama Medical University Hospital. The surgical techniques used for closure were categorized into 3 groups: 1) closure by suture (oversewn) in 45 patients between January 1991 and December 2005, 2) transection using bipolar scissors and not oversewn in 45 patients between January 2006 to August 2008, 3) closure using a stapling device (Endoscopic linear cutter (EC60A), ECR60D) alone in 40 patients between September 2008 and December 2010. Pancreatic fistulas were graded according to the recent international fistula definition (ISGPF).

**Results:** Each rates of grade B + C pancreatic fistula revealed 42.2% (19 of 45 cases) in hand-sew group, 15.6% (7 of 45 cases) in bipolar scissors group, and 10.0% (4 of 40 cases) in stapling device group, respectively. Bipolar scissors and stapling device significantly decreased the rates of PF compared with that of hand-sew group ( $P = 0.01$ ,  $P = 0.007$ ). There was no significant difference between bipolar scissors and stapling device group ( $P = 0.529$ ). As for stapling device, PFs were frequently detected in the cases with thick pancreas (thickness at the resection site of the pancreas is more than 15 mm).

**Conclusion:** The characteristics of devices and the pancreatic condition (hardness, thickness) should be taken into consideration to select the device for pancreatic transaction in DP.



**Figure:** Schema and real-time endoscopic view during instruments mutual task performance in two study groups are presented

**Abstract ID: 0710**      Specific Field: **Hepatobiliary and Pancreas Surgery**

**Mode of pres.: Poster Exhibition only**  
ISW 2011 Session PE 374

**Ergonomic risks associated with the performance of laparoscopic cholecystectomy**

G. Manukyan

Medical Governance of Police, Yerevan, Armenia

**Introduction:** The ergonomic poor environment in laparoscopic surgery can lead to situations, where the operator knows what to do, but performs it in a non-optimal way. The clinical study investigated the ergonomic conditions of the posture and movements in the left upper extremity with the grasper used during laparoscopic cholecystectomies. Intraperitoneal movement errors during the impact of the instruments or the instrument with the optics were also evaluated.

**Material and Methods:** This is a non-randomized ergonomic observational clinical study aimed at investigating the effectiveness of the use of curved and straight laparoscopic graspers during laparoscopic cholecystectomy. In two groups the postural balancing and the range of motions in the left upper extremity were compared. This occurs as laparoscopic grasper manipulation tasks are performed. Two groups were defined according to the instrument and the trocar position. Group 1 ( $n = 81$ ) underwent operations performed with the curved grasper in the surgeon's left-hand. In group 2 ( $n = 28$ ) straight forceps for the left hand were used. The overview video centered on the surgeon's posture, and the endoscopic view were recorded for further subsequent 15 s interval analysis. The incorporation and mutual impedance of the instruments, or the instrument with the laparoscope during different steps of the cholecystectomy were registered.

**Results:** The range of motions in the left upper extremity responsible for the atraumatic grasper manipulations was more extended in the second group where the straight grasper was used. The surgeon's bent torque was frequently used for the manipulations in the second group arrangement. The evaluation of the endoscopic view showed that the bimanually coordinated tasks performance with the curved grasper allowed to avoid instrumental or visualization conflicts intracorporeally.

**Conclusion:** The ergonomic problems more frequently occurred by the use of the straight grasper in the second group. In the first group the setup of the trocars and the curved grasper in the left hand allowed the ergonomic and sufficient manipulations, and helped to prevent any undesirable discomfort and errors in the optimal work environment.

**Abstract ID: 0711**      Specific Field: **Hepatobiliary and Pancreas Surgery**

**Mode of pres.: Poster Exhibition only**  
ISW 2011 Session PE 375

**Reinforcement of pancreaticojejunostomy using polyglycolic acid mesh and fibrin glue sealant**

S. Satoi, H. Toyokawa, H. Yanagimoto, T. Yamamoto, S. Hirooka, S. Yamaki, Rintaro Yui, A.-H. Kwon

Kansai Medical University, Hirakata, Japan

**Introduction:** The aim of this study is to examine whether pressure-tight reinforcement of pancreaticojejunostomy (PJ) using polyglycolic acid (PGA) mesh and fibrin glue sealant can reduce the incidence of post-operative pancreatic fistula (POPF).

**Material and Methods:** The study population included 128 consecutive patients who underwent pancreaticoduodenectomy between September 2006 and January 2010. Post-operative mortality and morbidity among the 50 patients who underwent reinforcement of the PJ anastomosis using PGA mesh (group A) and fibrin glue were compared to 78 patients who served as historical controls (group B).

**Results:** The two groups demonstrated no significant differences in the frequencies of overall (A 60% vs. B 51%) or septic complications (18% vs. 12%), re-operation (0% vs. 2.5%) or in-hospital death (2% vs. 3.8%). No significant difference in the frequency of post-operative pancreatic fistula (POPF, A 34% vs. B 44%), delayed gastric emptying (A 14% vs. B 8%), or intra-abdominal abscess (A 6% vs. B 8%) was found between groups. There was no difference between the two groups in the number of necessary interventions, and no bleeding complications or POPF-related mortality occurred. The median length of post-operative in-hospital stay between the two groups was similar: 13 days (range 8–101) versus 14 days (range 8–61). Similar findings were observed in a sub-group analysis consisting of patients with a pancreatic duct diameter smaller than 3 mm.

**Conclusion:** This retrospective single-center study showed that reinforcement of PJ anastomosis using PGA mesh and fibrin glue provided no significant benefit in reducing the frequency of POPF.

**Abstract ID: 0712**      Specific Field: **Hepatobiliary and Pancreas Surgery**

**Mode of pres.: Poster Exhibition only**  
ISW 2011 Session PE 376

**Duodenum-preserving pancreatic head resection for intraductal papillary mucinous neoplasm of the pancreas**

T. Maki, S. Hirano, E. Tanaka, J. Matsumoto, K. Kato, T. Tsuchikawa, T. Shichinohe, S. Kondo

Hokkaido University Graduate School of Medicine, Sapporo, Japan

**Introduction:** Limited surgery has recently been performed for benign or low-grade malignant neoplasms involving the pancreas. However, outcomes of the limited surgery for intraductal papillary mucinous neoplasm (IPMN) of the pancreas have not been fully verified. This retrospective study investigated the validity of duodenum-preserving pancreatic head resection (DPPHR) for IPMN, which includes resection of pancreatic parenchyma alone and preservation of structures surrounding the pancreatic head such as the duodenum and bile duct.

**Material and Methods:** Between 1995 and 2009, a total of 38 patients underwent resection for IPMN of the pancreatic head. DPPHR was performed in 16 patients diagnosed as having IPMN without invasion or lymph node metastasis as assessed by preoperative imaging, whereas pancreatoduodenectomy (PD) was performed in 22 patients with IPMN in which preoperative imaging showed any invasion or lymph node metastasis. Relationships between postoperative histopathological diagnosis and operative procedures were investigated. Clinicopathological factors were analyzed to compare oncological curability, postoperative patients' conditions, and postoperative complications between DPPHR and PD.

**Results:** Six patients with invasive carcinoma derived from intraductal papillary mucinous carcinoma underwent PD and showed significantly worse prognosis than the other patients. Excluding these 6 patients, no significant differences were seen between DPPHR ( $n = 16$ ) and PD ( $n = 16$ ) in terms of surgical margins, recurrence, postoperative survival, and postoperative complications. DPPHR was superior to PD in terms of postoperative weight loss ( $P = 0.0349$ ).

**Conclusion:** For benign or low-grade malignant IPMN of the pancreatic head, DPPHR is a feasible and useful operative procedure that enables curative resection and preservation of structures surrounding the pancreatic head, resulting in less postoperative weight loss than PD.

**Abstract ID: 0713**      Specific Field: **Hepatobiliary and Pancreas Surgery**

**Mode of pres.: Poster Exhibition only**  
**ISW 2011 Session PE 377**

**The reconstruction procedure after pancreatoduodenectomy (PD)**

I. Hisashi, T. Ochiai, E. Otsuji, Y. Kuriu, M. Nakanishi, D. Ichikawa, K. Okamoto, Y. Kokuba

Kyoto Prefectural University of Medicine, Kyoto, Japan

**Introduction:** The new reconstruction procedure after pancreatoduodenectomy (PD) is described to evaluate its usefulness.

**Material and Methods:** From April 2008 through to March 2010, 17 patients were submitted for PD reconstructed by pancreaticogastrostomy. The study consisted of 11 men and 6 women, with a median age of 65.1 years. The main indications for PD were cholangiocarcinoma in 5 patients, pancreatic ductal carcinoma in 6 patients, ampullary carcinoma in 3 patient, IPMN in 2 patients, SCN in one patient. Reconstruction by pancreaticogastrostomy was performed, after inserting the pancreatic stent into the posterior wall of the stomach.

**Results:** The average of duration of operation was 456 min, and the amount of blood loss 1583 ml. Two patients (11.8%) developed a pancreatic fistula (PF) at the grade B in ISGPF. They were managed conservatively. Two groups of patients (Pancreaticogastrostomy(PG) vs. Pancreaticojejunostomy(PJ)) were compared with patients without a PF for analysis, the PJ group included 36 patients, they were underwent the procedure from April 2005 to March 2010. There was no significant difference in the mean age, the gender ratio, surgical time and blood replacement. 17 patients (47%) developed a pancreatic fistula (PF) at the grade B or C in ISGPF in PJ group. ( $P = 0.0396$ ).

**Conclusion:** Our method in Pancreaticogastrostomy is safe for complications after PD.

**Abstract ID: 0714**      Specific Field: **Hepatobiliary and Pancreas Surgery**

**Mode of pres.: Poster Exhibition only**  
**ISW 2011 Session PE 378**

**Less morbidity after distal pancreatectomy using ultrasonically activated device**

R. Yui, S. Satoi, H. Toyokawa, H. Yanagimoto, T. Yamamoto, S. Hirooka, S. Yamaki, A. Kwon

Kansai Medical University, Hirakata, Japan

**Introduction:** Distal pancreatectomy is a standard operation for the pathological lesion of pancreatic body and tail. In the past decades, advances in surgical technique and sophisticated peri-operative management have reduced post-operative mortality of distal pancreatectomy less than 2% in high-volume center, yet morbidity remains as high as 11% to 38%. Purpose of this study is to investigate differences of frequency of post-operative complications retrospectively according to method of pancreas resection using between knife and scissor-type of ultrasonically activated device (USAD).

**Material and Methods:** From January 2000 to June 2010, consecutive 109 patients underwent distal pancreatectomy at Kansai Medical University Hospital. From January 2000 to May 2006, the 52 consecutive patients underwent pancreatic resection with cutting the pancreatic parenchyma by knife (knife group). From June 2006 to June 2010, we used ultrasonically activated device to cut the pancreatic parenchyma as a part of DP and to dissect the peri-pancreatic tissue including vascular and lymphatic vessels less than 3 mm in diameter in the 57 consecutive patients (USAD group).

**Results:** There were no differences in operative mortality, overall morbidity, and rate of re-operation between knife and USAD groups. The rate of post-operative pancreatic fistula (POPF), Grade B/C POPF, and surgical site infection in USAD group had the higher tendency relative to knife group, but significantly differences were not found. The rate of intra-abdominal abscess in USAD group was significantly lower than that in knife group ( $P = 0.012$ ). The frequency of grade 3/4 Clavien score in USAD group was significantly lower than that in knife group ( $P = 0.039$ ), although there was no difference in grade 1/2 Clavien score between them. The timing of drain removal (3 days vs. 8 days) and in-hospital stay (8 days vs. 17 days) in USAD group were significantly lower than those in knife group ( $P < 0.001$ ).

**Conclusion:** A use of the ultrasonically activated device in distal pancreatectomy was closely associated with low frequency of intra-abdominal abscess and grade 3/4 of Clavien score, resulting in shorter in-hospital stay.

**Abstract ID: 0715**      Specific Field: **Hepatobiliary and Pancreas Surgery**

**Mode of pres.: Poster Exhibition only**  
**ISW 2011 Session PE 379**

**Ultrasonically activated scalpel is an effective tool for cutting the soft pancreas to prevent pancreatic fistula after pancreaticoduodenectomy: a preliminary study**

T. Kobayashi [1], H. Hirukawa [1], T. Tada [1], T. Naito [1], M. Soeno [1], H. Matsuoka [1], K. Hatakeyama [2]



[1] Tachikawa General Hospital, Nagaoka, Japan, [2] Niigata University Graduate School of Medical and Dental Sciences, Niigata, Japan

**Introduction:** Pancreatic fistula (PF) after pancreatoduodenectomy (PD) remains a challenging problem. We preliminarily report the applicability of the ultrasonically activated scalpel for dividing parenchyma of the soft pancreas to prevent PF after PD.

**Material and Methods:** A retrospective review was performed of all 18 patients who underwent PD or pylorus preserving PD (PPPD) in the Tachikawa General Hospital from March in 2005 to November in 2010. We started to use an ultrasonically activated scalpel to divide the pancreas after May in 2008. The pancreas was cut with a knife before May in 2008. Surgical procedure was as followings. Pancreaticojejunostomy was performed as a pancreatic reconstruction after PD. The pancreatic duct was anastomosed to the full thickness of the jejunal wall with interrupted 6–0 absorbable sutures. The remnant pancreas was anastomosed to the sero-muscular wall of the jejunum with interrupted 4–0 non-absorbable sutures (modified Kakita's method). A stent was placed in the pancreatic duct through the ductojejunosomy as an external stent in most cases. In the ultrasonically activated scalpel (US) group ( $n = 8$ ), Two were female and six were male. Diagnosis were carcinoma of the Papilla Vater in 3, pancreatic carcinoma in 3, carcinoma of the bile duct in 1, and duodenal carcinoma in 1 patient. In the conventional surgical division (CV) group ( $n = 10$ ), three were female and seven were male. Diagnosis were carcinoma of the bile duct in 6, pancreatic carcinoma in 3, and cholelithiasis in 1 patient. Median operative time was 392 min. in US group and 428 min in CV group ( $P = n.s.$ ). Median operative bleeding was 860 ml in US group and 495 ml in CV group ( $P = n.s.$ ) PF defined according to the International Study Group of Pancreatic Fistula.

**Results:** PF occurred in 22% ( $n = 4$ ) of patients in the CV group. No PF occurred in US group ( $P < 0.05$ ). One case of ISGPF Grade A and three cases of ISGPF Grade B were observed. There was no ISGPF Grade C case.

**Conclusion:** The use of the ultrasonically activated scalpel may reduce the incidence of pancreatic fistula after pancreaticoduodenectomy. Further prospective randomized studies are required to confirm this preliminary result.

**Abstract ID: 0716** Specific Field: **Hepatobiliary and Pancreas Surgery**

**Mode of pres.: Poster Exhibition only**  
**ISW 2011 Session PE 380**

#### Middle pancreatectomy with pancreaticojejunostomy for pancreatic neoplasms

A. Kimijima, T. Hatori, I. Fujita, T. Furukawa, M. Yamamoto  
Tokyo Women's Medical University, Tokyo, Japan

**Introduction:** A middle pancreatectomy (MP) is sometimes performed to treat benign or low-grade malignant neoplasms in the neck or body of the pancreas. The aim of MP is to preserve pancreatic exocrine and endocrine function. However, MP requires two times of transaction of the pancreas and reconstruction of the distal pancreatic remnant. Therefore, the pancreatic fistula may occur after MP rather than after pancreatoduodenectomy or distal pancreatectomy. The aim of this study is to evaluate operative results after MP.

**Material and Methods:** A group of 85 patients who underwent MP for pancreatic neoplasms between 1991 and 2010 were investigated in this study, retrospectively. The reconstruction of the distal pancreatic

remnant was performed by pancreaticojejunostomy. Intraductal papillary mucinous neoplasm (IPMN) was found in 39 patients (adenomas 22, borderline lesion 6, non-invasive carcinoma 8, invasive carcinoma 3), neuro-endocrine tumor (P-NET) in 20 patients, serous cystadenoma (SCA) in 10 patients, pancreatic intraepithelial neoplasm (PanIN) in 7 patients, solid-pseudopapillary neoplasm in 6 patients and mucinous cystic adenoma (MCA) in 3 patients.

**Results:** Pancreaticojejunostomy without a stent tube was performed in 71 patients and 14 patients underwent pancreaticojejunostomy with a stent tube. Mortality rate was 0%. According to the ISGPF criterion, no pancreatic fistula with grade C was occurred. Moreover, no pancreatic fistula with grade B at the pancreaticojejunostomy was occurred. However, pancreatic fistula with grade B at the proximal pancreatic cut end was occurred in 15% of the patients because of the wide transection around the gastroduodenal artery. No tumor recurrence was observed. Pancreatic exocrine and endocrine functions were almost maintained.

**Conclusion:** In terms of the preservation of the pancreatic function, MP is a safe and useful procedure for the treatment of benign or low-grade malignant neoplasms in the pancreatic neck or body.

**Abstract ID: 0717** Specific Field: **Hepatobiliary and Pancreas Surgery**

**Mode of pres.: Poster Exhibition only**  
**ISW 2011 Session PE 381**

#### Early open drainage with delayed necrosectomy in treatment of severe pancreatitis

S. I. Galeev [1], M. A. Rubtsov [2], J. V. Knyazeva [2],  
J. V. Kolosovsky [1], J. P. Abdullaev [1]

[1] Saint-Petersburg State Medical Academy n.a. Mechnikov, Saint-Petersburg, Russian Federation, [2] Clinical Hospital of St. Luke, Saint-Petersburg, Russian Federation

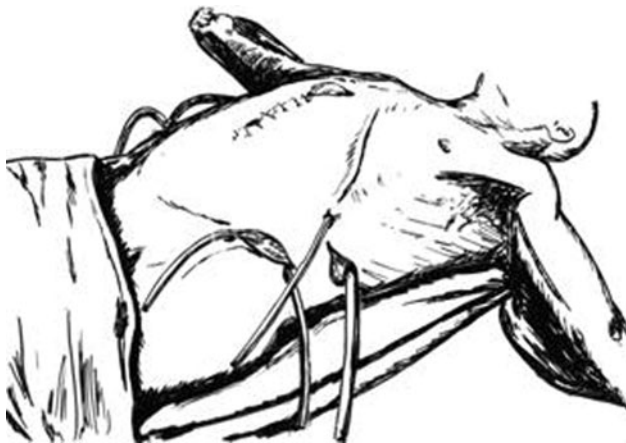**Introduction:** It's generally accepted: necrosectomy in early phase of severe pancreatitis increases mortality. At the same time, most of irreversible organ failures and deaths associated with infection resistant to conservative measures. Aim of present study: to perform comparative analysis of treatment results in two series of patients: managed conservatively (group 1), underwent early open drainage of extrapancreatic necrosis with delayed necrosectomy (group 2).

**Material and Methods:** A retrospective study of 71 patient with severe pancreatitis (abscesses and cysts were excluded) in 9 year period (2000–2009) was done. 17 patients were treated without operation, other (54) underwent early (mean time from the disease onset  $-6.1 \pm 7.1$  days) drainage with further necrosectomy (mean time from primary operation  $-12.5 \pm 6.0$  days). Drainage was performed via laparotomy with further retroperitoneum opening through apertures located in the lumbar and inguinal regions (Figure). Separated from abdominal cavity epigastric pathway was used for delayed pancreatic necrosectomy.

**Results:** Above-mentioned groups were comparable in regard to local complications severity (Balthazar index turned out to be equal,  $P = 0.49$ ; extended pancreatic necrosis ( $>50\%$ ) was diagnosed in 4 patients of group 1 (26.7%) and 8 of group 2 (19.5%),  $P = 0.83$ ). Mean admission APACHE II score between two groups didn't differ ( $8.9 \pm 5.4$  vs.  $14.5 \pm 7.8$ ;  $P = 0.24$ ). We haven't observed early drainage negative effect on a course of the disease (mortality rates in groups were practically similar: conservative therapy—4 patients died (23.5%); surgical treatment—19 patients died (35.2%),  $P = 0.37$ ). Misfortune of surgery in most part of cases might be explained by late admission of patients with advanced septic complications.



**Conclusion:** Drainage and necrosectomy temporal separation seems to be beneficial sepsis-preventive tactic in critically ill patient with severe pancreatitis, equalizing results of conservative and surgical treatment.



**Figure:** Retroperitoneal drainage of necrotizing pancreatitis

**Abstract ID: 0718**      Specific Field: **Hepatobiliary and Pancreas Surgery**

**Mode of pres.: Poster Exhibition only**  
**ISW 2011 Session PE 382**

**Usefulness of the clamp-crushing technique for pancreatic transection in pancreatoduodenectomy**

N. Kuroda, Y. Iimuro, T. Hirano, T. Okada, Y. Asano, N. Uyama, M. Satake, J. Fujimoto

Hyogo College of Medicine, Nishinomiya, Japan

**Introduction:** A postoperative pancreatic fistula (POPF) is one of the major complications following pancreatoduodenectomy (PD). Many kinds of techniques of pancreatoenterostomy have been reported aiming to prevent POPF from the main pancreatic duct so far. However, the incidence of POPF still remains high. POPF is consisted of fistula from the main pancreatic duct as well as from the pancreatic branch ducts on the cut surface of the pancreas. Thus, some kinds of attempt to prevent the fistula from the pancreatic branch ducts are required. A clamp-crushing technique, ideal method for branch duct ligation, has been safely used in hepatic resection. The aim of this study was to clarify the usefulness of this clamp-crushing technique in pancreatic transection in PD.

**Material and Methods:** Thirty-four patients with a normal soft pancreas who underwent PD using a clamp crushing pancreatic resection technique in the last 2 years were analyzed. In pancreatic resection, the pancreatic parenchyma was crushed using a mosquito-Kelly clamp with strokes of about 5 mm without blood flow occlusion. Pancreatic branch ducts and small vessels were ligated with 4–0 sutures and the main pancreatic duct was identified and cut. Pancreatojejunostomy was performed by duct-to-mucosa anastomosis. A pancreatic duct stent tube was inserted into the main pancreatic duct for external drainage of pancreatic juice. Using resected specimens, the number of pancreatic branch ducts was counted in HE staining. The incidence and the grading of POPF according to ISGPF criteria were determined.

**Results:** The median number of pancreatic branch ducts was 11 (range, 4–30). POPF occurred in 13 (37.1%) patients; POPF Grade A  $n = 7$  (20.0%), Grade B  $n = 6$  (17.1%). There were no Grade C patients, or no POPF-associated mortality.

**Conclusion:** This clamp-crushing technique appears to be a rational and safe method for pancreatic transection.

**Abstract ID: 0719**

Specific Field: **Hepatobiliary and Pancreas Surgery**

**Mode of pres.: Poster Exhibition only**  
**ISW 2011 Session PE 383**

**Surgical procedure for main duct type of intraductal papillary mucinous neoplasm of the pancreas**

T. Tsukamoto, A. Kanazawa, S. Shimizu, S. Kodai, S. Yamazoe

Department of Hepato-Biliary-Pancreatic Surgery, Osaka City General Hospital, Osaka, Japan

**Introduction:** Preoperative diagnosis of the degree of malignancy and invasion of main duct type of intraductal papillary mucinous neoplasm (IPMN) of the pancreas is difficult. In the international guideline of the treatment of IPMN, it is an indication for surgical treatment for its malignant potential. But the suitable procedure for it is not unclear. In this paper, our 20 cases of main duct type or mixed type of IPMN are estimated and the appropriate surgical treatment for it is discussed.

**Material and Methods:** Of the 20 cases of main duct type or mixed type of IPMN, 11 cases were performed proximal pancreatectomy, 7 cases were performed distal pancreatectomy, 2 cases segmental resection of the pancreas.

**Results:** Resected specimen revealed intraductal papillary mucinous adenoma (IPMA) in 9 cases and intraductal papillary mucinous carcinoma (IPMC) in 11 cases. In 16 cases the pancreatic stump was free of IPMN but in 4 cases it was involved with mild dysplastic cells of IPMN. No cases had lymphnode metastasis. All cases has been alive without recurrence for from 2 to 13 years (average, 6 years) but one case died of hepatocellular carcinoma 2.5 years after pancreatic resection.

**Conclusion:** Appropriate resection of the dilated lesion of the main pancreatic duct and free of IPMN at the pancreatic stump will be adequate procedure for main duct type of IPMN.

**Abstract ID: 0720**

Specific Field: **Hepatobiliary and Pancreas Surgery**

**Mode of pres.: Poster Exhibition only**  
**ISW 2011 Session PE 384**

**Analysis of pancreas volume using multidetector-row computed tomography (MDCT)**

T. Fukumoto, W. Kimura, I. Hirai, A. Takeshita, S. Murayama, T. Watanabe

Gastroenterological and General Surgery, Yamagata, Japan

**Introduction:** There are few studies about the assessment of pancreas volume using multidetector-row computed tomography (MDCT). Recently, technological advances in computed tomography make it easy to calculate pancreas volume more precisely than before. In this study, we examined the pancreas volume according to pancreatic disease.

**Material and Methods:** In Yamagata University Faculty of Medicine Since December, 2006 28 patients of pancreas cancer and 40 patients of intraductal papillary-mucinous neoplasms (IPMN) underwent Pancreatectomy. We calculated 30 patients underwent laparoscopic cholecystectomy (LC) as control. We studied 98 patients. We calculated pancreas volume by free hand tracing method using work station soft (Zio station). To adjust the difference by physique, we divided the volume by body surface area.

**Results:** Mean pancreas volume of pancreas cancer patients was 53.5 ml. Adjusted volume was 36.0 ml/m<sup>2</sup>. Mean pancreas volume of IPMN patients was 69.8 ml. Adjusted volume was 46.2 ml/m<sup>2</sup>. Mean pancreas volume of underwent LC patients was 77.2 ml. Adjusted volume

was 47.9 ml/m<sup>2</sup>. Adjusted pancreas volume of pancreas cancer patients was significantly smaller than Adjusted pancreas volume of IPMN and control (LC) patients ( $P < 0.01$ ). However there was no difference between Adjusted pancreas volume of IPMN and control (LC) patients. **Conclusion:** Pancreas volume of pancreas cancer patients was significantly smaller than pancreas volume of IPMN and control (LC) patients. Occlusion of main pancreatic duct with cancer invasion may be cause of fibrosis. Pancreas volume is not reduce for IPMN case. Therefore surgeon should take care of postoperative pancreatic fistula.

**Abstract ID: 0721**                      Specific Field: **Hepatobiliary and Pancreas Surgery**

**Mode of pres.: Poster Exhibition only**  
**ISW 2011 Session PE 385**

#### Glucose tolerance function after pancreas surgery

K. Shibata [1], I. Hirai [2], T. Moriya [2], A. Takeshita [2],  
W. Kimura [2]

[1] Yamagata University Faculty of Medicine, Yamagata city, Japan,  
[2] Yamagata University Faculty of Medicine, Japan

**Introduction:** There were several report concerning exocrine or endocrine function after pancreas surgery. However, exact volumetric study before and after pancreatic surgery is rare.

We studied correlation between resected volume of the pancreas and postoperative glucose tolerance function.

**Material and Methods:** We evaluate 53 cases of pancreatic resection without Diabetes Mellitus preoperatively. Pancreatoduodenectomy(PD) were 24 cases, and Distal pancreatectomy(DP) were 29 case from 2002 to 2007. Volumetric study of the pancreas was calculated by summation of each CT slice area.

We decide HbA1c >6.0 or required insulin or drug therapy case as glucose intolerance function.

**Results:** Mean resection rate of pancreatoduodenectomy(PD) was 64% and distal pancreatectomy(DP) was 38%. None of PD showed glucose intolerance function. On the other hands, 44% of cases of DP showed postoperative glucose intolerance function. Especially, four of five cases resected more than 50% of parenchyma showed postoperative HbA1c >6.0%.

**Conclusion:** Postoperative glucose intolerance is rare after pancreatoduodenectomy.

Distal pancreatectomy tended to deteriorate glucose tolerance function than pancreatoduodenectomy.

More than 50% parenchymal resection of distal pancreas have a risk of postoperative glucose intolerance function.

**Abstract ID: 0722**                      Specific Field: **Hepatobiliary and Pancreas Surgery**

**Mode of pres.: Poster Exhibition only**  
**ISW 2011 Session PE 386**

#### Preoperative 18[F]-fluorodeoxyglucose positron emission tomography/computed tomography predicts early recurrence after pancreatic cancer resection

K. Okamoto, I. Koyama, Y. Toshimitsu, M. Aikawa, K. Okada,  
M. Miyazawa

Saitama International Medical Center, Saitama Medical University,  
Hidaka, Japan

**Introduction:** An important step in deciding the treatment strategy for pancreatic cancer is to preoperatively predict the possibility of early recurrence. We reviewed whether 18[F]-fluorodeoxyglucose positron emission tomography/computed tomography (FDG-PET/CT) before pancreatic cancer resection could predict the tumor recurrence in the early postoperative period.

**Material and Methods:** FDG-PET/CT was performed preoperatively on 56 cases with pancreatic cancer. The maximum standardized uptake (SUVmax) values obtained by FDG-PET/CT were compared between two groups: patients with and without recurrence within the first 6 postoperative months. Besides the SUVmax, analyses were also performed to determine whether age, sex, CA 19-9 values, the operative method, and portal vein resection were also predictive of recurrence within less than 6 months after tumor resection.

**Results:** The median SUVmax values of the recurrence group and non-recurrence group were 7.9 and 4.2, respectively ( $P = 0.0042$ ). The SUVmax was the only risk factor for recurrence in the first 6 postoperative months identified by multivariate analysis ( $P = 0.0062$ ).

**Conclusion:** Preoperative SUVmax was higher in the recurrence group during the early postoperative period, and a high SUVmax was a risk factor for early postoperative recurrence. We conclude that FDG-PET/CT is predictive of the recurrence of pancreatic cancer in the early postoperative period.

**Abstract ID: 0723**                      Specific Field: **Hepatobiliary and Pancreas Surgery**

**Mode of pres.: Poster Exhibition only**  
**ISW 2011 Session PE 387**

#### For complete R0 resection of the pancreatic cancer: result of intraoperative frozen section study of the stumps of the extrapancreatic plexus of the nerve

T. Watanabe, W. Kimura, T. Fukumoto, K. Tezuka, Y. Kamio,  
T. Moriya, A. Takeshita, I. Hirai

Department of Gastroenterological and General Surgery, Yamagata University Faculty of Medicine, Yamagata, Japan

**Introduction:** Complete curative R0 resection is very important for the surgical treatment of the pancreatic cancer. For complete R0 resection, the extrapancreatic nerve plexus invasion (PL) should be evaluated strictly. But this evaluation tends to be unclear in the fixed specimen after surgery. We have performed and proposed that entire stumps of the extrapancreatic nerve plexus should be investigated and confirmed to be negative for cancer in the intraoperative frozen section study. This study aimed to investigate whether the pathological findings of the intraoperative frozen study of the stumps of the nerve plexus correlates with prognosis.

**Material and Methods:** During the operation, the stumps of the extrapancreatic nerve plexus (Plexus Ph-1 and Ph-2) were resected and numbered into an average of 16 parts, and investigated all stumps by the frozen section study. If there were the cancer cells in the initial stumps, we resected further nerve plexus and examined again. We divided the patients into positive group who were confirmed cancer cells in the initial stumps and negative group who were confirmed no cancer cells in the initial stumps.

**Results:** Totally 430 specimens (33 patients) were investigated.(Plexus Ph-1: average of 6 specimens, Plexus Ph-2: average of 10 specimens) Total number of the specimens that there were positive cancer cells was 15 (15/430 = 3.5%), 9 patients (9/33 = 27.3%) were confirmed cancer cells in the initial stumps. Patient characteristics are revealed that CEA value of positive group was significantly higher. Cumulative survival rate was not significantly different between the two groups ( $P = 0.51$ ). But, there is no hope of long survival in positive group.

**Conclusion:** This method is useful for curative R0 resection. But if there are the cancer cells in the initial stumps of the extrapancreatic

nerve plexus, the prognosis tend to be poor. In such cases, we should perform combined modality therapy as the neoadjuvant chemotherapy and/or radiation therapy, and adjuvant chemotherapy.

**Abstract ID: 0724** Specific Field: **Hepatobiliary and Pancreas Surgery**

**Mode of pres.: Poster Exhibition only**  
**ISW 2011 Session PE 388**

**Diagnostic value of various imaging procedures in cystic, in particular, neoplastic lesions of the pancreas: preliminary results of an ongoing systematic clinical prospective observational study to reflect daily clinical practice**

F. Meyer [1], A.-K. Mueller [2], F. Fuedner [2], I. Wanzar [2], U. Will [2]

[1] Department of General, Abdominal and Vascular Surgery, University Hospital, Magdeburg, Germany, [2] Department of Gastroenterology, Municipal Hospital, Gera, Germany

**Introduction:** The adequate diagnostic of pancreatic tumor(-like) lesions is challenging but indispensable for initiation of an appropriate treatment.

**Material and Methods:** Over a defined time period, all patients with suspicious cystic tumor lesions of the pancreas were enclosed in this study. The diagnostic value was characterized by i) the appropriate parameters such as sensitivity(Se), specificity(Sp), positive & negative predictive value (PPV/NPV) as well as diagnostic accuracy(DxAcc) &, for comparison, ii) histologic diagnosis after investigation of the surgical specimen as gold standard or iii) clinical follow up in patients with negative FNA or with low CEA levels of cystic fluid.

**Results:** From 2002 to 2007, in total 214 subjects (median age, 64 [range, 41–87] years; sex ratio, m:f = 122:92 [1.33:1]) were identified with a tumor(-like) manifestation. Pseudocysts predominated with 102 cases (47.7%) followed by cystic adenocarcinoma ( $n = 50$ ; 23.4%), serous cystic adenoma ( $n = 50$ ; 23.4%) & mucinous cystic adenocarcinoma, intraductal papillary mucinous neoplasia(IPMT), not further differentiated cysts ( $n = 10$  each; 4.7%). EUS were performed in all cases in part with FNA &/or puncture of cystic fluid, whereas CT scan & ERCP in 25.2% ( $n = 54$ (214) & 41.6% ( $n = 89$ (214), resp.

**Conclusion:** Though considered an investigator-dependent imaging procedure, EUS combined with FNA & CEA analysis of cystic fluid provides the best parameters in diagnosis-finding of cystic neoplastic pancreatic lesions, which needs to be favored in experienced hands with the further potential advantage of therapeutic continuation of the session if indicated & if it is promising.

**Table:** Detection parameters differentiating cystic lesions of the pancreas  $\pm$  neoplastic characteristics, which are lower differentiating between benign & malignant characteristics of such neoplastic lesions)

	Sensitivity	Specificity	PPV	NPV	Diagnostic accuracy
EUS	88.7%	67.0%	71.6%	84.0%	76.6%
CT	66.7%	73.3%	55.6%	81.5%	71.1%
ERCP	63.2%	86.2%	75.0%	78.1%	68.4%
FNA <sup>a</sup>	66.7%	75.0%	89.7%	40.9%	68.6%
Cytology <sup>a</sup>	66.7%	52.9%	90.0%	90.0%	52.9%
CEA <sup>b</sup>	63.2%	90.0%	85.7%	69.2%	75.0%

<sup>a</sup> Differential diagnosis of cystic lesions of the pancreas; <sup>b</sup> Detection of malignancy

**Abstract ID: 0725**

Specific Field: **Hepatobiliary and Pancreas Surgery**

**Mode of pres.: Poster Exhibition only**  
**ISW 2011 Session PE 389**

**Obesity as a risk factor for the pancreatic fistula after pancreaticoduodenectomy**

T. Yasuda, Q. Wu, S. Haji, R. Yoshida, T. Nakai, T. Murakami, H. Ohyanagi, Y. Takeyama

Kinki University School of Medicine, Osaka-Sayama, Japan

**Introduction:** Obesity is considered as a risk factor for the perioperative complications. Especially, the performing pancreaticoduodenectomy (PD) in the obese patient is more challenging and hazardous. In the complications after PD, postoperative pancreatic fistula (POPF) is a persistent and life threatening problem. In general, concerning obesity, the body mass index (BMI) has been widely used as a marker, but the improvement of the diagnostic modality allows the accurate analysis of obesity, such as subcutaneous fat volume and visceral fat volume. In this study, we investigated the specific impact of obesity on POPF after PD.

**Material and Methods:** A retrospective analysis was conducted on 58 consecutive patients undergoing PD who were able to measure fat volume, from July 2007 to March 2010. Volumetric measurement of abdominal visceral and subcutaneous fat tissue was performed by computed tomography. Intraoperative and perioperative data were collected, and the relationship between surgical outcome, especially POPF, and the obesity was investigated. Statistical analyses were performed using SPSS II software (SPSS Inc, Chicago, IL). A P value less than 0.05 were considered statistically significant.

**Results:** Among 58 patients, 13 patients developed POPF (22%). There were no significant differences in patients' background between two groups (patients with or without POPF). In the patients with POPF, operation time is longer than in the patients without POPF, but the difference was not significant. Intraoperative blood loss, and intraoperative blood transfusion is larger in the patients with POPF, but the difference was not significant. Concerning obesity, subcutaneous fat volume, visceral fat volume, body weight and BMI were significantly higher in the patients with POPF than those in the patients without POPF ( $P = 0.005, 0.002, 0.006, 0.042$ , respectively).

**Conclusion:** The patients with POPF were more obese, and therefore, obesity may be a risk factor for POPF after PD. Special surgical caution is recommended in obese patients to perform PD.

**Abstract ID: 0726**

Specific Field: **Hepatobiliary and Pancreas Surgery**

**Mode of pres.: Poster Exhibition only**  
**ISW 2011 Session PE 390**

**An influence of obesity on pancreaticoduodenectomy**

A. Miyamoto, S. Nakamori, M. Tsujie, M. Yasui, M. Ikenaga, M. Hirao, K. Fujitani, T. Tsujinaka

Osaka National Hospital, Osaka, Japan

**Introduction:** It is still controversial whether obesity influences postoperative complications after gastroenterological surgery. In this study, we investigated an influence of obesity on pancreaticoduodenectomy.



**Material and Methods:** We enrolled in this study thirty-four patients undergoing pancreaticoduodenectomy from July 2007 through March 2009. Body Mass Index (BMI) and Visceral Fat Area (VFA) were used as indicators of obesity. These indicators were measured by body composition analysis equipment InBody 720. We inquired a correlation between intraoperative blood loss, operative time, postoperative complications and BMI, VFA.

**Results:** Six patients were judged obesity by BMI (BMI OB group), and fifteen patients were diagnosed as visceral obesity by VFA (VFA OB group). Median blood loss was 1070 ml in VFA OB group, and it was much more than that of non obesity patients ( $P = 0.049$ ). Also, median operative time was 584 min in VFA OB group, and it was significantly longer than that of non obesity patients ( $P = 0.039$ ). While, median blood loss and operative time of BMI OB group were not different from those of not obese patients. In VFA OB group, pancreatic fistula, delayed gastric emptying and surgical site infection were observed in 3, 3 and 1 cases, respectively. The incidence rates of these complications were not significantly different from those of not obese cases. The result was the same when BMI was used as the indicator.

**Conclusion:** It is suggested that visceral obesity influences intraoperative blood loss and operative time by using VFA as an indicator of obesity. However, it was not clarified in this study whether obesity influences postoperative complications after pancreaticoduodenectomy.

**Abstract ID: 0727**      Specific Field: **Hepatobiliary and Pancreas Surgery**

**Mode of pres.: Poster Exhibition only**  
**ISW 2011 Session PE 391**

#### An example of the pancreatic panniculitis

S. Hosoya [1], Y. Ogawa [2]

[1] Kitasato University, Sagamihara, Japan,

[2] Japan Red Cross Hospital, Sagamihara, Japan

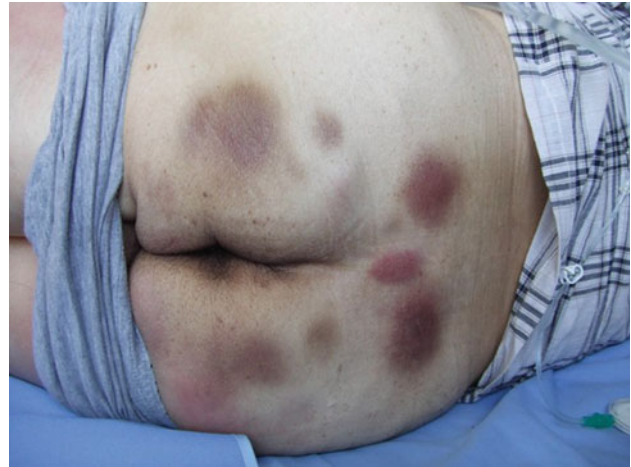**Introduction:** Because we experienced Pancreatic Panniculitis which occurred for pancreas head acinous cell cancer this time, I add it and announce the consideration from literatures.

**Material and Methods:** The case is a 73 years old man X-13-year He started going to hospital by high blood pressure, hyperuricemia. X-4-year He has begun to receive a clinical survey once a year. X-2-year the views were only a gall bladder polyp and liver cysts. X-1-year in December, It was pointed out a tumor of 38 mm to his pancreas head by an abdomen supersonic wave. As a result of detailed inspection, it was diagnosed pancreas head acinous cell cancer. It was judged that he was inoperable for liver metastasis, liver direct permeation, portal vein permeation, circumference lymph node permeation. Chemotherapy using GEM and S-1 was started for him. Three months later, he developed cutitis. It was diagnosed than a biopsy result Pancreatic Panniculitis.

**Results:** It was reported as a subcutaneous fat necrosis with the pancreas disease with Pancreatic Panniculitis (a tuberosity fat necrosis symptom with the pancreas disease under the skin) in 1883 by Chiari It occurs in approximately 2% of whole pancreas disease and appears most commonly on a man 50 years or older. Pancreatitis (65.1%), pancreatic cancer (32.6%) are nominated for a pancreas disease to be complicated with in it. The symptom is often seen as an existence ache-related node of multiple crimson mainly on a leg. By the way, I disintegrate, and denaturing agents may be performed an

expulsion of. Systemic, in the serious case example, an intestinal tract film, marrow, a brain produce a fat necrosis. The laboratory findings accept eosinophilic increase in blood and the rise of the pancreas deviation enzyme. I accept ghost-like cells and calcification by centrilobular fat texture flame by the pathological examination. The treatment is improved by the treatment of the underlying disease.

**Conclusion:** In this case, Pancreatic Panniculitis appeared after a diagnosis of the pancreatic cancer. Pancreatic Panniculitis may appear before the diagnosis of the underlying disease. When I recognized an intractable skin symptom by medical treatment every day, it seems that the close inspection that the dermatome is possible, and took the malignancy of blood and the internal organs into consideration is necessary.



**Figure:** Views of the gluteal skin

**Abstract ID: 0728**      Specific Field: **Hepatobiliary and Pancreas Surgery**

**Mode of pres.: Poster Exhibition only**  
**ISW 2011 Session PE 392**

#### A resectable case of the double cancer of duodenum and pancreas

K. Suzumura, N. Kuroda, Y. Iimuro, Y. Yoshida, J. Fijimoto

Department of Surgery, Hyogo College of Medicine, Hyogo, Japan

**Introduction:** A-67-year-old man was seen at another hospital because of hematemesis and melena. Upper endoscopic examination showed a type 2 tumor in the duodenal bulb. Abdominal CT showed a tumor in the pancreatic tail. The patient was admitted to our hospital with a diagnosis of duodenal carcinoma and pancreatic tail tumor. He underwent a total pancreatectomy. The postoperative course was uneventful. Histologically, the duodenal tumor was moderately differentiated adenocarcinoma and the pancreatic tumor was poorly differentiated adenocarcinoma. These tumors were not continuous in pathological examination. MUC1 found on immunohistological examination showed that the duodenal carcinoma origin was differed from the pancreatic carcinoma. Based on these findings, the definitive diagnosis was synchronous double cancers of the duodenum and pancreas. Since primary double cancers of the duodenum and pancreas are rare, we report on this case with some bibliographical comments.



**Abstract ID: 0729**      Specific Field: **Hepatobiliary and Pancreas Surgery**

**Mode of pres.: Poster Exhibition only**  
**ISW 2011 Session PE 393**

**Peculiarities of the complex intraarterial therapy in severe acute pancreatitis**

S. Chooklin [1], O. Hranat [2]

[1] Medical University, Ukraine, [2] Medical University, Lviv, Ukraine

**Introduction:** Severe acute pancreatitis (SAP) can lead to serious complications and death. One of principal causes of lethality of patients with severe acute pancreatitis is multiorgan dysfunction. Secondary infection of pancreatic necrosis (i.e., infected pancreatic necrosis) is associated with particularly high mortality rates. The improvement of the conventional therapy may decrease the morbidity and mortality rates in patients with SAP. Continuous regional arterial infusion (CRAI) of protease inhibitor and antibiotics were proposed as special therapy for SAP.

**Material and Methods:** 97 patients with severe acute pancreatitis were studied. The patients were divided into two groups: one received the protease inhibitor (aprotinin), antioxidant (quercetin) and the antibiotic (ertapenem, gatifloxacin) by continuous regional arterial infusion (group A—49 patients) during 12–14 days and the other received protease inhibitors, antioxidant, and antibiotics by intravenous infusion (group B—48 patients). Serum levels of IL-6 and IL-10 were measured in patients. Changes of the serum levels of the two cytokines were studied in relation to method of therapy.

**Results:** The combination of quercetin, a protease inhibitor and antibiotics in intraarterially, decreases the frequency of infection, limit the destructive process, reduced the number of surgical interventions and mortality. Continuous arterial infusion is effective in preventing bacterial translocation in acute pancreatitis, improves capillary circulation. After CRAI function of kidneys and liver much more quickly improved, the pulmonary complications decreased. The IL-10/IL-6 ration did not change significantly in the patients with SAP treated by intravenous therapy. The IL-10/IL-6 ration of the patients with SAP was significantly increased after continuous regional arterial infusion.

**Conclusion:** In complex management of acute necrotizing pancreatitis we include intraarterial therapy. It considerably improves function of lungs, liver, kidneys. Combined intraarterial therapy of acute destructive pancreatitis reduces the need for surgical treatment and reduces mortality. Continuous regional arterial infusion in acute pancreatitis inhibits the proinflammatory response and stimulates compensatory anti-inflammatory response.

**Abstract ID: 0730**      Specific Field: **Hepatobiliary and Pancreas Surgery**

**Mode of pres.: Poster Exhibition only**  
**ISW 2011 Session PE 394**

**Pancreatic metastasis of the descending colon cancer treated with disatal pancreatectomy 6 years after EMR was performed**

K. Nakamura, Y. Takahashi, K. Yamashita, H. Katagiri, K. Ishii, Y. Kumamoto, M. Watanabe

Kitasato University, Japan

**Introduction:** We herein report a very rare case of a 72-year-old woman who developed pancreatic metastasis from a primary descending colon cancer that had been curatively removed 6 years ago.

**Material and Methods:** The patient was initially diagnosed as primary colon polyp, which was removed by EMR, and colon cancer with submucosal invasion was pathologically confirmed with horizontal margin positive, and an operative resection was additionally performed. There was no residual cancer cell in the resected colon and lymph nodes tissues. Sixteen months later, right lung nodule with 1.0 cm in size was pointed out and right lobectomy was performed. Pathological diagnosis was metastasis from the initial colon cancer. Chemotherapy with FOLFIRI regimens was performed as postoperative therapy. Three years after the 2nd surgery, pancreatic tumor was detected by computed tomography, which showed obstruction of main pancreatic duct as atypical pancreatic cancer.

**Results:** We performed fine needle aspiration cytology by endoscopic ultrasound for diagnosis of the pancreas tumors, and diagnosed as X. We actually performed distal pancreatectomy without splenectomy, and final pathological finding including several immunostaining was confirmed to be the initial colon cancer metastasis to the tail of pancreas.

**Conclusion:** This case is very rare in terms of the two following 2 points; early stage colon cancer's metastasis and pancreatic metastasis.

**Abstract ID: 0731**      Specific Field: **Hepatobiliary and Pancreas Surgery**

**Mode of pres.: Poster Exhibition only**  
**ISW 2011 Session PE 395**

**Six cases of solid-pseudopapillary neoplasm (SPN) of the pancreas**

Y. Hirose, K. Doi, H. Shirai, F. Konishi

Japanese Red Cross Fukui Hospital, Fukui City, Japan

**Introduction:** Solid-pseudopapillary neoplasm (SPN) of the pancreas have been reported as relatively rare type of neoplasm found mainly in young women. But recently some reports have shown the cases of the male or the elderly.

**Material and Methods:** We examined the clinicopathological characteristics in six cases of pancreatic SPN that were resected in our hospital between 1999 and 2008.

**Results:** Five patients were female, and one was male. The mean age was 40.3(17–71). In one case the tumor was located in the head of the pancreas, the others in the tail. We performed enucleation in one case of the pancreatic head and distal pancreatectomy in other five cases. One patient with liver metastasis have died from its disease, but the others alive. In all surgical specimens NSE stain were performed and all of them showed positive results. The serum level of NSE(

**Conclusion:** We examined the clinicopathological characteristics of the pancreatic SPN. One case was young male, and three cases were over fifty in age. The NSE stain of the resected specimens were positive in all five cases. The serum NSE level was high in three cases preoperatively and it seems to be useful in the diagnosis and treatment of SPN.

**Abstract ID: 0732**      Specific Field: **Hepatobiliary and Pancreas Surgery**

**Mode of pres.: Poster Exhibition only**  
**ISW 2011 Session PE 396**

**Small malignant neuroendocrine tumor (NET) of the pancreas: report of a case**

M. Nakamoto, Y. Inoue, K. Yamaguchi

School of Medicine, University of Occupational and Environmental Health, Kitakyushu, Japan

**Introduction:** Small neuroendocrine tumor (NET) of the pancreas is usually followed up. We experienced a small malignant NET, 14 mm in size, with lymph node metastasis.

**Results:** A 55-year-old woman was admitted with fever and hypochondrial pain, and was diagnosed as calculous acute cholecystitis. Abdominal computed tomography scan (CT) showed gallbladder stones and a small pancreatic head mass, 14-mm in diameter, enhanced in equilibrium phase. Laboratory data showed no significant abnormalities. A T1-W1 weighted MRI showed a mass with low intensity, and T2-W1 weighted also showed with low intensity. Endoscopic retrograde cholangiopancreatography (ERCP) revealed no stenosis of the main pancreatic duct. Endoscopic ultrasound (EUS) showed a hypoechoic mass, 14-mm in diameter, in the head of the pancreas. Endoscopic ultrasound-guided fine needle aspiration (EUS-FNA) was performed, but it revealed no evidence of malignancy. A pylorus-preserving pancreatoduodenectomy (PPPD) was performed under the tentative diagnosis of possible invasive ductal carcinoma of the pancreas. Pathological examination revealed proliferation of atypical cells and these atypical cells were diffusely positive for synaptophysin and chromogranin A (endocrine cell markers) and negative for insulin, glucagon, gastrin, and somatostatin by immunohistochemistry. Although Ki-67 labeling index was 1%, lymph node metastasis was evident. The tumor was diagnosed as well-differentiated endocrine carcinoma according to the WHO classification.

**Conclusion:** We experienced a small well-differentiated endocrine carcinoma of the head of the pancreas, 14 mm in size, with lymph node metastasis.

**Abstract ID: 0733**      Specific Field: **Hepatobiliary and Pancreas Surgery**

**Mode of pres.: Poster Exhibition only**  
**ISW 2011 Session PE 397**

**The effect of erythropoietin on intestinal damage developed secondary to acute pancreatitis**

M. Bozgeyik [1], N. Kahramansoy [1], H. Erkol[1], A. Bozcaarmutlu [2], A. Kukner [3], O. Buyukasik [1]

[1] Abant Izzet Baysal University Medical Faculty General Surgery Department, Bolu, Turkey, [2] Abant Izzet Baysal University, Faculty of Arts & Sciences, Department of Chemistry, Bolu, Turkey, [3] Abant Izzet Baysal University, Faculty of Medicine, Department of Histology and Embryology, Bolu, Turkey

**Introduction:** In acute pancreatitis, damage of intestinal barrier develops and secondary bacterial translocation increases. Because of these reasons, clinical results develops which could be changed up to SIRS, sepsis and MODS. Erythropoietin is a hematopoietic hormone and has pleiotropic effects. It was shown that erythropoietin decreases the damage of ischemia and perfusion, apoptosis and inflammation. In this study, it was aimed to introduce of the erythropoietin's attenuator characteristic on intestinal damage caused by acute pancreatitis.

**Material and Methods:** In our study, 21 Wistar Albino rats were divided into three groups (sham-control-treatment groups) which were 7 rats in each group randomly. Infusion of the 4.5% Na taurocholate was applied slowly in pancreatic duct for purpose of to develop acute pancreatitis. 1000 U/kg/day erythropoietin applied to the rats in treatment

group subcutaneously for three days. All rats in each group were sacrificed and blood and tissue samples were collected at fourth day. Amylase, lipase, CRP were studied in serum whereas glutathione and catalase levels were measured in intestinal homogenate.

**Results:** Between all groups, serum CRP and lipase levels didn't show difference markedly. Amylase levels raised due to acute pancreatitis, however there was no difference between control and treatment group. Leukocyte level in blood didn't change by erythropoietin therapy. Despite glutathione and catalase levels in intestinal homogenate in treatment group were different from control group, these levels were not meaningful. On the histopathologic evaluation, the intensity of pancreatitis and intestinal damage decreased in treatment group and this decrease was statistically meaningful in terms of pancreatic damage.

**Conclusion:** The results of this study showed that pancreatic and intestinal histopathologic changes could be decreased in pancreatitis by using erythropoietin. It is thought that erythropoietin using could be instrumental to decrease morbidity and mortality of the patients with acute pancreatitis. Therefore, more extensive researches could be useful at this subject.

**Abstract ID: 0734**      Specific Field: **Hepatobiliary and Pancreas Surgery**

**Mode of pres.: Poster Exhibition only**  
**ISW 2011 Session PE 398**

**Successful transabdominal & endosonographic ultrasound (TUS/EUS)-guided minimally invasive fibrin glue or histoacryl application for "Hemosuccus pancreaticus" as an unusual cause of upper gastrointestinal (GI) bleeding (initial procedural experiences)**

U. Will [1], F. Fueldner [1], A.-K. Mueller [1], I. Wanzar [1], F. Meyer [2]

[1] Department of Gastroenterology, Municipal Hospital, Gera, Germany, [2] Department of General, Abdominal and Vascular Surgery, University Hospital, Magdeburg, Germany

**Introduction:** Further advances in interventional endoscopy allow increasingly to approach also unusual diagnoses such as "Hemosuccus pancreaticus".

**Material and Methods:** By detailed descriptions on 2 specific cases both with bleeding pseudoaneurysms of the splenic artery leading to "Hemosuccus pancreaticus", (i) feasibility, (ii) good prospects & (iii) outcome of this extraordinary therapeutic approach (including TUS or EUS imaging & guidance for fibrin glue/histoacryl application) of such a rare complication in pancreatitis with pseudocysts are demonstrated.

**Results:** Medical history was significant for recurrent bleedings within the upper GI tract in a 40-year old female & a 37-year old male patient (basic diagnoses, chronic & acute pancreatitis, both with pseudocysts), resp. Repeat upper GI endoscopy excluded ulcer disease but varices due to liver cirrhosis in the 2nd subject with no hints for recent bleeding. In both individuals, TUS plus duplex ultrasonography revealed a pseudoaneurysm adhered to the tail of the pancreas as cause of "Hemosuccus pancreaticus". (1) TUS guidance to apply (20-G needle) repeatedly both 2 ml of fibrin glue & 2 × 2 ml of the mixture of lipiodol/histoacryl & (2) transgastric EUS-guided application of 2 ml of fibrin glue (19-G needle) to the basis of the pseudoaneurysm were used. Control TUS & duplex ultrasonographies (up to 12 & 5 months, resp.) revealed a sufficient exclusion of the pseudoaneurysm in each case but complete & partial preservation

of the splenic artery as well as perfusion of the parenchyma, resp., but no further complications.

**Conclusion:** This is one of the initial reports on the successful control of “Hemosuccus pancreaticus” by a TUS- or EUS- guided transcutaneous fibrin glue & histoacryl application, which can (i) be recommended as a feasible & safe therapeutic tool with a favorable mid-term outcome, (ii) provide sufficient & permanent cessation of the bleeding but preserve the perfusion of the natural vessel, (iii) avoid more invasive approaches such as angiography-guided implantation of a prosthesis & even open surgical intervention.

**Abstract ID: 0735**                      Specific Field: **Hepatobiliary and Pancreas Surgery**

**Mode of pres.: Poster Exhibition only**  
**ISW 2011 Session PE 399**

**The circulating tumor cells in pancreatic cancer: detection and clinical impact**

D. Klos [1], J. Srovnal [2], R. Havlik [1], M. Lovecek [1], A. Benedikova [2], L. Radova [2], M. Hajduch [2], C. Neoral [1]

[1] 1st Department of Surgery, University Hospital and Palacky University, Olomouc, Czech Republic, [2] Laboratory of Experimental Medicine, Faculty of Medicine, Palacky University, Olomouc, Czech Republic

**Introduction:** Pancreatic cancer is one of the most aggressive malignities with the statistically proven upward trend and a very poor prognosis. Assessment of the circulating tumor cells in patients with this highly malignant disease could eliminate burdensome implementation of surgery in patients with systematic dissemination of molecular disease and provide a more precise prognosis.

**Material and Methods:** The study included 70 patients with carcinoma of the pancreas operated on with curative intent. Samples of peripheral and portal blood, bone marrow, peritoneal lavage and of the tumor itself were analyzed by real-time PCR which measured the expression of hTERT (telomerase), EGFR1 (receptor for epidermal growth factor) and CEA (carcinoembryonic antigen). The expression of these markers was correlated with clinicopathological characteristics and survival parameters.

**Results:** Overall, 40 of 70 (57.1%) pancreatic cancer patients died, the overall survival median was 9.5 months. 27 of 70 (38.6%) of patients underwent curative surgery (R0 surgery). Prognostic significance of CTCs was evaluated in the peripheral and portal blood, bone marrow and peritoneal lavage at the time of surgery based on the detection of significantly higher amounts of CEA and/or EGFR and/or hTERT mRNA copies compared to control cohort. We found a statistically significant association between EGFR and hTERT expression levels in the portal blood and clinical stage, where patients with advanced disease have a higher expression of EGFR or hTERT in the portal blood, than the patients with lower clinical stage. We also showed high expression of EGFR and CEA in the peritoneal lavage of patients with advanced metastatic disease, in contrast to patients without the presence of the metastases. CTCs positivity was not related to gender, age, tumor volume and grading.

**Conclusion:** Our study demonstrate, that the presence of CTCs at diagnosis is a negative prognostic factor for shorter overall survival in pancreatic cancer patients. Analysis of CTCs is clinically feasible, reproducible and further studies should demonstrate its applicability in individualization of adjuvant chemotherapy in pancreatic cancer patients and can influence the radical surgery decision.

**Abstract ID: 0736**                      Specific Field: **Hepatobiliary and Pancreas Surgery**

**Mode of pres.: Poster Exhibition only**  
**ISW 2011 Session PE 400**

**Cytokine network in pancreatic cancer: IL-1alpha from cancer cells and HGF from stromal cells oo-operatively enhance the pancreatic cancer angiogenesis**

Y. Matsuo, N. Ochi, S. Koide, H. Takeyama, Y. Okada

Dep. of Gastroenterological Surgery Nagoya City University Graduate School of Medical Sciences, Nagoya, Japan

**Introduction:** Pancreatic cancer is one of the most malignant carcinomas, with a very poor prognosis. The 5-year survival rate of patients with pancreatic cancer who undergo surgery and chemotherapy ranges from 1% to 2%. Since angiogenesis is required for pancreatic cancer to grow and metastasis, it is reasonable to suppose that to elucidate the mechanisms of angiogenesis is one of the best ways to cancer therapy. The aim of this study was to investigate the cooperative role of HGF and IL-1 $\alpha$  in metastatic processes promoted by interactions between pancreatic cancer and stromal cells.

**Material and Methods:** IL-1 $\alpha$  and HGF mRNA and protein were determined by RT-PCR and ELISA. The effect of HGF on metastatic potential was evaluated by proliferation, invasion, and angiogenesis assays using an in vitro system consisting of co-cultured tumor and stromal cells.

**Results:** IL-1 $\alpha$  expression was correlated with metastatic potential, and IL-1 $\alpha$  significantly promoted HGF expression by fibroblasts (P 0.01). HGF not only enhanced the invasiveness and proliferation of pancreatic cancer cells, but also enhanced migration and proliferation of HUVECs. HGF significantly enhanced HUVEC tube formation (P 0.01). Furthermore, the high liver-metastatic pancreatic cancer cell line (BxPC-3), which secretes IL-1 $\alpha$ , significantly enhanced HUVEC tube formation compared to the low liver-metastatic cell line (Capan-2), which does not produce IL-1 $\alpha$  (P 0.01).

**Conclusion:** The present study clearly provides novel insight about cooperative interactions between pancreatic cancer cells, endothelial cells, and fibroblasts with respect to the biological effects of cytokines. We have shown that pancreatic cancer cell-derived IL-1 $\alpha$  increases fibroblast-derived HGF secretion in a paracrine manner, and that enhanced HGF expression promotes cancer cell and HUVEC proliferation, invasion/migration, and tube formation. As tumor cell-dependent angiogenesis was inhibited by regulation of IL-1 $\alpha$ , these data suggest that IL-1 receptor antagonism (IL-1ra), alone or in combination with an anti-HGF antibody, may be of great clinical benefit for patients with various cancers that produce IL-1 $\alpha$ .

**Abstract ID: 0737**                      Specific Field: **Hepatobiliary and Pancreas Surgery**

**Mode of pres.: Poster Exhibition only**  
**ISW 2011 Session PE 401**

**Long term survivors after pancreatectomy for pancreatic adenocarcinoma: a retrospective analysis**

K. Kimura

Osaka City University, Osaka, Japan

**Introduction:** Pancreatic adenocarcinoma is one of the most lethal cancers in western countries as well as Japan. Long term survival after pancreatectomy for pancreatic adenocarcinoma has been rarely

reported. The purpose of this study is to report a series of long term survivors after pancreatectomy for pancreatic adenocarcinoma, and identify markers for determining possible long term survivors.

**Material and Methods:** Among the patients resected at our institution from 1982 to 2010, a total of 163 underwent pancreatic resection for pancreatic adenocarcinoma. The data of patients who survived more than 5 years was compared with those died within 5 years.

**Results:** Univariate prognostic analyses of 5 year survivors revealed that intrapancreatic nerve invasion ( $P = 0.026$ ), residual tumor status (R status; 0.0084), preoperative serum SPan-1 (0.02), preoperative CA19-9 (preCA19-9;  $P = 0.004$ ) were all significantly associated with poor prognosis. Multivariate logistic analysis confirmed that R status (0.0038) and preCA19-9 (0.021) were independent prognostic factors.

**Conclusion:** Our results suggested that preCA19-9 and residual tumor status were important prognostic factors to survive more than 5 years after pancreatectomy for pancreatic adenocarcinoma.

**Abstract ID: 0738**      Specific Field: **Hepatobiliary and Pancreas Surgery**

**Mode of pres.: Poster Exhibition only**  
**ISW 2011 Session PE 402**

**Efficacy of antiviral therapy after liver resection for hepatitis B virus-related hepatocellular carcinoma**

Y. Urata, S. Kubo, S. Takemura, T. Uenishi, S. Kodai, H. Shinkawa, M. Sakae, K. Kaneda

Department of Hepato-Biliary-Pancreatic Surgery, Osaka City University Graduate School of Medicine, Osaka, Japan

**Introduction:** Hepatocellular carcinoma is the sixth most common cancer and the third leading cause of death from the cancer world wide. Chronic infection with hepatitis B virus is one the main cause of HCC. Recently, antiviral therapy with nucleos(t)ide analogues (NAs) including lamivudine (LAM), adefovir dipivoxil (ADV), and entecavir (ETV) is useful for the prevention of the progress to cirrhosis and the development of HCC in patients with chronic hepatitis B. Since we reported that LAM have a potential for prevention of HCC recurrence after curative resection of HCC, several reports concerning the effects of the NAs after treatment of HCC. However, it is still unclear the effects of the NAs on the long-term outcome after curative treatment for HCC in patients with a high viral load. In this retrospective study, we investigated the effects of antiviral therapy with NAs on the long-term outcome after curative treatment for HCC in patients with chronic hepatitis B.

**Material and Methods:** From June 1999 to June 2010, 76 patients whose sera were positive for hepatitis B surface antigen and negative for anti-hepatitis C virus underwent liver resection for HCC at our department. The subjects in this study were reimaging 41 patients with high serum concentration of HBV DNA (4 log 10 copies/ml) prior to diagnosis of HCC. Of the 41 patients, antiviral therapy with NAs had started the diagnosis of HCC (within one month before surgery) in 9 patients and antiviral therapy started after surgery in 19 patients. On the other hand, the control group consisted of the remaining 13 patients.

**Results:** Tumor-free survival rate after surgery was significant higher in the antiviral therapeutic group than in control group ( $P = 0.0025$ ). By multivariate analysis, multiple tumors (risk ratio, 3.841; 95% CI, 1.625–9.078;  $P = 0.0022$ ) was independent risk factor for short tumor-free survival. The cumulative survival rate was significantly higher in the antiviral therapeutic group than in control group ( $P = 0.0048$ ). By multivariate analysis, the absence of the antiviral (risk ratio, 11.396; 95% CI, 1.362–95.33;  $P = 0.0247$ ) was an independent risk factor for a short survival time.

**Conclusion:** We showed the antiviral therapy with NAs is useful for patients who have a high serum concentration of HBV DNA and underwent liver resection for HCC.

**Abstract ID: 0739**      Specific Field: **Stomach/Duodenum**

**Mode of pres.: Video**  
**ISW 2011 Session 32.02**

**Laparoscopic roux en Y gastric bypass (LapRNYGBP) after Nissen fundoplicature and LapRNYGBP as a treatment of gastroesophageal reflux disease (GERD)**

J. Ph. M.m. K. Magema

Centre Hospitalier de Dinant, Dinant, Belgium

**Introduction:** More and more patients with efficient Nissen fundoplicature enter our consultation rooms with the will of treating their obesity. We thus face the feasibility of the procedure and its efficiency on treating GERD.

**Material and Methods:** Our video shows the feasibility of Conversion of Nissen fundoplicature into LapRNYGBP. Key steps of surgical procedure are highlighted. Tree Clinical cases are presented.

**Results:** We then present a review of the literature about the treatment of GERD and Obesity, and about the effect of RNYGBP on Barrett's Esophagus and Intestinal Metaplasia of the cardia in patients with Morbid Obesity.

**Conclusion:** Conclusions are that Nissen fundoplicature can be switched to LapRNYGBP in safe conditions and that the latter is efficient on treating GERD and associated morbidities. Questions remain on the treatment of reflux after LapRNYGBP

**Abstract ID: 0740**      Specific Field: **Stomach/Duodenum**

**Mode of pres.: Video**  
**ISW 2011 Session 32.04**

**Lymph node dissection and indocyanine green fluorescence guided sentinel lymph nodes sampling in the laparoscopy assisted pylorus preserving gastrectomy**

M. Yoshida [1], K. Kubota [1], J. Kuroda [1], K. Ota [1], M. Kobayashi [2], T. Sato [3], Y. Kitagawa [4], M. Kitajima [1]

[1] International University of Health and Welfare Mita Hospital Center for Digestive Diseases, Tokyo, Japan, [2] Department of Surgery, Kochi Medical School, Kochi University, Kochi, Japan, [3] Department of Physiology, Faculty of Medicine, Kochi University, Kochi, Japan, [4] Department of Surgery, Keio University School of Medicine, Tokyo, Japan

**Introduction:** Origin of the infrapyloric artery can be from the right gastroepiploic artery, the gastroduodenal artery and the anterior superior pancreaticoduodenal artery. The lymph node dissection is different according to the origin of the infrapyloric artery.

The ordinal detection system for indocyaninegreen fluorescence is gray scale imaging and requires a dark room. The operation can be interrupted during the observation of the fluorescence. We developed a new device, HyperEye chargecoupled device camera system, for detecting indocyanine green fluorescence. This system can simultaneously detect color and near-infrared rays and can be used under bright light. The operation can be continued, simultaneously, under the guidance of indocyanine green fluorescence.



**Material and Methods:** We would like to present the methods to preserve infrapyloric artery and vein with dissection of infrapyloric lymph nodes. We examined the timing and concentrations of indocyanine green injection.

**Results:** Both dorsal and ventral approaches to the right gastropyloric artery and vein are important to detect the origins of the infrapyloric artery and vein.

Endoscopic injection of 0.5 ml  $\times$  4 of 50  $\mu$ g/ml indocyanine green the day before operation was the best method for the administration of indocyanine green.

**Conclusion:** Movies of laparoscopy-assisted pylorus preserving gastrectomy with indocyanine green fluorescence-guided sentinel nodes sampling using HyperEye chargecoupled device camera system will be presented in this presentation.

#### Abstract ID: 0741 Specific Field: Stomach/Duodenum

**Mode of pres.: Video**  
ISW 2011 Session 32.05

##### Laparoscopic gastrectomy for patients with a history of upper abdominal surgery

S. Tsunoda, H. Okabe, K. Obama, H. Hosogi, E. Tanaka, H. Takagi, Y. Kadokawa, Y. Sakai

Kyoto University, Kyoto, Japan

**Introduction:** Laparoscopic surgery for gastric cancer has been widely accepted in eastern Asia, especially for early disease, and growing number of patients undergo laparoscopic gastrectomy. However, feasibility of laparoscopic gastrectomy for patients who have a history of previous upper abdominal surgery remains unclear.

**Material and Methods:** To investigate short term results of laparoscopic gastrectomy for gastric cancer, we reviewed records from a prospective database of 279 patients who underwent laparoscopic gastrectomy for gastric cancer between May 2005 and December 2010, and identified those who had a history of upper abdominal surgery. Short term results of laparoscopic gastrectomy for those patients were then analyzed.

**Results:** The review showed that 22 patients had a history of previous upper abdominal surgery: 14 patients had a history of previous open upper abdominal surgery (4 distal gastrectomy, 1 partial gastrectomy, 3 cholecystectomy, 1 transabdominal left nephrectomy, 1 distal pancreatectomy, 1 paraaortic lymphadenectomy for cervical cancer, 1 right hemicolectomy, 1 ileocecal resection and 1 partial hepatectomy) and 7 patients had a history of laparoscopic surgery (3 cholecystectomy, 2 gastrojejunostomy combined with staging laparoscopy and 2 right hemicolectomy). The types of laparoscopic gastrectomy was as follows: 4 completion gastrectomy for remnant gastric cancer, 10 distal gastrectomy, 3 proximal gastrectomy, 1 pylorus preserving distal gastrectomy and 4 total gastrectomy. When compared to patients with no history of previous upper abdominal surgery, there was no statistically significant difference in terms of operative time (322 min vs. 302 min), intraoperative blood loss (60 g vs. 70 g), postoperative hospital stay (14 days vs. 12 days), number of lymph node retrieval (42 vs. 46) and rate of open conversion (1/22 vs. 3/257). One case with a history of laparoscopic right hemicolectomy was converted to open surgery due to intraoperative splenic laceration, which was considered irrelevant to previous surgery. With regards to postoperative morbidity, three intraabdominal abscess and one aspiration pneumonia were found, but there was no operation related death.

**Conclusion:** Laparoscopic gastrectomy was feasible for patients who had a history of previous upper abdominal surgery. Our laparoscopic procedure for these patients will be presented.

#### Abstract ID: 0742 Specific Field: Stomach/Duodenum

**Mode of pres.: Free Paper**  
ISW 2011 Session 103.01

##### Multiorgan resection for carcinoma stomach: results from a tertiary care referral center in South India

V. Velayutham, J. Sathyasesan, J. Damodaran, S. Perumal, S. Eswaran, R. Palaniappan, S. Rajagopal

Govt Stanley Medical College Hospital, Chennai, India

**Introduction:** Carcinoma of the stomach invading one or more adjacent organs raises serious concerns over en bloc dissection because en bloc resection has an associated high risk and such advanced carcinoma is frequently associated with incurable factors. Thus, it is important to understand the efficacy of gastrectomy combined with other organ resection and to refine the indications for en bloc dissection. We retrospectively analysed our experience with extended multiorgan resection (EMR) in patients with advanced gastric cancer.

**Material and Methods:** Between January 2005 and May 2010, 125 patients were resected for extended gastric carcinoma macroscopically invading other organs. Various clinicopathologic factors influencing early and late results were evaluated. Survival rates were calculated according to the Kaplan–Meier method. Prognostic factors were evaluated by univariate and multivariate analysis.

**Results:** The majority of patients (85.5%) did receive a R0 curative resection. In 103 (82%) of the 125 presumed T4 cancers, histologic final analysis confirmed invasion. Postoperative morbidity and mortality was 27.7% and 5.3%, respectively. Follow up ranged from 6 months to 65 months Logistic regression identified the number of organs resected, two or greater, to be predictive of complications. Survival was significantly better in R0 versus R1 (32.6% vs. 0%,  $P = 0.001$ ).

**Conclusion:** Patients with locally advanced gastric carcinoma invading adjacent organs can benefit from aggressive surgical treatment with acceptable morbidity and mortality. However, curative resection is mandatory to improve prognosis.

#### Abstract ID: 0743 Specific Field: Stomach/Duodenum

**Mode of pres.: Free Paper**  
ISW 2011 Session 103.02

##### Worse prognosis of pathological N0 gastric cancer with preoperative diagnosis of node-positive gastric cancer

S. Komatsu, D. Ichikawa, E. Otsuji

Division of Digestive Surgery, Department of Surgery, Kyoto Prefectural University of Medicine, Kyoto, Japan

**Introduction:** Patients with pathological N0 (pN0) gastric cancer have sometimes been diagnosed as node-positive gastric cancer. However, little is known about clinical significance of preoperative overdiagnosis in lymph nodal staging. This study was designed to examine the clinicopathological characteristics of gastric cancers which diagnosed as clinically N-positive (cN+) but pathological N0 (pN0).

**Material and Methods:** Between 2002 and 2009, 1271 consecutive patients underwent gastrectomy for gastric cancer. Of these, 498 patients had pN0 gastric cancer. Preoperatively, 46 (9.2%) patients were diagnosed as cN(+)pN0 gastric cancer, and the remaining 452 (90.8%) patients were cN(–)pN0 gastric cancer. The clinicopathological features and prognoses of patients with cN(+)pN0 gastric cancers were compared to those of patients with cN(–)pN0.

**Results:** cN(+)pN0 gastric cancers were significantly associated with advanced type of macroscopic appearance, deeper tumor depth, larger tumor size and a presence of venous and lymphatic invasion. Univariate analysis showed that macroscopic appearance, depth of invasion, tumor size, venous invasion, lymphatic invasion and preoperative lymph node metastasis (cN(–)pN0 vs. cN(+)pN0) were significant prognostic factors. Multivariate analysis demonstrated that preoperative lymphatic diagnosis was an independent prognostic factor.

**Conclusion:** Preoperative nodal diagnosis was found to be an independent prognostic factor in patients with pN0 gastric cancer. Close follow-up and adjuvant therapy should be required for patients with cN(+)pN0 gastric cancer.

#### Abstract ID: 0744 Specific Field: Stomach/Duodenum

**Mode of pres.: Free Paper**  
**ISW 2011 Session 103.03**

##### Identification of risk factors of recurrence in gastric cancer patients who underwent R0 gastrectomy: recurrent mode-specific evaluation using multinomial logistic regression algorithm

E. Bando [1], J. Kondo [1], M. Tokunaga [1], Y. Tanizawa [1], T. Kawamura [1], H. Kanemoto [2], K. Uesaka [2], M. Terashima [1]

[1] Shizuoka Cancer Center, Gastric Surgery Division, Suntogun, Japan, [2] Shizuoka Cancer Center, Gastro-intestinal Surgery Division, Suntogun, Japan

**Introduction:** In gastric cancer, there were many previous reports evaluating the correlation between risk factors and recurrence using logistic regression analysis. However, we can use (binary) logistic regression only if a dependent variable is binary. To identify the risk factors of recurrence to each recurrent site, multinomial logistic regression algorithm, in which categorical independent variables was more than two, was calculated.

**Material and Methods:** To elucidate above analysis, this study enrolled 1798 primary gastric cancer patients, without prior chemotherapy, who underwent R0 gastrectomy (2002–2009). For calculation using polytomous logistic algorithm, sites for the recurrence were subdivided into three Groups: A; No recurrence; B; Dissemination (Peritoneum, Lymph node, Local) and C; Hematogenous (Liver, Lung, Brain, Bone). Nodal involvement and depth invasion was according to New TNM 7th edition.

**Results:** There were 1600 patients (89%) without evident recurrence during follow up, while 123 patients (7%) had disseminated recurrence or 75 patients (4%) had hematogenous relapse. Multinomial logistic regression analysis identified that the independent risk factors for disseminated recurrence (Group B) were pathologic lymph node metastases, [pN2 has 5.3-fold (95% CI; 2.8–9.8) relative risk compared pN0 and 2.5-fold (95% CI; 1.4–4.5) relative risk compared pN1] followed by pathologic depth of tumor invasion [pT3/4 has 4.7-fold (95% CI; 1.8–12.3) relative risk compared pT1 and 3.1-fold (95% CI; 1.5–6.6) relative risk compared pT2] and histologic type [undifferentiated tumors has 1.9-fold (95% CI; 1.2–3.2) relative risk compared tubular carcinoma] while venous invasion was the most valuable factor for hematogenous recurrence (Group B) [v2/3 has 8.7-fold (95% CI; 3.6–19.2) relative risk compared v0 and 1.9-fold (95% CI; 1.1–3.4) relative risk compared v1], following pN [pN2 has 6.5-fold (95% CI; 2.8–15.2) relative risk compared pN0]. Lymphatic invasion, macroscopic type and tumor size had no impact on both recurrent sites.

**Conclusion:** Pathologic lymph node metastases has potential power into both recurrent mode. Multinomial logistic regression analysis may be useful to predict the recurrent sites.

#### Abstract ID: 0745 Specific Field: Stomach/Duodenum

**Mode of pres.: Free Paper**  
**ISW 2011 Session 103.04**

##### Prognostic impact of left gastric artery lymph node metastasis in gastric cancer

H. Zhou, J. Zhang, W. J. Wang, Z. Q. Hu

Department of General Surgery, Changzheng Hospital, Shanghai, China, People's Republic

**Introduction:** Presence of regional lymph node metastasis is an important prognostic factor after curative resection for gastric cancer. There is no doubt that the number of metastatic lymph nodes is an essential factor for accurate staging. However, anatomical location may also have prognostic significance. The aims of this study are to evaluate the prognostic impact of Left Gastric Artery (LGA) lymph node metastasis in gastric cancer.

**Material and Methods:** From our collected database, a total of 942 patients who underwent resection with curative intent for patients with gastric cancer between Jan 2005 and Dec 2009 were selected. Patients were divided into the LGA -positive group ( $n = 187$ ) and the LGA -negative group ( $n = 755$ ) according to LGA lymph node metastasis status. Clinicopathological features, recurrence patterns, and 5-year disease-free survival rates were compared between the two groups.

**Results:** Following curative resection, 5-year disease-free survival rate was 28.3% in the LGA-positive group and 61.2% in the LGA -negative group ( $P < 0.001$ ). Cox regression analysis revealed that poorer differentiation, higher pathologic stage, and presence of LGA lymph node metastasis were independently associated with worse survival. Systemic recurrence rate was significantly higher in the LGA-positive group than in the LGA-negative group (60.4% vs. 26.2%, respectively,  $P < 0.001$ ). Perigastric nodal recurrence showed significant association with presence of LGA lymph node metastasis on multivariate analysis (hazard ratio 9.5; 95% confidence interval 3.7–21.3,  $P < 0.001$ ).

**Conclusion:** Presence of LGA lymph node metastasis should be considered as a predictive factor for high systemic recurrence, and should be treated and followed up with caution for perigastric nodal recurrence.

#### Abstract ID: 0746 Specific Field: Stomach/Duodenum

**Mode of pres.: Free Paper**  
**ISW 2011 Session 103.05**

##### Stage migration effect on survival in gastric cancer surgery with extended lymphadenectomy: the reappraisal of positive lymph node ratio as a proper N-staging

S. H. Kong, S.Y. Oh, H. J. Lee, J. M. Lee, J. J. Cho, W. H. Kim, K. U. Lee, H. K. Yang

Seoul National University College of Medicine, Seoul, Korea, Republic of

**Introduction:** The purpose of this study is to analyze the relationship between the number of examined lymph nodes (NexLN) and survival in gastric cancer and to determine whether the metastatic/examined lymph node ratio (LN ratio) system can compensate for the shortcomings of the UICC/AJCC staging.

**Material and Methods:** Prospective data of 8,949 primary T1–T4a gastric cancer patients who underwent curative surgery were reviewed. The patients were stratified by T-stage and grouped according to NexLN; 1–14 exLN denoted the first group and every subsequent 10 LNs thereafter. Numbers of LN and 5-year survival

rates were analyzed according to NexLN. “The NR-staging system” was generated using 0.2 and 0.5 as the cut-off values of LN ratio and then compared with UICC/AJCC stages

**Results:** The proportion of advanced N-stage increased with NexLN. Survival and the LN ratio were constant regardless of NexLN when combining all N0–N3b patients, however, T2/3 and T4a patients showed an increasing tendency toward survival in N1/2 and N3a as NexLN increased, due mainly to a stage migration effect. The LN ratio system showed better patterns of distribution of the LN stage and survival graph. The power of the differential staging of the LN ratio system was fortified with higher NexLN

**Conclusion:** The relationship between NexLN and survival is probably affected by stage migration in a high-volume gastric cancer center. The LN ratio system could be a better option to compensate for this effect, and the value of the prognosis prediction in this system increases with a higher NexLN.

**Abstract ID: 0747** Specific Field: **Stomach/Duodenum**

**Mode of pres.: Free Paper**  
**ISW 2011 Session 103.06**

**Dose S-1 adjuvant chemotherapy affect the survival and prognosticators of patients after recurrence of gastric cancer?**

T. Aoyama, Y. Takaki, T. Watanabe, H. Tsutomu, O. Takashi, C. Haruhiko, T. Akira

Kanagawa Cancer Center, Yokohama, Japan

**Introduction:** Although the ACTS-GC trial demonstrated that S-1 is effective as adjuvant chemotherapy for the patients who have underwent curative gastrectomy, some patients experience a recurrence of cancer even after curative D2 gastrectomy followed by adjuvant S-1 chemotherapy. The objective of this retrospective study was to clarify the survival and prognosticators of these patients.

**Material and Methods:** Methods: The study selected patients that underwent curative D2 surgery, were diagnosed with stage II, or III, received adjuvant S-1 for more than 4 weeks, and experienced recurrence confirmed by an imaging study.

**Results:** Results: A total of 34 patients were evaluated. The median overall survival (OS) was significantly longer in 26 patients who received chemotherapy than that of 8 who did not (8.5 months versus 2.5 months,  $P = 0.002$ ). Only 1 patient received S-1, 21 received taxanes-containing regimens, and 4 did irinotecan plus cisplatin as the first-line chemotherapy. Uni- and multivariate analyses showed that the histological type was only independent significant prognosticator.

**Conclusion:** Conclusions: The present study revealed that survival after failing the standard adjuvant chemotherapy did not reach the expected 12 months as observed in recent phase III trials for untreated advanced/metastatic gastric cancer. However, the OS of the differentiated type was significantly longer than that of the undifferentiated type (18.4 months versus 6.0 months,  $P = 0.009$ ). Thus, the histological type was a significant prognosticator in patients who experienced recurrence after adjuvant S-1 and thereafter received palliative chemotherapy.

**Abstract ID: 0748** Specific Field: **Stomach/Duodenum**

**Mode of pres.: Free Paper**  
**ISW 2011 Session 103.07**

**Full scale volume-rendering and left lateral position CT improve the diagnosis of the pancreas invasion of gastric cancer**

T. Natsume [1], K. Shuto [1], H. Aoyama [1], H. Kawahira [2], T. Akai [1], M. Mori [1], H. Hayashi [2], H. Matsubara [1]

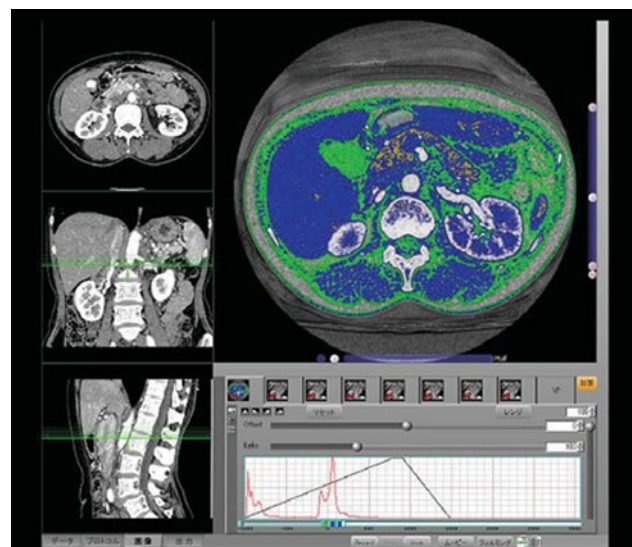
[1] Department of Frontier Surgery, Chiba University Graduate School of Medicine, Chiba, Japan, [2] Research Center for Frontier Medical Engineering, Chiba University, Chiba, Japan

**Introduction:** Stomach exists next to pancreas, so gastric cancer easily invades to pancreas. There are some reports about the diagnosis about pancreas invasion. However, that accuracy of the diagnosis has not ever been satisfied. Multidetector-row Computed Tomography (MDCT) is a useful imaging technique. It can easily provide preoperative images before an operation.

**Material and Methods:** From January 2009 to December 2010, a total of 54 consecutive patients with advanced gastric adenocarcinoma underwent surgery at Chiba University Hospital, Chiba, Japan. Scanning was performed using a 64-row MDCT scanner (Aquilion one, TOSHIBA) with a 0.5 mm slice thickness and a pitch factor of 0.8 after intravenous injection of contrast medium. Images were obtained in the arterial phase with the bolus tracking method at 30 s after the injection and in the portal phase at 80 s. We established full scale volume-rendering views using coloring and shading methods (ZIO workstation). Average CT scale in the arterial phase in stomach and gastric cancer were  $73 \pm 14$ , in pancreas were  $116 \pm 22$ , in fat was  $-100-20$ . We set blue as stomach and gastric cancer, yellow as pancreas, green as fat. Full scale volume-rendering views are established as Figure. If the interstitial segment was not seen and pancreas invasion was doubt, the left lateral position CT was performed. After drinking a foaming agent with 300 cc water, scanning was performed using a 64-row MDCT scanner with a same condition as usual CT. Full scale volume-rendering views are established as same protocol as usual CT.

**Results:** 36 cases were diagnosed without being performed left lateral position CT and all cases were performed operation and confirmed not having invasion to the pancreas. 18 cases were not seen the interstitial segment between stomach and pancreas, and the invasion was doubt. All cases were performed left lateral position CT. 10 cases were seen the interstitial segment and the invasion was not doubt in the left lateral position CT, and all cases were resected gastric cancer. 8 cases were not seen the interstitial segment and the invasion was doubt in the left lateral position CT, 7 cases were confirmed the pancreas invasion and one case were not invasion to the pancreas.

**Conclusion:** Full scale volume-rendering and left lateral position CT improves the diagnosis of the pancreas invasion of gastric cancer.



**Figure 1** Full scale volume-rendering CT



**Abstract ID: 0749** Specific Field: **Stomach/Duodenum****Mode of pres.: Free Paper**  
**ISW 2011 Session 103.08****A significance of surgery in stage IV gastric carcinoma**

K. Aoyagi, K. Kouhiji, M. Miyagi, T. Imaizumi, J. Kizaki, T. Isobe, K. Shirouzu

Kurume University, Kurume, Japan

**Introduction:** Recently, new anticancer drugs are being used for advanced and recurrent gastric cancer in many institutions. Moreover, only N3 or T4N2 factor of Stage IV gastric cancer according to The 13th Edition Japanese Classification of Gastric Carcinoma is excluded from Stage IV factors according to The 14th Edition.**Material and Methods:** We studied on the significance of surgery in 251 cases of Stage IV gastric cancer according to The 14th Edition Japanese Classification of gastric carcinoma who were treated in Kurume University Hospital from 1995 to 2009.**Results:** From various clinicopathological factors considered to be potentially associated with 1 year survival by univariate analysis, macroscopic type, the number of site, P factor, depth, histology, invasion of lymph vessel, proximal margin, N factor (14th Edition), resection, S-1 administration, lymph node dissection, and tumor size were found to differ significantly between 1 year survival case and cases who died within 1 year. A multivariate analysis showed that histology, N factor (14th Edition), and S-1 administration were significance for 1 year survival. On 2 year survival by univariate analysis, P factor, INF, invasion of lymph vessel, N factor (14th Edition), chemotherapy, curability were considered to be potentially associated. A multivariate analysis showed that INF and chemotherapy were significant for 2 year survival. There were no significant differences of prognosis between R0 and R1, 2 in cases who underwent operation without chemotherapy, and between postoperative chemotherapy cases and chemotherapy without surgery cases. Two of 3 cases who survived for more than two years were undergone postoperative chemotherapy in 14 preoperative chemotherapy cases. All 4 cases who survived for 5 years were removed primary site with R2 operation.**Conclusion:** Affection of surgery on the prognosis of Stage IV gastric cancer cases is thought to be limited. However, adjuvant surgery may contribute to the long survival of Stage IV gastric cancer.**Abstract ID: 0750** Specific Field: **Stomach/Duodenum****Mode of pres.: Free Paper**  
**ISW 2011 Session 103.09****Does non-curative gastrectomy improve survival in patients with metastatic gastric cancer?**

P. Puolakkainen, J. Louhimo, A. Kakkola

Department of Surgery, Helsinki University Central Hospital, Helsinki, Finland

**Introduction:** In Western countries a high proportion of gastric cancer patients have too advanced disease to allow curative resection at the time of the diagnosis. The role of non-curative or palliative gastrectomy remains controversial. Our aim was to compare retrospectively patients who have undergone non-curative gastrectomy to the patients with surgical exploration only.**Material and Methods:** Between years 2000 and 2009, 488 patients with gastric adenocarcinoma were treated at the Department of Surgery, Helsinki University Central Hospital. Fifty-five patients had metastatic disease but their symptoms were not severe enough to

require palliative surgery. Thirty-two of them underwent operative exploration (Group A), and 23 non-curative gastrectomy (Group B). All operations were initiated with curative intent.

**Results:** The difference in median survival between groups A and B was insignificant (5.7 months in group A and 10.8 months in group B,  $P = 0.152$ ). However, 33 patients with postoperative chemotherapy had significantly better median survival than the others (14.2 vs. 1.9 months,  $P < 0.001$ ). No significant differences were observed between groups A and B in the rate of late postoperative gastrointestinal obstruction or bleeding.**Conclusion:** Non-curative gastrectomy does not improve survival in patients with metastatic gastric cancer, nor reduces the rate of late occlusions. There is no need for prophylactic palliative gastrectomy in patients with gastric cancer who do not have bleeding or obstruction preoperatively. Among those patients, postoperative chemotherapy seems to improve survival.**Abstract ID: 0751** Specific Field: **Stomach/Duodenum****Mode of pres.: Prize Session FP**  
**ISW 2011 Session 105.02****Evaluation of modified estimation of physiologic ability and surgical stress (mE-PASS) in gastric carcinoma surgery**

Y. Haga [1], Y. Wada [2], H. Takeuchi [3], K. Ikejiri [4]

[1] National Hospital Organization Kumamoto Medical Center, Kumamoto, Japan, [2] National Hospital Organization Himeji Medical Center, Himeji, Japan, [3] National Hospital Organization Iwakuni Clinical Center, Iwakuni, Japan, [4] National Hospital Organization Kyushu Medical Center, Fukuoka, Japan

**Introduction:** We recently modified our prediction scoring system called Estimation of Physiologic Ability and Surgical Stress, and designated this modified version as mE-PASS (Ann Surg, in press). This estimation method uses a scoring system to preoperatively predict the postoperative mortality rates. This study evaluated its usefulness in elective surgery for gastric carcinoma.**Material and Methods:** We investigated seven variables for mE-PASS and the postoperative course in 3,449 patients who underwent elective surgery for gastric carcinoma between August 20, 1987 and April 9, 2007. Comprehensive Risk Score fixed (CRSf) and the predicted in-hospital mortality rates (R) were quantified in each patient. Calibration and discrimination power of R were assessed using the Hosmer-Lemeshow test and area under receiver operating characteristic curve (AUC), respectively. The ratios of observed-to-estimated mortality rates (OE ratio) were quantified as a measure of quality in six hospitals in which more than 200 patients were registered. We divided the study period into three phases; early period from 1987 to 2000, middle period from 2001 to 2004, and late period from 2005 to 2007 in order to investigate any historical change in the quality of care.**Results:** The overall postoperative morbidity and mortality rates were 19.0% and 2.0%, respectively. R demonstrated a good power in calibration (chi-square value, 12.5; degree of freedom 8;  $P = 0.89$ ) as well as discrimination (AUC, 95% confidence interval: 0.80, 0.75–0.85). When the CRSf increased, postoperative morbidity and mortality rates significantly increased (Fig. 1). OE ratios between the hospitals ranged from 0.44 to 1.8 (Table). In total, the OE ratio seems to be improved as time goes by (OE ratio, 95% confidence interval: 1.3, 0.73–2.4 for early period; 1.0, 0.59–1.7 for middle period; 0.65, 0.36–1.2 for the late period).**Conclusion:** mE-PASS may be useful for medical decision-making, providing informed consent and estimating quality of care in elective surgery for gastric carcinoma.



## Quality of care in gastric carcinoma surgery between hospitals

	N	Observed deaths	Estimated deaths	OE ratio (95% CI)
Hospital A	253	7	6	1.0 (0.36–2.8)
Hospital B	242	2	4	0.50 (0.092–2.7)
Hospital C	413	4	9	0.44 (0.14–1.4)
Hospital D	202	5	4	1.3 (0.34–4.6)
Hospital E	397	20	11	1.8 (0.88–3.7)
Hospital F	201	6	5	1.2 (0.37–3.9)

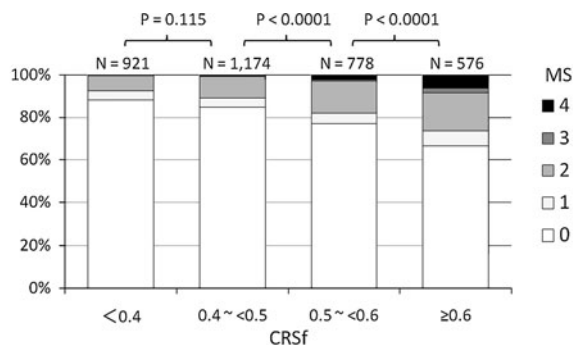


Fig. 1 Relationship between Comprehensive Risk Score fixed (CRSf) and severity of postoperative complications

MS: Morbidity score; 0, no complications; 1, mild complications; 2, moderate complications that were potentially life-threatening unless adequate treatment was performed; 3, severe organ dysfunction that usually required mechanical support; 4, in-hospital deaths due to complications

## Abstract ID: 0752 Specific Field: Stomach/Duodenum

Mode of pres.: Prize Session FP  
ISW 2011 Session 105.03

### Evaluation of postoperative motor function by cine-MRI in patients after laparoscopy-assisted pylorus preserving gastrectomy

K. Koeda, H. Fujiwara, J. Nakajima, T. Chiba, S. Baba, Y. Nishinari, A. Sasaki, G. Wakabayashi

Iwate Medical University, Morioka, Japan

**Introduction:** Laparoscopy-assisted pylorus preserving gastrectomy (LAPPG) has been reported increasingly as a treatment for early gastric cancer located in the middle third of the stomach, because of its less invasiveness and efficacy for preservation of pyloric function. However, there is little information on the advantage of LAPPG in terms of postoperative gastric motor function.

**Material and Methods:** Between April 2006 and October 2010, twenty-nine patients diagnosed preoperatively as T1 N0-stage gastric cancer underwent LAPPG with modified D2 lymphnodes dissections (D1+) in our department. Operative and postoperative outcomes including postoperative complications were investigated. Moreover, postoperative gastric motor functions were assessed by cine magnetic resonance imaging (cine-MRI) for 12 patients after PPG.

**Results:** Mean values were age, 61-year-old; operation time, 251 min; blood loss, 29 g; and postoperative hospital stay, 10 days. No postoperative morbidity including gastric stasis was observed. The stomach of the patients without postprandial symptoms could be

visualized almost as clearly as in healthy volunteers by cine-MRI. Patients with the symptoms exhibited antiperistalsis-like contraction waves of the stomach and reflux of gastric content from the antrum to the upper part of the stomach. The mean gastric emptying rate at 30 min after intake of test meal in patients with postprandial symptoms tended to be less than in those without such symptoms (9.9% vs. 22.1%). Improvement of antiperistalsis-like contraction waves and the symptoms was clearly observed in reexaminations performed for a few years later.

**Conclusion:** With respect to low postoperative morbidity and preserving pyloric function, LAPPG is a suitable treatment for early gastric cancer located in the middle third of the stomach. Furthermore, this study demonstrates that cine-MRI is a useful and non-invasive procedure for evaluation of postoperative gastric motor function in patients after LAPPG.

## Abstract ID: 0753 Specific Field: Stomach/Duodenum

Mode of pres.: Free Paper  
ISW 2011 Session 161.01

### Expression of hepatoma-derived growth factor is associated with progression and prognosis of gastric carcinoma

S. Yamamoto [1], Y. Tomita [2], Y. Doki [3], H. Nakamura [4]

[1] Department of Surgery, Uppsala University Hospital, Uppsala, Sweden, [2] Department of Pathology, Osaka University Graduate School of Medicine, Suita, Osaka, Japan, [3] Department of Gastroenterological Surgery, Osaka University Graduate School of Medicine, Suita, Osaka, Japan, [4] Division of Hepatobiliary and Pancreatic Medicine, Department of Internal Medicine, Hyogo College of Medicine, Nishinomiya, Hyogo, Japan

**Introduction:** Gastric carcinoma is one of the main causes of cancer death worldwide, especially in East and Southeast Asia, including Japan. Hepatoma-derived growth factor (HDGF) is a unique nuclear/growth factor and might play an important role in the development and progression of carcinomas. In fact, there have been several reports showing the correlation of increased HDGF expression and poor prognosis in cancers such as hepatocellular cancer and non-small-cell lung cancer. In the present study, association of HDGF expression with recurrence and prognosis of gastric carcinoma was examined.

**Material and Methods:** HDGF expression in 317 patients with gastric carcinoma (233 males and 84 females) with ages ranging from 26 to 81 years (median, 60 years) was analyzed by immunohistochemistry. Samples with >90% of tumor cells to express positive immunoreactivity similar to or stronger than that in endothelial cells both for nucleus and cytoplasm were regarded as HDGF index level 2, and others as HDGF index level 1.

**Results:** One hundred and eighty-two cases showed level 1 HDGF expression, whereas 135 cases showed level 2 HDGF expression. Patients with level 2 expression showed higher rates of proximal tumor location ( $P < 0.0001$ ), large tumor size ( $P < 0.0001$ ), infiltrative tumor growth ( $P < 0.0001$ ), presence of vascular and lymphatic invasion ( $P < 0.0001$  for both), presence of lymph node metastasis ( $P < 0.0001$ ), deep tumor invasion ( $P < 0.0001$ ), and poorer disease-free and overall survival ( $P < 0.0001$  for both) compared to those with level 1 expression. Multivariate analysis revealed HDGF expression level as an independent prognosticator for disease-free and overall survival.

**Conclusion:** HDGF expression could be used as a new prognosticator for gastric carcinoma. Although further study is still needed to determine the precise role of HDGF in the malignant behavior of gastric carcinoma, HDGF might be a potential target for anticancer drug design.

**Abstract ID: 0754** Specific Field: **Stomach/Duodenum**

**Mode of pres.: Free Paper**  
**ISW 2011 Session 161.02**

**Novel lectin-based glycan profiling and its related phenotypes in advanced gastric cancer (AGC)**

K. Yamashita [1], A. Kuno [2], A. Matsuda [2], Y. Ikehara [2], H. Narimatus [2], M. Watanabe [1]

[1] Kitasato University School of Medicine, Sagami-hara, Japan, [2] AIST (Advanced Industrial Science and Technology), Tsukuba, Japan

**Introduction:** Although various molecular profiling technologies have proposed prediction systems of specific tumor phenotypes such as lymph node metastasis, data is defective by comprehensive profiling of lectin-bound glycan patterns in human cancer tissues.

**Material and Methods:** We examined the lectin-bound glycan profiles of 242 advanced gastric cancer (AGC) with information of cytology testing, which are composed of UICC N0 ( $n = 62$ ), N1 ( $n = 34$ ), N2 ( $n = 44$ ), and N3a/3b ( $n = 50/52$ ), and identified specific lectins highly associated with phenotypes in AGC using lectin microarray.

**Results:** After normalized by the control lectin of SNA, binding signals were calculated. Unique lectins were robustly reduced in diffuse type AGC as compared to intestinal type AGC, involving 10 lectins (LTL, PHA-L, ECA, ConA, GNA, VVA, BPL, RCA120, SBA, and MAL), and the former 6 lectins were strongly associated with CY positivity, either. ECA predicted positive CY the best. Lymph node metastasis was more diversely associated with reduced signals of 24 kinds of lectins as compared to other phenotypes, and ROC curve determined the optimal cut-off value to predict pN0, where ECA, MAL, and PHA-L showed outstanding traits in terms of AUC (0.815, 0.813, and 0.792). Reduced MAL was closely associated with presence of lymph node metastasis, which seemed to represent tumor aggressiveness even in curable AGC with lymph node metastasis.

**Conclusion:** Lectin microarray can be possible for very accurate quantification of glycan profiles of tumor tissues, and its value may be useful to be applied as a biomarker representing specific phenotypes of AGC.

**Abstract ID: 0755** Specific Field: **Stomach/Duodenum**

**Mode of pres.: Free Paper**  
**ISW 2011 Session 161.03**

**Combined expression of metaplastic biomarkers predicts survival of gastric cancer patients**

Y. S. Suh [1], H. J. Lee [1], E. J. Jung [2], H.Y. Yoo [1], K. T. Nam [3], H. K. Yang [1], W. H. Kim [2], J. R. Goldenring [3]

[1] Department of Surgery, Seoul National University College of Medicine, Seoul, Korea, Republic of, [2] Department of Pathology, Seoul National University College of Medicine, Seoul, Korea, Republic of, [3] Nashville VA Medical Center and Epithelial Biology Center and Section of Surgical Sciences, Nashville, Tennessee, USA

**Introduction:** Our previous study revealed that gene expression profiling of gastric metaplastic lineages, such as intestinal metaplasia (IM) or spasmolytic polypeptide-expressing metaplasia (SPEM) can identify useful prognostic markers for gastric cancer (Lee HJ, et al. *Gastroenterology* 2010; 139:213). Herein, we investigated that the combined expression of several molecular markers which were up-regulated in IM or SPEM can predict the survival of gastric cancer patients.

**Material and Methods:** The protein expression of 7 metaplastic markers (MUC13, CDH17, OLFM4, KRT20, LGALS4, MUC5AC,

REG4) which was expressed in ~50% of human gastric cancer tissues were evaluated immunohistochemically with tissue-array comprising 450 gastric cancer patients who underwent gastrectomy at Seoul National University Hospital in 2004. Prognostic impact of proteins which were revealed to be associated with patients' prognosis was analyzed again according to the number of expression of each prognostic marker.

**Results:** MUC13, CDH17, LGALS4, and REG4 were revealed to be prognostic markers in univariate analysis. No expression of these 4 markers was found in 56 cases (14.2%), one in 67 (17.0%), two in 106 (27.0%), three in 101 (25.7%), and four in 63 cases (16.0%), respectively. The expression of 4 markers in gastric cancer tissues were significantly correlated each other ( $P < 0.001$  for each). The number of expression was found to be significantly associated with WHO classification ( $P < 0.001$ ), Lauren classification ( $P < 0.001$ ), and TNM stage ( $P = 0.001$ ). Three-year patients' survivals according to the number of 4 markers were 55.8% in no marker expression group, 68.3% in one, 67.0% in two, 76.3% in three, and 86.7% in all of four markers expression group ( $P = 0.004$ ).

**Conclusion:** The combined expression of metaplastic markers of MUC13, CDH17, LGALS4, and REG4 could be a useful prognostic tool to predict survival of gastric cancer patients.

**Abstract ID: 0756** Specific Field: **Stomach/Duodenum**

**Mode of pres.: Free Paper**  
**ISW 2011 Session 161.04**

**Tissue IL-8 mRNA expression is a possible predominant risk and prognostic marker for gastric cancer with independent correlation to low pepsinogen I/II ratio, and cagA mutation of *H. pylori***

S. Yamada [1], S. Kato [2], T. Matsuhisa [1], L. Makonkawkeyoon [3], M. Yoshida [4], T. Charkrabandhu [3], N. Lertprasertsuk [3], T. Azuma [4]

[1] Chiang Mai University, Thailand, [2] Nippon Meidical School, Tokyo, Japan, [3] Chiang Mai University, Chiang Mai, Thailand, [4] Kobe University School of Medicine, Kobe, Japan

**Introduction:** Regardless of high land such as Northern Thailand, the highest incidence rate of gastric cancer in Thailand is 6.6: 100,000 for male and 4.5:100,000 for female. The Interleukin-8 (IL-8) gene is one of the principal mediators for the inflammatory response. Recently, in vitro study showed the association of the mucosal tissue IL-8 mRNA expression related to *H. pylori*, cagA gene, East Asian genotype in gastric cancer. Low serum pepsinogen I/II ratio less than 3.0 with pepsinogen I level less than 70 ng/dl was referred as an important risk factor found in Japanese gastric cancer with significant relative risk. The cagA, East Asian genotype was commonly related in Japanese gastric cancer. There was no recent in vivo study reported of linkage among these factors. We aim to search for in vivo tissue IL-8 mRNA expression as a risk for advance gastric cancer in correlation with other recent reported factors.

**Material and Methods:** There were consent 186 Thai non-cancer volunteers who underwent endoscopic NBI examination during 2006–2008, and 97 Thais gastric cancer patients who underwent endoscopy and gastric surgery during year 2007–2009. All patients in this studied were in stage II to IVa (locally advanced gastric cancer) who were all resectable cases, and received standard i.v.5-FU based chemotherapy post surgery. Tissue samples were taken before any treatment by endoscopy with 3 points biopsies, and from surgical specimen immediately after gastric resection at lesser curvature and

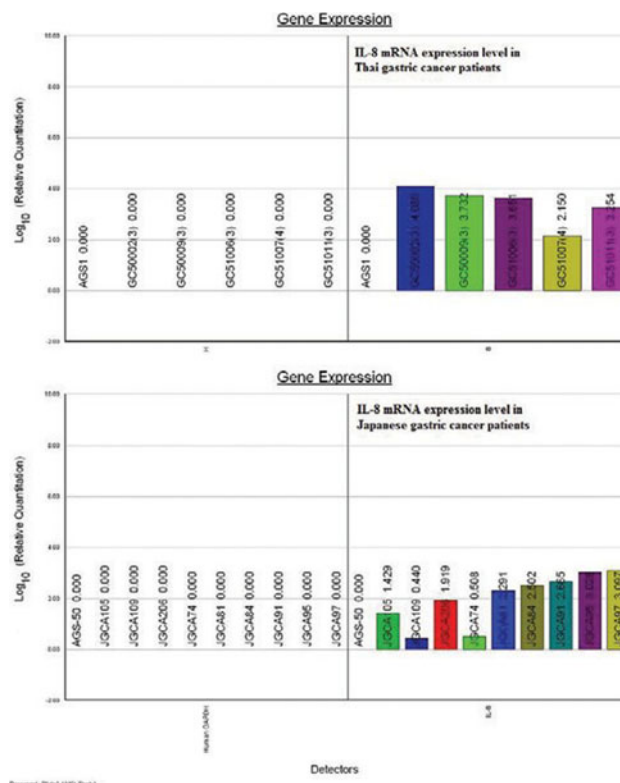
tumor site abovenon-necrotic area. All tissues were preserved at  $-80^{\circ}\text{C}$ . Blood exam and serum separation were done, and preserved at  $-20^{\circ}\text{C}$ . The serum pepsinogen I, II, and IgG Antibody for *H. pylori* were tested by standard ELISA technique. The Histopathology description of tumor, defined histologic type, chronic gastritis, and metaplasia with *H. pylori* detection were done with modified Sydney Score System by 2 pathologists. The serum *H. pylori* IgG antibody for *H. pylori* and pepsinogen I and II were tested. Tissue *H. pylori* DNA extracted from antral position in stomach was examined and genotyped for *cagA* mutation. Tissue mRNA were extracted and converted to cDNA kept in banking for all genetic testing in year 2009–2010. From 5 novel expressions of TNF- $\alpha$ , IL-4, IL-10, IL-8, and COX-2, we measured horizontal expression on 5 same cancers, benign, normal tissue cDNA sample, and AGS cell line as a control. Then, we decided to select for measurement of IL-8 and COX-2 mRNA expression due to regular detection, and much difference on cancer and normal and cell line control samples. We measured Tissue IL-8 mRNA expression conducted by RT-PCR and demonstrated on gel electrophoresis, and then on real time RT-PCR (Relative quantitation technique) by using AGS cell line control in all sets of samples. From 17 Japanese cancer and 12 benign gastric tissue samples, all were tested with same methods as in Thai tissue samples to compare on IL-8 and COX-2 expression. Univariate and multivariate were used for risk study. Standardized T-test was used for quantitative data. Correlation study on pair factors was done in subgroup analysis for defined group of cancer population and non-cancer population. STATA and SPSS 16 were used for statistical analysis and  $P$ -value  $<0.05$  was considered as a statistically significant.

**Results:** There were 71 normal control, 50 peptic ulcers and other benign lesion, 65 chronic gastritis, and 97 cancer cases. Thai male and female cancer incidences were 59.79% (58/97) and 40.21% (39/97), respectively. The *H. pylori* infection prevalence was reported by combined histopathology and *H. pylori* IgG Ab test with 77.12% and 97.44% of sensitivity and specificity, respectively. Among Thai non-cancer volunteers, *H. pylori* prevalence was 64.3%. There were 39.56% negative *cagA* genotyping and 60.44% positive *cagA* genotyping that yields 29.67% of East Asian type, 16.48% of Western, and 14.29% of Mix type. In the followed up case of Thai CAG group who had long term *H. pylori* *cagA* East Asian type infection, no one developed to be cancer. Meanwhile, Thai gastric cancer group had 69.6% of *H. pylori* prevalence, but *cagA* genotype could be found in only 13.21% of cases that yields 11.32% of East Asian and 1.89% of western type. There was a significantly lower PGII/II ratio at means of  $3.3 \pm 1.7$  in cancer patients,  $P = 0.042$ , and in chronic active gastritis (CAG),  $P = 0.002$  when compared to ratio in normal control. The detection rate of IL-8 expression is 77/86(79.38%) in gastric cancer patients. The mean level of IL-8 mRNA expression in Thai cancer group is higher than in non-cancer group,  $P = 0.058$ . The mean level of IL-8 mRNA expression in Thai cancer and Japanese cancer were 9,615.65 ( $\log_{10} = 2.62$ , 95% CI = 2.37–2.87) and 1,490.67 ( $\log_{10} = 2.2$ , 95% CI = 1.78–2.68), respectively. The means IL-8 mRNA expression in non-cancer Thais was 2,262 ( $\log_{10} = 1.49$ , 95% CI = 0.48–1.47). There was higher means IL-8 mRNA expression level in Thias than in Japanese for both cancer and non-cancer cases. In univariate analysis, there were 5 significant factors related gastric cancer risk in Thais, and showed in table 1. For the multivariate analysis application, 3 remaining factors related to gastric cancer risk are male, IL-8 expression level  $>100$ , and PG I/II less than 3.0. There was a significantly lower PGI/II ratio in Japanese than in Thai gastric cancer,  $P = 0.026$ . Serum PGI/II ratio at cut off less than 3.0 and IL-8 mRNA expression  $>100$  or  $\log_{10} >2$  were significantly found in cancer group when compared to non-cancer group,  $P = 0.013$  and  $P < 0.001$ , respectively. In the correlation study, low PGI/II ratio did not associate with CAG severity score in Thais non-cancer cases. However, there was a trend, but not significant convert correlation between IL-8 mRNA expression level and low pepsinogen I/II ratio.

**Conclusion:** In this study, we found that IL-8 cytokine expression was a significant risk and might act as a prognostic marker in gastric cancer. There was an independent correlation with very low PGI/II ratio in gastric cancer as well as in CAG, but not with *H. pylori* infection. The results of IL-8 mRNA expression and pepsinogen I/II ratio in both ethnics reflected to individualized host stomach mucosal defense and nature of cancer. Almost all of Thai cancer cases are diffuse type, while Japanese are commonly found to be intestinal type. Higher level IL-8 mRNA expression in non-cancer Thais comparing with non-cancer Japanese showed difference in mucosal defense of gastric mucosa between the two, while the higher expression matched also the poorer prognosis histopathology cell type. We found that IL-8 mRNA expression was a significant risk with independent correlation to low serum pepsinogen I/II, and *H. pylori* infection in gastric cancer. It is possible to use serum pepsinogen for early gastric cancer detection in low incidence area. There is possibility to use IL-8 mRNA expression as a biomarker for further chemotherapy study in advance gastric cancer.

**Table 1** Univariate analysis result for significant gastric cancer risk factors in Thais

	Relative risk (OR)	95%CI	$P$ -value
Smoking	1.74	1.04–2.90	0.033
Male	2.05	1.30–3.24	0.002
PGI/II $<3$ , PGI $<70$ ng/dl	1.61	0.98–2.63	0.059
Interlukin-8 Raw RQ $>100$	2.59	1.59–4.20	$<0.001$
Interlukin-8 Log $_{10} >2$	2.79	1.69–4.59	$<0.001$



**Figure:** IL-8 mRNA expression level in Thai and Japanese cancer patients



**Abstract ID: 0757** Specific Field: **Stomach/Duodenum**

**Mode of pres.: Free Paper**  
**ISW 2011 Session 161.05**

**Clinical significance of circulating tumor cells in blood from patients with gastric cancer**

Y. Uenosono, T. Arigami, S. Yanagita, H. Arima, M. Hirata, T. Hagihara, S. Ishigami, S. Natsugoe

Kagoshima University School of Medicine, Kagoshima, Japan

**Introduction:** The presence of circulating tumor cells (CTCs) was inspected in blood of patients with various cancers. Early detection of CTCs has the possibility of becoming useful information before beginning of the treatment of the operation or systemic chemotherapy. CellSearch System (CSS) has been developed to identify CTCs in blood, and its utility has been already reported in patients with breast and prostate cancer. The purpose of this study is to assess the clinical impact of CTCs in blood of patients with gastric cancer.

**Material and Methods:** 176 patients with gastric cancer were enrolled in this study. In 123 patients with T1–4 gastric cancer, peripheral blood was collected before gastrectomy. On the other hand, gastrectomy was not performed in the remaining 53 patients with distant metastasis or recurrence. In these 53 patients, peripheral blood was collected before chemotherapy. CTCs was assessed by CSS. CSS was used for the isolation and enumeration of CTCs. The 7.5 ml of 10 ml in tubes were evaluated by the system. The procedure enriches the sample for cells expressing EpCAM with antibody-coated magnetic beads, and it labels the nucleus with the fluorescent nucleic acid dye. Fluorescently labeled monoclonal antibodies specific for leukocytes (CD45-allophycocyan) and epithelial cells (pancytokeratin) are used to distinguish epithelial cells from leukocytes. CTCs were defined as nucleated cells lacking CD45 and expressing cytokeratin.

**Results:** CTCs were detected in 13 patients (11%) with gastrectomy, and 31 patients (59%) with chemotherapy. CTCs in patients with gastrectomy were significantly correlated with depth of tumor invasion, lymph node metastasis, stage, vessel invasion, and lymphatic invasion. The 5-year survival rate was significantly lower in patients with than without CTCs ( $P < 0.0001$ ). Multivariate analysis demonstrated that CTCs was an independent prognostic factor ( $P = 0.0196$ ). In 53 patients with chemotherapy, overall survival rate was significantly lower in patients with than without CTCs ( $P = 0.0236$ ). Median survival time is 211 days in patients with CTCs, and 503 days in patients without CTCs.

**Conclusion:** The evaluation of CTCs in blood may be a useful tool for predicting tumor progression, prognosis, and the effect of chemotherapy in patients with gastric cancer.

**Abstract ID: 0758** Specific Field: **Stomach/Duodenum**

**Mode of pres.: Free Paper**  
**ISW 2011 Session 161.06**

**Prospective, consecutive study for sentinel lymph node mapping in gastric cancer: Hungarian experiences**

D. Tóth, S. Kathy, T. Csobain, Zs. Kincses, J. Plósz, M. Török, I. Kovács

Kenézy Teaching Hospital, Debrecen, Hungary

**Introduction:** Well known the increased perioperative morbidity and mortality with D2 versus D1 lymph node dissection. Forty percent of patients have an unnecessary extended lymph node dissection in cases of R0 resection.

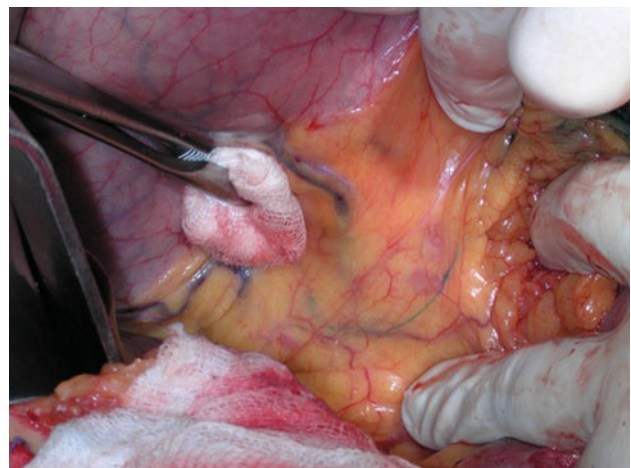
**Material and Methods:** Sentinel lymph node (SLN) mapping was investigated by blue dye method alone for the possibility of less invasive surgery in patients with gastric adenocarcinoma. The subjects were 36 patients who had undergone laparotomy, gastric resection or total gastrectomy with SLN biopsy using patent blue dye and modified extended lymphadenectomy. The mapping procedure and the lymphadenectomy was supervised by the same surgeon.

**Results:** The patients enrolled were 20 females and 16 males. 716 lymph nodes were removed, average 20 lymph nodes per patient were examined. The mean number of blue nodes was 4.4 per patient. In 21/22 cases at least one SLN showed tumor involvement. Sensitivity of SLN mapping was 95.4%, the false negative rate was 4.6% and the specificity was 100%. Negative predictive value was 92.8% and the positive predictive value was 100%. In cases of T1 and T2 tumours the sensitivity was 100%. There was no any side-effect of blue dye mapping.

**Conclusion:** Sentinel lymph node mapping with blue dye alone is a safety procedure and adaptable in the eastern European region with high sensitivity and specificity, especially in cases of T1 and T2 tumours.

**Table** Results of SLN mapping procedure using blue dye only method

Detection rate	35/36 (97.2%)
False negative rate	1/22 (4.6%)
Sensitivity	21/22 (95.4%)
Specificity	13/13 (100%)
Negative predictive value	13/14 (92.8%)
Positive predictive value	21/21 (100%)



**Figure** Sentinel lymph node mapping

**Abstract ID: 0759** Specific Field: **Stomach/Duodenum**

**Mode of pres.: Free Paper**  
**ISW 2011 Session 161.07**

**Perioperative IL6 serum levels may predict postoperative morbidity in gastric cancer patients**

A. M. Szczepanik [1], L. Scislo [2], M. Siedlar [3], A. Galas [4], T. Scully [5], E. Walewska [2], J. Kulig [6]



[1] 1st Department of General and Gastrointestinal Surgery, Jagiellonian University Medical College, Cracow, Poland, [2] Department of Clinical Nursing, Faculty of Health Sciences, Institute of Nursing and Midwifery, Jagiellonian University, Cracow, Poland, [3] Department of Clinical Immunology Polish-American Institute of Pediatrics, Jagiellonian University Medical College, Cracow, Poland, [4] Chair of Epidemiology and Preventive Medicine Jagiellonian University Medical College, Cracow, Poland, [5] Intensive Care Unit Eastbourne District General Hospital, Eastbourne, United Kingdom, [6] Jagiellonian University Medical College, Poland

**Introduction:** Despite the progress in surgical technique and perioperative care, gastrectomy is still a procedure of significant morbidity. Several scoring systems and clinical measures were adopted to predict postoperative complications in gastric cancer patients.

Cytokines, especially IL6, are also known to correlate with operative stress and in some surgical procedures cytokines have been shown to be reliable markers of postoperative morbidity. IL6 is a cytokine which rises very early post surgery. The aim of this study was to assess the IL6 serum levels of gastric cancer patients in the perioperative period and to ascertain its influence on morbidity.

**Material and Methods:** A group of 99 consecutive patients with resectable gastric cancer were enrolled. Mean Age 62.9 and M/F ratio 72/27. Subtotal gastric resection was performed in 22 and total in 77 patients. Cytokine serum levels (IL6, IL10, IL12, IL18, TNF-alpha) were measured preoperatively and in 1, 3 and 7 POD.

**Results:** Complications were recorded in 28 patients (28.3%). Observed mortality rate was 3.03%. The levels IL6 were significantly higher preoperatively ( $P < 0.01$ ) and in 3rd POD ( $P < 0.05$ ) in the "complications" group. Levels of other cytokines did not differ between groups. IL6 serum level  $>288.7$  pg/ml at 1POD in univariate and multivariate Cox proportional hazard model was an independent prognostic factor for overall and infective complications.

**Conclusion:** Postoperative IL6 serum level could be used as a very early prognostic marker. Further investigation of the pathogenesis of high IL6 production and possible strategies of complication preventions are needed.

**Abstract ID: 0760** Specific Field: **Stomach/Duodenum**

**Mode of pres.: Free Paper**  
**ISW 2011 Session 161.08**

**The assessment of feasibility of proximal gastrectomy combined with sentinel node mapping for early gastric cancers.**

S. Kamiya, H. Takeuchi, M. Niihara, T. Nakahara, M. Mukai, Y. Kitagawa

Keio University, Tokyo, Japan

**Introduction:** Recent studies have shown favorable results for identification of sentinel node (SN) in gastric cancer and SN concept is acceptable especially in isolated early gastric cancer, less than 4 cm in size. We have performed minimized gastrectomy with SN mapping actively, and in this study we assessed SNs status and feasibility of proximal gastrectomy (PG) with SN mapping for less invasive and function preserving surgery.

**Material and Methods:** From 1999 to 2009, 48 patients suffering from cT1N0 gastric cancer who had undergone PG with SN mapping during surgery were enrolled in this study. 99 m Technetium tin colloid (RI) and indocyanine green or isosulfan blue (dye) were injected endoscopically into four quadrants of the submucosa surrounding the tumor. During surgery, SN labeled with dye and/or RI was detected by visual contact and gamma probe, and the presence of

SN metastasis was judged by intraoperative histopathological examination. And to look for a reasonable surgical procedure in PG with SN mapping, the cases were classified with three groups retrospectively, 9 were in laparoscopy assisted esophagogastric anastomosis (Lap-EG) group, 14 were in laparotomy esophagogastric anastomosis (Open-EG) group and 25 were in jejunum interposition (IP) group, and we investigated the amount of surgical bleeding, operation time, degree of body weight loss and so on.

**Results:** Histopathological examination by hematoxylin and eosin staining revealed lymph node metastasis in 2 of 48 patients, and one had only SN metastasis and another had SN and non SN metastasis. In this study, conventional lymphadenectomy was added to SN biopsy, so that the metastatic lymph nodes were removed at the same time. Accordingly, the SN detection rate, sensitivity, negative predictive value and accuracy were all 100%. The mean number of detected SNs was 4.6 per patient, and there were no significant differences between three groups. The EG group, especially Lap-EG group, was more preferable than IP group in the aspect of the surgical bleeding, postoperative hospital days and keeping up the body weight. And no significant differences were found in the postoperative status of the remnant stomach endoscopically.

**Conclusion:** This study suggested that the laparoscopy assisted PG with SN mapping is feasible and comparable to the other procedures for function preserving minimized surgery.

**Abstract ID: 0761** Specific Field: **Stomach/Duodenum**

**Mode of pres.: Free Paper**  
**ISW 2011 Session 181.01**

**Laparoscopy-assisted gastrectomy in patients with previous endoscopic resection for early gastric cancer**

N. Hiki, S. Nunobe, S. Tanimura, T. Sano, T. Yamaguchi, X. Jiang  
Cancer Institute Hospital, Tokyo, Japan

**Introduction:** Some patients undergoing endoscopic resection for early gastric cancer need to receive further surgical treatment for the aim of curability. However, the influence of endoscopic resection on the subsequent laparoscopy-assisted gastrectomy (LAG) remains unclear. Methods: Seven hundred and eleven patients who underwent LAG were retrospectively analyzed. Of them, 111 patients experienced previous endoscopic resection (ER group) and the other 600 patients had no history of endoscopic resection (NER group). Patient characteristics, operative and postoperative outcomes were compared between the two groups. Risk factors associated with postoperative complications were analyzed.

**Material and Methods:** Seven hundred and eleven patients who underwent LAG were retrospectively analyzed. Of them, 111 patients experienced previous endoscopic resection (ER group) and the other 600 patients had no history of endoscopic resection (NER group). Patient characteristics, operative and postoperative outcomes were compared between the two groups. Risk factors associated with postoperative complications were analyzed.

**Results:** There were no significant differences in operation time ( $230 \pm 61$  vs.  $229 \pm 52$  min,  $P = 0.876$ ) and estimated blood loss ( $55 \pm 85$  vs.  $56 \pm 110$  ml,  $P = 0.881$ ) between ER and NER. Compared to NER, ER had less number of dissected lymph nodes, and less percentage of celiac branch of vagus nerve preservation especially in patients who had LAG within two months after endoscopic resection. Sixteen patients (14.4%) experienced early postoperative complications in ER, which was comparable to NER (10.8%,  $P = 0.275$ ). Univariate analyses showed that BMI and preoperative comorbidity affected postoperative complications.

Furthermore, multivariate analysis identified BMI (24) as an independent risk factor associated with postoperative complications (odds ratio [OR] 1.898, 95% confidence interval [95% CI] 1.172–3.072,  $P = 0.009$ ). Previous endoscopic resection was not a risk factor associated with postoperative complications.

**Conclusion:** LAG can be performed safely even after endoscopic resection. Endoscopic resection might increase the difficulty of subsequent LAG procedure including lymph node dissection and celiac branch of vagus nerve preservation; however, endoscopic resection has little influence on the early postoperative outcome.

**Abstract ID: 0762** Specific Field: **Stomach/Duodenum**

**Mode of pres.: Free Paper**  
**ISW 2011 Session 181.02**

### Suprapancreatic lymph node dissection in laparoscopic gastrectomy for gastric cancer

T. Kawabata, K. Inaba, Y. Ishida, K. Taniguchi, J. Isogaki, S. Sato, S. Kanaya, I. Uyama

Fujita Health University, Toyoake, Aichi, Japan

**Introduction:** Development of the high definition laparoscope enabled to visualize minute anatomical structure including the outmost layer surrounding the autonomic nerves along the common hepatic artery and splenic artery, which are the marks of the secure and precise lymph node dissection. For the purpose of performing meticulous suprapancreatic nodal dissection in laparoscopic gastrectomy, we developed a novel maneuver as “medial approach”. We present our surgical approach for suprapancreatic lymph node dissection using high definition video imaging system.

**Material and Methods:** The ventral surfaces of the right and left sides of celiac plexus are widely dissected and the left gastric artery is divided. By this step, the stations no. 8 and 11p lymph nodes are sufficiently mobilized. Over the appropriate tension to the ventral side, the stations no.12a and 8 lymph nodes are fully retrieved. Finally, the dorsal area of the station no. 11p lymph node is widely dissected.

**Results:** Magnified view of the high definition laparoscope and “medial approach” enabled to visualize the outmost layer between the target lymph nodes and the autonomic nerve surrounding the arteries. We accomplished precise lymph node dissection along this layer.

**Conclusion:** The combination of the clear and magnified surgical view and the “medial approach” are helpful to accomplish accurate suprapancreatic lymph node dissection in gastric cancer treatment.

**Abstract ID: 0763** Specific Field: **Stomach/Duodenum**

**Mode of pres.: Free Paper**  
**ISW 2011 Session 181.03**

### Totally laparoscopic reconstruction for gastrectomy

T. Tokuhara, E. Nomura, N. Tanigawa

Osaka Medical College, Osaka, Japan

**Introduction:** For reconstruction following laparoscopic distal gastrectomy (LDG), the Billroth-(B-)andRoux-en-Y (RY) methods, have been employed to perform totally laparoscopic surgery that does not require minor laparotomy since 2004. On the other hand, we designed a reconstructive procedure in which totally laparoscopic intracorporeal anastomosis is performed in accordance with the delta method to achieve a favorable esthetic result low-level invasiveness,

even when performing laparoscopic pylorus-preserving (LPpG) and segmental gastrectomy (LSG). We assessed the safety and feasibility of totally laparoscopic reconstruction during LDG, LPpG, and LSG for gastric cancer.

**Material and Methods:** For reconstruction following LDG, the Billroth-(B) and Roux-en-Y (RY) methods, have been employed to perform totally laparoscopic surgery that does not require minor laparotomy since 2004. On the other hand, we designed a reconstructive procedure in which totally laparoscopic intracorporeal anastomosis is performed in accordance with the delta method to achieve a favorable esthetic result and low-level invasiveness, even when performing LPpG and LSG.

**Results:** Out of 666 laparoscopic gastrectomies performed, 251 (38%) of patients underwent totally LDG (B:164 RY:87). Complications included anastomotic leakage in 4 (2.4%), stenosis in 1 (0.6%) in the B group, and anastomotic leakage in 2 (2.3%), stasis in 2 (2.3%) in the RY group. Since 2008, 42 patients have undergone LPpG and LSG (LPpG:19, LSG:23). Stenosis occurred in 1 (5.3%) in the LPpG group, and anastomotic leakage was encountered in 1 (4.3%) in the LSG group.

**Conclusion:** In our experience, totally laparoscopic reconstruction is safe and feasible. Observed advantages of this technique of this procedure include improved cosmetic result and early recovery after surgery.

**Abstract ID: 0764** Specific Field: **Stomach/Duodenum**

**Mode of pres.: Free Paper**  
**ISW 2011 Session 181.04**

### Laparoscopic trans-hiatal extended gastrectomy for type II, III esophago-gastric junction cancer: a preliminary report of 30 cases

W. H. Tong [1], Q. Wang [2]

[1] The First Hospital of Jilin University, China, People’s Republic,  
[2] The First Hospital of Jilin University, Changchun, China, People’s Republic

**Introduction:** The laparoscopic operation for esophagogastric junction cancers is difficult, some surgeons have tried for them, we want to explore the feasibility and safety of laparoscopic extended gastrectomy through the trans-hiatal approach in patients with esophagogastric junction cancer.

**Material and Methods:** From Feb 2008 to Dec 2010, 30 cases with Siewert type II or III esophagogastric junction cancer underwent laparoscopic trans-hiatal extended gastrectomy at the first hospital of Jilin university. We used three methods for esophagojejunostomy, using circular stapler and linear stapler (overlap method and functional end to end anastomosis method FEEA). Clinical data were analyzed retrospectively.

**Results:** Esophagogastric junction cancer was Siewert type II in 9 patients and Siewert type III in 21. We performed total gastrectomy for all cases. There were 30 D2 lymph node excisions and 3 palliative resections. 28 patients underwent laparoscopic extended gastrectomy successfully, with 2 convention to open operations. A safe anastomosis between inferior pulmonary vein and pulmonary hilum was achieved in the majority of patients. We use modified function side-to-side esophagojejunal anastomosis method and end-to-end esophagojejunal anastomosis method to finish alimentary reconstruction. The mean operative time was  $(235 \pm 125.5)$  min and the mean estimated blood loss was  $(59.6 \pm 23.1)$  ml. There were no postoperative mortalities or anastomotic leakage/stenosis. No reoperations were required. There were 3 patients developed pulmonary infection.

**Conclusion:** Laparoscopic transhiatal extended gastrectomy is feasible and safe for patients with esophago-gastric junction cancer.

**Abstract ID: 0765** Specific Field: **Stomach/Duodenum**

**Mode of pres.: Free Paper**  
**ISW 2011 Session 181.05**

**The knack and the early postoperative outcomes of an intracorporeal esophagojejunostomy after laparoscopic total gastrectomy (overlap method)**

K. Ishikawa, Y. Ishida, K. Inaba, K. Taniguchi, J. Isogaki, S. Sato, S. Kanaya, I. Uyama

Fujita Health University, Toyoake, Aichi, Japan

**Introduction:** Although laparoscopic distal gastrectomy has been used extensively for treatment of gastric cancer, laparoscopic total gastrectomy for gastric cancer is still uncommon. One of the reasons is the technical difficulty of performing the esophagojejunostomy laparoscopically. To simplify the anastomotic procedure of esophagojejunostomy after laparoscopic total gastrectomy, we previously performed intracorporeal esophagojejunostomy by functional end-to-end anastomosis using an endoscopic linear stapler. In this method, however, extensive mobilization of the jejunal limb is necessary to reduce tension at the anastomotic site. So we developed an intracorporeal end-to-side anastomosis for the esophagojejunostomy using an endoscopic linear stapler. Briefly, in this method, end-to-side anastomosis alleviates tension at the esophagojejunal anastomotic site. In addition, the difficulty of closing the enterotomy with the linear stapler has been eased by combining an intracorporeal interrupted hand-sewn technique with extracorporeal Roeder's knots. We describe here our new surgical procedure for intracorporeal esophagojejunostomy after laparoscopic total gastrectomy using a linear stapler. We named the procedure the "overlap method" and present the patients' postoperative courses.

**Material and Methods:** Between July 2004 and March 2009, we performed 53 consecutive laparoscopic total gastrectomies with Roux-en-Y reconstruction, using the overlap method of intracorporeal esophagojejunostomy, at Fujita Health University Hospital, Toyoake, Japan. All operations were performed by one surgeon.

**Results:** Forty patients were men and 13 patients were women. These patients had a median age of 59.4 years (range 30 to 82 years) and a body mass index of 22.0 kg/m<sup>2</sup> (range 15.0 to 32.4 kg/m<sup>2</sup>). Neoadjuvant chemotherapy was administered in 15 patients. No procedures were converted to open or other laparoscopic anastomosis techniques. The mean operative time was 373.4 ± 105.0 min (range 215 to 663 min), and the estimated blood loss was 146.5 ± 325.3 g (7 to 2,267 g). The mean hospital stay of patients with no morbidity was 14.4 days (range 10 to 33 days).

**Conclusion:** The device and the technique of Overlap Method procedures is displayed with the video, and reported the early postoperative outcomes.

**Abstract ID: 0766** Specific Field: **Stomach/Duodenum**

**Mode of pres.: Free Paper**  
**ISW 2011 Session 181.06**

**Intra-abdominal infectious complications following laparoscopy assisted gastrectomy**

M. Tokunaga, Y. Tanizawa, E. Bando, T. Kawamura, Y. Kinugasa, H. Kanemto, K. Uesaka, M. Terashima

Shizuoka Cancer Center, Shizuoka, Japan

**Introduction:** Increasingly, laparoscopy assisted gastrectomy (LAG) is performed in patients with early gastric cancer. Although the incidence of postoperative morbidity following LAG has been reported before, the severity was rarely investigated due in part to the absence of appropriate criteria. The aim of the present study is to clarify the incidence and severity of postoperative morbidity following LAG by using Clavien-Dindo (CD) classification.

**Material and Methods:** Consecutive 151 patients who underwent LAG at Shizuoka Cancer Center between September 2002 and December 2010 were included in this study. The incidence and severity of each complication were investigated by using CD classification.

**Results:** There were 95 male and 56 female patients with median age of 61 years. Median operation time, intra-operative bleeding, and duration of post-operative hospital stay were 250 min, 48 ml, and 9 days, respectively. Of 151 patients, 13 (8.6%) patients developed grade II or more intra-abdominal complications. It was grade II in four patients, and grade IIIa complication was found in six patients. More severe, grade IIIb and grade IVa complications were observed in one and two patients, respectively. Grade IVb and grade V were not observed.

**Conclusion:** The present study represents that the incidence of postoperative intra-abdominal complication following LAG was 8.6%. By the use of CD classification, we could appropriately evaluate the severity as well as the incidence of postoperative complications. Widespread use of CD classification helps assure the quality of surgery, and intergroup and international comparison of early surgical outcome can be performed effectively.

**Abstract ID: 0767** Specific Field: **Stomach/Duodenum**

**Mode of pres.: Free Paper**  
**ISW 2011 Session 181.07**

**Two-ports laparoscopic distal gastrectomy for gastric cancer**

T. Kosaka [1], C. Kunisaki [1], S. Hasegawa [1], T. Oshima [1], S. Fujii [1], H. Makino [2], H. Akiyama [2], I. Endo [2]

[1] Department of Surgery, GastrointestinalCtr., Yokohama City University, Yokohama, Japan, [2] Department Gastrointestinal Surg. Grad. Sch. Med, Yokohama City University, Yokohama, Japan

**Introduction:** Laparoscopic distal gastrectomy (LDG) seems to be accepted as the approach for the treatment of early gastric cancer in many institutions. Single Incision Laparoscopic Surgery (SILS) has the potential to reduce postoperative port-site complications as well as improving cosmesis. In this study, we evaluated the feasibility of Two-ports (SILS port + 1 port) laparoscopic distal gastrectomy (TP-LDG) for early gastric cancer patients.

**Material and Methods:** TP-LDG was performed in six early gastric cancer patients in our hospital. Surgical outcomes of TP-LDG were compared with those of 8 patients received a conventional laparoscopy-assisted distal gastrectomy (5 ports and 5 cm skin incision). All operations were carried out by a same surgeon. Access was gained via an open umbilical incision. SILSPort (Covidien Japan) inserted in this incision. A 12 mm laparoscopic port inserted at the right lateral abdomen where drainage tube was introduced at the end of surgery. Distal gastrectomy, typical lymphnode dissection and Billroth-I reconstruction (delta-shaped anastomosis) were performed with the use of vessel sealing system, Roticulator instruments and linear stapler.

**Results:** The Median operation time was 299.2 ± 17.6 min in TP-LDG group and 204.5 ± 26.7 min in conventional LADG group ( $P < 0.001$ ). There was no significant difference in surgical outcomes (intraoperative blood loss, number of dissected lymphnodes,



postoperative peak of CRP and WBC, morbidity and hospital stay) between TP-LDG group and conventional LADG group.

**Conclusion:** The use of TP-LDG appears to be a feasible and safe technique for the treatment of early gastric cancer. Further studies are warranted to fully investigate advantages of this new technique in a large number of patients.

**Abstract ID: 0768** Specific Field: **Stomach/Duodenum**

**Mode of pres.: Free Paper**  
**ISW 2011 Session 181.08**

### One step redo bariatric surgery

P. Chiotasso

CHU Purpan, Toulouse, France

**Introduction:** Usually, redo bariatric surgery is performed in 2 step in order to avoid an increased risk of postoperative morbidity and particularly the risk of gastric fistulae after laparoscopy. The purpose of the study was to evaluate the risk of postoperative morbidity after a one step redo bariatric surgery done by laparotomy.

**Material and Methods:** All consecutive patients having had a redo bariatric surgery between January 2006 and December 2010, were retrospectively reviewed. There were 32 cases. The mean age was 44.3 years (22–63), there were 29 females and 3 males. The first bariatric surgery was a band in 27 cases, vertical banded gastroplasty in 4 cases, a sleeve gastrectomy in 1 case. In the second procedure, all the bands were removed, 11 had a VBG, 20 a gastric bypass, 1 no procedure. In all cases, we avoid a transection-suture near the his angle.

**Results:** No patient presented a gastric fistulae during the postoperative period and the late follow-up. There were no other major postoperative complication except an early anastomotic gastrojejunal bleeding ulcer.

**Conclusion:** Doing a redo bariatric surgery through a laparotomy is feasible in a one step procedure without a high risk of gastric fistulae or major postoperative complications.

**Abstract ID: 0769** Specific Field: **Stomach/Duodenum**

**Mode of pres.: Free Paper**  
**ISW 2011 Session 181.09**

### Effect of body mass index on the signal amplitude of magnetogastrogram

C. B. Obioha [1], J. Erickson [1], E. Chung [1], A. Bradshaw [1], W. Richards [2]

[1] Vanderbilt University, Nashville, USA, [2] University of South Alabama, Mobile, USA

**Introduction:** Some gastric disorders affect spatiotemporal parameters of the gastric slow wave. The electrogastrogram (EGG) evaluates electrical potential to determine these temporal parameters but are limited by volume conduction properties of the abdominal wall. The magnetogastrogram (MGG) evaluates the gastric magnetic field activity and are not affected as much by volume conductor properties of abdominal wall. However, MGG degrades in response to the distance from signal source and effect of BMI on MGG has not been reported. We hypothesize that increased BMI would have less effect on MGG than EGG recordings.

**Material and Methods:** We simultaneously recorded gastric slow wave signals with mucosal electrodes, multichannel MGG and EGG

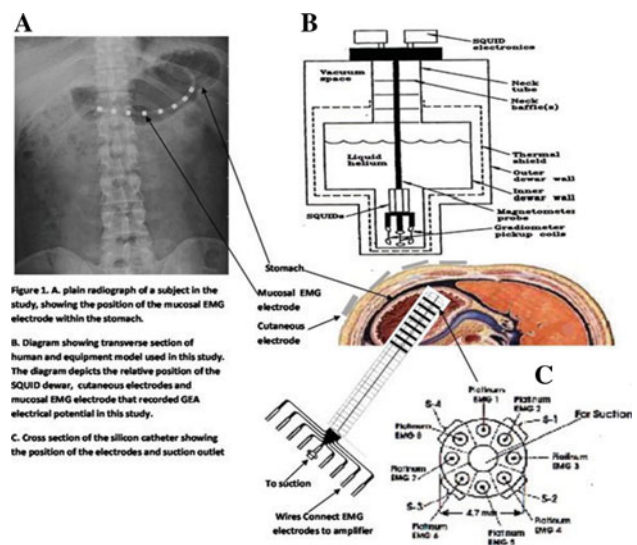
while fasting, for 30 min and 1 h after a test meal. Data was recorded from representative pools of humans with different BMI (normal,  $n = 12$ ; overweight,  $n = 8$ ; obese,  $n = 8$ ). Magnetic signals were subjected to second order blind identification (SOBI) to isolated MGG component. Dominant frequencies and amplitude of recorded signals were obtained from FFT spectral analysis for comparison.

**Results:** Mucosal gastric slow wave activity was recorded in 19/25; but 15/19 subjects (78%) recorded simultaneous signals due to signal detection failures with EGG. slow wave amplitude from mucosal recording detected significant increase in amplitude from  $1.3 \pm 0.3$  mV preprandially to  $3.9 \pm 0.6$  mV postprandially ( $P = 0.001$ ); which was not demonstrated in MGG and EGG recordings. EGG amplitude increased from  $56.1 \pm 9.3 \mu\text{V}$  to  $60.3 \pm 8.5 \mu\text{V}$  ( $P = 0.356$ ); and MGG from  $1.6 \pm 0.3$  pT to  $1.7 \pm 0.3$  pT ( $P = 0.679$ ). The differences in mean gastric slow wave amplitude between the BMI categories were not statistically significant.

**Conclusion:** MGG failed to detect change from pre to post-prandial amplitude, but had similar outcome with mucosal signals in other statistical comparisons. EGG on the other was profoundly attenuated by increase in abdominal wall girth and BMI.

**Table** Experiment data

	N	Minimum	Minimum	Mean	Std. Error	Std. Deviation
BMI	25	18.0	61.3	29.19	1.84	9.21
WC (inch)	17	27.5	53.5	35.71	1.41	5.82
EMG_pre (mV)	19	0.00	5.78	1.38	0.32	1.45
MGG_pre (pT)	18	0.26	5.16	1.59	0.27	1.15
EGG_pre (mV)	19	0.00	0.1373	0.0562	0.0093	0.0403
EMG_post (mV)	19	0.76	9.11	3.90	0.60	2.62
MGG_post (pT)	18	0.38	5.22	1.69	0.31	1.31
EGG_post (mV)	19	0.00	0.1157	0.0603	0.0085	0.0368



**Figure:** Simultaneous recording of gastric slow wave signals



**Abstract ID: 0770** Specific Field: **Stomach/Duodenum**

**Mode of pres.: Poster Discussion**  
**ISW 2011 Session PW 11.01**

**Laparoscopic partial duodenectomy and duodenojejunostomy for gastrointestinal stromal tumor of the duodenum**

H. Narasaki, T. Shichinohe, E. Tanaka, J. Matsumoto, K. Kato, T. Tsuchikawa, S. Hirano, S. Kondo

Hokkaido University Graduate School of Medicine, Sapporo, Japan

**Introduction:** Gastrointestinal stromal tumors (GIST) are the most frequent mesenchymal tumors of the gastrointestinal tract. Only 3–5% of GIST is localized in the duodenum. Surgical resection is treatment of choice if the tumor can be completely resected. Partial duodenectomy could be an appropriate procedure for GIST resection, and pancreatoduodenectomy could be too much invasive procedure. Duodenal resection by using laparoscopic technique is not fully established. In this presentation, we show the details of operative procedure of laparoscopic partial duodenectomy and intracorporeal duodenojejunostomy for gastrointestinal stromal tumor of the duodenum.

**Material and Methods:** Forty five year-old male was admitted to our hospital because of surgical extirpation of tumors in both chest wall and 4th portion of the duodenum. He was also diagnosed as von Recklinghausen disease and the sarcoma in his right chest wall which was 12 cm in size. The chest wall tumor was resected first, and 11 days after resection of the sarcoma, we performed laparoscopic partial duodenectomy and intracorporeal duodenojejunostomy for GIST. In this operation, we used 5 ports (three of 12 mm diameter and two of 5 mm diameter). First port was inserted in the umbilicus, next two ports in the left upper quadrant and last two in the right upper quadrant. The tumor was located in just oral side from the ligament of Treitz. The duodenum was mobilized and cut by the linear stapler at the level of the left edge of SMA, and the jejunum was cut at about 10 cm anal side from the ligament of Treitz. Intracorporeal duodenojejunostomy was performed in the manner of “functional end to end anastomosis”.

**Results:** The operation time was 214 min, and the operative blood loss was 25 ml. Post-operative course was uneventful. He discharged on the eleventh day after second operation. On pathological examination, the surgical margin is negative and mitotic rate is low (MIB-1 index <5%).

**Conclusion:** Laparoscopic partial duodenectomy and intracorporeal duodenojejunostomy is the minimally invasive procedure and could be applicable to GIST in the 3rd and 4th portion of the duodenum.

**Abstract ID: 0771** Specific Field: **Stomach/Duodenum**

**Mode of pres.: Poster Discussion**  
**ISW 2011 Session PW 11.02**

**Surgery for gastrointestinal stromal tumors of the duodenum: 3 case report, different choices of surgical procedure**

A. Kurita, E. Kanehira, K. Miyauchi

Ageo Central General Hospital, Ageo-Shi, Japan

**Introduction:** Duodenal gastrointestinal tumors (GISTs) are uncommon and relatively small subset of GISTs. Optimal surgical procedure for duodenal GISTs has not been well defined.

**Material and Methods:** Three patients underwent surgery for non-metastatic GIST of the duodenum in our institution since April 2009 to December 2010. One patient underwent laparoscopic local gastroduodenectomy. One patient underwent duodenal tumor enucleation. One patient underwent segmental duodenectomy.

**Results:** All the patients had a complete resection (R0), with no postoperative morbidity and mortality. Two patients were classified as

low risk, one patient was classified as ultra low risk, according to the Fletcher scale. None patients had neoadjuvant or adjuvant therapy. All the patients were alive and disease-free.

**Conclusion:** In patients with primary GISTs who demonstrate no evidence of metastasis, surgical resection is the primary treatment. There is little submucosal spread and local and regional lymph node involvement is infrequent. Less invasive surgical treatment, such as local or segmental resection, or laparoscopic surgery should be the choice of duodenal GISTs.

**Abstract ID: 0772** Specific Field: **Stomach/Duodenum**

**Mode of pres.: Poster Discussion**  
**ISW 2011 Session PW 11.03**

**A case of laparoscopic resection of ascending part of duodenum GIST**

H. Moriya [1], M. Amano [1], H. Miura [1], Y. Sakamoto [1], T. Kaizu [1], H. Kanazawa [1], G. Kaneda [1], M. Watanabe [2]

[1] National Hospital Organization Sagami National Hospital, Sagami City, Kanagawa Prefecture, Japan, [2] Kitasato University, Sagami City, Kanagawa Prefecture, Japan

**Introduction:** Gastrointestinal stromal tumor (GIST) is specific mesenchymal neoplasm that occurs in the digestive tract between the esophagus and anus. GIST is common in the stomach (60–70% of cases), small intestine (30%), and colorectum (10%). Only 3–5% of GIST occurs in the duodenum. We reported a case of gastrointestinal stromal tumor (GIST) located in the ascending part of duodenum, which could be resected laparoscopically.

**Material and Methods:** A 46-year-old woman with general fatigue and anemia was diagnosed as upper abdominal tumor 50 mm in size, in CT. Successively, she took endoscopy and was pointed out submucosal tumor at the ascending part of duodenum. On whole body CT, the primary tumor was well-demarcated and neither invasion nor metastasis was found. Preoperatively, the diagnosis was GIST of the ascending part of duodenum without metastasis.

**Results:** We thought that could perform radical resection. Laparoscopic resection was performed at five ports. The tumor was located in the ascending part of duodenum. The patient underwent laparoscopic resection with reconstruction of the duodenectomy defect using automatic linear stapling. The operative blood loss was minimal. The patient had no postoperative complication and was discharged on 9th postoperative day. The resected specimen was 60x32x23 mm in size. Histopathologically, the tumor was positive for c-kit and CD34 but negative for  $\alpha$ -SMA and S-100 in immunostaining. The definitive diagnosis was uncommitted intermediate because the tumor was over 5 cm in size with minimal mitosis.

**Conclusion:** Laparoscopic partial resection of the duodenum seems to be one of the treatment choices for duodenal GIST, if the size and location of the tumor are appropriate.

**Abstract ID: 0773** Specific Field: **Stomach/Duodenum**

**Mode of pres.: Poster Discussion**  
**ISW 2011 Session PW 11.04**

**Laparoscopic excision of a Brunner's gland hamartoma of the duodenum: report of a case and literature review**

A. D. Rao, K. Y. How, J. K. Rao

Tan Tock Seng Hospital, Singapore, Singapore

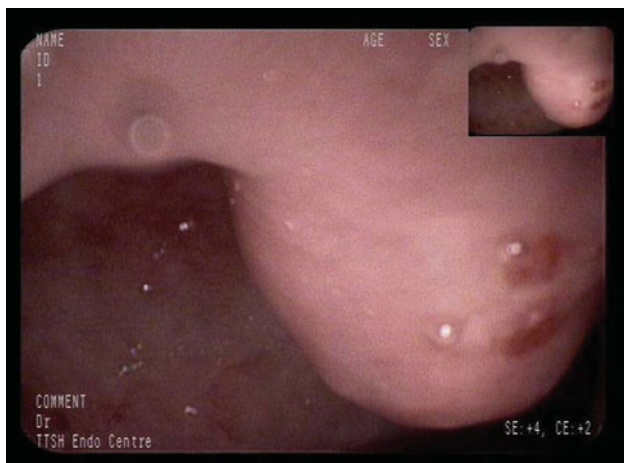
**Introduction:** Brunner's gland adenoma is a nodular hyperplasia of the normal Brunner's gland with an unusual admixture of normal tissues. It

accounts for 10% of benign tumours of the duodenum and is better designated as a hamartoma rather than a true neoplasm. It is very rare, with only slightly over 150 cases reported so far in world literature. This is the third reported case to be resected laparoscopically.

**Material and Methods:** Endoscopy, for anaemia in a 71 year old chinese males howed a submucosal mass in the first part of the duodenum. Endoscopic ultrasound showed a large submucosal mass arising from the superior wall of the first part of the duodenum with no suspicious perilesional/duodenal or celiac nodes. FNA showed spindle and epithelioid cells with no features suggestive of a malignant or neuroendocrine tumour. CT imaging showed a well circumscribed polypoid mass in the first part of the duodenum measuring 20 × 16 × 10 mm. On account of its size, an elective laparoscopic resection was performed. At surgery a duodenotomy was made along the first part of the duodenum. The tumour was divided with stapler at its base and the duodenotomy was closed transversely.

**Results:** The resected specimen (20 mm × 16 mm × 15 mm) was polypoid with a 5 mm stalk with intact duodenal mucosa. The tumour showed lobules of hyperplastic Brunners glands with gastric mucosal glands, oxyntic cells and cyst formation, all features consistent with Brunners gland hamartoma with gastric heterotopia. There was no evidence of cancer. He was discharged well on the 5th post operative day after a normal gastrograffin contrast study.

**Conclusion:** The aetiology of Brunners gland hamartoma is obscure. It is predominantly seen in the fifth and sixth decades of life. The most common location is the posterior wall of the duodenum near the junction of its first and second portions. The presentation can be either incidental or symptomatic due to bleeding or obstruction. Duodenal intussusception has been reported in two cases. A preoperative histological diagnosis is usually not possible and the conditions that can mimic it are a duodenal GIST, neuroendocrine tumour or rarely adenocarcinoma. It has no malignant potential. Endoscopic polypectomy is the first choice for small adenomas while laparoscopic wedge resection can be performed for larger cases.



**Figure:** Endoscopic photograph of brunners gland hamartoma

**Abstract ID: 0774** Specific Field: **Stomach/Duodenum**

**Mode of pres.: Poster Discussion**  
**ISW 2011 Session PW 11.05**

**Clinical evaluation of prognostic factors in patients with ampullary adenocarcinoma**

T. Kawaguchi, T. Ochiai, E. Otsuji

Kyoto Prefectural University of Medicine, Kyoto, Japan

**Introduction:** Ampullary adenocarcinoma (AmpCA) has a greater overall survival (OS) rate than other periampullary cancers such as pancreatic cancer or bile duct cancer. Nevertheless, the OS of AmpCA is still poor. In the present study we evaluated the clinicopathologic features of AmpCA with respect to its impact on OS.

**Material and Methods:** Records of 28 patients with AmpCA undergoing pancreaticoduodenectomy from 1995 to 2009 in Kyoto Prefectural University of Medicine were reviewed retrospectively. Mean age was 65.6 and mean tumor size was 2.08 ± 1.13 cm. Of the 28 patients, nine (32%) were ≥T3 tumors and nine (32%) were pN1 stage. There were seven (25%) cases of pancreatic invasion (Panc-invasion) and 15 (54%) cases of duodenal invasion (Du-invasion). Further, 14 (50%) cases involved lymphatic vessel invasion (ly+) and five (18%) cases involved histological blood vessel invasion (v+). Eleven (39%) patients experienced recurrences, of which eight were liver metastases. The median OS was 37 months (range 0.6–139.6 months) and the five-year survival rate was 56.4%. The clinicopathologic features and prognoses of these patients were analyzed and the prognostic factors determined.

**Results:** On log-rank testing, Du-invasion ( $P = 0.029$ ), ly+ ( $P = 0.022$ ), and v+ ( $P =$

**Conclusion:** Blood vessel invasion was an independent prognostic indicator, while prevention of liver metastases was important for longer survival.

**Abstract ID: 0775** Specific Field: **Stomach/Duodenum**

**Mode of pres.: Poster Discussion**  
**ISW 2011 Session PW 11.06**

**Duodenal web: a late presentation complicated by Eisenmenger's syndrome**

B. Wademan, K. Pringle, T. Phang

Capital and Coast District Health Board, Wellington, New Zealand

**Introduction:** The presence of congenital duodenal webs in adults is exceptionally uncommon, as the vast majority are diagnosed and treated at or shortly after birth. Adult patients with duodenal webs classically present with symptoms of gastric outlet obstruction and may have associated gastric ulceration. Diagnosis may be delayed due to non-specific X-ray and endoscopic findings as well as the rarity of the condition. We present a case of a duodenal web in an adult with significant co-morbidities including trisomy 21, VSD and Eisenmenger's syndrome. We review the literature to highlight diagnostic features at presentation, appropriate investigation and options for surgical management of this rare entity.

**Material and Methods:** Presentation and investigation: The patient was a 23 year old female with known trisomy 21, a large inoperable VSD and associated Eisenmenger's syndrome who presented acutely with generalised abdominal pain and associated nausea and vomiting. A CT scan revealed a grossly dilated stomach and proximal duodenum and free gas within the retroperitoneal tissues around the pancreas. A diagnosis of probable duodenal web with possible perforation was made. Management: The patient responded well to nasogastric decompression and antibiotics. After discussion with the patients family regarding the significant risk involved with a surgical intervention given her cardiac co-morbidities, she underwent a laparotomy. At the time of operation a duodenal web and a small sealed perforation of the duodenum were found. The duodenal web was partially excised through a longitudinal duodenotomy crossing the web. The perforation was oversewn. The patient was initially

managed through ICU, mainly for monitoring of her cardiac condition. She went on to make an un-eventful recovery.

**Results:** A review of case reports of duodenal webs in adults is made looking at presenting symptoms, surgical management and clinical outcomes. Patients classically present with signs of gastric outlet obstruction and may have associated gastric and/or duodenal ulceration. The majority of cases were successfully managed with transduodenal excision and duodenoplasty.

**Conclusion:** Even in the face of significant cardiac compromise, a “paediatric surgical” approach to an adult with a missed duodenal web yields good results.

#### Abstract ID: 0776 Specific Field: Stomach/Duodenum

Mode of pres.: Poster Discussion  
ISW 2011 Session PW 14.01

##### Outcome of surgical treatment for patients with locoregional recurrence of gastric cancer

S. Nunobe, N. Hiki, S. Aikou

Cancer Institute Ariake Hospital, Tokyo, Japan

**Introduction:** Locoregional recurrent gastric cancer is commonly treated by systemic chemotherapy. The effectiveness of surgical treatment, in terms of complete tumor resection, is unknown.

**Material and Methods:** We reviewed the case histories of 36 patients with locoregional recurrent gastric cancer, selected for surgical treatment by careful preoperative assessment. Patient characteristics and survival data were collected and analyzed. Prognostic factors were also assessed by univariate analysis using the log-rank test.

**Results:** Among 36 patients with recurrent gastric tumors, including 18 patients with local recurrences and 18 patients with single-regional lymph node recurrences, the average time to recurrence after initial surgery was  $26.4 \pm 2.8$  months. Complete resection was possible in 29 patients (80.6%), with incomplete resection in the remaining seven patients (19.4%). Various types of surgery were used for tumor recurrence; 23 patients (63.9%) underwent procedures to resect the tumor and the affected organs. The median survival time (median  $\pm$  standard error) was  $23.0 \pm 2.8$  months, and overall one-year, three-year, and five-year survival rates were 73.0%, 36.7%, and 9.8% respectively. Complete resectability of the tumor was the only significant prognostic factor identified.

**Conclusion:** Although there was no control group in the present study with similarly limited tumor recurrence and treated solely with modern systemic chemotherapy, such a study population would be too small to conduct a randomized study in. For those patients for whom surgery is indicated by multidisciplinary assessment, surgical resection can be applied for recurrent lesions, if complete resection can be accomplished with low peri-operative risk for the extended surgery.

#### Abstract ID: 0777 Specific Field: Stomach/Duodenum

Mode of pres.: Poster Discussion  
ISW 2011 Session PW 14.02

##### Clinicopathologic analysis of extranodal metastases in patients with gastric cancer

E. Bando [1], J. Kondo [1], M. Tokunaga [1], Y. Tanizawa [1], T. Kawamura [1], H. Kanemoto [2], K. Uesaka [2], M. Terashima [1]

[1] Shizuoka Cancer Center, Gastric Surgery Division, Suntogun, Japan, [2] Shizuoka Cancer Center, Gastro-intestinal Surgery Division, Suntogun, Japan

**Introduction:** In cancer of the colon and rectum, extranodal metastasis was defined as vital factor for grading the lymph node involvement in new TNM 7th stage. To evaluate the significance of extranodal metastasis in gastric cancer cases, several analysis were performed for next generation of staging system.

**Material and Methods:** This study enrolled 253 primary gastric cancer patients, without prior chemotherapy, (2010 Feb. to Nov.) who underwent R0 or R1 gastrectomy. To compare the malignant potential between with- and without-extranodal metastases, correlation with extra nodal metastases and clinicopathologic feature was analyzed.

**Results:** Lymph node metastases were detected 81 patients (23%), of the 23 had extra-nodal involvement (28%). In analysis of numbers of metastatic lymph node, there was significant difference between non-extra nodal metastases group (mean; 5.1, median; 2, 1–44) and extra ones (mean; 9.8, median; 9, 1–42) ( $P = 0.004$ ). Also in tumor size calculation, significant difference was observed between non-extra nodal metastases group (mean; 52, median; 53, 16–180) and extra ones (mean; 71, median; 63, 36–200) ( $P = 0.044$ ). Patients with extranodal involvements had significant deeper tumors (T1, 2/T3, 4; 35/46) than did those with non-extra nodal involvement (T1, 2/T3, 4; 2/21) ( $P < 0.001$ ).

**Conclusion:** Extra-nodal involvement may have a malignant potential comparing those without extra metastases. In the future, further prognostic analysis, adding stage-specific subset data, would be necessary for including next edition of TNM system.

#### Abstract ID: 0778 Specific Field: Stomach/Duodenum

Mode of pres.: Poster Discussion  
ISW 2011 Session PW 14.03

##### Clinical evaluation of metastatic lymph node counts on preoperative MDCT for predictive factor of surgical curability in gastric cancer

T. Kawaguchi, D. Ichikawa, E. Otsuji

Kyoto Prefectural University of Medicine, Kyoto, Japan

**Introduction:** Significance of reliable preoperative nodal staging systems and precise diagnostic modalities has been emphasized for adequate treatment in gastric cancer. Recently, thin-sliced multidetector row computed tomography (MDCT) has emerged as a new modality in the diagnosis of gastric cancer because of its powerful spatial cognitive function. In this study, we evaluated the predictive value of metastatic lymph node counts on preoperative MDCT for surgical curability in gastric cancer.

**Material and Methods:** Between January 2005 and December 2007, 92 consecutive patients, diagnosed as gastric cancer, underwent preoperative MDCT at a slice thickness of 1.0 mm.

**Results:** (1) Total counts of metastatic lymph nodes on preoperative MDCT (N-counts on MDCT) ( $1.61 \pm 2.38$ ) were significantly smaller than those on histopathological results (histological N-counts) ( $5.14 \pm 9.12$ ) ( $P = 0.0004$ ). (2) There was significant correlation between lymph nodes counts on MDCT and histopathological results by Spearman analysis.

**Conclusion:** Lymph nodal count detected on MDCT was independent risk factor for surgical curability of gastric cancer and might be an indicator of therapeutic strategy such as neoadjuvant chemotherapy or palliative operation.

**Abstract ID: 0779** Specific Field: **Stomach/Duodenum**

**Mode of pres.: Poster Discussion**  
ISW 2011 Session PW 14.04

**Preoperative evaluation of lymph node metastasis in patients with gastric cancer on computed tomography: a comparison of the directionality of lymph node metastasis and the total number of metastatic lymph nodes**

M. Kitagawa [1], D. Ichikawa [1], S. Komatsu [1], K. Okamoto [1], A. Shiozaki [1], H. Fujiwara [1], T. Ochiai [1], E. Otsuji [2]

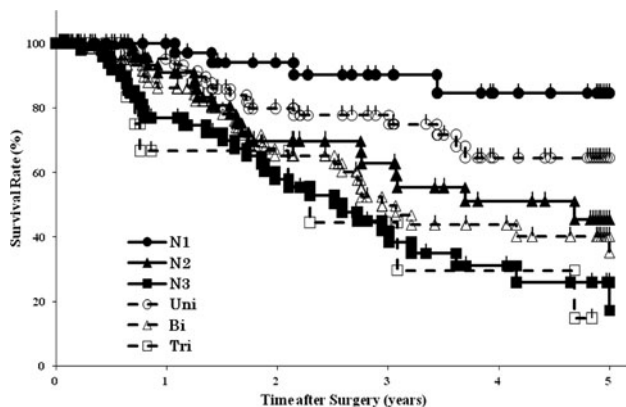
[1] Kyoto Prefectural University of Medicine, Kyoto, Japan,  
[2] Kyoto Prefectural University of Medicine, Japan

**Introduction:** The numerical lymph node staging system is widely used to determine the stages of gastric cancer. However, exact preoperative evaluation of the stages on the computed tomography (CT) is often difficult. We determined the directionality of lymph node metastasis on CT, and compared its clinical impact with the staging by the Japanese Classification of Gastric Carcinoma (JCGC).

**Material and Methods:** We classified 241 patients with gastric cancer into three groups (unidirectional [Uni-], bidirectional [Bi-], and tridirectional [Tri-] groups) depending on the directionality of lymph node metastasis, and assessed the prognosis and the accuracy of preoperative evaluation in comparison with the findings obtained by the JCGC system. The retrospective analysis of the CT images was performed in 54 cases.

**Results:** The survival rate of the Uni-group was significantly greater than that of the Bi- or the Tri-group, whereas there was no significant difference between the survival rate of the Uni-group and that of the N1-group. The exact preoperative evaluation of the stages was found to be 70.2% for the directionality system and 61.7% for the JCGC system, respectively, with no significant difference between these two systems. The stages were less frequently underestimated by the directionality system than the JCGC system ( $P < 0.02$ , 19.1% vs. 34.0%), and the staging could be more precisely performed by using both systems in combination.

**Conclusion:** The results show that the directionality system is a reliable staging system, and more precise preoperative evaluation of the stages could be obtained by using the directionality system and the JCGC system in combination.



**Figure** Survival rates of each group classified by the directionality system or the JCGC system

**Abstract ID: 0780** Specific Field: **Stomach/Duodenum**

**Mode of pres.: Poster Discussion**  
ISW 2011 Session PW 14.05

**The significance of histological predominance in advanced gastric cancer**

M. Iwatsuki, M. Watanabe, H. Baba

Kumamoto University, Kumamoto, Japan

**Introduction:** Gastric cancer is well-known to have histological heterogeneity in primary lesion. According to the Japanese Classification of Gastric Carcinoma, one predominant type should be selected to represent the histology of the carcinoma. Whereas according to TNM staging of stomach cancer by UICC, lower or poorer differentiated type is determined as the histological classification, regardless of the predominant histological type. The aim of this study is to clarify which histological classification is valuable for predicting a prognosis in gastric cancer patients.

**Material and Methods:** Methods: A total of 164 patients with advanced gastric adenocarcinoma were examined. Histological types were documented in descending order of the predominant histological types, according to the Japanese Classification. The relationships between the histological types determined by each staging system and the clinicopathological parameters including prognosis were examined.

**Results:** Results: According to the Japanese Classification, 76 patients were categorized as differentiated types including papillary and tubular adenocarcinoma (Group D), 88 patients as undifferentiated types, including poorly differentiated, mucinous adenocarcinoma or signet ring cell carcinoma (Group U). According to TNM staging system, 18 patients of Group D (23.7%) were converted from Group D to Group U (Group C). The location of tumor in Group C is significantly found in upper third portion of stomach compared with Group D and U ( $P = 0.001$ ). Patients in Group C had significantly poorer prognosis than those in Group D ( $P < 0.05$ ). There were no significant difference of overall survival rate between Group C and Group U.

**Conclusion:** Conclusions: The findings in the current study suggest that it is necessary to value not only quantitative predominance but also qualitative predominance of tumor component in advance gastric adenocarcinoma.

**Abstract ID: 0781** Specific Field: **Stomach/Duodenum**

**Mode of pres.: Poster Discussion**  
ISW 2011 Session PW 14.06

**Strategy of treatment for gastric cancer with synchronous liver metastasis**

O. Hachiya [1], T. Nomura [2], Y. Kamio [1], K. Shibata [1], M. Mizutani [1], H. Isobe [1], I. Hirai [1], W. Kimura [1]

[1] Yamagata University Faculty of Medicine, Yamagata, Japan,  
[2] Yamagata Prefectural Central Hospital, Yamagata, Japan

**Introduction:** The indication of surgical treatment for synchronous liver metastasis from gastric cancer is not established. This study aimed to evaluate the prognostic factors of surgical treatment in such patients.

**Material and Methods:** A clinicopathological analysis was retrospectively performed on the outcome of 48 patients of gastric cancer with synchronous liver metastases.

**Results:** Twenty one cases of all underwent both gastrectomy and hepatic resection, 16 cases underwent only gastrectomy, 13 cases underwent no surgical treatment. Overall 5-year survival rate was 21.6%.0%.0% respectively. Multivariate analysis showed that size of



liver metastatic tumor (more than 5 cm or not) and primary tumor type (infiltrating type or not) were independent prognostic factors.

**Conclusion:** In patients of gastric cancer with synchronous liver metastases, the indication of surgical resection of stomach and liver may be the cases of less than 5 cm size of liver metastatic tumor or non-infiltrating type of primary tumor. The cases of only gastrectomy showed the same prognosis as non-resection cases.

**Abstract ID: 0782** Specific Field: **Stomach/Duodenum**

**Mode of pres.: Poster Discussion**  
**ISW 2011 Session PW 15.01**

**A hemi-double stapling method to create Billroth-I anastomosis following laparoscopically assisted distal gastrectomy**

N. Suzuki, S. Yoshino, M. Iida, S. Takeda, T. Ueno, S. Hazama, M. Oka

Yamaguchi University Graduate School of Medicine, Ube, Yamaguchi, Japan

**Introduction:** We have reported a hemi-double stapling method (HDS) to create Billroth-I (B-I) anastomosis (Oka M et al. J. Am. Coll. Surg., 1995) and adapted this technique for B-I reconstruction following laparoscopically assisted distal gastrectomy (LADG).

**Material and Methods:** A HDS is performed through the 6-cm midline minilaparotomy. After completion of lymph nodes dissection, the stomach is pulled out through minilaparotomy and a linear stapler is used for transection, from the greater curvature halfway to the lesser curvature. The anterior wall of the remaining of the stomach is opened partially and circular stapler is inserted into the gastric segment. The center rod is used to penetrate through the corner of the staple line at the greater curvature. After that, the center rod is connected to the anvil shaft in the duodenum laparoscopically lifting the abdominal wall with retractor. The instrument is closed and fired laparoscopically. The remaining upper gastric segment is divided using a linear stapler, which completes the distal partial gastrectomy with B-I reconstruction. 164 patients with gastric cancer who underwent B-I reconstruction with HDS were assessed.

**Results:** All patients underwent B-I reconstruction successfully through the minilaparotomy. Only 2 patients developed minor leakage, 2 developed anastomotic stricture which was easily treated with balloon dilatation and one patient developed anastomotic hemorrhage.

**Conclusion:** This technique is safe and simple and should become one of a standard approach for B-I reconstruction following LADG. This technique is also adapted for Roux-Y and B-II reconstruction following LADG.

**Abstract ID: 0783** Specific Field: **Stomach/Duodenum**

**Mode of pres.: Poster Discussion**  
**ISW 2011 Session PW 15.02**

**Roux-Y reconstruction after distal gastrectomy for gastric cancer using linear staplers**

Y. Kodera, M. Fujiwara, C. Tanaka, N. Ohashi, G. Nakayama, M. Koike, A. Nakao

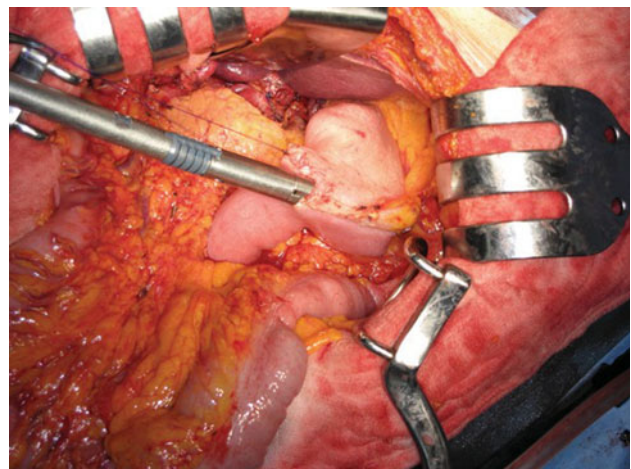
Nagoya University Graduate School of Medicine, Nagoya, Japan

**Introduction:** In Japan, hand-sewn Billroth I anastomosis has been the most frequently performed type of reconstruction after distal gastrectomy.

**Material and Methods:** Since 2004, the authors utilized Roux-Y anastomosis after distal gastrectomy by open approach, employing gastrojejunostomy by a linear stapler as proposed by T. Sano (formerly National Cancer Center, Tokyo). In this technique, jejunum is lifted through the retrocolic route and is approximated with the remnant stomach side-by-side using a linear stapler (see Figure). The remnant stomach is fixed to the mesocolon, and a jejunojejunostomy is created 30 cm anal from the gastrojejunostomy either by hand-sewing or using a circular stapler. Since 2006, jejunojejunostomy was created in the same way as the gastrojejunostomy using a linear stapler. The entry holes are closed by hand-sewing to avoid stenosis. In summary, one TA75 is used to dissect the stomach and an Endocutter with 3 additional staples are used to close the duodenal stump and create the other two anastomoses. A brief video summarizing the procedure will be shown. Operation was conducted by 10 operators, with the author invariably taking up the role of assistant whenever he is not operating by himself.

**Results:** Sixty cases treated by this mode of reconstruction before Oct 2010 were analyzed. The median age of patients was 68, and had various co-morbidities, including 10 patients (17%) who were under the anticoagulant therapy for cardiac diseases. R0 resection was performed in 44 patients and D2 dissection in 49. Median duration of surgery was 221 min. There was one in-hospital death (1.7%) due to interstitial pneumonia possibly related to the neoadjuvant chemotherapy. Deep surgical site infection was observed in 4 cases including Grade I (as classified by Dindo et al.) abdominal abscess in 2 patients (of which one had been operated on perforated gastric cancer), Grade II abdominal abscess in one and Grade II pancreatic fistula in one. No case of anastomotic leakage, stenosis or bleeding was seen. The only case with bowel obstruction was due to twisting of the jejunum just prior to the jejunojejunostomy (Grade IIIa).

**Conclusion:** Roux-Y reconstruction using linear staplers is easy to perform and safe. We are confident that we could go on to employ the ERAS program in which oral feeding starts early following surgery.



**Figure:** Gastrojejunostomy by a linear stapler

**Abstract ID: 0784** Specific Field: **Stomach/Duodenum**

**Mode of pres.: Poster Discussion**  
**ISW 2011 Session PW 15.03**

**Roux-en-Y reconstruction with stapled distal jejunal pouch after total gastrectomy**

S. Ishigami [1], Y. Uenosono [1], T. Arigami [1], Y. Uchikado [1], Y. Kita [1], M. Matsumoto [2], H. Okumura [2], S. Natsugoe [2]

[1] Kagoshima University School of Medicine, Kagoshima, Japan,  
[2] Kagoshima University School of Medicine, Japan

**Introduction:** Roux-en-Y reconstruction after total gastrectomy is a simple and safe procedure; however, it eliminates the gastric reservoir function and markedly changes the postoperative digestive physiology. The patients therefore suffer from insufficient food intake and malabsorption. It has been reported that jejunal pouch reconstruction increases food intake and improves the nutritional status. We established a novel Roux-en-Y reconstruction with stapled distal jejunal pouch after total gastrectomy.

**Material and Methods:** A jejunal pouch, 8 cm in size, was attached at the jejunojejunostomy. We performed this novel reconstruction for 20 gastric cancer patients after total gastrectomy with lymph node dissection as a feasible study.

**Results:** One year after operation, the average percentage weight was maintained in more than 90 per cent and 17 (85%) of these patients were in the normal range of the body mass index.

**Conclusion:** This procedure may improve postoperative malnutrition after total gastrectomy according to our feasible study.

**Abstract ID: 0785** Specific Field: **Stomach/Duodenum**

**Mode of pres.: Poster Discussion**  
**ISW 2011 Session PW 15.04**

**Laparoscopic total gastrectomy with minimal pancreateo-splenectomy(LATG-mPS) for the patient with gastric cancer**

K. Taniguchi, S. Satoh, K. Inaba, Y. Ishida, J. Isogaki, S. Kanaya, I. Uyama

Fujita Health University School of Medicine, Toyoake, Japan

**Introduction:** Total gastrectomy with distal pancreatectomy has been the standard surgical treatment for advanced gastric cancer, this operation frequently complicated by leakage of pancreatic juice. However, laparoscopic total gastrectomy with a pancreas-preserving procedure has been taken long time, and this has the technical difficulty. We, to solve these problem, designed with laparoscopic total gastrectomy with minimal pancreateo-splenectomy (LATG-mPS) as a simple technical procedure.

**Material and Methods:** We describe an improved technique for pancreateo-splenectomy. We perform pancreateo-splenectomy as much as possible on the distal side. Preserving greater pancreatic artery for the blood flow maintenance of pancreas, we make the excision of the pancreas tail a minimum using new linear stapling devices “Duet Tissue Reinforcement System (Duet TRS)”. It is important that this removal to pancreas with Duet TRS is performed spending five minutes or more.

**Results:** Thirteen patients with gastric cancer underwent this procedure. There is two cases of intra abdominal abscess due to leakage of pancreatic juice. The operation time of this procedure was not extended compared with laparoscopic total gastrectomy with a pancreas-preserving procedure in our hospital.

**Conclusion:** LATG-mPS with Duet TRS is very simple and technically feasible. Additionally, this procedure may be came standard operation in laparoscopic total gastrectomy for the patient with gastric cancer. Herein we give the details of our new method and offer some caveats for its performance.

**Abstract ID: 0786** Specific Field: **Stomach/Duodenum**

**Mode of pres.: Poster Discussion**  
**ISW 2011 Session PW 15.05**

**Laparoscopic surgery for co-existence of gastric gastrointestinal stromal tumors with gastric cancer: a report of two cases**

W. H. Tong [1], Q. Wang [2]

[1] The First Hospital of Jilin University, China, People’s Republic,  
[2] The First Hospital of Jilin University, Changchun, China, People’s Republic

**Introduction:** To report two cases we use the laparoscopic surgery procedure to finished the therapy of the gastrointestinal stromal tumors with gastric cancer.

**Material and Methods:** Case 1: a 64-year-old male patient with an advanced gastric carcinoma and a synchronous gastric GIST. Case 2: a 78-year-old male patient with a giant gastric GIST and a synchronous early stage gastric cancer. Two were diagnosed before operation with gastroscope and CT-scan,. In both cases, the laparoscope procedure were successfully applied.

**Results:** The radical gastrectomy were performed. Operation time is 125 min and 171 min, immuno-histochemical examinations of the resected specimens confirmed the coexistences of GISTs and gastric cancers.

**Conclusion:** The coexistences of GISTs with epithelial tumors have been increasing in recent years. In any case of a GIST or gastrointestinal adenocarcinoma, the surgeon should be alert to recognize a possible coexistent tumor with different histological origin.

**Abstract ID: 0787** Specific Field: **Stomach/Duodenum**

**Mode of pres.: Poster Discussion**  
**ISW 2011 Session PW 16.01**

**Significance of gastrectomy for early gastric cancer after endoscopic submucosal dissection**

Y. Nagata, Y. Kamohara, S. Maeda, T. Tagawa, H. Nishiyama, H. Fujioka

National Hospital Organization Nagasaki Medical Center, Omura, Japan

**Introduction:** Endoscopic submucosal dissection (ESD) has been accepted and standardized as the treatment of early gastric cancer in Japan and also in the Western countries recently. However, additional gastrectomy is recommended in case of non-curative dissection. The aim of this study is to evaluate the outcome of gastrectomy after ESD in our institute.

**Material and Methods:** From January 2005 to December 2009, 389 patients were undergone ESD for early gastric cancer in our institution. Following gastric cancer treatment guideline of Japanese gastric cancer association, the non-curative criteria were defined as follow, infiltration to submucosa, invasion of vessels, or positive of margin. The medical records of those patients were retrospectively reviewed, particularly focusing on operation procedure and post-operative outcome.

**Results:** After pathological investigation, 34 patients of them (8.7%) were recommended gastrectomy, because of non-curative ESD, and all of them were received operation. The average period was 55 days between ESD and gastrectomy. Twenty-one distal gastrectomies, 9 total gastrectomies, 3 partial gastrectomies, and one proximal

gastrectomy were performed. The laparoscopic gastrectomy was performed in 23 cases (67.6%). Pathological examination revealed remnant cancer cells in 6 patients (17.7%), 2 of them were margin negative of specimen at ESD. The metastasis of lymph node was revealed in 2 cases. There was no mortality and no serious complication. In this study, around 20% of patients with non-curative ESD had remnant cancer or lymphnode metastasis. Although there was one patient with cancer recurrence after gastrectomy, all the patients are alive.

**Conclusion:** Gastrectomy after ESD is safe. From the point of view of oncologic analysis, gastrectomy is needed in the non-curative case after ESD.

## Abstract ID: 0788 Specific Field: Stomach/Duodenum

**Mode of pres.: Poster Discussion**  
**ISW 2011 Session PW 16.02**

### Clinical results of short incisional laparotomy for distal gastrectomy of the patients with gastric cancer

S. Miyazaki [1], K. Yamabe [2], M. Nagaoka [1]

[1] social insurance Kinan Hospital, Tanabe City, Japan,  
[2] Social Insurance Kinan Hospital, Japan

**Introduction:** Laparo-assisted distal gastrectomy (LADG) has been spreaded widely among Japan. However, the indication of the LADG was limited to the patients with early gastric cancer. We have performed the short incisional laparotomy (10 cm>) to the patients with gastric cancer out of indication of LADG. In this study, we compared clinical results of short incisional laparotomy (10 cm>), long incisional larotomy (10 cm<) and laparo-assisted laparotomy for the distal gastrectomy.

**Material and Methods:** This study was retrospective analysis of 168 patients with gastric cancer for the past five years. Laparo-assisted distal gastrectomy (Group A) was performed in 38 patients, short incisional laparotomy was performed in 79 patients (Group B) and long incisional laparotomy was performed in 54 patients (Group C). The operation times, amount of intraoperative bleeding, the maximum level after operation of white blood cell (WBC) and C-reactive protein (CRP) were compared with three groups. These factors were examined by two group classified according to the BMI(25≥ or 25<) in each group.

**Results:** The operation time of Group a (260 ± 61 min.) was significantly longer than these of Group B (179 ± 46 min) and Group C (189 ± 54 min) Amount of intraoperative bleeding of Group A was significantly more than that of Group B and C. There was no significant difference in maximum value of WBC after operation. The maximum level of CRP after operation of Group C (14.9 ± 5.3 mg) was significantly more than that of Group A (12.2 ± 6.0 mg) and B (11.6 ± 4.5 mg). The operation time of two groups classified according to the BMI (25 or 25<) in Group A were 256 ± 51 min.:271 ± 87 min. and amount of intra-operative bleeding was 172 ± 140 ml: 280 ± 165 ml. There was significant difference in amount of intra-operative bleeding. In Group B and Group C, there were no significant difference in operation time and amount of intra-operative bleeding between the two groups classified according to the BMI.

**Conclusion:** Laparo-assisted distal gastrectomy and short incisional laparotomy were minimally-invasive surgery in comparison with long incisional laparotomy surgery. For the obese patients with BMI value more than 25, there were no advantage of short incisional laparotomy for distal gastrectomy.

## Abstract ID: 0789 Specific Field: Stomach/Duodenum

**Mode of pres.: Poster Discussion**  
**ISW 2011 Session PW 16.03**

### Feasibility of laparoscopic distal gastrectomy for gastric cancer in elderly patients

J. Ueda, E. Nagai, K. Ohuchida, N. Yamanaka, H. Toma, S. Shimizu, M. Tanaka

Department of Surgery and Oncology, Kyushu University, Fukuoka, Japan

**Introduction:** The feasibility of laparoscopic distal gastrectomy for gastric cancer in elderly patients remains uncertain.

**Material and Methods:** From January 2008 to December 2009, we performed laparoscopic distal gastrectomy for gastric cancer in 14 patients aged more than 80 (aged group) in the Department of Surgery and Oncology, Kyushu University. The outcomes of laparoscopic distal gastrectomy in these patients were analyzed, and compared with those in 27 patients aged less than 60 (young group) who underwent laparoscopic distal gastrectomy during the same period. **Conclusions:** Laparoscopic distal gastrectomy was performed safely even in elderly patients aged more than 80.

**Results:** In aged group, the mean age was 82.3 years old (80–86) and stage of disease was stage IA in 8 patients, stage II in 2 patients, and stage IV in 2 patients. Operative procedure was laparoscopy-assisted distal gastrectomy in 6 patients and laparoscopic distal gastrectomy with intra-corporeal anastomosis in 8 patients. Operation time and blood loss was 322 ± 86 min and 116 ± 150 g, respectively. Only one patient had a postoperative complication (atelectasis), and postoperative hospital stay was 12.4 ± 8.0 days. In the comparison with young group, preoperative cardiovascular complication was more in aged group than in young group (47 vs. 15%,  $P < 0.05$ ). However, there were not significant differences between aged and young groups in operation time (322 ± 86 min vs. 337 ± 78 min,  $P = 0.560$ ), blood loss (116 ± 150 g vs. 103 ± 311 g,  $P = 0.880$ ), postoperative morbidity (7% vs. 7%,  $P = 0.975$ ), and postoperative hospital stay (12.4 ± 8.0 vs. 10.3 ± 4.8 days,  $P = 0.298$ ).

**Conclusion:** Laparoscopic distal gastrectomy was performed safely even in elderly patients aged more than 80.

## Abstract ID: 0790 Specific Field: Stomach/Duodenum

**Mode of pres.: Poster Discussion**  
**ISW 2011 Session PW 16.04**

### Evaluation of proximal gastrectomy with jejunal pouch interposition (JPI)

H. Yabusaki

Niigata Cancer Center Hospital, Japan

**Introduction:** Objective: We evaluated JPI.

**Material and Methods:** Objective: We evaluated JPI. Method: From 1996, 133 patients with early gastric cancer in the upper third of the stomach underwent JPI. We assessed the result of JPI compared to 20 JI and 10 RY. 116 men with median age of 63 years old, 68 with intramucosal, 73 with submucosal regions and 22 deeper than the proper muscular layer.

**Results:** Results: Operation time was significantly longer in JI ( $p < 0.05$ ), but no significant differences were seen in other operating influences (bleeding volume and postoperative hospitalization days) and postoperative complications. Post-operative complaints were JPI



43%, JI, EG 30% respectively. Postoperative endoscopic examination showed stenosis (JI/JPI/EG) 5/4/20% (p0.01), reflux esophagitis 35/24/30%, food residue 20/24/20%, remnant gastritis 20/8/20% (p0.05). Positive rate of congo-red test in JPI was 50%. There were no differences in postoperative changes of body weight, hemoglobin, total protein, total cholesterol. Carcinomas of the remnant stomach were 7 in JPI.5 patients underwent complete endoscopic resection easily and other 2 patients were operated curative resection.

**Conclusion:** JPI was favorable procedure as a limited surgery for early gastric cancer located in the upper third of the stomach without severe complications or decline of the remote survival.

Evaluation of Proximal Gastrectomy with JejunalPouch Interposition (JPI).

Atsushi Nashimoto Satoru Nakagawa Atsushi Matsuki

**Abstract ID: 0791** Specific Field: **Stomach/Duodenum**

**Mode of pres.: Poster Discussion**  
**ISW 2011 Session PW 16.05**

**Surgical morbidity after gastrectomy in patients under maintenance hemodialysis**

T. Sakai [1], Y. Oshima [1], T. Nanami [1], S. Yajima [1], K. Yamazaki [1], S. Mizuiri [2], H. Shimada [1], H. Kaneko [1]

[1] 1. Department of Surgery, Toho University Omori Medical Center, Ota-ku, Tokyo, Japan, [2] 2. Department of Nephrology, Toho University Oomori Medical Center, Ota-ku, Tokyo, Japan

**Introduction:** Although number of major surgery for patients on maintenance hemodialysis was growing, only a few reports focused on gastric cancer surgery. We analyzed, in this report, postoperative complications in patients with gastric cancer on maintenance hemodialysis.

**Material and Methods:** During 2001 to 2008, a total of 7 patients, treated with hemodialysis, underwent gastrectomy for gastric cancer. Six patients were male and one patient was female with mean age of 65.1 (54 to 76). We retrospectively reviewed medical records of these patients to assess postoperative complications and prognosis after surgery. Cause of nephropathy of these 7 patients were diabetic nephropathy in 4 patients and un-known nephropathy in the other 3 patients. The mean duration of dialysis treatment until gastrectomy was 29.3 moths (2 to 68 months).

**Results:** All of 7 patients had pleural co-morbidities before surgery. A total of 4 patients developed early cancer and 3 patients developed advanced cancer. A total of 6 patients underwent distal gastrectomy and one patient underwent total gastrectomy. Four of 7 (57%) developed postoperative complications, such as leakage, atelectasis and cardiac failure. One patient died of cardiac failure within one month. Among 3 patients with advanced disease, two patients received oral 5-FU treatment as adjuvant therapy. Two patients survived more than 5-years after surgery.

**Conclusion:** For gastric cancer patients associated on maintenance hemodialysis, it seemed to be high risk to perform standard gastrectomy. More strict indications for surgery and more intensive postoperative care than for current series should be needed for future patients with gastric cancer.

**Abstract ID: 0792** Specific Field: **Stomach/Duodenum**

**Mode of pres.: Poster Discussion**  
**ISW 2011 Session PW 18.01**

**Over the counter sale of non-steroidal anti-inflammatory drugs should be banned !**

T. Govender, M. Brand

University of the Witwatersrand, Johannesburg, South Africa

**Introduction:** Non-steroidal anti-inflammatory drugs (NSAIDs) are well known for their many complications. The United States Food and Drug Administration issued a ruling in April 2009 that made it compulsory to list the gastro-intestinal and cardiac side effects of NSAIDs clearly on all NSAID packaging. Many studies have documented the high incidence of gastro-intestinal as well other complications, and several calls have been made to ban NSAIDs due to their cardiac side effects. In South Africa, NSAID preparations are freely available over the counter, even in non-pharmaceutical stores. A large proportion of patients admitted to our hospital with upper gastro-intestinal complaints are users of NSAIDs, and appear to be unaware of their significant side effects.

**Material and Methods:** We performed a retrospective study from 1 January 2010 to 31 December 2010 at Charlotte Maxeke Johannesburg Academic Hospital (CMJAH). All patients that were admitted with an upper gastro-intestinal complaint, and subsequently underwent esophagogastroduodenoscopy or a surgical procedure and who did not have portal hypertension were included. We used a university associated hospital. "Duet Tissue Reinforcement System (Duet TRS)". It is important that this removal to pancreas with Duet TRS is performed spending five minutes or more.

**Results:** In 2010, 163 patients were admitted with epigastric pain, upper gastro-intestinal haemorrhage or perforation. Of 94 patient files collected to date, 36 are confirmed NSAID users. Of these, 4 underwent laparotomy. R20,520 (South African Rand) was the cost per such admission which includes only the following: 4 days in a general ward, consultation fees and esophagogastroduodenoscopy and excludes admission to an intensive care unit and blood products. Each patient that required a laparotomy accrued a cost R88,800. The estimated cost for these 36 patients was R1,093,920.

**Conclusion:** The cost associated with NSAID use to the CMJAH is substantial. Our experience is verified in the literature. We suggest that NSAIDs become prescription only medication in an attempt to reduce their cost to national health systems.

**Abstract ID: 0793** Specific Field: **Stomach/Duodenum**

**Mode of pres.: Poster Discussion**  
**ISW 2011 Session PW 18.02**

**Surgical treatment of gastric stromal tumors**

Q. S. M. Al-Ani, A. S. Briezaz, A. Al-Dhumour, A. H. Al-Ani, O. Sadieh

Al-Basher teaching Hospital, Amman, Jordan

**Introduction:** Gastrointestinal stromal tumor (GIST) is a rare neoplasm exhibiting, in most cases, mutations of c-kit tyrosine kinase, it is the most common mesenchymal tumor of the gastrointestinal tract. Two thirds of all gut malignant GISTs occur in the stomach.

**Material and Methods:** 13 patients presented with GIST tumors from the period of January 2000 to August 2010. Surgical treatment done in all patients with local Gastric wedge resection in 4 patients, subtotal gastrectomy in 3, total gastrectomy in 2, laparoscopic proximal gastrectomy in 1, distal gastrectomy in 2 patient. A very huge intra-abdominal mass more than 8 kilograms was resected from intra-abdominal cavity with the involved stomach. In all the patients safe margin of at least 2 cm was ascertained and safety margin were carefully looked for with frozen section in the last 5 cases. Lymphadenectomy was not necessary. Imatinib was used post-operatively in all the patients.

**Results:** There were 9 males and 4 females, with age range from 21 years to 64 years. Patients presented with upper gastrointestinal bleeding in 4

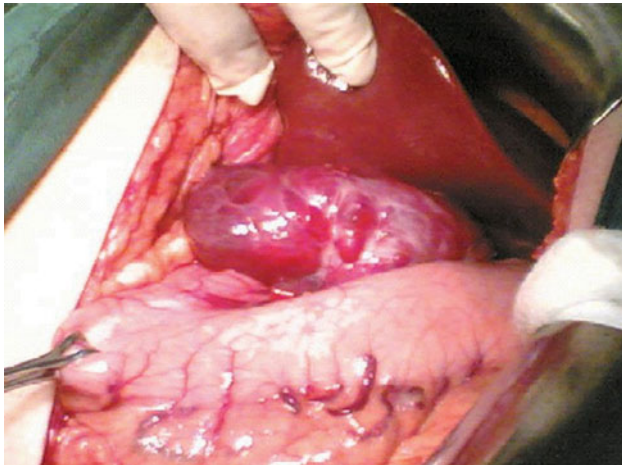


patients, abdominal mass and weight loss in 5, dysphagia in 3 patients, while one patient presented acutely with haemoperitoneum. Preoperative diagnosis was done in 4 patients as gastric GIST, while in the remainder the diagnosis was done postoperatively. Gastric tumors located in the cardia of the stomach in 2 patients, body of the stomach in 6 patients and the antrum in 2 patients. There was no operative mortality. follow up from 6 months to 6 years, there were two deaths 18 months after R1 resection in one, and 24 months in the other. Other patients followed in the oncology department, with norecurrences.

**Conclusion:** The therapy of choice of resectable GIST is complete surgical removal of the tumor. Lymphadenectomy is not necessary; GIST rarely involves the loco regional lymph nodes. The margins of resection from the tumor specimen should be carefully oriented and examined. Lparoscopic resection is feasible and was successfully applied to the management of GIST.

#### Tumour pathological characteristics

	Tumour characteristics	Patients
Size of the tumour	<5 cm	4
	5–10 cm	5
	>10 cm	4
Mitotic figure	<5/50 HPF	6
	>5/50 HPF	7
CD117	positive	13
Residual disease	Microve	11
	Positive	2



**Figure** Extragastric growth pattern GIST

#### Abstract ID: 0794 Specific Field: Stomach/Duodenum

**Mode of pres.: Poster Discussion**  
ISW 2011 Session PW 18.03

#### LECS for submucosal tumors located at the esophago-gastric junction

S. Aikou, N. Hiki, S. Nunobe, S. Tanimura, S. Ohyama, T. Sano, T. Yamaguchi

Cancer Institute Ariake Hospital, Japanese Foundation for Cancer Research, Tokyo, Japan

**Introduction:** Laparoscopic surgery is increasingly used in gastric procedures including wedge resections of the stomach for gastric submucosal tumors. The wedge resections may result in excessive gastric resection cause postoperative transformation of the stomach with consequent gastric stasis. We have previously introduced laparoscopic and endoscopic cooperative surgery (LECS) to prevent excessive resection of stomach. We applied LECS procedure to the tumors located near the esophago-cardiac junction which is difficult to be resected by wedge resection. We report our experience with LECS for submucosal tumors located at the esophago-gastric junction.

**Material and Methods:** Between June 2006 and March 2010, 8 patients with gastric tumor underwent LECS (4 GIST and 4 Leiomioma). In LECS procedure, confirmation of the tumor location and submucosal dissection is performed by endoscopy to determine the appropriate resection line. Then, under laparoscopy, seromuscular layer dissection was performed using ultrasonically activated device and the incision line was closed using laparoscopic stapling devices.

**Results:** One of the cases was convert to open proximal gastrectomy because the defect of the wall after resection was two third of circumference of esophagogastric junction. The average operation time for this procedure was  $172.3 \pm 7.7$  min, and the estimated blood loss was  $11 \pm 3.6$  ml. In all cases the postoperative course was uneventful with no anastomosis leakage, stenosis, or bleeding.

**Conclusion:** LECS for submucosal tumors located at the esophago-gastric junction were performed safely with reasonable operation times, less bleeding, and complication rate.

#### Abstract ID: 0795 Specific Field: Stomach/Duodenum

**Mode of pres.: Poster Discussion**  
ISW 2011 Session PW 18.04

#### Laparoscopic sleeve gastrectomy in Japanese patients with morbid obesity

M. Ohta, T. Hirashita, T. Masuda, Y. Iwashita, T. Ogawa, K. Yada, H. Eguchi, S. Kitano

Oita University Faculty of Medicine, Yufu, Oita, Japan

**Introduction:** Now, in Japan, 25% of the population is obese (BMI >25 kg/m<sup>2</sup>, defined by Japan Society for the Study of Obesity) and 0.3% is morbidly obese (BMI >35 kg/m<sup>2</sup>). Therefore, bariatric surgery has not been popular until now, and only 70–80 patients annually undergo it. We have performed laparoscopic adjustable gastric banding since 2005 and laparoscopic sleeve gastrectomy (LSG) since 2006. Here, our Japanese data on LSG are presented.

**Material and Methods:** Since June 2006, 19 patients with 135 kg averaged weight and 47 kg/m<sup>2</sup> BMI have undergone LSG. The inclusion criteria of LSG were initially morbid obesity with contraindication of gastric banding and super obesity (BMI >50 kg/m<sup>2</sup>) but recently common morbid obesity (BMI >35 kg/m<sup>2</sup>). LSG was carried out using endoscopic linear staplers (EndoGIA, US Surgical) from the greater curvature of the antrum 6 cm proximal to the pyloric ring to the angle of His alongside a 32-Fr endoscope or a 45-Fr overtube of the endoscope. The staple lines were manually oversewn in 13 of the 19 patients, and buttressing of the staple lines (Duet TRS, Covidien) was used in the remaining 6 patients.

**Results:** All the procedures were laparoscopically completed, and no major complications were experienced. Weight loss and% excess weight loss were 42 kg and 65% after 12 months, and 41 kg and 59% after 24 months. Accordingly, comorbidities such as type 2 diabetes were frequently cured or improved (resolution (remission) rate: type 2

diabetes 100%, hypertension 60%, dyslipidemia 64%, metabolic syndrome 100%).

**Conclusion:** LSG will play an important role in treatment for Japanese morbidly obese patients in the near future.

#### **Abstract ID: 0796** Specific Field: **Stomach/Duodenum**

**Mode of pres.: Poster Discussion**  
**ISW 2011 Session PW 18.05**

##### **Prognostic value of protease activated receptor-1 (PAR-1) in gastric cancer**

Y. Hirono, T. Watanabe, D. Fujimoto, H. Nagano, T. Goi, A. Iida, K. Kayatama, A. Yamaguchi

University of Fukui, Fukui, Japan

**Introduction:** Protease-activated receptors (PARs) are proposed to be involved in the invasive and metastatic processes of various types of cancer. We considered whether the expression of PAR-1 has relevance to progression in gastric cancer.

**Material and Methods:** An immunohistochemical study was carried out on 129 resected specimens of gastric cancer using an anti-PAR-1 mouse monoclonal antibody. Associations between immunohisto-staining and clinicopathological factors were analyzed statistically. We also analyzed relationship between immunohistostaining and prognosis.

**Results:** There were 58 carcinomas (45%) positive for PAR-1 expression. The expression of PAR-1 was significantly associated with the depth of wall invasion and peritoneal dissemination. These patients with PAR-1 positive tumors had a significantly poorer prognosis than those with PAR-1 negative tumors. Univariate and Multivariate analyses indicated that PAR-1 expression was an independent prognostic factor.

**Conclusion:** These results led us to believe that the expression of PAR-1 is associated with the progression of gastric cancer and an independent prognostic predictor.

#### **Abstract ID: 0797** Specific Field: **Stomach/Duodenum**

**Mode of pres.: Poster Discussion**  
**ISW 2011 Session PW 18.06**

##### **Expression of protease-activated receptor-2(PAR2) in gastric cancer**

D. Fujimoto, Y. Hirono, T. Goi, K. Katayama, A. Yamaguchi

University of Fukui, Fukui, Japan

**Introduction:** Recently, the four-kind cloning of the protease-activated receptor (PAR) had been carried out. PAR2 is activated by trypsin and it is supposed that PAR2 participated in proliferation of the endothelial cell or in neovascularization. We considered whether the expression of PAR2 has relevance to progression in gastric cancer.

**Material and Methods:** Immunohistochemical study by the envision method was carried out on 183 samples of gastric cancer in the first department of surgery, University of Fukui, using anti-PAR2 mouse monoclonal antibody and on 95 samples of them that were pointed out advanced gastric cancers by pathological diagnosis using anti-trypsin rabbit polyclonal antibody. Tissues, which were stained more than 20% of the tumor cells, were classified as PAR2 protein-positive. Correlation with immunostainings and clinicopathological factors was analyzed statistically.

**Results:** There were 77 (42.1%) carcinomas positive for PAR2 expression. The PAR2 expression was intensely strong on the cell membrane of primary cancer tissues. The expression of PAR2 correlated with the depth of wall invasion, lymphatic invasion, venous invasion, and liver metastasis. The patients with PAR2 expression-positive tumors had a significant poorer prognosis than those with expression-negative tumors. Univariate analyses identified PAR2 expression as negative predictors. Multivariate analyses indicated that PAR2 expression was not an independent factor. A positive reaction for trypsin was obtained in 45 (47.4%) patients. We found a significant correlation between PAR2 immunostaining and trypsin immunostaining.

**Conclusion:** The results of this study lead us to believe that expression of PAR2 is concerned with progression of gastric cancer.

#### **Abstract ID: 0798** Specific Field: **Stomach/Duodenum**

**Mode of pres.: Poster Discussion**  
**ISW 2011 Session PW 18.07**

##### **Clinical significance of measuring Serum p53 antibodies in gastric cancer**

Y. Yabushita [1], C. Kunisaki [1], I. Endo [2]

[1] Yokohama City University Medical Center, Gastroenterological Center, yokohama, Japan, [2] Department of Gastroenterological Surgery, Yokohama City University, Yokohama, Japan

**Introduction:** To evaluate the clinical significance of the serum p53 antibody (p53) in gastric cancers.

**Material and Methods:** This study included 178 patients with gastric cancer. We preoperatively measured serum level of p53, CEA and CA19-9. Positive rate of serum p53 level was compared with CEA and CA19-9 level. The correlation between serum p53 level and clinicopathological factors were examined. (Cut off level: p53 1.30 U/ml, CEA 4.9 ng/ml, CA19-9 37.0 U/ml).

**Results:** The positive rate of serum level of p53, CEA and CA19-9 were 15%, 13% and 10%, respectively. The positive rates of each tumor markers according to the histological stages (I/II/III/IV) were 11/26/17/19 in p53, 6/9/33/23 in CEA, and 3/4/16/32 in CA19-9, respectively. That is, positive rate of serum level of p53 had no association with tumor stage. However, the positive rates of CEA and CA19-9 had significantly increased according to the stage. ( $P = 0.03$ ,  $P = 0.01$ ) While positive rates of CEA and CA19-9 correlated with depth of invasion and lymph nodes metastasis (CEA;  $P = 0.01$ ,  $P < 0.01$ , CA19-9;  $P = 0.03$ ,  $P = 0.02$ ), that of p53 had no association with any clinicopathological factors.

**Conclusion:** The positivity rate of serum level of p53 had no correlation with tumor progression. Thus, serum level of p53 may be useful to detect early gastric cancers.

#### **Abstract ID: 0799** Specific Field: **Stomach/Duodenum**

**Mode of pres.: Poster Exhibition only**  
**ISW 2011 Session PE 249**

##### **Phase I study of preoperative chemoradiotherapy consisted of S-1 and cisplatin for patients with curable advanced gastric cancer (KOGC-01)**

T. Takahashi [1], Y. Saikawa [2], H. Takaishi [1], H. Takeuchi [2], N. Wada [2], T. Oyama [2], N. Shigematsu [3], Y. Kitagawa [2]

[1] Keio Cancer Center, Keio University Hospital, Tokyo, Japan, [2] Department of Surgery, School of Medicine, Keio University, Tokyo, Japan, [3] Department of Radiology, School of Medicine, Keio University, Tokyo, Japan

**Introduction:** The prognosis of advanced gastric cancer was still poor and surgery is the only treatment for patients with curable advanced gastric cancer. Recent clinical trial showed the survival benefit of the adjuvant chemotherapy after curative gastrectomy in patients with Stage II/III gastric cancer. However, the further improvement of prognosis has been expected in advanced gastric cancer. In the present study, we conducted a phase I study of chemoradiation therapy for the treatment of curable advanced gastric cancer. We determined the maximum-tolerated dose (MTD) and recommended dose (RD) of cisplatin (CDDP) and also examined preliminary therapeutic effect of this combination therapy.

**Material and Methods:** The chemotherapy schedule consisted of one cycle given every 5 weeks. S-1 was administered orally every day on days 1–21 and the total dose was based on the patient body surface area (BSA). CDDP was infused 1 on days 1, 8 and 15 with escalating doses (15–30 mg/m<sup>2</sup>). Radiation therapy (5 days/week) at 2 Gy/day was started concurrently with chemotherapy and repeated hourly on days 1–5, 8–12, 15–19, and 22–26. Irradiation was planned using a computed tomography (CT) simulator for two rectangular portals (anterior and left lateral) with a pair of 45-degree wedge filters, and was targeted at the primary tumor and surrounding lesions, including lymph nodes. Surgery was scheduled to take place within 6 weeks after completion of the second cycle of chemotherapy.

**Results:** A total of 10 patients were recruited to this study. The median age was 64 years (range 52–75 ages). There were 7 male and 3 female and all patients were PS0. The first 4 patients were entered into level 1, and next 6 patients entered into level 0. The dose-limiting toxicity was delay of second course of chemotherapy. The MTD of CDDP was identified as 15 mg/m<sup>2</sup>. Five patients underwent surgery till December 2010 and all had an R0 resection. No major surgical complications such as leakage occurred.

**Conclusion:** Chemoradiotherapy consisted with S-1 and CDDP might be considerable in terms of the treatment delay, but effective as a preoperative therapy for curable advanced gastric cancer.

**Abstract ID: 0800** Specific Field: **Stomach/Duodenum**

**Mode of pres.: Poster Exhibition only**  
**ISW 2011 Session PE 261**

#### **Preoperative diagnosis of metastatic lymph nodes in advanced gastric cancer by multidetector-row**

CT M. Katsuda, M. Iwahashi, M. Nakamori, M. Nakamura, T. Ojima, T. Iida, T. Tsuji, H. Yamaue

Wakayama Medical University, Wakayama, Japan

**Introduction:** Precise pre-operative diagnosis of regional lymph node metastasis in gastric cancer is very important in planning the therapeutic strategy. The purpose of this study is to identify the optimal diagnosis criteria using 64-MDCT for predicting the metastasis of regional lymph nodes.

**Material and Methods:** Thirty patients who underwent curative gastrectomy for gastric cancer during the period of January 2009 to March 2010 were enrolled in this study. Eligibility criteria were as follow; selected as patients who (1) did not undergo preoperative chemotherapy; (2) had undergone MDCT before the surgery; (3) had undergone curative surgery; (4) whose T factor was pathologically T2 or more; (5) whose N factor was pathologically N2 or less. The

diameter of the regional lymph nodes that were identified on 64-MDCT image were measured and compared with pathological specimens.

**Results:** The total number of histologically counted lymph nodes with surgical resection was 1183, and 41 lymph nodes were metastatic. The number of regional lymph nodes that were measured at least 3 mm in diameter by MDCT was 731. ROC curve showed that lymph nodes that measured 8 mm or more in diameter were regarded as positive (sensitivity; 0.88, specificity; 0.90, accuracy; 0.89). On the other hand, lymph nodes along common hepatic artery (#8a lymph nodes) were metastatic in only one of 30 patients. Moreover, the length of the metastatic #8a lymph node was 9 mm, whereas that of non-metastatic #8a was as large as  $12.1 \pm 3.5$  mm. Therefore, we assessed 40 patients including 10 patients whose N factor was pathologically N3, and 6 patients showed #8a lymph node metastasis. Among these patients, the length of the metastatic and non-metastatic #8a lymph node was not statistically different ( $14.7 \pm 8.8$  mm,  $12.0 \pm 3.5$  mm, respectively,  $P = 0.19$ ). Therefore, we assessed the ratio of the long-axis diameter to short-axis diameter (L/S ratio) of #8a lymph nodes. L/S ratio of metastatic lymph nodes was statistically smaller than that of non-metastatic lymph nodes ( $1.6 \pm 0.3$ ,  $2.3 \pm 0.6$ , respectively,  $P < 0.005$ ). #8a lymph nodes that measured less than 2.0 in L/S ratio could be regarded as positive (sensitivity; 0.76, specificity; 1.00, accuracy; 0.80).

**Conclusion:** Lymph nodes, except for #8a, that measured 8 mm or more in diameter, and #8a lymph nodes that measured less than 2.0 in L/S ratio could be defined as metastatic lymph nodes.

**Abstract ID: 0801** Specific Field: **Stomach/Duodenum**

**Mode of pres.: Poster Exhibition only**  
**ISW 2011 Session PE 271**

#### **Percutaneous drainage in conservative therapy for perforated gastroduodenal ulcers**

T. Oida [1], K. Mimatsu [1], H. Kano [1], A. Kawasaki [1], Y. Kuboi [2], N. Fukino [1], K. Kida [1], S. Amano [2]

[1] Social Insurance Yokohama Central Hospital, Yokohama, Japan, [2] Nihon University School of Medicine, Tokyo, Japan

**Introduction:** The management of peptic ulcers has dramatically changed, and the incidence of elective surgery for gastroduodenal peptic ulcers has markedly decreased; hence, the incidence of emergency surgery for perforated peptic ulcers has slightly increased. In select cases, conservative therapy can be used as an alternative for treating perforated gastroduodenal ulcers. In this study, we evaluated the efficacy of percutaneous abdominal drainage for the conservative treatment of perforated gastroduodenal ulcers.

**Material and Methods:** We retrospectively studied 51 patients who had undergone conservative therapy for perforated gastroduodenal ulcers. These patients were divided into 2 groups on the basis of the initial treatment with conservative therapy with or without percutaneous drainage: group PD included patients who had undergone percutaneous drainage, and group NPD, patients who had undergone non-percutaneous drainage.

**Results:** In the PD group, 14.3% ( $n = 3$ ) of the patients did not respond to conservative therapy, while this value was 43.3% ( $n = 13$ ), in the NPD group. The 2 groups differed significantly with respect to conversion from conservative therapy to surgery ( $P < 0.0352$ ).

**Conclusion:** Conservative therapy for perforated gastroduodenal ulcers should be performed only in the case of patients meeting the required criteria; its combination with percutaneous intraperitoneal drainage is effective as initial conservative therapy.

## Outcomes

	PD group (n = 21)	NPD group (n = 30)	P value
Convert to operation	3 (14.3%)	13 (43.3%)	0.0352#
Complications			
Abscess	0 (0%)	3 (10%)	0.2588
Ileus	1 (4.8%)	2 (6.7%)	1.00
Pneumonia	1 (4.8%)	1 (3.3%)	1.00
Duration of percutaneous drainage (day)	6.9	None	–
Duration of hospitalization (day)	13.1	15.4	0.0004#

**Abstract ID: 0802** Specific Field: **Stomach/Duodenum**

**Mode of pres.: Poster Exhibition only**  
**ISW 2011 Session PE 272**

**Long term outcome in peptic ulcer bleeding patients and controls: 15 years follow-up**

M. Udd [1], K. Kainiemi [2], H. Mustonen [1], J.-P. Mecklin [3], P. Miettinen [2]

[1] Helsinki University Central Hospital, Helsinki, Finland, [2] Kuopio University Hospital, Kuopio, Finland, [3] Central Finland Central Hospital, Jyväskylä, Finland

**Introduction:** After peptic ulcer bleeding (PUB) episode, 30-day mortality has been 5–15%. Additionally, long term survival has been poor compared to general population. Decreased survival after an episode of PUB has been associated with comorbidities rather than peptic ulcer (PU) complications. However, the published data of this issue is scarce. Aim of the study was to examine the long term outcome after PUB.

**Material and Methods:** Earlier we estimated the role of multiple risk factors and their combined effects in acute PUB in a case-control setting. In the present study we retrospectively reviewed patient files of these 94 PUB cases and 94 age ( $\pm 5$  year)—and sex matched controls treated in years 1994–1996. After the PUB event, *H. pylori* eradication was scheduled and NSAID consumption was discontinued. Control endoscopy (OGD) was performed after 2, 6 and 12 months to PUB patients. In 2010, data (episodes of recurrent PU, PU complications, events of upper gastrointestinal bleeding and performed OGDs, hospital admissions and potential PU risk factors) was collected from patient files with follow up of 15 years. Causes of deaths were obtained from Statistics Finland. Chi-square, Kaplan-Meier and log-rank tests were used for statistical analysis.

**Results:** Findings during the follow up in cases vs. controls: Recurrent PU 13 vs. 2,  $P = 0.005$  (uncomplicated PU 5 vs. 0, complicated PU 8 vs. 2), other upper gastrointestinal bleeding 3 vs. 0. There was no difference in consumption of NSAID, ASA, oral anticoagulants, corticosteroids or Ca-blockers between PUB cases and controls. Two cases but none of the controls died in 30 days. However, long term mortality was significantly higher in cases compared to controls,  $P = 0.016$ . After 10 years, 55% of the cases and 67% of the controls were alive. Coronary heart disease (22 vs. 10), cerebrovascular disease (8 vs. 9) and malignancy (6 vs. 9) were the most common causes of death in both groups. Deaths were not associated with acute PU episodes.

**Conclusion:** After an episode of acute PUB, patients had increased risk of PU recurrence and of long term mortality. However, mortality was not associated with PU disease.

**Abstract ID: 0803** Specific Field: **Stomach/Duodenum**

**Mode of pres.: Poster Exhibition only**  
**ISW 2011 Session PE 273**

**Duodenal switch operation for juxtapapillary duodenal diverticula**

T. Oida [1], K. Mimatsu [1], H. Kano [1], A. Kawasaki [1], Y. Kuboi [1], N. Fukino [1], K. Kida [1], S. Amano [2]

[1] Social Insurance Yokohama Central Hospital, Yokohama, Japan, [2] Nihon University School of Medicine, Tokyo, Japan

**Introduction:** Since the first case of juxtapapillary diverticulum reported by Lemmel, several reports have demonstrated an association between periampullary diverticulum and gallstone disease. Thus, we compared the efficiency of the duodenal switch operation and choledchojejunostomy for patients who underwent surgery for cholangitis with juxtapapillary duodenal diverticula.

**Material and Methods:** We retrospectively studied 17 patients who had cholangitis associated with juxtapapillary duodenal diverticula. These patients were divided into 2 groups on the basis of the operative procedure: the duodenal switch operation group (DS group) and the choledchojejunostomy group (CJ group).

**Results:** The mean operative time and blood loss were significantly lesser in the DS group than in the CJ group ( $P < 0.0001$  and  $P < 0.0005$ , respectively); however, the duration of nasogastric suction requirement and time after which oral ingestion of solid diet could be safely resumed after surgery were significantly longer in the DS group than in the CJ group ( $P < 0.0001$  and  $P < 0.0001$ , respectively). Gallstone formation after the surgery did not occur in both groups.

**Conclusion:** Duodenal switch operation is useful and less invasive for cholangitis associated with juxtapapillary duodenal diverticula, and for preventing cholangitis for a long period after the operation; however, gastric stasis still remains a problem with this procedure.

## Outcomes

	DS group (n = 8)	CJ group (n = 9)	P-value
Operative time (min)	110	147	0.0001
# Blood loss (ml)	66.9	89.4	0.0005#
Duration of requiring nasogastric suction (day)	6.4	2.0	0.0001#
Oral ingestion of solid diet could be safely resumed (day)	13.9	10.7	0.0001#
Complications			
Cholangitis	0 (0%)	3 (33.3%)	0.2059
Ileus	1 (12.5%)	0 (%)	0.4706
Pneumobilia	0 (0%)	9 (100%)	0.0001#
Follow-up period (months)	55.8	52.6	0.7301



**Abstract ID: 0804** Specific Field: **Stomach/Duodenum**

**Mode of pres.: Poster Exhibition only**  
**ISW 2011 Session PE 274**

**Is Jaboulay gastroduodenostomy effective for treating duodenal stricture due to duodenal ulcer in the early postoperative term? Clinical consideration**

N. Fukino [1], T. Oida [1], K. Mimatsu [1], H. Kano [1],  
 A. Kawasaki [1], Y. Kuboi [1], K. Kida [1], S. Amano [2]

[1] Social Insurance Yokohama Central Hospital, Yokohama, Japan,  
 [2] Nihon University School of Medicine, Tokyo, Japan

**Introduction:** Indications for surgery in patients with duodenal ulcers have changed radically. Gastric outlet obstruction (GOO) is an important complication of duodenal ulcers. From the perspective of organ preservation, gastroduodenostomy (e.g., Jaboulay procedure) is ideal for the treatment of GOO due to duodenal ulcer-induced stricture; however, delayed gastric emptying is frequently observed postoperatively. We compared the short-term clinical outcomes of Jaboulay procedure with those of antrectomy.

**Material and Methods:** We retrospectively studied 30 patients who underwent surgery for GOO due to duodenal ulcer. The patients were divided into the J group (those who underwent highly selective vagotomy with Jaboulay gastroduodenostomy) and the A group (those who underwent highly selective vagotomy and antrectomy with Billroth II reconstruction).

**Results:** The mean duration of nasogastric suction, number of days until diet initiation, number of days until oral ingestion of solid food, and postoperative duration of hospitalization were significantly shorter in the A group than in the J group. Moreover, delayed gastric emptying was significantly less frequent in the A group than in the J group.

**Conclusion:** Considering the short-term postoperative outcomes, we believe that highly selective vagotomy and antrectomy with Billroth II reconstruction are the preferred procedures for duodenal ulcer-induced GOO.

## Outcomes

	J ( <i>n</i> = 12)	A ( <i>n</i> = 18)	<i>P</i> value
Operative time (min)	67.1	122	<i>P</i> < 0.001#
Blood loss (ml)	48.8	255	<i>P</i> < 0.001#
Duration of N-G (day)	7.1	4.1	<i>P</i> < 0.001#
Initial diet (day)	7.3	5.2	<i>P</i> < 0.001#
Solid diet (day)	11.3	9.4	<i>P</i> < 0.001#
DGE	10 (83%)	6 (33%)	<i>P</i> < 0.0106#
Complications			
Pneumonia	1 (8.3%)	1 (5.6%)	<i>P</i> < 1
Wound infection	1 (8.3%)	1 (5.6%)	<i>P</i> < 1
Hospitalization (day)	13.7	12.1	<i>P</i> < 0.002#

**Abstract ID: 0805** Specific Field: **Stomach/Duodenum**

**Mode of pres.: Poster Exhibition only**  
**ISW 2011 Session PE 275**

**A giant duodenal gastrointestinal stromal tumor: a case report**

Y. Murayama, H. Ikoma, E. Otsuji

Kyoto Prefectural University of Medicine, Kyoto City, Japan

**Introduction:** We report the rare case of 64-year-old male with a over 15 cm duodenal gastrointestinal stromal tumor(GIST).

**Material and Methods:** He presented with a history of diarrhea. Although a large upper abdominal mass was detected, there were no clearly abnormal findings on blood tests. Abdominal computed tomography (CT) demonstrated a tumor measuring 15 cm in diameter extending from the lower part of the second portion of the duodenum to the pancreatic head, without any metastatic lesions. Gastroduodenal endoscopy to the point of the papilla of Vater did not detect the presence of a tumor. Subsequent double contrast gastrointestinal radiography demonstrated transformation of the second portion of the duodenum by the extrinsic pressure of the tumor, and the third portion was displaced downward. Barium enema demonstrated that the transverse colon was also displaced downward.

**Results:** Based on these findings, GIST of the duodenum was diagnosed. The patient was underwent partial duodenectomy and reconstructed by Roux-en-Y duodenojejunostomy.

**Conclusion:** In this report, we describe a case of GIST involving the second and third portion of the duodenum successfully treated by partial duodenectomy with Roux-en-Y duodenojejunostomy. A duodenal GIST measuring over 15 cm is very rare. The patient has not shown any sign of recurrence for more than 6 years postoperatively.

**Abstract ID: 0806** Specific Field: **Stomach/Duodenum**

**Mode of pres.: Poster Exhibition only**  
**ISW 2011 Session PE 276**

**Gastrointestinal stromal tumor in the ileum causing invagination and obstruction: a case report**

N. Hirose, T. Fukano, T. Abe, S. Takiguchi, Y. Fujii

Nakatsu Gastrointestinal Hospital, Nakatsu, Japan

**Introduction:** Gastrointestinal stromal tumors (GIST) are the mesenchymal tumors of the gastrointestinal tract, and the frequency of small bowel GIST is between 0.2 and 1% of all gastrointestinal neoplasm. Moreover, GIST of the ileum causing invagination and obstruction is extremely rare. We have experienced one of such cases and would discuss with literature reviews.

**Material and Methods:** A 72-year-old male was presented with a history of vomiting and abdominal distention. Abdominal CT revealed a target sign of the small intestine in the pelvis. Abdominal US showed multiple concentric ring sign. He underwent laparotomy with the preoperative diagnosis as intussusception of the small intestine caused by an intestinal tumor. A tumor of the ileum located 20 cm proximal to the terminal ileum was a leading point of the intussusception, and the resection of the ileum with the tumor was carried out.

**Results:** Surgical specimen showed a well-defined dumbbell type (extra- and intra-luminal growth pattern) tumor sized 3 cm in diameter. Histologically, it was diagnosed as GIST of low-grade malignancy. Immunohistochemically, the tumor expressed positive for c-kit, partially positive for CD34 and SMA, and negative for S-100.

**Conclusion:** We have experienced an extremely rare case of GIST of the ileum causing invagination and obstruction. The patient is well without recurrence one year postoperatively.

**Abstract ID: 0807** Specific Field: **Stomach/Duodenum****Mode of pres.: Poster Exhibition only**  
**ISW 2011 Session PE 277****Radical endoscopic resection is unsuitable for most synchronous, multiple, early gastric cancers**

S. Fujiwara [1], T. Noguchi [2]

[1] Oita San-Ai Medical Center, Oita, Japan,  
[2] Oita University, Yufu, Japan**Introduction:** Many studies on EMR for gastric cancer have investigated only solitary gastric cancer. It remains unclear whether synchronous, multiple, early gastric cancers can be radically resected with EMR or ESD. Therefore, the present study aimed to identify the clinicopathological features of synchronous, multiple, early gastric cancers and to determine whether synchronous, multiple, early gastric cancers can be radically resected with EMR or ESD.**Material and Methods:** Patients who underwent gastrectomy for early gastric cancer were included in this study and divided into two groups: a solitary gastric cancer group and a multiple gastric cancer group. The clinicopathological features of patients in each group were compared, and the criteria for endoscopic resection were subsequently investigated.**Results:** A total of 244 patients were included in the present study. The solitary and multiple gastric cancer groups included 228 patients (93.4%) and 16 patients (6.6%), respectively. The multiple gastric cancer group included 35 lesions, including a greater number of larger tumors and protruded-type tumors, as well as increased incidence of submucosal and lymphatic invasion. Only 2 of 16 cases (12.5%) in the multiple gastric cancer group met the criteria for endoscopic resection. Eleven cases were excluded due to submucosal invasion, and three cases were excluded due to undifferentiated histopathological type tumors.**Conclusion:** To be suitable for radical endoscopic resection, prompt detection of early gastric cancer is essential, before it becomes multiple gastric cancer and invades the submucosa.**Abstract ID: 0808** Specific Field: **Stomach/Duodenum****Mode of pres.: Poster Exhibition only**  
**ISW 2011 Session PE 278****Sentinel node mapping for gastric cancer treated with endoscopic submucosal dissection**T. Fujimura [1], J. Kinoshita [1], I. Makino [1], K. Oyama [1],  
I. Ninomiya [1], S. Fushida [1], T. Ohta [1], S. Kinami [2]

[1] Kanazawa University, Kanazawa, Japan, [2] Kanazawa Medical University, Uchinada, Japan

**Introduction:** Endoscopic submucosal dissection (ESD) is a minimally invasive therapy for early gastric cancer. But some patients need to receive additional operation because pathological diagnosis discloses incurable factors. Recently the sentinel node (SN) concept has been established in the early gastric cancer and SN navigation surgery is tried for clinical application. But the SN concept in gastric cancer patients undergoing ESD has not been confirmed. We performed SN mapping to such patients.**Material and Methods:** Eleven patients were operated after ESD between April, 2004 and December, 2010 in our department. The reasons for operation include SM2 invasion in 4 patients, undifferentiated type in 4, lymphatic invasion in 5, and positive vertical margin in 2. Eight patients showed no residual cancer but 3 had residual cancer. Seven of 11 patients received SN mapping, which was carried out usingpreoperative RI mapping ( $^{99m}\text{Tc}$ -tin colloid) and intraoperative dye mapping (lymphazurin) with an upper gastrointestinal endoscope. We performed gastrectomy with lymphadenectomy and compared the status of lymph node metastasis between SNs and non-SNs according to the final pathological reports.**Results:** Five patients had a tumor at the middle-third of stomach and 2 had a tumor at the lower third. Macroscopic tumor type included IIc in 4 patients, IIa + IIc in 2, and IIa in one. Identification rate of SNs was 100%. Average number of SN was six. All patients had SNs in left gastric artery basin (#1, #3, and #7) and 4 patients had SNs in right gastroepiploic artery basin (#4d and #6). There was no lymph node metastasis in SNs or other dissected non-SNs. Thus specificity was 100% but sensitivity could not be calculated. No adverse effect by SN mapping was reported. No patients recurred or died of original cancer.**Conclusion:** These results suggested that SN mapping for the patients who underwent ESD was feasible. But it remains unknown whether the SN concept in such patients was confirmed or not because there was no patients with lymph node metastases. More experiences of SN mapping are necessary to resolve the question.**Abstract ID: 0809** Specific Field: **Stomach/Duodenum****Mode of pres.: Poster Exhibition only**  
**ISW 2011 Session PE 279****The validity of sentinel lymph node biopsy using dye technique alone in patients with gastric cancer**

T. Sato [1], Y. Rino [1], R. Yamada [1], D. Inagaki [1], T. Oshima [2], N. Yukawa [1], M. Masuda [1], T. Imada [1]

[1] Department of Surgery, Yokohama City University, School of Medicine, Yokohama, Japan, [2] Gastroenterology Center, Yokohama City University, Medical Center, Yokohama, Japan

**Introduction:** Sentinel lymph nodes (SLNs) mapping has been recently introduced to the field of gastric cancer. The aim of the present study was to evaluate the feasibility and accuracy of SLN mapping using dye technique alone in patients for gastric cancer.**Material and Methods:** One hundred and seventy-nine patients with T1N0M0 or T2N0M0 gastric cancer were enrolled. Endoscopic injection of patent blue dye was performed during gastrectomy. Gastrectomy with lymphadenectomy was performed in all patients. Dissected nodes were evaluated by pathologic examination (HE stain).**Results:** SLNs were identified successfully in 175 (97.7%) of 179 patients. No SLNs patients were excluded. The mean number of identified SLNs per case was 4.4. 4 cases with lymph node metastases were not diagnosed SLNs metastases. Twenty-three (85.1%) of 27 cases with lymph node metastasis showed positive SLNs. The diagnostic accuracy based on SLN status was 97.7% (171/175).**Conclusion:** This study revealed that SLN mapping using dye technique alone is an accurate diagnostic procedure for detecting lymph node metastasis in patients in patients with early-stage gastric cancer.**Abstract ID: 0810** Specific Field: **Stomach/Duodenum****Mode of pres.: Poster Exhibition only**  
**ISW 2011 Session PE 280****Laparoscopic repair of perforated ulcer in western Denmark**

T. Sommer

Region Hospital Randers, Denmark

**Introduction:** Objective: To report the distribution and results of laparoscopic repair of perforated ulcer surgery in surgical departments in a major region in Denmark and compare it with the results from the national database regarding mortality and morbidity.

**Material and Methods:** Method: Case charts from all patients who underwent laparoscopic repair of perforated ulcer in Western Denmark in the period 1 January 2003–1 July 2007 were collected. Demographical data, surgical details, morbidity, 30 day mortality, and length of stay were recorded. For comparison, data from the National Health Registry (NIP) describing all patients who had an operation due to perforated ulcer in this period was obtained.

**Results:** Results: No more than 51 out of 818 patients undergoing operation for perforated ulcer in the region had a laparoscopic operation. Mortality in the laparoscopic group was 4% compared to 26% reported from the national database (NIP). The laparoscopic group had a higher reoperation rate but length of stay was equal. No formal criteria concerning surgeon or patients selection for laparoscopic surgery were met.

**Conclusion:** Conclusion: Laparoscopic repair of perforated ulcer was done without any selection criteria in few surgical departments in Western Denmark and was associated with a low mortality but a higher risk of reoperation.

#### Complications after surgery

	Laparoscopic- Jylland	NIP data Jylland	NIP data Denmark
Patients (n)	51	818	1714
Mortality (%)	4	25 (22–28)	28(25–30)
Reoperation (%)	10	5	4
other re operation (%)	10	14	14
Length of stay (days)	7(2–57)	8(13–16)	8(13–15)

#### Abstract ID: 0811 Specific Field: Stomach/Duodenum

**Mode of pres.: Poster Exhibition only**  
**ISW 2011 Session PE 281**

#### The benefits of laparoscopy-assisted distal gastrectomy for obese patients

T. Ohno, A. Ogawa, M. Yanai, Y. Toyomasu, E. Mochiki, T. Asao, H. Kuwano

Gunma University, Maebashi, Japan

**Introduction:** In Japan, the number of obese patients with gastric cancer is increasing. The aim of this study was to evaluate the advantages of laparoscopy-assisted distal gastrectomy (LADG) in obese patients relative to those of conventional distal gastrectomy (DG).

**Material and Methods:** Between January 2004 and June 2009, a total of 197 consecutive patients with gastric carcinoma underwent curative distal gastrectomy with Billroth 1 reconstruction in Gunma University Hospital. Patients were assigned to undergo LADG in 120 or DG in 77 cases according to the depth of tumor invasion and lymph

node status. BMI 25 or higher was defined as obesity, and the amount of blood loss, operating time, number of lymph nodes dissected, and postoperative complications in obese and non-obese patients were compared.

**Results:** None of the patients in the LADG group required conversion to laparotomy. In DG, significantly fewer lymph nodes were retrieved in the obese group than in the non-obese group ( $22.5 \pm 3.4$  vs.  $31.9 \pm 2.0$ ); however, in the obese group, there was no significant difference in the number of lymph nodes retrieved in the LADG and DG groups. In LADG, the operating time and estimated blood loss in the obese group were significantly greater than those in the non-obese group ( $206.6 \pm 6.3$  min vs.  $192.0 \pm 3.1$  min,  $158.2 \pm 24.7$  ml vs.  $101.9 \pm 10.4$  ml). The estimated blood loss correlated the surgical procedures and body mass index (BMI). No significant differences in postoperative complications were noted between the obese and non-obese groups following each procedure.

**Conclusion:** Relative to DG, LADG in obese patients does not affect the radicality of the procedure, and there is no significant difference in the operating time. The estimated blood loss was significantly less in LADG than DG. Surgeons should elect to perform LADG in obese patients with gastric cancer.

#### Abstract ID: 0812 Specific Field: Stomach/Duodenum

**Mode of pres.: Poster Exhibition only**  
**ISW 2011 Session PE 282**

#### Single port access intragastric resection for gastric tumors

K. Hagiwara, M. Matsuda, M. Yamagata, H. Tamegai, S. Hayashi, M. Fujii, T. Takayama

Nihon University School of Medicine, Tokyo, Japan

**Introduction:** Laparoscopic intragastric resection (IGR) became a good surgical option with its gastric functional preservation for intraluminal growth submucosal tumor (SMT), gastrointestinal stromal tumor (GIST) and early gastric cancers those failed endoscopic mucosal resection (EMR). On the other hand, single port access (SPA) surgery is getting popular with its cosmetic and less pain benefit for the patients. In this presentation, we would like to present our successful results of SPA-IGR for gastric tumors.

**Material and Methods:** From Sep.2009 to Dec.2010, 8 cases of SPA-IGR were performed. There are 5 gastric GIST, 1 ectopic pancreas, 1 duplication of the stomach and 1 depth M early gastric cancer. Operative technique of SPA-IGR is as follows; gastrostomy was created through 3 cm umbilical incision and the wound retractor was attached. Then, 12 mm trocar, 5 mm trocar and 12 mm camera port were placed inside of the retractor. Overall procedures were quite similar to the standard laparoscopic intra-gastric resection other than the number of incision. Defect of gastric mucosa was sutured using laparoscopic suturing technique. Gastrostomy was closed with linear stapler extracorporeally.

**Results:** Mean size of GIST was 35.6 mm and ectopic pancreas, duplication of the alimentary tract and gastric cancer were 20 mm, 55 mm, 5 mm in diameter. Mean operative time was 99 min and mean blood loss was 2.5 ml. All patients started oral intake at a day after surgery and mean postoperative hospital stay was 4.7 days. There were no conversions to open surgery or additional trocars insertion. No case had postoperative complication and pathological margins were all negative.

**Conclusion:** SPA-IGR is safe, feasible and has much clinical benefit compared to the conventional IGR by reducing the damage of gastric wall that resulted in shorter operative time and hospital stay. We consider that SPA-IGR shows promise as the therapeutic option for gastric SMT, GIST, depth M gastric cancer and maximize the patient's benefit.

**Abstract ID: 0813** Specific Field: **Stomach/Duodenum**

**Mode of pres.: Poster Exhibition only**  
**ISW 2011 Session PE 283**

**Laparoscopic distal gastrectomy after non-curative endoscopic submucosal dissection for early gastric cancer**

Y. Ebihara, D. Saikawa, Y. Watanabe, T. Sasaki, Y. Kawarada, S. Kitashiro, S. Okushiba, H. Katoh

Tonan Hospital, Japan

**Introduction:** Background: Endoscopic mucosal resection (EMR) has been accepted as a treatment of early gastric cancer (EGC). The number of EMR procedures for EGC has been increasing because a patient's quality of life after EMR is superior to that after surgical gastrectomy. The recently developed EMR procedure, endoscopic submucosal dissection (ESD), makes en-bloc resection possible for mucosal cancer regardless of the size of cancer. In addition, this procedure enable to resect in one piece, therefore accurate pathology can be diagnosed. In Japan, although the number of patients with EGC treated by ESD has increased, the appropriate strategy for treating those with non-curative resection has not been established. Laparoscopic gastrectomy (LG) with regional lymph node dissection has been used in the treatment of EGC with low mortality and morbidity and improvement in patient's quality of life. We performed ESD and LG, by these combinations for EGC. However, ESD is deeper and wide dissection on the gastric wall, therefore it is feared that the scar of ESD makes LG difficult and influences to the post-operative course. Especially concerning LG after ESD difficulty in operation was not proven yet. The purpose of the current study was to determine the feasibility of LG for non-curative EGC following ESD.

**Material and Methods:** We reviewed the clinical data 222 patients undergoing laparoscopic distal gastrectomy (LDG) with ESD ( $n = 25$ ) or without ESD ( $n = 197$ ) to assess treatment outcomes.

**Results:** Operation times required for LDG with ESD, without ESD were  $243.3 \pm 13.9$ ,  $234.7 \pm 5.2$  min ( $P = 0.47$ ), and blood loss was  $142.4 \pm 53.0$ ,  $72.1 \pm 8.7$  g, respectively ( $P = 0.19$ ). There was no significant difference between with ESD and without ESD, in time to solid diet (4.2 vs 4.5 days), length of postoperative hospital stay (16.9 vs 15.7 days). There were no conversions to conventional open surgery and no perioperative deaths.

**Conclusion:** There was no difference between our two study groups. Thus, the treatment strategy for EGC with combination ESD and LG is feasible and acceptable.

**Abstract ID: 0814** Specific Field: **Stomach/Duodenum**

**Mode of pres.: Poster Exhibition only**  
**ISW 2011 Session PE 284**

**Laparoscopy-assisted distal gastrectomy for early gastric cancer in elderly patients**

K. Kumagai, N. Hiki, S. Nunobe, S. Tanimura, S. Ohyama, T. Sano, T. Yamaguchi

Cancer Institute Hospital, Koto-ku, Tokyo, Japan

**Introduction:** Laparoscopy-assisted gastrectomy (LAG) is being increasingly performed as a less-invasive treatment method for early gastric cancer in Japan. However, the feasibility and survival benefit of LAG in elderly patients who usually have preoperative morbidities still remains unclear.

**Material and Methods:** Among 485 patients who underwent LAG at the Cancer Institute Hospital, 394 cases were younger than 75 years old (Y-LAG) and 97 cases were 75 years or older (E-LAG). Operation time, intraoperative blood loss, postoperative hospital stay and the frequency and the severity of postoperative complications were compared retrospectively between two groups. And the cumulative survival rate was calculated using the Kaplan–Meier method to validate the significance of LAG for elderly patients.

**Results:** 1. Preoperative morbidities; In the E-LAG group, the number of the cases classified into Class 2 or 3 in ASA(American Society of Anesthesiologists) classification were 51 (52.6%) or 10 (10.3%) cases, respectively. 2. Early surgical outcomes; Operation time was significantly shorter in the E-LAG group compared to that in the Y-LAG group ( $214 \pm 54$  min vs.  $233 \pm 57$  min,  $P < 0.01$ ). Intraoperative blood loss in the E-LAG was not significantly different from that in the Y-LAG group ( $61 \pm 131$  ml vs.  $66 \pm 135$  ml,  $P = 0.75$ ). Postoperative hospital stay in the E-LAG was not significantly different from that in the Y-LAG group ( $14.0 \pm 6.6$  days vs.  $12.7 \pm 6.9$  days,  $P = 0.09$ ). The frequency of postoperative complications classified above Grade IIIa in Clavien-Dindo classification of surgical complications in the E-LAG group was not significantly different from the Y-LAG group (5.2% vs. 7.2%,  $P = 0.62$ ). 3. Outcome; In the E-LAG group, the number of the cases classified into Stage IA, Stage IB, Stage II and Stage IIIA were 72 (74.2%), 17 (17.5%), 5 (5.2%) and 3 (3.1%) cases, respectively. The 3-years overall survival rates were 100% in StageIA, 84.9% in StageIB, 80% in Stage II and 100% in Stage IIIA (The median observation period was 28.3 months). Three patients died during the observation period and one patient died of liver metastasis from gastric cancer and other two patients died of other diseases.

**Conclusion:** LAG proved to be a feasible and safe procedure in elderly patients provided that the patients were selected carefully. Although the 3 year-survival was satisfactory, a further observation is necessary to consider the meaning of LAG for elderly patients.

**Abstract ID: 0815** Specific Field: **Stomach/Duodenum**

**Mode of pres.: Poster Exhibition only**  
**ISW 2011 Session PE 285**

**Laparoscopic surgery for gastric cancer in patients 80 years or older**

H. Mieno, S. Sakuramoto, T. Shibata, M. Nemoto, K. Yamashita, N. Katada, S. Kikuchi, M. Watanabe

Department of Surgery, Kitasato University School of Medicine, Sagami-hara, Japan

**Introduction:** In Japan, elderly persons account for more than 20% of the total population. Surgical therapy is already a routine treatment even in the very elderly, many of whom have concurrent diseases. Laparoscopic gastrectomy (LAG), a widely used minimally invasive procedure, is often performed in elderly patients.

**Material and Methods:** The study group comprised 46 patients 80 years or older who underwent resection of gastric cancer in our



hospital from January 2006 through December 2009. We compared short-term outcomes between LAG and open gastrectomy (OG).

**Results:** The 46 patients comprised 25 men and 21 women with a median age of 82 years (range, 80 to 91). Twenty-five patients had early gastric cancer, and 21 had advanced gastric cancer. The surgical procedure was LAG in 22 patients, and OG in 24. Distal gastrectomy was performed in 13 patients in the LAG group and 14 in the OG group. Total gastrectomy was performed in 0 patients in the LAG group and 5 in the OAG group. Proximal gastrectomy was performed in 4 patients in the LAG group and 3 in the OG group. Other procedures were done in 5 patients in the LAG group and 2 in the OG group. The operation time was significantly longer in the LAG group ( $233.1 \pm 46.7$  min) than in the open surgery group ( $185.7 \pm 53.1$  min,  $P = 0.002$ ). In contrast, the bleeding volume was significantly lower in the LAG group ( $67.5 \pm 45.9$  ml) than in the OG group ( $349.0 \pm 301.1$  ml,  $P < 0.01$ ). The incidence of complications did not differ significantly between the LAG group (31.8%, 7/22) and the OG group (29.2%, 7/24). No patient died during the hospital stay in either group.

**Conclusion:** Laparoscopic surgery can be performed safely in elderly patients with gastric cancer, similar to open surgery.

#### Abstract ID: 0816 Specific Field: Stomach/Duodenum

Mode of pres.: Poster Exhibition only  
ISW 2011 Session PE 287

##### The impact of new concept of linear stapler (Duet TRSTM) on laparoscopy-assist gastrectomy (LAG)

K. Muguruma [1], M. Ohira [1], H. Tanaka [1], K. Sakurai [1], N. Kubo [1], Y. Yamashita [2], T. Sawada [3], K. Hirakawa [1]

[1] Osaka City University Graduate School of Medicine, Osaka, Japan, [2] Osaka Municipal General Medical Center, Osaka, Japan, [3] Osaka Ekisaikai Hospital, Osaka, Japan

**Introduction:** Recently, laparoscopy-assist gastrectomy (LAG) have widely spread and attempt to try for more advanced gastric cancers. In our department, we experienced more than 170 cases of LAG after induction of it on April 2000, and completed the fixed procedure in terms of operation method, including anastomosis. The year before last, suture instruments of coming generation with new approach to tissue reinforcement; endostapling with fully integrated tissue reinforcement film (Duet TRS<sup>TM</sup>, COVIDIEN, Mansfield, MA, USA) were appeared, and we immediately introduced them into LAG. In this present study, we report the short term result and utility about them.

**Material and Methods:** After usual lymphadenectomy, we used Duet TRS<sup>TM</sup> on transection of duodenum and stomach. Until now, we used them 51 cases of LAG.

**Results:** In all cases, we used one cartridge for transection of duodenum and two for stomach. The hemostasis of cut end on duodenum and stomach was completely, and the transparent material allows easy inspection of the staples and transected materials. No obvious insufficiency of cut end on duodenum and stomach was recognized yet.

**Conclusion:** We have successfully performed LAG with using this devices in 51 patients without any major complications, such as postoperative bleeding or insufficiency of cut end. We expect that this device is secure and reliable for bleeding or tissue adhesion, and enables shortening of operation time in terms of elimination of the need for the conventional sero-sero suture for tissue reinforcement on cut end of duodenum and stomach.

#### Abstract ID: 0817 Specific Field: Stomach/Duodenum

Mode of pres.: Poster Exhibition only  
ISW 2011 Session PE 288

##### Laparoscopic gastrectomy for advanced gastric cancer with positive peritoneal cytology

N. Yamanaka, E. Nagai, T. Aso, K. Ohuchida, J. Ueda, H. Toma, S. Shimizu, M. Tanaka

Department of Surgery and Oncology, Kyushu university, Fukuoka, Japan

**Introduction:** Positive peritoneal cytology is a predictor of poor prognosis in patients with gastric cancer. The role of gastrectomy remains unclear for patients with positive peritoneal cytology but negative macroscopic peritoneal implant (POCY1). Recently, the prognostic benefit by surgical resection for the POCY1 patients has been expected by adding chemotherapy. However, surgical resection may be harmful for the POCY1 patients, so laparoscopic gastrectomy, which has been done for safety and evaluated minimally invasive for gastric cancer patients, is expected to be useful for the POCY1 patients. The aim of this study is the evaluation of laparoscopic gastrectomy for the POCY1 patients.

**Material and Methods:** A prospectively maintained gastric cancer database of gastric cancer patients who underwent surgical resection was reviewed. Immediately after laparotomy or insertion of laparoscope, the pouch of Douglas was washed with 100 ml of physiologic saline solution, and the fluid was collected for cytologic examination using Giemsa and Papanicolaou staining methods. Positive peritoneal cytology without macroscopic peritoneal dissemination or distant organ metastases was considered operable. Laparoscopic gastrectomy with nodal dissection has been performed in the POCY1 patients without invasion to other organs since 2008.

**Results:** During the period 2000–2010 as series of 431 consecutive patients underwent surgery for gastric cancer that had invaded muscularis propria or deeper layers of the stomach wall. According to the macroscopic (P) and cytologic (CY) results, the 18 patients were POCY1 without distant organ metastases. Laparoscopic gastrectomy with nodal dissection was performed in 8 POCY1 patients. The mean follow-up period of the group underwent laparoscopic gastrectomy is 9.6 months, the average length of postoperative hospital stay is 13.8 days, three cases revealed recurrence and 5 cases survived without disease. All these patients required postoperative chemotherapy, such as S-1, that was not interfered by laparoscopic surgery.

**Conclusion:** Laparoscopic gastrectomy was minimally invasive and safe for the POCY1 patients and adjuvant chemotherapy after laparoscopic surgery could be started immediately. Laparoscopic gastrectomy for advanced gastric cancer with POCY1 may be beneficial.

#### Abstract ID: 0818 Specific Field: Stomach/Duodenum

Mode of pres.: Poster Exhibition only  
ISW 2011 Session PE 289

##### Development of an artificial gastric wall using bioabsorbable polymer sheet

M. Miyazawa, M. Aikawa, I. Koyama, S. Yamaguchi, K. Okada, K. Okamoto, Y. Toshimitsu, K. Takase

Saitama Medical University International Medical Center, Japan

**Introduction:** The growing prevalence of endoscopic surgery, a minimally invasive procedure, has helped to minimize wounds on the

body surface in recent years. The procedure fails, however, in allowing regeneration of a resected digestive tract, and this compromises the postoperative maintenance of digestive functions after various transplantations. Our group has developed an artificial gastric wall (AGW) of bioabsorbable polymer (BAP) in the hopes of preserving the stomach by repairing defects without stenosis or deformity. In this study we investigated whether a BAP patch could repair and regenerate a widely defective gastric wall in an animal model.

**Material and Methods:** Hybrid pigs were laparotomized under general anesthesia. A 8 × 8 cm round-shaped portion (about half of the perimeter) of the anterior gastric wall was excised and replaced by a AGW at the excision site. The AGW was composed of a 50:50 copolymer of lactic acid and caprolactone reinforced with polyglycolic acid fibers. There was no prior cell seeding or other preparatory treatment for the AGW. Four, eight, twelve weeks after implantation, the animals were respectively re-laparotomized and underwent resections of the whole stomach for exploration of the graft sites by gross and histological studies.

**Results:** All of the recipient pigs survived until sacrifice without any decreases in oral intake. At 4–8 weeks, the graft site revealed ulcer reducing by the day. Twelve weeks after AGW implantation, the grafted area was identical to the native stomach both macroscopically and in gross structure. The structures of the regenerated mucous membrane and muscle layers were also identical to those of the native stomach, and functional proton pumps were found in the regenerated tissue.

**Conclusion:** The effects of these BAP sheets in facilitating stomach regeneration may lead to a novel treatment modality after gastrectomy for stomach cancer.

**Abstract ID: 0819** Specific Field: **Stomach/Duodenum**

**Mode of pres.: Poster Exhibition only**  
**ISW 2011 Session PE 290**

**Application of hypereye charge coupled device camera system for detecting indocyanine green fluorescence to the gastric cancer surgery**

T. Nakamura [1], M. Yoshida [2], M. Kitajima [2], N. Nitori [2], K. Matsubara [3], Y. Kato [4], J. Saitou [1], Y. Kitagawa [3]

[1] Division of Surgery, Inagi Municipal Hospital, Tokyo, Japan, [2] Department of Surgery, Center for Digestive Diseases, International University of Health and Welfare Mita Hospital, Tokyo, Japan, [3] Department of Surgery, Keio University School of Medicine, Tokyo, Japan, [4] Department of Surgery, Fujita Health University School of Medicine, Aichi, Japan

**Introduction:** Perioperative navigation such as the sentinel lymph node biopsy is devised as a method of the individualization surgery. The reported sensitivity of the radioisotope + dye method (dual tracer method) is satisfactory for detecting sentinel nodes in the gastric cancer surgery. The dye method is a simple method that can be conducted in a community hospital without the approved area for injection of the radioactive colloid nor special equipments. However, it is unsuitable for long-time observation, deep layer observation and back table observation.

In comparison with the dye-guided method, Hyper Eye charge coupled device camera system, for detecting indocyanine green fluorescence is more sensitive and allows visualization of the lymph nodes when indocyanine green is injected the day before surgery. The ordinal detection system for indocyanine green fluorescence is gray scale imaging and requires a dark room. The operation is interrupted

during the observation of the fluorescence. We developed a new device, Hyper Eye charge coupled device camera system, for detecting indocyanine green fluorescence. This system can simultaneously detect color and near-infrared rays and can be used under bright light. The operation can be continued, simultaneously, under the guidance of indocyanine green fluorescence.

Our group had made experiments in swine for examining the effectiveness of the device to the sentinel node detection in digestive surgery. Experiments with swine showed that this system may be suitable for deep layer observation, long-time observation and back table observation. Indocyanine green fluorescence-guided sentinel node sampling can be performed under light. Then, our group made appraisal of this system to clinical use.

**Abstract ID: 0820** Specific Field: **Stomach/Duodenum**

**Mode of pres.: Poster Exhibition only**  
**ISW 2011 Session PE 291**

**Infrapyloric lymph node dissection based on the prepancreatic fascial structures in laparoscopic gastric cancer surgery**

H. Shinohara, Y. Kurahashi, R. Okamura, O. Inamoto, K. Yamashita, H. Araki, T. Nakamura, Y. Mizuno

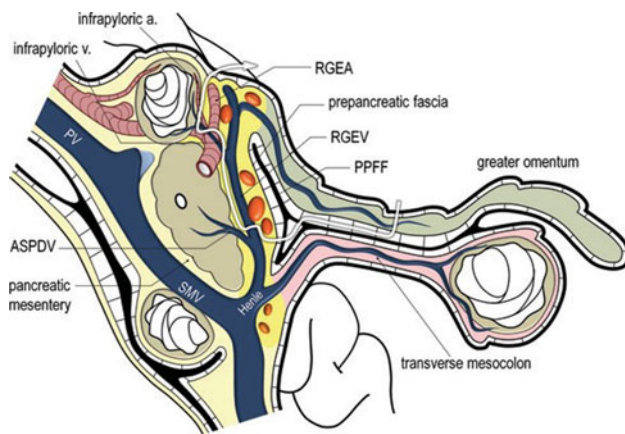
Hyogo Prefectural Amagasaki Hospital, Amagasaki, Japan

**Introduction:** Technological development of laparoscopic gastrectomy has become accepted as a surgical option for gastric cancer, and enabled surgeons to perform fine operations. However, dissection of the infrapyloric lymph nodes (IPLNs) adjacent to the right gastroepiploic vessels is still technically insecure, since injury of the pancreas results in annoying complications. Here we describe a technique for dissection of IPLNs based on the prepancreatic fascial structures.

**Material and Methods:** The greater omentum is divided rightward until the descending part of duodenum, and dissected from the surface of the transverse mesocolon. The dissected layer usually leads to a space on PPF, i.e., a mat membranous structure created by fusion between the peritoneum of greater omentum and pancreatic mesentery. Behind PPF, we can usually identify the confluence of the anterior superior pancreaticoduodenal vein (ASPDV) and the right gastroepiploic vein (RGEV), indicating the lower border of IPLNs (“first view point”). After incising PPF, sheer prepancreatic fascia will be appearing over RGEV (“second view point”). RGEV is then exposed and cut above the confluence. A fat tissue including IPLNs is removed from surface of the pancreas together with RGEV and the infrapyloric vein. Perivascular nerves are dissected to expose right gastroepiploic artery (“third view point”), and the artery is divided at its root. Finally, the infrapyloric artery is divided and IPLNs are completely dissected.

**Results:** The procedures were performed for 55 consecutive patients with T1/T2 gastric cancer. The mean operative time was 301 ± 34 min, and the estimated blood loss was 85 ± 64 g. The mean number of retrieved IPLNs was 5 ± 3. All operations were achieved laparoscopically, except in one patient with liver cirrhosis, who underwent conversion to open surgery because of a huge suprapancreatic varix. Any pancreas-related postoperative complications, such as intra-abdominal abscess or fistula, were not found. To date, no local or regional lymph node recurrences have been observed.

**Conclusion:** The described technique would allow surgeons to laparoscopically perform safe and precise dissection of IPLNs in patients with gastric cancer. PPF may be a useful landmark for surgical planes.



**Figure** Anatomy and procedure of IPLN dissection

**Abstract ID: 0821** Specific Field: **Stomach/Duodenum**

**Mode of pres.: Poster Exhibition only**  
**ISW 2011 Session PE 292**

#### Preoperative bone mineral density in gastric cancer patients

T. Katsube, M. Murayama, K. Yamaguchi, A. Miyaki, S. Asaka, N. Isohata, Y. Naritaka, K. Ogawa

Tokyo Women's Medical University Medical Center East, Tokyo, Japan

**Introduction:** It has been reported that there is a high rate of bone mineral density (BMD) loss after gastrectomy for gastric cancer. To clarify the course of postoperative BMD loss, it is necessary to precisely determine the preoperative BMD of gastric cancer patients.

**Material and Methods:** From October 2005 through September 2008, preoperative BMD was measured in 91 patients (59 males and 32 females, mean age of the patients was 67.3 years) who underwent gastrectomy for gastric cancer. Then, the percentage of the subject's BMD divided by the BMD of young adult mean (YAM) (% of YAM) was obtained for each subject and the incidence of osteoporosis as well as the relationship between % of YAM and the patient's clinicopathological factors or biochemical parameters was examined.

**Results:** The incidence of osteoporosis was 15.4%. There is a correlation between BMD in preoperative gastric cancer patients and serum albumin levels, and that BMD decreases further in the elderly and individuals with a BMI lower than 18.5.

**Conclusion:** From the viewpoint of osteoporosis prevention, this suggests the importance of nutritional management for elderly gastric cancer patients with associated nutritional disorder.

**Abstract ID: 0822** Specific Field: **Stomach/Duodenum**

**Mode of pres.: Poster Exhibition only**  
**ISW 2011 Session PE 293**

#### Double tract reconstruction after distal gastrectomy for gastric cancer is effective in reducing reflux esophagitis and remnant gastritis

T. Namikawa [1], H. Kitagawa [2], T. Okabayashi [2], T. Sugimoto [2], M. Kobayashi [2], K. Hanazaki [2]

[1] Kochi Medical School, Nankoku-City, Japan,  
[2] Kochi Medical School, Japan

**Introduction:** So far, there have been no reports that have evaluated double tract (DT) reconstruction after distal gastrectomy for gastric cancer, which maintains the duodenal passage of food. With this procedure, a gastrojejunostomy is performed as in the RY technique and a duodenojejunostomy is added approximately 7 cm distal from the gastrojejunostomy. The aim of this study was to evaluate the clinical significance of DT following distal gastrectomy.

**Material and Methods:** Outcomes following DT in 33 patients, Roux-en Y reconstruction (RY) in 38 patients, and Billroth I reconstruction (BI) in 47 patients were investigated retrospectively. Patients were compared in terms of postoperative esophagogastrosopic findings, the angle of His and the length of the lesser curvature of the remnant stomach as measured from postoperative esophagogastrography. The results of the quality of life as determined by the gastrointestinal symptom rating scale (GSRs) were compared among the three patient groups, until 1 year after surgery.

**Results:** The degree and extent of gastritis was significantly lower in patients who had undergone DT and RY compared with BI ( $P < 0.05$ ). Although the incidence of reflux esophagitis tended to be higher in the BI group compared with the DT and RY groups, the differences did not reach statistical significance. The angle of His was significantly greater in patients who had undergone BI rather than RY or DT reconstruction (107 degrees vs. 77.9 degrees vs. 84.3 degrees;  $P < 0.05$ ), and significantly greater in patients with reflux esophagitis than in those without reflux esophagitis (108.6 degrees vs. 80.6 degrees;  $P < 0.01$ ). Using the GSRs, patients who underwent DT and RY had significantly lower reflux and indigestion than patients who had undergone BI. The length of the lesser curvature of the remnant stomach did not differ significantly between the three reconstruction procedures.

**Conclusion:** Advantages of DT following distal gastrectomy include a reconstruction technique that maintains overall better outcomes such as reduced reflux esophagitis and remnant gastritis in addition to the physiological passage of food. It seems that DT is superior to RY reconstruction from the viewpoint of the potential future endoscopic requirements.

**Abstract ID: 0823** Specific Field: **Stomach/Duodenum**

**Mode of pres.: Poster Exhibition only**  
**ISW 2011 Session PE 294**

#### Prophylactic drain is not necessary for gastric cancer after distal gastrectomy

T. Iida [1], M. Iwahashi [1], M. Nakamori [1], M. Nakamura [1], T. Ojima [1], M. Kastuda [2], T. Tsuji [1], H. Yamaue [1]

[1] Wakayama Medical University, Wakayama, Japan,  
[2] Wakayama Medical University, Japan

**Introduction:** Prophylactic drain for major abdominal surgery has been widely practiced, although there were no scientific evidence to support it. In our department, we had routinely inserted prophylactic drains in a distal gastrectomy with the standard lymphadenectomy for gastric cancer before 2005. After a 2-year transition term, we have not inserted prophylactic drains after 2007. In this study, we examined significance of prophylactic drains in the distal gastrectomy.

**Material and Methods:** The medical records of 422 consecutive patients who had underwent distal gastrectomy with D1 or D2 lymph node dissection between January 2004 and December 2009 were retrospectively reviewed. We examined postoperative complications,



activities of daily living (ADL) and serum C-reactive protein (CRP) level.

**Results:** The prophylactic drains were inserted in 158 patients (the drain group), and were not in 264 (no-drain group). The median duration of drain placement was 3.21 (2–6) days. Each group had two postoperative complications, there was no statistical significance. The complication in the drain group showed one pancreatic fistula (0.63%) and one gastrojejunostomy leak (0.63%). Both cases needed percutaneous additional drainage. Also the complication in the no-drain group showed one pancreatic fistula (0.37%) and one gastrojejunostomy leak (0.37%). Those complications were successfully managed by percutaneous drainage without laparotomy. In patients who underwent open gastrectomy, the frequency of the analgesic agent was significantly higher in drain group (1.33 + 1.61 times) than in no drain group (1.14 + 1.80 times) ( $P < 0.05$ ). The serum CRP level were also higher in drain group (9.86 + 5.45 mg/dl) than in no drain group (7.29 + 4.31 mg/dl) at postoperative day 4 ( $P < 0.0001$ ). In terms of postoperative ADL, postoperative days until walking outside a room were shorter in no-drain group than drain group, regardless of the approach for gastrectomy. Also, a postoperative fever term tended to be longer in drain group than in no-drain group.

**Conclusion:** There were no clinical benefits of the prophylactic drains in the distal gastrectomy for gastric cancer. The prophylactic drain is not necessary after distal gastrectomy with the standard lymphadenectomy.

#### Abstract ID: 0824 Specific Field: Stomach/Duodenum

Mode of pres.: Poster Exhibition only  
ISW 2011 Session PE 295

##### Prognostic impact of the gastric cancer patients with post-operative complications

T. Kubota, N. Hiki, T. Yamaguchi, T. Sano, S. Nunobe, S. Tanimura, K. Kumagai, S. Aiko

Cancer Institute Hospital, Japanese Foundation for Cancer Research, Tokyo, Japan

**Introduction:** Anastomotic leakage, a major complication of post-gastrectomy, has recently been reported to affect the prognosis of the patients with gastric cancer. The aim of this study is to reveal the prognostic impact of gastric cancer patients with post-operative complications.

**Material and Methods:** We reviewed 1182 patients who underwent gastrectomy at Cancer Institute Hospital, Japanese Foundation for Cancer Research, Tokyo, from March 2005 to December 2007. We evaluate post-operative complications using Clavien-Dindo classification and divided the patients into 2 groups, complication group (more than Clavien-Dindo grade 2) and no complication group. Tumor staging was evaluated according to the 13th edition of Japanese classification of gastric cancer.

**Results:** The average age of the patients was  $63.3 \pm 11.4$  years old (range; 28–90). The male:female ratio was 7:4. Surgical procedure (Laparoscopic surgery): distal gastrectomy 597 (225), total gastrectomy 187 (138), pylorus preserving gastrectomy 187 (138), proximal gastrectomy 49 (28), segmental/partial resection 15 (0). The median follow-up duration was 24 months. Three-year survival rate of each pathological Stage ( $P$  Stage) I/II/III/IV was 94.3/81.6/64.5/33.2%, respectively. Complication more than grade 2 was observed in 139 patients (11.8%). Of these patients, anastomotic leakage was observed in 39 (3.3%), post-operative bleeding in 10 (0.8%), pancreatic fistula in 23 (1.9%), abdominal infection/abscess in 22 (1.9%), ileus in 7 (0.6%), stasis in 14 (1.2%), wound infection in 8 (0.7%), bile leakage in 5 (0.4%). The 3-year survival of the complication group was significantly worse than that of no complication group (56.2% vs. 80.9%).

**Conclusion:** Our data revealed that post-operative complications made the prognosis worse in gastric cancer patients.

#### Abstract ID: 0825 Specific Field: Stomach/Duodenum

Mode of pres.: Poster Exhibition only  
ISW 2011 Session PE 296

##### Duodeno-jejunal motility in patients after distal gastrectomy and pylorus-preserving gastrectomy for early gastric cancer

K. Nishikawa [1], T. Yumiba [2], T. Nishida [3], S. Endo [4], T. Takahashi [1], K. Iwase [1], Y. Tanaka [1], T. Ito [5]

[1] Osaka General Medical Center, Osaka, Japan, [2] Osaka Koseinenkin Hospital, Osaka, Japan, [3] Osaka Police Hospital, Osaka, Japan, [4] National Hospital Organization Kure Medical Center, Kure, Japan, [5] Osaka University Graduate School of Medicine, Osaka, Japan

**Introduction:** Duodeno-jejunal motility after gastric surgery frequently is disturbed and results in postoperative intestinal symptoms and poor quality of life (QOL). Distal gastrectomy (DG) and pylorus-preserving gastrectomy (PPG) have been employed for gastric cancer, with PPG having been reported to be superior to DG in regard to postoperative QOL. In this study, we aimed to investigate the early and late postoperative duodeno-jejunal motility in patients undergoing DG and PPG.

**Material and Methods:** Duodeno-jejunal manometric study was performed in 12 patients within 2 month after DG (DG-E group) and 9 patients after PPG (PPG-E group), in 6 patients more than 1 year after DG (DG-L group) and 7 patients after PPG (PPG-L group), and in 20 preoperative patients (C group). Duration, velocity of Migrating Motor Complex (MMC) phase III and interval of each phase III were evaluated. We observed abnormal phase III activities such as short duration less than 3 min, short interval less than 30 min, no aboral migration, not followed phase I, with over 10 mmHg tonic component and low amplitude less than 20 mmHg.

**Results:** All patients except for one patient in DG-E group showed MMC phase III. Duration was 283, 318, 338, 387, 370 s in DG-E, PPG-E, DG-L, PPG-L, and C group, respectively. Velocity and interval were 4.2, 5.2, 4.9, 5.3, 8.8 cm/min and 53, 71, 56, 76, 112 min in each groups. Short duration and short interval were observed 54.5, 11.1, 0, 0, 5% and 63.6, 11.1, 20, 0, 5% in each groups. No aboral migration, not followed phase I, with tonic component and low amplitude were observed 72.7, 44.4, 66.7, 28.6, 10%, 81.8, 44.4, 66.7, 28.6, 10%, 81.8, 44.4, 66.7, 14.3, 14% and 54.5, 22.2, 0, 0, 0% in each groups, respectively. Velocity and interval were significantly lower in postoperative group compared with in C group. Abnormal phase III activities were higher in postoperative group compared with in C group. Although these were improved in L group compared with in E group. In post-operative groups, DG group showed lower velocity and interval, frequent abnormal phase III activities compared with PPG group.

**Conclusion:** Duodeno-jejunal manometric study revealed that PPG patients were associated with better duodeno-jejunal motility than DG patients.

#### Abstract ID: 0826 Specific Field: Stomach/Duodenum

Mode of pres.: Poster Exhibition only  
ISW 2011 Session PE 297

##### Postoperative morbidity and mortality in elderly patients with gastric cancer



M. Aoki, T. Igarashi, T. Kawashima, H. Kido, H. Tamura, M. Kojima, T. Amemiya

Ohtawara Red Cross Hospital, Ohtawara city, Tochigi, Japan

**Introduction:** With an aging society, elderly gastric cancer patients have been increasing in Japan. The early postoperative complication in elderly gastric patients often becomes severe. The aim of this study was to elucidate the factor influencing early postoperative complication/death and to evaluate the significance of the preoperative nutritional management.

**Material and Methods:** A retrospective analysis was undertaken of 47 patients over the 80 years old who had undergone gastrectomy from January 2002 to April 2009 in our institute. A total of 12 patients (25.5%) with early postoperative complication, within 2 weeks after surgery, were classified as complication group (C) and 30 patients (63.8%) as non-complication group (NC). 5 patients were excluded from this study because of late postoperative complication. The two groups were analyzed based on clinicopathological characteristics, surgical records. Furthermore, we also validate the correlation between preoperative nutrition management with early postoperative complication and death.

**Results:** There was no significant difference in clinicopathological characteristics and surgical records between the two groups. The mean value of Cholinesterase and total cholesterol in group C was lower than that one in group NC (respectively,  $P = 0.073$ ,  $0.084$ ). The morbidity and mortality in preoperative intravenous nutrition alone were significantly higher than that in enteral nutrition (respectively,  $P = 0.022$ ,  $0.004$ ). The mortality in preoperative insufficient energy administration was significantly higher than that in sufficient ( $P = 0.042$ ).

**Conclusion:** An appropriate preoperative nutritional management in elderly gastric cancer patients is vital to decrease the morbidity and mortality.

**Abstract ID: 0827** Specific Field: **Stomach/Duodenum**

**Mode of pres.: Poster Exhibition only**  
**ISW 2011 Session PE 298**

#### Examination of Roux stasis syndrome after distal gastrectomy

T. Matsumoto, M. Sasako, S. Kikuchi, M. Takemura, T. Hori, K. Koishi, N. Kaibe, H. Yamashita

Hyogo College of Medicine, Nishinomiya, Japan

**Introduction:** Billroth 1 or Billroth 2 is the commonest reconstruction procedure after a distal gastrectomy in Japan, whereas Roux-en Y (R-Y) method is getting popular like western countries. The main advantage of R-Y procedure is rareness of anastomotic leak and prevention of alkaline reflux gastritis, but this procedure may be accompanied some postoperative problems, including so-called Roux stasis syndrome (RSS). This retrospective study aimed to analyze the incidence of RSS by our reconstructive technique after distal gastrectomy.

**Material and Methods:** We defined RSS as symptoms characterized by chronic abdominal pain, persistent nausea, and intermittent vomiting, which were not caused by stricture of gastrojejunostomy in this study. During three-year period from August 2007, 155 patients underwent a distal gastrectomy and R-Y reconstruction. It consisted of 94 men and 61 women, the median age was 68 (33–92) years. Seventy-one patients were diagnosed as pT1 (45.8%) and eighty-four patients were diagnosed as more than pT2 (54.2%). For the R-Y procedure, we cut the stomach at 5 cm or more proximal to the Demel's watershed and gastrojejunostomy was performed via

the retrocolic route at the left side of the middle colic vein, with the length of the Roux limb at about 30 cm. Anastomosis was performed as an end-to-side gastrojejunostomy with reversed peristalsis positioning. We fixed the remnant stomach to the transverse meso-colon. D2 lymph node dissection was performed in most cases (98.7%).

**Results:** RSS occurred in 3 patients (1.94%, 95% confidence interval: 0–4.1%).

**Conclusion:** This incidence is much lower than previous reported incidence rates. We suggested that the capacity of the remnant stomach and its fixation to the mesentery contributed to the reduction of RSS.

**Abstract ID: 0828** Specific Field: **Stomach/Duodenum**

**Mode of pres.: Poster Exhibition only**  
**ISW 2011 Session PE 299**

#### Impact of postoperative infection on long-term survival after potentially curative resection for gastric cancer

H. Tsujimoto, T. Ichikura, S. Hiraki, R. Takahata, S. Nomura, S. Ono, J. Yamamoto, K. Hase

National Defense Medical College, Tokorozawa, Japan

**Introduction:** Postoperative surgical and medical complications have been implicated as a negative predictor of long-term outcome in various malignancies. However, there have been no published reports assessing the impact of complications arising from postoperative infection on survival in gastric cancer. In this study, we focused on the impact of postoperative infection on long-term survival after potentially curative resection for gastric cancer.

**Material and Methods:** We studied a population of 1332 patients who underwent curative resection for gastric cancer. These patients were divided into two groups based on the occurrence (141 patients, 10.6%) or absence (1,191 patients; 89.4%) of postoperative complications due to infection. We investigated the demographic and clinicopathological features of each patient with and without postoperative complications from infection, and thereby the impact of postoperative infection on long-term survival.

**Results:** Patients with postoperative infection had significantly higher frequency of males, aged, upper side of tumor location, total gastrectomy as a surgical procedure, and more advanced stage of gastric cancer as compared to those without postoperative infection. Patients with complications due to postoperative infection had a significantly more unfavorable outcome compared with those patients without postoperative infection. Multivariate analysis demonstrated that age, preoperative co-morbidity, blood transfusion, tumor depth, nodal involvement, and postoperative infection correlated with overall survival.

**Conclusion:** Postoperative complications from infection are a predictor of adverse clinical outcome in patients with gastric cancer. However, further immunological study and prospective trials are necessary to confirm the biological significance of these findings.

**Abstract ID: 0829** Specific Field: **Stomach/Duodenum**

**Mode of pres.: Poster Exhibition only**  
**ISW 2011 Session PE 300**

#### Retrospective analysis for prognostic outcome of gastric cancer in young patients

R. Nakamura, Y. Saikawa, T. Oyama, T. Takahashi, N. Wada, H. Takeuchi

Department of Surgery, School of Medicine, Keio University, Tokyo, Japan

**Introduction:** It has been suggested that gastric cancer in young patients has a worse prognosis than in older patients, but this is controversial. This retrospective investigation was undertaken to evaluate whether the prognosis of young patients are equal to or poorer than that of older patients in fact and to understand the clinicopathological features and identify the prognostic factors of gastric cancer in young patients.

**Material and Methods:** Patients included in this study were those treated and followed for gastric cancer from 1989 to 2005. Operative records, clinical, pathological, and follow-up data were reviewed. The critical age cut-off value for obtaining distinctive prognoses using Receiver Operating Characteristic (ROC) curve was 34 years. Of 1730 gastric cancer patients whose records were reviewed, there were 27 patients aged less than 34 years old (34L group) and 1703 patients aged 34 years or more (34U group).

**Results:** 34L group contained significantly higher percentages of female, stage IV, macroscopic type 4 tumors, poorly-differentiated histology, peritoneal dissemination, and epigastric pain symptoms than 34U group. Survival in the 34L group was significantly worse compared to the 34U group ( $P = 0.0363$ ). Survival rates at 10 years were 68.5% in the 34L and 81.8% in the 34U groups. Prognosis of 34L patients detected in early stage is equal to that of 34U patients, while survival in 34L was poorer for the stage IV patients, compared to 34U patients, especially for the stage IV patients with peritoneal dissemination and without liver metastases (HOP1 patients) ( $P = 0.049$ ). The most 34L patients in advanced stage had tendency to have peritoneal dissemination as recurrence and died from peritoneal dissemination.

**Conclusion:** Age in gastric cancer affects the prognosis. In this study, we showed that survival in HOP1 stage IV 34L patients and survival in all 34L patients was statistically worse compared with survival in 34U patients, and peritoneal dissemination was seen to be a poor prognostic factor in 34L patients.

**Abstract ID: 0830** Specific Field: **Stomach/Duodenum**

**Mode of pres.: Poster Exhibition only**  
**ISW 2011 Session PE 301**

**Clinical factors and ISGPF classification to predict the severity of pancreatic fistula following gastrectomy in gastric cancer**

S. Komatsu, D. Ichikawa, E. Otsuji

Division of Digestive Surgery, Department of Surgery, Kyoto Prefectural University of Medicine, Kyoto, Japan

**Introduction:** Pancreatic fistula (PF) following gastrectomy for gastric cancer is one of the lethal complications. However, there has never been no accepted prognostic factors. This study was designed to investigate prognostic factors and evaluate the significance of International Study Group on Pancreatic Fistula (ISGPF) classification to identify high-risk patients.

**Material and Methods:** Between 1997 and 2010, 1341 consecutive patients underwent gastrectomy for gastric cancer. Of these, 35 patients (2.61%) were diagnosed as PF and treated intensively. Several clinical factors and perioperative laboratory data were analyzed as possible predictive factors, and ISGPF classification was also evaluated retrospectively.

**Results:** 1) The median treatment periods for PF were 28 (4–210) days. Of 35 PF patients, 17 (48.6%) patients were classified in Grade B and 18 (51.4%) patients in Grade C according to ISGPF

classification. 2) The ISGPF classification was found to be a significant independent variable to predict treatment period on multivariate analysis. 3) Concerning clinical factors and classification to predict treatment period, ISGPF classification was a significant independent variable according to the logistic regression model. 4) Regarding clinical factors to predict the severity of PF, patients age ( $P < 0.05$ ) and lymphocyte counts ( $P < 0.05$ ) were significantly correlated with ISGPF grade. The lymphocyte count was a significant independent variable.

**Conclusion:** ISGPF classification was reliable prognostic factor, and intensive care should be required for PF patients with older age and a low postoperative marker of lymphocyte counts.

**Abstract ID: 0831** Specific Field: **Stomach/Duodenum**

**Mode of pres.: Poster Exhibition only**  
**ISW 2011 Session PE 302**

**Evaluation of changes in clinicopathological features and survival following gastrectomy for gastric cancer over a 37-year period**

T. Ishimoto, D. Ichikawa, E. Otsuji

Kyoto Prefectural University of Medicine, Kyoto, Japan

**Introduction:** Recent prevalence of endoscopic screening and advances in treatment technology has led to improvement of gastric cancer treatments. Particularly, the proportion of early gastric cancer patients and elderly patients is increasing. This study was designed to investigate changes in clinicopathological features and survival following gastrectomy for gastric cancer over a 37-year period at our institute.

**Material and Methods:** Between 1970 and 2006, 2284 consecutive patients underwent gastrectomy for gastric cancer. Of these, 1651 patients were treated in between 1970 and 1999 (previous period) and 663 patients were treated in between 2000 and 2006 (later period).

**Results:** (1) Compared with previous period patients, later period patients were significantly associated with elderly patients over 80 years old, tumor in upper-third stomach, a presence of venous invasion, earlier tumor stage, lesser treatment death, lesser recurrence and R0 or R1 resection. (2) Comparing survival rate of both groups, 5-year survival rate of later period was improving in elderly patients, female, patients with tumor in middle stomach, patients with undifferentiated type and patients with R2 resection. However, patients with tumor in upper-third stomach and young patients under 40 years old showed no improvement of survival rate.

**Conclusion:** Recently, incidence of elderly patients and patients with tumor in upper-third stomach was increasing. Patients with tumor in upper-third stomach should be specifically targeted in the effort to improve the prognosis.

**Abstract ID: 0832** Specific Field: **Stomach/Duodenum**

**Mode of pres.: Poster Exhibition only**  
**ISW 2011 Session PE 303**

**Microscopic cancer cell deposits in gastric cancer: whole-section analysis of mesogastrium**

A. Ohki, N. Abe, M. Sugiyama

Kyorin University Hospital, Tokyo, Japan

**Introduction:** On routine pathologic examination of resected gastric cancer specimens, cancer cells are often found in the adipose connective

tissue apart from the primary lesion or around the lymph nodes. Furthermore, several reports suggested that such a pathological finding could be an independent negative prognostic factor for postoperative survival. However, the methodologies to detect these cancer cells were inconsistent among studies. To investigate the incidence and distribution of the microscopic cancer cell deposits around the lymph nodes, whole-section analysis of the mesogastrium was conducted.

**Material and Methods:** One thousand five hundred fifty-two sections of the mesogastrium obtained from 37 patients with gastric cancer were examined. To accurately identify cancer cell deposits, an anti-human cytokeratin antibody (AE1/3, DAKO, Copenhagen, Denmark) was used. A monoclonal antibody D2-40 (Signet Laboratories, Dedham, MA, USA), a specific marker of lymphatic vessels, was also used to identify lymphatic vessels.

**Results:** As a whole, microscopic deposits were detected in three (8%) of the 37 patients examined. Microscopic deposits were found in three of the 12 patients with advanced cancer, while not in 25 patients with early stage cancer, which was defined as a lesion confined to the mucosa or submucosa regardless of the presence or absence of lymph node metastasis. The distributions of microscopic deposits were classified into three types: cancer cell deposits in adipose connective tissue apart from the primary lesion or around the metastatic lymph nodes in 3 cases, cancer cell deposits in the lymphatic vessels in 2 cases, and cancer cell deposits as the result of the rupture of the metastatic lymph node capsule followed by infiltration around lymph nodes in 2 cases. These patients had an undifferentiated type of tumor (two with poorly differentiated adenocarcinoma, and one with mucinous adenocarcinoma), lymph node metastasis, and peritumoral lymphatic invasion.

**Conclusion:** Microscopic cancer cell deposits may be present in the mesogastrium apart from metastatic lymph nodes. Therefore, we should pay particular attention to the potential existence of microscopic deposits when curative resection of gastric cancer is attempted.

**Abstract ID: 0833** Specific Field: **Stomach/Duodenum**

**Mode of pres.: Poster Exhibition only**  
**ISW 2011 Session PE 304**

**Prognosis of metastatic splenic hilum lymph node in patients with gastric cancer after total gastrectomy and splenectomy**

K. Aoyagi, K. Kouhujii, M. Miyagi, T. Imaizumi, J. Kizaki, T. Isobe, K. Shirouzu

Kurume University, Kurume, Japan

**Introduction:** Some complications in splenectomy, for example pancreatic fistula and left subdiaphragmatic abscess, sometimes occur, and splenectomy has been associated with increased morbidity after gastrectomy for gastric cancer. To clarify the significance of combined resection of the spleen to dissect the No.10 lymph node (LN).

**Material and Methods:** We studied 191 patients who had undergone total gastrectomy with splenectomy. Various clinicopathological factors were evaluated for any independent contributions to No.10 LN metastasis, using  $\chi^2$  test. Significant factors were extracted for further analysis, carried out using a logistic regression method. Furthermore, lymph node metastasis was evaluated for any independent contribution to No.10 LN metastasis, using the same methods. The cumulative survival rate was calculated using the Kaplan–Meier method. The significance of any difference between the survival curves was determined using the Cox-Mantel test, and any difference was considered significant at the 5% level.

**Results:** From the variables considered to be potentially associated with No.10 LN metastasis, age, depth, invasion of lymph vessel, N factor, the number of lymph node metastasis, Stage, the number of site, and location were found to differ significantly between those

with metastasis (the Positive Group) and those without (the Negative Group). A logistic regression analysis showed that the localization and Stage were significant parameters for No.10 LN metastasis. There was no case located on the lesser curvature in the Positive Group. A logistic regression analysis showed that No.4sa, No.4sb, and No.11 LN metastasis were each a significant parameter for No.10 LN metastasis. There was no significant difference in survival curves between the Positive Group and the Negative Group.

**Conclusion:** Splenectomy should be performed performed to dissect No.10 LN for cases which have No.4sa, No.4sb or No.11 LN metastasis. However, in cases with the tumor located on the lesser curvature, splenectomy can be omitted.

**Abstract ID: 0834** Specific Field: **Stomach/Duodenum**

**Mode of pres.: Poster Exhibition only**  
**ISW 2011 Session PE 305**

**Strategy for submucosal invasive stomach cancer**

R. Yamada

Yokohama City University School of Medicine, Yokohama, Japan

**Introduction:** We treated submucosal invasion (SM) stomach cancer by mainly gastrectomy with conventional lymph node dissection according to the Japanese guideline. But recently modified lymphadenectomy using sentinel node navigation surgery, less invasive procedure, were performed in some cases. The aim of this study is to evaluate the validity of our strategy.

**Material and Methods:** We performed gastrectomy for 760 cases with stomach cancer in Department of Surgery, Yokohama City University from 1992 to 2010.162 cases (21%) with SM stomach cancer treated with R0 gastrectomy were enrolled in this study. We evaluated the correlation between the pathological finding and the location of lymph node stations..

**Results:** 26 cases (16%) involved lymph node metastasis. Multivariate analysis using logistic regression model indicates that the only tumor size >30 mm was independent risk factor. Patient's age, gender, tumor location,, macroscopic type, differentiation of cell and vessel invasion showed no relationship with lymph node state. One patient died of liver recurrence, 4 patients died of another diseases. All of lymph nodes with metastasis are regional. 4 cases have the distant lymph node metastasis with regional lymph node metastasis.

**Conclusion:** Modified lymph node dissection using sentinel node navigation system can be challenging for SM stomach cancer.

**Abstract ID: 0835** Specific Field: **Stomach/Duodenum**

**Mode of pres.: Poster Exhibition only**  
**ISW 2011 Session PE 306**

**Neoadjuvant chemotherapy with S-1 and cisplatin in locally-advanced resectable gastric cancer**

H. sasaki, H. idani, S. Asami, H. Kin, N. Takakura

Fukuyama City Hospital, Fukuyama, Japan

**Introduction:** In Japan, S-1 plus cisplatin (S-1/CDDP) chemotherapy is currently the most commonly used first-line chemotherapeutic regimen in patients with advanced gastric cancer. The aims of neoadjuvant chemotherapy include enhancement of curability by tumor down-staging, eradication of micrometastases outside the surgical field, and preoperative acquisition of information about in vivo drug

sensitivity. The neoadjuvant approach has the potential to help overcome problems such as low R0 resection rate and poor prognosis in the treatment of advanced gastric cancer, and various neoadjuvant trials have been conducted.

**Material and Methods:** Patients suffering from locally-advanced (T3-4 any N M0 or any T N1-3 M0) gastric cancer, staged with endoscopy, barium meal and computed tomography. S-1 was administered orally (80 mg/m<sup>2</sup>/day) twice daily for 21 consecutive days, and cisplatin (60 mg/m<sup>2</sup>) was infused over 2 hours on day 8 with hydration. This schedule repeated 4–5 weeks. After 2 cycle, the clinical response evaluation was performed. Surgery was carried about 3–4 weeks after chemotherapy. Result for a series in our institute 14 consecutive patient with locally-advanced gastric cancer treated with S-1/CDDP chemotherapy since April 2005 were analyzed retrospectively.

**Results:** All patients completed the planned regimens of chemotherapy and surgery, 100% of which were R0. Progression of the disease during chemotherapy was observed in 1 patient. No treatment-related deaths occurred, and adverse effects (grade 3) were observed in 2 patients. Pathological response was complete in 2 patients. No surgical mortality and only two patients occurred intra abdominal abscess which have need to treatment. With a median follow up of 36 months the median OS and 1- and 4- survival rate were 26 months, 86% and 46.5% respectively.

**Conclusion:** Surgery following S-1/CDDP chemotherapy for locally-advanced resectable gastric cancer was safe and promising treatment.

#### **Abstract ID: 0836** Specific Field: **Stomach/Duodenum**

**Mode of pres.: Poster Exhibition only**  
**ISW 2011 Session PE 307**

##### **Patterns of post-operative oral medication in gastric cancer patient**

S. Nagao, S. Kusachi, Y. Saida, J. Nagao, Y. Nakamura, T. Enomoto, M. Katagiri, K. Takabayashi

Toho University Ohashi Medical Center, Tokyo, Japan

**Introduction:** There is a several possibilities of post operative gastrointestinal dysfunction after gastrectomy. Therefore, several oral medication to improve gastrointestinal peristalsis or to suppress gastric secretion. This retrospective analysis patterns of post operative oral medication in gastric cancer patient after discharge to 1 post operative year.

**Material and Methods:** 206 patients under going gastrectomy for gastric cancer (distal gastrectomy + Billroth1:37 cases, distal gastrectomy + Roux-Y: 92 cases, total gastrectomy + Roux-Y: 77 cases) from 2005 to 2009 were analyzed.

**Results:** Distal gastrectomy + Billroth1: 56.8% at discharge, and 65% at 1 post-operative year received oral medication. Majority medications were Mosapride (24.3% at discharge, and 55.0% at 1 post-operative year) and Rikkunshito (10.8% at discharge, and 15.0% at 1 post-operative year). Distal gastrectomy + Roux-Y: 68.5% at discharge, and 63.5% at 1 post-operative year received oral medication. Majority medications were Mosapride (59.8% at discharge, and 42.3% at 1 post-operative year) and Rikkunshito (23.9% at discharge, and 32.7% at 1 post-operative year). Total gastrectomy + Roux-Y: 50.6% at discharge, and 50.0% at 1 post-operative year received oral medication. Majority medications were Daikenchuto (18.2% at discharge, and 8.3% at 1 post-operative year), Camostat (9.1% at discharge, and 14.6% at 1 post-operative year) and Mosapride (26.0% at discharge, and 14.6% at 1 post-operative year).

**Conclusion:** Our analysis revealed that post-operative oral medication was significantly dependent of the surgical procedures.

#### **Abstract ID: 0837** Specific Field: **Stomach/Duodenum**

**Mode of pres.: Poster Exhibition only**  
**ISW 2011 Session PE 308**

##### **Treatment results with S-1 based chemotherapy for advanced gastric cancer**

N. Okumura, S. Saito, A. Ikawa, T. Takahashi, K. Yamaguchi, S. Osada, K. Yoshida

Gifu University Graduate School of Medicine, Gifu, Japan

**Introduction:** Although Japanese standard chemotherapy for advanced gastric cancer is S-1 plus cisplatin (CDDP), S-1 plus docetaxel (TXT) is another promising regimen. The entry for phase III study of S-1/TXT has completed and the results will be open before long.

**Material and Methods:** We treated 63 patients of advanced gastric cancer with S-1/CDDP or S1/TXT so far. Thirty patients were administered with S-1 plus CDDP and 33 patients with S-1 plus TXT as the first line. We analyzed these treatment results.

**Results:** Thirty-seven out of 63 patients were transitioned into the second line treatment and 20 patients were into the third line. Tumor responses (CR or PR) were seen in 30 patients (48%). The period of the first line treatment ranged from 1 month to 11 months. Gastrointestinal adverse events were seen more frequently in the group of S-1/CDDP than S-1/TXT. Mean survival time (MST) of all patients was 16.5 months, and there was no significant difference of MST between the group of S-1/CDDP and S-1/TXT. Twenty-seven patients underwent gastrectomy and severe perioperative complications were not observed. Among the patients that showed tumor response to a certain degree, MST was extended in the patients who underwent gastrectomy.

**Conclusion:** S-1 based chemotherapy for advanced gastric cancer was established and it performed safely. The safety of gastrectomy after chemotherapy was admitted retrospectively. We are now performing the phase II feasibility study of gastrectomy after S-1 based chemotherapy for advanced gastric cancer patients.

#### **Abstract ID: 0838** Specific Field: **Stomach/Duodenum**

**Mode of pres.: Poster Exhibition only**  
**ISW 2011 Session PE 309**

##### **Evaluation of patients with highly advanced gastric cancer undergoing surgical resection after chemotherapy with DOC + CDDP + S-1(DCS)**

T. Nagase, T. Kanai, M. Nakagawa

Hiratsuka City Hospital, Hiratsuka, Japan

**Introduction:** Highly advanced gastric cancer has a poor prognosis, and to improve prognosis, various combined treatment modalities with chemotherapy and surgery are being investigated. In this study, treatment outcomes in patients with highly advanced gastric cancer who underwent surgical resection after preoperative combined chemotherapy with DOC + CDDP + S-1(DCS) were investigated.

**Material and Methods:** This study included 5 patients, all of whom underwent exploratory laparoscopy for a clinical diagnosis. One course of chemotherapy consisted of S-1 80 mg/m<sup>2</sup> for 14 days,



followed by a 14-day drug washout, as well as DOC 35 mg/m<sup>2</sup> and CDDP 35 mg/m<sup>2</sup> on days 1 and 15. Gastric resection was performed within 4 weeks after chemotherapy was completed.

**Results:** Two patients had 2 courses, 2 patients had 3 courses, and 1 patient had 7 courses of chemotherapy. Adverse events included grade 3 neutropenia in 3 patients (60%). Imaging studies to evaluate the effect showed a PR in all patients (100%). Total gastrectomy was performed in 3 patients, and pylorus side gastrectomy was performed in 2 patients. Four patients had radical surgery. On histopathology, 3 patients had grade 1a, 1 had grade 2, and 1 had grade 3. There were no postoperative complications. All patients received postoperative adjuvant chemotherapy.

**Conclusion:** The combination of DCS therapy and gastrectomy may be a useful option as a combined treatment modality for highly advanced gastric cancer.

#### Abstract ID: 0839 Specific Field: Stomach/Duodenum

Mode of pres.: Poster Exhibition only  
ISW 2011 Session PE 310

##### Laparoscopic resection for gastric GIST preoperatively diagnosed by doppler endoscopic ultrasonography and biopsy

Y. Tokunaga [1], S. Matsueda [2], H. Sasaki [1]

[1] Osaka North Japan Post Hospital, Osaka, Japan, [2] Osaka North Japan Post Hospital, Japan

**Introduction:** It has been difficult to diagnose submucosal tumors (SMT) preoperatively. Recently, color and power doppler endoscopic ultrasonography (EUS) and ultrasonography-guided biopsy has made it feasible to accurately diagnose gastrointestinal stromal tumor (GIST), for which laparoscopic surgery provides a less invasive treatment in early phase.

**Material and Methods:** There have been 52 cases of laparoscopic gastric resection, in which two cases with GIST were diagnosed preoperatively by doppler endoscopic ultrasonography and biopsy, and resected laparoscopically. Case 1: A 39-year-old male was detected with a gastric SMT based on an upper gastrointestinal series during a medical checkup. The tumor located in the gastric middle body. Case 2: A 49-year-old male was also detected with a gastric SMT during a medical checkup. The tumor located in the gastric upper body. EUS showed the tumors had heterogeneous contents originated from the fourth EUS layer of the stomach. Color and power doppler EUS revealed rich blood flow in the tumors, and EUS-guided biopsies demonstrated ovoid and/or spindle-shaped cells. Immunohistochemical stains revealed that the tumors were positive for CD34 and c-kit. They were diagnosed as GIST. Laparoscopic partial gastrectomy including the tumor was performed with lesion lifting technique and so on. Pathological examination and immunohistochemical stains revealed that the tumors were positive for vimentin, CD34 and c-kit.

**Results:** After surgery, these patients have been well without any recurrence for about 1.5 and 5 years respectively. Color and power doppler EUS allowed a better characterization of the SMT, and degree of vascularization is considered a prognostic factor independently associated with malignancy. Since lymphatic spread of GIST is uncommon, it is accepted that the goal of a surgical resection of gastric GIST would be a complete resection including gross negative margin. This unique characteristic has allowed for a role of minimally invasive techniques, particularly laparoscopic gastrectomy in the management of small- to medium-sized gastric GIST.

**Conclusion:** Laparoscopic surgery for GIST, diagnosed in early phase with color and power doppler EUS and EUS-guided biopsy, may provide the improvement of prognosis in patients with GIST.

#### Abstract ID: 0840 Specific Field: Stomach/Duodenum

Mode of pres.: Poster Exhibition only  
ISW 2011 Session PE 311

##### Expression of BMP-7 in human gastric cancer and its clinical significance

M. Aoki, S. Ishigami, S. Natsugoe, Y. Uenosono, T. Arigami, Y. Uchikado, Y. Kita, H. Kurahara

Kagoshima University School of Medicine, Kagoshima, Japan

**Introduction:** Bone morphogenetic protein-7 (BMP-7) is signaling molecule belonging to the transforming growth factor (TGF)—beta superfamily. Recent studies demonstrated that BMP-7 was expressed in various human cancers. The purpose of the present study was to investigate expression of BMP-7 in clinical samples of human gastric cancer to determine its clinicopathological and prognostic impact.

**Material and Methods:** 233 gastric cancer patients who received gastrectomy from 1995 to 2004 were enrolled in the study. Expression of BMP-7 in cancerous tissue was evaluated by immunohistochemistry. Correlations between expression of BMP-7 and clinicopathological factors and prognosis were analyzed retrospectively.

**Results:** Immunohistochemically, 233 were classified into two groups (BMP-7-positive group, 129 cases; BMP-7-negative group, 104 cases). Expression of BMP-7 correlated with tumor size, nodal involvement, lymphatic invasion, venous invasion and histology. Multivariate analysis revealed BMP-7-positivity as an independent prognostic factor.

**Conclusion:** Expression of BMP-7 is novel clinical marker for patients with gastric cancer.

#### Abstract ID: 0841 Specific Field: Stomach/Duodenum

Mode of pres.: Poster Exhibition only  
ISW 2011 Session PE 312

##### Surgical outcomes of gastrointestinal stromal tumor of the stomach

H. Miyamoto [1], C. Kunisaki [1], I. Endo [2]

[1] Department of Surgery, Gastroenterological Center, Yokohama City University, Yokohama, Japan, [2] Department of Gastroenterological Surgery, Yokohama City University, Yokohama, Japan

**Introduction:** This retrospective study was conducted to evaluate the surgical outcomes for gastrointestinal stromal tumor (GIST) of the stomach.

**Material and Methods:** From January 2001 to September 2010, a series of 35 patients with gastric GIST were enrolled in this study. We compared short term outcome between open gastrectomy (20 patients) and laparoscopic gastrectomy (15 patients). When the diameter of tumor was within 50 mm and the tumor did not extended to esophagogastric junction by preoperative images, laparoscopic gastrectomy was employed. We evaluated disease free survival and overall survival.

**Results:** There were no significant differences in age (63.1/67.1 years,  $P = 0.367$ ) and gender (male:female = 6:14/7:8,  $P = 0.313$ ), location (U:M:L = 10:8:2/8:5:2,  $P = 0.903$ ) between two groups. In open gastrectomy, tumor size was significantly larger (45.9/33.4 mm,  $P = 0.026$ ) and pathological high risk group was more frequently included (high:others = 6:14/0:15,  $P = 0.032$ ) than laparoscopic gastrectomy. There were no significant differences in procedures (partial:proximal = 17:3/14:1,  $P = 0.443$ ) and blood loss (88.5/23.3

ml,  $P = 0.068$ ). Operation time was significantly shorter in laparoscopic gastrectomy (142.1/96.7 min,  $P = 0.048$ ). Postoperative hospital stay tended to be shorter in laparoscopic gastrectomy (11.4/8.7 days,  $P = 0.11$ ) than open gastrectomy. Postoperative morbidity was observed in one patients of open gastrectomy (hepatic infarction). There was no postoperative morbidity in laparoscopic gastrectomy. We administered imatinib to 3 patients of high risk group as adjuvant therapy and all 3 patients have no recurrence (the mean follow-up time was 27.7 months). In other 32 patients, one patient has peritoneal recurrence 12 months after the operation and died 38 months later, while 31 patients have no recurrence (the mean follow-up time was 26.6 months).

**Conclusion:** Laparoscopic gastrectomy was safe and justifiable operation for GIST. It is necessary to accumulate more patients to establish efficacy. Indication of adjuvant therapy is an immediate issue.

**Abstract ID: 0842** Specific Field: **Stomach/Duodenum**

**Mode of pres.: Poster Exhibition only**  
**ISW 2011 Session PE 313**

**Combination of irinotecan plus cisplatin as the second-line chemotherapy against metastatic and unresectable gastric cancer: a report from retrospective study**

H. Fujiwara, K. Koeda, M. Takahashi, G. Wakabayashi

Iwate Medical University, Morioka, Japan

**Introduction:** In Japan, for metastatic gastric cancer, the most appropriate chemotherapeutic regimen after failure of the first-line S-1 based chemotherapy has not yet been established with respect to prognosis. The aim of the present study is to retrospectively investigate the efficacy and toxicity of combination therapy of irinotecan (CPT-11) plus cisplatin (CDDP) as 2nd-line chemotherapy.

**Material and Methods:** All patients had a performance status of 0 or 1, and had received previously S-1 based chemotherapy as 1st-line treatment. The treatment consisted of bi-weekly intravenous administration of CPT-11 (60 mg/m<sup>2</sup>), and CDDP (30 mg/m<sup>2</sup>).

**Results:** Results Between September 2006 and March 2010, 20 patients were enrolled in this study. After a median follow up time of 17 months, 25% of patients remain alive and free of disease. The Median age of the patients was 63 years (range, 45–76 years). The overall objective response rate was 40% [8 partial response among 20 patients]. The progression free survival and median overall survival time were 4.6 months and 16.8 months, respectively. The 1-year survival proportion was 60%. The major adverse events were myelosuppression and gastrointestinal toxicity, frequent grade 3 toxicities were anemia(25%), Neutropenia(10%), appetite loss(15%), and nausea(15%). Grade 4 toxicity was not observed. All cases were able to be treated in outpatient department.

**Conclusion:** With respect to toxicity and feasibility, combination of CPT-11 plus CDDP can be an alternate treatment as 2nd-line chemotherapy for metastatic and unresectable gastric cancer.

**Abstract ID: 0843** Specific Field: **Stomach/Duodenum**

**Mode of pres.: Poster Exhibition only**  
**ISW 2011 Session PE 314**

**Clinicopathologic significance of HIF-1 $\alpha$  expression in gastric cancer**

T. Isobe, K. Aoyagi, K. Koufujii, M. Miyagi, T. Imaizumi, J. Kizaki, K. Shirouzu

Kurume University, Kurume, Japan

**Introduction:** Hypoxia-inducible factor-1 $\alpha$  (HIF-1 $\alpha$ ) is a transcription factor for many genes recognized to control the delivery of oxygen and nutrients by the induction of angiogenesis and glycolysis under hypoxic condition. HIF-1 $\alpha$  activates the transcription of vascular endothelial growth factor(VEGF), a key factor in tumor angiogenesis, and the expression of glucose transporters, glycolytic enzymes, and growth factors, which may promote tumor cell survival under hypoxic conditions. Therefore, Inhibition of expression of HIF-1 $\alpha$  will be expected to the tumor specific molecular target-based therapy.

**Material and Methods:** Paraffin-embedded tumor specimens from 73 patients, excluded mucosal cancer, multiple primary cancer, multiple gastric cancer, remnant cancer and the remnant cancer post ESD, representing patients who had undergone gastrectomy at the Kurume University in 2004, were used to assess the clinical significance of HIF-1 $\alpha$  protein expression. Paraffin-embedded tissues were subjected to immunohistochemical analysis performed by the avidin-biotin-peroxidase complex(ABC) method after activation The primary antibody was a rabbit polyclonal antibody directed against HIF-1 $\alpha$ . The expression of HIF-1 $\alpha$  was defined as positive if nuclear staining was observed in >5% of the tumor cells. Clinicopathological variables were compared between the positive and negative expression group. In regard to postoperative survival rates, The expression of HIF-1 $\alpha$  was classified as follows: –(0–5%), 1+ (5–10%), 2+ (10–15%) and 3+ (>15%).

**Results:** There was no significant correlation with the expression of HIF-1 $\alpha$  among T, N, M, H, P, CY factors, ly, v and stage. The positive number of HIF-1 $\alpha$  and the positive rates of histology; tub1: 16, 6.33  $\pm$  5.62, tub2: 12, 8.05  $\pm$  5.39, por1: 8, 7.89  $\pm$  10.7, por2: 24, 8.52  $\pm$  5.52, sig: 6, 12.2  $\pm$  11.1, pap: 2, 1.08  $\pm$  1.45, muc, 5, 10.6  $\pm$  10.6. The expression of HIF-1 $\alpha$  in the groups of signetring cell carcinoma and mucinous adenocarcinoma tended to be higher than that in the other groups. According to the 5-year survival rates, (–); 45.0%, (1+); 51.6%, (2+); 53.6%, (3+); 45.3%. The survival curve in the HIF-1 $\alpha$  low-expression group tended to be higher than that in the HIF-1 $\alpha$  high-expression group.

**Conclusion:** HIF-1 $\alpha$  expression was found to be a poor prognostic factor for patients with gastric cancer.

**Abstract ID: 0844** Specific Field: **Stomach/Duodenum**

**Mode of pres.: Poster Exhibition only**  
**ISW 2011 Session PE 315**

**Gastric gastrointestinal stromal tumor (GIST) under the laparoscopic and endoscopic cooperative dissection**

S. Tabuchi, K. Koyanagi, I. Koyama

Department of Gastroenterological Surgery, Saitama International Medical Center, Saitama Medical University, Hidaka, Japan

**Introduction:** Laparoscopic wedge resection are increasingly applied for gastrointestinal stromal tumor (GIST) of the stomach. However, tumors located near the esophagogastric junction or posterior gastric wall are traditionally resected using an open approach to ensure negative margins and not to deform stomach.

**Material and Methods:** The procedure of laparoscopic and endoscopic dissection for gastric GIST was as follows: At first, we performed endoscopic submucosal resection around the tumor. The tip

of the needleknife was apparent beyond the seromuscular layer, and artificial perforation was performed. After this procedure, the seromuscular layer around the tumor was dissected using by endoscopic method and laparoscopic coagulating shears (LCS). Next we sutured the gastric wall under laparoscopic suturing technique. Then, the procedure dissected a minimal mucosal area of the stomach wall. We report two cases of gastric GIST under the laparoscopic and endoscopic dissection.

**Results:** (Case1)The 46 years-old woman. Upper gastrointestinal endoscopy showed a 35 mm submucosal tumor of anterior upper body of stomach. A distance between the tumor and the esophagogastric junction was about 2 cm. We perform endoscopic ultrasonography guided fine needle aspiration (EUS-FNA), and diagnosed the tumor as GIST.(Case2)The 63 years-old man. Upper gastrointestinal endoscopy showed a 8 mm submucosal tumor of posterior fornix of stomach. Endoscopic ultrasonography showed that the tumor was originated from the gastric submucosal layer. Therefore we tried to endoscopic submucosal dissection (ESD) of the tumor. But we interrupted ESD of the tumor because the tumor was originated from the gastric muscle layer. The tumor size was small, but the laparoscopic and endoscopic dissection was done because the patient strongly hoped for the operation. We diagnosed it as GIST of pathological results.

**Conclusion:** Gastric GIST under the laparoscopic and endoscopic cooperative dissection may be performed safely with adequate cut lines. In addition, the success of the procedure does not depend on the tumor location such as the vicinity of the esophagogastric junction or posterior gastric wall.

**Abstract ID: 0845** Specific Field: **Stomach/Duodenum**

**Mode of pres.: Poster Exhibition only**  
**ISW 2011 Session PE 316**

**Therapeutic potential of PRL-3 targeting and clinical significance of PRL-3 genomic amplification in gastric cancer**

A. Ooki, K. Yamashita, M. Watanabe

Kitasato University, Japan

**Introduction:** Phosphatase of regenerating liver-3 (PRL-3) has deserved attention as a crucial molecule in the multiple steps of metastasis. In the present study, we examined the mechanisms regulating PRL-3 expression, and assessed the clinical potential of PRL-3-targeted therapy in gastric cancer.

**Material and Methods:** PRL-3 genomic amplification was analyzed using quantitative-polymerase chain reaction and/or fluorescence in situ hybridization in 77 primary gastric tumors. The anticancer activity of PRL-3 inhibitor (1-4-bromo-2-benzylidene rhodanine) treatment was evaluated against cancer cells with different genetic and expression status.

**Results:** PRL-3 genomic amplification was closely concordant with high level of its protein expression in cell lines, and was found in 20% (8/40) among human primary tumors with its expression, which were all stage III/IV disease (40%, 8/20), but in none (0/37) among those without expression. Additionally, PRL-3 genomic amplification was associated with metastatic lymph node status, leading to advanced stage and thereby poor outcomes in patients with lymph node metastasis ( $P = 0.021$ ). PRL-3 small interfering RNA robustly repressed metastatic properties, including cell proliferation, invasion, and anchorage-independent colony formation. Although neither PRL-3 genomic amplification nor expression level was responsible for the sensitivity to PRL-3 inhibitor treatment, the inhibitor showed

dose-dependent anticancer efficacy, and remarkably induced apoptosis on all the tested cell lines with PRL-3 expression.

**Conclusion:** PRL-3 genomic amplification is one of the predominant mechanisms inducing its expression, especially in more advanced stage, and that PRL-3-targeted therapy may have a great potential against gastric cancer with its expression.

**Abstract ID: 0846** Specific Field: **Stomach/Duodenum**

**Mode of pres.: Poster Exhibition only**  
**ISW 2011 Session PE 317**

**Role of thrombospondin 1 (THBS1) expression in peritoneal metastasis of gastric cancer treated with taxanes**

K. Yoshikawa, M. Shimada, N. Kurita, T. Iwata, S. Morimoto, T. Miyatani, C. Mikami, M. Nishioka

The University of Tokushima, Japan

**Introduction:** The aim of this study is to clarify the utility of taxanes and to pick up the prognostic factors in the treatment with 5FU based chemotherapy for peritoneal metastasis of gastric cancer.

**Material and Methods:** Responder analysis 18 patients with peritoneal metastasis of gastric cancer were enrolled in phase I study. Regimen: S-1 (80–120 mg) for 14 days and intraperitoneal infusion of PTX (Dose escalation: 40–100 mg/m<sup>2</sup>) at day 1 and 14. To pick up the predictive factors, the 137 genes, which were selected in the viewpoint of sensitivity of 5FU, CPT11 and taxanes, were analyzed using focused DNA microarray for the 12 patients. Role of THBS1 expression THBS1 expressions were evaluated in immunohistochemical staining of surgical specimens of 59 patients with peritoneal metastasis of gastric cancer who were received 5FU based chemotherapy.

**Results:** Responder analysis Clinical benefits were confirmed in 6 patients (2: partial response in RECIST, 2: positive adenocarcinoma cells in peritoneal cytology became negative, 2: remarkable decrease of ascites) Expressions of THBS1 gene were higher more than 2 folds in these 6 patients compared with no responders. THBS1 was confirmed in 5 of 6 responders (83.3%) using immunohistochemical staining, who had higher survival rate. Role of THBS1 expression 17 patients (28.8%) was THBS1 positive and had significantly better prognosis compared with THBS1 negative patients (1 year survival: 64.7% vs. 34.7%). 38 patients treated with taxanes and 16 patients with CPT11 revealed tendency of improved overall survival rates, respectively ( $P = 0.05$ ,  $P = 0.10$ ). Overall survival of THBS1 positive patients treated with taxanes was significantly higher than that of THBS1 negative patients.

**Conclusion:** PTX could improve the survival of peritoneal metastasis of gastric cancer. THBS1 is a prognostic factor especially in the patients treated with taxanes, which leads to tailor made therapy.

**Abstract ID: 0847** Specific Field: **Stomach/Duodenum**

**Mode of pres.: Poster Exhibition only**  
**ISW 2011 Session PE 318**

**Treatment results of type 4 advanced gastric cancer**

S. Katayanagi [1], M. Shimazu [1], T. Suda [2], S. Hoshino [2], K. Itoh [2], Y. Takagi [2], A. Tsuchida [2], T. Aoki [2]

[1] Digestive Tract Surgery and Transplantation Surgery, Tokyo Medical University Hachioji Medical Center, Tatemachi Hachioji, Tokyo, Japan, [2] Department of Surgery, Tokyo Medical University, Nishi-shinjyuku Shinjyuku-ku, Tokyo, Japan

**Introduction:** The patients with type 4 gastric cancer have still a bad prognosis. We evaluated treatment of type 4 gastric cancer.

**Material and Methods:** We studied 75 patients who had undergone operation for type 4 gastric cancer. We evaluated the effect of resection and chemotherapy after surgery or relapse.

**Results:** Operative procedures are total gastrectomy in 57, Distal gastrectomy in 11, bypass without resection in 7, exploratory laparotomy in 7 cases. The tumor size was 128 mm (median) in diameter and depth of tumor invasion were MP 1, the SS in 9, SE in 54 and SI in 11 cases. Final stage were A 2, B 12, A 4, B 12, C 15 and 29 cases, respectively. R0 resection was 37, R1 was 18, R2 was 20 cases (JCGC The 14th edition). 19 cases (51%) of R0 had recurrence. Median survival time (MST) of R0, R1, R2 was 1024, 567, 439 days respectively. There were significant differences between R2 and R0, R1. MST days without resection or recurrence was 352 days. The patients who was administered more than 3 drugs or more than 3rd line chemotherapy tended to have longer MST.

**Conclusion:** R0 or R1 operation for type 4 gastric cancer is effective. Chemotherapy for unresectable or relapsed cases seems to bring about the equal prognosis to non type 4 gastric cancer.

**Abstract ID: 0848** Specific Field: **Stomach/Duodenum**

**Mode of pres.: Poster Exhibition only**  
**ISW 2011 Session PE 319**

**CD83 + dendritic cells and Foxp3 + regulatory T cells in peritumoral lesions and regional lymph nodes are inversely correlated with prognosis of gastric cancer**

S. Kashimura [1], M. Gotoh [2]

[1] Fukushima Medical University, Fukushima, Japan, [2] Fukushima Medical University, Japan

**Introduction:** Dendritic cells (DCs) are potent antigen-presenting cells that are central to regulation, maturation and maintenance of the cellular immune response against cancer. In contrast, CD4 + CD25 + regulatory T cells (Tregs) play a central role in self-tolerance and suppress antitumor immunity. This study investigated the clinical significance of mature CD83 + DCs and Foxp3 + Tregs in the primary tumor and regional lymph nodes from the standpoint of the two opposing players in the immune responses.

**Material and Methods:** We investigated immunohistochemically the prevalence of CD83 + DCs and Foxp3 + Tregs in peritumoral lesions of gastric cancer ( $n = 123$ ), as well as in regional lymph nodes with ( $n = 40$ ) or without metastasis ( $n = 40$ ).

**Results:** Decreased prevalence of CD83 + DCs and increased prevalence of Foxp3 + Tregs were observed in primary tumor and metastatic lymph nodes. Prevalence was significantly correlated with certain clinicopathological features. Better prognosis was observed in patients with high prevalence of CD83 + DCs or low prevalence of Foxp3 + Tregs in primary lesions. For patients with metastatic lymph nodes, prevalence of CD83 + DCs in negative lymph nodes was found to be an independent prognostic factor by multivariate analysis.

**Conclusion:** Prevalence of CD83 + DCs and Foxp3 + Tregs was inversely correlated with tumor progression and reflected prognosis of gastric cancer.

**Abstract ID: 0849** Specific Field: **Stomach/Duodenum**

**Mode of pres.: Poster Exhibition only**  
**ISW 2011 Session PE 320**

**Survival benefit of chemotherapy after palliative surgery for stage IV gastric cancer**

K. Mimatsu [1], T. Oida [1], A. Kawasaki [1], H. Kano [1], N. Fukino [1], K. Kida [1], Y. Kuboi [1], S. Amano [2]

[1] Social Insurance Yokohama Central Hospital, Yokohama, Japan, [2] Nihon University School of Medicine, Tokyo, Japan

**Introduction:** Stage IV gastric cancer is poor prognosis, and clinical benefits of chemotherapy after palliative surgery for stage IV gastric cancer is unclear. We retrospectively analyzed the influence of chemotherapy and the survival of patients with reduction surgery and gastrojejunostomy in stage IV gastric cancer.

**Material and Methods:** Clinical data of 95 patients for stage IV gastric cancer at the Social Insurance Yokohama Central Hospital between 1990 and 2009 were analyzed. Of 95 patients, 67 patients underwent reduction surgery (35 patients received chemotherapy after operation (Chemo group) and 32 patients received best supportive care (BSC group)) and 28 patients underwent gastrojejunostomy (14 patients received chemotherapy after operation (chemo group) and 14 patients received best supportive care (BSC group)) for stage IV gastric cancer. These each two groups were compared with clinicopathologic factors and survival rate.

**Results:** (1). Reduction surgery for stage IV gastric cancer; The chemo group was younger patients and better performance status than the non-chemo group. Postoperative complication was found in the non-chemo group more than the chemo group. Tumor wall invasion, lymph node metastasis, peritoneal dissemination, liver metastasis and peritoneal washing cytology were not significantly difference in two groups. Median survival time in the chemo group (262 days) was longer than that in the non-chemo group (132 days). (2). Gastrojejunostomy for stage IV gastric cancer; Clinical background was not significant difference in two groups. The overall 1- and 2- year survival rates in the chemo group and BSC group were 21.4%/7.7%, and 14.3%/0%, respectively. Median survival time in the chemo group was significantly longer than in the BSC group (157 days vs. 63 days,  $P < 0.05$ ).

**Conclusion:** Adjuvant chemotherapy after reduction surgery and gastrojejunostomy may contribute to improvement of survival in stage IV gastric cancer.

**Abstract ID: 0850** Specific Field: **Stomach/Duodenum**

**Mode of pres.: Poster Exhibition only**  
**ISW 2011 Session PE 321**

**Laparoscopy-assisted percutaneous gastrostomy tube placement along with laparoscopic gastropexy**

H. Tsujimoto, Y. Yaguchi, I. Kumano, K. Yoshida, H. Horiguchi, S. Ono, J. Yamamoto, K. Hase

National Defense Medical College, Tokorozawa, Japan

**Introduction:** Percutaneous endoscopic gastrostomy (PEG) has gained wide acceptance for patients suffering malnutrition. However, PEG technique is not always feasible in cases in which endoscopic passage is not possible due to an obstruction in esophagus.

**Material and Methods:** Under general anesthesia, a camera port was inserted into an inferior umbilical incision. Next, a pneumoperitoneum



of 10 mmHg was created, and 2 additional ports with a diameter of 5 mm were inserted into the right upper and right lower quadrants under laparoscopic imaging. The 2.0 nylon suture with straight needle was inserted into the peritoneal cavity approximately 1 cm from the cranial direction of the planned gastrotomy. After this straight needle was held with the laparoscopic needle holder, the layers of the anterior gastric wall were sutured, and then the needle was put through the abdominal wall. The same procedures were performed at 2 cm on the caudal side of the first suture. A trocar with a peel-away sheath was used to penetrate the gastric wall. The peel-away sheath was removed and a balloon catheter was placed between the two gastropexy sutures.

**Results:** This surgical procedure was performed in 6 cases. The mean operation time was  $46.7 \pm 10.0$  min, and the postoperative courses were uneventful, and feeding was started on postoperative day 1 in all cases.

**Conclusion:** This laparoscopic gastrotomy procedure should be especially useful in patients in whom endoscopic passage is not possible due to a laryngeal or esophageal stenosis.

#### Abstract ID: 0851 Specific Field: Stomach/Duodenum

**Mode of pres.: Poster Exhibition only**  
ISW 2011 Session PE 322

##### Clinicopathological features and prognosis of gastrointestinal stromal tumor (GIST) showing severe physical signs

Y. Kurahashi, H. Shinohara, O. Inamoto, R. Okamura, Y. Shirakata, H. Sawada, A. Maki, Y. Mizuno

Hyogo Prefectural Amagasaki Hospital, Amagasaki, Japan

**Introduction:** Although GIST is often detected incidentally at asymptomatic stage, some patients show severe physical signs. Few studies have focused on correlation between clinical symptoms and histologically high-grade malignancy or poor prognosis.

**Material and Methods:** Twenty-three patients with GIST (14 men, 9 women; mean age  $62 \pm 15$  years), who underwent resection between January 2005 and July 2010, were divided into two groups. Group A ( $n = 9$ ) was categorized as the patients who had tumor-related symptoms, while group B ( $n = 14$ ), the patients who didn't show any pathognomonic signs before operation. Clinicopathological features and prognosis of symptomatic GIST were compared with those of asymptomatic cases.

**Results:** Clinical symptoms of patients in group A were gastrointestinal hemorrhage ( $n = 5$ ), unconsciousness ( $n = 1$ ), abdominal pain ( $n = 1$ ), dizziness ( $n = 1$ ) and appetite loss ( $n = 1$ ). Emergency operations were performed for two patients with intraperitoneal bleeding and abscess. Eighteen out of 23 tumors (group A,  $n = 5$ ; group B,  $n = 13$ ) were detected in the stomach. Five out of 9 tumors in group A developed in the small intestine (2 in the duodenum, 2 in the jejunum, 1 in the ileum), but only one tumor in group B did. The mean tumor size of group A ( $84 \pm 51$  mm) was significantly larger than that of Group B ( $36 \pm 19$  mm,  $P = 0.019$ ). However, the rate of high-grade malignancy, microscopically defined by mitotic index, of group A (3 of 9 patients; 33.3%) was not significantly higher than that of group B (1 of 14 patients; 7.1%,  $P = 0.261$ ). Although two patients in group A had distant metastases (1 in the peritoneum and 1 in the liver), all patients underwent R0 resection except one with peritoneal metastasis. After surgery, the two patients with distant metastases were administered oral imatinib mesylate. As of January 2011 (mean follow up: 31 months), there was no tumor recurrence in each group.

**Conclusion:** Symptomatic GIST was significantly larger than asymptomatic GIST, but not related to histologically high-grade malignancy. These results suggest that the prognoses of patients with GIST that shows severe physical signs might not be so worse in comparison with those of asymptomatic cases.

#### Abstract ID: 0852 Specific Field: Stomach/Duodenum

**Mode of pres.: Poster Exhibition only**  
ISW 2011 Session PE 323

##### Liver metastasis and peritoneal dissemination from alpha-fetoprotein(AFP)-producing gastric cancer completely responding to the chemotherapy by Docetaxel and S-1: report of a case

T. Yamaguchi, S. Murata, H. Yamamoto, T. Tatsuta, T. Shimizu, H. Shiomi, S. Naka, T. Tani

Shiga University of Medical Science, Otsu, Japan

**Introduction:** Alpha-fetoprotein(AFP)-producing gastric cancer is a rapidly growing, highly invasive, widely metastasizing neoplasm, of which prognosis were reported 7.3–13.5 months. We report the case of the liver metastasis and peritoneal dissemination from AFP-producing gastric cancer completely responded to the chemotherapy by Docetaxel and S-1.

**Material and Methods:** A 57-year-old male, whose chief complaint was exertional dyspnea, visited a hospital and detected anemia, Hemoglobin 5.9 g/dl. Although he has the history of pneumoconiosis, he has no history of any other significant disease including liver disease. An upper gastrointestinal endoscopy showed advanced gastric cancer on the lower to the middle third of the stomach. Abdominal dynamic-CT scan revealed liver metastasis at S7, which of the size was 5 cm in diameter. Serum AFP level was high, 8515 ng/ml. He was diagnosed AFP-producing gastric cancer, T3N1M1 StageIV. Because he has anemia due to the gastric tumor bleeding, gastrectomy was undergo before chemotherapy. Total gastrectomy with D2 lymph node dissection and Roux-en-Y reconstruction were performed. Gastric carcinoma with serosal invasion, a liver metastasis at S7, and microscopic peritoneal dissemination were found in the surgery. His postoperative course was uneventful. He was discharged on the 11th day after the operation.

**Results:** Ten cycles of chemotherapy by Docetaxel and S-1 was started on the 22nd day after the operation. Docetaxel was administered at  $30 \text{ mg/m}^2$  biweekly, and S-1 was administered orally at  $60 \text{ mg/m}^2$  for consecutive 14 days, followed by 2-week rest, as one cycle. Serum AFP level was gradually decreased, and was within normal limit in 4 months after the operation. The size of the liver metastasis was also decreased, and was almost disappeared at abdominal enhanced-CT scan.

**Conclusion:** Because of the possibility that viable malignant cells would exist in the lesion at S7, partial liver resection of S7 was undergo in 14 months after the previous operation. Microscopically, no liver metastasis and no peritoneal dissemination were found. Now it is 33 months since the first surgery was undergo, no recurrence or distant metastasis has occurred.

#### Abstract ID: 0853 Specific Field: Endocrine Surgery

**Mode of pres.: Free Paper**  
ISW 2011 Session 5.01

##### Long-term results of surgery for midgut carcinoid tumours at a tertiary referral center

O. Norlen [1], P. Stalberg [1], J. Eriksson [1], O. Hessman [1], E. Tiensu-Janson [2], G. Akerström [1], P. Hellman [1]

[1] Department of Surgery, Uppsala University, Uppsala, Sweden,  
[2] Department of Medical Science, Uppsala University, Uppsala, Sweden

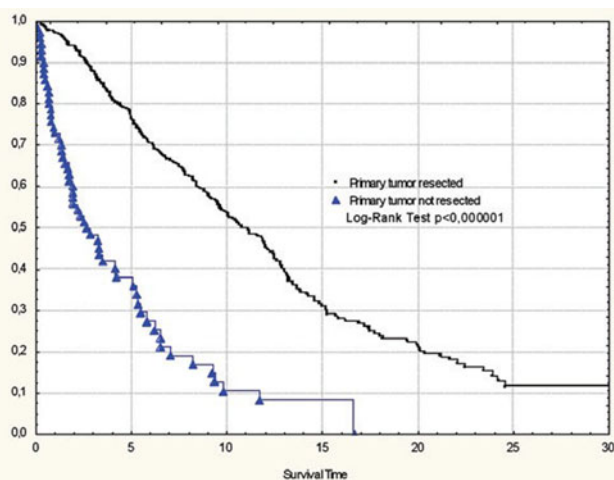
**Introduction:** Midgut carcinoid tumors (MGC) are rare, with a clinical incidence of about 0.5 to 1.5 per 100,000 individuals. The primary tumor is usually small (5–10 mm) but it has nevertheless

often spread to regional lymph nodes and the liver at diagnosis. Patients with MGC who undergo removal of the primary tumor and mesenteric and liver metastases tend to have a better survival than patients who do not undergo resection, although it is not unambiguous whether this is due to the operation itself or due to selection bias.

**Material and Methods:** We included 579 patients (265 women, age at diagnosis  $62 \pm 11$  (mean  $\pm$  SE)) with histopathologically verified MGC that were diagnosed and treated between 1985 and 2009 at Uppsala University Hospital. Hospital charts were reviewed, and we scrutinized for the following parameters at diagnosis; lymph node, liver and extra hepatic metastases, symptoms, hormone values, KI-67 index and comorbidities. Various treatment regimes, such as resection of the primary tumor, metastatic lymph nodes, and/or liver metastases as well as radiofrequency treatment, hepatic artery embolization, biotherapy, chemotherapy and radiotherapy were recorded. Measurement endpoints were survival, clinical staging with lymph node/liver/extrahepatic metastases and hormone values. Adverse events of operations and interventions (i.e. complications) were also noted. Patients were followed for until their last visit at the hospital or until death in mean  $7.8 \pm 6.1$  (mean  $\pm$  SE) years.

**Results:** Overall median survival for the entire patient group was 9.64 years. Patients who underwent resection of the primary tumor ( $n = 508$ ) fared significantly better (median 10.9 years) than the patients who did not undergo resection ( $n = 71$ ) (median survival 2.65 years) (Figure). 90-day mortality after initial surgery was <1%.

**Conclusion:** Overall survival has improved significantly with time compared to older series, including our own. The primary tumor surgery is strongly associated with better survival in patients with midgut carcinoid disease, both in short- and long term. Mortality after initial carcinoid surgery due to surgical complications is rare.



**Figure** Survival after primary surgery for midgut carcinoid tumors

**Abstract ID: 0854** Specific Field: **Endocrine Surgery**

**Mode of pres.: Free Paper**  
**ISW 2011 Session 5.02**

**Randomized controlled trial of visualization versus neuromonitoring of the external branch of the superior laryngeal nerve during thyroidectomy**

M. Barczynski [1], A. Konturek [1], M. Stopa [2], A. Honowska [2], W. Nowak [1]

[1] Jagiellonian University, Medical College, Krakow, Poland,  
[2] Narutowicz Municipal Hospital, Krakow, Poland

**Introduction:** Injury to the external branch of the superior laryngeal nerve (EBSLN) can occur during the dissection and clamping of the superior thyroid vessels. This injury causes a complete paralysis of the cricothyroid muscle which results in lowered fundamental frequency of the voice and worsened voice performance in producing high-frequency sounds. Intraoperative nerve monitoring (IONM) can be used to identify both the recurrent laryngeal nerve (RLN) and the EBSLN. However, it remains unclear if there is any IONM added-value to the clinical outcome of thyroidectomy in terms of preserved individual voice performance. This study was designed to test that hypothesis.

**Material and Methods:** Two hundred consenting patients planned for total thyroidectomy (between 09/2009 and 06/2010) were randomly assigned to two groups equal in size ( $n = 100$ ): visual inspection of the EBSLN and RLN vs. this plus additional EBSLN and RLN monitoring (NIM3.0). The primary outcome was the identification rate of the EBSLN. The secondary outcomes included: anatomical variability of the EBSLN according to Cernea classification, and changes in postoperative voice performance. The voice assessment included pre- and postoperative laryngoscopy and analysis of maximum phonation time (MPT), voice level (VL), fundamental frequency (FF), and voice quality rating on GRBAS scale. All patients underwent 6-month postoperative follow-up.

**Results:** Among patients operated without vs. with IONM the identification rate of the EBSLN was 34% vs. 83% ( $P < 0.001$ ), whereas 10% or higher decrease in phonation parameters was found in 10% vs. 3% of patients for MPT ( $P = 0.04$ ), 13% vs. 3% for VL ( $P = 0.009$ ), and 9% vs. 2% for FF ( $P = 0.03$ ), respectively. Change in voice quality rating according to GRBAS scale of 4 points or more (possible range 0–15 points) was found after thyroidectomy in 8% vs. 1% of patients operated without vs. with IONM of the EBSLN, respectively ( $P = 0.02$ ). Temporary RLN injury was found in 2% vs. 1% (with vs. without IONM, respectively;  $P = 0.56$ ). There were no permanent RLN palsies in this study.

**Conclusion:** Use of IONM significantly improved the identification rate of the EBSLN during thyroidectomy as well as reduced the risk of phonation changes following thyroidectomy.

**Abstract ID: 0855** Specific Field: **Endocrine Surgery**

**Mode of pres.: Free Paper**  
**ISW 2011 Session 5.03**

**Ga-DOTATOC PET/CT and 3D-CT computer-assisted surgical planning in planning management of neuroendocrine liver metastases**

A. Frilling [1], G. C. Sotiropoulos [2]

[1] Imperial College London, London, United Kingdom,  
[2] University Hospital Essen, Essen, Germany

**Introduction:** Hepatic surgery is presumed to have a beneficial effect on survival in patients with liver metastases (LM) from neuroendocrine tumors (NET). Establishment of the intra- and extrahepatic extent of NET is crucial for surgical planning and has an impact on prognosis. Standard imaging techniques often inadequately identify the extent of the disease and fail to precisely predict volume and quality of the remaining liver tissue. The objective of this study was to determine the role of  $^{68}$  Ga-DOTATOC PET/CT and 3D-CT computer-assisted surgical planning (3D-CASP) in management of patients with neuro-endocrine LM.

**Material and Methods:** Our pre-treatment imaging protocol encompassed  $^{68}$  Ga-DOTATOC PET/CT and 3D-CASP in NET patients with LM and 3D-CASP in corresponding potential donors for

living donor liver transplantation (LT). Intra- and extrahepatic extent of the disease and hepatic resectability were determined.

**Results:** In total, 80 patients were potential candidates for liver resection or LT. Compared to standard imaging with CT and/or MRI  $^{68}\text{Ga}$ -DOTATOC PET/CT revised tumor extent in terms of additional tumor deposits or identification of an initially unknown primary tumor site in 42 patients (52.5%). Three of the final 15 candidates for liver resection (20%) were assessed as inoperable due to 3D-CASP results revealing unrealistic vascular reconstruction and/or insufficient functional remnant volume. Eight of the 18 potential liver donors were excluded from further evaluation for donation after 3D-CASP indicated unsuitable anatomy or insufficient future functional liver remnant volume.

**Conclusion:**  $^{68}\text{Ga}$ -DOTATOC PET/CT and 3D-CASP have significant impact on management of patients with neuro- endocrine LM. This new technology contributes to more accurate assessment of the disease extent, better patient selection for individualised treatment, lower risk of morbidity, and better prognosis.

**Abstract ID: 0856** Specific Field: **Endocrine Surgery**

**Mode of pres.: Free Paper**  
**ISW 2011 Session 5.04**

**Prognostic factors and treatment outcomes in anaplastic thyroid carcinoma (ATC): ATC Research Consortium of Japan Cohort Study for 654 patients**

I. Sugitani [1], A. Miyauchi [2], K. Sugino [2], A. Yoshida [2], K. Fujimori [2], T. Okamoto [2], K. Itoh [2], S. Suzuki [2]

[1] Cancer Institute Hospital, Japanese Foundation for Cancer Research, Tokyo, Japan, [2] Anaplastic Thyroid Carcinoma Research Consortium of Japan, Tokyo, Japan

**Introduction:** Anaplastic thyroid carcinoma (ATC) accounts only for 1–2% of all thyroid carcinomas, but is one of the most lethal neoplasms in humans. To date, most findings about ATC have been derived from single-institution studies with limited number of cohorts. To obtain further insights into this “orphan disease”, we have established a multicenter registry, the ATC Research Consortium of Japan (ATCCJ). We analyzed prognostic factors and treatment outcomes using the large cohort database of the ATCCJ.

**Material and Methods:** The majority of Japanese centers involved in the treatment of thyroid cancer were invited to the ATCCJ and have provided information on ATC patients treated between 1995 and 2007. The database included 654 cases from 33 registered institutions. Survival curves were determined using Kaplan–Meier methods and were compared using the log-rank test. Cox’s proportional hazards model was used for multivariate analysis.

**Results:** Clinical varieties of ATC were classified into 4 types: common type ( $n = 508$ ); incidental type ( $n = 40$ ); anaplastic transformation at the neck ( $n = 94$ ); and anaplastic transformation at a distant site ( $n = 12$ ). Incidental type showed significantly better outcomes than other types, while anaplastic transformation at a distant site showed the worst outcomes. As for common-type ATC, 6-month and 1-year cause-specific survival (CSS) rates were 39% and 18%, respectively. Multivariate analysis showed age 70 years, presence of acute symptoms, white blood cell count  $10,000/\text{mm}^3$ , large tumor  $>5$  cm, gross extrathyroidal invasion and distant metastasis were significant risk factors for lower survival. CSS rates also differed significantly depending on UICC stages, with 6-month CSSs of 64% for IVA, 50% for IVB, and 22% for IVC. For 37 of 63 (59%) stage

IVA patients who underwent radical surgery, adjuvant therapies including radiation therapy (RT) and chemotherapy (CT) did not show any additional benefit statistically. Conversely, among 221 stage IVB patients, 69 (31%) received radical surgery. For those, therapies combining RT with CT significantly improved CSS.

**Conclusion:** Long-term survival is possible for selected patients with ATC. To determine the treatment strategy, UICC stage (disease extent) and other prognostic factors (grade of biological malignancy) should be considered.

**Abstract ID: 0857** Specific Field: **Endocrine Surgery**

**Mode of pres.: Free Paper**  
**ISW 2011 Session 5.05**

**Surgical strategy for thyroid carcinoma primary originating in thyroglossal duct cyst: twelve cases report**

R. Dzodic [1], I. Markovic [1], M. Buta [1], I. Djuricic [1], M. Jevric [1], B. Stanojevic [2], G. Pupic [1], S. Yamashita [2]

[1] Institute of Oncology and Radiology of Serbia, Belgrade, Serbia, [2] Atomic Bomb Disease Institute, Nagasaki, Japan

**Introduction:** Thyroglossal duct cyst is the most common embryonal anomaly of the thyroid gland. On the other hand, thyroid carcinoma development in TDC is extremely rare and accounts only one percent of all thyroid cancers. About 250 cases have been reported in relevant literature. Surgical management and additional treatment is based on the individual experience.

**Material and Methods:** We report 12 cases of primary TDC thyroid carcinoma operated in one Institution in 20 years. In 11 cases first operation of TDC excision was performed in other hospitals. After histology of thyroid carcinoma they were reoperated in our Institute. Sistrunk’s procedure was done in all cases. Resection of hyoid bone was mandatory because of different embrional pathways of thyroid gland positioning. The procedure was followed by dissection of submental and prehyoid lymph nodes (LN) and bilateral biopsy of LN around common carotid artery bifurcation. All dissected LN were examined by frozen section and standard histopathology. In the same act 10 out of 11 patients underwent total thyroidectomy for frozen section histology. In one patient we performed resection of isthmus and partial resection of the right thyroid lobe. In cases of synchronous thyroid gland carcinomas, immediate central neck dissection (level 6 and 7) and frozen-section examination of level 4 LN was performed. In cases of LN metastases modified radical neck dissections (MRND) were performed.

**Results:** Definitive histopathology revealed 11 papillary and one follicular thyroid carcinomas in TDC. Synchronous thyroid gland carcinomas were found in 3 cases (25%). Lymph node metastases were found in six cases (50%) with following distribution in the neck: level 1 in 5, level 3 in 4, level 4 in 2 and level 6 in 3 cases. MRND was done in 4 cases and central neck dissection in 3 cases. Radioiodine therapy was applied in 42% of patients. In a follow-up time all patients were alive without evidence of relapse.

**Conclusion:** Our experience implies that thyroid carcinomas in TDC were associated with synchronous thyroid gland carcinomas in 25% and LN metastases in 50% of cases. TDC thyroid carcinoma should be treated as thyroid gland carcinomas by total thyroidectomy. In a lack of surgical consensus, algorithm of lymph node management can be safely applied to obtain optimal radical surgery and disease staging in those patients.

**Abstract ID: 0858** Specific Field: **Endocrine Surgery**

**Mode of pres.: Free Paper**  
**ISW 2011 Session 5.06**

**Clinical features, treatment and long-term outcome of papillary thyroid cancer in children and adolescents without radiation exposure**

Y. Enomoto, K. Enomoto, S. Uchino, H. Noguchi, S. Noguchi

Noguchi Thyroid Clinic and Hospital Foundation, Beppu, Oita, Japan

**Introduction:** Thyroid cancer (TC) is rare in children and adolescents. History of the neck irradiation is a well-established risk factor for TC development, and most previous reports focused on cases induced by radiation exposure. We present a retrospective review of clinical features, treatment and long-term outcome for children and adolescent papillary TC (PTC) without history of radiation exposure that have been treated in the Noguchi Thyroid Clinic and Hospital Foundation over a period of about 50 years.

**Material and Methods:** We studied 142 PTC without irradiation history in patients younger than 20 year treated from 1961 through 2005 (17 males and 125 females; age  $16.3 \pm 2.7$  year [range 6–19]; follow-up  $22 \pm 12$  years). The clinicopathological results were evaluated in all patients. Disease-Free Survival (DFS) and Cause-Specific Survival (CSS) were assessed with the Kaplan–Meier method and compared with the log-rank test.

**Results:** At diagnosis, 3 had distant lung metastasis, and 33 had neck lymph node (LN) metastasis. All patients were treated with surgery (hemi/partial thyroidectomy in 45, total/subtotal thyroidectomy in 97), and postoperative radiation therapy was performed in 60. The recurrences were found in neck LN ( $n = 25$ ), lung ( $n = 9$ ), remnant thyroid gland ( $n = 5$ ), and others ( $n = 4$ ). The DFS and the CSS at 40 years were 74.1% and 97.5%, respectively. Significant differences in DFS were observed in ages under 16 year ( $P = 0.03$ ), familial history of TC ( $P = 0.04$ ), clinically neck LN metastasis ( $P < 0.01$ ), tumor diameter ( $P = 0.03$ ), extra thyroidal invasion ( $P < 0.01$ ), and histological neck LN metastasis ( $P < 0.01$ ). Clinical LN metastasis ( $P = 0.01$ ) and distant metastasis ( $P < 0.01$ ) at diagnosis were significant factors for CSS. Other factors did not contribute to DFS and CSS. Postoperative hypoparathyroidism was significantly more frequent in total/subtotal thyroidectomy than in hemi/partial thyroidectomy ( $P = 0.01$ ). There was no significant difference in the incidence of laryngeal palsy.

**Conclusion:** PTC in children has a higher recurrence rate than in adolescents, but there is no difference in survival rate. Lung and neck LN are most common metastatic foci for PTC in children and adolescents. Presence of these metastasis at diagnosis were significant factors for survival. Extent surgery and postoperative radiation therapy did not improve outcome, but increased the rate of postoperative hypoparathyroidism.

**Abstract ID: 0859** Specific Field: **Endocrine Surgery**

**Mode of pres.: Free Paper**  
**ISW 2011 Session 25.01**

**Characterization of thyroid nodules using the proposed Thyroid Imaging Reporting and Data System (TI-RADS)**

S. P. Cheng, J. L. Lin, S. M. Chuang, M. N. Chien, J. J. Lee, C. L. Liu  
 Mackay Memorial Hospital, Taipei, Taiwan

**Introduction:** Thyroid ultrasound plays an important role in risk stratification and management of patients with thyroid nodules. There

are, however, few data on standardization of sonographic findings and terminology. Recently, the Thyroid Imaging Reporting and Data System (TI-RADS) was proposed based on a scheme similar to BI-RADS lexicon used in breast lesions. The purpose of this study was to evaluate its interobserver variability and potential application to clinical decision making.

**Material and Methods:** We included 498 nodules in 437 patients undergoing thyroidectomy whose preoperative ultrasound images were available in our picture archiving and communications system. There were 336 (67%) benign lesions, 36 (7%) incidental microcarcinomas, 23 (5%) follicular adenomas, and 103 (21%) thyroid carcinomas. Two endocrine surgeons and two endocrinologists blinded to the pathological diagnosis and clinical information retrospectively reviewed sonographic images. Each lesion was assigned a TI-RADS category by each observer. Benign lesions and incidental microcarcinomas were grouped as “benign”. Follicular lesions and malignant tumors were grouped as “non-benign”. Institutional review board approval was obtained.

**Results:** There was substantial interobserver agreement for final assessment category ( $\kappa = 0.61$ ), but considerable discrepancies among categories were noted ( $\kappa = 0.77, 0.54, 0.64, 0.47$ , and  $0.40$  for category 2, 3, 4A, 4B, and 5, respectively). Interobserver agreement was generally higher for benign lesions than for malignant lesions. The overall sensitivity, specificity, and negative predictive value were 94%, 43%, and 96%, respectively. Positive predictive values for categories 4 and 5 were 32% (24% for 4A and 52% for 4B) and 60%.

**Conclusion:** The TI-RADS is a helpful but not optimal reporting tool in classifying thyroid lesions with different risks of malignancy. A classification system which describes and illustrates sonographic features more precisely is needed.

**Abstract ID: 0860** Specific Field: **Endocrine Surgery**

**Mode of pres.: Free Paper**  
**ISW 2011 Session 25.02**

**Parathyroid 4DCT: evaluation of radiation dose exposure during preoperative localization of parathyroid tumors in primary hyperparathyroidism**

A. Mahajan, L. F. Starker, M. Ghita, R. Udelsman, J. Brink, T. Carling

Yale University School of Medicine, New Haven, CT, USA

**Introduction:** Parathyroid 4-dimensional CT (4DCT) provides greater sensitivity than sestamibi with SPECT (SeS) for preoperative localization of parathyroid tumors in primary hyperparathyroidism (PHPT). The routine use of 4DCT remains controversial due to concern of thyroid radiation exposure. The radiation dose imparted to the patient during preoperative parathyroid imaging, however, has not been analyzed.

**Material and Methods:** Patients with biochemically unequivocal PHPT referred for minimally invasive parathyroidectomy underwent 4DCT or SeS. 4DCT was performed using a 64 detector row CT scanner in one non- and 3 post-contrast phases at 1.25 mm slice thickness from the angle of the mandible to the tracheal carina using an x-ray tube voltage of 120 kV. SeS used a standardized protocol of 20 mCi of Tc-99m followed by planar and SPECT images. The CT radiation dose was estimated using the ImPACT (Imaging Performance Assessment of CT Scanners) calculator, and the SeS dose was estimated using the NUREG (US Nuclear Regulatory Commission Regulation) method. The patient effective and organ specific doses were calculated and expressed as absorbed dose in various organs. Calculated effective doses are expressed according to



recommendations of the ICRP (International Commission on Radiological Protection) 103.

**Results:** The calculated patient effective dose of 4DCT and SeS was 26.4 and 7.8 mSv, respectively, as compared to an estimated annual background radiation exposure of approximately 2.5 mSv and the annual average per capita radiation dose received from medical procedures of 3.2 mSv in the United States. The thyroid dose of 4DCT, however, was about 100 times higher (188 mGy vs. 1.6 mGy) compared to SeS. Based on the age and gender-dependent risk factors from the multiplicative model from the Biological Effects of Ionizing Radiation Committee VII (BEIR VII), the calculated risk of thyroid cancer for a 40 year old female patient from 4DCT was 263/million (i.e. about 0.03%).

**Conclusion:** 4DCT, a superior preoperative imaging modality of parathyroid tumors, is associated with significantly higher thyroid radiation dose than SeS. Given the enhanced risk of thyroid cancer in individuals with radiation exposure at a young age, 4DCT should be used extremely judiciously in young PHPT patients.

**Abstract ID: 0861** Specific Field: **Endocrine Surgery**

**Mode of pres.: Free Paper**  
**ISW 2011 Session 25.03**

**Risk of iatrogenic nerve injury with heat producing surgical instruments**

J. Carlander [1], K. Johansson [2], C. Koch [3], O. Gimm [2], L. Brudin [4], C. Nordborg [5]

[1] Department of Surgery, Västerås, Sweden, [2] Department of Surgery, University Hospital, Linköping, Sweden, [3] PTB, Braunschweig, Germany, [4] Department of Clinical Physiology, Kalmar, Sweden, [5] Department of Pathology, Sahlgrenska University Hospital, Gothenburg, Sweden

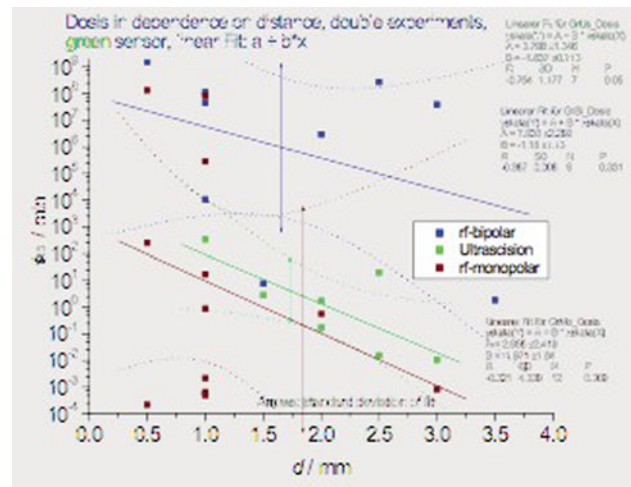
**Introduction:** Postoperative nerve dysfunction is a problem in many areas of surgery and may be caused by heat produced by surgical instruments. The aim of this study was to compare an ultrasonically activated instrument (US), monopolar electrocautery (ES) and bipolar ES in respect to heat production, nerve function and nerve morphology following in vivo application.

**Material and Methods:** The biceps femoris muscle of anesthetized rats was cut in a standardized manner longitudinally 1 mm adjacent to the sciatic nerve using US shears, monopolar ES knife or bipolar ES scissors. Activation time and temperature was recorded continuously within 1–4 mm of the activation site (green sensor) and behind the nerve using two thermoelectric microsensors designed for application in tissue. Temperature rise and time delay, as an expression of heat spread within tissue, maximum temperature and thermal dose (minutes of exposure at 43 degrees C) were measured and calculated. A total of 49 functional experiments were conducted. The electromyographic (EMG) potential was recorded distally before and after each experiment. Nerve dysfunction was defined as more than 10 per cent loss of the evoked EMG potential. Forty-eight nerves were coded and submitted to blind histopathological examination and graded on a 4 grade scale.

**Results:** The maximum temperature elevation and thermal dose was significantly higher for the bipolar ES compared with the US instrument ( $P = 0.015$  resp  $P = 0.049$ ), and with much less thermal variation for the US instrument (Fig 1). The monopolar ES maximum temperature and thermal dose were lower but very large variation probably due to more random spread to the ground electrode and muscle motion artefacts making comparison unreliable. Functional loss were least common in the US group without being significant

compared to bipolar and monopolar ES ( $P = 0.11, P = 0.10$ ). Moderate and severe morphological damage was significant less common in the US group compared to the monopolar ES group ( $P = 0.01$ ). We found no correlation between the highest temperatures and morphological damages.

**Conclusion:** The temperature elevation depends strongly on the distance to the activated instrument. The bipolar ES scissors generates a higher maximum temperature and thermal dose with a greater variation in temperature than the US. Functional loss and severe morphological damage was uncommon in all groups.



**Figure** Thermal dose

**Abstract ID: 0862** Specific Field: **Endocrine Surgery**

**Mode of pres.: Free Paper**  
**ISW 2011 Session 25.04**

**Incidence, management and outcome of laryngeal diplegia after thyroidectomy**

C. Desvant, R. Caiazzo, L. Arnalsteen, M. Gregoire, G. Dezfoulian, D. Chevalier, B. Carnaille, F. Pattou

Lille University Hospital, Lille, France

**Introduction:** Laryngeal diplegia (LD) is the most dreaded complication after thyroidectomy. Not always predictable, LD is rarely reported and its clinical management and outcome remain ill defined.

**Material and Methods:** Retrospective analysis of the incidence, the clinical management and the outcome of postoperative LD following total thyroidectomy during 8 consecutive years (2000–2007) in an academic department of endocrine surgery. All patients routinely underwent preoperative and immediately postoperative laryngoscopy.

**Results:** Postoperative LD occurred in 31 patients (7H/22F,  $51 \pm 17$  years) with an overall incidence of 0.7%. Three patients had previous neck surgery (10%) and four had pre-existing laryngeal palsy (12%). The thyroid disease was malignant in 18 cases (58%). The procedure included central lymph node dissection in 16 cases (51%), and/or lateral lymph node dissection in 11 cases (34%). Difficulty arouse during laryngeal nerve dissection in 16 cases (52%) and one laryngeal nerve was deliberately sacrificed in one case (3%). Transient hypocalcemia occurred in 7 patients (23%). Corticosteroids were administered during surgery in 28 cases (91%) and postoperatively (IV and aerosols) in all patients. Immediate tracheal re-intubation was

required due to dyspnea in 13 cases (42%), and maintained during 24 hours ( $n = 2$ ), 48 hours ( $n = 8$ ), or more ( $n = 3$ ). A complementary procedure was necessary in 4 cases (13%), including 2 tracheostomies and 2 partial posterior cordectomies. The average length of stay was  $8 \pm 6$  days (max 27 days), including  $4 \pm 5$  days in the intensive care unit. Two patients died of upper airway obstruction after discharge, one for tumoral evolution, and one as a direct consequence of DL. Partial recovery of laryngeal mobility was observed in 27 patients (88%) after  $18 \pm 25$  days (max 77 days). Full recovery of laryngeal mobility was achieved in 7 patients (22%) after 3 months, 19 (61%) at 6 months, and 24 patients (77%) at one year.

**Conclusion:** DL is rare but not exceptional (0.7%) after thyroidectomy. It can often be predicted by previous history or during intervention. In the absence of laryngeal nerve sacrifice and with an aggressive initial management based on early tracheal reintubation and use of topical and general corticosteroids, the LD recovers in most cases. It may however requires a laryngeal complementary procedure and can be life-threatening.

**Abstract ID: 0863** Specific Field: **Endocrine Surgery**

**Mode of pres.: Free Paper**  
**ISW 2011 Session 25.05**

**Post-operative radioactive iodine scans in patients with papillary thyroid cancer after total thyroidectomy and prophylactic central lymph node dissection**

A. M. Laird, P. G. Gauger, G. M. Doherty, B. S. Miller  
University of Michigan, Ann Arbor, USA

**Introduction:** Background: Prophylactic central lymph node dissection (CLND) accompanying total thyroidectomy for papillary thyroid cancer (PTC) remains controversial. Our hypothesis is that CLND may identify patients who benefit from post-operative radioactive iodine (RAI).

**Material and Methods:** Methods: 119 patients without clinically evident nodal metastases underwent total thyroidectomy/bi-lateral central neck dissection for papillary thyroid cancer (PTC)  $>1$  cm from 2002–2010. Pathology results, RAI results, and outcomes were compared between node positive (NP) and node negative (NN) patients.

**Results:** Results: NP and NN patients were similar with respect to age, gender, tumor size, and MACIS score. Mean number of nodes excised was 7.8. Mean number of parathyroid glands autotransplanted was 0.78, the rate of permanent hypocalcemia was 1.68%, the rate of temporary recurrent laryngeal nerve injury was 1.68%, with no permanent nerve injuries. Fourteen of 52 (27%) NN patients and 24/67 (36%) of NP patients had suspicious nodes by intraoperative inspection. The node-assessment negative predictive value was 47%; the positive predictive value was 63%. 56% (67/119) of patients were NP; 101 patients were treated with RAI for ablation of remnant tissue or nodal disease. Fourteen of 62 NP patients had abnormal post-operative RAI scans outside of the thyroid remnant, compared to 5/39 NN patients (23% vs. 13%,  $P = 0.17$ ). Median stimulated thyroglobulin (Tg) level at 1 year was 0.0 for both groups (0.0–1.2, NN; 0.0–22.7, NP;  $P = 0.07$ ). Comparing 1-year stimulated Tg, 1/21 NN and 10/44 NP patients had levels  $>1$  ( $P = 0.07$ ). NP patients received higher doses of RAI (119.7 vs. 59.8 mCi,  $P < 0.0001$ ). Four of 119 patients (3.4%) recurred requiring reoperation (mean follow-up of 28 months) with one had central neck node recurrence. Remaining recurrences were in the lateral neck in the NP group.

**Conclusion:** Conclusion: Few node-negative patients have abnormal RAI scans outside of the thyroid bed. Node-positive patients had greater

variability in stimulated Tg levels 1 year after higher doses of RAI. Intraoperative inspection of lymph nodes was inaccurate to identify patients with involved nodes. CLND may identify patients most likely to have persistent elevated stimulated Tg after initial therapy for PTC.

**Abstract ID: 0864** Specific Field: **Endocrine Surgery**

**Mode of pres.: Free Paper**  
**ISW 2011 Session 25.06**

**Is the intraoperative neuromonitoring useful during redo thyroid surgery: results of a retrospective comparative analysis**

P. F. Alesina, T. Rolfs, S. Hommeltenberg, J. Hinrichs, B. Meier, W. Mohmand, S. Hofmeister, M. K. Walz

Kliniken Essen-Mitte, Essen, Germany

**Introduction:** Recurrent laryngeal nerve (RLN) palsy is certainly the major concern during reoperative thyroid surgery and the introduction of neuromonitoring could be supposed to reduce the rate of this complication. The present study is a retrospective analysis of the experience with completion thyroidectomy with and without neuromonitoring in a referral centre.

**Material and Methods:** Between October 1999 and November 2010, 4222 thyroid operations were performed for benign or malignant diseases. During the same period 238 patients (39 men, 199 women; mean age:  $55 \pm 12$  years, range: 25–80) underwent a reoperation for recurrent goitre ( $n = 196$ ), hyperthyroidism ( $n = 23$ ) or recurrent thyroid cancer ( $n = 19$ ). The mean interval between the initial and the reoperative procedure was 17.5 years. According to the availability of the neuromonitoring system (since 2005) and to the surgeon preference, 72 operations were performed under neuromonitoring control (NM-Group) and 167 were performed with direct nerve visualization only (NV-Group). Patients' characteristics, perioperative data as well as postoperative complications were collected in a prospectively maintained database.

**Results:** In the NM-Group 40 unilateral and 32 bilateral resections were performed, whereas 120 and 46 in the NV-Group, respectively. We registered 5 RLN palsy in the NM-Group and 6 in the NV-Group [ $P = 0.31$ ]. The incidence of postoperative transient hypoparathyroidism was 8.4% (NM-Group) and 5.4% (NV-Group) [ $P = 0.38$ ]. The rate of postoperative bleeding was 2.5% (2 and 4 cases, respectively) [ $P = 1.0$ ]. No wound infection was observed in both groups.

**Conclusion:** The routine use of intraoperative neuromonitoring seems not to reduce the incidence of RLN in redo thyroid surgery, at least in the setting of a tertiary referral centre.

**Abstract ID: 0865** Specific Field: **Endocrine Surgery**

**Mode of pres.: Free Paper**  
**ISW 2011 Session 25.07**

**Clinico-pathological profile, airway management and outcome in huge multinodular goiters ( $\geq 300$  g): an institutional experience from an endemic goiter region**

A. Agarwal, S. Agarwal, P. Tewari, G. Chand, A. Mishra, G. Agarwal, A. K. Verma, S. K. Mishra

SGPGIMS, Lucknow, India

**Introduction:** Information regarding problems unique to large goiters is sparse. Huge-goiters are of concern to the surgeons due to anticipated increased chances of surgical complications, and to anesthetists' due to anticipated intubation related difficulties and tracheomalacia.

We present our experience of managing 72 patients with huge goiters, highlighting their clinico-pathological profile, peri-operative airway related difficulties, their management and morbidity compared to smaller goiters.

**Material and Methods:** Retrospective analysis of patients who underwent total thyroidectomy in primary setting at our institute from 1995 till 2009 was done and based on the gross gland weight grouped them into Group A-300 g and Group B-200 g. Data was analyzed using mean  $\pm$  SD, Student t-test and Chi-square.

**Results:** There were 72 patients in Group A and 670 in Group B. Mean gross gland weight was 476.3 vs. 72.31 g ( $p=0.000$ ), Group A patients were older ( $p=0.000$ ), had longer duration of goiter ( $p=0.000$ ), higher rate of compressive symptoms ( $p=0.000$ ), retro-sternal extension ( $p=0.000$ ), thoracic-inlet syndrome ( $p=0.000$ ), and tracheal compression ( $p=0.000$ ). In Group A intubation difficulty was present in 16.7% cases. Rate of tracheomalacia ( $p=0.000$ ), sternotomy ( $p=0.049$ ) and mean duration of hospital stay ( $p=0.000$ ) was significantly higher in Group A whereas mean duration of surgery ( $p=0.079$ ), recurrent-laryngeal nerve (RLN) injury ( $p=0.264$ ), hemorrhage ( $p=0.120$ ) wound complications ( $p=0.285$ ); temporary hypocalcaemia ( $p=0.293$ ); temporary RLN palsy ( $p=0.848$ ) permanent hypo-parathyroidism ( $p=0.639$ ) and permanent-RLN palsy ( $p=0.423$ ) was not significantly different.

**Conclusion:** Long standing huge goiters is common in iodine deficient endemic areas. Majority of the patients have clinico-radiological evidence of airway involvement. Incidence of retrosternal extension, airway deformity, intubation difficulty, and tracheomalacia is high with huge goiters. Surgery is technically demanding with higher chances of injury to native structures. However, in centers with experienced endocrine surgeons and dedicated anesthetists huge goiters can be successfully managed with minimal short and long term morbidity.

**Abstract ID: 0866** Specific Field: **Endocrine Surgery**

**Mode of pres.: Free Paper**  
**ISW 2011 Session 45.01**

**Combination of dexamethasone and tropisetron before thyroidectomy to improve postoperative nausea, vomiting and pain: a randomized controlled trial**

H. Zhou, H. T. Xu, J. Zhang, W. J. Wang, Y. Wang, Z. Q. Hu

Department of General Surgery, Changzheng Hospital, Shanghai, China, People's Republic

**Introduction:** Nausea, vomiting, and pain alteration frequently occur after thyroidectomy. Little evidence exists regarding effects of combination of dexamethasone and tropisetron in patients undergoing thyroidectomy. We aim to evaluate the effects of combination of dexamethasone and tropisetron on thyroidectomy outcomes.

**Material and Methods:** 150 patients undergoing thyroidectomy were included in this prospective randomized, controlled, three armed (group D: 8 mg dexamethasone,  $n=50$ ; group T: 5 mg tropisetron,  $n=50$ ; group D + T: 8 mg dexamethasone and 5 mg tropisetron,  $n=50$ ), study. Nausea, vomiting, and pain, antiemetic and analgesic consumptions were recorded 2, 4, 8, 16, 24, 36, and 48 hours postoperatively.

**Results:** The complete response rate of nausea and vomiting was significantly higher in group D + T (78%, 39/50), compared with those in group D (58%, 29/50) and group T (66%, 33/50) ( $P=0.01$ ). The incidence and severity of nausea in the group D + T was

significantly lower, compared with those in group D and group T, and the difference mainly occurred in the late postoperative period (6–48 h). The severity of postoperative pain was significantly lower in the dexamethasone-containing groups compared with tropisetron group.

**Conclusion:** Combination of dexamethasone and tropisetron offers better prophylaxis for nausea, vomiting and pain than either drug alone in patients undergoing thyroidectomy, especially in late period (6–48 h). (ChiCTR-TRC-00000558).

**Abstract ID: 0867** Specific Field: **Endocrine Surgery**

**Mode of pres.: Free Paper**  
**ISW 2011 Session 45.02**

**Rate of clinically significant post operative pancreatic fistula in pancreatic neuroendocrine tumor**

S. Inchauste [1], B. Lanier [1], S. Libutti [2], G. Phan [1], N. Nilubol [1], S. Steinberg [1], E. Kebebew [1], M. B. Hughes [1]

[1] National Institutes of Health, National Cancer Institute Surgery Branch, Bethesda, USA, [2] Albert Einstein Cancer Center, Montefiore Medical Center, Bronx, USA

**Introduction:** In 2005, the International Study Group of Pancreatic Fistula (ISGPF) developed a definition and grading system for post-operative pancreatic fistula (POPF). There is very little data on POPF rate for pancreatic neuroendocrine tumor (PNET). The authors sought to determine the rate of clinically significant POPF after enucleation or resection of PNETs and identify clinical, surgical, or pathologic factors associated with POPF.

**Material and Methods:** A retrospective single institution review was done for pancreatic enucleations or resections performed from March 1998 to April 2010. We defined a clinically significant fistula as ISGPF Grade B requiring nonsurgical intervention and Grade C POPF. Fisher's exact test and Wilcoxon rank sum test were performed to evaluate the association between dichotomous and continuous clinical parameters.

**Results:** Of 122 patients, 62 underwent pancreatic enucleation and 60 patients underwent pancreatic resection including distal pancreatectomy, pancreaticoduodenectomy or both. Our clinically significant fistula rate for pancreatic neuroendocrine tumors was 23.7% (29/122). We identified 24/122 (16.4%) Grade B (14 enucleation and 10 resection) and 5/122 (4.1%) Grade C (3 enucleation and 2 resection). There was no significant difference in POPF between patients who underwent enucleation (27.4%) versus resection (20%) ( $P=0.4$ ). Patients with VHL or MEN-1 ( $P=0.02$ ) versus sporadic PNET's and noninsulinoma histology ( $P=0.02$ ) had increased POPF rate after enucleation. Patients with BMI > 25 ( $P=0.004$ ), MEN-1 ( $P=0.0047$ ) and those with multiple procedures such as enucleation and resection or pancreaticoduodenectomy and distal pancreatectomy ( $P=0.02$ ) had an increased POPF rate after resection. In a univariate analysis age, gender, albumin, number of lesions resected, size and location of largest lesion, functional status, were factors not associated with POPF.

**Conclusion:** Using the ISGPF criteria as a guide we found the clinically significant POPF for pancreatic neuroendocrine tumors was 23.7% with no difference by type of operation. Our POPF is comparable to that found in the literature for pancreatic resection for pancreatic adenocarcinoma. Certain familial diseases were associated with a higher rate of POPF possibly due to underlying abnormal pancreatic parenchyma such as cystic lesions in VHL and microscopic multiple PNETs in MEN.



**Abstract ID: 0868** Specific Field: **Endocrine Surgery**

**Mode of pres.: Free Paper**  
**ISW 2011 Session 45.03**

**Video-assisted versus conventional total thyroidectomy and central compartment neck dissection for papillary thyroid carcinoma**

R. Bellantone, M. Raffaelli, L. Revelli, C. De Crea, A. D'Amore, L. Sessa, V. Rampulla, C. P. Lombardi

Università Cattolica del Sacro Cuore-Policlinico "A. Gemelli", Rome, Italy

**Introduction:** Papillary thyroid carcinoma (PTC) may require central compartment neck dissection (CCD) even in the absence of preoperatively demonstrated lymph node involvement. Despite video-assisted (VA) thyroidectomy emerged as an effective treatment option for selected patients with PTC, some concerns still remain about the possibility to obtain an adequate central neck node clearance if indicated. We compared patients who underwent VA and conventional total thyroidectomy (TT) and CCD for PTC.

**Material and Methods:** Fifty-two consecutive consenting patients successfully underwent VA TT and CCD for PTC (VA-Group). Selection criteria were: small PTC (35 mm); thyroid volume 30 ml; no previous neck surgery; absence of any preoperative evidence of lymph node metastases. A case-control study including 52 controls who underwent conventional TT and CCD (C-Group) for PTC without any preoperative evidence of lymph node involvement was performed. The controls were matched for age, sex and tumor size.

**Results:** The two groups were well matched for age, sex and tumor size ( $P = NS$ ). Operative time and postoperative complications were similar in the two groups ( $P = NS$ ). No significant difference was found between the two groups concerning pT and pN ( $P = NS$ ). The mean number of removed nodes was similar in the two groups ( $10.6 \pm 4.6$  in VA-Group Vs  $12.2 \pm 5.6$  in C-Group) ( $P = NS$ ). Mean postoperative serum thyroglobulin (sTg) off levothyroxine (LT4) suppressive treatment was  $3.2 \pm 5.0$  ng/ml in the VA-Group and  $2.6 \pm 7.4$  ng/ml in the C-Group ( $P = NS$ ). Mean post-operative radioiodine uptake (RAIU) was similar in the two groups ( $1.5 \pm 1.3\%$  Vs  $1.7 \pm 1.3\%$ ) ( $P = NS$ ). When considering only patients with central neck node metastases (pN1a), no significant difference was found between VA-Group (21 patients) and C-Group (24 patients) concerning the mean number of removed nodes ( $10.3 \pm 4.1$  Vs  $12.4 \pm 5.6$ ) ( $P = NS$ ), the mean RAIU ( $1.9 \pm 1.5\%$  Vs  $1.7 \pm 1.3\%$ ) ( $P = NS$ ) and the mean sTg off LT4 ( $4.4 \pm 6.0$  ng/ml Vs  $1.9 \pm 2.7$  ng/ml) ( $P = NS$ ). No patients in both groups showed recurrent disease.

**Conclusion:** The results of VA TT and CCD in case of PTC seem comparable to those of conventional operation, even in case of central neck lymph node involvement. Gross central neck metastases still represent a contraindication for the VA approach. A longer follow-up and larger series are necessary to draw definitive conclusions concerning long-term local and regional recurrence.

**Abstract ID: 0869** Specific Field: **Endocrine Surgery**

**Mode of pres.: Free Paper**  
**ISW 2011 Session 45.04**

**Combining early postoperative parathyroid hormone and serum calcium levels allows for an efficacious selective post-thyroidectomy supplementation treatment**

M. Raffaelli, C. De Crea, A. D'Amore, G. D'Amato, L. Sessa, R. Bellantone, C. P. Lombardi

Università Cattolica del Sacro Cuore-Policlinico "A. Gemelli", Rome, Italy

**Introduction:** Optimal treatment protocol (routine Vs selective; oral calcium [OC] with or without vitaminD [VD]) to prevent symptomatic hypocalcemia following total thyroidectomy (TT) is matter of debate. Postoperative PTH measurement has been proposed as a guide for early selective supplementation, but hypocalcemia may develop even in presence of normal PTH levels in up to 14% of the cases. We prospectively evaluated the efficacy of an algorithmic protocol to prevent post-TT hypocalcemia based on both early postoperative (PO) PTH and serum calcium levels.

**Material and Methods:** 230 consecutive patients who underwent TT were divided in three different groups of treatment according to PTH levels 4 hours after the end of the operation (4 h-PTH) and serum calcium levels in the morning of the first postoperative day (IPO-Ca): group A (4 h-PTH  $>10$  pg/ml and IPO-Ca 8.5 mg/dl) no treatment; group B (4 h-PTH  $>10$  pg/ml and IPO-Ca  $<8.5$  mg/dl) OC 3 g per day; group C (4 h-PTH 10 pg/ml) OC 3 g + VD 1  $\mu$ g per day. Treatment was started on PO day 1 in groups B and C. Biochemical hypocalcemia was defined as serum calcium  $<8.0$  mg/dl, even if in one single measurement obtained following PO day 1.

**Results:** Overall, 59 patients (25.6%) had subnormal 4 h-PTH levels (10 pg/ml) (Group C). Among 171 patients (74.4%) with normal 4 h-PTH levels, 25 (10.9%) had subnormal IPO-Ca ( $<8.5$  mg/dl) (Group B). The remaining 146 patients (63.5%) had normal 4 h-PTH and IPO-Ca levels (Group A). No patients in groups A and B developed biochemical hypocalcemia. Among the patients in group C, 18 (30.5% of the hypoparathyroid patients and 7.8% of all the series) developed biochemical hypocalcemia and 3 (5.1% of the hypoparathyroid patients and 1.3% of all the series) referred some minor symptoms. OC supplementation treatment was discontinued within PO day 8 in all the 25 patients in group B. OC and VD supplementation was discontinued within PO day 14 in most of the patients of group C (36/59–61.0%).

**Conclusion:** An algorithmic selective supplementation treatment protocol, incorporating both 4 h-PTH and IPO-Ca, seems efficacious in preventing post-TT hypocalcemia, biochemical and/or symptomatic. It could allow a safe and early discharge of most of the patients who underwent TT, avoiding both the constraints and the costs of routine OC and VD supplementation and the risk of rehospitalization.

**Abstract ID: 0870** Specific Field: **Endocrine Surgery**

**Mode of pres.: Free Paper**  
**ISW 2011 Session 45.05**

**Ectopic hormone secreting pheochromocytoma: a francophone observational study**

J. Kirkby-Bott [1], A. F. C. E. Research Collaborators [2], B. Carnaille [1]

[1] CHRU Lille, Lille, France, [2] Association Francophone de Chirurgie Endocrinienne, France

**Introduction:** Ectopic hormone secreting pheochromocytomas are rare, only case reports exist in the literature. This condition has been linked with increased malignancy, familial syndromes and ACTH secretion. We wanted to test these hypotheses and shed light on the nature of ectopic hormone secreting pheochromocytomas.

**Material and Methods:** This is a multi-centre (francophone) observational study. Inclusion was based upon abnormal pre-operative



hormone tests in patients with pheochromocytoma that normalised after removal of the tumour. Where possible immuno-histochemistry was performed to confirm ectopic secretion came from the tumour.

**Results:** 16 cases were found. There were 9 female and 7 male patients. Median age was 50.5 years (31–89). Most presented with hypertension, diabetes or cushingoid features. 10 patients had specific symptoms from the ectopic hormone secretion. Two had a familial syndrome. Of 8 patients with excess cortisol secretion, 3 died as a result of the tumour resection: 2 had pheochromocytomas >15 cm and their associated cortisol hyper-secretion complicated their post-operative course, the other died from a torn sub hepatic vein. The 13 survivors didn't develop any evidence of malignancy during follow-up (median 50 mth). Symptoms from the ectopic secretion resolved after removal of the tumour. Immuno-histochemistry was performed and positive in 8 tumours: 5 ACTH, 3 calcitonin and 1 VIP.

**Conclusion:** Most pheochromocytomas with ectopic secretion are neither malignant nor familial. Most ectopic hormones secrete cortisol. Patients with a pheochromocytoma should be worked up for ectopic hormones as removal of the pheochromocytoma resolves those symptoms. Associated cortisol secretion needs careful attention.

**Abstract ID: 0871** Specific Field: **Endocrine Surgery**

**Mode of pres.: Free Paper**  
**ISW 2011 Session 45.06**

**Level VI lymph node dissection does not decrease radioiodine uptake in patients undergoing radioiodine ablation for differentiated thyroid cancer**

P. J. Mazzaglia

Rhode Island Hospital, Warren Alpert School of Medicine, Brown University, Providence, USA

**Introduction:** In patients with well-differentiated thyroid cancer, the incidence of pathologic central compartment lymph node metastases is reported to be approximately 50%. Recently level VI lymph node dissection has been advocated as a means of reducing recurrence rates, even if there are no clinically apparent nodal metastases. This study investigates whether level VI lymph node dissection decreases the percent radioiodine uptake when patients undergo radioiodine ablation.

**Material and Methods:** All thyroid cancer patients entered into the endocrine surgery database at a tertiary care center from 2006–2010 were reviewed. Those treated with radioactive iodine were analyzed for performance of a central compartment lymph node dissection, and the percent uptake of radioiodine (I131) on the pre-ablation scan.

**Results:** There were 148 patients with well-differentiated thyroid cancer. Sixty-one of them have received radioiodine ablation. Sixty-nine percent were female, and mean age was 46. Twenty-two patients underwent central compartment lymph node dissection. The mean number of level VI nodes resected was 10 (125), and mean number positive for metastatic disease was 3.6 (011). Additionally 9 of these patients had a simultaneous lateral neck dissection for metastatic disease. Thirty-nine patients did not have a formal level VI neck dissection, and mean number of nodes resected was 1.3 (05). The percent uptake of radioiodine on the pre-ablation scan was  $2.65 \pm 2.65\%$  in patients who had undergone level VI lymph node dissection, and  $2.87 \pm 5.80\%$  in those who had not ( $P = 0.86$ ). The number of radioactive foci noted within the thyroid bed was  $2.8 \pm 1.5$  in the level VI dissection group, versus  $2.3 \pm 1.3$  in patients without formal lymph node dissection ( $P = 0.26$ ).

Pre-ablation thyroglobulin levels measured after thyroxine withdrawal or thyrogen stimulation were  $30.1 \pm 48.5$  ng/ml in the level VI dissection group, versus  $3.6 \pm 5.4$  ng/ml in patients who had not undergone central compartment dissection ( $P = 0.008$ ). The average ablative dose of I131 was 116.1 mCi in the dissection group and 91.1 mCi in the others ( $P = 0.01$ ).

**Conclusion:** There is no evidence that uptake of I131 is reduced by the performance of a central neck dissection in patients with well-differentiated thyroid cancer.

**Abstract ID: 0872** Specific Field: **Endocrine Surgery**

**Mode of pres.: Free Paper**  
**ISW 2011 Session 146.02**

**Adrenalectomy improves outcomes of selected patients with metastatic carcinoma**

B. Vazquez, M. Richards, C. Lohse, J. Moreno, G. B. Thompson, D. Farley, M. Huebner, C. Grant

Mayo Clinic, Rochester, USA

**Introduction:** The adrenal glands are commonly involved by metastatic disease and the indications for adrenalectomy (ADX) are not clearly defined. This study aims to identify prognostic factors for overall survival (OS) and determine which malignancies may benefit from ADX for metastatic disease.

**Material and Methods:** A retrospective review (1992–2010) was conducted to identify patients treated with ADX for metastatic cancer. Recurrence-free survival (RFS) and OS were determined. Clinical, surgical and pathologic features were evaluated. OS for those treated with ADX was compared to OS of SEER database stage IV patients that underwent primary resection without resection of distant disease.

**Results:** 166 patients underwent ADX to resect metastatic disease from primary malignancies involving: kidney-60, lung-24, sarcoma-19, colon-15, pancreas-13 and other sites-35. Intent was cure in 45% and palliation in 55%; 30% had persistent disease. 101 died at a mean of 1.9 years postop. Mean follow-up for the 65 alive was 3.1 years. Estimated OS rates at 1, 5 and 10 years following ADX were 68%, 31% and 17% (median OS, 2.2 years). 58/81 with recurrence data recurred at a mean of 1.3 years. Estimated RFS rates at 1, 5 and 10 years were 51%, 19% and 14% (median RFS 1.1 years). Univariate analysis identified primary diagnosis <2 years before ADX, other distant site, pancreatic primary, palliative operation and persistent disease as risks for death ( $P < 0.05$ ). There was no relationship between the risk of death and age, gender, open vs. laparoscopic resection and tumors of the kidney, lung or colon. Patients with sarcoma, kidney, lung and pancreas tumors who underwent ADX had improved estimated OS rates at 1, 2 and 3 years compared to the SEER cohort (sarcoma-100%, 93%, 86% vs. 57%, 36%, 30%,  $P < 0.001$ ; median OS 5.8 vs. 1.3 years) (kidney-86%, 80%, 72% vs. 55%, 37%, 27%,  $P < 0.001$ ; median OS 8.4 vs. 1.3 years) (lung-91%, 69%, 52%, vs. 52%, 34%, 25%,  $P = 0.002$ ; median OS 3.5 vs. 1.1 years) (pancreas-79%, 56%, 45% vs. 33%, 20%, 12%,  $P = 0.011$ ; median OS 2.5 vs. 0.6 years).

**Conclusion:** Aggressive surgical approach for adrenal metastasis results in improved RFS and OS in patients with metastatic disease arising from soft tissues, kidney, lung, and pancreas. Other tumors may benefit, but larger study cohorts are needed for a meaningful comparison. Synchronous disease, tumor type and additional distant disease are risks for death and should be considered when selecting patients for ADX.

**Abstract ID: 0873** Specific Field: **Endocrine Surgery****Mode of pres.: Free Paper**  
**ISW 2011 Session 66.02****Clinical applications of PET probe-guided surgery in recurrent papillary thyroid carcinoma**

D. H. Koo, S. W. Oh, K. E. Lee, J. C. Paeng, J. K. Chung, S. K. Oh, Y. K. Youn

Seoul National University College of Medicine, Seoul, Korea, Republic of

**Introduction:** Fluorine 18-fluoro-2-deoxyglucose (FDG) positron emission tomography ( $^{18}\text{F}$ -FDG PET) has been reported to be useful for detecting the persistent or recurrent neck mass of differentiated thyroid carcinoma patients. This study aimed to evaluate the feasibility of PET probe guided surgery protocol and assessment of probe utility and to identify the intraoperative radiologic safety in  $^{18}\text{F}$ -FDG injection and probe guided surgery in patients with recurrent papillary thyroid carcinoma (PTC).

**Material and Methods:** From March to December 2009, 15 recurrent PTC patients in whom FDG accumulation was identified at the cervical area and 20 hypermetabolic foci including three double and one triple target lesions were enrolled. They received 5 mCi FDG one hour before operation. Then PET-probe guided surgery was performed using a high-energy gamma probe (IntraMedical Imaging LLC, Los Angeles, CA). Standard uptake values (SUV) of target lesion, in-situ, ex-vivo and operation bed tumor-to-background ratios (TBR) and probe utility were analyzed. Two types of thermoluminescence dosimeters (TLD) including a chest badge and a ring type were worn by the main or an equivalent operator. The radiation exposure was compared with the Occupational Exposure Limits by the International Commission on Radiological Protection (ICRP).

**Results:** The mean SUV was  $6.9 \pm 8.5$  (range 2.3–35.6). The mean in-situ and ex-vivo TBR were  $1.67 \pm 0.55$  (range 1.02–3.02) and  $3.52 \pm 5.46$  (range 1.16–24.50), respectively. The mean operation bed TBR was  $1.32 \pm 0.15$  (range, 0.94–1.54). Probe utility can be divided into three categories. In 11 foci (55%), tumor was adequately resected from localizing target, as its TBR has a unique pattern and is concordant with final pathologic report. There were 5 foci (25%) of localization available, which shows unique pattern of TBR but discordant with final pathology or adequate TBR not associated with distinguishing pattern. The other 4 cases (20%) are inadequate from data unavailable or cannot be assessed. Radiation exposure was less than 0.4 mSv for the chest and 1.13 mSv for the fingers. The exposure is assumed to be much lower than the ICRP Exposure Limit.

**Conclusion:**  $^{18}\text{F}$ -FDG PET probe-guided surgery is clinically feasible and could be safely utilized for the operative management in patients with recurrent PTC.

**Abstract ID: 0874** Specific Field: **Endocrine Surgery****Mode of pres.: Free Paper**  
**ISW 2011 Session 66.03****Partial small bowel resection with sleeve gastrectomy increases adiponectin levels and improves glucose homeostasis in obese rodents with type 2 diabetes**

G. Kopsombut [1], L. Milone [2], R. Shoulson [3], J. Korner [3], J. C. Lifante [4], M. Sebastian [3], W. B. Inabnet [1]

[1] Mount Sinai Medical Center, New York, USA, [2] Mount Sinai Medical Center, USA, [3] Columbia University, New York, USA, [4] University of Lyon, Lyon, France

**Introduction:** Weight loss surgery results in remission of type 2 diabetes in 78% of patients; however, the mechanism of action is poorly understood. The aim of this study was to examine the effect of small bowel resection with and without vertical sleeve gastrectomy on glucose homeostasis and peptide levels in a rodent model of obesity and type 2 diabetes.

**Material and Methods:** Zucker Fatty diabetic rats were randomized into three surgical groups: Sham, small bowel resection (BR), and small bowel resection with sleeve gastrectomy (BRSG). In the BR and BRSG groups, 40 cm of jejunum (approximately 40% of small bowel) was resected. Weight and fasting glucose were measured at randomization (baseline) and monitored for 45 days postoperatively. Oral glucose tolerance testing (OGTT) was also performed after an overnight fast of 12 hours at baseline and 45 days after surgery to determine the area under of the curve for glucose ( $\text{AUC}_{\text{glucose}}$ ), a measure of glucose tolerance. Blood was also collected at time 0 and 30 min into OGTT testing to assess peptide changes associated with glucose challenge.

**Results:** At baseline, all animals exhibited impaired glucose tolerance and showed no difference in weight or fasting  $\text{AUC}_{\text{glucose}}$ . At post operative day 45, the Sham group experienced a significant increase in  $\text{AUC}_{\text{glucose}}$  compared to baseline ( $P = 0.02$ ) whereas there was no difference in  $\text{AUC}_{\text{glucose}}$  in either surgical group at any time point (BR  $P = 0.58$  and BRSG  $P = 0.56$ ). Single Factor ANOVA showed a significant difference in  $\text{AUC}_{\text{glucose}}$  of  $P = 0.004$  between groups postoperatively [Sham ( $50745 \pm 11170$ ) v BR ( $23865 \pm 432.6$ )  $P = 0.01$  and Sham v BRSG ( $28710 \pm 3188.8$ )  $P = 0.02$ ]. There was no difference in serum insulin, GLP-1 and adiponectin levels before surgery, but 45 days following surgery adiponectin levels were higher in the BRSG group ( $P = 0.004$ ). At sacrifice, the groups showed no difference in weight (ANOVA  $P = .345$ ).

**Conclusion:** Partial small bowel resection results in improved glucose tolerance independent of weight. The combination of small bowel resection and sleeve gastrectomy leads to an increase in adiponectin levels which may contribute to the improvement in glucose homeostasis.

**Abstract ID: 0875** Specific Field: **Endocrine Surgery****Mode of pres.: Free Paper**  
**ISW 2011 Session 66.04****Cosyntropin evaluation aids in determining need for postadrenalectomy steroid replacement**

E. G. Grubbs, P. V. Dickson, C. Wathoo, N. D. Perrier, J. E. Lee

MD Anderson Cancer Center, Houston, USA

**Introduction:** Patients (pts) who undergo unilateral adrenalectomy (adx) may be at risk for postoperative(postop) adrenal insufficiency (AI), including those with cortisol-producing adrenal tumors and those with metastatic cancer. No formal data exist on the use of postop Cosyntropin evaluation (CE) as a guide to postop steroid replacement (SR). We reviewed our experience with CE in the postop management of pts undergoing unilateral adx.

**Material and Methods:** pts who had postop CE within 1 week after unilateral adx were identified. All pts underwent a standard-dose Cosyntropin stimulation test (CST) (250 mcg i.v.). Preop dexamethasone suppression testing (DST) of autologous cortisol production by an adrenal cortical tumor was defined as unsuppressed [cortisol  $>3$  after low dose (1 mg) dexamethasone], borderline (DST $>1$  and  $<3$ ) or suppressed (DST $<1$ ).

**Results:** 53 pts underwent postop CST, including 37 pts with a primary adrenal cortical(AC) tumor(AC adenoma, 24; AC carcinoma,

10) and 19 pts with metastasis(met) to the adrenal. Among the 34 pts with AC tumors, 18 had an unsuppressed cortisol on preoperative DST, 9 were borderline, and 3 suppressed.50%(9/18) of pts with an unsuppressed DST had a subnormal (subnl) postop CST, compared with 44% (4/9) of pts with a borderline DST( $P = 0.9$ ) and no (0/3) pts with a suppressed DST ( $P = 0.3$ ). A subnl CST was only slightly more common in pts with an AC tumor than adrenal met(41% vs. 26%;  $P = 0.3$ ). No pt developed clinical signs of postop AI. Overall, postop SR was provided to 61%(11/18) of pts with a subnl CST; in contrast, SR was successfully withheld from 77% (27/35) with a normal CST( $P = 0.004$ ). Postop CST identified 5/20(25%) pts with a unilateral met to the adrenal who had a subnl CST response and were discharged on SR.

**Conclusion:** Postop CST correlates poorly with preop DST. pts with preop evidence for significant cortisol overproduction should receive postop SR and do not require early postop CST evaluation. However, early postop CST evaluation can identify a subset of pts with mild cortisol overproduction who do not require postop SR, thus avoiding the associated inconvenience, expense, and side effects. In addition, one fourth of pts with a clinically unilateral met to the adrenal have biochemical evidence of postop AI, possibly from occult metastasis to the remaining adrenal, making CST reasonable in this subset of pts.

**Abstract ID: 0876** Specific Field: **Endocrine Surgery**

**Mode of pres.: Free Paper**  
**ISW 2011 Session 66.05**

**Usefulness of the adrenal venous sampling (AVS) for the preoperative diagnosis of the patients with primary aldosteronism (PA)**

K. Nakano, S. Suzuki, C. Ohkouchi, N. Yoshimoto, T. Fukushima, S. Takenoshita

Fukushima Medical University, Organ Regulatory Surgery, Fukushima, Japan

**Introduction:** Primary aldosteronism (PA) is the most frequent form of secondary hypertension. Aldosterone acts directly to the cardiovascular system, and definitely induces the irreversible change. So, it is required to diagnose and treat in early stage. Recently, it is recognized the entity of UAH, micro APA which cannot distinguish with diagnostic imaging.

We examined the usefulness of AVS to distinguish the subtype of PA.

**Material and Methods:** Subjects were 121 cases biochemically diagnosed PA from 2004 to 2010. Ninety one patients of them who were successfully carried out and gained complete results of AVS were evaluated.

Prior to AVS, contrast enhanced computer tomography (CE-CT) was performed.

The adrenal veins were catheterized from both adrenal veins by the percutaneous approach, and the proper position of the catheter tip was verified by gentle injection of a small amount of contrast medium.

Plasma aldosterone concentration (PAC) and cortisol level were obtained from the inferior vena cava(IVC) below the level of the renal vein, the right and left adrenal vein before and 15 min after a bolus injection of 250 µg ACTH.

The criteria to determine the source of aldosterone hyper secretion was based on "clinical practice guideline for diagnosis, and treatment of patients with primary aldosteronism" from the Japan endocrine society.

**Results:** A solitary unilateral adrenal nodule was detected in 35 patients, bilateral adrenal nodules and/or enlargement in 4 patients,

and no adrenal lesion in either adrenal gland in 52 patients. Based on the result from ACTH-AVS, 30 patients were diagnosed as UAH from ipsilateral lesion, and 61 patients diagnosed as BAH.

In 35 patients with unilateral nodule, 22 patients were diagnosed as UAH, 12 patients as BAH, and 1 patient as contralateral UAH. In 52 patients without adrenal lesion, 46 patients were diagnosed with AVS as BAH, and 6 patients as UAH. In 4 patients with bilateral adrenal nodules, 3 patients were diagnosed as BAH, 1 patients as UAH.

**Conclusion:** In 20 patients, there were discordant results between the localization of CT and AVS.

If these cases were performed adrenalectomies without AVS, the levels of serum aldosterone of these cases would not be able to decrease.

AVS is the gold standard method to determine the laterality of aldosterone hyper secretion for subgrouping PA.

**Abstract ID: 0877** Specific Field: **Endocrine Surgery**

**Mode of pres.: Free Paper**  
**ISW 2011 Session 106.01**

**Do we overtreat post-thyroidectomy hypocalcemia?**

S. M. Huang

National Cheng Kung University, Medical College and Hospital, Tainan, Taiwan

**Introduction:** Calcium and Calcitrol supplement has been used as a global standard treatment for patients whose serum calcium is less than 8.0 mg/dl after thyroidectomy; however, we reflected on the fact of that whether we overtreat post-thyroidectomy hypocalcemia by the Intraoperative Parathyroid Hormone (Quick iPTH)? Thus, in this study, the goal was to examine the Quick iPTH assay and to find the suitable treatment for post-thyroidectomy hypocalcemia.

**Material and Methods:** The research studied 201 patients underwent bilateral thyroidectomy for 12 months in 2009 at a national university affiliated hospital. There were 96 patients with Grave's disease and 105 with non-Grave's thyroid disease. Post-thyroidectomy hypocalcemia was defined as serum calcium <8.0 mg/dl after thyroidectomy. Intraoperative Quick PTH assay (QiPTH15) was performed 15 min after the end of thyroidectomy. The treatment of QiPTH15 was implemented to find out whether the treatment had caused any difference on various factors, such as: postoperative iPTH, Serum calcium levels, medical treatment, and response of hypocalcemia.

**Results:** 3 patients with QiPTH15 <10 pg/ml developed 24 h postoperative hypoparathyroidism. 2 of 7 patients with QiPTH15 10–15 pg/ml developed 24h postoperative hypoparathyroidism, 5 of them recover to normal parathyroid function in postoperative 24 h. None of 187 patients with QiPTH15 >15 pg/ml had postoperative hypoparathyroidism; however, those patients with Graves' disease had higher post-thyroidectomy hypocalcemia than those with non-Graves' disease ( $P < 0.05$ , 50%(47/94) vs. 34.4%(32/93)), and the serum calcium declined to the lowest level within postoperative 18 h. Among those 187 patients with QiPTH15 >15 pg/ml, 7 patients had serum calcium <7.0 mg/dl had been successfully treated by calcium supplement only, and all the others recovered spontaneously without any treatment.

**Conclusion:** Our findings show that the QiPTH15 >15 pg/ml can exclude the possibility of post operative hypoparathyroidism. When QiPTH15 >15 pg/ml was for bilateral thyroidectomy, more than one third of patients developed post-thyroidectomy hypocalcemia <8.0 mg/dl, most of them recovered naturally without any treatment, and very few of them recovered only via calcium supplement. Findings from this study, we believe that under the QiPTH15 guide, overtreatment of post-thyroidectomy hypocalcemia can be avoided.

**Abstract ID: 0878** Specific Field: **Endocrine Surgery**

**Mode of pres.: Free Paper**  
**ISW 2011 Session 106.02**

**A surgical completeness of robotic thyroidectomy: a prospective comparison of the open conventional thyroidectomy versus the robotic thyroidectomy**

J. H. Park, S. K. Park, C. R. Lee, J. S. Jeong, S. W. Kang, J. J. Jeong, W.Y. Chung, C. S. Park

Yonsei University College of Medicine, Seoul, Korea, Republic of

**Introduction:** With the application of da Vinci robotic system to thyroidectomy fields, surgeons can perform a precise and accurate operation with improved cosmesis. The aim of this study is to compare the surgical completeness of two groups who underwent conventional open thyroidectomy versus robotic thyroidectomy in papillary thyroid carcinoma patients.

**Material and Methods:** From March to November 2009, a total of 115 patients with papillary thyroid carcinoma who underwent total thyroidectomy and postoperative radioactive iodine (RAI) ablation therapy (30 mCi) at Yonsei University Health System were enrolled. Of these, 58 patients were conventional open thyroidectomy group (OG) and 57 patients were robotic thyroidectomy group (RG). These two groups were prospectively compared with respect to clinicopathological characteristics, surgical outcomes and surgical completeness.

**Results:** Mean age was significantly younger in RG. Mean tumor sizes were larger in RG, but the incidence of capsular invasion, multifocality and bilaterality showed no significant differences between two groups. Tumor and nodal status showed no significant differences, but advanced stage is more frequent in OG. In terms of surgical outcomes, there were no significant differences in numbers of retrieved central nodes, lengths of postoperative hospital stay, and incidences of postoperative complications. In terms of surgical completeness, stimulated serum thyroglobulin (Tg) level and relative <sup>131</sup>I iodine uptake of operation bed (thyroid uptake/whole body uptake and thyroid uptake/brain uptake) was significantly higher in RG. However, serum Tg level which was measured six months after RAI therapy under TSH suppression showed no significant differences between two groups.

**Conclusion:** Robotic thyroidectomy showed a comparable surgical completeness with conventional open procedure in papillary thyroid carcinoma patients who were managed with RAI ablation therapy after total thyroidectomy.

**Abstract ID: 0879** Specific Field: **Endocrine Surgery**

**Mode of pres.: Free Paper**  
**ISW 2011 Session 106.03**

**Impact of prophylactic central lymph node dissection on tumor recurrence in papillary thyroid carcinoma (PTC)**

X. Zarate, M. F. Herrera, B. Perez

Instituto Nacionalde Ciencias Medicas y Nutrición “Salvador Zubirán”, Mexico, Mexico

**Introduction:** PTC is the most common endocrine cancer. Surgical treatment includes total/near total thyroidectomy and compartment resection in the presence of suspicious or metastatic lymph nodes. Prophylactic central lymph node dissection (PCLND) has been suggested as an appropriate alternative. However, its impact on

recurrence and survival is still unknown. The aim is to comparatively analyze the recurrence rate of PTC in two cohorts of patients who underwent total tumor resection alone (Group 1) or with PCLND (Group 2).

**Material and Methods:** From the total of patients who underwent initial treatment for PTC at our Institution between 1992 and 2007, patients with the following inclusion criteria were selected: 1) Complete primary tumor excision by total/near total thyroidectomy, 2) Absence of clinically suspicious lymph nodes or by ultrasound, 3) Adjuvant treatment with <sup>131</sup>I, 4) 3-year follow up.

**Results:** There were 169 patients, (95 Group 1 and 74 Group 2). Both groups were similar in terms of age, sex distribution, size of the tumor, dose of <sup>131</sup>I received after surgery, and surgical morbidity. Mean number of lymph nodes in group 2 was  $5.5 \pm 4.05$  with 55% presenting metastases. In a mean follow-up of  $116.6 \pm 40.1$  and  $71.3 \pm 38.1$  months, 10 and 11 patients respectively for groups 1 and 2 developed recurrence of the disease.

**Conclusion:** Our results do not support a positive impact of PCLND on tumor recurrence in patients with PTC.

**Abstract ID: 0880** Specific Field: **Endocrine Surgery**

**Mode of pres.: Free Paper**  
**ISW 2011 Session 146.01**

**Prognostic relevance of survivin in pancreatic endocrine tumors**

S. Ekeblad [1], M. H. Lejonklou [1], P. Ståhlberg [2], B. Skogseid [1]

[1] Department of Medical Sciences, Uppsala, Sweden,

[2] Department of Surgical Sciences, Uppsala, Sweden

**Introduction:** Better prognostic markers are needed for pancreatic endocrine tumors, especially for patients with well-differentiated carcinoma where it is difficult to predict patient outcome. Survivin, an apoptosis inhibitor, is suggested to have a negative prognostic impact in several tumor types. Contradictory data exist, especially regarding the significance of a nuclear vs. cytoplasmic location of survivin. The prognostic relevance of nuclear and cytoplasmic survivin expression in pancreatic endocrine tumors, controlled for tumor Ki-67, WHO classification and TNM stage, was investigated.

**Material and Methods:** One-hundred-and-eleven patients, treated at a tertiary referral centre, were retrospectively evaluated. Clinical data were gathered from medical records. Immunohistochemistry for survivin and Ki-67 was performed on paraffin-embedded tissue, and nuclear and cytoplasmic survivin expression was evaluated in a semi-quantitative manner; <5% (low), 5–50% (medium) or >50% (high) of cells. Test-retest reliability was calculated. Uni- and multivariate Cox analysis was performed.

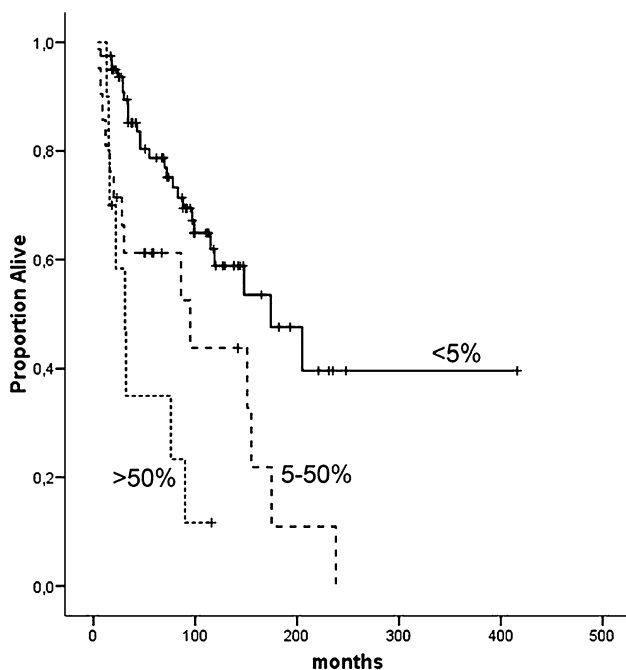
**Results:** The test-retest reliability between the observers was 0.89 and 0.84 for nuclear and cytoplasmic staining, respectively. Patients with tumors with <5% survivin positive nuclei had a mean survival of 225 months (95% CI, 168–281). The corresponding figure for patients with 5–50% positive tumor cell nuclei was 101 months (95% CI, 61–140; HR 2.4;  $P < 0.01$ ) and with >50% survivin positive nuclei 47 months (95% CI, 24–71; HR 4.9;  $P < 0.001$ ). Nuclear survivin was an independent marker of poor prognosis (HR 5.7;  $P < 0.01$ ). High cytoplasmic survivin was not a significant prognostic factor in multivariate analysis (HR, 0.94;  $P = 0.90$ ), and neither was a Ki-67 >2% (HR, 1.7;  $P = 0.38$ ).

**Conclusion:** Nuclear survivin is a highly significant marker of poor prognosis in patients with pancreatic endocrine tumors. It could prove useful to incorporate survivin evaluation in addition to the currently used investigations of patients with pancreatic endocrine tumors.



Survivin immunoreactivity in pancreatic endocrine tumors (Total;  $n = 111$ , with WHO class;  $n = 95$ )

	Total no. of patients	Patients with WDET	Patients with WDEC	Patients with PDEC
<b>Nuclear survivin</b>				
<5%	80 (72%)	23 (92%)	44 (70%)	2 (29%)
5–50%	21 (19%)	2 (8%)	12 (19%)	3 (43%)
>50%	10 (9%)	–	7 (11%)	2 (29%)
<b>Cytoplasmic survivin</b>				
<5%	39 (35%)	4 (16%)	28 (44%)	3 (43%)
5–50%	10 (9%)	–	6 (10%)	1 (14%)
>50%	62 (56%)	21 (84%)	29 (46%)	3 (33%)



**Figure:** Nuclear survivin is a significant negative predictor of survival

**Abstract ID: 0881** Specific Field: **Endocrine Surgery**

**Mode of pres.: Free Paper**  
ISW 2011 Session 66.01

**Not the number but the location of positive lymph nodes predicts recurrence and disease free survival in patients with PTC**

S. G. A. de Meer [1], M. Dauwan [1], B. de Keizer [1], G. D. Valk [1], I. H. M. Borel Rinke [2], M. R. Vriens [1]

[1] University Medical Center Utrecht, Utrecht, Netherlands,  
[2] University Medical Center Utrecht, Netherlands

**Introduction:** Lymph node spread occurs frequently in patients with papillary thyroid cancer and recurrence rate is higher for these patients. Several studies have focused on identifying prognostic

factors in patients with positive lymph nodes to predict recurrence rate and disease free survival. Lateral lymph nodes, nodes larger than 3 cm, extranodal growth and the number of positive lymph nodes have been indicated as prognostic factors by some authors. Most studies, however, are performed in Japan where they have a different treatment protocol compared to the European and American approach. The aim of our study was to identify prognostic factors in patients with positive lymph nodes treated according to European/American guidelines.

**Material and Methods:** All 402 patients that were treated at the Department of Nuclear Medicine from 1998 to 2010 for DTC were reviewed. Patients were treated with (near) total thyroidectomy, lymph node dissection in case of clinical evident metastasis and postoperative I-131 ablation. Follow-up included laboratory analysis (Tg-Tg-Ab), imaging studies (ultrasound, DxBWBS, postablation scintigraphy) and clinical evaluation. Follow-up period varied from 10 to 240 months (mean of 62 months). Patients were compared for having N1a or N1b status according to the TNM criteria. Outcome measures were recurrence rate, disease free survival and mean time till recurrence.

**Results:** Overall, ninety-seven patients (24%) had clinical evident and histological proven positive lymph nodes. Recurrence rate was significantly higher in patients with positive lymph nodes in the lateral compartment (60% versus 30%  $P = 0.007$ ). Disease free survival and mean time until recurrence were also significantly shorter in N1b patients (52 months versus 30 months,  $P = 0.035$ , and 44 months versus 7 months,  $P = 0.004$ ). Also age significantly contributed to time of disease free survival ( $P = 0.010$ ). The number of lymph nodes and extranodal growth, however, were not significantly associated with our outcome measures.

**Conclusion:** Only the location of positive lymph nodes was significantly related to the risk of recurrence and time until recurrence. Lateral lymph nodes and age >45 years old were significantly related to DFS. The TNM criteria can adequately be used in subdividing patients based on risk of recurrence and disease free survival.

**Abstract ID: 0882** Specific Field: **Endocrine Surgery**

**Mode of pres.: Free Paper**  
ISW 2011 Session 146.03

**Thoracoscopic approach for removal of mediastinal parathyroid lesions: selection of surgical approach and pitfalls of preoperative and intraoperative localization**

M. Iihara, T. Okamoto, A. Kawamata

Tokyo Women's Medical University, Tokyo, Japan

**Introduction:** In the era of minimally invasive surgery, thoracoscopic surgery has replaced conventional sternotomy or thoracotomy for resection of mediastinal parathyroid lesions. We review our experience with this type of surgery with reference to selection of the appropriate approach and the pitfalls of localization before and during surgery.

**Material and Methods:** During a 13-year period, we treated 948 patients with parathyroid lesions, among whom a mediastinal lesion was localized preoperatively by sestamibi scan in 15. Primary hyperparathyroidism was present in 12 (single adenoma in 11, associated with MEN 1 in one), secondary hyperparathyroidism in 2, and a huge parathyroid cyst in one. Two reoperative patients were included. Thoracoscopic procedures were performed by the 3-port method.

**Results:** The thoracoscopic procedure was successful in 8 patients in whom a deep (5 anterior, 3 middle) mediastinal lesion was localized preoperatively. Cervical parathyroidectomy was done concurrently with thoracoscopy in 2 patients (MEN 1 and secondary

hyperparathyroidism). The mean weight of the parathyroid lesions resected by thoracoscopy was 1740 mg. Intraoperative visual confirmation of parathyroid adenoma was difficult only in a 19-yr-old patient whose tumor was embedded in thymic tissue, and partial thymectomy was necessary. One of the 8 mediastinal lesions resected thoracoscopically was a sestamibi-positive thymoma. This patient required postoperative re-localization and neck exploration. Secondary hyper-parathyroidism recurred 4 years after thoracoscopic mediastinal parathyroidectomy in one patient, necessitating additional thoracoscopic removal of this supernumerary lesion. However, 7 patients with mediastinal parathyroid lesions localized at the aortic arch or upper region were treated successfully by a cervical approach. None of the patients suffered any surgical complications.

**Conclusion:** Thoracoscopic surgery is safe and feasible for resection of deep mediastinal parathyroid lesions, even in the anterior region of the aortico-pulmonary window. Mediastinal parathyroid lesions localized preoperatively at the aortic arch or upper region can be treated by a cervical approach. Preoperative sestamibi scan can sometimes give a false positive result in cases of concurrent thymoma.

**Abstract ID: 0883** Specific Field: **Endocrine Surgery**

**Mode of pres.: Free Paper**  
**ISW 2011 Session 146.04**

**Adrenal cortical cancer: open or endoscopic approach achieved comparable results in properly selected patients**

A. Béliard [1], L. Gust [1], D. Taieb [1], B. Coulibaly [2], F. Amouyal [1], C. De Micco [1], I. Morange [1], J. F. Henry [1], F. Sebag [1]

[1] Department of Endocrine surgery, Chu Timone, Marseille, France,  
[2] Department of Endocrinology. Chu Timone, Marseille, France

**Introduction:** Adrenal cortical carcinoma is an endocrine neoplasm with poor prognosis. Surgical resection remains the only curative treatment. Because of disease rarity, limited surgical data are available. Optimal surgical strategy remains debatable regarding approach (endoscopic or open) and extension of surgery (adrenalectomy with or without additional resection). We advocate that a tailored procedure, whatever the approach would be, could give equivalent results in properly selected patients, in expert centres.

**Material and Methods:** We reviewed data of patients who were referred to our department for initial surgical management for ACC from January 2002 to December 2009. All patients underwent pre-operative work up, surgery and follow up in our centre. **Results:** We identified 24 patients. Mean follow was 26.5 months (4.4–62.9). Mean age at diagnosis was 46.5 years (20–78), 62.5% had hormonal excess. Mean size at pre-operative CT-scan was 87 mm (38–200). Seventeen patients/18 (95%) presented hyper metabolic tumours at FDG-PET scan. Twenty/24 patients (83%) had a curative resection. Four resections were considered palliative, because of distant metastases at time of diagnosis. Thirteen resections were performed by laparoscopy, all of these were adrenalectomy with complete clearance of surrounding fatty tissue. Nine patients had an extensive resection (at least 2 organs). All were done by open approach. There was no operative mortality. The results of ENSAT staging were stage I in 2 patients, stage II in 12 patients, stage III in 6, and stage IV in 4 patients. Estimated mean time to first recurrence was 40.2 months ( $\pm 5.8$ ). Recurrence occurred in 8/20 of patients (40%) who underwent curative resection. No difference was found between laparoscopic and open approach in terms of disease-free survival, overall survival and site of recurrence. Overall estimated survival rate was 53.5% at 3 years (Kaplan-Meier). A worth prognosis was found for patients with a high Weiss's score ( $P = 0.003$ ), high mitotic index ( $P = 0.005$ ) and advanced ENSAT stage ( $P = 0.011$ ).

**Conclusion:** The prognosis of ACC remains poor. Laparoscopic and open approaches achieved comparable results in our experience with equivalent outcomes compared to previously reported studies.

**Abstract ID: 0884** Specific Field: **Endocrine Surgery**

**Mode of pres.: Free Paper**  
**ISW 2011 Session 146.05**

**A novel definition of extrathyroidal invasion in papillary thyroid carcinoma for predicting prognosis**

M. Hotomi, I. Sugitani, K. Toda, K. Kawabata, Y. Fujimoto  
The Cancer Institute Hospital of JFCR, Tokyo, Japan

**Introduction:** Extrathyroidal invasion is one of the most significant risk factors for patients with papillary thyroid carcinoma (PTC) while minimal superficial invasion does not affect the prognosis of this disease. The criteria for extrathyroidal invasion of PTC by the Japanese Society of Thyroid Surgery in 2005 have classified minimal invasion as Ex1 and massive invasion as Ex2. However, the definition is sometimes inconsistent between institutions or surgeons. We have reported the extensive invasion of the mucosa of the trachea or esophagus and the recurrent laryngeal nerve palsy as prognostic factors. In this study, we further defined the extension as Ex3 and evaluated the novel classification as prognostic factors.

**Material and Methods:** Patients eligible for this prospective study were those who had primary PTC and underwent curative surgery from 1993 to 2009. The patients who had preoperative palsy of the recurrent laryngeal nerve or patients with invasion of the mucosa of the trachea or esophagus were defined as Ex3 in addition to the current classification. All patients were continuously followed-up for their survival and recurrences. Survival curves were determined by Kaplan–Meier method and were compared for statistical significance by the log-rank test.

**Results:** The 930 patients with PTC were enrolled in this study. They were 213 males and 717 females ranging in ages between 15 and 89 years old. The observation periods were ranged between 1 and 17 years. There were 418 patients with Ex0, 272 with Ex1, 139 with Ex2, and 101 with Ex3. The 10-year disease-specific survivals (DSS) were 98.3%, 95.5%, 78.6%, and 51.7%, respectively ( $P$

**Conclusion:** Although the DFS of PTC were significantly different between Ex1 and Ex2, the DSS of PTC was significantly shorter for patients with Ex3 compared with patients with Ex2. The preoperative assessment of Ex3 is much reliable than that of Ex2 and Ex1 is thought to be an important prognostic factor predicting survival. The novel definition of extrathyroidal invasion for patients with PTC would make it possible to arrange risk-adapted approach for initial treatment and postoperative follow-up.

**Abstract ID: 0885** Specific Field: **Endocrine Surgery**

**Mode of pres.: Free Paper**  
**ISW 2011 Session 146.06**

**Prevalence of germ-line mutations in patients with pheochromocytoma or abdominal paraganglioma and sporadic presentation: a population-based study in Western Sweden**

A. Muth [1], F. Abel [2], H. Ahlman [1], S. Jansson [1], O. Nilsson [3], B. Wangberg [1]

[1] Department of Surgery, Sahlgrenska University hospital, Gothenburg, Sweden, [2] Genomics Core Facility, Sahlgrenska Academy, Gothenburg, Sweden, [3] Department of Pathology, Sahlgrenska University Hospital, Gothenburg, Sweden

**Introduction:** Germ-line mutations in the susceptibility genes RET, SDHB, SDHD and VHL have been reported in 7.5–24 per cent of patients with pheochromocytoma (Pheo) or paraganglioma (PGL) and sporadic presentation. SDHB-mutation has been associated with malignant behaviour in 34 to 37 per cent of cases. We aimed to (1) establish population-based data on the frequency of germ-line mutations in patients with apparently sporadic Pheo or abdominal PGL in Western Sweden, and (2) correlate mutation status with clinical features.

**Material and Methods:** From the National Cancer Register all patients with Pheo or PGL in the western health-care region in Sweden (pop. 1.72 million) registered between 1958 and 2009 were identified ( $n = 256$ ). Patients were characterized using register data, hospital records and clinical interviews. All living patients with Pheo or abdominal PGL and sporadic presentation ( $n = 81$ ) were invited to genetic screening, 71 patients accepted. Germ-line mutations were investigated using direct sequencing for point mutations in RET, SDHB, SDHD and VHL, and multiplex ligation dependent probe amplification for gross deletions in SDHB, SDHC, SDHD and VHL. Plasma or urinary metanephrines and/or urinary catecholamines were used for biochemical follow-up.

**Results:** The prevalence of germ-line mutations was 5.6 per cent. Mutations were only seen in RET ( $n = 1$ ) and SDHB ( $n = 3$ ). Notably, in the patients with SDHB mutations no malignant phenotype was observed during a mean follow-up of 23 years.

**Conclusion:** The frequency of germ-line mutations in patients with apparently sporadic Pheo and abdominal PGL in Western Sweden was lower than in previous studies. Variations in reported frequencies of germ-line mutations in patients with clinically sporadic Pheo/PGL may reflect geographical differences or patient selection.

**Abstract ID: 0886** Specific Field: **Endocrine Surgery**

**Mode of pres.: Free Paper**  
**ISW 2011 Session 146.07**

**Change in degree of central sarcopenia is inversely correlated with survival in patients with adrenocortical carcinoma**

B. S. Miller, K. M. Ignatoski, C. Lindland, S. Daignault, P. G. Gauger, G. D. Hammer, S. C. Wang, G. M. Doherty

University of Michigan, Ann Arbor, USA

**Introduction:** Five-year survival from adrenocortical carcinoma (ACC) is poor. Accurate prediction of survival is difficult and current staging models are unreliable. Central sarcopenia (CS) is a marker of frailty and predicts mortality. This study seeks to confirm that psoas muscle density (PMD) can be used to help predict survival in ACC patients.

**Material and Methods:** Using a novel technology developed at this institution, which breaks down a patient's CT scan into hundreds of thousands of granular data elements that are multi-dimensional in character, a measurement of photographic density can be transformed into a numerical density. PMD in Hounsfield units (HU) was measured on CT scans of patients with ACC using a defined protocol and values were recorded at specific areas on each CT scan. Clinical outcome and quantitative data from serial CT scans of patients with ACC were analyzed. A linear regression model was used to describe the relationship between PMD, time to recurrence, and length of survival according to tumor stage.

**Results:** 152 ACC patients (94 female) were treated in our clinic from 2005 to 2010. 119 patients had 234 CT scans available for analysis. Mean age at diagnosis was 45.5 years (SD-13.05), median follow-up 1.79 years (0.06–11.1), and median survival-4.3 years (2.8–10.0). ACC Stage at diagnosis: Stage 1–3%, Stage 2–43%, Stage 3–31%, Stage 4–23%. Significant predictors of survival include change in PMD over time ( $P$ -value = 0.0018) and stage at diagnosis ( $P$ -value < 0.0001). PMD decreases a mean of 0.42 HU per year (SD-0.21,  $P$ -value = 0.0499) when evaluating serial CT scans in individual patients. An incremental 5 HU decrease in PMD suggests a 28% increase in risk of death (hazard ratio (HR) = 0.72 (95%CI)=[0.58, 0.88]). Stage 1/2 patients and stage 3 patients have a 91% (HR: 0.09 CI: [0.03, 0.23]) and 67% (HR:0.33 CI:[0.14, 0.78]) lower risk of death compared to stage 4 patients, respectively.

**Conclusion:** Change in PMD is inversely correlated with survival in ACC patients and enhances current staging data. Objective measures of the burden of ACC, such as sarcopenia, may allow for more precise assessment of overall patient frailty, allow for better prediction of ability to tolerate treatment, and more accurately predict length of survival than using stage alone.

**Abstract ID: 0887** Specific Field: **Endocrine Surgery**

**Mode of pres.: Free Paper**  
**ISW 2011 Session 146.08**

**Preoperative localization study for initial parathyroidectomy in MEN1 syndrome: is there any benefit?**

N. Nilubol, K. Ramya, C. Cochrane, W. Simonds, G. Phan, M. Hughes, S. Marx, E. Kebebew

National Cancer Institute, Bethesda, USA

**Introduction:** It is unknown if localizing studies in patients who would require bilateral neck exploration (BNE) for multigland disease is helpful for identifying ectopic and supernumerary enlarged glands. The objective of this study is to evaluate the utility of preoperative localization study in patients with MEN1 undergoing initial BNE and subtotal parathyroidectomy for primary hyperparathyroidism.

**Material and Methods:** We performed a retrospective study of patients diagnosed with MEN1 undergoing initial para-thyroidectomy from December 1993 to December 2010. Results of preoperative localization studies were compared with intraoperative findings and postoperative calcium and PTH levels. The localizing study result was defined as "true positive" if it correctly identified at least one enlarged parathyroid gland.

**Results:** Data from 60 patients with MEN-1 syndrome undergoing initial BNE and subtotal parathyroidectomy was analyzed. There were 32 female and 28 male from 54 families with mean age at the time of surgery of 32.3 years. 57 patients had one or more positive localizing study results. Neck ultrasonography (USG), sestamibi scan (MIBI), parathyroid protocol CT scan and neck MRI were performed in 93%, 86%, 33%, and 17%, respectively. 48 patients (84%) had both neck ultrasound and MIBI. Mean number of correctly identified glands preoperatively and intraoperatively were 1.5 and 3.4, respectively. USG, MIBI, CT scan and MRI had true positive result in 87%, 82%, 58%, and 50% respectively. 68% of largest glands were identified correctly by preoperative localizing studies. 52 patients (87%) had transcervical thymectomy. 19 patients had 20 ectopic parathyroid glands removed successfully, mostly via transcervical thymectomy (75%). Ectopic glands outside the thymus were only identified in 3 patients (5.3%): 1 intrathyroidal, 1 undescended and 1 mediastinal. There was no supernumerary gland identified.

**Conclusions:** In patients with MEN1, preoperative localizing studies did not identify all enlarged parathyroid glands. Routine preoperative

localizing studies to identify ectopic and supernumerary enlarged parathyroid glands are not warranted in patients with MEN1 undergoing bilateral neck exploration and subtotal parathyroidectomy.

**Abstract ID: 0888** Specific Field: **Endocrine Surgery**

**Mode of pres.: Free Paper**  
**ISW 2011 Session 166.01**

**Treatment and survival of anaplastic thyroid cancer: an analysis of 30 year's experience of a single institute**

A. Sakamoto, T. Okamoto, H. Tokumitsu, T. Yoshida, A. Kawamata, R. Suzuki, K. Horiuchi, M. Iihara

Tokyo Women's Medical University, Tokyo, Japan

**Introduction:** Because of the low prevalence and highly aggressive clinical behavior of anaplastic thyroid carcinoma (ATC), it has been quite difficult for us to establish the best treatment strategy. The purpose of the present study is to investigate how treatment modalities are correlated with prolonged survival of patients with ATC.

**Material and Methods:** A retrospective study on 47 patients with ATC who underwent therapy at our institute between 1981 and 2008 was conducted. The study population included 19 males and 28 females with median age of 71 years (range 50–90 years). Clinical characteristics and treatment modalities used were correlated with survival data.

**Results:** All patients died from ATC, except one who has survived more than 7 years. 1-year overall survival (OS) was estimated to be 19.7% (95%CI: 18–40%) with mean survival time of 290 days (range 6–2583 days). Among clinical characteristics investigated, presence of distant metastasis was significantly associated with poorer OS while other factors including age, tumor size, inflammatory findings, and aggressive tumor growth were not significant. Use of operation (OT:  $n = 21$ ), chemotherapy (CT:  $n = 21$ ) and radiotherapy (RT:  $n = 18$ ) were significantly associated with better OS. Mean survival times based on the combination of the modalities were 664 days for 3 modalities (OT + CT + RT:  $n = 7$ ), 200 days for 2 modalities ( $n = 12$ ), 145 days for 1 modality ( $n = 14$ ), and 70 days for only best supportive care ( $n = 14$ ) ( $P < 0.05$ ). For patients treated with 1 or 2 modalities, no significant difference was observed in OS among each single modality (OT/CT/RT) or the combinations (OT + CT/OT + RT/CT + RT). As for the CT regimens, platinum plus adriamycin (and/or VP-16) based regimens or paclitaxel or docetaxel monotherapy were administered before and/or after operation, yet no single regimen was associated with prolonged OS. Among 3 patients who survived for more than 3 years, all had both OT and CT. One of them completed 5th line regimen while others received one or 3 regimens.

**Conclusion:** Treatment with 3 modalities (OT + CT + RT) was found to be significantly associated with prolonged survival of ATC patients. Multimodal therapy as well as multi-line CT is warranted whenever possible.

**Abstract ID: 0889** Specific Field: **Endocrine Surgery**

**Mode of pres.: Free Paper**  
**ISW 2011 Session 166.02**

**Prospective electromyographic evaluation of functional post-thyroidectomy voice and swallowing symptoms**

C. P. Lombardi, M. Raffaelli, C. De Crea, D. Maccora, L. D'Alatri, M. R. Marchese, M. Lo Monaco, R. Bellantone

Università Cattolica del Sacro Cuore-Policlinico "A. Gemelli", Rome, Italy

**Introduction:** Voice and swallowing symptoms following thyroidectomy in the absence of any demonstration of laryngeal nerves injury are usually considered functional outcome of otherwise uncomplicated operations, mainly related to scar formation and emotional reaction. However, they could be related to clinically unapparent laryngeal nerves or cricothyroid muscle injuries detectable only by laryngeal electromyography (LEMG). We correlated such symptoms with LEMG patterns

**Material and Methods:** Thirty-three consenting patients undergoing total thyroidectomy (TT) were enrolled. Exclusion criteria were: age  $< 21$  and  $> 65$  years; laryngeal or pulmonary diseases; previous neck surgery; malignancy other than papillary thyroid carcinoma. Fibrolaryngoscopy (FL), acoustic voice analysis (AVA) and maximum phonation time (MPT) evaluation were performed preoperatively and 3 months after TT. The Multi-Dimensional Voice Program and Voice Range Profile program were used for AVA. Subjective evaluation of voice (Voice Impairment Score = VIS) and swallowing (Swallowing Impairment Score = SIS) were obtained preoperatively, 1 and 3 months after TT. One month after TT, LEMG was performed examining the thyroarytenoid (TA) and cricothyroid (CT) muscles to evaluate the inferior laryngeal nerve (ILN) and the external branch of the superior laryngeal nerve (EBSLN), respectively.

**Results:** One patient experienced transient vocal cord palsy and was excluded from the study. The remaining 32 patients, in whom no ILN injury was found at postoperative FL, completed the postoperative evaluation. No significant difference was found between pre- and postoperative AVA and MPT parameters ( $P = NS$ ). Mean VIS was significantly worse than preoperatively 1 and 3 months after TT (1.8 Vs 7.1 Vs 4.4) ( $P < 0.05$ ). No significant difference was found between pre- and postoperative SIS (2.2 Vs 2.8 Vs 1.7) ( $P = NS$ ). LEMG evaluation of TA muscle demonstrated a decreased voluntary activity and spontaneous fibrillation potentials in 1 patient. No other sign of ILN injury was found by means of LEMG of TA muscle. LEMG of the CT muscle did not reveal any sign of EBSLN injury.

**Conclusion:** Patients frequently complain of subjective vocal and swallowing alterations early after thyroidectomy. LEMG demonstrated the absence of any subclinical laryngeal nerves injury in all but one patients and excluded inadvertent cricothyroid muscle lesion, unequivocally confirming their functional nature.

**Abstract ID: 0890** Specific Field: **Endocrine Surgery**

**Mode of pres.: Free Paper**  
**ISW 2011 Session 166.03**

**Preoperative FDG-PET result is highly predictive of malignancy and strongly correlated with Weiss score and molecular markers of aggressiveness in adrenal cortical tumours**

L. Gust, D. Taieb, A. Barlier, A. Beliard, I. Morange, C. De Micco, J. F. Henry, F. Sebag

University Hospital La Timone, Marseilles, France

**Introduction:** Malignancy of adrenal cortical tumours is difficult to assess in absence of distant metastases or loco regional spread. Surgery is the only potential curative treatment. Definite preoperative diagnosis could help to propose optimal management. If surgery required, preop diagnosis could help to choose the most appropriate approach. High Weiss scores and molecular markers (LOH17p13 and IGF-II gene over expression) are strong predictors of malignancy but they are available only after tumour resection. The aim of this study



was to evaluate the correlation between preoperative FDG-PET findings, pathology, Weiss score, molecular markers and final diagnosis.

**Material and Methods:** All patients who underwent surgery for suspicious adrenal cortical tumour (06/2006–10/2010). All underwent a complete preop evaluation (hormonal assessments, CT ± MRI, and FDG PETscanning). FDG-PET was considered suspicious if SUVmax tumour/SUVmax liver Ratio was 1.8 (group: PET+). Pathology examination was done by an expert and Weiss score was quantified. Weiss score 3 was considered suspicious. LOH17p13 and quantification of IGF II mRNA (abnormal 30 copies, group: IGFII+) was evaluated for all tumours. Malignancy was confirmed regarding clinical presentation and follow up, and pathology report. Correlations were analysed between FDG-PET, LOH17p13, IGF II mRNA expression; Weiss score and final diagnosis.

**Results:** There were 51 patients (30F/21M) with mean age 51.2 years ( $\pm 15.3$ ).

- LOH17p13 was present in 13 patients. Fourteen patients were IGFII+.
- Weiss score 3 ( $n = 22$ ) was strongly correlated with LOH17p13 ( $P = 0.009$ ) and IGFII+ ( $P < 0.0003$ ).
- Twenty one (21) patients were PET+. PET+ was strongly correlated with Weiss score 3 ( $P < 0.0001$ ), with LOH17p13 ( $P = 0.002$ ) and IGFII+ ( $P = 0.0005$ ).
- Malignancy was demonstrated for 22 patients. All these patients were PET+ except two. Out of these 22 patients, six had no molecular markers abnormalities.

**Conclusion:** Preoperative FDG-PET results were highly predictive of malignancy. FDG-PET results were at least as efficient compared to molecular markers in predicting malignancy. FDG-PET should be systematically proposed at initial preop work up for suspicious adrenal tumour. It could help to optimize initial management and/or surgical approach and/or postop management.

**Abstract ID: 0891** Specific Field: **Endocrine Surgery**

**Mode of pres.: Free Paper**  
**ISW 2011 Session 166.04**

**Prognostic factors for recurrence to the lymph node, lung and bone of papillary thyroid carcinoma: analysis for 5768 patients with 10-year follow-up in average**

Y. Ito [1], Y. Takamura [1], K. Kobayashi [1], A. Miya [1], K. Ichihara [2]

[1] Kuma Hospital, Kobe, Japan, [2] Yamaguchi University, School of Medicine, Yamaguchi, Japan

**Introduction:** Papillary thyroid carcinoma (PTC) frequently recurs to the lymph node, which may not be fatal immediately but is a stressor for physicians and patients. Recurrence to the distant organs is often life-threatening and the lung and bone are organs to which PTC are likely to recur. In this study, we investigated factors predicting recurrence to the lymph node, lung and bone of PTC using a large number of patients with long time follow-up.

**Material and Methods:** Fifty-seven hundred and sixty-eight PTC patients (608 males and 5159 females) without distant metastasis at diagnosis who underwent initial surgery between 1987 and 2004 in Kuma Hospital were enrolled in this study. Their postoperative follow-up period ranged from 12 to 280 months and was 129 months (10.8 years) in average.

**Results:** To date, recurrences to the node, lung and bone were detected in 389 (7%), 118 (2%), and 33 patients (0.6%), respectively,

and 57 (1%) died of PTC. We examined prognostic significance of tumor size (T) >4 cm, pathological node metastasis (pN), extrathyroid extension (Ex), age 55 years or older, male gender, node metastasis (N) >3 cm, and extranodal tumor extension (LNex) for each outcome. (a) Lymph node; All affected recurrence to the node on univariate analysis and all but LNex were independent predictors on multivariate analysis. (b) Lung; All except affected recurrence to the lung. T >4 cm, pN, Ex, age, and N >3 cm were independent predictors. (c) Bone; Ex, N >3 cm, T >4 cm, gender and LNex predicted recurrence to the bone and the former two were independent predictors. (d) Cause-specific survival (CSS); T >4 cm, Ex, age, N >3 cm, and LNex were independent prognostic factors.

**Conclusion:** Extensive node dissection is recommended to avoid recurrence for patients having large tumors and/or extrathyroid extension, even though it is prophylactic. PTC with these characteristics is likely to recur also to distant organs requiring careful follow-up. Large lymph node metastasis is a sign of high aggressiveness regardless of the status of primary lesions, because it is an independent predictor for recurrence not only to the node but also to distant organs. Extranodal tumor extension is also a high-risk characteristic, because it predicted poor CSS.

**Abstract ID: 0892** Specific Field: **Endocrine Surgery**

**Mode of pres.: Free Paper**  
**ISW 2011 Session 166.05**

**The importance of recognizing non-endocrine MEN 2B components for early diagnosis and cure of medullary thyroid cancer**

M. Brauckhoff [1], A. Machens [2], K. Lorenz [2], J. E. Varhaug [1], K. Brauckhoff [1], J. Ukkat [2], H. Dralle [2]

[1] University of Bergen, Bergen, Norway, [2] University of Halle, Halle, Germany

**Introduction:** In multiple endocrine neoplasia 2B (MEN 2B), genetic family screening is limited by the fact that more than 90% of the patients harbor a de-novo RET germline mutation. In the present study, the impact of non-endocrine syndrome components on timely MEN 2B diagnosis was evaluated.

**Material and Methods:** Thirty-two MEN 2B patients with de-novo RET germline mutations were examined for syndromic components. In eight patients, MEN 2B diagnosis was based on recognition of a non-endocrine component (intestinal hyperganglioneosis  $n = 6$ , ocular symptoms  $n = 1$ , oral symptom  $n = 1$ ). Twenty-four patients were diagnosed with clinically manifest medullary thyroid cancer (MTC). The two groups were compared with each other regarding clinical and oncological outcome.

**Results:** MEN 2B patients diagnosed based on non-endocrine syndromic components were significantly younger than patients diagnosed with clinically manifest MTC (mean age  $\pm$  SD  $4.9 \pm 4.6$  vs.  $17.1 \pm 8.1$  years,  $P < .01$ ). All MEN 2B patients presented with MTC. In patients diagnosed based on non-endocrine components, five patients (62%) had MTC 10 mm. In contrast, all patients diagnosed with manifest MTC had tumors >10 mm ( $P < .001$ ). Biochemical cure was achieved in 5/8 (62%) patients diagnosed before clinical manifestation of MTC whereas all patients with clinically manifest MTC had persistent calcitonin levels after surgery ( $P < .001$ ).

**Conclusion:** To identify MTC in MEN 2B patients with de-novo RET germline mutations as long as it is curable, syndrome diagnosis must be made before clinical manifestation of MTC. Timely recognition of non-endocrine syndrome components is critical for long term prognosis. Intestinal hyperganglioneosis but also MEN 2B related ocular and oral phenotype should prompt immediate genetic testing.

**Abstract ID: 0893** Specific Field: **Endocrine Surgery****Mode of pres.: Poster Discussion**  
**ISW 2011 Session PW 09.01****Pheochromocytoma in pregnancy: which management to choose?**

P. de Wailly [1], V. Rhomer [2], A. Brossard [1], C. Mor-Martinez [3], V. Arnault [3], L. de Calan [3], F. Pierre [1], J. L. Kraimps [1]

[1] CHU Poitiers, Poitiers, France, [2] CHU Angers, Angers, France, [3] CHU Tours, Tours, France

**Introduction:** Pheochromocytoma during pregnancy is rare. Antenatal diagnosis is difficult but imperative so as to avoid maternal and fetal morbidity and mortality. Timing of delivery and adrenal surgery necessarily depends on maternal and fetal state.**Material and Methods:** four patients (23 to 28 years old) were diagnosed with pheochromocytoma between 25 and 26 weeks of gestation on the basis of labile hypertension, elevated plasmatic chromogranin A, and urine metanephrines, normetanephrines. Management consisted in adrenalectomy and delivery at term in one case, caesarean and adrenalectomy (one laparoscopy) in same time because of the consequences of hypertension on mother and fetus in two cases, and adrenalectomy 6 months after caesarean in the other case.**Results:** due to relatively high fetal and maternal mortality, resection of the tumour following medical stabilization is the preferred treatment. The timing of surgery, however, is controversial, and depends on maternal and fetal condition, as well as the time of diagnosis during pregnancy. If the diagnosis is carried out in the first or second trimester, laparoscopic adrenalectomy may be proposed with delivery at normal term. In the third trimester, adrenalectomy at the time of caesarean could be recommended in accordance with fetal maturity. More rarely, depending on the degree of tolerance, it is possible to carry out caesarean and perform laparoscopic adrenalectomy some months later.**Conclusion:** management of pheochromocytoma in pregnancy depends of medical treatment efficacy and materno-fetal tolerance and necessitates a multidisciplinary approach involving gynecologists, endocrinologists, anesthesiologists, and endocrine surgeons.**Abstract ID: 0894** Specific Field: **Endocrine Surgery****Mode of pres.: Poster Discussion**  
**ISW 2011 Session PW 09.02****Clinical usefulness of contrast-enhanced ultrasound and elastography for the estimation of extent of ablated area in thyroid thermal ablation therapies**

N. Fukunari, K. Arai, M. Nakano, A. Nakamura

Show University School of Medicine, Yokohama Northern Hospital, Yokohama, Japan

**Introduction:** For the clinical evaluation of thyroid interventional therapies, diagnostic imaging applications must play important roles such as targeting of the lesion to be treated, guidance for energy deposition for the duration of the treatment plan and assessment of results at follow-up. Both gray-scale US imaging and color-Doppler imaging can demonstrate accurate and reliable information for determination of the adequacy of the therapy. On the other hands, hyper-echogenic focus which was observed in heated area with thermal ablation therapies often obscure the accuracy of US diagnosis predicting the extent of ablation area. In this study, Elastography and Contrast-enhanced Ultrasound (CEUS) were applied to diagnostic imaging in thyroid interventional therapies, and the clinical evaluation of their usefulness for the estimation of extent of ablated area was made**Material and Methods:** Forty-seven thyroid nodules which treated by Radio-Frequency Ablation (RFA) were examined with Elastography and US contrast medium in the sessions. Elastography: Real-time tissue Elastography (Hitachi Medico, Japan), CEUS: Sonazoid perfluorobutane microbubbles (GE Healthcare, Amersham, Buckinghamshire, England). The objects of this study were consisted of 35 hyperplastic nodules, 6 papillary carcinomas, 4 lymph nodes metastasis of PTCs and 2 Graves' diseases. All of the patients who underwent thyroid RFA in this series refused the thyroid surgery and accept the conditions.**Results:** Before treatment of RFA, the findings of CEUS and Elastography were different from each other due to histological characters. After RFA, CEUS and Elastography revealed the satisfactorily ablated area as the defected area of contrast medium and blue-colored area of Elastography, respectively.**Conclusion:** CEUS and Elastography can demonstrate the quiet obvious difference of US images between before and after RFA. Both application enable rapid assessment of the extent of tissue destruction and it will lead safe and satisfactory results of interventional therapies for thyroid nodules.**Abstract ID: 0895** Specific Field: **Endocrine Surgery****Mode of pres.: Poster Discussion**  
**ISW 2011 Session PW 09.03****Preoperative assessment of the MEN 1 pancreas**

M. Lewis, W. F. Young, G. B. Thompson

Mayo Clinic, Rochester, MN, USA

**Introduction:** Many serologic and radiographic modalities are used for monitoring multiple endocrine neoplasia type 1 (MEN 1) patients for pancreaticoduodenal neuroendocrine tumors (PNETs). Our goal was to compare serum markers and imaging studies obtained preoperatively with the gross pathology and immunohistochemical findings, and to correlate preoperative testing with postoperative outcome.**Material and Methods:** From 2000 to 2008, 52 MEN 1 patients [32 (62%) female; median age:43 year; range 19–74 year] underwent 56 pancreatic operations [49 (88%) distal pancreatectomies] for suspected PNETs. Preoperative data, including serum markers (human pancreatic polypeptide [HPP], gastrin, & glucagon) and imaging (CT, octreotide scintigraphy, & endoscopic ultrasound [EUS]), were compared to the pathologic findings. Postoperative serum markers and survival were followed.**Results:** For HPP, there was 83% agreement between elevated HPP (>227 pg/ml) and + immunostaining of tumor specimens; 81% of tested patients showed lower levels after surgery. For gastrin, there was 50% agreement between elevated gastrin (>100 pg/ml) and + immunostaining; 66% of tested patients had lower levels after surgery. For glucagon, there was 67% agreement between elevated glucagon (>60 pg/ml) and + immunostaining; 100% of patients tested postoperatively had lower glucagon levels. Preoperative CT was obtained in 77% of cases, with sensitivity = 81%; positive predictive value (PPV) = 97%. Octreotide scintigraphy was performed in 57% of cases, with sensitivity = 84%; PPV = 96%. Both scans were false-positive in the case of a heterotopic spleen. Preoperative EUS was obtained in 63% of cases, all of which correctly identified PNETs (sensitivity and PPV = 100%). There was close correlation ( $r_s = 0.93$ ) between the largest lesions seen on EUS and on gross pathology. Median follow-up was 4.3 year (range 0.1–10.9 year). Overall survival was 89% at 5-year follow-up.**Conclusion:** Our study substantiates EUS as providing the highest pre-operative sensitivity and PPV in assessing the presence of PNETs in MEN 1 patients. CT and octreotide scintigraphy can yield both false-positive and false-negative results. HPP, gastrin, and glucagon

were the most commonly measured tumor markers in our series, but did not always correlate with immunostaining. With an aggressive surgical approach, satisfactory rates of biochemical improvement and long-term survival were observed.

**Abstract ID: 0896** Specific Field: **Endocrine Surgery**

**Mode of pres.: Poster Discussion**  
**ISW 2011 Session PW 09.04**

**Cinacalcet influences parathyroidectomy for secondary hyperparathyroidism**

Y. Tominaga, T. Hiramitsu, K. Izumi, T. Yamamoto, K. Nanboku, K. Uchida

Nagoya Second Red Cross Hospital, Nagoya, Japan

**Introduction:** Cinacalcet HCl (cinacalcet) directly reduces PTH by allosteric modulating the Calcium Sensing Receptor in parathyroid cells and widely available for the treatment of secondary hyperparathyroidism (SHPT). It has been reported that cinacalcet aggressively suppresses PTH secretion and reduces frequency of parathyroidectomy (PTx). In Japan the medicine has been available in hemodialysis patients with SHPT from January 2008. We evaluated the frequency of PTx for SHPT and causes (surgical indications) of PTx before and after induction of cinacalcet.

**Material and Methods:** The annual number of PTx for SHPT except for re-operation in our department for the last 5 years and the causes by which patients were referred for us were evaluated. Moreover, characteristic findings of patients in whom SHPT was refractory to cinacalcet and underwent PTx.

**Results:** (1) The annual number of PTx for SHPT in our department from 2006 to 2010 were 205, 266, 219, 100, 75 operations. The number significantly decreased after induction of cinacalcet. (2) In 2009, the ratio of the patients who underwent PTx without cinacalcet treatment was 52% and in 2010 the ratio was 22%. (3) In 2010, 31/54 (41%) patients could not tolerate GI symptoms induced by cinacalcet and PTx was required and in 8/54 (14%) patients SHPT was refractory to cinacalcet treatment and PTx was performed. (4) PTH level, weight of the largest gland and total glandular weight were higher in cinacalcet resistant group than in patients without cinacalcet.

**Conclusion:** Cinacalcet significantly reduce the number of PTx for SHPT. Some patients require for PTx because of GI symptoms induced by cinacalcet and resistance to cinacalcet. It has been proposed PTx improve mortality and quality of life dramatically. If the patients complain on symptoms induce by cinacalcet or SHPT is refractory to cinacalcet and long-survival is expected, PTx should be performed aggressively.

**Abstract ID: 0897** Specific Field: **Endocrine Surgery**

**Mode of pres.: Poster Discussion**  
**ISW 2011 Session PW 09.05**

**Correlation of BRAF mutation and clinicopathologic characteristics in papillary thyroid cancer**

B. Kang

Ajou University Hospital, Suwon, Korea, Republic of

**Introduction:** The BRAF mutation is frequently demonstrated in papillary thyroid carcinoma (PTC). But at present, most studies have demonstrated an association of BRAF mutation in PTC patients with poor clinicopathologic characteristics, although the results remain

controversial. In this study, we investigated the frequency of BRAF mutations in PTCs and their correlation with clinicopathologic characteristics.

**Material and Methods:** We analyzed the BRAF mutation in a consecutive series of 687 PTC patients who underwent thyroidectomy from June 2009 to August 2010. Data on their clinicopathologic characteristics and BRAF mutation status were retrospectively collected. And we correlated presence of BRAF mutation with clinicopathologic characteristics in PTC, especially those with PTC smaller than 20 mm and micro PTCs.

**Results:** In this study, the BRAF mutation was found in 534 cases (77.7%), 497 of 643 cases (77.3%) in PTCs smaller than 20 mm, and 355 of 472 cases (75.3%) in micro PTCs. The BRAF mutation was associated with male patient ( $P = 0.012$ ), tumor size ( $P = 0.004$ ), presence of nodal metastasis ( $P = 0.002$ ), and extrathyroid extension ( $P < 0.001$ ) in PTCs. Similar results were obtained in PTCs smaller than 20 mm and micro PTCs. By multivariate analysis, male patients, extrathyroid extension, and lymphovascular invasion were associated with BRAF mutation. In PTCs smaller than 20 mm, tumor size ( $P = 0.001$ ) were also related to BRAF mutation. In micro PTC, BRAF mutation was only associated with tumor size ( $P = 0.002$ ) and extrathyroid extension ( $P < 0.005$ ).

**Conclusion:** We suggest that BRAF mutation associated with poor clinicopathologic characteristics in PTCs including small PTCs. And although analysis of recurrence and survival data are necessary, BRAF mutation status could be useful to improve the risk stratification and management of PTC patients, even for micro PTCs.

**Abstract ID: 0898** Specific Field: **Endocrine Surgery**

**Mode of pres.: Poster Discussion**  
**ISW 2011 Session PW 09.06**

**Immunohistochemistry for P27 and BCL-2 is useful to identify normal rim in parathyroid adenoma**

T. Hiramitsu, Y. Tominaga, K. Izumi, T. Yamamoto, T. Tsuzuki, K. Uchida

Nagoya Second Redcross Hospital, Nagoya, Japan

**Introduction:** It is sometimes difficult to differentiate histopathologically parathyroid adenoma from hyperplasia. Single gland enlargement and existence of normal rim are characteristic pathological features in parathyroid adenoma, however it is sometimes difficult to identify normal rim by hematoxylin and eosin stain. Recently immunohistochemistry for P27 has been used to identify parathyroid adenoma. P27 is one of cyclin-dependent kinase inhibitors that regulate the transition of the cell cycle from G1 to S phase. In normal parathyroid cells, expression of P27 is enhanced and expression in nodular area (adenoma cells) is usually decreased. BCL-2 is related to the anti-apoptotic regulation, it is speculated that BCL-2 also could be a useful marker to evaluate the normal rim. The aim of this study is to show that BCL-2 is a new useful marker as well as P27 to diagnose parathyroid adenoma.

**Material and Methods:** Twenty nine patients (male/female 8/21, Mean age  $56.1 \pm 13.8$  year) with typical primary hyperparathyroidism underwent parathyroidectomy and 29 specimens removed at surgery were investigated by P27 and BCL-2 immunohistochemistry. **Results:** 1) In 20 specimens (69.0%), parathyroid adenoma was diagnosed based on findings of immunohistochemistry for only P27. Normal rim was clearly detected by P27 staining. 2) 19 specimens (65.5%) were diagnosed by only BCL-2 staining. 3) By combination of immunohistochemistry of P27 and BCL-2, accuracy to identify parathyroid adenoma was increased to 25/29 (86.2%). 4) In four



specimens, it was impossible to clearly detect normal rim even by combination of P27 and BCL-2 staining.

**Conclusion:** P27 and BCL-2 immunohistostain are very useful markers to identify normal rim in parathyroid adenoma, and the combination of P27 and BCL-2 staining increases accuracy of histopathological diagnosis of parathyroid adenoma.

**Abstract ID: 0899** Specific Field: **Endocrine Surgery**

**Mode of pres.: Poster Discussion**  
**ISW 2011 Session PW 09.07**

**A comparative study for the surgical outcomes of laparoscopic adrenalectomies (transperitoneal approach vs. posterior retroperitoneal approach) for small adrenal tumors**

S.-W. Kang, J. S. Jeong, C. R. Lee, S. K. Park, S. H. Lee, J. J. Jeong, W.Y. Chung

Yonsei University College of Medicine, Seoul, Korea, Republic of

**Introduction:** With the development of endoscopic instruments and minimally invasive techniques, the laparoscopic adrenalectomy has been the gold standards for the surgical treatment of small adrenal tumors. Several approaching routes for laparoscopic adrenalectomy such as transperitoneal (TPA), lateral retroperitoneal or posterior retroperitoneal accesses (PRA) are being used according to the surgeon's preference. PRA has several superior benefits comparing to the others in terms of direct and short access to the target organ, no trespass and irritation of intraperitoneal space, no need of retracting adjacent organs, and safety and ease for learning this method.

**Material and Methods:** From Jan.2009 to July.2010, a total of 43 patients had undergone laparoscopic adrenalectomy, and transperitoneal approach (TPA) and PRA were conducted in 26 and 17 patients, respectively. We have evaluated and compared the clinic-pathologic data and surgical outcomes of the two groups retrospectively.

**Results:** There were no significant differences between the two groups in terms of age, sex, lesion side, the volume of blood loss, and tumor size. Cushing syndrome, primary aldosteronism, pheochromocytoma, and non-functioning adrenal tumor were in 3, 4, 8, and 11 patients in TPA group and 2, 7, 2, and 6 patients in PRA group, respectively. Mean operative time of PRA was shorter than that of TPA (TPA: 116.2 vs. PRA: 87.2 min  $P = .043$ ). Average time to oral intake and postoperative hospital stay of PRA also showed shorter results comparing to the TPA (TPA: 1.19 vs. PRA: 0.88 days,  $P = .028$ . TPA: 5.96 vs. PRA: 3.00 days,  $P = .002$ , respectively). The mean numbers of analgesics use for pain control was fewer in the PRA group (TPA: 3.81 vs. PRA: 1.29 times,  $P = .001$ ). There was no conversion to open surgery and postoperative complications.

**Conclusion:** In our initial experiences, the posterior retroperitoneoscopic adrenalectomy is a safe and fast procedure. Ordinal anatomical dissection in the bloodless planes provides a clear operative field and avoids inadvertent injury to surrounding organs and major vessels. Thus, it decreases the complication rate with a significantly short operative time. In experienced hands, this method can be an ideal approach in adrenal surgery.

**Abstract ID: 0900** Specific Field: **Endocrine Surgery**

**Mode of pres.: Poster Discussion**  
**ISW 2011 Session PW 09.08**

**The usefulness of intraoperative monitoring of intact PTH(IOPTH) for secondary hyperparathyroidism and the evaluation of long-term outcomes**

I. Kumiko [1], Y. Tomonaga [1], T. Hiramitsu [2], T. Yamamoto [2], K. Uchida [2]

[1] Nagoya second red cross Hospital, Nagoya-city, Japan,  
[2] Nagoyadaini Red Cross Hospital, Japan

**Introduction:** The procedure of parathyroidectomy (PTx) for primary hyperparathyroidism (PHPT) has shifted from bilateral neck exploration to focused exploration, because about 90% of PHPT are caused by a single adenoma and the improvement in preoperative localizing images allow us make accurate preoperative diagnosis. Many studies have reported the usefulness of IOPTH for PHPT, however there are few reports for secondary hyperparathyroidism (SHPT). We evaluated long-term outcomes based on results of IOPTH for SHPT.

**Material and Methods:** IOPTH monitoring was performed between February and October 2005 in 44 patients (21 men, 23 women) with SHPT who underwent total PTx and forearm autograft. We measured i-PTH after induction of anesthesia (P0) and 10 min after all glands excision (P10). Reductions of PTH levels were evaluated and expressed in percentage of basal levels. If the value of i-PTH on POD1 were under 60 pg/ml, we considered PTx successful (sufficiently declining group)- and all glands were removed. Otherwise, we considered PTx failed and residual glands remaining (insufficiently declining group). If the cutoff value was defined as 10.8% at 10 min ( $P10 0.108 \times P0$ ), the sensitivity was 100% and specificity 90%. We followed up all of them using i-PTH as indicator, for more than three years, and evaluated relationship between results of IOPTH and long-term outcomes.

**Results:** The mean age at PTx was 53.4 years. All of them were chronic dialysis patients. Forty one patients (93.2%) were included sufficiently declining group, and three (6.8%) were insufficiently declining group. In sufficiently declining group, a patient died of metastatic parathyroid cancer. In insufficiently declining group, 5 glands were resected in two, and 3 glands were removed in a case. All of them might have residual glands, because high i-PTH level continued after initial surgery. However, re-operation has not required in all patients and SHPT have been controlled by medical treatment. In sufficiently declining group, high i-PTH was not detected except for three patients who required removal of autograft.

**Conclusion:** IOPTH during surgery for SHPT is useful to detect complete removal of all parathyroid glands. We concluded that the cutoff value of i-PTH on POD1 is 60 pg/ml and  $P10 0.108 \times P0$  is useful to predict for residual gland and long-term outcomes.

**Abstract ID: 0901** Specific Field: **Endocrine Surgery**

**Mode of pres.: Poster Discussion**  
**ISW 2011 Session PW 09.09**

**Preoperative serum osteocalcin may predict postoperative elevated parathyroid hormone in patients with primary hyperparathyroidism**

N. Perrier [1], G. Alex [1], N. Riahon [2]

[1] MD Anderson Cancer Center, Houston, USA, [2] University of Texas Health Science Center, Houston, USA

**Introduction:** Persistent postoperative elevation of parathyroid hormone (POePTH) is not uncommon following successful parathyroidectomy for primary hyperparathyroidism (PHPT). Preoperative serum calcium, creatinine, and vitamin D levels have been associated with POePTH but the clinical significance of POePTH is unknown and presumed to result from bone remineralization. Predicting which patients may need treatment is difficult. This study investigated whether preoperative serum osteocalcin (OC), a bone formation marker "apparently" involved in mineralization, can predict POePTH



**Material and Methods:** This is a retrospective analysis of a postoperatively maintained database of 146 patients (120 women & 26 men) who underwent parathyroidectomy for PHPT from 11/2007–10/2009. Chart review collected information on patients' demographics (age, gender, race, height, weight, BMI), preoperative bone mineral density (BMD), and bone promoting medication use for this analysis. Serum levels of parathyroid hormone (PTH), calcium, vitaminD, creatinine, phosphate and OC were collected preoperatively, at 6 and 12 months postoperatively. Adenoma weight was recorded. Multiple regression models determined associations between preoperative OC and POePTH at 6 and 12 months postoperatively. The models were forced adjusted for demographics, adenoma weight and factors known to affect bone mineralization, e.g., bone promoting medication use, preoperative serum levels of calcium, vitaminD, creatinine and phosphate

**Results:** Mean age ( $\pm$ standard deviation) of 146 patients was 60 ( $\pm$ 14) years (range 18–92 years). Ninety (62%) had all biochemical data available at 12 months of follow up. POePTH ( $>80$  pg/ml) occurred in 13% and 12% patients at 6 and 12 months, respectively. Preoperative OC was predictive of POePTH ( $P < 0.05$ ) at 6 months [ $\beta$  coefficient ( $\beta$ ) 0.24, confidence interval (CI) 0.03–0.44] and at 12 months ( $\beta$  0.29, CI 0.02–0.57). Consistent with previous studies, preoperative serum calcium and creatinine also showed positive associations ( $P < 0.05$ ) with POePTH

**Conclusion:** Preoperative OC may help predict risk of POePTH in patients with PHPT. We suggest that OC be obtained preoperatively in all patients with PHPT undergoing parathyroidectomy. Further study to evaluate whether early measures to improve bone remineralization are beneficial in patients with preoperative elevation of OC should be considered.

**Abstract ID: 0902** Specific Field: **Endocrine Surgery**

**Mode of pres.: Poster Discussion**  
**ISW 2011 Session PW 09.10**

#### **Vitamin D supplementation does not alter size or perfusion of parathyroid adenomas**

N. Perrier, T. Vu, C. Warnecke

MD Anderson Cancer Center, Houston, USA

**Introduction:** Low vitaminD(VitD) levels are common in patients with primary hyperparathyroidism(PHPT). The effect of VitD supplementation on preoperative localization studies is not known. Four dimensional CT scans(4DCT) provide anatomic and functional information about parathyroid glands. Hyperfunctional glands have increased washout following injection of intravenous contrast. We sought to determine whether VitD supplementation would alter imaging characteristics of parathyroid adenomas

**Material and Methods:** A prospective study was performed on patients with biochemically confirmed PHPT and a concomitant VitD level  $<20$  ng/dl. A defined VitD replacement regimen of Ergocalciferol was implemented. Serum calcium, PTH and 25OH VitD measurements were obtained pretreatment, and at 6 and 12 wks post treatment. All patients had a VitD level increased to  $>30$  ng/dl and were maintained at this level for 8 weeks.4DCT scans were obtained at pre and post treatment. Hounsfield unit(HU) measurements were obtained at baseline, 25, 55 and 85 s delays. Perfusion was defined as change in HU over time. Pre- and post- treatment changes in perfusion and in vitaminD level were determined. Size was recorded. Associations between VitD levels and perfusion measures were tested using the Spearman's correlation coefficient, and the Wilcoxon signed-rank test was used to determine the significance of pre- to post-treatment changes in perfusion

**Results:** Higher vitaminD levels were associated with lower 55 s perfusion measures ( $n = 14$ ,  $P = 0.04$ ). Specifically, pre- treatment

perfusion levels at 55 s had a moderate negative correlation ( $r = -0.56$ ) with pretreatment vitaminD level. No significant associations were detected between perfusion measures and vitaminD levels post-treatment. The change in the pre- to post-treatment 55 s perfusion level was present with a median increase from baseline of 101 HU (range 43–231 HU) ( $n = 14$ ,  $P = 0.0001$ ). Neither the percent change in perfusion at any time point nor gland size showed significant changes from pre- to post-treatment

**Conclusion:** In patients with PHPT and a low VitD level, there is no significant change in perfusion or gland size following VitD supplementation. Low VitD levels at the time of 4DCT imaging are associated with higher perfusion as determined by HU. Whether this information has clinical significance for interpretation of localization studies is yet to be determined.

**Abstract ID: 0903** Specific Field: **Endocrine Surgery**

**Mode of pres.: Poster Discussion**  
**ISW 2011 Session PW 09.11**

#### **Safety and effectiveness of video-assisted thyroidectomy and modified radical neck dissection for papillary thyroid carcinoma**

H. Hara, T. Ikeda, T. Saito, K. Tachi, A. Iguchi, Y. Tanaka, H. Bando, N. Ochiai

University of Tsukuba, Graduate School of Comprehensive Human Science, Tsukuba-shi Ibaraki-ken, Japan

**Introduction:** We performed video-assisted thyroidectomy and modified radical neck dissection for 49 patients with papillary thyroid carcinoma. The purpose of this study was to evaluate the safety and effectiveness of this procedure.

**Material and Methods:** Using a small skin incision made on the line of usual collar incision, we divided the strap muscles at the central white line. After thyroidectomy (total or subtotal) and dissection of the lymph nodes in the central area, we opened the vascular sheath of the common carotid artery and the internal jugular vein for the dissection of lateral cervical lymph nodes. We divided the vessels and vagus nerve and pulled out the underlying fatty tissue between them, which includes the lymph nodes. We prospectively compared 13 video-assisted cases (tumor size 8–33 mm; mean 16.6 mm) with 13 non-video-assisted cases (tumor size 3–36 mm; mean 17.8 mm) on the following variables: 1. Operative time 2. Blood loss 3. Extent of lateral lymph node dissection (measurement of width from trachea to lateral edge at the level of the cricoid) 4. Length of skin incision

**Results:** The average operative time was 173.9 min(range, 113 to 252 min) in the video-assisted group and 173.5 min(range, 132 to 220 min) in the non-video-assisted group. The mean volume of blood loss was 42.1 ml (range, 8 to 120 ml) in video- assisted group and 54.7 ml (range, 8 to 220 ml) in the non-video-assisted group. The average width of lateral lymph node dissection was 7.7 cm (range, 7.0 to 9.0 cm) in the video-assisted group and 6.2 cm (range, 4.5 to 7.5 cm) in the non-video-assisted group. The mean length of skin incision was 3.1 cm (range, 2.5 to 3.8 cm) in the video-assisted group and 8.6 cm (range, 6.5 to 12.5 cm) in the non-video-assisted group. There was no significant difference between the video-assisted group and the non-video-assisted group in the comparison of operative time, blood loss, and range of lymph node dissection. However, the length of skin incision in the video-assisted group was significantly smaller than in the non-video-assisted group.

**Conclusion:** Video-assisted thyroidectomy and modified radical neck dissection might be an acceptable surgical procedure for papillary thyroid carcinoma.

**Abstract ID: 0904** Specific Field: **Endocrine Surgery**

**Mode of pres.: Poster Discussion**  
**ISW 2011 Session PW 09.12**

**Analysis of factors influencing outcome of localization of parathyroid adenomas by <sup>99m</sup>Tc-MIBI imaging**

Y. Hibi [1], Y. Shimizu [1], C. Kagawa [1], Y. Mizuno [1],  
 T. Imai [2], K. Iwase [1]

[1] Fujita Health University School of Medicine, Toyoake, Japan,  
 [2] Nagoya University Hospital, Nagoya, Japan

**Introduction:** Although the sensitivity of <sup>99m</sup>Tc-MIBI scanning is 70–90% in patients with solitary parathyroid adenomas, false-negative results of <sup>99m</sup>Tc-MIBI scanning are unavoidable. Previous studies have reported a correlation between tumor size and detectability of parathyroid adenomas by <sup>99m</sup>Tc-MIBI imaging. However, false negative results have been reported in large tumors and, conversely, some very small tumors have been detected. The purpose of this study is to assess the effect of various clinicopathological characteristics which influence the outcome of <sup>99m</sup>Tc-MIBI imaging.

**Material and Methods:** 122 consecutive patients who underwent parathyroidectomy and were clinicopathologically diagnosed with a single-affected gland from 2005 to 2008 in our institution were analyzed. 84 cases (69%) were MIBI-positive and 38 cases (31%) were MIBI-negative. The clinicopathological characteristics (age, body mass index, adenoma weight, adenoma volume, preoperative intact PTH level, parathyroid cell type content; oxphil cell content, clear cell content) were compared between the MIBI-negative and MIBI-positive group.

**Results:** The average age, BMI, glandular weight, volume, intact PTH level oxphil cell content and clear cell content in the MIBI-negative group and MIBI-positive group were 62.5 vs. 61.2 years (N. S), 22.5 vs. 22.4% (N. S), 502 vs. 1024 mg ( $P = 0.001$ ), 464 vs. 1239 mm<sup>3</sup> (N. S), 204 vs. 217 pg/ml (N. S), 2.7 vs. 11.1% ( $P = 0.006$ ) and 61.2 vs. 39.0% ( $P = 0.003$ ), respectively. On multivariate analysis, the glandular weight and the clear cell content were statistically significant independent factors. Moreover, the average of intact PTH level per glandular weight was unexpectedly lower in the MIBI-positive group (0.79 vs. 0.37;  $P = 0.001$ ).

**Conclusion:** Some studies have reported that MIBI substrate accumulation is preferable in oxyphil cells that are rich in mitochondria and that oxphil cell content in parathyroid tumors is a significant influencing factor. In this study, clear cell content had more influence than oxphil cell content. This might be because clear cells may contain fewer mitochondria compared with not only oxyphil cells, but other types of chief cell (e.g., chief dark cell). The functionality of parathyroid adenomas may not directly reflect the outcome of the scintigram examination.

**Abstract ID: 0905** Specific Field: **Endocrine Surgery**

**Mode of pres.: Poster Discussion**  
**ISW 2011 Session PW 09.13**

**Outcomes and prognostic factors of 251 patients with minimally invasive follicular thyroid carcinoma**

K. Sugino [1], K. Ito [1], K. Kameyama [2], M. Nagahama [1],  
 W. Kitagawa [1], T. Uruno [1], Y. Yano [1], K. Okuwa [1]

[1] Ito Hospital, Tokyo, Japan, [2] Keio University Department of Pathology, Tokyo, Japan

**Introduction:** Radioiodine ablation following total thyroidectomy for patients with widely invasive follicular thyroid carcinoma (FTC) is

generally accepted. On the other hand, therapeutic strategy for minimally invasive FTC is still controversial. Histological diagnosis is often made after lobectomy in patients with minimally invasive FTC. We investigated whether radioiodine ablation following completion total thyroidectomy should be necessary for all patients with minimally invasive FTC diagnosed after lobectomy.

**Material and Methods:** Between 1989 and 2006, 251 patients with minimally invasive FTC underwent initial surgery at our hospital with a median follow up of 7.2 years. There were 194 females and 57 males with a mean age of 46 years. Distant metastases were observed in 52 patients (20.7%). Twenty two patients had distant metastasis at the initial surgery (M1), and the other 30 patients had during follow-up periods. Risk factors for distant metastasis free survival (DMFS) and cause-specific survival (CSS) were analyzed. Factors analyzed here were as follows; age at initial surgery, sex, primary tumor size, histological findings (type of invasion, differentiation, extent of vascular and capsular invasion), completion total thyroidectomy and distant metastasis at initial surgery. The Kaplan–Meier method and log rank test were adopted to analyze time-dependent variables. The Cox proportional hazard model was adopted for multivariate analyses.

**Results:** Univariate analysis showed age (>45 y/o) and primary tumor size (>4 cm) were significant factor related to postoperative distant metastasis in 229 patients without distant metastases at the initial surgery. Cumulative survival rate was significantly poorer in patients with M1, patients aged >45 y/o, patients with primary tumor size >4 cm. Multivariate analyses showed that age and primary tumor size were significant risk factors for DMFS, and distant metastases at initial surgery (M1), age and primary tumor size were significant risk factors for CSS.

**Conclusion:** Radioactive iodine ablation following completion total thyroidectomy should be considered for patients with age >45 y/o and primary tumor >4 cm, diagnosed histologically as minimally invasive FTC after lobectomy.

**Abstract ID: 0906** Specific Field: **Endocrine Surgery**

**Mode of pres.: Poster Discussion**  
**ISW 2011 Session PW 09.14**

**Minimally invasive posterior adrenalectomy: a framework for the successful introduction of a novel surgical technique**

T. C. Lairmore [1], C.Y. Lee [1], P. Dickson [2], Gillian Alex [2],  
 E. G. Grubbs [2], S. K. Snyder [1], J. E. Lee [3], N. D. Perrier [2]

[1] Scott & White Hospital, Texas A&M University Health Science Center, Temple, Texas, USA, [2] M. D. Anderson Cancer Center, Houston, Texas, USA, [3] Scott & White, Texas A&M University Health Science Center, USA

**Introduction:** Models for the safe introduction of innovative surgical technologies are needed in academic training centers. Implementing novel techniques involves graduated experience and avoidance of trial-and-error learning curves on live patients. High volume centers with expertise in the disease condition as well as surgical training are optimal.

**Material and Methods:** We employed a cooperative model for technology transfer to facilitate assimilation of a novel surgical technique. We focused on directed surgical skills development, preparative laboratory studies, and direct scientific interchange among academic colleagues in the clinical development of the procedure at a new site.

**Results:** The study involved collaboration between two academic surgical training centers in Texas, USA. The initial adoption of posterior retroperitoneoscopic adrenalectomy(PRA) by the group at M. D. Anderson involved travel of the entire surgical team to

Germany to directly observe and learn the procedure from the surgeon who pioneered the current technique. In order to transition this procedure to the second center (Scott & White), the following steps were taken: 1) prior experience including laparoscopic adrenalectomy by the second surgical team, 2) surgical skills laboratory training and subsequent cadaver/-anesthetized animal studies, 3) direct proctoring by an M. D. Anderson surgeon colleague in the initial cases, 4) continuous monitoring of early outcomes, and 5) incorporation of the technique into a fellowship training program. Shared interim analysis was performed assessing the results of PRA, stratified into earlier and later developmental periods. This effort was further expanded on by the successful development of robot-assisted PRA by both groups.

**Conclusion:** We present a framework for the safe implementation of new surgical technologies between partnered academic training institutions. Appropriate preparation and sharing of lessons learned were utilized to establish these techniques, culminating in the development of RAPRA by both groups. The potential advantages to patients, surgical team and trainees needs further objective evaluation.

Surgical Experience with Posterior Retroperitoneoscopic Adrenalectomy ( $N = 200$ , 2005–2010)

	Scott & White	M. D. Anderson Cancer Center	Robot-assisted posterior ret-roperitoneoscopic adrenalectomy (RAPRA) combined
2005	0	14	
2006	6	19	
2007	9	20	
2008	13	35	
2009	5	25	6
2010	4	9	21
Total	37	122	27

**Abstract ID: 0907** Specific Field: **Endocrine Surgery**

**Mode of pres.: Poster Discussion**  
**ISW 2011 Session PW 09.15**

**Differences in thyroid cancer presentation across racial/ethnic groups: are we dealing with distinct clinical entities?**

R. T. Williams [1], A. K. Stewart [2], M. Talamonti [3], R. Prinz [3], T. Moo-Young [3]

[1] University of Chicago Medical Center, Chicago, IL, USA,  
[2] American College of Surgeons, Chicago, IL, USA,  
[3] NorthShore University Health System, Evanston, IL, USA

**Introduction:** Treatment of thyroid cancer in the United States (US) is fairly standardized. Patients undergo thyroidectomy  $\pm$  neck dissection followed by radioactive iodine as indicated. Stratification of treatment is largely based on pathologic variables like tumor size and lymph node status. Increasing evidence has shown that patient factors like age and gender may predict extent of disease and recurrence risk. This study aims to characterize the impact of race/ethnicity on thyroid cancer presentation and explore whether differences can be explained by socioeconomic factors or hospital variation.

**Material and Methods:** 93,467 thyroid cancer patients diagnosed in 2004–2008 were queried from the National Cancer Database (NCDB), which captures  $\sim$ 81% of thyroid cancers in the US. Univariate logistic regression was used to evaluate differences in clinicopathologic disease presentation across racial/ethnic groups. Multivariate logistic regression was used to re-examine these differences while controlling for sociodemographic (education, insurance, comorbidity) and hospital (type, location, case volume) variables.

**Results:** Significant variation in disease presentation was detected across racial/ethnic groups. Compared to non-Hispanic whites, blacks were more likely to have tumors  $>4$  cm (OR 1.95, 95% CI 1.78–2.14) and distant metastasis (OR 1.88, 95% CI 1.54–2.30) but less likely to have nodal disease (OR 0.52, 95% CI 0.48–0.57) or capsular extension (OR 0.73, 95% CI 0.62–0.86). In contrast, Hispanics tended to be younger than non-Hispanic whites (OR for age  $>45$  years of 0.66, 95% CI 0.62–0.70), exhibit more capsular invasion (OR 1.53, 95% CI 1.35–1.74) and node positive disease (OR 1.13, 95% CI 1.06–1.21). Asian/Pacific Islanders had slightly larger tumors than non-Hispanic whites (OR 1.19, 95% CI 1.10–1.29) and more distant metastasis (OR 1.92, 95% CI 1.51–2.45). These differences were present even after adjusting for histologic variant, insurance status, education level, comorbidity index, and hospital characteristics.

**Conclusion:** The extent of disease at diagnosis differs across racial/ethnic groups. These differences are not fully explained by variations in socioeconomic status or treatment facility. Such findings have potential implications for treatment stratification in thyroid cancer. Further studies are needed to explore environmental, cultural or even biologic factors that may be at play.

**Abstract ID: 0908** Specific Field: **Endocrine Surgery**

**Mode of pres.: Poster Discussion**  
**ISW 2011 Session PW 09.16**

**Disturbances in calcium homeostasis after bariatric surgery**

P. Hellman, M. Sundbom, K. Michaelsson, H. Hultin  
Inst of Surgical Sciences, Uppsala, Sweden

**Introduction:** A state resembling secondary hyperparathyroidism including raised levels of parathyroid hormone (PTH) and normal levels of calcium has been reported in morbidly obese patients. vitaminD-deficiency, caused by sequestration of vitaminD in fatty tissue, has been suggested as explanation.

**Objective:** To evaluate the postoperative effects of bariatric surgery on calcium homeostasis and bone densitometry.

**Material and Methods:** A total of 143 pre-menopausal Swedish white women were studied 1–13 years after gastric bypass (GBP) surgery. A subset of six women underwent citrate-calcium (CiCa)-clamping before and one year after bariatric surgery in order to further characterize the calcium homeostasis. The results were compared to healthy volunteers of normal weight and to individuals with pHPT. Dual-energy X-ray absorptiometry (DXA) was performed in 95 GBP-patients 1–13 years after surgery. A group of 335 randomly selected pre-menopausal Swedish white women were used as controls.

**Results:** Levels of PTH were significantly higher postoperatively, and calcium was lower. vitaminD remained low after bariatric surgery despite initiation of supplementation immediately postoperatively. CiCa clamping revealed that the sensitivity for calcium remained high postoperatively. The calcium/PTH set point was slightly, but not significantly higher postoperatively. The bone mineral density (BMD) was lower in the operated, with a correlation to the extent of weight loss and to time since surgery.

**Conclusion:** Preoperative disturbance of calcium homeostasis with insufficiency of vitaminD, decreased levels of calcium and elevated levels of PTH is deteriorated after GBP. BMD is decreasing after bariatric surgery, independently of weight gain. Lifelong follow-up with an individually adjusted substitution of vitaminD is vital for GBP patients.

**Abstract ID: 0909** Specific Field: **Endocrine Surgery**

**Mode of pres.: Poster Discussion**  
**ISW 2011 Session PW 09.17**

**Management of Grave's disease is improved by total thyroidectomy**

M. Annerbo, P. Stålberg, P. Hellman

Department of Surgery, Uppsala University, Uppsala, Sweden

**Introduction:** Operative strategy for Graves disease (GD) has changed from subtotal (ST) to total thyroidectomy (TT) during the last decade. Smaller previous studies evaluating the outcome have indicated similar results. We performed a study with principal aims to evaluate the risk for recurrence, complications, and influence on progressive dysthyroid ophthalmopathy (DO) when changing from ST to TT.

**Material and Methods:** Information from 267 consecutive patients operated for GD between 2000–2006 were collected at Uppsala University hospital (143) and Falun County hospital (128). There were 229 women and 38 men. Four patients were operated on twice. A total of 41 STs and 230 TTs were performed. Results were compared to a previous cohort from the same hospital of a majority of STs (157/176) performed between 1980 to 1992.

**Results:** The risk for relapse of GD was reduced from 20 to 2.5% after the shift from ST to TT. Surgical complications such as permanent vocal cord paralysis was demonstrated in 2.2%, and persistent hypocalcemia in 4.4%, being similar in the previous series of ST. Change of surgical method did not affect postoperative progression of DO, (7.8%). There were no differences in outcome related to where the patients were operated on (University or County Hospital).

**Conclusion:** Change from ST to TT dramatically reduced the risk for recurrence without increasing the rate of complications. TT is not more effective than ST in hampering progression of DO as been advocated by some.

**Abstract ID: 0910** Specific Field: **Endocrine Surgery**

**Mode of pres.: Poster Discussion**  
**ISW 2011 Session PW 09.18**

**Definition and outcome of massive adrenal tumours**

J. Kirkby-Bott, M. L. Sequeira, Z. El-Khatib, R. Caiazza, S. Aubert, E. Leteurre, F. Pattou, B. Carnaille

CHRU Lille, Lille, France

**Introduction:** This series aims to define what constitutes an abnormally large adrenal tumour, what pathologies cause these tumours and what their outcome is

**Material and Methods:** Between 1992 and 2009 we searched the adrenal database for cases that fell between the 95th and 100th percentile range for size. The measurement taken post-excision was used to determine the size of the tumour.

**Results:** Fifteen centimetres (cm) was the definition of a massive adrenal neoplasm as this was the size to the nearest cm that straddled the 95th percentile. 34 patients were included in the analysis. 14 tumours were hormone secreting. Median tumour size was 17 cm (range 15–30). 25 patients had malignant tumours. Pathology included: 21 adreno-cortical carcinomas, 5 pheochromocytomas, 2 adrenal metastases, 2 adrenal sarcomas, 2 necrotic adrenal glands and one each of: schwannoma and myelolipoma. Median follow-up time was 761 days (2–4673 days). An R0 resection was accomplished in 22 patients. Five of 21 patients with adreno-cortical cancer are disease free, 6 have recurred and 10 have died. There were significant survival differences comparing R0 and R1 and R2 resections ( $P = 0.0001$ ) but not with capsular tear ( $P = 0.161$ ). Patients receiving adjuvant mitotane had a longer survival than those that didn't ( $P = 0.018$ ). 5/21 patients with adrenocortical cancer presented with an inferior vena cava (IVC) tumour thrombus (median survival 257 days v 810 days,  $P = 0.978$ ).

**Conclusion:** A massive adrenal neoplasm is an adrenal tumour greater than 15 cm. Malignant corticoadrenal cancers are the commonest encountered massive adrenal neoplasm. All patients with a massive adrenal neoplasm should be operated on because 25% are benign and some adreno-cortical cancers can be cured. Patients with IVC tumour thrombus should be discussed. Mitotane was beneficial to survival in adreno-cortical cancers.

**Abstract ID: 0911** Specific Field: **Endocrine Surgery**

**Mode of pres.: Poster Discussion**  
**ISW 2011 Session PW 09.19**

**Lobectomy is a logical procedure for unilateral benign thyroid pathologies**

H. Genc, M. Hacıyanli, E. Kamer, H. R. Unalp, C. Tavusbay, E. Tarcan

Ataturk Egitim Arastirma Hastanesi (AEAH), Izmir, Turkey

**Introduction:** There is an ongoing debate about the extent of thyroidectomy in unilateral thyroid pathologies. One favors the total thyroidectomy to eliminate the risk of second procedure in case of a malignancy and also argues that many patients having unilateral lobectomy will develop nodules in the remaining lobe and need to use thyroid supplementantion therapy. On the other hand, others favor lobectomy in the era of fine needle aspiration biopsy (FNAB) and frozen examination to rule out a proportion of malignancy before completion of surgery and try to preserve native thyroid functions. So we investigated the nodule development, necessity of additional surgical procedure and necessity of thyroid hormone supplementantion in a group of patient having lobectomy for a benign pathology.

**Material and Methods:** The medical records of patients having lobectomy for various reasons were recorded prospectively between 2005 and 2010. One hundred and eighty patients had lobectomy in the period. Patients with malignant pathology ( $n = 29$ ) and having toxic adenoma ( $n = 13$ ) were excluded for further analyses. The patients ( $n = 11$ ) who didn't come to follow-up visits were also excluded and remaining 127 patients composed the study group. Blood thyroid function tests and antithyroid antibodies, neck ultrasound for remaining lobe were done six months postoperatively and annually then.

**Results:** The median follow-up was 25 months. Thyroid hormone supplementantion was needed in seven (5.5%) patients and all had high anti-T and anti-M antibodies. Nodule development was seen in 11 (8.6%) patients during the follow-up. The nodules were solitary in seven and multiple in four. The nodule size was smaller than 7 mm in



eight patients and between 7–10 mm in four patients. FNAB was done in two patients and none of the patients has received further surgical intervention.

**Conclusion:** Thyroid lobectomy was a convenient option for unilateral thyroid diseases. The rate of nodule development in the remaining lobe was low. The underlying autoimmune disease determined the necessity of thyroid hormone supplementation.

**Abstract ID: 0912** Specific Field: **Endocrine Surgery**

**Mode of pres.: Poster Discussion**  
**ISW 2011 Session PW 09.20**

**Clinical application of real time tissue elastography (RTE) in thyroid and parathyroid disease: a new attempt to establish qualitative and quantitative methods**

S. Suzuki, T. Fukushima, K. Nakano

Fukushima Medical University, Fukushima, Japan

**Introduction:** Real time Tissue Elastography (RTE) which can display the stiffness of tissue was used in the diagnosis of thyroid and parathyroid tumors. We herein report on the utility of using new qualitative and quantitative evaluations of RTE for the diagnosis of both thyroid and parathyroid disease.

**Material and Methods:** The subjects consisted of 830 thyroid and parathyroid patients who were diagnosed based on a qualitative evaluation of RTE. In addition, a quantitative examination of RTE was also performed in 160 out of the 830 cases. All patients underwent elastography accompanied with B-mode ultrasonography using either the EUB-8500 or 7500 device (Hitachi Medico.). For the qualitative method, 4 steps grad classification method was used for judgment by moving images. Grade 1 is the softest and Grade 4 is the hardest. In addition, the ratio of a distortion of the sternocleid muscle as a control and a lesion based on still pictures was quantitatively calculated as the Strain Ratio (SR).

**Results:** Malignant nodule showed Grade 3 and 4 whereas the benign nodule showed Grade 1 and 2 with significant differences. From the above thyroid cancer was obviously hard in comparison to benign thyroid tumor. It is therefore considered to be useful for making a differential diagnosis between thyroid cancer and benign tumors, especially between follicular thyroid cancer (FTC) and adenoma (FA). In addition, hyperparathyroidism such as adenoma or hyperplasia were as soft as Grade 1 in all cases. Average of SR in FA was 1.0, and averages of SRs in thyroid cancers including papillary thyroid carcinoma, FTC, medullary thyroid carcinoma and anaplastic thyroid carcinoma were all under 0.4. SRs in thyroid carcinomas were also significantly lower than those in benign thyroid tumors. We recommend that the cut-off value of SR between benign and malignant thyroid tumors is 0.4. Parathyroid adenoma was higher SR than the normal thyroid gland and sternocleid muscle.

**Conclusion:** RTE is therefore considered to be a useful diagnostic modality for making a differential diagnosis of either thyroid or parathyroid disease.

**Abstract ID: 0913** Specific Field: **Endocrine Surgery**

**Mode of pres.: Poster Discussion**  
**ISW 2011 Session PW 09.21**

**Post-operative hungry bone syndrome in patients with secondary hyperparathyroidism**

M. Goldfarb [1], S. Gondek [2], S. Lim [1], J. I. Lew [1]

[1] University of Miami Miller School of Medicine, Miami, USA,  
[2] Beth Israel Deaconess Medical Center, Boston, USA

**Introduction:** Hungry bone syndrome (HBS) is a postoperative condition of severe hypocalcemia that is occasionally seen in patients who have undergone parathyroid surgery for secondary hyperparathyroidism (2HPT). Although a transient phenomenon that often resolves with calcium supplementation, much remains unknown about HBS. This study investigates the incidence and potential risk factors of HBS in patients after parathyroidectomy (PTX) for secondary hyperparathyroidism.

**Material and Methods:** Retrospective review of a prospectively collected database of 79 patients who underwent PTX for 2HPT at one institution. Data collected included pre- and post-operative laboratory values, presenting symptoms, duration of dialysis, and use of Sensipar or vitaminD supplementation among others. HBS was defined as the need for additional days of hospitalization or readmission for IV calcium supplementation due to clinical symptoms of hypocalcemia including tingling, muscle spasms, and bone pain and/or immediate postoperative low serum calcium level.

**Results:** 79 patients underwent PTX for 2HPT; 48 were female (60.7%) and 31 male with a mean age of 38 years. Of the entire group, 21 patients (26.6%) experienced HBS of which 19 underwent subtotal PTX. High pre-op calcium level ( $>11$  mg/dl,  $P = 0.02$ ) and young age ( $<45$  years,  $P = 0.02$ ) were associated with the development of HBS. Of 8 patients who presented with calciphylaxis, only 2 developed HBS (NS). No other pre- or intra-op variable was a significant predictor of HBS. Most patients that developed HBS experienced symptoms of hypocalcemia within 24 h after operation and required a prolonged hospital stay (19/21) compared to hospital readmission within the first 7 days (2/21). Initial post-op serum calcium levels drawn within 18 h of surgery were significantly lower in those patients that developed HBS compared to those individuals that did not have HBS (mean 7.1 v 8.3 mg/dl,  $P = .001$ ).

**Conclusion:** HBS develops in a significant proportion of patients undergoing subtotal parathyroidectomy for 2HPT, which generally occurs within the first 24 h postoperatively. The only identifiable risk factors for HBS include young age and high pre-op calcium levels. In addition, low initial calcium levels within the first 18 h postoperatively may help identify those patients that will develop symptoms requiring judicious calcium supplementation.

**Abstract ID: 0914** Specific Field: **Endocrine Surgery**

**Mode of pres.: Poster Discussion**  
**ISW 2011 Session PW 09.22**

**Assessment of swallowing function disorders in benign goiters and impact of thyroidectomy upon them: a case control study**

M. S. Retnam [1], A. Mishra [1], G. Chand [1], G. Agarwal [1], A. Agarwal [1], A. K. Verma [1], S. K. Mishra [2]

[1] Sanjay Gandhi Post Graduate Institute of Medical Sciences, Lucknow, India, [2] Sanjay Gandhi Post Graduate Institute of Medical Sciences, India

**Introduction:** There is scarce data regarding Swallowing Function disorders (SFD) in patients with benign goiters. The aim of this study was to assess SFD in patients with benign goiters, impact of thyroidectomy and factors affecting the outcome of SFD following thyroidectomy.

**Material and Methods:** Prospective case-control study (Sept 2009–Dec 2010) consisting of 100 patients with benign goiters and 100 age

and sex matched controls. Controls and patients (pre-surgery and 6 months following surgery) filled the translated (Hindi) and validated modified SWAL-QOL questionnaire, consisting of 11 domains describing physical, mental and social aspects of swallowing. Patients with history of endotracheal intubation, diabetes and neuromuscular disorders were excluded. Pre-surgery scores of patients and controls and pre- and follow-up scores of patients ( $n = 58$ ) were compared (Student's T test). Linear regression and multivariate analysis were done to analyze factors affecting outcome.

**Results:** Mean age of males and females for control and patient groups were 37.8 Vs 39.2 and 37.5 Vs 39.5 years respectively. 7.8% patients complained of dysphagia at presentation. 75.7% of patients were euthyroid, 22.3% hyperthyroid and 1.9% hypothyroid. 84.5% patients had nodular goiter, 15.5% diffuse and 8.7% had retrosternal extension. 49 patients had total and 51 had hemithyroidectomy performed. No patient had permanent RLN palsy or hypocalcemia. Mean specimen weight was  $118 \pm 80$  g for total and  $50 \pm 30$  g for hemithyroidectomy respectively. As compared to controls, pre-surgery scores of patients were low in all domains of SWAL-QOL, though significant differences were observed for Physical (87 Vs 73,  $P = .003$ ), and Social domain (95 Vs 81,  $P = .04$ ) in females only. At follow up patients had significantly improved scores in all domains with minimum in desire ( $P = .02$ ) and maximum in fear ( $P = .0001$ ) and in fact bettered those of controls in seven domains. None of the factors (age, nodularity status, retrosternal extension, type of surgical procedure and gland weight) except for sex ( $P = .000$ ) and thyroid function status ( $P = .001$ ) for fear and fatigue domains respectively were significantly associated with improved scores.

**Conclusion:** SFD seems to be an underestimated problem in patients with benign goiters. Thyroidectomy results in amelioration of this problem signifying improvement in Quality of Life.

**Abstract ID: 0915** Specific Field: **Endocrine Surgery**

**Mode of pres.: Poster Discussion**  
**ISW 2011 Session PW 09.23**

**The expression pattern of somatostatin receptor in primary and metastatic pancreatic neuroendocrine tumors**

K. Ariake [1], F. Motoi [2], M. Unno [2], H. Ohstuka [2]

[1] South Miyagi Medical Center, Oogawara, Japan, [2] Division of Hepato-Biliary Pancreatic Surgery, Sendai, Japan

**Introduction:** Pancreatic neuroendocrine tumor (P-NET) has grown slowly and expected long term survival compared with pancreatic cancer. But in Japan, there is no effective systemic therapy currently available for P-NET because Streptozocin could not be utilized. Recently, Octreotide (OCT) a somatostatin analogs was demonstrated to prolong time to progression in patients with functionally active and inactive P-NET and was thought to be effective in metastatic tumor. However the detail mechanisms and the predictive factors of effectiveness were not fully discussed. In this study, we analyzed the expression pattern of somatostatin analogs receptor (SSTR) a target of OCT in the primary and metastatic tumor, and investigate the effectiveness and the resistant acquisition mechanism of OCT in P-NET.

**Material and Methods:** We reviewed our institutional experience of 74 P-NET from 2000 to 2010. In 74 cases, liver metastases were found in 16 cases. We studied SSTR subtype expression in hepatic metastases with primary P-NET from 11 patients and compared SSTR subtype in each tumor. The intensity of immunohistochemical staining for SSTR was categorized as negative, weak and positive.

**Results:** Positive and weak expression of SSTR in primary tumor was 66.7% in SSTR2A, 33.3% in SSTR3 and 16.7% in SSTR5. The expression in metastatic tumor tended to be decreased comparing with its primary tumor, 50% in SSTR2A, 6.3% in SSTR3, and 12.5% in SSTR5. In two cases, serial repeated hepatectomies were performed. The expression pattern of SSTR of the serially-resected tumor was different in each other. After the injection of OCT, the expression pattern of SSTR in metastatic tumor was reduced compared with primary tumor. Especially the expression of SSTR3 was decreased.

**Conclusion:** One of the possible explanations for the acquired resistant mechanisms of P-NET against OCT might be that the expression of SSTR in P-NET is decreased or lost after the tumor metastases.

**Abstract ID: 0916** Specific Field: **Endocrine Surgery**

**Mode of pres.: Poster Discussion**  
**ISW 2011 Session PW 09.23**

**Discovery of cribriform-morula variant of papillary thyroid carcinoma in patients with familial adenomatous polyposis: large-scale ultrasonographic thyroid screening**

S. Uchino [1], H. Ishikawa [2], A. Miyauchi [3], C. Tomoda [3], M. Hirokawa [3], S. Noguchi [1], T. Yoshida [4], K. Sugano [5]

[1] Noguchi Thyroid Clinic, Beppu, Oita, Japan, [2] Department of Molecular-Targeting Cancer Prevention, Graduate School of Medical Science, Kyoto Prefectural University of Medicine, Osaka, Japan, [3] Kuma Hospital, Kobe, Japan, [4] Genetics Division, National Cancer Center Research Institute, Tokyo, Japan, [5] Oncogene Research Unit/Cancer Prevention Unit, Tochigi Cancer Center, Utsunomiya, Japan

**Introduction:** Familial adenomatous polyposis (FAP) is an autosomal dominantly inherited polyposis syndrome characterized by hundreds of colorectal adenomatous polyps. Cribriform-morula variant of papillary thyroid carcinoma (CMV-PTC) is a rare variant of papillary thyroid carcinoma (PTC) and are associated with FAP. The aim of this study is to investigate the incidence of thyroid cancer among FAP patients.

**Material and Methods:** A total of 114 FAP patients (53 males and 61 females) who were going to Ishikawa Gastroenterological Clinic between May 2008 and October 2010 were entered in this study. 45 of these underwent colorectal surgery and the rest of 95 had not. Two female patients had underwent thyroid surgery due to thyroid cancer. Ultrasonography was screened in Ishikawa Gastroenterological Clinic, and the patients who were found to have thyroid tumor were reexamined, diagnosed or operated on Kuma Hospital. Germline APC gene mutation was examined by protein truncation test (PTT) or DNA sequencing from peripheral blood leukocytes.

**Results:** Twenty patients (17.5%) had solid tumor(s) (solitary in 11 and multiple in 9) and 21 patients (18.4%) had benign cystic tumor(s). In 6 male patients who had solitary solid tumor, 5 was reexamined (4–23 mm in diameter) and the cytological diagnosis all showed benign nodule. In 5 female patients who had solitary solid tumor (4–12 mm), PTC was found in 3 patients (CMV-PTC in 1 and typical PTC in 2). In 9 female patients who had multiple solid tumors (7–45 mm), CMV-PTC was found in 5 patients and typical PTC was found in 1. In total, PTC was newly found in 9 female patients and 6 of these were CMV-PTC. In 14 female patients with thyroid tumor (aged  $39.6 \pm 17.1$ , 18–79), CMV-PTC

was found in 6 of 7 patients aged 35 or younger, and in none of 7 patients older than 36 ( $P < 0.01$  by Fisher's exact test). 14 of 17 patients (82%) with solid thyroid tumor had the germline mutation in the 5' side of the APC gene.

**Conclusion:** Thyroid cancer is prevalent in around 18% of female FAP patients and is much higher than thought. CMV-PTC is only found in younger female FAP patients and never found in male or older female patients. We speculate that the clinical course of CMV-PTC may undergo spontaneous regression after the age of 35 or menopause.

### Abstract ID: 0917 Specific Field: Endocrine Surgery

**Mode of pres.: Poster Discussion**  
**ISW 2011 Session PW 09.24**

#### Elevated expression of cyclin A in post-Chernobyl papillary thyroid carcinoma

A. Dinets [1], M. Hulchiy [2], A. Sofiadis [1], A. Höög [3], C. Larsson [1], J. Zedenius [1]

[1] Karolinska Institutet, Stockholm, Sweden, [2] Kyiv City Teaching Endocrinological Center, Kyiv, Ukraine, [3] Karolinska University Hospital, Stockholm, Sweden

**Introduction:** Most patients with papillary thyroid cancer (PTC) have an excellent prognosis. The levels of expression of cell-cycle regulators or markers of proliferative activity can be a useful tool in obtaining prognostic information for PTC patients. Cyclin A is one of the proteins regulating cell cycle through its ability to control the correct sequence of events that brings the cell through S-phase to the G2-M checkpoint. Ki-67 (MIB-1) is a nuclear antigen used as a marker of cell proliferation. Cell-cycle deregulation is the cause of uncontrolled proliferation in many tumors including PTC and is a possible factor for a worse prognosis. The aim of this study was to investigate and correlate the expression of cyclin A and Ki-67 in a cohort of adult patients with different sizes of PTC who, during their childhood were exposed to radioactivity from the Chernobyl (Chornobyl) accident in 1986.

**Material and Methods:** Seventy patients (61 females and 9 males), with a mean age of 30.5 (range 19–39 years) operated on for PTC during 2004–2008 were identified for the study. Two groups were established according to size of primary tumor. Patients with size of PTC less than or equal to 2 cm in maximum diameter comprised Group 1 ( $n = 50$ ), whereas Group 2 consisted of patients with PTC larger than 2 cm ( $n = 20$ ). A minimum of 2,000 tumor cells were scored for each sample. Expressions of both cyclin A and Ki-67 (MIB-1) were determined by immunohistochemistry using monoclonal antibodies. The percentage of positive cells was calculated for both target proteins. Clinical data, expressions of cyclin A and MIB-1 were compared between groups.

**Results:** Expression of cyclin A was significantly higher in Group 2 (mean 1.10) as compared to Group 1 (mean 0.59),  $P < 0.05$ . MIB-1 index (mean 2.36), age at diagnosis (mean 30 years) and age at the time of the Chernobyl accident (mean 10 years) were not significantly different between the groups.

**Conclusion:** The clinical features of this cohort of adult PTC patients exposed to the radioactive fallout from the Chernobyl accident seem to be no different than other PTC cohorts. Elevated expression of cyclin A may reflect worse prognosis in the group of patients with tumor size larger than 2 cm. However, it is yet not possible to say due to the short follow-up time. Still, a closer follow-up may be justified to determine consequences for patients' outcome.

### Abstract ID: 0918 Specific Field: Endocrine Surgery

**Mode of pres.: Poster Discussion**  
**ISW 2011 Session PW 09.25**

#### Recurrent laryngeal nerve deliberation and reconstruction during the operation and reoperation of thyroid cancer and recurrent goiter

R. Dzodic [1], I. Markovic [1], I. Djuricic [1], M. Buta [1], M. Oruci [1], Z. Milovanovic [1], M. Jevric [1], A. Miyauchi [2]

[1] Institute of Oncology and Radiology of Serbia, Belgrade, Serbia, [2] Institute of Oncology and Radiology of Serbia, Medical School University of Belgrade, Serbia

**Introduction:** Recurrent laryngeal nerve (RLN) palsy is a major obstacle in thyroid and parathyroid surgery. Permanent RLN paralysis was reported in 0.5 to 10% of cases. RLN injuries are more frequent during the operation and reoperations of cancer and recurrent goiter. A method of RLN reconstruction or deliberation depends on type of injury. Secondary goal during the reoperations was to improve phonation.

**Material and Methods:** We operated 14 patients of which 11 who had been previously operated in regional hospitals. RLN paralysis was verified by direct laryngoscopy. All patients had severe hoarseness. We explored paratracheal regions, identified RLN, the point of suture, resection or infiltration. We have performed nerve deliberation due to ligation in 7 cases, direct suture in two and ansa cervicalis RLN anastomosis (ARA) using Miyauchitechnique in five cases.

**Results:** We performed reoperations due to the thyroid cancer recurrence in ten patients and recurrent goiter in one patient within 3 months to 23 years (Median 5.5 months) after the first surgery. Three patients were primary operated in our Institute due to locally advanced papillary (2) and medullary (1) thyroid carcinoma. After RLN deliberation by removing the sutures, direct suture (end-to-end) or ARA we observed it's recovery within 3 weeks to 6 months. The rate of RLN recovery was verified by postoperative direct laryngoscopy. It is important to underline that if the nerves were reconstructed by sutures vocal cords don't regain normal movement and are usually fixed in the median position. The patient's voice improves because reinnervated cords recover from atrophy and restore tension during phonation which is shown on audio recording.

**Conclusion:** It is important to explore the neck in order to identify RLN and to deliberate it in the case of ligation. Nerve reconstruction is also strongly suggested. The ultimate method to evaluate quantitatively the voice recovery is the maximum phonation time.

### Abstract ID: 0919 Specific Field: Endocrine Surgery

**Mode of pres.: Poster Discussion**  
**ISW 2011 Session PW 09.26**

#### Surgery of differentiated thyroid carcinoma in children and adolescents: 30 years experience

R. Dzodic [1], I. Markovic [1], M. Buta [1], I. Djuricic [1], B. Stanojevic [2], G. Pupic [1], M. Jevric [1], A. Babic [1]

[1] Institute of Oncology and Radiology of Serbia, Belgrade, Serbia, [2] Atomic Bomb Disease Institute, Nagasaki, Japan

**Introduction:** Differentiated thyroid carcinoma (DTC) in children and adolescents is very rare and accounts less than 1% of all thyroid cancers. It shows aggressive behavior with gross tumor burden, lymph



node and distant metastases on first clinical presentation. **Material and Methods:** We operated 38 children and adolescents between 7 and 21 years of age due to PTC. Mean age was 16.6 years. At the time of diagnosis 13% had distant lung metastases. Total thyroidectomy (TT) or completion of thyroidectomy was performed in all cases followed with central neck dissection and frozen section examination of lower lateral compartments. Modified radical neck dissection (MRND) was performed in all cases with histological finding of lymph node metastases (LNM). According to age at the time of diagnosis patients were divided into two groups—children ( $\leq 16$  years) and adolescents ( $>16$  years).

**Results:** Median tumor size was 1.9 cm. Papillary TC was found in 37 and follicular TC in one patient. Multifocal tumors were found in 37%, capsular invasion in 29% and vascular invasion in 24% of cases. LNM in either central or lateral neck compartments were found in 76% of patients (children vs. adolescents—92% vs. 68%;  $P = NS$ ). Tumors capsular and vascular invasion were significantly more frequent in children ( $P = 0.0026$  and  $P = 0.0034$ ). Incidence of bilateral multifocal tumors was not significantly different among those groups (children vs. Adolescents—46% vs. 32;  $P = 0.39$ ). Postoperative ablative or systemic radioiodine therapy was applied in 16 patients. Median follow-up was 163 (range 9–348) months. Relapse occurred in three (7.9%) patients in primary not dissected lymph nodes. Treatment of relapse was multidisciplinary comprising surgery with radioiodine and/or external radiotherapy. Overall survival rate was 100% in a follow up period.

**Conclusion:** Differentiated thyroid carcinoma in children and adolescents is characterized with loco-regional and distant aggressiveness at the time of diagnosis. Multifocality, capsular and vascular invasion were present in about 25–37% of cases, while lymph node metastases in more than 75%. Capsular and vascular invasion were significantly more common in younger patients. Extensive surgical approach should be performed in both primary and recurrent disease in young patients with DTC because of excellent prognosis regardless to bad first clinical presentation.

**Abstract ID: 0920** Specific Field: **Endocrine Surgery**

**Mode of pres.: Poster Discussion**  
ISW 2011 Session PW 09.27

**A novel surgical technique for thyroid cancer with intra-cricotracheal invasion: Windmill resection and Tetrus reconstruction**

K. Enomoto, S. Uchino, H. Noguchi, Y. Enomoto, S. Noguchi

Noguchi Thyroid Clinic and Hospital Foundation, Beppu, Oita, Japan

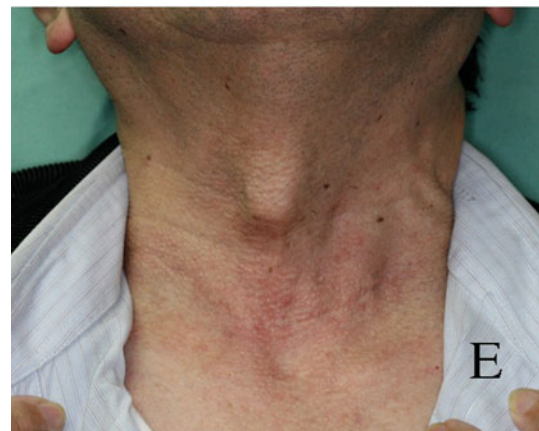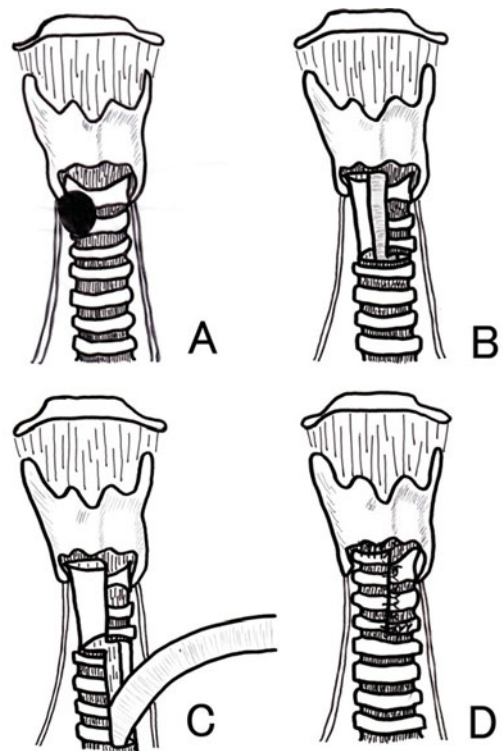
**Introduction:** We report a novel surgical technique, which we named Windmill resection and Tetrus reconstruction, for patients with thyroid cancer (TC) invaded into the laryngeal lumen.

**Material and Methods:** We treated 8 cases of TC with invasion into the laryngeal lumen by Windmill resection and Tetrus reconstruction at Noguchi Thyroid Clinic and Hospital Foundation between 2009 through 2011. The surgical parameters including complications, clinical and pathological data were analyzed in all patients.

**Results:** Patients were 1 male and 7 females (age  $69 \pm 10$  year). Histopathology of TC was papillary TC in 5 patients, poorly differentiated TC in 1 patient, anaplastic TC in 1 patient, and squamous cell carcinoma in 1 patient. Unilateral recurrent laryngeal nerve (RLN) palsy was confirmed preoperatively by laryngoscope in 4 patients. All

patients were treated with Windmill resection and Tetrus reconstruction along with total thyroidectomy (3 patients), subtotal thyroidectomy (3 patients) and lobectomy (2 patients). Radical neck dissection was performed in all patients (8 central, 3 unilateral, 1 bilateral). Average blood loss and operation time were 200 ml and 304 min. Resection of larynx was on the right side in 4 patients and on the left side in 4 patients. The resected length of larynx with trachea was  $29 \pm 6$  mm.

Post-surgical hypothyroidism and hypoparathyroidism occurred in 8 and 2 patients. Air leakage at the suture line occurred in 3 patients. Two of them required re-reconstruction surgery and the other one needed only a 2 weeks observation. RLN palsy newly occurred in 5 patients (2 bilateral, 3 unilateral). Dysphagia, pneumonia and pleural effusion occurred in 2, 2 and 2 patients, respectively. No



**Figure** The illustration of Windmill resection and Tetrus reconstruction (A-D), and postoperative surgical wound (E)



other complications such as airway stenosis occurred during follow-up.

There was no postoperative mortality. Two patients underwent tracheostomy because of bilateral RLN palsy. Two patients with anaplastic and poorly differentiated TC respectively had local recurrence 13 and 21 months after surgery. In all patients, we could preserve laryngeal functions such as phonation and swallowing.

**Conclusion:** This novel surgical technique may be as effective for local control as window resection of the larynx and contributes to the QOL of patients by resulting in a less unsightly surgical wound.

#### Abstract ID: 0921 Specific Field: Endocrine Surgery

**Mode of pres.: Poster Discussion**  
**ISW 2011 Session PW 09.28**

##### NAMPT inhibitor GMX1778 radiosensitizes xenotransplanted human carcinoid

V. Johanson [1], A. K. Elf [1], P. Bernhardt [1], E. Forssell-Aronsson [1], O. Nilsson [2], H. Ahlman [1]

[1] Institute of Clinical Sciences, Gothenburg, Sweden,  
[2] Institute of Biomedicine, Gothenburg, Sweden

**Introduction:** Most small intestinal (midgut) carcinoids are metastatic at diagnosis. For selected patients peptide receptor radionuclide therapy (PRRT) with radiolabelled somatostatin analogs is a treatment option that has resulted in partial response, symptomatic improvement and benefit in quality of life. However, the unspecific kidney and bone marrow uptake usually limits the tumor dose to sub-curative levels, and complete tumor regression is rarely seen. One way to improve the results of PRRT would be by the concomitant use of a radiosensitizer. The pyridyl cyanoguanidine GMX1778 has experimentally showed significant antitumor activity, which is probably mediated by inhibition of the NAD<sup>+</sup> biosynthesis enzyme nicotinamide phosphoribosyltransferase (NAMPT). In nude mice with subcutaneously xenografted midgut carcinoid (GOT1) we have shown that either <sup>177</sup>Lu-octreotate (30 MBq i.v.) or CHS 828/GMX1778 (250 mg/kg once weekly, p.o.) can each completely eradicate the tumors in 3 weeks. In this work we studied the radiosensitizing effect of lower doses of GMX1778 in combinations with a low dose of <sup>177</sup>Lu-octreotate.

**Material and Methods:** Nude mice, xenografted with the midgut carcinoid GOT1, were given a relatively low dose of <sup>177</sup>Lu-octreotate (7.5 MBq i.v.) and GMX1778 (100 mg/kg p.o.), alone or in combinations, and tumor volumes were followed.

**Results:** Tumors in control animals ( $n = 8$ ) almost doubled in volume over 4 weeks. Treatment with one dose of GMX1778 ( $n = 6$ ) resulted in a small reduction in tumor size, to 70% of the initial volume, but after 2 weeks tumors continued to grow. One dose of <sup>177</sup>Lu-octreotate ( $n = 10$ ), or 3 weekly doses of GMX1778 ( $n = 5$ ), resulted in a stronger antitumoral effect; at 3 weeks tumor volumes were reduced to 55% and 43% respectively. The combination of one dose of <sup>177</sup>Lu-octreotate and one dose of GMX1778 ( $n = 8$ ) resulted in a pronounced tumor reduction to 25% of the initial volume at 3 weeks. One dose of <sup>177</sup>Lu-octreotate and 3 weekly doses of GMX1778 ( $n = 5$ ) resulted in almost complete tumor regression at 3 weeks.

**Conclusion:** GMX1778 and <sup>177</sup>Lu-octreotate had a synergistic antitumoral effect in nude mice xenotransplanted with human midgut carcinoid tumors (GOT1). This radiosensitizing effect of GMX1778 is probably due to the inhibition of NAMPT, resulting in depletion of tumor NAD<sup>+</sup> levels and impaired energy metabolism.

#### Abstract ID: 0922 Specific Field: Endocrine Surgery

**Mode of pres.: Poster Discussion**  
**ISW 2011 Session PW 09.29**

##### Papillary thyroid cancer in pregnancy: a variant of the disease?

J. C. Lee, R. J. Clifton-Bligh, M. S. Sywak, L. W. Delbridge,  
B. G. Robinson, S. B. Sidhu

University of Sydney, Sydney, Australia

**Introduction:** Thyroid cancer is the second commonest malignancy during pregnancy. About 10% of thyroid cancers diagnosed during reproductive years are during pregnancy or the 12 months post-partum. Discordant data regarding the prognosis of these patients exist. We conducted a case-control study to compare outcomes of pregnancy associated (including post-partum) papillary thyroid cancer patients (PA-PTC) and a control group of patients with papillary thyroid cancer (C-PTC). To further investigate if PTCs in these two groups are biologically different, we compared their miRNA profiles.

**Material and Methods:** Twenty-three patients with PA-PTC were compared to a control group of thirty age-matched non-pregnant female patients for tumour characteristics, treatment details and patient outcome. MiRNA profiling was performed on tumours from ten of the PA-PTCs, and compared to the miRNA profiles of a control group.

**Results:** The two groups had similar indications for surgery, however the PA-PTC group had larger tumours ( $p 0.05$ ) and more nodal involvement ( $p 0.05$ ) than the C-PTC group. However, there was no significant difference in tumour subtypes, dose of radioactive iodine ablation given, length of follow-up, disease persistence, or recurrence. When compared to the baseline miRNA expression profile of normal thyroids, both groups showed deregulation of commonly reported miRs including miR-146, miR-221 and miR-222. However it appears that several other miRNAs play a biological role in the pathogenesis of PA-PTC, because they were differentially expressed when miRNA profiles of the two groups were compared.

**Conclusion:** The clinical impression is that pregnancy associated PTC is more aggressive, however this was not confirmed in this study. MiRNA profiling of pregnancy associated PTC appears to be biologically different to that of non-pregnancy related PTC suggesting that a larger clinical cohort would uncover outcome differences.

#### Abstract ID: 0923 Specific Field: Endocrine Surgery

**Mode of pres.: Poster Discussion**  
**ISW 2011 Session PW 09.30**

##### Intraoperative bilateral internal jugular venous sampling and rapid parathyroid hormone testing in patients with primary hyperparathyroidism and negative technetium-99m-sestamibi subtraction scintigraphy.

M. Barczynski, A. Konturek, A. Hubalewska-Dydejczyk,  
F. Golkowski, W. Nowak

Jagiellonian University, Medical College, Krakow, Poland

**Introduction:** In patients with primary hyperparathyroidism (pHPT) and negative Tc-99m-sestamibi subtraction scintigraphy (SS) many surgeons recommend ultrasound imaging and apt to proceed with bilateral neck exploration (BNE) in cases of non-localized disease. However, intraoperative bilateral internal jugular venous sampling with rapid parathyroid hormone assay (BIJV-IOPHT) may be helpful in lateralizing the side of the neck harboring a parathyroid disease and

in directing surgical approach. This study was designed to test that hypothesis.

**Material and Methods:** A prospective, case-control study. Negative SS was found in 102 of 502 patients with biochemically confirmed pHPT who were referred to our institution between 12/2002 and 06/2010 for parathyroidectomy. All those patients underwent ultrasound-guided BIJV-IOPHT before skin incision. Patients with iPTH gradient of 10% or higher between both sides of the neck underwent unilateral neck exploration (UNE) on the side indexed by higher iPTH level, whereas others underwent BNE. The primary outcome measure was accuracy of the test in correct qualification of patients with a unilateral parathyroid disease for UNE.

**Results:** Of 102 patients, 72.5% had a single adenoma, 7.8% had double adenomas and 19.6% had four-gland hyperplasia. UNE was successfully completed in 76.9% of 65 attempted patients with lateralizing iPTH gradient, whereas all others underwent BNE. Eighty percent of 65 patients with lateralizing vs. 64.9% of 37 patients with non-lateralizing iPTH gradient had a unilateral parathyroid disease, respectively ( $P = 0.09$ ). However, BIJV-IOPHT was true positive in lateralizing the side of the neck harboring a solitary parathyroid adenoma in 41 of 45 (91.1%) versus 9 of 29 (31.0%) patients with superior versus inferior parathyroid adenoma, respectively ( $P < 0.001$ ). The following overall accuracy, sensitivity, specificity, positive predictive value, and negative predictive values of this method were found, respectively: 63.7%, 68.4%, 50%, 80%, and 35%.

**Conclusion:** BIJV with IOPHT was helpful in lateralizing the side of the neck harboring a single parathyroid adenoma in most patients with superior adenomas, but not inferior adenomas.

**Abstract ID: 0924** Specific Field: **Endocrine Surgery**

**Mode of pres.: Poster Discussion**  
**ISW 2011 Session PW 09.31**

**The change of serum thyroglobulin levels after reoperation for nodal recurrence in patients who underwent total thyroidectomy for papillary thyroid carcinoma (PTC)**

D. H. Cho, S.Y. Bae, M.-Y. Choi, M.Y. Koo, S. K. Lee, J.-H. Choe, J. S. Kim, J.-H. Kim

Samsung Medical Center, Seoul, Korea, Republic of

**Introduction:** The recurrence in regional lymph node is frequent in patients operated on PTC and most of them need reoperations. In this study, we investigated serum thyroglobulin(Tg) levels before and after the 2nd surgery in them and analyzed the postoperative results.

**Material and Methods:** Patients who underwent reoperation for nodal recurrence after total thyroidectomy with or without central neck node dissection for PTC by a single surgeon between January 2002 and May 2008 at Samsung Medical Center were enrolled. These are categorized into two groups based on the post-ablation Tg level measured after the 2nd operation; Group A (off-Tg  $< 2$  ng/ml) and Group B(off-Tg  $2$  ng/ml).

**Results:** During follow-up period(mean 58.1 months), 30 patients (2.5%) had a recurrence in regional lymph node among total 1302 cases who underwent total thyroidectomy. Mean size of primary tumors was 2.0 cm(0.4–5.7). All of them had at least one metastatic node in central compartment during the first surgery. Most nodal recurrence was diagnosed by ultrasound and fine needle aspiration cytology but only 2 cases were detected by computed

tomography.131 I whole body scan in 18 patients did not show any iodine uptake in the neck. Nodal recurrence was most common in ipsilateral lateral neck(15 cases); 12 case in more than two compartment and 2 cases in supramediastinal node. Other 3 cases presented as a recurrence in central, contralateral, and bilateral neck respectively. The number of metastatic lymph nodes was 6(1–17) on average at the 2nd surgery. Before the 2nd operation, postablation Tg level of 23 patients was 2 ng/ml or more, but 11 patients of them had a postablation Tg level below 2 ng/ml after the 2nd operation. As compared between Group A and B, primary tumor size( $P = 0.042$ ), postablation Tg level after 1st operation( $P = 0.020$ ) and the number of metastatic lymph nodes at the 2nd operation( $P = 0.029$ ) were significant prognostic factors for reduction of postablation Tg levels after reoperation for nodal recurrence.

**Conclusion:** A nodal recurrence after total thyroidectomy for PTC was not common during early follow-up period and detected mainly by ultrasonography. Even for the patients presenting nodal recurrence, a proper nodal dissection could reduce the Tg level.

**Abstract ID: 0925** Specific Field: **Endocrine Surgery**

**Mode of pres.: Poster Discussion**  
**ISW 2011 Session PW 09.33**

**Evaluation of non-stimulated thyroglobulin velocity in detection of papillary thyroid carcinoma recurrence**

K. P. Wong, B. H. Lang, T. Yau, R. Leung, K.Y. Wan

The University of Hong Kong, Hong Kong, China, People's Republic

**Introduction:** A rise in serial non-stimulated thyroglobulin (nTg) may suggest papillary thyroid carcinoma (PTC) recurrence after seemingly curative surgery and radioiodine ablation but it remains unclear what rate of nTg rise signifies recurrence as some with persistently high nTg ( $> 1$   $\mu\text{g/L}$ ) often have no demonstrable recurrence despite repeated imaging studies. The study aimed to evaluate the annualized rate of nTg change (or nTg velocity (nTgV)) in those with PTC recurrence and compare with those with no demonstrable recurrence.

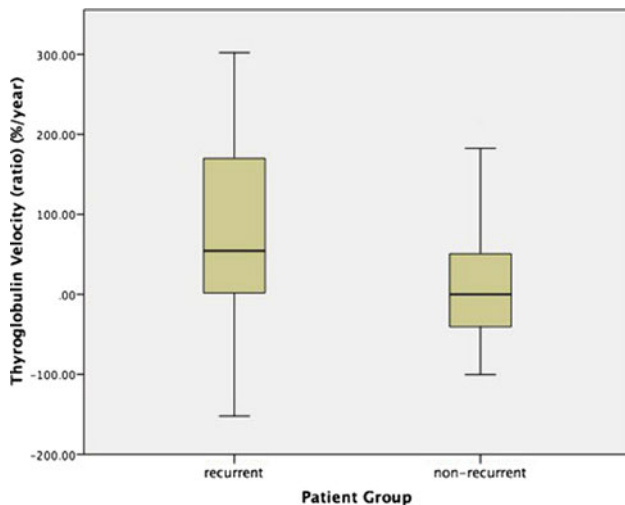
**Material and Methods:** Over a 5-year period, 51 out of 852 patients (6.0%) had post-ablation nTg  $> 1$   $\mu\text{g/L}$  on at least two consecutive visits were included for analysis. 16 patients subsequently developed recurrence (recurrent group) whereas 35 patients had no clinical and radiological evidence of recurrence (non-recurrent group). In recurrent group, nTgV = annualized rate of change between the two latest nTg readings before reoperation. In non-recurrent group, nTgV = annualized rate of change between the two latest readings before the latest follow-up visit.

**Results:** After a median follow up of 68.8 (3.0–347.0) months, demographics, pathological stage and extent of surgery & radioiodine ablation were comparable between two groups. In the recurrent group, the median time to recurrence was 58.1 (16.8–332.0) months, it had significantly higher baseline nTg ( $\mu\text{g/L}$ ) [12.4 vs. 2.4,  $P = 0.005$ ] and median nTgV (%/year) [54.4 vs. 0.0,  $P = 0.035$ ] than non-recurrent group. nTgV  $> 67\%$  was the best cut-off value for distinguishing tumor recurrence from no demonstrable recurrence with a specificity of 80.0% and a negative predictive value of 77.8%.

**Conclusion:** For patients with elevated post-ablation nTg  $> 1$   $\mu\text{g/L}$ , the median nTgV was significantly higher in those with proven recurrence than those with no demonstrable recurrence. At nTgV  $> 67\%$ /year, it suggested PTC recurrence.

Non-stimulated Thyroglobulin Velocity between recurrent and non-recurrent groups

	Recurrent (n = 16)	Non-recurrent (n = 35)	P-value
Baseline nTg (µg/L)	12.4 (1.3–111.0)	2.4 (1.2–76.0)	0.005
nTg velocity (µg/L/year)	4.2 (–36.5–222.4)	0.0 (–234.8–14.5)	0.015
nTg velocity (ratio) (%/year)	54.4 (–152–1853)	0.0 (–468–214)	0.035



**Figure:** Box-plot of nTgV between recurrent and non-recurrent groups

**Abstract ID: 0926** Specific Field: **Endocrine Surgery**

**Mode of pres.: Poster Discussion**  
**ISW 2011 Session PW 09.34**

**Critical appraisal of selective adrenal venous sampling demonstrated both a significant increase in the accuracy and the necessity of this procedure in the management of patients with primary hyperaldosteronism**

A. Harvey [1], J. L. Pasiaka [1], B. So [2], G. Kline [3], M. Hill [3], C. Jones [3], N. Scott-Douglas [3]

[1] University of Calgary, Faculty of Medicine, Department of Surgery and Oncology, Calgary, Canada, [2] University of Calgary, Faculty of Medicine, Department of Diagnostic imaging, Calgary, Canada, [3] University of Calgary, Faculty of Medicine, Department of Internal Medicine, Calgary, Canada

**Introduction:** Adrenal venous sampling (AVS) is frequently utilized in the work-up of primary hyperaldosteronism (PA). Unfortunately, AVS is technically challenging, leading some to question its role. In 2006 we reported our experience. Despite radiographic success, only 44% had biochemical evidence of bilateral vein cannulation. From this we altered our AVS protocol to include a single radiologist. The purpose of this study was to examine the impact of this protocol

change on the technical success rates for AVS and its subsequent influence on management.

**Material and Methods:** The charts of all patients referred for surgery with the diagnosis of PA since the protocol change was implemented were reviewed. Successful biochemical cannulation was defined as an adrenal vein to IVC cortisol greater than 3:1 at baseline (5:1 with ACTH stimulation). Lateralization was defined as an aldosterone: cortisol ratio of 4 times greater than the unaffected side. Baseline demographics, anatomical imaging, pathology and follow-up were recorded. Ethical approval was obtained through the institutional conjoint ethics board.

**Results:** 37 AVS procedures in 34 patients (19F:15M) were evaluated. The median age was 49 years. Patients were on an average of 3 antihypertensive medications at presentation. Cortisol ratios confirmed both adrenal veins were cannulated in 89% of procedures. In 19 patients, anatomical imaging and AVS were clearly concordant. However, in 15/34 (44%) patients AVS results contributed to surgical decision-making. 8 patients had inconclusive adrenal lesions on imaging for which AVS confirmed lateralization to the suspected side. 4 patients had anatomic evidence of bilateral disease. Of these AVS confirmed bilateral hyperplasia in 2 and in 2 lateralized resulting in the removal of an adenoma. 3 patients had unilateral anatomical disease, yet AVS demonstrated bilateral hyperplasia in 2 and discordant lateralization in 1.

**Conclusion:** The implementation of a AVS protocol with a dedicated radiologist resulted in a significant improvement in technical success rates. AVS influenced the management decisions in 44% of these patients. Thus the availability of accurate AVS continues to be an important adjunct in the management of patients with PA.

**Abstract ID: 0927** Specific Field: **Endocrine Surgery**

**Mode of pres.: Poster Discussion**  
**ISW 2011 Session PW 09.35**

**A comparative study for surgical outcomes of robotic versus conventional open modified radical neck dissection for the papillary thyroid carcinoma with lateral neck node metastasis**

S.-W. Kang [1], C. R. Lee [1], S. K. Park [1], J. S. Jeong [1], J. H. Park [1], S. H. Lee [1], J. J. Jeong [2], W.Y. Chung [1]

[1] Yonsei University College of Medicine, Seoul, Korea, Republic of, [2] Yonsei University College of Medicine, Korea, Republic of

**Introduction:** Since the introduction of endoscopic technique to thyroid surgery, several endoscopic lateral neck dissection trials have been conducted with the aim of avoiding a long cervical scar, and the recent introduction of surgical robotic systems has simplified and increased the precisions of endoscopic techniques. The aim of this study was to evaluate and compare the early surgical outcomes of robotic and conventional open modified radical neck dissection (MRND) for papillary thyroid carcinoma (PTC) with lateral neck node metastasis (LNM).

**Material and Methods:** From January 2009 to May 2010, 165 patients with PTC underwent bilateral total thyroidectomy with ipsilateral MRND for PTC with LNM. Of these patients, 56 underwent a robotic procedure using a gasless, transaxillary approach (the robotic group; RG) and 109 a conventional open procedure (the conventional open group; OG). These two groups were retrospectively compared in terms of their clinicopathologic characteristics, early surgical outcomes, and surgical completeness.

**Results:** The RG was younger than the OG ( $35.8 \pm 9.1$  vs.  $46.1 \pm 13.0$ ,  $P < 0.0001$ ). The operative time was longer in the RG

than the OG ( $277.4 \pm 43.2$  vs.  $218.2 \pm 43.8$  min,  $P < 0.0001$ ). The number of retrieved lymph nodes were similar between the RG and OG ( $37.3 \pm 12.8$  vs.  $39.4 \pm 14.1$ ,  $P = 0.359$ ). The RG had smaller tumor size ( $1.14 \pm 0.59$  vs.  $1.49 \pm 0.80$ ,  $P = 0.004$ ) and earlier stage than the OG (stage I: IVa = 80.4%:19.6% vs. 46.3%:53.7%,  $P < 0.0001$ ). The period of hospital stay after surgery was shorter in the RG than the OG ( $6.0 \pm 2.5$  vs.  $8 \pm 5.2$ ,  $P = 0.008$ ). Compared with the OG, the complication-rate was not different. There was no abnormal uptake on RAI scans in the two groups. The mean level of serum Tg (TSH suppressed) were acceptable in the two groups. The patients who had  $>1$  ng/ml of serum Tg were 3 and 7 in the RG, and OG, respectively (Tg level;  $4.59 \pm 4.54$  vs.  $3.41 \pm 2.40$ ).

**Conclusion:** Robotic MRND was found to be similar to conventional open MRND in terms of early surgical outcomes and surgical completeness but to offer an advantage of excellent cosmetic result. Based on our initial experiences, robotic MRND should be viewed as an acceptable alternative method in low risk PTC patients with lateral neck node metastasis.

**Abstract ID: 0928** Specific Field: **Endocrine Surgery**

**Mode of pres.: Poster Discussion**  
**ISW 2011 Session PW 09.36**

**Preoperative serum thyrotropin (TSH) level is associated with increased cancer risk in nodular goitres**

Y. Law, B. B. H. Lang

Department of Surgery, Queen Mary Hospital, Hong Kong, China, People's Republic

**Introduction:** Differentiating benign from malignant thyroid disease can be challenging. Male, extremes of age, large nodule and exposure to irradiation have been shown to be risk factors for malignancy. Recent studies found that preoperative serum TSH level might be another risk factor. Hypothesis that thyroid cancers express TSH receptors and TSH stimulates cancer growth is supported by improved survival in thyroid cancer patients treated with suppressive doses of levothyroxine and by cases of tumor growth post-T4 withdrawal or recombinant TSH. This study aimed to examine whether preoperative TSH level is associated with increased risk of malignancy in nodular goitre.

**Material and Methods:** Total 1383 patients underwent thyroidectomy in Queen Mary Hospital during March 2004 till December 2009. Those (1) on antithyroid medication ( $n = 172$ ), (2) on thyroxine ( $n = 16$ ), (3) with history of thyroidectomy or I131 ( $n = 69$ ), (4) final pathology medullary/anaplastic/lymphoma ( $n = 51$ ), (5) TSH data missing or taken more than one year before operation ( $n = 106$ ) were excluded, leaving 969 patients for analysis. Demographic data, presentation, clinical nodule size, and preoperative serum TSH level were recorded. Final pathologies were stratified as benign and malignant.

**Results:** 185 (19.1%) patients had malignancy. The median TSH level was significantly higher in the malignant than the benign group ( $1.40$  mIU/l vs.  $0.88$  mIU/l,  $P < 0.001$ ). The incidence of malignancy were 12.6% (57 of 451 patients), 21.6% (72 of 334), 29.9% (50 of 167), 35.3% (6 of 17) for TSH group 0.89, 0.90–1.79, 1.80–4.49 and 4.50 mIU/l, respectively ( $P < 0.001$ ). On univariate analysis, age, sex, history of previous non-thyroidal malignancy, nodule size and TSH level were all significant risk factors of malignancy. On multivariate analysis, age, nodule size and TSH level remained significant. When compared with TSH 0.89, the adjusted odd ratios for TSH = 0.90–1.79, =1.80–4.49 and 4.50 mIU/l were OR = 1.765, 95%CI 1.091–2.856,  $P = 0.021$ , OR = 2.487, 95%CI 1.432–4.320,

$P = 0.001$  and OR = 4.215, 95%CI 1.204–14.757,  $P = 0.024$ , respectively.

**Conclusion:** The risk of malignancy in a nodular goitre increased with TSH levels, even within the normal range. In addition to patient's gender and nodule size, serum TSH was an independent predictor for the presence of malignancy. Our study did not find TSH level to be a useful clinical adjunct in those with indeterminate FNAC.

**Abstract ID: 0929** Specific Field: **Endocrine Surgery**

**Mode of pres.: Poster Discussion**  
**ISW 2011 Session PW 09.37**

**The role of preoperative  $^{99}\text{Tc}$ -lymphoscintigraphy with SPECT/CT and intraoperative gamma-probe for identification of the sentinel lymph node in patients with papillary thyroid carcinoma**

J. Lee, K.Y. Na, J. K. Yoon, E.Y. Soh

Ajou University School of Medicine, Suwon, Korea, Republic of

**Introduction:** Occult regional lymph node(LN) metastases in papillary thyroid carcinoma(PTC) are detected in 57–85% and are associated with increased tumor recurrence. However, the management of occult lymphatic disease in patients with PTC has been ongoing source of debate. In this study, we prospectively assessed the usefulness and accuracy of sentinel LN biopsy(SLNB) for detection of regional LN metastasis in patients with PTC.

**Material and Methods:** Patients with PTC who had no clinical LN involvement were prospectively enrolled. Twenty two patients underwent SLNB from August 2010 to September 2010. Patients underwent preoperative lymphoscintigraphy and SPECT/CT. With intraoperative gamma probe, the surgeons detected sentinel lymph node. Then, all patients underwent total thyroidectomy and bilateral central compartment node dissection.

**Results:**  $^{99}\text{Tc}$  lymphoscintigraphy and SPECT/CT localized SLN in 22 patients(100%) and the gamma probe identified 97 SLNs in lateral neck of 22 patients. On the distribution of SLNs, 45 SLNs were found in bilateral 97 SLNs in lateral neck of 22 patients. On the distribution of SLNs, 45 SLNs were found in bilateral level III, 34 in bilateral level IV respectively. Skip metastasis was found in one case, and lateral compartment LN metastasis in 9 cases. The sensitivity, specificity, and accuracy of SLNB for lateral compartment LN metastasis were 88.8%, 100% and 95.4% respectively.

**Conclusion:** SPECT/CT appears to improve SLN detection and anatomical localization compared to lymphoscintigraphy. SLNB in patients with PTC without gross clinical or US lymph node involvement was able to detect occult metastasis with high accuracy and may be helpful in the decision to perform lateral compartment dissection in patients with PTC.

The accuracy of sentinel LN biopsy for lateral and central LN metastasis

	Sensitivity of SLN biopsy	Specificity of SLN biopsy	Accuracy of SLN biopsy
For lateral LN metastasis	88.8%	100%	95.4%
For central LN metastasis	88.8%	100%	90.4%



**Abstract ID: 0930** Specific Field: **Endocrine Surgery**

**Mode of pres.: Poster Discussion**  
**ISW 2011 Session PW 09.38**

**Endoscopic surgical skill qualification of laparoscopic adrenalectomies: six-year experiences in Japanese society of endourology**

T. Matsuda, T. Terachi, Y. Ono, T. Miki, T. Ichikawa, T. Habuchi, S. Baba, S. Naito

ESSQ Committee of Japanese Society of Endourology, Tokyo, Japan

**Introduction:** The Japanese Society of Endourology started a nationwide surgical skill evaluation, the Endoscopic Surgical Skill Qualification (ESSQ) system to improve quality of urologic laparoscopic surgeries including adrenalectomies in 2004. The 6-year results of the ESSQ system will be presented, focusing mainly on laparoscopic adrenalectomies.

**Material and Methods:** In the ESSQ system, the surgical skills of applicants are evaluated on non-edited videos showing entire procedures of laparoscopic nephrectomy or adrenalectomy in a double-blinded fashion. From 2004 to 2009, a total of 906 urologists applied, 246 with laparoscopic adrenalectomy and the others with laparoscopic nephrectomies.

**Results:** Of 906 applicants, 564 were qualified, resulting in the pass rate of the video assessment of 62.3%. The pass rates of adrenalectomies and nephrectomies were 50.0% and 65.5%, respectively ( $P < 0.001$ ). In the disqualified videos, a variety of poor skills were pointed out by referees, including inappropriate use of hemostasis instruments, inappropriate application of clips, insufficient hemostasis, narrow surgical fields, inappropriate surgical planes, and so on. By evaluating the adrenalectomy videos carefully, injury of adrenal tumors was pointed out in 28.7% of the disqualified videos.

**Conclusion:** Surgeons' skills could be assessed using non-edited video tapes of laparoscopic procedures. In the era when pheochromocytomas and large adrenal tumors are treated laparoscopically, careful and skillful procedures are mandatory to prevent intra-operative injury of adrenal tumors.

**Abstract ID: 0931** Specific Field: **Endocrine Surgery**

**Mode of pres.: Poster Discussion**  
**ISW 2011 Session PW 09.39**

**Validation of the "Perrier" parathyroid adenoma location nomenclature**

H. Mazeh, S. J. Stoll, R. S. Sippel, H. Chen

University of Wisconsin, Madison, USA

**Introduction:** In 2009, the Perrier nomenclature was first introduced to enhance communication among surgeons and specialists regarding the location of parathyroid adenomas. The purpose of this study is to validate the utility of the nomenclature in a prospective manner at a different institution in patients undergoing minimally invasive parathyroidectomy (MIP).

**Material and Methods:** A prospective database was created from June 2010 through December 2010 evaluating 100 consecutive patients who underwent MIP. For each case, the Perrier location of the parathyroid adenoma was predicted by the attending and resident based on preoperative imaging studies. These predictions were then compared to the actual operative findings.

**Results:** The mean age of the patients was  $63 \pm 1$  years and 83% were females. The actual distribution using the Perrier nomenclature was: A (adherent to posterior thyroid capsule) 20%; B (tracheoesophageal groove) 23%; C (tracheoesophageal groove but close to clavicle) 11%; D (directly over the recurrent laryngeal nerve) 1%; E (easy to identify, inferior thyroid pole) 31%; F (fallen into thymus) 4%. Ten cases (10%) were consistent with multi-gland disease and no adenomas were located within the thyroid gland (G). The mean overall OR time was  $58 \pm 2$  min with a range of 50 min for F location and 88 min for B location ( $P = 0.4$ ). The overall predicting accuracy based on the preoperative imaging appeared significantly higher by the attendings than the residents (71% [range 25% for F location to 91% for C location] vs. 58% [range 47% for A location to 74% for B location],  $P = 0.06$ ). The accuracy of the attendings was not significantly different for the various preoperative imaging studies (MIBI 71%, MIBI + US 69%, CT 75%,  $P = 0.89$ ). In addition, the attendings' predicting accuracy was not affected by elevated PTH and calcium levels or gland weight.

**Conclusion:** The Perrier nomenclature is useful and reproducible. The most common adenoma location for our patient population was E, which is similar to previous studies. Nevertheless, there is a wide range of preoperative predicting accuracy based on the imaging studies alone.

**Abstract ID: 0932** Specific Field: **Endocrine Surgery**

**Mode of pres.: Poster Discussion**  
**ISW 2011 Session PW 09.40**

**Breast irradiation correlates with side of parathyroid adenoma**

M. L. Woll, H. Mazeh, H. Chen, R. S. Sippel

The University of Wisconsin, Madison, USA

**Introduction:** Head and neck irradiation is a known risk factor for hyperparathyroidism. It is not clear whether radiation for breast cancer, which may expose the neck to radiation, is also a risk factor for hyperparathyroidism. This study analyzes the association between the side of radiation to the chest following breast surgery and the side of parathyroid adenoma.

**Material and Methods:** We analyzed a prospective database of 1,428 consecutive patients who underwent parathyroidectomy at our institution between March 2001 and August 2010. Patients who previously underwent breast surgery were included. Patients with multi-gland disease were excluded. Patients with bilateral breast surgery were counted as having two separate procedures; one on each side. Patients who had radiation therapy following breast surgery (RadRx) were compared to those who had breast surgery without radiation (No RadRx).

**Results:** One hundred and forty three breast procedures were performed in 121 patients. Forty procedures were in the RadRx group versus 106 cases in the No RadRx group. Patients with radiation therapy were older ( $68 \pm 1.8$  vs.  $63 \pm 1.2$  years,  $P = 0.02$ ) and had higher pre-operative calcium levels ( $11.3 \pm 0.1$  vs.  $10.9 \pm 0.1$  mg/dl,  $P = 0.001$ ), however there was no significant difference in PTH levels or gland weight. Patients with radiation exposure had a significantly shorter latency period between breast and parathyroid surgeries, with a mean latency of  $8 \pm 0.9$  years (vs.  $13 \pm 1$  years,  $P = 0.002$ ). Interestingly, the side of radiation therapy was associated with the side of the parathyroid adenoma in 76% of cases compared to only 44% in those without radiation exposure ( $P = 0.0004$ ).

**Conclusion:** Similar to head and neck radiation, this study demonstrates that breast radiation correlates with parathyroid disease. Specifically, there is a strong correlation between the side of the

radiation therapy and the side of the parathyroid adenoma. Breast radiation should therefore be considered as a risk factor for the development of parathyroid adenomas.

**Abstract ID: 0933** Specific Field: **Endocrine Surgery**

**Mode of pres.: Poster Discussion**  
**ISW 2011 Session PW 09.41**

**Comparison of quality of life in patients with Graves' ophthalmopathy after surgery versus radioiodine therapy: an explorative study**

I. Hassan, S. Rahman, R. Edelmann, T. Hoeffkin

Alain Hospital, Alain, United Arab Emirates

**Introduction:** To explore differences in quality of life (QoL) after thyroidectomy for Graves' disease (GD) in contrast to radioiodine therapy (RJT) using the German version of the newly developed Graves' ophthalmopathy (GO) quality of life (GO-QOL) survey the SF12.

**Material and Methods:** A cross-sectional study comprised of 227 consecutive patients with GD—with or without GO—who received thyroidectomy between 1988 and 2007 and 278 patients treated with RJT for GD. The GO-QoL survey consists of 16 items measuring visual functioning and psychosocial consequences of changed appearance [mean scores (range, 0–100), higher score= better health], and the generic SF12 questionnaire was distributed to study participants. Comparisons were made to determine the factors influencing QoL in Graves' patients with GO received surgery or RJT.

**Results:** Completed questionnaires were received from 63 of 227 (27.7%) patients in the surgical group and 116 of 278 (41.7%) in the RJT group. At time of surgery, 44 of 63 (69.8%) had GO compared to 37 of 116 (31.9%) at time of RJT. Demographic data were similar in both groups. Before treatment, there was no significant difference in TSH ( $P = 0.879$ ) and TSHR-Ab ( $P = 0.068$ ) between both groups. The severity of GO (NOSPECS more than 3) was higher in the surgical group 40 of 44 patients vs. 20 of 37 in the RJT group ( $P = 0.001$ ). However, after treatment, the visual functioning of the GO-QOL was better in the RJT group ( $P = 0.018$ ), while the psychosocial consequences of changed appearance did not differ ( $P = 0.350$ ). The analysis of the SF12 questionnaire revealed a better physical health in the surgical group ( $P = 0.014$ ), while the mental health did not differ ( $P = 0.227$ , Mann-Whitney test). QoL did not correlate with extend of thyroidectomy or surgical morbidity (permanent, hypocalcemia rate 4.7%, 3/63; no case of permanent vocal cord palsy).

**Conclusion:** The German version of the GO-QOL survey is a disease-specific, practical tool that can be used easily to determine the QOL issues in subjects with Graves' ophthalmopathy. In addition, thyroidectomy in patients with GD and GO revealed better physical health measured by the SF12 than RJT by a low surgical morbidity. Furthermore, the QoL seems to be affected by the severity of the ophthalmopathy rather than by surgery.

**Abstract ID: 0934** Specific Field: **Endocrine Surgery**

**Mode of pres.: Poster Discussion**  
**ISW 2011 Session PW 09.42**

**Risk factors for development of hypertrophic surgical scars after thyroidectomy**

M. R. Roh [1], K. W. Chun [1], J. H. Kim [1], Y. S. Lee [1], J.Y. Sung [1], Y. H. Kim [2], H. S. Chang [1], C. S. Park [1]

[1] Yonsei University College of Medicine, Seoul, Korea, Republic of, [2] University of Pittsburgh, Pittsburgh, USA

**Introduction:** Hypertrophic surgical scars can cause significant cosmetic problems if they are readily apparent in exposed areas. The aim of this study was to investigate the risk factors influencing hypertrophic scar formation after thyroidectomy.

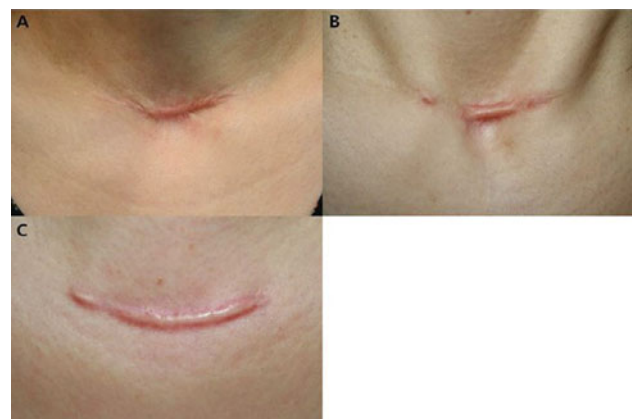**Material and Methods:** A total of 100 patients were selected from thyroidectomy patient between 2004 and 2010. The patients were divided into two groups based on type of scars (Group 1: Hypertrophic scar group [ $n = 50$ ], Group 2: Linear flat scar group [ $n = 50$ ]). All patients were followed up for more than 6 months after surgery. Data including age, sex, body mass index (BMI), skin type, tumor type, site of scar from sternal notch, scar length, site of hypertrophy, time of development of hypertrophic scar, prominence of the sternocleidomastoid (SCM) muscle, type of operation, and date of operation were collected and analyzed.

**Results:** The two groups were similar in age, sex, skin type, tumor type, and type of operation. Patients with scars located within 1 cm above the sternal notch (OR = 6.69,  $P$ -value < 0.01), prominent sternocleidomastoid (SCM) muscle (OR = 30.24,  $P$ -value < 0.01), and high body mass index (BMI) (OR = 1.40,  $P$ -value < 0.01) had increased risks for developing hypertrophic scars. Intermediate levels of sensitivity and high specificity were shown for prominent SCM muscle (sensitivity = 0.50, specificity = 0.88) and the location of the scar near the sternal notch (sensitivity = 0.58, specificity = 0.82).

**Conclusion:** Therefore, appropriate planning and choice of incision site for thyroid surgery is necessary for the prevention of hypertrophic scar formation.

Multivariate model of three predictors

	Odd Ratio [95%, C. I.]	$P$ -value
Location of scar from sternal notch <1 cm above	6.69 [1.99, 22.41]	<0.01
Prominent SCM muscle	30.24 [6.90, 132.55]	<0.01
Body mass index	1.40 [1.15, 1.71]	<0.01



**Figure** Clinical manifestations A. Scar located right over the sternal notch is predisposed to form rope-like hypertrophic scar in the middle of the sternum. B. Prominence of the SCM muscle correlate with the formation of rope-like hypertrophic scars. C. High BM

**Abstract ID: 0935** Specific Field: **Endocrine Surgery**

**Mode of pres.: Poster Discussion**  
**ISW 2011 Session PW 09.43**

**Long-term results of adrenalectomy for preclinical Cushing's syndrome**

S. Noda, T. Imai, T. Kikumori, S. Masataka, I. Ai, H. Uchida, M. Sassa, S. Satou

Nagoya University Hospital, Nagoya, Japan

**Introduction:** The indication for adrenalectomy in patients with preclinical Cushing's syndrome (PCS) has not yet been established.

**Material and Methods:** This study is a retrospective cohort analysis of patients who underwent surgery for PCS in a single institution between 1986 and 2009, to determine its effectiveness. Thirty-eight PCS patients underwent adrenalectomy, of which 25 patients replied to the questionnaire. The following data were collected: height, body weight, supplementation with glucocorticoids, postoperative hypertension and diabetes, prevalence of cardiovascular, cerebrovascular and musculoskeletal disorders, and postoperative symptoms such as skin changes, fatigue, hirsutism, and edema.

**Results:** The median age of the 25 patients was 54.5 years (range, 34–72), and 17 of 25 were women. The median follow-up was 1563 days (range 150–8550). Durations of post-operative glucocorticoid supplementation were as follows:  $\geq 1$  year in 3 cases (15%), 0.5–1 year in 5 cases (20%),  $< 0.5$  year in 7 cases (28%) and never in 10 cases (40%). No patients suffered from adrenal insufficiency or postoperative cardiovascular, cerebrovascular, musculoskeletal or critical infectious events. Of 19 patients with preoperative hypertension, postoperative improvement was demonstrated in 13 cases (63%). Of 8 patients with preoperative diabetes, postoperative improvement was demonstrated in 5 cases (62%). Postoperative improvement was observed in skin fragility (11 cases, 44%), acne (6 cases, 25%), muscle weakness (6 cases, 24%), fatigability (6 cases, 24%), hirsutism (12 cases, 48%) and edema (13 cases, 52%).

**Conclusion:** Long-term supplementation with glucocorticoids was required in some patients despite the preoperative diagnosis of PCS. Glucocorticoid hormone secreted from adrenal tumors in patients with PCS could affect comorbidities because improvements in hypertension, diabetes and other symptoms were demonstrated. Adrenalectomy for PCS may provide medical benefits, including improvement of quality of life in about a half of patients.

**Abstract ID: 0936** Specific Field: **Trauma**

**Mode of pres.: Free Paper**  
**ISW 2011 Session 18.01**

**Decreasing trend of acute respiratory distress syndrome after trauma: a population-based study in Olmstead County, Minnesota**

M. Rivera, G. Li, G. A. Wilson, O. Gajic, H. J. Schiller, M. S. Park

Mayo Clinic, Rochester, MN, USA

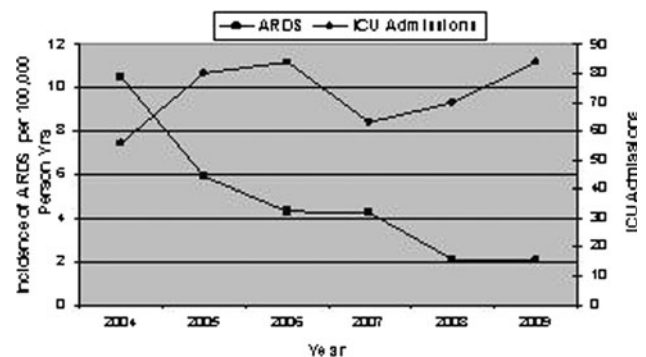
**Introduction:** Significant progress has been made in understanding the pathogenesis of ARDS. We sought to determine if there was a change in the overall incidence of acute respiratory distress syndrome (ARDS) at our Level 1 Trauma Center.

**Material and Methods:** This is a population-based cohort study with a focus on the Olmsted County trauma patients (pts) admitted to our

Trauma ICU from 2004 through 2009. The Multidisciplinary Epidemiology and Translational Research in Intensive Care (METRIC) and the Trauma Registry databases were reviewed. The definition of ARDS was based on the American-European Consensus Conference (AECC) criteria.  $\chi^2$ , Wilcoxon Rank Sum and Kruskal-Wallis tests were performed as appropriate. Data are expressed as median [IQR]; *P*-value of  $< 0.05$  was considered significant.

**Results:** During this period, we admitted 438 ICU patients from Olmsted County. The number of ICU admissions did not change but the APACHE III score increased ( $P < 0.003$ ) while the overall hospital mortality decreased ( $P < 0.001$ ) during the 6 year period. Of these pts, 40 developed ARDS after admission. The age was 57 [44–69], ICU days 11 [6–19], ISS 29 [16–36] and APACHE III score of 55 [41–73]. Thirty five percent of ARDS pts were women and the death rate was 10% (4/40). Forty four percent of pts had pulmonary contusions, 66% had chest wall trauma, and 80% had multiple injuries prior to their diagnosis of ARDS. Median time between admission and development of ARDS was 1 [0–3.75] day(s). Expectedly, the pts with ARDS had increased hospital days and ISS as compared to those without ARDS (20 [16–35] versus 6 [3–11] days,  $P < 0.001$ ) and (29 [16–36] versus 10 [9–17],  $P < 0.001$ ), respectively. The case fatality of ARDS did not change over time ( $P = 0.330$ ). However, we observed an incidence reduction of trauma-related ARDS from 10.53 to 2.05 per 100,000 person year ( $P < 0.001$ ) over the 6 year period.

**Conclusion:** Despite increased illness severity over the past 6 years, we have noted a decline in the incidence of traumarelated ARDS. This may be attributable to institution-wide changes in practice such as use of leukocyte-reduced red blood cells, male-donor specific plasma, earlier use of lung protective ventilation strategy, goal directed therapy and the availability of in-house critical care team.



**Figure** Incidence of ARDS compared to ICU admissions during 2004 to 2009

**Abstract ID: 0937** Specific Field: **Trauma**

**Mode of pres.: Free Paper**  
**ISW 2011 Session 18.02**

**Group VIB phospholipase A2 is associated with acute lung injury following trauma and hemorrhagic shock**

K. Morishita [1], J. Aiboshi [1], S. Mikami [1], Y. Yokoyama [2], T. Kobayashi [2], Y. Otomo [1]

[1] Tokyo Medical and Dental University, Bunkyo-ku, Japan,

[2] Ochanomizu University, Bunkyo-ku, Japan

**Introduction:** A variety of inflammatory mediators enter into the systemic circulation through the mesenteric lymph duct after

hemorrhagic shock, thus leading to lung injury/MODS. Recent studies reported that post-hemorrhagic shock mesenteric lymph (PHSML) contains pro-inflammatory mediators, such as cytokines, and biologically active lipids, which thus activates neutrophils/vascular endothelial cells. Our studies have already demonstrated that the PHSML contains biologically active lipids, such as lyso-phosphatidylcholine and lyso-phosphatidylethanolamine with linolic acid and arachidonic acid. We hypothesize that Group VIB phospholipase A2 (iPLA<sub>2</sub>) may be the enzyme involved in the production of these lipids. The purpose of our study was to determine the role of iPLA<sub>2</sub> in acute lung injury following trauma and hemorrhagic shock (T/HS) using (E)-6-(bromomethylene)-3-(1-naphthalenyl)-2H-tetrahydropyran-2-one (BEL), an iPLA<sub>2</sub> specific inhibitor.

**Material and Methods:** Male SD rats were anesthetized and femoral artery and jugular vein were cannulated. A midline laparotomy was performed. The blood was withdrawn via jugular vein from the T/HS group until the mean arterial pressure was reduced to 40 mmHg and maintained for 30 min. The animals were resuscitated over 2 h with shed blood and normal saline. At the end of infusion, lung injury was assessed by lung permeability (Evans Blue Dye method) and lung histology. The trauma and sham shock (T/SS) group underwent the same procedures without shock and resuscitation. Rats were randomly allocated into three groups: T/SS + dimethyl superoxide (DMSO), T/HS + DMSO, T/HS + BEL. BEL or DMSO was injected into the artery 30 min before T/HS or T/SS. The final concentration of BEL was calculated to be about 10 μM. The animals were exposed to T/HS and T/SS as described above.

**Results:** Lung permeability of T/HS with BEL ( $0.024 \pm 0.0041$  μg/g of tissue wt) was significantly decreased in comparison to that of T/HS with DMSO ( $0.044 \pm 0.014$ ;  $P < 0.01$ ). Furthermore the lung permeability of T/HS with BEL was not significantly different from that of T/SS with DMSO ( $0.019 \pm 0.014$ ). The histologic appearance of the lungs of T/HS with BEL showed no evidence of interstitial edema and an inflammatory cell infiltrate.

**Conclusion:** BEL attenuates pulmonary permeability following T/HS. iPLA<sub>2</sub> is possibly involved in the pathogenesis of acute lung injury/multiple organ dysfunction syndrome.

**Abstract ID: 0938**

Specific Field: **Trauma**

**Mode of pres.: Free Paper**  
**ISW 2011 Session 18.03**

#### **Mechanical ventilation causes more lung damage than haemorrhagic shock**

K. J. P. van Wessel, M. Heeres, M. P. Hennis, T. J. Blokhuis, L. Koenderman, L. P. H. Leenen

University Medical Centre Utrecht, Utrecht, Netherlands

**Introduction:** Haemorrhagic shock is common in trauma patients and is associated with a systemic inflammatory response. This is signified by primed polymorphonuclear leukocytes (PMN). Trauma patients often require mechanical ventilation that can cause additional pulmonary and systemic inflammation. The aim of this study was to evaluate a possible synergistic effect of positive pressure ventilation (PPV) and haemorrhagic shock on the development of inflammation in rats.

**Material and Methods:** Twenty-one male Sprague-Dawley rats were randomised for shock with or without PPV. Twelve rats underwent haemorrhagic shock. Six of them were ventilated (PEEP 5 cm H<sub>2</sub>O, Pressure Controlled + 20 cm H<sub>2</sub>O, FiO<sub>2</sub> 0.33) and the other six were only sedated with isoflurane with spontaneous respiration. Six rats were ventilated without shock. Three rats were used as controls. Rats

were terminated after 5 hours. The number of PMNs in blood and broncho-alveolar lavage fluid (BALF) and lung myeloperoxidase (MPO) were determined. Interleukin-6 (IL-6) was measured in both plasma and BALF. Results are expressed as means + SEM,  $P < 0.05$  = statistically significant.

**Results:** Blood samples of all groups showed no statistically significant differences in absolute PMN numbers. Ventilation alone caused significantly more PMNs in BALF ( $1.2 + 0.5 \times 10^6$  cells/ml) than controls ( $0 \times 10^6$  cells/ml,  $P = 0.01$ ) or shock alone ( $0.26 + 0.2 \times 10^6$  cells/ml,  $P = 0.008$ ). BALF of ventilated/shocked rats showed significantly more PMNs ( $0.54 + 0.2 \times 10^6$  cells/ml, than shock alone ( $P = 0.02$ ), but no significant effect was found for the additional shock ( $P = 0.58$ ). MPO analysis demonstrated a significant increase in ventilated and ventilated/shocked rats compared to control rats ( $11.44 + 1.2$  and  $11.90 + 2.2$  vs.  $1.31 + 0.4$ ,  $P = 0.02$  and  $P = 0.01$  respectively). MPO in shocked rats was not significantly different to controls ( $4.64 + 2.3$  units/gram lung tissue,  $P = 0.29$ ). Blood IL-6 levels showed no differences between groups. BALF IL-6 was significantly higher in ventilated, and ventilated/shocked rats compared to controls ( $350 + 135$  and  $273 + 83$  pg/ml vs.  $3 + 3$ ). Shocked rats showed no difference in BALF IL-6 compared to controls ( $83 + 57$  vs.  $3 + 3$  pg/ml,  $P = 0.13$ ).

**Conclusion:** Our data show that PPV (alone or in combination with shock) is the determining factor in the induction of the inflammatory response. The results show the importance of local damage for development of systemic inflammation.

**Abstract ID: 0939**

Specific Field: **Trauma**

**Mode of pres.: Free Paper**  
**ISW 2011 Session 18.04**

#### **Management of the mangled upper extremity: an analysis of the National Trauma Databank**

C. de Mestral, B. Haas, A. B. Nathens

Keenan Research Centre in the Li Ka Shing Knowledge Institute of St Michael's Hospital, University of Toronto, Toronto, Canada

**Introduction:** The management of a severe extremity injury (mangled extremity) is complex. The surgeon must consider a patient's medical history, social context, global injury pattern and degree of limb injury. In contrast to the lower mangled extremity, literature on mangled upper extremities is limited to case series. Through an analysis of the National Trauma Databank (NTDB), the largest aggregation of United States trauma registry data, our primary objective was to characterize the management of the mangled upper extremity and identify factors associated with primary amputation, as compared to the intention of limb salvage.

**Material and Methods:** We used a retrospective cohort design. We included adults with a mangled upper extremity treated at a level 1 or 2 trauma center over 2007–2009. A mangled extremity was identified based on diagnoses codes for (1) severe crush injury to the upper extremity or, (2) a combination of selected injuries from at least 3 of 4 injury categories: bone, soft tissue, blood vessel, nerve. Patients who died or were transferred in the first 24 hours were excluded.

**Results:** We identified 1,337 patients with a mangled upper extremity from 140 centers. The cohort was predominantly male with an average age of  $40 \pm 15$  and mean ISS of  $11 \pm 7.60\%$  of patients had commercial insurance. Injury from machinery (35%) and motor vehicle crashes (28%) were the most common mechanisms of injury. 1,277 (96%) patients had procedure codes available in NTDB. 59 patients (4.6%) underwent primary amputation. Adjusting for age, comorbidity count, insurance status, ISS, mechanism and shock, an



increased odds of undergoing primary amputation was associated with older age (1.27, 1.07–1.50), higher ISS (1.70, 1.34–2.15), and shock in the emergency department (ED) (7.11, 2.93–17.25).

Of the 1,218 patients managed with the intention of limb salvage, 16 (1.3%) had amputation later in their hospital course. As compared to patients with successful limb salvage, patients requiring secondary amputation were more severely injured (mean ISS 14 vs. 11,  $P = 0.04$ ) and more frequently had 2 or more comorbidities (31% vs. 8%,  $P = 0.01$ ).

**Conclusion:** Our study of a large cohort of patients with a mangled upper extremity shows a primary amputation rate lower than previous reports, and that most limbs are successfully salvaged. Primary amputation was associated with increasing age, greater overall injury severity and shock in the ED.

**Abstract ID: 0940**

Specific Field: **Trauma**

**Mode of pres.: Free Paper**  
**ISW 2011 Session 18.05**

#### Vascular reconstruction in lower extremity trauma

T. U. Cohnert [1], S. Koter [1], S. Schweiger [2], J. Fruhmann [1], A. Baumann [1]

[1] Department of Vascular Surgery, Graz Medical University, Graz, Austria, [2] Graz Medical University, Austria

**Introduction:** In vascular surgical practice the total of operations for treatment of traumatic lesions is rare with 0.3 to 4%. Nevertheless there is a considerable risk of limb loss or death in complex trauma including vessel injuries. Immediate diagnosis and therapy are vital. Aim of this study was to analyze outcome in vascular surgical revascularization in extremity trauma.

**Material and Methods:** Between 1.1.2003 and 30.11.2010 a total of 69 vascular surgical operations were performed in trauma patients (pts). Prospectively collected data were analyzed retrospectively.

**Results:** In 9 pts (9/69=13.0%) surgery was necessary for vascular lesions in the body trunk, in 14 pts (14/69=20.3%) in the head and neck area, in 23 pts (23/69=33.3%) in the upper extremity and in 24 pts (24/69=34.8%) in the lower extremity. Three pts died 1–8 days postoperatively (mortality 3/69=4.3%). Reconstructions for trauma in the lower extremity were performed in 5 pts above the knee and in 19 pts in the genicular or infragenicular region. In 19 pts with distal vascular reconstruction there were 5 women and 14 men with a mean age 41.8 + 19.7 years (range 15 to 78 years). Reconstruction was due to penetrating trauma in 8 pts and in 11 pts after non-penetrating trauma because of ischemia of the distal extremity. A 39 y.o. man died on postoperative day 1 due to multi organ failure (mortality in lower extremity trauma 4.2% (1/24 pts)). In 4 pts a major amputation (1 exarticulation at knee level, 3 amputations above knee). In 2 pts amputation was performed early post revascularisation (day 5 and day 20 postop) and in 2 pts after an interval of 4 and 5 months because of deep infections with osteomyelitis. Limb salvage rate is 78.9% (15/19 extremities).

**Conclusion:** Optimal interdisciplinary cooperation and emergency revascularisation by an experienced vascular surgeon can help to prevent amputation in extremity trauma. Especially in polytraumatized patients the decision for or against vascular reconstruction is important depending on the patients condition and the extent of injuries. In some patients primary amputation may be the safe treatment approach to save the patients life.

**Abstract ID: 0941**

Specific Field: **Trauma**

**Mode of pres.: Free Paper**  
**ISW 2011 Session 18.06**

#### Comparing patterns of significant trauma from skiing and snowboarding: use of epidemiological data to help develop “smarter” boards and skis

A. Haider, C. Villegas, E. Schneider, E. Haut, K. Stevens, A. Chi, A. Rushing, D. Efron

Johns Hopkins School of Medicine, Baltimore, USA

**Introduction:** Information on patterns and biomechanics of injuries have been used to help develop injury prevention initiatives. Objective of this study is to compare discrete injury patterns between skiing and snowboarding to inform the creation of safer equipment and training programs to decrease the incidence of severe injuries

**Material and Methods:** Retrospective, comparative review of ski (E885.3) and snowboard (E885.4) injuries in the US National Trauma Data Bank 2002–2008. Severe injuries by anatomic region were defined by an Abbreviated Injury Score 3. Multiple logistic regression was used to determine the odds of a severe injury in each body region among snowboarders compared to skiers after controlling for age, gender, insurance status, and ethnicity. Secondary outcomes of mortality, Intensive Care Unit (ICU) admission, and ventilator need were also compared. Cluster analysis and multiple imputation were employed to prevent biased results.

**Results:** There were 5,495 snowboard and 5,115 ski injuries. Mortality was equally low for both sports (<1%), and no differences were found in adjusted odds of mortality, ICU admission, or placement on a ventilator. Both sports also demonstrated similar rates of severe head and spine injuries. However skiers were 3 times more likely to suffer a severe lower extremity injury while snowboarders were twice as likely to suffer a severe abdominal or upper extremity injury. Upon adjusted analyses, snowboarders had a 1.68 increased odds (95% CI 1.22–2.30) of an abdominal injury and were 140% more likely to have an upper extremity injury [Odds Ratio= 2.41(1.47–3.95)] compared to skiers. Snowboarders were 63% less likely to have a lower extremity injury [OR= 0.37 (0.26–0.55)].

**Conclusion:** Snowboarders are at a significantly elevated risk of upper extremity and abdominal injuries while skiers are at an increased risk of severe lower extremity injuries. These differential injury patterns emphasize the need for developing sport-specific, injury prevention interventions.

#### Comparison of Severe Injuries (AIS >3) by Anatomic Region

	Skiers	Snowboarders	P value
Body region	$n = 5,115$ (%)	$n = 5,495$ (%)	
Abdomen	95 (1.9)	232 (4.2)*	$P < 0.01$
Upper extremity	78 (1.5)	212 (3.9)*	$P < 0.01$
Head	218 (4.3)	233 (4.2)	No difference
Spine	146 (2.9)	162 (3.0)	No difference
Lower extremity	528 (10.3)	223 (4.1)*	$P < 0.01$

**Abstract ID: 0942**

Specific Field: **Trauma**

**Mode of pres.: Free Paper**  
**ISW 2011 Session 18.07**

**Combined brain tomography and adjunct lodox/statscan facilitate early detection of commonly overlooked injuries in traumatic brain injuries patients**

C.Y. Fu [1], S. C. Wu [2], R. J. Chen [1]

[1] Taipei Medical University, Wan Fang Hospital, Taipei, Taiwan,  
 [2] China Medical University, Taichung, Taiwan

**Introduction:** Brain computed tomography(CT) has become a standard diagnostic tool to examine traumatic brain injury(TBI) patients. However, the evaluation of torso or extremity injuries has been ineffective. We attempted to establish a diagnostic modality to systematically evaluate TBI patients without missed injuries.

**Material and Methods:** The initially unconscious patients received this diagnostic modality(both brain CT and Lodox/Statscan for TBI and torso/extremities injuries evaluation) between January 2008 and December 2008 were enrolled. The accuracy in detecting torso or extremity injuries were analyzed by comparing the initial diagnosis(by Lodox/Statscan) to the final diagnosis(after two weeks of follow-up).

**Results:** In all 604 enrolled patients, 309 (51.2%) patients were evaluated by this diagnostic modality. Thirteen (4.2%) patients (three rib fracture, four T-L spine fractures and six extremity fractures) had missed injuries. All patients with missed torso injuries could be managed conservatively without further treatment or complications. The accuracy in diagnosing long bone fractures was fair (sensitivity: 100% and specificity:100%).

**Conclusion:** Combined brain CT and adjunct Lodox/Statscan can provide benefit to survey injuries in initially unconscious patients. The Lodox/Statscan can reduce the usage of further torso CT scan, emits a very low dose of radiation and appears to be a relatively inexpensive adjunct to screen torso or extremity injuries in TBI patients.

Injuries at various body sites diagnosed and missed by the Lodox/Statscan and the addition treatment

	Number of injuries by LX/Brain CT screening	Final diagnosis (after 2 weeks follow-up)	Sensitivity	Missed injuries	Additional treatment
Torso injuries(N)	45 (14.6%)	52 (16.8%)	81.8%		
Chest	18	21	85.7%	Ribs fractures(3)	Observation(3)
Pelvis	6	6	100%		
T-L spines	15	19	78.9%	Transverse process fracture (1), Compression fracture (3)	Bed rest and observation (3)
/Two parts of the torso	6	6	100%		
Extremity unjuries (N)	58(18.8%)	64(20.7%)	90.6%		
Long bone fracture	46	46	100%		

**Table** continued

	Number of injuries by LX/Brain CT screening	Final diagnosis (after 2 weeks follow-up)	Sensitivity	Missed injuries	Additional treatment
Distal bone fracture	12	18	75%	Metacarpal fracture (3), Metatarsal fracture (3), Patellar fracture (1)	Surgical fixation (3), Splint immobilization (4)

**Abstract ID: 0943**

Specific Field: **Trauma**

**Mode of pres.: Free Paper**  
**ISW 2011 Session 18.08**

**Continuos noninvasive hemoglobin monitor from pulse OX in critically ill trauma patients**

B. A. Joseph, R. S. Friese, N. Kulvatunyou, T. O’Keeffe, A. Tang, J. Wynne, R. Latifi, P. Rhee

University of Arizona, Tucson, USA

**Introduction:** Advancement in technology has allowed for continuous non-invasive hemoglobin monitoring (SpHb). Monitoring changes in hemoglobin level are important in trauma patients and invasive hemoglobin (Ihb) is one of the most commonly ordered laboratory measurements. The use of SpHB may enable earlier detection of bleeding and more efficient surgical and/or blood transfusion management. The use of SpHB has not been described in the trauma population. The purpose of this study was to evaluate the accuracy of a SpHB measurement device in severely injured trauma patients.

**Material and Methods:** We performed a prospective cohort analysis of severely injured trauma patients admitted to the ICU at our level I trauma center over 6 month period (Dec 09 to May 2010). Serial Ihb levels and SpHB for the first 72 hours were measured. Each SpHb measurement was matched with a corresponding Ihb and Spearman Correlation coefficient plot was calculated. We defined normal Hgb as >8 mg/dl and low Hgb <8. Data was than grouped based on Hgb level. Sensitivity, specificity, positive predictive value, negative predictive value and accuracy were calculated.

**Results:** 23 trauma patients with 89 data pairs were reviewed. Eighty-Six percent of the patients were male with a mean age of 32 and a mean ISS of 21.1 ± 14. Ihb had a range of 7.2–16.9 and SpHB had a range of 3.3–15.2. Average mean and difference of Ihb and SpHB was 10.7 and 1, respectively. On average during monitor application SpHB did not record data points 13.5% of the time. Spearman Correlation Plot revealed a Correlation R = 0.670 (P < 0.001). After dichotomization with Hgb > 8, SpHB was found to have a Sensitivity of 91%, PPV 96%, Specificity 40%, NPV 20%, and an accuracy of 88%.

**Conclusion:** Continuous non-invasive hemoglobin monitoring in injured patients does not appear to represent serum hemoglobin. Correlation was poor when corresponded with invasive hemoglobin. While the SpHB may not give accurate values as previously reported in normal individuals, we were able to identify utility for this non-invasive tool when Hgb was dichotomized into normal or low levels.

**Abstract ID: 0944**Specific Field: **Trauma****Mode of pres.: Prize Session FP**  
**ISW 2011 Session 56.01****Geriatric trauma service: one year data and lessons learned**C. Mitchell, M. S. Truitt, V. Shifflette, M. Lorenzo, A. Goel,  
M. Lyons, E. Dunn

Methodist Hospital, Dallas, USA

**Introduction:** Trauma centers are treating increasing numbers of elderly trauma patients due to the aging population. Many studies have demonstrated the physiologic differences between older trauma patients compared to younger trauma patients. These differences, in concert with medical co-morbidities, make caring for this population challenging. To meet these challenges, we created a geriatric trauma service specifically designed to take a more aggressive, multidisciplinary approach to the care of the geriatric trauma patient.

**Material and Methods:** We created a geriatric trauma service at our urban trauma center. We opened a specialty unit, dubbed the G-60 unit, for admission in August 2009. Inclusion criteria included all trauma patients older than the age of 60 with a traumatic injury within the previous 48 hours that warranted hospital admission. Data was abstracted from our G-60 unit from August 2009 to July 2010. We compared this data to a similar patient population (control group) from January 2008 to December 2008. Variables such as average emergency department (ED) length of stay (LOS), average ED to operating room (OR) time, average intensive care unit (ICU) LOS, average hospital LOS, urinary tract infections (UTI), and respiratory failure (RF) were analyzed.

**Results:** Our registry yielded 673 patients for the study time period. The G-60 group contained 393 patients, while the control group had 280 patients. Injury severity scores and age were similar between groups (10 v 11,  $P > 0.05$ , 77 v 75  $P > 0.05$ ). Statistically significant decreases were seen among the following categories: ED LOS (4.2 v 6.1 hours,  $P < 0.05$ ); ED to OR time (37.6 v 52.9 hours,  $P < 0.05$ ); ICU LOS (3 v 5.2 days,  $P < 0.05$ ); hospital LOS (4.8 v 7 days,  $P < 0.05$ ); UTI (6 v 11,  $P < 0.05$ ); and RF (5 v 19,  $P < 0.05$ ). Mortality rates decreased from 5.7% to 3.8% over the study time period but this did not reach statistical significance ( $P = 0.2$ ).

**Conclusion:** Our one year data, we believe to be the first of its kind, demonstrates a geriatric trauma unit that addresses the specific needs of elderly trauma patients can lead to a more streamlined hospital stay, a significant reduction in morbidity, and a trend towards decreased mortality.

**Abstract ID: 0945**Specific Field: **Trauma****Mode of pres.: Prize Session FP**  
**ISW 2011 Session 56.02****Dose response relation between injury severity and systemic inflammation in burn patients**K. M. Groeneveld, L. Koenderman, G. I. J. M. Beerthuisen,  
M. K. Nieuwenhuis, L. P. H. Leenen

UMC Utrecht, Utrecht, Netherlands

**Introduction:** Our research group previously showed that a decrease of the expression of fMLP induced active Fc $\gamma$ RII on neutrophils in peripheral blood correlated to the development of late inflammatory complications after trauma. However heterogeneity in type and location of injuries obscures the exact relationship between tissue damage and the inflammatory response to the injury.

**Hypothesis:** There is a dose response relationship between the injury severity and the amount of systemic inflammation.

**Material and Methods:** We are performing a pilot study in thirty consecutively admitted adult patients in the Burns centre of the Martini Hospital (<12 hours after injury). Injury severity is assessed as percentage of total body surface area (TBSA) burned. Neutrophil activation, measured by flowcytometry, is used as a read-out for systemic inflammation.

**Results:** Preliminary results show there is an inverse relation between the amount of injury and the expression of fMLP induced active Fc $\gamma$ RII. In addition, with increasing percentage of TBSA, the percentage of both hypersegmented and progenitor neutrophils increases up to sixty percent.

**Conclusion:** With increasing severity of tissue damage, there is a marked rise in the amount of dysfunctional neutrophils and subsets of this cell type. These refractory cells can cause susceptibility to infections. Age, co morbidity and genetics also influence this relationship.

**Abstract ID: 0946**Specific Field: **Trauma****Mode of pres.: Prize Session FP**  
**ISW 2011 Session 56.03****A self-designated trauma center can reduce mortality and expenditures in the absence of an established trauma system: an institutional experience in Taiwan**

R. J. Chen

Taipei Medical University-Wan Fang Hospital, Taipei City, Taiwan

**Introduction:** Studies have demonstrated that severely injured patients have lower mortality rates and shorter hospital stays when directly treated at a trauma center. This study is aimed at understanding the effectiveness of a self-designated trauma center in the absence of a trauma system.

**Material and Methods:** Using a hospital trauma registry and insurance claims data from a tertiary care academic institute located in central Taiwan, data from fiscal years 2005 and 2006 (FY 05 and 06) were identified, corresponding to the initiation and integration of the trauma center, respectively. In-hospital mortality rates, admission expenditures, and lengths of stays between the two periods were used to assess the effectiveness of the trauma center. Trauma and Injury Severity Score (TRISS) analysis with adjustment was used to evaluate the institutional trauma care quality.

**Results:** During a two-year period, 4,613 injured patients who were admitted to China Medical University Hospital were enrolled in the study. As compared with FY 05, data from FY 06 revealed an increase in the number of admissions, indirect transfers, and major trauma patients by 15.4%, 38.3%, and 256.9%, respectively. Patients with minor, severe, and very severe injuries had a reduction in mortality from FY 05 to FY 06 of 33.3%, 74.5%, and 15.3%, respectively; only the difference in the severe injuries group (Injury Severity Score (ISS) =16–24) was significant (11.4% versus 2.9%,  $P < 0.001$ ). The admission expenditures of FY 06 were reduced in the above three injury groups by 8.0%, 18.5%, and 13.0%, respectively, and were significant in the minor and severe injury groups. TRISS analysis with National Trauma Data Bank 5.0 adjustment showed the Z and W scores to be -1.47 and -0.5 in FY 05, and -2.17 and -0.6 in FY 06, respectively.

**Conclusion:** This study demonstrated that a self-designated trauma center could reduce the mortality rate and admission expenditures in patients with severe injuries. In the absence of an established trauma system, a self-designated trauma center could still provide cost-effective trauma care, and the improvement was initiated from the group of patients with an ISS between 16 and 24.

**Abstract ID: 0947**Specific Field: **Trauma****Mode of pres.: Prize Session FP**  
**ISW 2011 Session 56.04****Long-term pre-clinical evaluation of the intracorporeal use of advanced local hemostatics in a damage control swine model of grade IV liver injury**K. Inaba, B. Branco, P. Rhee, B. Putty, G. Barmparas, D. Demetriades  
University of Southern California, University of Arizona, USA**Introduction:** Advanced local hemostatic agents are effective adjuncts to standard intracavitary damage control packing. The purpose of this study was to evaluate the long-term efficacy and safety of kaolin and chitosan based hemostatic agents for hemorrhage control in a 14-day survival damage control swine model of grade IV liver injury.**Material and Methods:** Anesthetized pigs (40 kg) underwent a 35% total blood volume bleed, cooling to 35° C and injury with a standardized 10 × 3 cm liver avulsion. The animals were randomized to gauze control (GC, *n* = 9), Celox™ (CX, *n* = 11), QuikClot® Combat Gauze (QC CG, *n* = 9) or Celox™ Gauze (CXG, *n* = 9) packing. At 15 min the packs were removed to calculate shed blood followed by damage control closure. At 48 hs, the animals underwent pack removal and definitive closure. At the 14 day sacrifice liver edge, kidney, heart, lung and adjacent small bowel were sampled for histopathology.**Results:** Uncontrolled bleeding at 2 min demonstrated internal consistency of the injury (GC: 3.2 ± 0.7, CX: 3.3 ± 0.6, QC CG: 3.4 ± 0.8, CXG: 3.3 ± 0.6 ml/Kg, *P* = 0.81) was consistent. Blood loss at 15 min was significantly lower in the CX and QC CG arms (GC: 11.0 ± 1.3, CX: 5.6 ± 0.9, QC CG: 5.5 ± 0.8, CXG: 9.1 ± 1.0 ml/Kg, *P* = 0.001). Survival at 48 hs was 55.6% (5) for GC, 72.7% (8) for CX, 55.6% (5) for QC CG and 42.9% (3) for CXG (*P* = 0.633). Survival at 14 days was 42.9% (3) for GC, 63.6% (7) for CX, 44.4% (4) for QC CG and 42.9% (3) for CXG (*P* = 0.754). 3 deaths in the CX arm and 1 in the QC CG were due to bowel obstruction; the remainder to blood loss. Histopathology in one CX animal demonstrated eosinophilic material in the coronaries consistent with emboli of granules.**Conclusion:** Celox™ and QuikClot® Combat Gauze are effective adjuncts to standard intra-cavitary damage control packing for the control of bleeding. However, Celox™ in particular, was associated with the development of intra-abdominal adhesions and small bowel obstruction. Distant emboli of granules was also noted. Further research is warranted.**Abstract ID: 0948**Specific Field: **Trauma****Mode of pres.: Prize Session FP**  
**ISW 2011 Session 56.05****Tomographic finding does not always predict the outcome and necessity of angioembolization in blunt renal injury**

Y. C. Huang, C.Y. Fu, C. H. Hsieh

China Medical University Hospital, Taichung, Taiwan

**Introduction:** Most patients with blunt renal injury (BRI) could be managed nonoperatively with advance of diagnostic (CT scan) and interventional radiology (angioembolization). However, there was discrepancy between the findings of CT scan and angiography. We tried to delineate the outcome and complications of management of BRI patients based on the CT scan finding.**Material and Methods:** From January 2005 to September 2009, BRI patients received NOM were enrolled. The angiography would be performed in patient with contrast extravasation (CE) seen on CT scan, then the angioembolization was performed in CE on angiography. On the other hand, patients without CE were treated conservatively. The outcome and complications of these patients were described.**Results:** A total of 70 BRI patients were enrolled. The patient distribution and associated complications were listed in the table. There were 28.6% (6/21) patients with negative angiography while CE was noted on CT scan. In patients without CE on CT scan, the delayed hemorrhage occurred in two patients (2/49, 4.1%) during the period of observation. The post-embolization hemorrhage occurred in five patients (33.3%) who received angioembolization. The overall complication rate of NOM for BRI is 17.1% (12/70).**Conclusion:** Although CT scan is important to evaluate the patients with BRI. In current study, tomographic finding doesn't always predict the outcome and necessity of angioembolization in BRI. There are still complications in NOM despite the avoidance of celiotomy. The close observation and follow-up are suggested in the NOM of BRI.

Table

Patient with BRI ( <i>N</i> = 70)	Complications
CE (+) on CT scan ( <i>N</i> = 21)	
CE (+) on angiography?	Post-embolization hemorrhage
embolization hemorlization	( <i>N</i> = 5, 33.3%) Abscess
( <i>N</i> = 15, 71.4%)	formation ( <i>N</i> = 2, 13.3%)
CE (–) on angiography?	Delayed hemorrhage
observation ( <i>N</i> = 6, 28.6%)	( <i>N</i> = 1, 16.7%)
CE (–) on CT scan? observation	Delayed hemorrhage
( <i>N</i> = 49)	( <i>N</i> = 2, 4.1%) Abscess
	formation ( <i>N</i> = 1, 2.1%)
	Symptomatic hematoma
	( <i>N</i> = 1, 2.1%)

**Abstract ID: 0949**Specific Field: **Trauma****Mode of pres.: Prize Session FP**  
**ISW 2011 Session 56.06****Risks of postoperative mortality and complications among surgical patients with dialysis: a population-based study**

C.-C. Liao, T. L. Chen

Department of Anesthesiology, Taipei Medical University Hospital, Taipei, Taiwan

**Introduction:** Patients with dialysis have an increased risk of complications. Few studies investigated the postoperative mortality among surgical patients with dialysis. The objective of this study is to investigate the risk of postoperative mortality and complications among surgical patients with dialysis (including hemodialysis and peritoneal dialysis).**Material and Methods:** This study is a population-based cross-sectional study conducted in Taiwan. We used data obtained from the Taiwan National Health Insurance program to identify 14558 surgical



patients with dialysis during the period 2004–2007 and 58232 controls without dialysis were randomly selected with frequency matching by age and sex. The 30-day postoperative mortality and complications including pneumonia, postoperative bleeding, septicemia, and stroke were evaluated.

**Results:** Surgical patients with dialysis had higher rates of 30-day mortality and complications compared with controls. After adjustment, patients with dialysis were at higher risks of postoperative 30-day mortality (odds ratio [OR] = 2.29, 95% confidence interval [CI] = 1.90–2.76), pneumonia (OR = 1.44, 95% CI = 1.26–1.64), postoperative bleeding (OR = 1.14, 95% CI = 1.02–1.28), septicemia (OR = 2.03, 95% CI = 1.83–2.26), and stroke (OR = 1.43, 95% CI = 1.25–1.64) compared with controls.

Further analysis showed that the adjusted ORs of postoperative 30-day mortality for surgical patients with hemodialysis or peritoneal dialysis were 2.09 (95% CI = 1.59–2.74) and 2.38 (95% CI = 1.95–2.91), respectively.

**Conclusion:** Surgical patients with hemodialysis or peritoneal dialysis had higher risks of postoperative complications and at least twice the odds of 30-day mortality than surgical patients without dialysis.

#### Abstract ID: 0950

Specific Field: **Trauma**

Mode of pres.: **Free Paper**  
ISW 2011 Session 77.01

#### Effect of introduction of ER to OR rapid transfer sequence on times and mortality: a triumph of cooperation

M. Wullschleger, M. Handy, K. Grant, C. Pollard, M. Muller  
Royal Brisbane & Women's Hospital, Brisbane, Australia

**Introduction:** The early management of critically ill trauma patients, such as non-responding hypotension and hemorrhagic shock, is crucial for their outcome. We recognized that delays frequently occurred moving these critical patients from the emergency room (ER) to the operating room (OR) and that the reasons were multifactorial. Our Trauma Service facilitated an interdepartmental approach and creation of the Rapid Transfer Sequence from ER to OR—our version of the Los Angeles County Hospital 'Red Blanket'. The sequence was practiced by simulation and then a written procedure formulated. This study reports our early results and experiences.

**Material and Methods:** Critically ill trauma patients with ISS >16 and a systolic blood pressure <90 mmHg failing to respond to initial fluid resuscitation and requiring damage control surgery were included. From January 2006 to October 2007 (pre-implementation period) data were retrospectively collected from the Queensland Trauma Registry and patient charts. From November 2007 to February 2010 prospective data collection was performed. The times from arrival in ER to arrival in OR as well as the patient outcome were analyzed using Mann-Whitney test.

**Results:** In the pre-implementation group, 12 patients (8 male/4 female; mean age 49.8 years; mean ISS 37.3) met the inclusion criteria. After the implementation 19 patients (11 m/8 f; mean age 34.9 years; mean ISS 40.2) were included. The post-implementation group showed a statistically significantly shorter transfer time to theatre ( $19 \pm 11$  min (mean/SD);  $P < 0.005$ ) compared to the pre-implementation group ( $206 \pm 140$  min). The mortality rate was 25% for the patients prior to protocol implementation and 42% afterwards ( $P = 0.22$ ), while the mean length of hospital stay was 34 days versus 31 days, respectively.

**Conclusion:** This study shows the successful implementation of this Rapid Transfer Sequence protocol with a 10fold decrease in ER-OR times. The discrepancy in mortality needs to be investigated further. Confounding variables are the faster transfer from scene plus en-route

interventions introduced by ambulance medical officers during the study. Also, there is uncertainty regarding the number of ER deaths during the pre-implementation period.

ER to OR times can be improved by cooperation, but do we just delay the inevitable?

#### Abstract ID: 0951

Specific Field: **Trauma**

Mode of pres.: **Free Paper**  
ISW 2011 Session 77.02

#### Single training session for first time pelvic C-clamp users: what to expect% 3F

H. Koller [1], S. Uranues [1], Z. J. Balogh [2]

[1] Medical University of Graz, Graz, Austria, [2] University of Newcastle, Newcastle, Australia

**Introduction:** Unstable pelvic fractures with associated haemodynamic instability are major contributors of mortality and morbidity after blunt trauma. The Pelvic C-Clamp is favored by many authors for the initial stabilization of the pelvic ring. The application of this device is taught on courses, still it is seldom used. The safety and efficiency of C-clamp application by trained first time users is unknown. We hypothesised that the pelvic C-clamp cannot be safely and efficiently positioned on a training model after one training session.

**Material and Methods:** The Pelvic Trainer™ was used for the accuracy and time of pelvic C-clamp application. The standard posterior pin placement was taught and practiced with a study population of 27 participants with different levels of experience. A theoretical and a practical session were held before the actual study ( $11.2 \pm 4.4$  days).

**Results:** 20 (70.4%) of all participants were able to place both pins inside the safe area, while 81.5% of all pins were positioned safe. The average distance to the optimal target was  $9.15 \pm 7.86$  cm. The time needed for assembly was  $99.7 \pm 39.7$  s, for placement it averaged at  $133.9 \pm 74$  s.

**Conclusion:** After one training session the pelvic C-clamp can be rapidly applied on a training manikin with over 80% safely positioned pins. The risks associated with the 20% suboptimal pin positioning even in controlled environment within 2 weeks of training require careful assessment in view of the potential benefits of the C-clamp.

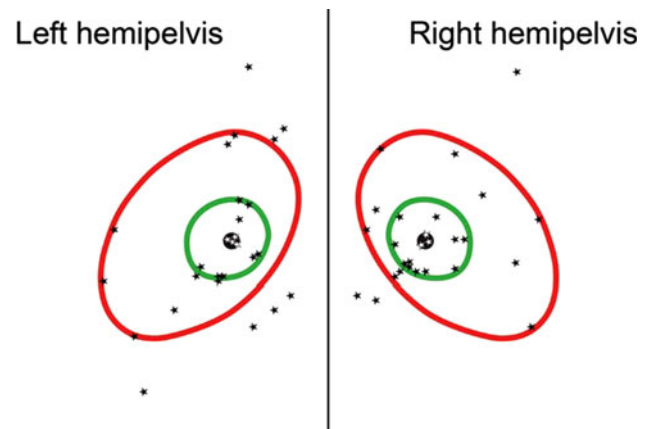


Figure Bulls-eye

**Abstract ID: 0952**Specific Field: **Trauma****Mode of pres.: Free Paper**  
**ISW 2011 Session 77.03****The elimination of whole blood intervention improves blood utilization in a Middle East trauma center**

R. Peralta Rosario [1], R. Seliem [2]

[1] Hamad General Hospital, Doha, Qatar,

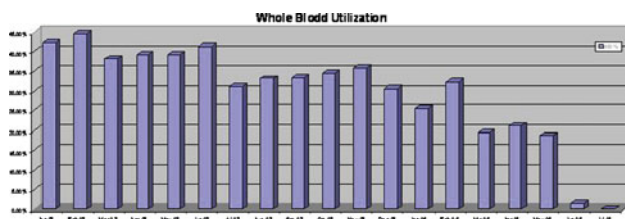
[2] Rashid Hospital &amp; Rashid Hospital Trauma Center, Dubai, United Arab Emirates

**Introduction:** Uncontrolled hemorrhage is the main cause of mortality in severe acute injured patients. Dubai is a relative new metropolis with multiple cultures merging from different backgrounds. There also is an impressive construction activity in recent years, resulting in an explosive, exponential increase in the incidence of major trauma admissions. This increase makes optimization of blood products inventory a priority hospital-wide risk management program. The optimization of blood products was further complicated by a unique characteristic of medicine in Dubai in that the Thalassemia Center utilized a largely disproportional 50–60% of the city's blood inventory. Aim: The main purpose of our study was to compare the use of whole blood (WB) in a tertiary trauma center pre and post a multidisciplinary quality improvement whole blood utilization elimination intervention. The goal was to decrease the use of whole blood in the trauma center.

**Material and Methods:** A prospective study to evaluate blood products utilization was conducted at the Dubai Rashid Hospital Trauma Center (RHTC), a major trauma center in the Middle East. Hospital blood utilization data was analyzed pre and post intervention, and comparison of 2007 and 2008 data was performed. The intervention consisted of implementing a multidisciplinary quality improvement project to optimize blood utilization in the hospital and address the demand for blood products in trauma patients, thus in turn improving our standard of medical practice.

**Results:** A complete elimination of WB utilization was achieved in July 2008 at the RHTC, in comparison with an average of 240 units of WB usage per month (40% of hospital blood utilization) in 2007. In transfusing a whole blood unit, frequently patients received unnecessary old blood components. These components such as platelet concentrates, fresh frozen plasma, and cryoprecipitate were wasted in the majority of the cases at our institution.

**Conclusion:** The elimination of WB utilization program, a major multidisciplinary quality improvement project clearly has optimized blood products delivery and utilization at the RHTC, bringing the practice up to the international standards and more importantly adapting our clinical service delivery to our unique local and regional medical needs.



**Figure:** Results: elimination of Whole blood utilization at The Rashid Trauma Center

**Abstract ID: 0953**Specific Field: **Trauma****Mode of pres.: Free Paper**  
**ISW 2011 Session 77.04****Constructing a low budget trauma registry for developing countries**

H. Zafar, S. N. Zafar, M. A. Moosa, A. Jawwad

Aga Khan University, Karachi, Pakistan

**Introduction:** Trauma registries are an essential component of modern trauma care. However, most developing country institutions do not maintain such registries. The main obstacle is of expertise and financial resources. We share our experience of developing and maintaining a low cost trauma registry

**Material and Methods:** Our institution has previously used the DOS based CDC hospital trauma registry v3. We used this experience to address the shortcomings and construct our own trauma database specific for the needs of a developing country using Microsoft Access. The structure was based on the previous software. Previously missing variables and categories were replaced with data items more relevant to Pakistan. Additional variables were added after reviewing the literature and user manuals of functioning international databases. The database was tested by entering data prospectively from current patients and retrospectively from medical records. Modifications were made accordingly. A recent medical graduate was hired and trained to enter data and maintain this database

**Results:** The database interface was easily constructed using built in help features and online resources. Entry fields included patient demographic information, incident characteristics, injury characteristics including ICD 9 codes, the barrel matrix and checkboxes that help in identifying groups of patients based on special injury types (for example bomb blast victims), relevant clinical information, transfer information, injury severity information, procedure related information with codes and outcomes including complications, length of stay and disposition. ICD 9 codes were added as easy to use drop down menus. Built in formulas calculated the revised trauma score. Data items for AIS codes and injury severity score were made available and calculated by switching to the previous software. For data entry purposes the database proved to be easy to use and user friendly. As the software was constructed by the authors there was no cost of developing the registry. The cost of maintaining and updating the registry which includes the salary of the medical graduate, amounts to only \$2200 (USD) per year

**Conclusion:** Using readily available software and minimal resources it is possible to construct and maintain a trauma registry in a developing country on a low budget. This model is useful for institutions in developing countries to initiate and maintain trauma registries

**Abstract ID: 0954**Specific Field: **Trauma****Mode of pres.: Free Paper**  
**ISW 2011 Session 77.05****Review of key performance indicators in acute surgery: have we made an impact?**

M. Devaud, L. Hsee, I. Civil

Auckland City Hospital, Auckland, New Zealand

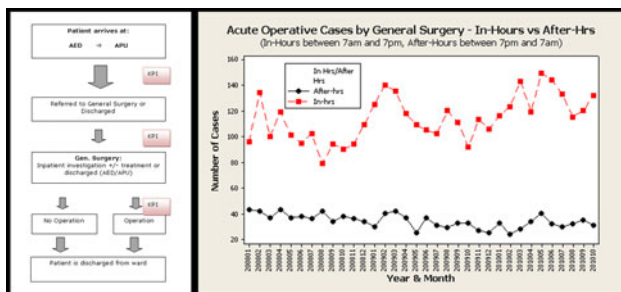
**Introduction:** Lack of timely access to acute surgery is a growing problem worldwide. Auckland City Hospital (ACH) is one of the largest metropolitan public hospitals in NZ where >60% of surgical admissions fit into this category. In January 2009, an Acute Surgical Unit (ASU) was set up to improve the acute surgical flow.

Key Performance Indicators (KPI) are valuable tools in evaluating the ASU service performance. Our aim is to describe the current acute patient pathway, present the early trend of KPI's for ASU & determine whether an impact has been made on acute surgical patients.

**Material and Methods:** A retrospective review of patients admitted with acute general surgical conditions from January 2008(pre-ASU) to October 2010 was performed. The current adopted Acute Surgical Pathway is described in Figure. Patient data was identified through hospital electronic records. KPIs assessed included: 1) Time to assess referred patients from Emergency Department (ED) & GP in Assessment and Planning Unit (APU), 2) Pre-operative length of stay (LOS[PO]) 3) Length of Stay of non-admitted patients (LOS[NA]), and 4) Case volume in hours vs. after hours before and after ASU was set up. Statistical analysis was performed with Anderson-Darling Normality test.

**Results:** Results show a reduction of mean request time to assessment from 2.28 hours to 1.6 hours ( $P < 0.005$ ). Patients are seen in APU earlier from 2 hours to 1.76 hours ( $P = NS$ ). The LOS[NA] has decreased from 15.23 hours to 9.48 hours ( $P < 0.005$ ). The LOS[PO] has not changed significantly for all procedure types (34.58 vs. 34.88 hours). There are encouraging signs in high volume procedures eg appendectomy. The mean LOS[PO] for appendectomy was 7.81 hours but is now 6.53 hours ( $P < 0.005$ ). The graph below (Figure) suggests that since ASU, the number of cases operated on 'in hours' is increasing with a corresponding decrease in 'out of hours' operating.

**Conclusion:** Our KPIs demonstrate an early positive trend of facilitating the acute patient flow. There is minimal difference between pre and post ASU LOS[PO]. The causes are likely multi-factorial, including: increased case volume displacing minor cases of lesser urgency, lack of operating staff & shortage of hospital beds in winter months. This study supports the utility of ASU in facilitating patient flow in a NZ metropolitan public hospital.



**Figure:** Acute patient pathway

**Abstract ID: 0955**

**Specific Field: Trauma**

**Mode of pres.: Free Paper**  
**ISW 2011 Session 77.06**

#### Improving care of the injured in the Asia-Pacific region

R. L. Gruen [1], M. Joshipura [2], H. T. Stelfox [3], W. Chadbunchachai [4], R. Ellawala [5], T. S. Nguyen [6], G. O'Reilly [7]

[1] National Trauma Research Institute, Melbourne, Australia, [2] Academy of Traumatology, Ahmedabad, India, [3] Foothills Medical Centre, Calgary, Canada, [4] Kohn Kaen Hospital, Kohn Kaen, Thailand, [5] College of Surgeons, Colombo, Sri Lanka, [6] Duc Giang Hospital, Hanoi, Viet Nam, [7] The Alfred, Melbourne, Australia

**Introduction:** Over 90% of injury-related deaths occur in low and middle-income countries (LMICs). Integrated trauma systems have lowered mortality in many high-income countries, and quality improvement (QI) programs have been used to strengthen these systems and improve care. The World Health Organization (WHO) and IATSIIC launched Guidelines for Trauma Quality Improvement Programs at International Surgical Week in 2009. The Guidelines focus on optimal use of morbidity and mortality (M&M) meetings, preventable death panel reviews and registry-based data analyses. We aimed to explore opportunities to improve trauma QI activities in the Asia-Pacific region.

**Material and Methods:** An Asia-Pacific Trauma Quality Improvement Seminar was held in Melbourne in November 2010. Participants selected had demonstrated leadership in trauma care in their own institutions or the region, identified through their work with WHO, IATSIIC or the National Trauma Research Institute and The Alfred Trauma Service. Participants summarized their existing trauma QI resources, their perceived gaps and barriers to QI, and they proposed strategies for improving QI activities. Discussions were facilitated and recorded, with immediate feedback of main points and subsequent thematic analysis.

**Results:** 31 participants representing 9 countries attended. 65% were surgeons and 35% emergency physicians. 62% had previous QI experience. Current trauma QI activities varied between countries and trauma centres within countries, but included M&M conferences (56%), monitoring complications (31%), preventable death studies (25%), audit filters (19%) and statistical methods for analyzing morbidity and mortality (6%). Identified QI needs included reliable and valid injury data, establishment of integrated trauma QI programs, and policies for establishing and enforcing minimum quality of care standards. Barriers to trauma QI highlighted by the group included limited resources, lack of leadership and decentralized organization of injury care. Participants proposed establishing a regional trauma QI network to facilitate training and dissemination of QI methodologies, injury data management, promotion of cultures of quality and advocacy for quality trauma care.

**Conclusion:** Opportunities exist to improve and expand existing trauma QI activities in the Asia Pacific region. A regional trauma QI network may be an effective tool to support local and regional activities to improve the care of injured patients.

**Abstract ID: 0956**

**Specific Field: Trauma**

**Mode of pres.: Free Paper**  
**ISW 2011 Session 77.07**

#### The liberal use of whole body CT scan for trauma patient is not necessary: a single centre experience

H.Y. Lo, T. S. Go, L. T. Teo, V. Appasamy, M. T. Chiu

Tan Tock Seng Hospital/Singapore Armed Forces, Singapore

**Introduction:** The benefits of Whole body CT (WBCT) for evaluating trauma patients include faster diagnosis, fewer missed injuries and mortality benefits. Critics of WBCT cite radiation exposure, erosion of doctors' acumen and rising healthcare cost as pitfalls. We set out to study the outcome differences between WBCT and Organ Specific CT (OSCT) at a major trauma centre in Singapore.

**Material and Methods:** We adopt a targeted CT scan protocol for trauma. Patients are triaged at the A&E-unstable ones are sent to the OT without scans. Stable ones get OSCT or WBCT depending on the resus team's assessment. Patients admitted from Jan 08 to Dec 09 were selected from our trauma registry. Inclusion criteria—multi-trauma patients admitted to the General Surgery Department who had

OSCT or WBCT. Those with isolated head or purely ortho injuries were excluded.

**Results:** 266 patients (mean ISS 19.3) were included—54 WBCT and 212 OSCT. The mean probability of survival (TRISS) for OSCT is 95.3%, actual survival—97.2% (206/212). The mean TRISS for WBCT is 77.7%, actual survival—81.5% (44/54). The survival is poorer for WBCT ( $P < 0.001$ ) due to a selection bias as the patients are more severely injured - ISS 29.3 (WBCT) vs. 16.8 (OSCT). After adjusting for TRISS, the survival rate is still poorer for WBCT (OR 0.34) but it is not statistically significant,  $P = 0.121$ . Of 212 OSCT, 38 needed additional CT to complete the work up—30 of these were within 24 hours of the first scan. 12 had either missed injuries or needed a change in management based on the new scan findings. Most were small pneumothoraces which could have been managed conservatively.

**Conclusion:** Unlike the German study (Lancet 2009), we did not find a survival benefit for WBCT. After adjusting for TRISS, WBCT patients still had a poorer survival (OR 0.34) but  $P = 0.121$ . This may be due to the small sample size. However, 38 (17.9%) OSCT required additional CT to complete their work up. This translated into unnecessary patient transfer. These patients might have been better off getting WBCT during the first trip to radiology. Our centre does not recommend the liberal use of WBCT for trauma. This is because the mortality advantage for WBCT is still not validated. Even though OSCT patients may need additional scans subsequently, we deem it to be an acceptable inconvenience as it does not worsen the treatment outcome.

combination of HE, FF and IMN. The model has a potential to investigate secondary organ damage caused by medical interventions in blunt polytrauma.

Physiological and histological parameters (mean  $\pm$  SEM)

	Mean arterial pressure (in shock/after shock/after RE, mmHg)	Base excess (in shock/after shock/after RE, mmol/l)	Histology for lung (Range 0 (normal) to 21 (severe tissue damage))	Fat embolism (%)	Histology for intestine park score
Group 1 (sham)	56	4	4	0	1.2
Group 2 (FF + IMN) 48	1	8	25	1.1	
Group 3 (HS) 30	-11	6	0	3.5	
Group 4 (HS + FF) 30	-10	9	0	3.6	
Group 5 (HS + FF + 32 IMN)	-10	8	50	4.1	

**Abstract ID: 0957**

**Specific Field: Trauma**

**Mode of pres.: Free Paper**  
**ISW 2011 Session 77.08**

#### Blunt polytrauma model with femur fracture

O. Yoshino [1], R. Matthys [2], Z. Balogh [1]

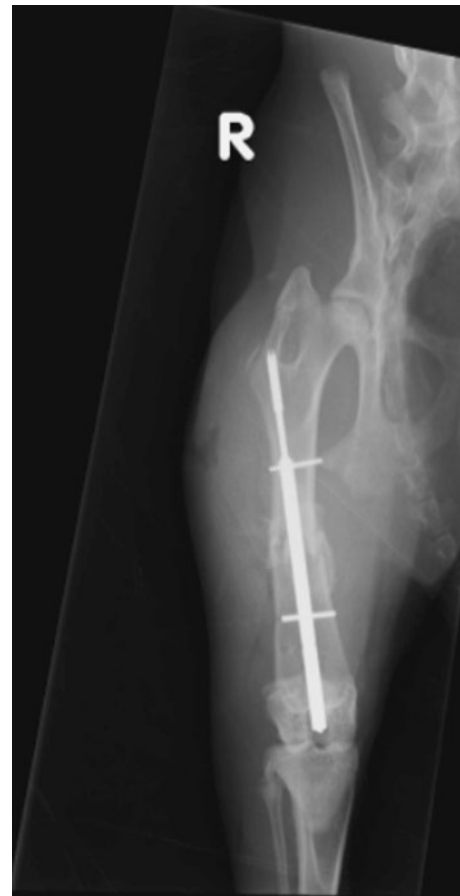[1] John Hunter Hospital/University of Newcastle, Newcastle, Australia, [2] AO Development, Davos, Switzerland

**Introduction:** Femur fracture is one of the major injuries in polytrauma. Its management in polytrauma is controversial due to potential risk of secondary organ damage. The aim was to develop a blunt trauma model to investigate the effects of femur fracture and its fixation on the physiology and histology.

**Material and Methods:** Intramedullary nail was specifically developed for the femur of rabbit (Rabbit Nail®). NZ rabbits were used ( $N = 6$  in each group). Group 1, served as sham without hemorrhagic shock (HS) or closed femur fracture (FF), Group 2 FF and fracture fixation with intramedullary nailing (IMN), Group 3 HS only (MAP ~ 30 mmHg/60 min), Group 4 & 5 had HS and FF without & with IMN, respectively. Resuscitation (RE) was conducted by the combination of crystalloid and shed blood. After 6 hours, the tissues were harvested. t-test and ANOVA used.

**Results:** All fractures (type B or C, AO classification) were stabilized with Rabbit Nail®. Groups 3, 4 and 5 were exposed to severe HS. While RE was successful in Group 3 & 5, Group 4 remained acidotic with severely damaged organs. In Group 5, the most severe fat embolism and intestinal damages were observed. Although observed intestinal damage in Group 2 was less than Group 5, the levels of lung damage were similar. Observed histological damage in the lung of Group 3 was less than that of other experimental groups.

**Conclusion:** The early timing of IMN led to the successful RE although the organs were damaged. It appeared that FF and IMN was independently harmful enough to damage lung. Moreover, the accumulated damage of the lung and intestine could be caused by the



Definitive fixation with intramedullary nail (Rabbit Nail)



**Abstract ID: 0958**Specific Field: **Trauma****Mode of pres.: Poster Discussion**  
**ISW 2011 Session PW 08.01****Prognosis of laparotomy for trauma in Japan**R. Yamaguchi, T. Fujita, T. Sakamoto, M. Kitamura, Y. Uchida  
Teikyo University Hospital, Itabashi Tokyo, Japan

**Introduction:** Laparotomy for trauma is intended to prevent physiological breakdown. The main procedure is intended to decrease hemorrhage, and/or to provide peritoneal lavage or drainage, based on a prompt decision made by the surgical team. Time-consuming procedures such as the repair or reconstruction of organs is often contraindication in such patients. Such laparotomies, regarded as simple procedures among gastroenterological surgeries, tend to be underestimated as a surgeon's experience, especially according to the specialist certification system. Patients undergoing a laparotomy for trauma often have high morbidity and mortality rates and difficulties in terms of perioperative management. We studied the frequency of laparotomy for trauma, patient survival, and whether there are difference between the probability of survival and actual survival.

**Material and Methods:** A total of 29,563 cases were registered in the Japan Trauma Data Bank (JTDB) from 2004–2008. Of these, 898 (3%) patients underwent an open laparotomy. A probability of survival could be calculated based on the Trauma Score-Injury Severity Score (TRISS) for 657 of these patients, who were selected for analysis in this study. The Wilcoxon signed-rank test was used for verification of the probability of survival and the actual survival calculated from the TRISS.

**Results:** A total of 488 (74%) of the patients were males, and 169 (26%) were females. Their mean age and injury severity score (ISS) were  $47.2 \pm 20.3$  (age range 2–90),  $23.9 \pm 16.2$  (point range 1–75). The actual discharged survival was  $72.1 \pm 0.449\%$ , while the probability of survival was  $74.6 \pm 0.336\%$  (range 0–99.6). The actual survival was significantly lower than the probability of survival.

**Conclusion:** Cases of laparotomy for trauma presented relatively low rates of probable and actual survival. Our present study revealed that the actual survival of patients in our country was significantly lower than that of the Major Trauma Outcome Study in the 1980's. Laparotomy for trauma should be properly evaluated based on its high level of difficulty, and it may be necessary to reconsider the methods used for on and off-the-job training for the trauma surgery and the treatment approach, and to provide better surgical education.

**Abstract ID: 0959**Specific Field: **Trauma****Mode of pres.: Poster Discussion**  
**ISW 2011 Session PW 08.02****Non-operative management of blunt splenic trauma in adults: a systematic review**I. N. Jayatilleke, G. D. Eslick, M. R. Cox  
Nepean Hospital, Sydney, Australia

**Introduction:** Over the last few decades there has been a paradigm shift in surgical care of splenic injuries following blunt abdominal trauma, from splenectomy to non-operative management (NOM). This is due to both the recognition of splenic function and overwhelming post splenectomy infection, and successful NOM of splenic injuries in the paediatric age group. Despite the widespread adoption of NOM, there is no clear consensus within the literature regarding

the predictive factors for failure of NOM (FNOM). The aim of this study was to systematically review the evidence regarding blunt splenic trauma in the adult population.

**Material and Methods:** A systematic literature review was conducted using MEDLINE, EMBASE, PubMed, and Current Contents database (1950–2010) of all studies that evaluated the non-operative management of blunt splenic trauma in adults. All languages were included.

**Results:** A total of 44 studies were identified, with sample sizes ranging from 12 to 4103 patients. The mean age was 36 years, with 65% males. 68% of studies originated from North America, 9% Europe, 14% Asia and 9% Australasia. 50% were identified as originating from Level 1 trauma centres. Patients were categorized as operative 38.4%, non-operative 58.8%, failed non-operative 10.3%, and interventional angiography 26.2%. Operative patients when compared to non-operative patients had a higher ISS score (29.9 vs. 19.1,  $P < 0.001$ ), tachycardia (113 vs. 99,  $P = 0.03$ ), required greater packed red blood cells (6.3 vs. 1.6,  $P < 0.001$ ), a longer ICU stay (7.9 vs. 4.2 days,  $P = 0.003$ ), longer total stay (16 vs. 11.3,  $P = 0.004$ ) and had a higher mortality (17.7% vs. 5.0%,  $P < 0.001$ ). Only 4.6% of Grade 1 splenic injuries were managed operatively compared to 23% of Grade 5 injuries. In contrast, there was a linear trend for failed non-operative injuries (grade 1: 1.7% vs. grade 5: 18.8%).

**Conclusion:** The results support the current practice of non-operative management of blunt splenic trauma. However, data is sparse regarding both short and long term morbidity and follow-up. There is a lack of data regarding the failed non-operative management and non-operative management among angiography groups, as well as biochemical and clinical data. We conclude that there is a definite need for prospectively gathered modern data concerning the predictive factors for failure of non-operative management of blunt splenic trauma.

**Abstract ID: 0960**Specific Field: **Trauma****Mode of pres.: Poster Discussion**  
**ISW 2011 Session PW 08.03****Essential surgical skills simulators**

H. Gill, T. Razek

McGill University, Montreal, Canada

**Introduction:** It is estimated that surgical diseases represent 11.2% of the global burden of disease. Lack of access to surgical interventions is a major problem in low and middle income countries (LMIC). Across Africa there is 1 surgeon for 250 000 people, and that drops to 1 for 2.5 million in rural areas. Training personnel in basic surgical skills is a critical public health issue. In high income countries (HIC), there has been significant research into the advantages of simulator based training as a means of promoting surgical competency. This knowledge led to the creation of a curriculum based on a series of low cost, low tech, universally applicable surgical training simulators.

**Material and Methods:** Based on a concept of train the trainer, the Canadian Network for International Surgery (CNIS) has created multiple standardized courses centered on the diffusion of essential surgical and obstetric skills through the use of basic low tech, low cost simulators. We describe these simulators in this article. Initially volunteer surgeons from Canada teach a 3 day workshop where they train clinicians how to build and use the models, as well as teach the course curriculums. Once certified, the trainers then put on a 5 day workshop where they teach basic surgical skills to medical students, nurses, and other health officers using interactive lectures and skills based curriculums using the low cost simulators. The models are constructed using universally available low cost materials.

**Results:** The CNIS essential surgical workshops began in 1996. Since that time they have been incorporated into the curricula of 12 medical

schools in 8 African nations. Nearly 14 000 health care professionals have been trained in the basic surgical principles on these simple, cost effective simulators. The feedback from trainers and students has been overwhelming and the durability of the educational framework has been demonstrated

**Conclusion:** As the surgical training in HICs shifts to a proficiency based system with objective metrics, surgical simulation will become increasingly important. In LMICs where there are not enough surgeons to train the future generation, a collection of low cost, easy to create and universally applicable simulators will be invaluable. These simulators have been used successfully in over 8 countries to train thousands of health professionals. The next step will be to properly and objectively validate them as useful academic tools.

**Abstract ID: 0961**

Specific Field: **Trauma**

**Mode of pres.: Poster Discussion**  
**ISW 2011 Session PW 08.04**

**Predictive value of contrast extravasation on contrast enhanced computed tomographic (CT) scans in trauma victims with pelvic fractures**

A. K. Jain, J. P. Boland, J. A. DeLuca, A. Modak, V. Sorrell

Charleston Area Medical Center, West Virginia University, Charleston, West Virginia, USA

**Introduction:** Due to a strong association with multiple injuries and >50% mortality, pelvic fracture related hemorrhage remains a diagnostic challenge. Contrast Extravasation (CE) is seen in 5–10% of patients with pelvic fractures and carries a recommendation of mandatory angiography. Review of literature fails to reveal a strong data in favor of this recommendation. This study reviews our experience with the patients with pelvic trauma who subsequently underwent a pelvic angiogram.

**Material and Methods:** Study was conducted at Charleston Area Medical Center, a Level I trauma center. Retrospective chart review was done for pelvic fracture patients undergoing angiogram between January 2005 to October 2009.

Information abstracted included demographics, mechanism, vitals at arrival, Injury Severity Score, radiologic and angiographic findings and indications. Patients were divided into groups based on the need for angiography and on the results of angiogram. Continuous variables were compared by using Two sample t-test. Patients with positive and negative angiogram were compared using Chi-square/Fisher's exact test. Statistical analysis was done using SAS 9.2.

**Results:** 34 (3.9%) out of 869 pelvic fracture patients underwent angiogram with no intra-operative mortalities. 41% angiograms were negative and did not require embolization. Demographic and clinical characteristics of the two groups are discussed in detail. Positive and negative predictive values of the blush on CT scan were 63% and 47% respectively with an overall accuracy of only 53%.

**Conclusion:** A blush on CT scan of fractured pelvis correlates with a therapeutic embolization in only about 50% of the patients. A recommendation of mandatory angiography for all patients with a pelvic blush carries with it a potential for unacceptably high number of unnecessary procedures in critically ill patients. There is a need for larger multi-center prospective studies to better define the significance of a finding of blush in a patient with pelvic fracture.

Characteristics based on need of angiogram

	No angiogram (n = 835)	Angiogram (n = 34)	P-value
Age	48	43	0.30

**Table** continued

	No angiogram (n = 835)	Angiogram (n = 34)	P-value
Glasgow Coma Scale	9	20	0.0001
Injury Severity Score	16	32	<0.0001
Pulse	93	107	0.0003
Systolic blood pressure	134	113	< 0.0001

**Abstract ID: 0962**

Specific Field: **Trauma**

**Mode of pres.: Poster Discussion**  
**ISW 2011 Session PW 08.05**

**Exploring disparities in access to trauma care: the discrepancy between potential and realized access**

D. Gomez [1], C. de Mestral [1], B. Haas [1], B. Zagorski [2], J. Ray [1], G. Rubinfeld [3], B. A. McLellan [3], A. B. Nathens [1]

[1] Keenan Research Centre in the Li Ka Shing Knowledge Institute of St Michael's Hospital, University of Toronto, Toronto, Canada,

[2] Institute for Clinical Evaluative Sciences, Toronto, Canada,

[3] Sunnybrook Health Sciences Centre, University of Toronto, Toronto, Canada

**Introduction:** Mortality is lower and functional outcomes superior among severely injured patients who receive care in a trauma centre (TC). Unfortunately, a significant proportion of such patients never receive TC care. It is unclear whether impeded access is due to geographic factors or other barriers to TC care. Our objective was to evaluate the discrepancy between the availability of trauma services (potential access) and their utilization (realized access).

**Material and Methods:** This is a population-based retrospective cohort study of severely injured adult patients surviving to reach hospital in Ontario, Canada (2002–2009). Access to care was evaluated using geographic information system network-based spatial analysis and data sources that capture all emergency department visits and hospital admissions. Access was defined as direct transport to a TC or successful transfer to a TC after initial evaluation at a non-trauma centre. Predictors of TC access at the patient and county level were evaluated.

**Results:** Approximately 83% of Ontarians reside within 1 hour of a TC. Of the 23,835 severely injured patients identified across 49 counties, only 38% were transported directly from the scene of injury to a TC and 19% reached a TC through inter-facility transfer. Overall, only 57% (n = 13,551) of severely injured patients had access to TC care. There was marked variability in access across counties with a range of 16–94% (median 50%, IQR 40–64%). Patients residing in a county with a TC had greater access (83%) than residents of counties without (47%). Female sex, advanced age, and comorbidities were significantly associated with reduced access. After adjusting for patient level factors, we identified 15 counties with above average access and 11 counties with below average access.

**Conclusion:** While prior studies have identified potential access to TC care, we have used a novel approach to identify discrepancies between realized and potential access to care. The gap between realized and potential access to care is a key metric to assess disparities in access at the patient or regional level.

**Abstract ID: 0963**Specific Field: **Trauma****Mode of pres.: Poster Discussion**  
**ISW 2011 Session PW 08.06****Variability in the classification of early trauma center deaths: a significant challenge for trauma quality improvement programs**

B. Haas [1], S. Goble [2], D. Gomez [1], C. De Mestral [1], S. Sharma [1], M. Neal [2], A. B. Nathens [1]

[1] University of Toronto, Toronto, Canada, [2] NationalTrauma Databank, Chicago, USA

**Introduction:** Comparisons of risk-adjusted mortality across institutions are important tools in trauma quality improvement, and are the cornerstone of the Trauma Quality Improvement Project (TQIP) of the American College of Surgeons. The consistent definition of patient outcomes across centers is essential to ensure unbiased comparisons. In particular, patients who are dead on arrival (DOA) are typically excluded from mortality comparisons. Incorrectly classifying patients as DOA would result in a lower risk-adjusted mortality at the center level. Our objective was to identify whether variability exists in the classification of patients as DOA across centers.

**Material and Methods:** Data were derived from the National Trauma Databank version 10. Level 1 and level 2 centers were included. Patient-level inclusion criteria were based on TQIP criteria: age  $\geq 16$ , ISS  $\geq 9$  and blunt or penetrating mechanism of injury. NTDB criteria specify that patients who are DOA are those that arrive to hospital with no signs of life and undergo minimal or no resuscitation attempt. Patients who receive any significant resuscitation attempt, even if they die within 15 minutes of arrival, should not be considered DOA. We examined the characteristics of DOA patients at each center in order to estimate whether this NTDB definition was consistently applied.

**Results:** Inclusion criteria identified 169,891 patients across 266 facilities. Overall, 7% of patients died ( $n = 11,936$ ), of whom 5% ( $n = 562$ ) were identified as DOA. 170 centers did not report any DOA. Among centers reporting any DOAs, the median proportion of deaths classified as DOA was 11.1% (IQR 5.3%–18.5%). However, centers classified as few as 1.3% and as many as 80.0% of all deaths as DOAs. 17% ( $n = 16$ ) of centers that reported DOA reported that 100% of deaths that occurred in the ED were DOA. At individual centers, the median time to death for DOAs ranged from 0 to 160 min. 7% ( $n = 36$ ) of DOA patients had time to death  $>30$  min.

**Conclusion:** The characteristics of DOA patients in NTDB vary significantly across centers, and appear to be inconsistent with NTDB definitions. Discrepancies in classification of DOAs across centers likely have significant implications for external benchmarking programs. Increased consistency in identifying DOAs is essential to ensure validity of comparisons of trauma center performance.

**Abstract ID: 0964**Specific Field: **Trauma****Mode of pres.: Poster Discussion**  
**ISW 2011 Session PW 08.07****Are there better survival prediction models than the TRISS for Asian blunt trauma victims?**

A. Kimura [1], S. Nakahara [2], W. Chadbunchachai [3]

[1] National Center for Global Health and Medicine, Tokyo, Japan, [2] St. Marianna University School of Medicine, Kawasaki City, Japan, [3] Khon Kaen Regional Hospital, Khon Kaen, Thailand

**Introduction:** To identify logistic regression models with better survival prediction for blunt trauma (BT) victims in Japan and Thailand, and to demonstrate the possibility of probability of survival (Ps) estimation without the respiratory rate (RR) on admission, which is often missing or unreliable in Asian countries.

**Material and Methods:** Data of 14,376 BT patients registered in the Japan Trauma Data Bank (JTDB, 2007–2009) were used. BT patients injured in Khon Kaen District between January 2005 and December 2008 ( $n = 6409$ ) were also extracted from the Khon Kaen Hospital Trauma Registry. For logistic regression analyses, injury severity score (ISS), age in years (AY), Glasgow coma scale score (GCS), systolic blood pressure (BP), respiratory rate (RR), and their coded values (c) were used as explanatory variables, as well as Revised Trauma Score (RTS) Parameters were estimated by the method of maximum likelihood estimation, and Akaike's information criterion (AIC), area under the receiver-operating characteristic curve (AUROC) and accuracy were used for model comparison; a model having the lower AIC is considered better.

**Results:** The logistic regression model with ISS, AY, and the coded values of SBP, GCS, and RR demonstrated the lowest AIC (Table). AIC of the model without information of respiratory rate was lower than that of TRISS method model. There was no large difference in AUROCs and accuracies among the models.

**Conclusion:** For better prediction of Ps, the real number of age in years should be used as an explanatory variable instead of the categorical data of age in the TRISS Method. The logistic regression model with ISS, AY, and the coded values of SBP, GCS, and RR is the best estimate for prediction. Information about respiratory rate seems to be unimportant for survival prediction in blunt trauma victims in Asian countries.

Akaike

	AIC (Japan)	AIC (Khon Kaen)
ISS, RTS, cAY	4372	1120
ISS, RTS, AY	4305	1109
ISS, AY, cBP, cGCS, cRR	4305	1105
ISS, AY, cBP, cGCS	4347	1105

**Abstract ID: 0965**Specific Field: **Trauma****Mode of pres.: Poster Discussion**  
**ISW 2011 Session PW 08.08****Calcaneal x-rays: should they be done routinely in fall from height (FFH) patients?**

S. R. Motilall [1], M. S. Moeng [2], M. C. Tsai [1], J. Goosen [1], K. D. Boffard [2]

[1] University of Witwatersrand, Johannesburg, South Africa, [2] University of Witwatersrand, South Africa

**Introduction:** FFH is associated with increased incidence of fracture calcaneus. Our protocol supports liberal use of radiological investigations in order to avoid missed fractures, especially in patients with clinical suspicion of a calcaneal fracture, altered level of consciousness and associated local tissue injury. The aim of this study was to

assess the yield of calcaneal radiological investigation in patients with a fall >2 m.

**Material and Methods:** A retrospective analysis of prospectively collected data between January 2005 to September 2008. All patients who fulfilled the criteria were classified as priority one patients and were resuscitated according to the unit protocol. Data were collected from patient records and from the Trauma Bank at Charlotte Maxeke Hospital Trauma Unit. Analysed data included age, sex, ISS, NISS, GCS, height fallen, calcaneal x-ray findings and outcomes. All data collected was submitted for statistical analysis

**Results:** 466 FFH patients were identified. There were 369 male and 97 females. The mean age was 26 years. Median height fallen was 8.5 m. Two hundred and forty one (51.7%) patients were assessed clinically and found not to have any evidence of calcaneal injuries. (No calcaneal x-rays were done). The remaining 225(48.3%) had calcaneal x-rays according to the unit protocol (Table). Calcaneal fractures were confirmed in 37(16.4%) of the 225. In patients with GCS <13 the yield of positive radiological findings was 12.1% compared to those with GCS >13 with a yield of 18.4%. On review (tertiary survey) and follow-up no missed injuries were identified in either group. Of the 225 that were x-rayed only 37(16.4%) were positive for calcaneal fractures.

**Conclusion:** Our protocol of selective calcaneal radiological investigation was shown to be safe and safety was not affected by an altered level of consciousness. Radiological examination for possible calcaneal fracture is associated with a low yield of 1:6, and importantly is not compromised by an altered level of consciousness.

Total study population <i>n</i> (%)	Calcaneal Xray Positive	Calcaneal Xray negative	NO calcaneal Xray	
Total population	466 (100%)	37 (7.9%)	188 (40.3%)	241
%Xrayed population	225	37 (16.8%)	188 (83.6%)	N/A
Missed injuries	NIL	NIL	NIL	NIL

**Abstract ID: 0966**

Specific Field: **Trauma**

**Mode of pres.: Poster Discussion**  
**ISW 2011 Session PW 08.09**

#### The distribution of survival times after injury

D. E. Clark

Maine Medical Center, Portland, Maine, USA

**Introduction:** The distribution of survival times after injury has been described as “trimodal”, but studies from several countries have not confirmed this finding.

**Material and Methods:** We constructed frequency histograms for survival times (in minutes) recorded in the US Fatality Analysis Reporting System (FARS, for traffic crashes) and National Violent Death Reporting System (NVDRS, for homicides) for 2004–2007. We obtained prehospital times (PT) and hospital times (HT) for patients in the US National Trauma Data Bank (NTDB), who died in 2008 from traffic crashes or homicide and whose declared survival times (PT + HT) were ≤150 min. We determined the proportions of the selected NTDB patients who had been pulseless at or before

hospital admission. We theorized that the true survival time until circulatory arrest was 0 for patients pulseless at the scene of injury, PT for other patients pulseless at hospital admission, and PT + HT for the rest; we then calculated, for any declared survival time, a weighted estimate of the mean survival time until circulatory arrest. We applied such estimates to hospital deaths recorded in FARS or NVDRS to create histograms of the theoretical survival times until circulatory arrest, thus removing delays in recording time of death attributable to futile resuscitation attempts.

**Results:** FARS and NVDRS deaths were most frequent in the first few minutes. Both showed a second peak at 35–40 min after injury, corresponding to the peak in hospital deaths. A third peak was not seen. Among 4,314 NTDB cases with PT + HT ≤150 min, 1,145 (66.4%) of traffic deaths and 1,191 (74.1%) of homicide deaths had been declared Dead on Arrival or had no pulse on admission; however, their HT were 2–4 min when PT was <20 min, ranging up to HT >60 min when PT was >90 min. Assuming that distributions and delays found in NTDB were similar for FARS and NVDRS, histograms of the theoretical survival times until circulatory arrest did not show a second peak.

**Conclusion:** The frequency of deaths per unit time after injury is a monotonically decreasing function. The temporary increase seen at 35–40 min in US data is an artifact created because declaration of death in hospitals after circulatory arrest is delayed until the diagnosis is confirmed and resuscitative attempts have ceased. A third peak is not present.

**Abstract ID: 0967**

Specific Field: **Trauma**

**Mode of pres.: Poster Discussion**  
**ISW 2011 Session PW 08.10**

#### Study of serum zinc & selenium in trauma patients

V. Jain, S. Misra, A. Mishra, D. V. Amla

C. S. M. Medical University, UP, Lucknow, Lucknow, India

**Introduction:** Severe trauma & head injury are associated with numerous nutritional & metabolic alterations. Recently, interest has risen towards antioxidant and micronutrient therapy in critically ill patients including trauma. Moreover, trauma is the 4th leading cause of death in India and is predicted to be third by 2020. Trauma victims occupy 10–38% of hospital beds, needing specialized care. Nutritional therapy is an integral part of critically ill trauma patients. Zinc is required for protein synthesis & cell division with direct stimulatory effect on DNA synthesis and cell mediated immunity, while Selenium is an antioxidant to protect the tissue damage done by free radicals. A study was planned to know the association of serum Zinc & Selenium in trauma patients along with severity and outcome.

**Material and Methods:** Serum Zinc & Selenium was estimated in thirty patients of medically managed, isolated head injury patients of 2–40 years by atomic absorption spectrophotometer on Day 0, Day 5, and Day 10. Baseline levels were compared with controls.

**Results:** The study revealed that levels of Zinc & selenium were low in trauma patients. These levels further decreased by 5th day. After Ten days the levels of Zinc recovered incompletely but the serum selenium continued to have low levels. The levels were related to severity & outcome.

**Conclusion:** Zinc & Selenium are important micronutrients in trauma management. Early supplementation may improve the outcome of severely injured patients. This is ongoing study; hence definite conclusion of Interventional study will be drawn in next phase.



**Abstract ID: 0968**Specific Field: **Trauma****Mode of pres.: Poster Discussion**  
**ISW 2011 Session PW 08.11****Inter-hospital transfer for penetrating injury in Japan**

M. Kitamura, T. Fujita, R. Yanaguchi, Y. Uchida, T. Sakamoto

Teikyo University Hospital, Tokyo, Japan

**Introduction:** There is no protocol for an inter-hospital transfer in Japan. However, about fifteen percent of traumatized patients are transferred for definitive care. The purpose of this study is to determine whether the current inter-hospital transfer procedure used for penetrating injury is acceptable.

**Material and Methods:** A total of 23,631 cases of ambulance transport were registered by the Japan Trauma Data Bank (JTDB) from 2004 to 2008. Of these 648 had penetrating injuries reported in the data set of the JTDB to calculate the probability of survival (Ps) by the TRISS method. We divided patients into a direct transport group (DG,  $n = 591$ ) and an inter-hospital transferred group (IG,  $n = 57$ ) for analysis.

**Results:** The ratio of male patients ( $\pm$ SE) was 0.71 ( $\pm$ 0.02) for the DG versus 0.81 ( $\pm$ 0.05) for the IG ( $P = 0.29$ ). The mean age ( $\pm$ SE) was 47.0 ( $\pm$ 0.8) for the DG versus 45.6 ( $\pm$ 2.9) for the IG ( $P = 0.64$ ). The mean injury severity score (ISS) was 9.3 ( $\pm$ 0.3) for the DG versus 7.9 ( $\pm$ 0.9) for the IG ( $P = 0.64$ ). The mean Revised Trauma Score (RTS) was 7.12 ( $\pm$ 0.05) for the DG versus 7.59 ( $\pm$ 0.12) for the IG ( $P = 0.10$ ). The mean Ps by the TRISS method was 0.93 ( $\pm$ 0.01) in the DG and 0.96 ( $\pm$ 0.01) in the IG ( $P = 0.026$ ). The mean survival was 0.96 ( $\pm$ 0.01) in the DG and 0.98 ( $\pm$ 0.02) in the IG ( $P = 0.084$ ).

**Conclusion:** Inter-hospital transfer is not significantly contributing to an increase in survival. Ideally, all patients with penetrating injuries should be brought to the trauma center. However, about 10% of patients with penetrating injuries were transferred for definitive care in this study. Standard transfer protocol and resuscitation guidelines during transfer are needed in Japan.

	DG	IG	P value
Number of patients	$n = 591$	$n = 57$	
Age	47(	45.6	$P = 0.64$
Ratio of male patients	0.71	0.81	$P = 0.29$
Injury Severity Score	9.3	7.9	$P = 0.64$
Revised Trauma Score	7,12	7.59	$P = 0.10$
TRISS Ps	0.93	0.96	$P = 0.026$
Survival	0.96	0.98	$P = 0.084$

**Abstract ID: 0969**Specific Field: **Trauma****Mode of pres.: Poster Discussion**  
**ISW 2011 Session PW 08.12****Utilization of the motor score to guide ICP monitor placement in patients with severe traumatic brain injury: an institutional experience**

N. McQuay [1], W. S. Hoff [2], J. Cipolla [2]

[1] Johns Hopkins Bayview Medical Center, Baltimore, USA,  
[2] St. Luke's Hospital, Bethlehem, USA

**Introduction:** Guidelines for routine placement of an ICP monitor in patients with severe Traumatic Brain Injury (TBI) are based on studies with conflicting outcomes.

While the motor component of the Glasgow Coma Score (GCS) has been shown to be a good predictor of outcome, its use in the acute setting to guide management has not been recommended. We hypothesize that the index motor score can be used to identify patients with severe TBI who do not benefit from routine ICP monitor placement.

**Material and Methods:** Retrospective review of patients with a severe TBI (GCS 8) managed at a Level I Trauma Center over a 5 year period. The study cohort was divided into two groups based on the index motor score (Group I  $M < 5$ , Group II  $M \geq 5$ ). Routine ICP monitor placement occurred in Group I only. Monitor placement occurred in Group II when the motor score decreased from the index value. Standard demographics and outcome measures were compared.

**Results:** 156 pts (Group I = 143, Group II = 13) with severe TBI were identified. The most common mechanism was blunt trauma with SDH being the most common injury type. Both groups were similar in terms of age and ISS. A significantly lower mortality rate was noted in group II vs. Group I.(Table) No patients in Group II required an ICP monitor due to change in motor score.

**Conclusion:** The index motor score 5 may serve as a guide for the selective placement of an ICP monitor when managing patients with severe TBI. Although a higher index motor score was associated with improved mortality, further prospective evaluation is required.

	Group I ( $n = 143$ ); motor score <5	Group II ( $n = 13$ ); motor score $\geq 5$	P-value
Age	41 (24	35 (21.50	.83
Gender	105 male/38	10 male/3 female	1.00
GCS 3 (3	7 (7	<.0001*	
HLOS	6 (1	10 (4	.24
ILOS	3 (1	5 (2	.48
ISS	29 (22.75	29.50 (25	.75
Mortality	46.2%	7.7%	007*

**Abstract ID: 0970**Specific Field: **Trauma****Mode of pres.: Poster Discussion**  
**ISW 2011 Session PW 08.13****Whole-body computed tomography for blunt trauma in Japan**

T. Fujita, K. Nakazawa, M. Kono, Y. Uchida, T. Sakamoto

Trauma and Resuscitation Center, Teikyo University, Tokyo, Japan

**Introduction:** The use of Whole-body Computed Tomography (WBCT) for trauma has increased rapidly. Whole-body CT reduces mortality in patients with major trauma. However, there is no evidence to show the effect of WBCT during trauma evaluation in Japan. The purpose of this study was to determine whether the use of WBCT for patients with an Injury Severity Score (ISS) of over 16 is acceptable.

**Material and Methods:** This study used the data recorded in JTDB to calculate the probability of survival according to the trauma and injury severity score (TRISS) for 5528 patients with blunt trauma that underwent either whole-body or non-whole-body CT.

**Results:** One thousand five hundred and nineteen (27.5%) of the 5528 patients were evaluated by WBCT. The mean age was  $47.7 \pm 0.6$  in

the patients evaluated by WBCT versus  $48.9 \pm 0.3$  for the Non-WBCT patients ( $P = 0.074$ ). The ratio of male was 1110/1519  $73 \pm 1\%$  for WBCT versus 3095/4284  $72 \pm 1\%$  for Non-WBCT ( $P = 0.556$ ). The mean ISS was  $27.3 \pm 0.3$  for WBCT versus  $25.5 \pm 0.2$  for Non-WBCT ( $P < 0.001$ ) patients. The revised trauma score was  $6.73 \pm 0.04$  for WBCT versus  $6.73 \pm 0.02$  for Non-WBCT ( $P = 0.998$ ). The Ps as calculated by the TRISS method was  $0.785 \pm 0.007$  for WBCT versus  $0.794 \pm 0.004$  for Non-WBCT ( $P = 0.262$ ). The mean survival rate was  $0.830 \pm 0.010$  for WBCT patients versus  $0.786 \pm 0.006$  for those who did not receive WBCT ( $P < 0.001$ ). In order to avoid one death, twenty-three scans were required for survival.

**Conclusion:** The use of WBCT significantly contributed to an increase in the survival rate in this study. Whole-body CT is recommended as a standard diagnostic method during the early resuscitation phase for the patients with an ISS over 16. This is the first report that has demonstrated the effectiveness of WBCT examination with the JTDB which is a national representative trauma data base in Japan.

#### Patients' Demographic Data and Survival

Number patient	Whole-body CT of $n = 1519$	Non-whole-body CT $n = 4284$	<i>P</i> -value
Age(years)	47.7	48.9	$P = 0.074$
Men(%)	73	72	$P = 0.556$
ISS	27.3	25.5	$P < 0.001$
RTS	6.73	6.73	$P = 0.998$
Ps	0.785	0.794	$P = 0.262$
Survival	0.830	0.786	$P < 0.001$

**Abstract ID: 0971**

Specific Field: **Trauma**

**Mode of pres.: Poster Discussion**  
**ISW 2011 Session PW 08.14**

#### Creation of a trauma registry in Tanzania

H. Gill [1], T. Razek [1], L. Museru [2]

[1] McGill University, Montreal, Canada, [2] Muhimbili Orthopedic Institute, Dar es Salaam, United Republic of Tanzania

**Introduction:** Worldwide approximately 5.8 million people die annually as a result of injuries. It is estimated that within the next 10 years road traffic collisions (RTC) will be the third leading cause of death and disability adjusted life years. Awareness about the extent of this problem has lagged behind others due partly to a lack of information about the actual scope of the problem.

Reliable empirical data allows for increased awareness, increased political support, and increased resource allocation. **Material and Methods:** In 2005, Physicians at the Muhimbili Orthopedic Institute (MOI) with help from the Canadian Network of International Surgery (CNIS) created a basic trauma database. This registry collected demographic data and information on the mechanism and extent of injuries. It was originally modeled after a registry created in Kampala,

Uganda. Trained nurses and House Officers, would fill out a one page hand written questionnaire. Senior physicians with advanced training would enter the data into the database and verify follow up information. In 2009, an audit of the database proved that it was too complex to be maintained. The registry was then modified so that both input and analysis would be simpler. A preliminary review of the data from 2005 to 2006 and from November 2008–January 2009 was conducted.

**Results:** Between 2005 and 2006 4928 patients were seen and treated at MOI. 77% of patients were male and over 70% were between the ages of 15–44. The most common cause of injury was road traffic collisions (RTC) followed by falls and assault. From Nov 2008–Jan 2009 1380 patients were seen. The population was again overwhelmingly male (70%). While the majority of patients were again between 15–44 years of age (56%) the proportion of patients under 15 had increased from 13.5% to 25%.

In a change from previous, the most common mechanism of injury was falls (44%), followed closely by RTC (41%).

**Conclusion:** This project provides some of the only empirical evidence of injury patterns in Africa. While the data analysis is in its preliminary phase it has already raised some interesting questions and trends. In addition to simple analysis, the plan is to use this data to begin to define specific outcome measures and to create regional standards similar to what the Major Trauma Outcome Study did in North America. Hospitals, regions, or countries could then compare themselves to the normative standards of their peers as a method of quality control and improvement.

**Abstract ID: 0972**

Specific Field: **Trauma**

**Mode of pres.: Poster Discussion**  
**ISW 2011 Session PW 08.15**

#### Changes in the outcomes of severe trauma patients: a western european experience in trauma ICU (1996–2010)

E. Giorgini [1], S. Di Saverio [2], A. Biscardi [2], S. Villani [2], C. Coniglio [2], A. Giugni [2], G. Gordini [2], G. Tugnoli [2]

[1] Maggiore Hospital, Italy, [2] Maggiore Hospital—Bologna Local Health District, Department of Emergency and Trauma Surgery Unit, Trauma Center, Bologna, Italy

**Introduction:** Our experience in trauma center management increased over time and improved with development of better logistics, optimization of structural and technical resources. In addition recent Government policy in safety regulations for RTA prevention, such compulsory helmet use (2000) and seat-belts restraint (2003) aimed to decrease mortality rate for trauma. The evaluation of the influence on mortality and causes of death during a 15-years period of these factors can lead to further improvements.

**Material and Methods:** In our level I trauma center in Bologna, 60247 trauma admissions have been recorded between 1996 and 2010, with 2183 deaths. 2935 patients with severe polytrauma and ISS >16 have been admitted to Trauma ICU and recorded in a prospectively collected database (1996–2010). 74.8% of them were males with mean age of 44,12 years. Blunt trauma occurred in 97.1% of the cases, whereas 2.5% were penetrating and 0.4% other causes. A retrospective review of the outcome has been carried out, including mortality, cause of death, morbidity and LOS in ICU, with stratification and analysis of the changes in outcome through the years; age, sex, mechanism, GCS, SBP, RR, RTS, ISS, pH, BE, therapeutic intervention like angioembolization and number of blood units

transfused in the first 24 hours, were included in univariate and multivariate analysis of mortality predictive value.

**Results:** Overall mortality through the whole period was 17.2%, major Respiratory Morbidity in ICU was 23.3%. Through the study period a significant increase of the number of trauma admissions has been observed (before and after 2001,  $P < 0.01$ ). Mean GCS (10.2) significantly increased during the period (Test Trend  $P < 0.05$ ). Mean age, ISS (24.83) and mechanisms did not change significantly whereas mortality rate significantly decreased with two marked drops, from 25.8% in 1996, to 18.3% in 2000 and again down to 10.3% in 2004 (Test Trend  $P < 0.01$ ). TBI accounted for 58.4% of the causes of death, Hemorrhagic shock in 28.5% and MOF/Sepsis in 13.1%. However the distribution of causes of death changed during the period showing reduction of TBI-related and increase of MOF/Sepsis (Test Trend  $P < 0.05$ ). Significant predictors of mortality in the whole group were year of admission ( $P < 0.05$ ), age, hemorrhagic shock and SBP at admission, ISS and GCS and tissue perfusion indicators such as pH and BE (all factors  $P < 0.01$ ). In the subgroup of patient underwent emergency surgery the same factors confirmed to be significantly associated with mortality in addition with number of Blood Units transfused ( $P < 0.05$ ). Duration of surgery (mean 71 min, showing a significant trend to reduction in the recent years) did not reach a statistically significant association with mortality ( $P = 0.06$ ). **Conclusion:** Mortality of severe trauma decreased significantly during the last 15 years as well as mean GCS whereas ISS remained stable. New safety regulations influenced incidence and severity of TBI and seemed to improve the outcomes. ISS seems to be a better predictor of outcome than RTS.

**Abstract ID: 0973**

Specific Field: **Trauma**

**Mode of pres.: Poster Discussion**  
**ISW 2011 Session PW 08.16**

**Systemic neutrophil responses to ischemia reperfusion, hypothermia and tissue damage in a human cardiopulmonary model**

K. M. Groeneveld, S. O. Algra, L. H. Ulfman, B. J. Prakken, N. J. G. Jansen, L. Koenderman, L. P. H. Leenen

University Medical Center Utrecht, Utrecht, Netherlands

**Introduction:** Tissue damage, ischemia-reperfusion and hypothermia, which are associated with trauma, can lead to several levels of systemic inflammation. Literature shows that reaching a threshold of inflammation is associated with multi-organ dysfunction syndrome. Neutrophil phenotypes can be used as a read-out of the inflammatory status. Goal of the current study is to gain insight into the kinetics of systemic neutrophil activation in response to the above mentioned 'lethal trauma triad'. A humane model of cardiac surgery with a cardiopulmonary bypass machine and deep hypothermic circulatory arrest was used as a trauma model. We tested the hypothesis that recirculation and ventilation after aortic arch reconstruction surgery cause immune activation, which leads to a decrease in neutrophils with a functional phenotype.

**Material and Methods:** Infants (<1 month of age) undergoing aortic arch reconstruction were included in this prospective study. Primary outcome were the kinetics of neutrophil phenotypes measured by flowcytometry. Secondary outcomes were the functional capacities of these neutrophils (reactive oxygen species production, phagocytosis, adhesion). All measurements were performed pre-, peri- and postoperative.

**Results:** Results showed a low grade activation (priming) of neutrophils during the surgical procedure, measured as a mild increase in classical activation marker MAC-1 and priming marker fMLP-induced active Fc $\gamma$ RII. After rewarming and reperfusion were sustained, the expression of MAC-1 returned to baseline. The expression of fMLP-induced active Fc $\gamma$ RII showed a marked decrease, which is a sensitive marker of severe systemic activation of the neutrophil compartment.

**Conclusion:** Aortic arch reconstruction during deep hypothermic circulatory arrest mildly primed systemic neutrophils. Subsequent recirculation, rewarming and reperfusion caused a marked activation of systemic neutrophils, which is a possible risk factor for inflammatory complications.

**Abstract ID: 0974**

Specific Field: **Trauma**

**Mode of pres.: Poster Discussion**  
**ISW 2011 Session PW 08.17**

**Demographic & population-based analysis of traumatic injury transport outcomes and health-care infrastructure in Northern Quebec's rural communities**

F. Hamadani, T. Razek, K. Khwaja, D. Deckelbaum, P. Fata, J. Prudhommes

McGill University Health Centre, Montreal, Canada

**Introduction:** North American & international studies show mortality & morbidity rates from traumatic injury to be higher in remote & rural populations when compared to urban areas. Little research is available to assess the health infrastructure & outcomes of traumatic injuries in such regions, which include Northern regions of Canada. In isolated Northern Quebec communities, transport to the Montreal University Health Centre (MUHC), a level 1 regional centre, is the only option for complex trauma care. This study aims to provide: (1) a demographic analysis of the Northern Quebec region, characterizing the available health care infrastructure; (2) the mechanisms & rates of Northern injuries requiring transfer; (3) transfer times & outcomes of patients with traumatic injury from this region.

**Material and Methods:** Quantitative data from trauma cases transferred to MUHC from Northern Quebec was obtained & analyzed from the MUHC trauma registry (1/1/2005–31/12/2009). Demographic & health services data was obtained & analyzed from the Réseau universitaire intégré de santé de l'Université McGill (RUIS), administrator of Northern Quebec health services.

**Results:** From 1/1/2005 to 31/12/2009, 305 patients were transported to MUHC, mostly for MVCs (40%), followed by falls (20%) & blunt injury (20%) (Table). MVCs were the most common reason for transport across all communities. Penetrating trauma represented 26% of transfers from Puvirnitug, the capital of the region. Overall, penetrating trauma averaged 12% of all transports across all communities. Transfer times across all communities & all injuries averaged 21.5 h, highest for all communities in stab wound patients (21.3 h), & lowest for all communities in MVC patients (18.6 h).

**Conclusion:** We identify a new category of very remote regions in Quebec's Northern terrain, an area of 839,000 sq km with a population of 39,300 people divided into 10 isolated communities. This body of work identifies the challenges in treating complex trauma injuries with the hope of improving trauma care in remote areas.

## Rates, Mechanisms &amp; Avg Transfer Time of Injuries Transported to MUHC from Northern Quebec (2005–09)

	Number of Transfers (305)	Percentage of Transfers (%)	Average Transfer Time (hr)
MVC	130	40	15.6
Fall	57	20	17.4
Blunt Trauma	57	20	19.6
Stab	22	7	21.3
Gun Shot	13	5	18
Cutting Object	11	3	17
Other	15	5	21

Abstract ID: 0975

Specific Field: Trauma

Mode of pres.: Poster Discussion  
ISW 2011 Session PW 08.18

## Ranking injury prevention priorities using administrative datasets: moving beyond trauma registries

A. Haider [1], C. Villegas [2], E. Haut [1], E. Schneider [1], A. Chi [1], K. Stevens [1], D. Efron [1], E. Cornwell [3]

[1] Johns Hopkins School of Medicine, Baltimore, USA, [2] Johns Hopkins School of Medicine, USA, [3] Howard University, Washington DC, USA

**Introduction:** The Injury Prevention Priority Score (IPPS) was designed for use by individual trauma centers to objectively rank the burden of different trauma mechanisms. IPPS is calculated using both the mean Injury Severity Score (ISS) and the frequency of occurrence for different injury mechanisms. Currently this methodology is restricted to trauma registries that contain ISS. This study explores the feasibility of calculating the IPPS from commonly available administrative datasets which typically contain ICD 9 codes.

**Material and Methods:** The NTDB National Sample Population (NSP), a nationally representative, weighted sample of trauma in the US was utilized as it contains both ISS information that is available only in trauma registries and ICD 9 diagnosis codes which are present in most administrative datasets. Two IPPS scores were calculated for each injury mechanism: first using ISS values present in the NSP registry and second with ISS's generated from ICD9 codes using freely available ICDPIC software. IPPS scores were compared and injury mechanisms ranked accordingly. (Scores are standardized to mean = 50, SD = 10.)

**Results:** Results: IPPS scores calculated using registry data were similar to those from administrative data. In fact the Priority Ranking of various mechanisms was identical using either methodology (table).

**Conclusion:** This study demonstrates that the IPPS can reliably be calculated from non trauma registry, administrative data. Hospitals, health systems, regions, and countries without trauma registries can apply this methodology to readily available administrative/discharge data to objectively determine injury prevention priorities specific to their needs. The most significant injury problem in the US remains Motor Vehicle Crashes, followed by falls, pedestrians struck by motor vehicles and then gun shot wounds.

## Comparison of IPPS ranking/scores derived from registry data versus administrative data

	Mean ISS	Number of patients	Registry based IPPS	Administrative data IPPS
1. Motor vehicle crash	11.2	154,410	69.00	69.21
2. Falls from height	9.1	106,302	60.76	60.68
3. Pedestrian struck by car/truck	12.5	16,049	55.25	55.20
4. Gunshot	11.6	28,877	54.58	52.24
5. Falls at the same level	7.9	53,320	50.80	51.28
6. Bicycle crash	10.2	3,407	49.14	49.42
7. Motorcycle crash	9.7	3,988	48.17	49.17
8. Blunt assault	8.0	27,936	48.05	48.09
9. Stabbings	5.6	22,613	42.58	43.39
10. Sports injuries	4.6	768	37.81	37.98

Abstract ID: 0976

Specific Field: Trauma

Mode of pres.: Poster Discussion  
ISW 2011 Session PW 08.19

## Analysis of the relation of head and cervical spine injury in maxillofacial trauma

P. Lawanlakkana

Sawanpracharak Hospital, Nakorn Sawan, Thailand

**Introduction:** Maxillofacial trauma is usually found along with head and cervical spine injuries. This study has analyzed the relationship of facial fracture patterns with concomitant head and neck injuries.

**Material and Methods:** A review of 458 consecutive patients with maxillofacial fractures and collected the data; facial fracture patterns were divided into 3 groups and concomitant head and cervical spine injuries. The difference between groups were compared and analyzed for identified relation of facial fracture with head and cervical spine injuries.

**Results:** Patients with maxillofacial fracture, 214 (46.7%) had associated with head injuries and 10 (2.18%) with cervical spine fractures. Mostly facial fractures were found with head injuries that was not severe (GCS 13–15) but the upper facial fracture were associated with severe intracranial injuries and skull fractures, whereas the mandibular fracture was associated with temporal bone fracture. The mortality rate of the patient with the facial fracture is 2.4%.

**Conclusion:** Maxillofacial fractures are commonly associated with head and cervical spine injury therefore should be watched out for head injuries in order to reduce the errors and delay in diagnosis and should be protected cervical spine injuries in case suspicious before being diagnosis because force spread from facial bone transmission to cranial and cervical spine with different types of facial fractures.



Patients with facial fracture associated with the head and cervical spine injuries

	Upper Facial Fracture	Middle Facial Fracture	Lower Facial Fracture
Intracranial hemorrhage (n = 15)	n = 4, P = 0.010	n = 12, P = 0.270	n = 3, P = 0.178
Epidural hemorrhage (n = 15)	n = 1, P = 0.794	n = 13, P = 0.097	n = 4, P = 0.423
Subdural hemorrhage (n = 17)	n = 3, P = 0.169	n = 13, P = 0.389	n = 4, P = 0.100
Subarachnoid hemorrhage (n = 12)	n = 2, P = 0.305	n = 8, P = 0.991	n = 5, P = 0.704
Intraventricular hemorrhage (n = 2)	n = 0, P = 0.665	n = 1, P = 0.613	n = 1, P = 0.690
Temporal fracture (n = 12)	n = 7, P < 0.001*	n = 11, P = 0.064	n = 0, P = 0.008*
Parietal fracture (n = 8)	n = 4, P < 0.001*	n = 6, P = 0.062	n = 1, P = 0.155
Occipital fracture (n = 1)	n = 0, P = 0.760	n = 1, P = 0.480	n = 0, P = 0.488
Base of skull fracture (n = 14)	n = 5, P < 0.001*	n = 13, P = 0.036*	n = 3, P = 0.239
Upper (C1–2), (n = 3)	n = 1, P = 0.122	n = 2, P = 0.996	n = 1, P = 0.276
Middle (C3–5), (n = 5)	n = 1, P = 0.355	n = 4, P = 0.529	n = 1, P = 0.442
Lower (C6–8), (n = 2)	n = 0, P = 0.665	n = 1, P = 0.613	n = 1, P = 0.283

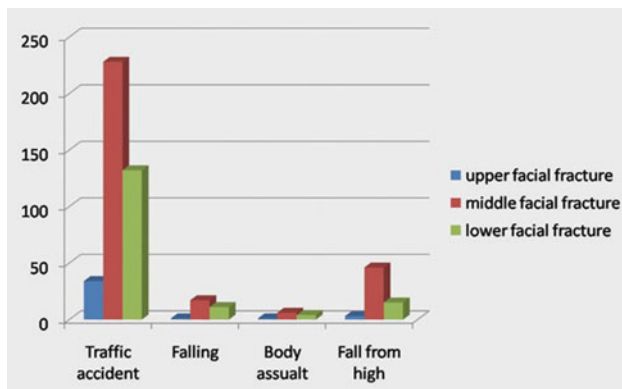


Figure: Cause of facial fractures

Abstract ID: 0977

Specific Field: Trauma

Mode of pres.: Poster Discussion  
ISW 2011 Session PW 08.20

### A load of bull: frequency, type and severity of injuries in rodeo riders

L. Koval, R. Livingston

Rockhampton Base Hospital, Rockhampton, Australia

**Introduction:** The main objectives of this study was to document the frequency, type, severity, anatomic location and sequelae of injury to bull riders participating in regional rodeo competitions in Central Queensland and to suggest strategies to minimize their occurrence.

**Material and Methods:** A five-year retrospective study including a total of 35 riders with a median age 21.7 (range 12–58) who required

admission to the hospital after injury at the rodeo. The data concerning the injury management and length of hospital stay was extracted from the hospital records and from the EDIS (Emergency Department Information System). Injuries were classified according to their type and anatomical site.

**Results:** Fractures were the most common injury, constituting 51.4% of total injuries, with tibia and fibula being the most common fracture site (33.3%). Lacerations constituted 17% of all injuries; head injuries accounted for 11%, two of which necessitated ICU admission. The rest was due to dislocation, ligament tear, pneumothorax, spleen rupture and paraphimosis. Mean duration of hospital stay was 1.9 days. Only 2 participants were recorded to wear protective equipment at the time of injury. Two riders were re-admitted with rodeo-related injuries.

**Conclusion:** Muskuloskeletal and head injuries are the most common types of rodeo injuries. It is impossible to completely eliminate them due to the unpredictable behaviour of the animal during rodeo, but it is possible to minimize their frequency and severity by wearing appropriate protective equipment and by improving general fitness by adopting the program focusing on balance and isometric conditioning.

Abstract ID: 0978

Specific Field: Trauma

Mode of pres.: Poster Discussion  
ISW 2011 Session PW 08.21

### Chronic pain and its impact on quality of life following a traumatic rib fracture

V. G. Shelat [1], S. J. Lee [2], E. Sim [2], L. T. Teo [1], M. T. Chiu [1]

[1] Tan Tock Seng Hospital, Singapore, [2] Yong Loo Lin School of Medicine, National University of Singapore, Singapore

**Introduction:** Thoracic trauma comprises of 10–15% of all trauma patients and traumatic rib fractures account for 7–40% of trauma admissions. Most of the traumatic rib fractures heal spontaneously and do not contribute to disability. Prevalence of chronic pain and its impact on quality of life following a traumatic rib fracture is not studied well.

**Material and Methods:** Retrospective review of electronic medical records of all the traumatic rib fracture admissions from January 2007 up to December 2008 was conducted. This was followed up with a brief telephonic survey of following questions:

1. Do you have pain following the trauma?
2. If YES, how severe is your pain from a score of zero to ten?
3. Does the pain affect your life style?
4. Does the pain affect your work?
5. Do you need to take regular pain medications?

**Results:** One hundred and two patients responded to the survey and 23 patients (22.5%) complained of persistent pain after a median duration of 18 months. Five patients (4.9%) had a persistent pain that required regular use of analgesic medications. Six patients (5.9%) complained of impairment of work like and three patients (2.9%) complained of impairment of personal quality of life. The persistent pain was not related to the number of fractures, flail chest, hemo-pneumothorax, insertion of chest tube and duration of hospitalization ( $P > 0.05$ ).

**Conclusion:** This study from a busy trauma centre confirms high incidence of chronic pain after a traumatic rib fracture. While, majority of the patients can manage this pain without interference with quality of life, a few minorities do suffer from life style/work interference and may have to resort of regular analgesic usage.

**Abstract ID: 0979**Specific Field: **Trauma****Mode of pres.: Poster Discussion**  
**ISW 2011 Session PW 08.22****Conservative management of splenic trauma: the Royal Adelaide experience**

A. Jukes, P. Bautz

Royal Adelaide Hospital, Adelaide, Australia

**Introduction:** The spleen is one of the most commonly injured abdominal organs in both blunt and penetrating trauma. Conservative management of splenic trauma has created new phenomenon of delayed pseudoaneurysm formation. Increasingly, angio-embolisation is being utilised for both penetrating and blunt trauma. This study reviews the RAH splenic injury protocol efficacy.

**Material and Methods:** Retrospective review of CT scans of a cohort of 24 trauma patients admitted under the trauma unit at the Royal Adelaide Hospital (RAH). Initial CT was compared with post embolisation films at 1 week and 3 months to determine the incidence of splenic haematoma and of pseudoaneurysm formation.

**Results:** Lacerations of all grades in 87% initial scans. Contrast blushes in 25%. Peri-splenic haematomas in 75%. Pseudoaneurysm in 4%. In one week follow-up films post angio-embolisation: Lacerations 86%, Contrast blushes 5%, Peri-splenic haematomas 27% and Pseudoaneurysm in 22%. At 3 months Lacerations 37%, Contrast blushes 0%, Peri-splenic Haematoma 62%, Pseudoaneurysm 0%.

**Conclusion:** Angio-embolisation of traumatic splenic lesions at RAH safely controls bleeding and effectively manages pseudo-aneurysms. The benefit of splenic CT 7–10 days post injury in diagnosing pseudo-aneurysm is shown. Three month post embolisation CT determines remaining splenic tissue. RAH splenic injury protocol is safe, and effective.

**Abstract ID: 0980**Specific Field: **Trauma****Mode of pres.: Poster Discussion**  
**ISW 2011 Session PW 08.23****Anatomical consideration of pancreatic branches of splenic vessels for spleen-preserving distal pancreatectomy with complete conservation of splenic vascular and nervous system: cadaver study and case reports**

N. Kaneko [1], Y. Kobayashi [2], M. Itoh [1]

[1] Tokyo Medical University, Tokyo, Japan, [2] National Defense Medical College, Saitama, Japan

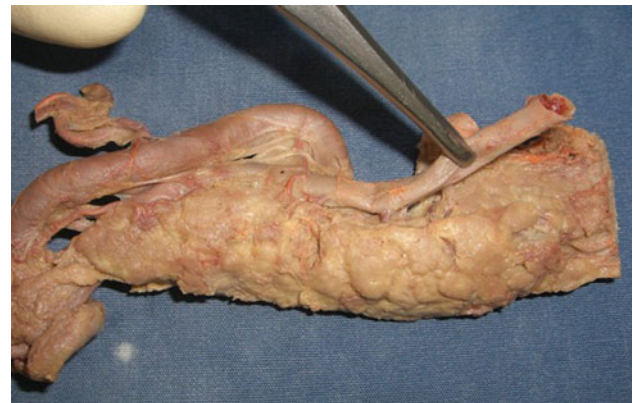
**Introduction:** Distal pancreatectomy proceeds with splenectomy because dissection between the pancreas and splenic artery/vein (SA/V) has been thought difficult. Although spleen-preserving distal pancreatectomy (SPDP) has recently been advocated after being aware of overwhelming postsplenectomy infections, many SPDP has sacrificed the SA/V while maintaining splenic blood circulation by preserving the short gastric vessels. The reason for this is that the pertinent anatomic variations of the pancreatic branches (p-branches) of SA/V are not well understood.

**Material and Methods:** In 50 cadavers, the numbers of the p-branches of SA/V were studied. The directions of the p-branches emerging from the SA/V were also investigated.

**Results:** The numbers of the p-branches were  $3.0 \pm 1.7$  (mean  $\pm$  SD) from SA (ranged 1–8), and  $4.3 \pm 2.2$  from SV (1–10). The SA branches emerged only at the inferior side of the SA in 48

(96%) cadavers, additionally the superior in 1 (2%), and also the anterior in 1 (2%). However, the entering directions of the venous branches to the SV varied widely. The branches, to which most careful attention should be paid, were anterior ones observed in 26 (52%) cadavers. The number of the branches was  $1.0 \pm 1.2$  (0–4). No correlation was found between the number of SA branches and SV branches. Alongside the SA run the vagus nerve to the spleen. Case presentations: A 10-year-old boy sustained pancreatic damage during a bicycle accident. Pancreatic laceration was identified via incision of the gastrocolic ligament at laparotomy. The distal pancreas was mobilized without touching the spleen, and SPDP with preserved SAV was achieved with the operation period of 270 minutes and the intraoperative hemorrhage volume of 210 cc. Complete conservation of the spleen and SA/V flow were confirmed by CT scans of 1-year follow-up. Another case was 16-year-old boy injured by a motorcycle accident. The operation period was 195 min and the intraoperative hemorrhage was 180 cc.

**Conclusion:** SPDP with preserved the SAV is a safe way to totally conserve the splenic vascular and nervous system. The key issue in the procedure is the disconnection between the SV and the pancreas at the anterior face of the SV.

**Figure:** Anterior and inferior venous branches**Abstract ID: 0981**Specific Field: **Trauma****Mode of pres.: Poster Discussion**  
**ISW 2011 Session PW 08.24****High impact foreign domestic help falls in Singapore: an institution's experience comparing pre/post government policy changes in improving their work environment**

H. M. Liu, L. T. Teo, K. T. S Go, Y. T. Yeo, M. T. Chiu

Tan Tock Seng Hospital, Singapore

**Introduction:** There are approximately 196,000 foreign domestic help (FDW) working in Singapore. The majority of Singaporeans live in high rise apartments. FDWs working in such homes are at risk of high impact falls. Few will survive high impact falls to enable us to study the reasons behind these falls. There has been an increase in FDWs from 1 in 7 households in 2004/5 to 1 in 5 households in 2010. There have been a slew of Government policies/measures, since 2004, to improve the working environment for FDWs. These included raising the minimum age of FDW working in Singapore and legislating courses such as an Employer's Orientation Programme and a FDW Safety Awareness Course.

The aim of this descriptive study is to describe the demographics, injury patterns, outcomes, and reasons behind high impact falls in FDW. The secondary objective is to evaluate the impact of Government measures to improve their work environment. A retrospective review of all foreign domestic help who fell from height (>2 m) and who required admission from 1st July 2001 to 30th June 2010 to our hospital were studied. There were a total of 53 patients in the study. All were female and 67.9% were from Indonesia. Of the 53, 45.2% of the falls were accidental, 35.8% intentional and the remaining were indeterminate for the reason behind the falls. 47 patients survived their injuries. 31 were repatriated back to their country of origin and 8 were able to return to their original jobs. Suicidal attempts were the cause of the falls in 13 FDWs, of which 9 had acute depression and 4 had underlying psychosis. The incidence of such high impact falls has been stable since 2005, taking into account the increasing FDW population in Singapore. The majority of high impact falls in FDWs are due to accidental falls during the course of work. An underlying psychiatric reason is behind 24% of all falls in this group of patients. Despite the increase in the FDW population in Singapore between 2005–2010 on a yearly basis, the high impact fall rate has been relatively stable after 2005. The incidence of FDWs having acute stress reactions or depression has also fallen. FDW falls are potentially preventable. An increased awareness of dangers at the workplace and the attention to psychiatric/emotional support, have shown to be effective in our study.

**Abstract ID: 0982**

Specific Field: **Trauma**

**Mode of pres.: Poster Discussion**  
**ISW 2011 Session PW 08.25**

**Management outcome in pancreatic trauma: a critical analysis at a tertiary care referral trauma center in South India**

M. A. Johnson, C. Subramaian

Kanyakumari Govt. Medical College Hospital, Asaripallam, Nagercoil, Tamilnadu, India

**Introduction:** Following pancreatic trauma, pseudo cysts develop in 40–100%, but abscesses are not uncommon, and recurrent episodes of pancreatitis may occur remote to the time of injury. Non operative management of pancreatic transection or ductal disruption can, however, be costly.

**Material and Methods:** A prospective analysis of a cohort of 16 pancreatic injury patients, blunt  $n = 16$ , motor vehicle accident  $n = 11$ , bicycle handle bar injury  $n = 2$ , fall from a height  $n = 3$  during the period from 2003 to 2009. Diagnosis and assessment of injury severity are based on imaging studies and operative findings. Data regarding mechanism of injury, management strategy and outcome are also documented.

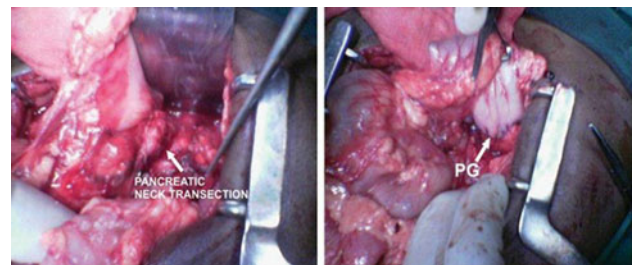
The incidence of AAST grade I to V pancreatic injuries were 40.0%, 18%, 27%, 0%, and 15% respectively. Time from injury to hospital presentation was 6–8 h. Time from hospital presentation to diagnosis of injury was 10–12 h. Time from injury to operation was 24–28 h. Surgery was required in 10 patients, which included ligation of bleeding vessel, pancreatorrhaphy and peri-pancreatic drainage in three, central pancreatectomy in six and pancreaticoduodenectomy in one patient respectively.

**Results:** Overall morbidity rate was 54.5% which included intra-abdominal abscess in two, pseudocyst in two, pancreatitis in one and pancreatic fistula in one patient respectively with no mortality.

**Conclusion:** A high index of clinical suspicion and repeated computed tomography scans should lead to earlier diagnosis in pancreatic trauma. The complication rate for major blunt pancreatic injury was

high; especially when treatment was delayed for more than 24 hours. Central pancreatectomy with pancreaticogastrostomy is a safe pancreas preserving conservative surgical strategy worthy of consideration as an alternative to distal pancreatectomy in the setting of traumatic complete transection of pancreatic neck

Total patient $n = 16$	Mechanism of injury	Site/grade of pancreatic injury	Type of operation
$n = 11$	Blunt, motor vehicle accident	AAST Gr-III	Central pancreatectomy + left hepatic lobectomy $n = 1$ central pancreatectomy $n = 5$
$n = 2$	Blunt, bicycle handle bar	AAST Gr-III	Central pancreatectomy + simple suture closure of duodenal defect $n = 1$ Whipples procedure $n = 1$
$n = 3$	Fall from height	AAST Gr-II	Pancreatorrhaphy, ligation of bleeding vessel and peri-pancreatic drainage $n = 3$



Traumatic pancreatic neck transection

**Abstract ID: 0983**

Specific Field: **Trauma**

**Mode of pres.: Poster Discussion**  
**ISW 2011 Session PW 08.26**

**Non-operative management of splenic injury and factors predictive of failure**

E. K. Tan, V. G. Shelat, L. T. Teo, A. Vijayan, M. T. Chiu

Tan Tock Seng Hospital, Singapore

**Introduction:** Spleen is the commonest organ to be injured in blunt abdominal trauma. Management of splenic injury has evolved over the last few decades with focus on strategies for spleen conservation. Outcomes of splenectomy avoidance and factors predictive of failure of non-operative management (NOM) are yet ill defined.

**Material and Methods:** A retrospective study of the Tan Tock Seng Hospital Trauma Registry database from Jan 04 to May 09 was done. All statistical analysis was performed on SPSS version 14.0 (SPSS Institute, Chicago, USA). All *P*-values were two-sided and a value of less than 0.05 was considered significant.



**Results:** Forty-five of the 90 patients admitted with splenic injuries were managed non-operatively. The patients who underwent operative treatment (with or without splenectomy) had poorer Injury severity score (ISS) ( $P = 0.0001$ ), Revised trauma score (RTS) ( $P = 0.005$ ) and probability of survival (PS) ( $P = 0.0001$ ). The mean ages of patients undergoing NOM was 38 years and were mostly male (88.9%). All the patients had a computerized tomography scan of the abdomen and 19 (42.2%) had Grade II, 13 (28.9%) had Grade III, 11 (24.4%) had Grade IV and two (4.4%) had Grade V splenic injury. Three patients required splenectomy after an initial attempt at NOM. All the three patients failed NOM within 48 hours of admission. Three patients underwent angio-embolization for hemodynamic instability following an attempt at NOM. The overall splenic salvage rate was 92.2% and median hospital stay was seven days. There was no mortality. A hematocrit value of  $< 30.0$  on admission ( $P = 0.04$ ) and splenic injury severity score of V ( $P = 0.003$ ) were predictive of failure of NOM.

**Conclusion:** Traumatic splenic injury with hemodynamic stability is an indication for NOM. Splenic artery angioembolization is a useful adjunct to NOM for splenic injury with hemodynamic instability or active ongoing bleeding evident on CT scan. Splenorrhaphy can be performed in a patient with an injured spleen requiring a laparotomy for any reason including an isolated splenic injury. Splenectomy should not be considered as a failure in patient care, but a valid management option for splenic injury in accordance with available resources and local practice. While Grade V splenic injury is not an absolute indication for splenectomy, failure rates for NOM will be high.

**Abstract ID: 0984**

Specific Field: **Trauma**

**Mode of pres.: Poster Discussion**  
**ISW 2011 Session PW 08.27**

**Trauma trends in Singapore: its impact on future trauma programmes**

H. L. Sim, L. T. Teo, K. T. S. Go, Y. T. Yeo, V. Appasamy, M. T. Chiu

Tan Tock Seng Hospital, Singapore

**Introduction:** A good understanding of local trauma epidemiology is the cornerstone to the management of trauma patients and to the success of any trauma programme. Tan Tock Seng Hospital (TTSH), the largest and busiest tertiary trauma care centre in Singapore, embarked on a formal multi-disciplinary trauma programme since 2005. Through this study, we hope to delineate significant trends in our trauma population over the years and aid us in targeted trauma programmes in future.

**Material and Methods:** A retrospective review was conducted on all trauma patients that were admitted to TTSH from 01 January 2005 to 31st December 2009. Data was obtained from the hospital's trauma registry, Emergency Department records, clinical records and post mortem reports. Patients who had incomplete records were excluded from the study. Demographics, mechanism of injury, ISS, patterns of injury, mortality rates and outcomes of patients were collected. Data analysis was done with SPSS version 13.

**Results:** There were 5720 trauma patients who required admission. 69.3% of them were males (3963 patients) and 30.7% were females (1757 patients). 67.8% were Chinese, 13.4% were Malays, 12.9% were Indians and remaining 6% belonged to other ethnic groups. Majority of the mechanism of injury was attributed to falls (49.2%) and vehicular accidents (38.9%). The median age of patients was 47 years (30–66 years) with 26.3% classified as elderly ( $> 65$  years). There was a steady increase in the number of elderly admitted over

this 5 year period from 173 (20.8%) in year 2005 to 466 (32.3%) in year 2009. The median age of patients had also shown similar increase from 42 years in year 2005 to 51 years in 2009. The number of admissions was noted to be on the rise from 833 in year 2005 to 1441 in year 2009. The overall median length of stay was 5 (3–11) and the overall mortality rate was 9% with 2.5% of the patients who died at Emergency department. The median ISS did not change during this period (range 9–10) but the mortality rate was noted to have significantly gradually decreasing from 13% in year 2005 to 6.8% in year 2009 ( $P = 0.000$ ).

**Conclusion:** The yearly increase in the number of elderly trauma patients reflects our aging population and that of developed countries in the region. Future trauma programmes/initiatives should devote more attention to the elderly. Having a multi-disciplinary trauma management system has resulted in a decrease in overall mortality rate.

**Abstract ID: 0985**

Specific Field: **Trauma**

**Mode of pres.: Poster Discussion**  
**ISW 2011 Session PW 08.28**

**Traumatic colon and rectal injuries: experience in an urban asian hospital**

W. S. Tan, M. H. Chew, M. H. Goh, Y. T. Yeo, K. T. S. Go, A. Vijayan, M. T. Chiu Tan

Tock Seng Hospital, Singapore, Singapore

**Introduction:** The management of traumatic colon and rectal injuries has evolved and changed dramatically over the past century with recent studies from high volume trauma centers recommending primary repair or resection with primary anastomosis. The aim of this study was to evaluate if this is applicable to a relatively lower volume trauma center like ours.

**Material and Methods:** Medical records of consecutive patients who were admitted with traumatic colon, rectal and/or anal injuries to our institution between January 2003 and December 2009 were retrieved from a prospectively collected computer database. Patients with penetrating luminal injuries, with or without vascular compromise, were included in the study.

**Results:** Twenty-nine patients were admitted with traumatic injuries involving the colon, rectum or anus during this 6 year period. The majority (90%) of the patients were male with a median age of 35 years old (range 21 to 60). The mechanism of injury was most commonly due to vehicular accident (55%). Ten patients required immediate laparotomies. In the remaining 19 patients, computed tomographic scans were diagnostic in every case. 5 patients had perineal entry wounds requiring wound debridement, primary repair of anorectal injuries and defunctioning stomas. Nineteen patients (66%) had primary repair or resection without a covering stoma while 4 patients had colonic resection with a covering stoma. One patient was treated conservatively. Post-operative morbidity was 16%. Patients who suffered post-operative complications had a significantly higher median ISS score (35.5 versus 10,  $P = 0.006$ ). Mortality rate was 3%; One patient, who had a ISS score of 41, died a few hours after surgery from extensive injuries.

**Conclusion:** Most of the patients in our series had repair or resection without stoma formation and these patients did well post-operatively with low morbidity. Complications were more likely to happen in patients with high ISS scores indicating that it is the severity of the original injury and not the management of the injury that dictates outcome. Hence evidence from large trauma centers that favour resection or repair without the use of a stoma may be applicable to our institution.



**Abstract ID: 0986**Specific Field: **Trauma****Mode of pres.: Poster Discussion**  
**ISW 2011 Session PW 08.29****Serious motorcycle accidents in Singapore: lessons from a helmeted population**L. T. Teo, M. T. Chiu, D. H. Hong, K. T. S. Go, Y. T. Yeo,  
L. T. J. Tan, V. Appasamy

Tan Tock Seng Hospital, Singapore, Singapore

**Introduction:** Motorcycles are an affordable and popular mode of transportation in Singapore. Their relatively small size and lack of protection make motorcyclists potentially more prone to serious road traffic accidents (RTAs). Except for strict helmet laws, there are no other legislated physical injury prevention modalities. The aim of this descriptive study is to understand the epidemiology of serious motorcycle accidents admitted to Tan Tock Seng Hospital, the busiest and largest trauma centre in Singapore. We hope to better understand the pattern of injuries sustained, the factors influencing morbidity and mortality. A secondary aim is to use the results to guide future injury prevention programmes.

**Material and Methods:** A retrospective study was performed of all motorcyclists with serious injuries (Injury Severity Score  $\geq 9$ ) admitted from 2005–2009. Data was obtained from the hospital's trauma registry and clinical records. Exclusion criteria were those where data was missing, mechanism of injury was uncertain and where patients did not survive the initial resuscitation en route to hospital.

**Results:** A total of 1227 patients were admitted into the study. 89.65% were males. Malays and Indians were the most commonly involved. 89.7% of our patients were in the economically active age group of <60 years, mean age of 37.5 years. The most commonly affected anatomical region of injury was that of the limbs (51%), followed by thoracic injuries and head injuries (HI). There were 108 mortalities in total with the mean age (at time of mortality) of 33.0 years. Majority of the mortalities were due to multi-system trauma. Isolated HIs accounted for 17.8% of motorcycle injuries.

**Conclusion:** Strict helmet legislation has decreased the incidence of trauma mortality from isolated HIs. However, isolated HIs requiring admission accounted for 17.8% of injuries sustained. The overall mortality rate of a motorcycle accident victim after a serious accident is that of 8.8% regardless of ISS/age. The young age of the trauma victims is typical of motorcycle accident victims. Injury prevention programmes should be targeted at the "young rider", safe/defensive riding habits needs to be emphasized, additional protective gear, should be encouraged. This study has enabled us to understand this unique population of trauma victims better and target our future trauma management programmes.

**Abstract ID: 0987**Specific Field: **Trauma****Mode of pres.: Poster Discussion**  
**ISW 2011 Session PW 08.30****Advances in the management of hepatic injuries: a single-center report**

Y. Uchida, T. Fujita, T. Sakamoto

Teikyo University school of Medicine, Tokyo, Japan

**Introduction:** Nonsurgical management has become the standard of care for patients with hepatic injuries in most trauma centers in Japan. The aim of this study was to determine whether the advances in the

management of hepatic injuries have improved the outcomes of such patients.

**Material and Methods:** Details for 90 patients with severe hepatic injury (organ injury scaling grades III, IV, and V) who were examined and treated in our department during a 23-year period were analyzed. We compared the severity of injury, treatment, and outcome between the previous term (1985–1994) and the recent term (1995–2008).

**Results:** The laparotomy rate for severe hepatic injuries has dropped, from 88.5% to 31.6%. Conversely, transarterial embolization (TAE) was performed in 52.6% of patients in the recent term, compared with 9.6% in the previous term. The overall mortality rate improved to 26.3% from 46.2%.

**Conclusion:** Although hemodynamically unstable patients with severe hepatic injuries require surgical intervention, nonsurgical management, including TAE, can be safely applied to hemodynamically stable patients even with high grade hepatic injuries.

**Table** Treatments and outcomes of patients with severe hepatic injuries

	1985–1994	1995–2008	P-value
Cases of severe hepatic injury	52	38	
Organ injury scaling grades III, IV, and V			
Age	28.4	36.7	$P = 0.024$
Laparotomy rate	88.5	31.6	$P < 0.001$
TAE rate	9.6	52.6	$P < 0.001$
Mortality rate	46.2	26.3	$P = 0.052$
Mortality due to liver injury	36.5	5.3	$P < 0.001$
ISS	33.6	30.4	$P = 0.346$

**Abstract ID: 0988**Specific Field: **Trauma****Mode of pres.: Poster Discussion**  
**ISW 2011 Session PW 08.31****Twenty three new cases of isolated small bowel perforation after blunt injury to the abdomen: diagnostic and therapeutic challenges in low income environment**A. Chichom Mefire [1], P. E. Weledji [2], V. S. Verla [2],  
N. M. Lidwine [3], E. E. Malonga [4]

[1] Faculty of Health Sciences, University of Buea and Regional Hospital Limbé, Limbé, Cameroon, [2] Faculty of Health Sciences, University of Buea, Buea, Cameroon, [3] Regional Hospital Limbe, Limbe, Cameroon, [4] Faculty of Medicine and Biomedical Sciences, University of Yaoundé, Yaounde, Cameroon

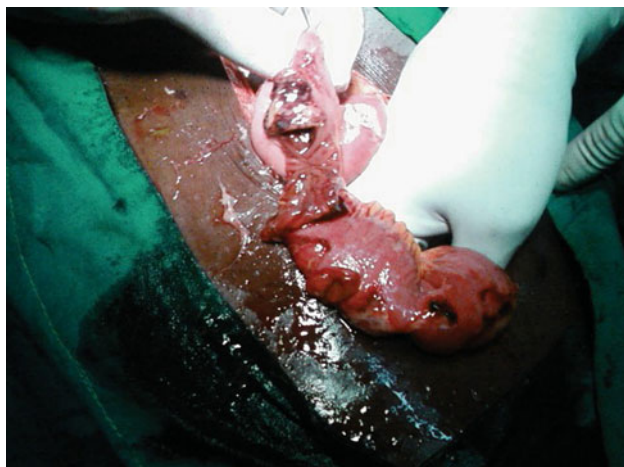**Introduction:** Isolated small bowel injury (ISBI) related to abdominal blunt trauma is rare. Outcome has been shown to depend on timely diagnosis, especially in the absence of modern imaging and laparoscopic facilities. We present twenty three cases of ISBI due to blunt injury to the abdomen observed over a 5 years period in a low income environment and discuss the specific diagnostic and therapeutic challenges related to this special environment.

**Material and Methods:** Clinical and paraclinical information of patients diagnosed and managed for an isolated small bowel injury over a period of 5 years, from January first 2005 to December 31st

2009 were retrieved from A database. All cases were reviewed for modalities of diagnosis, therapeutic procedures, delay between injury and laparotomy, operative findings and outcome.

**Results:** Results: 23 patients were identified over the study period. Their mean age was 19 years. The most frequent mechanism of injury included falls ( $n = 11$ ) and road traffic accidents ( $n = 9$ ). Most cases (69.5%) presented as an isolated abdominal injury. Delay before diagnosis ranged from 6 to 38 hours. 65.2% of patients presented with features of acute peritonitis. Plain abdominal X-ray diagnosed free air in the abdominal cavity in 11 patients. Laparotomy discovered an isolated small bowel perforation, multiple in 2 patients. Treatment was either simple suture ( $n = 15$ ) or intestinal resection ( $n = 8$ ). Morbidity was 21.73% and 2 patients died.

**Conclusion:** Small bowel injury in blunt trauma of the abdomen is seldom suspected as in many cases, the initial injury seem to be minor. The mechanism of injury in our study seems to be different. Diagnosis is usually delayed and most patients are seen with obvious signs of peritonitis. Plain abdominal X-ray seems to be more useful than what is usually described and it is not clear weather CT scan would improve diagnostic accuracy. Mortality does not seem to be increased by the delay in diagnosis. In low income environment, early diagnosis and management is more likely to improve with increase awareness of clinicians about the risk of ISBI in blunt abdominal trauma, even with low ISS.



**Figure:** Multiple perforations of the ileum after blunt abdominal injury in a 9 years old boy

**Abstract ID: 0989**

**Specific Field: Trauma**

**Mode of pres.: Poster Discussion**  
**ISW 2011 Session PW 08.32**

#### **Injury severity and distribution of injuries in motorcyclists and pillion Riders**

M. H. Goh, V. Appasamy, K. T. S. Go, Y. T. Yeo, M. T. Chiu  
Tan Tock Seng Hospital, Singapore, Singapore

**Introduction:** Motorcyclists make up about 18% of Singapore's total vehicle population. However, motorcyclists and pillion riders contribute more than 50% of total fatalities on the road. This study aims to determine and compare the distribution and severity of injuries between motorcyclists and pillion riders, and identify injury clusters contributing to high mortality and morbidity.

**Material and Methods:** Retrospective data on motorcycle accident victims admitted to a trauma centre between 1st Jan 2005 to 31st Dec 2009 were collated. Demographics, clinical parameters in Emergency Department (ED), mechanism of injury of motorcyclists and pillion riders, injury distribution and severity, and outcomes from ED were analyzed. Victims who died in ED and patients admitted were included. Patients more than 65 years old and those discharged from ED were excluded. Analysis of the data was done using Stata U9.2.

**Results:** 1155 patients were included in the study. Mean age of the patients was 35.4. 1034 (89.5%) were riders; 1035(89.6%) of the patients were male. 121(10.5%) of the patients were pillion riders, of which 69(5.9%) were female pillion riders. 1124(97.3%) were admitted; 31(2.7%) died in ED. Top three mechanism of injuries were head on ( $n = 386$ , 33.4%), skidding ( $n = 360$ , 31.2%), and side on ( $n = 179$ , 15.5%). Mean ISS of riders was 16.3, while mean ISS of riders who died was 43.0. Mean ISS of pillion riders was 14.1. Distribution of three most frequent injuries among those who died in ED were chest (AIS = 3.9), head (AIS = 2.9), abdomen (AIS = 2.7). Injuries among riders who were admitted were chest (AIS = 2.9), head (AIS = 2.8), abdomen (AIS = 2.8). Statistically significant injuries among pillions who were admitted were chest (AIS = 3.1), head (AIS = 2.8), limbs (AIS = 2.8).

**Conclusion:** Preliminary analysis shows that severity of chest injuries are related to mortality and morbidity of patients. Pillion riders suffered more limb injuries than motorcyclists.

**Abstract ID: 0990**

**Specific Field: Trauma**

**Mode of pres.: Poster Discussion**  
**ISW 2011 Session PW 08.33**

#### **Trauma mortality: are elderly patients at higher risk?**

K. Jayasuriya, L. T. Teo, K. T. S. Go, Y. T. Yeo, V. Appasamy, M. T. Chiu

Trauma Service, Department of General Surgery, Tan Tock Seng Hospital, Singapore, Singapore

**Introduction:** In Singapore, an aging population has resulted in new challenges faced by health care providers. Trauma management in the elderly will potentially be a significant health care challenge. A better understanding of this unique population is required to manage elderly trauma and formulate management strategies. Anecdotally, we observed that the overall trauma mortality rate in elderly group (>64 years) is significantly higher than that of younger group (<65 years).

The aim of this retrospective descriptive study is to identify the association between both the cause of death and the time of death, in relation to Pre-existing Medical Conditions (PMC) and Injury Severity Score (ISS) in 2 groups of trauma patients.

**Material and Methods:** A retrospective analysis of all trauma deaths from 2005 to 2009 (5 years) was performed. Data was obtained from the trauma registry, emergency department records, clinical records and post mortem reports. Adult deaths were compared with deaths in elderly in relation to PMC, ISS, time of death and cause of death.

**Results:** Of the 5720 trauma admissions analysed for the period of 5 years, there were 513 deaths (Chinese 75.4%; Indian 11.3%; Malay 9.2%; others 4.1%). The elderly had increased risk of death (14.5% vs. 7%,  $P < 0.001$ ). Elderly patients were more likely to die even if they survived the first 72 hours, compared to the adults ( $P < 0.001$ ). Majority (76.6%) of elderly patients had PMC compared to 19.7% in the adult group ( $P < 0.001$ ). Nearly 93% of adult mortality was due to multiple trauma and head injury but only 64% in elderly

( $P < 0.001$ ). Late trauma deaths (>14 days) were higher in elderly patients sustaining minor and moderate injuries (ISS <25), (OR2.7, 95% CI 1.2–5.9). Nearly 84% of elderly deaths with ISS <25 injuries had associated with PMC compared to 36.6% in adults.

**Conclusion:** Age >65 alone is a risk factor of mortality in trauma. Elderly patients with minor and moderate injuries are more likely to die late in hospital admissions relative to their younger patients. PMCs have significant association with elderly late deaths. These findings will guide us our management strategies when managing elderly trauma not only clinically but also from a healthcare perspective as a country.

## Abstract ID: 0991

Specific Field: **Trauma**

Mode of pres.: **Poster Discussion**  
ISW 2011 Session PW 08.34

### Treatment strategy of damage control surgery for the patients with open long bone fractures and head injuries

H. Minehara, S. Konno, K. Soma, T. Suzuki, T. Matsuura, K. Nakahara, T. Kitahara, M. Takaso

Kitasato University School of Medicine, Sagamihara, Japan

**Introduction:** Open long bone fractures are surgical emergency. However, it is often difficult for surgeons to give priority to which procedure when patients have head injuries. Appropriate decision for the treatment is mandatory in a short time in such cases. In this study, clinical courses of the head-injured patients with open long bone fractures treated in our facility were reviewed and treatment protocol was established in order to determine the adequate treatment promptly.

**Material and Methods:** Registry data and charts of patients admitted to our emergency centre from March 2002 to October 2008 were reviewed retrospectively. 22 open long bone fractures of 21 patients (10 male, 11 female) with head injuries were included in this study. Average age at the time of injury was 48 (15–76) years old. The open fracture sites of long bones and their treatment methods, involvement of craniotomy, complications were investigated and treatment protocol was established.

**Results:** Open fracture sites included Tibia: 12 cases, humerus: 5 cases, femur: 3 cases, radius: 2 cases. 9 cases with GCS >8 required no neurosurgical intervention and definitive fracture fixation following thorough debridement was performed on the day of injury. External fixators were applied in 13 cases.

Craniotomy was performed in 9 cases. Craniotomy and open long bone fracture fixation were done in the same operative setting at the day of injury in 5 of 9 cases. External fixators was applied on all 5 cases and definitive treatment was planned after stabilization of general condition. Definitive fixations were performed on 3 cases and 2 patients died due to head injuries.

There were no orthopaedic complications in all patients such as deep infection or nonunion.

**Conclusion:** For the patients with open long bone fractures and severe head injury, application of external fixators was beneficial for the concept of damage control.

In our established protocol, for the patients with GCS >8, definitive treatment can be considered for the open long bone fractures following stabilization of general status if neurosurgery or second look operation are not required. For the patients with GCS <9, ICP monitoring is mostly indispensable and external fixation should be performed regardless of neurosurgical intervention.

New established protocol may precisely conduct the surgeons for decision making in chaotic emergency situations.

## Abstract ID: 0992

Specific Field: **Trauma**

Mode of pres.: **Poster Discussion**  
ISW 2011 Session PW 08.35

### Nonoperative management for blunt hepatic trauma

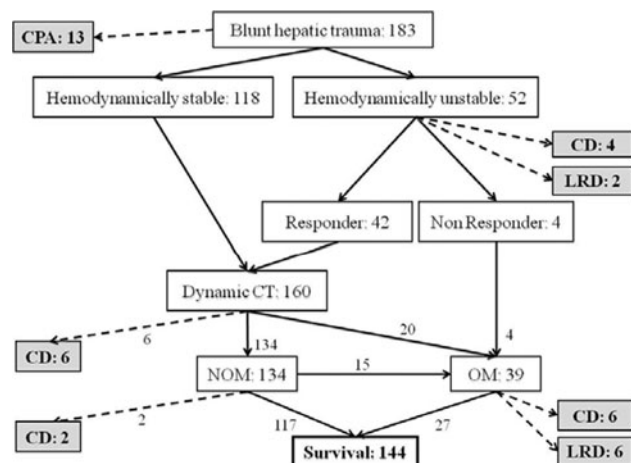
T. Ochiai, K. Shinohara, S. Yamazaki

Ohta Nishinouchi General Hospital, Kohriyama, Japan

**Introduction:** Liver trauma is the leading cause of death after severe abdominal injuries, with related mortality of 10%–15%. The nonoperative management (NOM) of blunt hepatic injuries for hemodynamically stable patients has become safe and standard over the past two decades.

**Material and Methods:** Between January 1, 2001 and December 31, 2008, 183 patients with blunt hepatic injuries were transferred to the Emergency Room, Ohta Nishinouchi General Hospital. We reviewed their medical records and recorded sex, age, mechanism and severity of injury, physical findings, laboratory findings, radiologic imaging findings, and whether they were treated with NOM or operative management (OM) and their treatment results.

**Results:** Among 183 patients, 13 patients were in cardiopulmonary arrest (CPA), when paramedics arrived. Another 118 were hemodynamically stable and 52, unstable. Of these last 52, 6 died in our emergency room (ER): 2 of severe hepatic damage and 4 of concomitant organ injuries. The remaining 46 hemodynamically unstable patients were resuscitated with crystalloids, to which 42 responded and became stable, therefore, dynamic computed tomography was examined. However, 4 did not respond, emergent laparotomy was performed. Among hemodynamically stable patients, 6 patients died due to severe cerebral hernia without having received any additional treatment. Initially, 134 were treated with NOM, including 10 treated by arterial embolization (AE), and 24 were treated with OM. Of these 134 NOM patients, 15 needed OM at last. In the present study, 121 of the 142 patients with grade I, II, or III injury and 13 of the 20 patients with grade IV injury were treated with NOM, which was completed in 87.3% with 1.5% mortality. On the other hand, conversion from NOM to OM was needed in 2 patients (3.3%) with a grade II injury, 7 (12.5%) with a grade III injury, and 6 (46.2%) with a grade IV injury. None of the 134 patients initially treated with NOM were in grade V. **Conclusion:** Our data suggest that low-grade injuries are more suitable for our NOM than high-grade injuries. Strict observation is needed for high grade liver injury to detect signs of delayed hemorrhage or liver abscess.



**Figure:** Management of blunt hepatic trauma in 183 consecutive patients



**Abstract ID: 0993**Specific Field: **Trauma****Mode of pres.: Poster Discussion**  
**ISW 2011 Session PW 08.36****Management outcome in hepatic trauma: a critical analysis at a tertiary care referral center in South India**

M. A. Johnson, C. Subramanian

Kanyakumari Govt. Medical College Hospital, Asaripallam, Nagercoil, Tamilnadu, India

**Introduction:** Non operative managements now considered as the standard of care for hemo-dynamically stable blunt liver injury patients with success rates as high as 85% to 95%. Concomitant liver injuries in poly-trauma patients complicate management decisions.

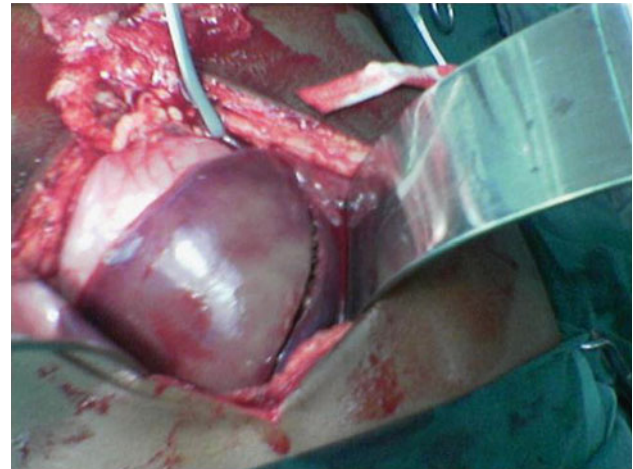
**Material and Methods:** A retrospective analysis of 38 patients treated for hepatic injuries, blunt  $n = 37$  (Road Traffic Accident  $n = 35$ , Assault  $n = 2$ ); penetrating  $n = 1$  during the period from 2002 to 2007 at one trauma center. Diagnosis and assessment of injury severity were based on imaging studies and operative findings. Data regarding patient demographics, the mechanism of injury, management strategy and outcome were retrieved.

Among 38 patients with hepatic trauma, there were 31 men, 7 women; with the mean age being  $35 \pm 18$  years. The incidence of Moore grade I to V liver injuries were 31.5%, 34.2%, 23.6%, 7.8%, and 2.6% respectively. Surgery was required in 17 (44.7%) patients and was best predicted by the classification of the American Association for the Surgery of Trauma (AAST). The operative procedures included right hepatic artery ligation in 1, peri-hepatic packing in 5, suture hepatorrhaphy in 6, anatomical in one and non anatomical liver resection in 5 patients respectively.

**Results:** Angiographic embolization achieved permanent hemostasis in 3 patients (2 in re-bleeding after packing, 1 in bleeding hepatic artery pseudoaneurysm). Patients requiring surgical intervention had a morbidity rate of 47.0% which included bile leak in 4, re-bleeding in two, and sepsis in two patients respectively. The mortality rate being 23.5% due to sepsis in two, grade V injury in one and head injury in one patient respectively.

**Conclusion:** The incidence of liver injury among poly- trauma patients is likely to be under-estimated and must be determined by the independent application of reference standard such as helical computed tomography. High- grade hepatic injuries and the need for surgical repair are associated with poor survival. Non-operative management should be considered as the standard of care for hemodynamically stable blunt liver injury patients.

Hepatic trauma	$n = 38$
Associated abdominal injury [31.5%]	$n = 11$
Lacerations & rupture of ascending colon & caecum	$n = 2$
Rupturing DJ flexure	$n = 1$
Mesenteric tear	$n = 1$
Pancreatic injury	$n = 1$
Diaphragmatic injury	$n = 6$

**Figure:** Left lobe liver injury with devascularization**Abstract ID: 0994**Specific Field: **Trauma****Mode of pres.: Poster Discussion**  
**ISW 2011 Session PW 08.37****Craniomaxillofacial and mandibular fractures: an Asian institution's review of epidemiology**

V. Nallathamby, S.Y. M. Ho

Tan Tock Seng Hospital, Singapore, Singapore

**Introduction:** Craniomaxillofacial fractures and mandible fractures are commonplace in a trauma centre. There are many different presentations and etiologies to these fractures. Here we present an analysis of the epidemiology of these cases and review similarities and differences with other institutions.

**Material and Methods:** Our institution, Tan Tock Seng Hospital is the trauma centre for Singapore. This was a retrospective review on 140 patients, who presented to this institution from January 2009 to June 2010, with facial or mandible fractures. Ethical board approval was obtained.

**Results:** The mean age of these patients were 43.5 years. There were 110 males and 30 females in this group of patients. The ethnic distribution was different from the Singapore census 2005, as they were 58% Chinese, 15% Malay, 18% Indian and 8% other races. Up to 12% of cases were delayed presentation to our outpatient clinic as compared to the remaining 88% who were admitted acutely following the injury. There were only 5% isolated nasal fractures but 16% isolated orbital fractures. Of all these cases, 60% were operated on, whilst the remainder 40% were treated conservatively.

**Conclusion:** Facial fractures are common, however there were no specific associated injuries with facial trauma. There was also no association between age or gender and type of fracture sustained. 54% of the cases were due to road traffic accidents while 30% was due to falls. Only 13% fractures were sustained as a result of an assault. There are many types of facial fractures and many combinations of it. In addition to that, together with the diversified population and modes of presentation, we can conclude that not all fractures needs to be operated on.



**Abstract ID: 0995**      Specific Field: **Breast Surgery****Mode of pres.: Prize Session FP**  
**ISW 2011 Session 47.01****Initial result from the Hong Kong Breast Cancer Registry**

P. Cheung [1], W. K. Hung [2], C. Cheung [1]

[1] Hong Kong Breast Cancer Foundation, Hong Kong, China, People's Republic, [2] Pedder Clinic, Hong Kong, China, People's Republic

**Introduction:** Current strategy for breast cancer prevention and treatment in Hong Kong are adopted from the practice and data from overseas countries. It is essential to establish a cancer-specific registry to monitor the occurrence of breast cancer locally. A first-of-its-kind cancer-specific registry called the Hong Kong Breast Cancer Registry (HKBCR) was established in 2008. The current status of breast cancer in Hong Kong based on the data collected from this Registry is presented.**Material and Methods:** Prevalent and newly diagnosed breast cancers (including in-situ and invasive cancers) were registered. Information on demographics, risk factors, clinico-pathological characteristics, treatment details, psychological impact, recurrence and survival information were collected. The data were analyzed and reported.**Results:** Data was collected from 2330 breast cancer patients. The median age at diagnosis was 48.8 and 69% of the patients aged 40–59. We observed an earlier median age at diagnosis than those reported in other countries. At the time of diagnosis, 77.2% of the patients were symptomatic. Among them, 89.4% presented with a painless lump. Only 49.2% sought medical consultation within 3 months after the onset of symptoms. The most prevalent risk factors included a lack of physical activity (<3 h per week in 70.8%), no breast feeding (53.5%) and overweight/obesity (34.4%). 81.1% had never had screening mammogram. 85.2% had no family history and 8.8% had first degree relative having breast cancer. Distribution of cancer stage was: stage 0 (11.4%), stage I (31.4%), stage II (41.0%), stage III (12.5%), stage IV (0.8%) and unclassified (2.9%). The percentages of the patients receiving surgery, chemotherapy, radiation therapy and hormonal therapy were 98.7%, 67.9%, 64.8% and 64.1% respectively. At a mean followup of 2.2 years, locoregional recurrence was recorded at 2%, distant recurrence at 2.8% and breast cancer related mortality at 0.3%.**Conclusion:** Our data represented the current situation of breast cancer in Hong Kong. The coverage to include all local breast cancer cases is expected to improve and the HKBCR will become an important tool for monitoring the incidence in Hong Kong and will serve as a platform for future breast cancer research.**Abstract ID: 0996**      Specific Field: **Breast Surgery****Mode of pres.: Prize Session FP**  
**ISW 2011 Session 47.02****Residual malignant cells in the re-excision tissue after breast conserving surgery for cancer**

J. Gatek, P. Vazan, J. Kotoc, K. Kotocova, L. Hnatek, B. Dudesek, J. Duben

Department of Surgery Atlas Hospital Zlin, University of Tomas Bata Zlin, Zlin, Czech Republic

**Introduction:** Definition of clear margins after breast conserving surgery is controversial. Patients who undergo breast conservation

surgery require up to 60% re-excision to secure tumor free margins. Re-excision is associated with worse cosmetic result, extended stay in hospital and discomfort of the patient. Aim of the study was find out presence of malignant cells in re-excision tissue and signification of re-excision.

**Material and Methods:** Breast conserving surgery was performed in 330 of 398 patients with breast cancer at Atlas Hospital Zlin between January 2004 and December 2008. We have reviewed all medical record to detect malignant cells in re-excision tissue. We have divided patients in three groups according distance between tumor and resection line: 1.tumour cell in resection line, 2.distance up 2 mm and 3.distance 2–5 mm. We have compared all three groups.**Results:** Re-excision was performed in 78 patients 23, 6%. Tumor characteristic: DCIS 8, Invazive ductalCa 53, LobularCa 10, Others 7; Number of re-excision according distance: positive margin 10× (12, 8%) distance up 2 mm 12 (15, 3%), distance 2–5 mm 56× (71, 7%). Re-excision tissue in patients with positive margin was positive 10× (100%) and mastectomy was final procedure in all patients. Re-excision in distance up 2 mm was positive 3× (25%) and mastectomy was 2× final procedure. Re- excision in distance 2–5 mm was positive 18× (32, 1%) and direct mastectomy was made 5×. Second re-excision was also 2× positive and so procedure finished with mastectomy. Breast after mastectomy contained tumor in all cases. Local breast recurrence appeared only in 5 patients 1, 5%.**Conclusion:** Common recommendation for resection margin is 1–2 mm. We have made regressive examination of the re- excised tissue and distance 2–5 mm was main reason for re-excision (71%). Re-excision tissue in these cases contained in 32, 1% malignant cells and nearly in 40% of patients we had to perform mastectomy for impossibility to reach clear margins. All mastectomy breast was positive. Local recurrence was very low and we are convinced that distance more than 2 mm is more suitable.**Abstract ID: 0997**      Specific Field: **Breast Surgery****Mode of pres.: Prize Session FP**  
**ISW 2011 Session 47.03****Nine-years experience with the sentinel lymph node biopsy in a single Italian center: a retrospective analysis of our 1050 cases**

S. Bernardi [1], S. Bertozzi [1], F. Giacomuzzi [2], V. Angione [3], G. Gentile [1], A. Carbone [4], A. P. Londero [5], R. Petri [1]

[1] Department of Surgery, AOU “S M della Misericordia” of Udine, Udine, Italy, [2] Department of Nuclear Medicine, Azienda Ospedaliero-Universitaria di Udine, Udine, Italy, [3] Department of Pathology, Azienda Ospedaliero-Universitaria di Udine, Udine, Italy, [4] Department of Radiodiagnostics, AOU “SM della Misericordia” of Udine, Udine, Italy, [5] Clinic of Obstetrics and Gynecology, Universit, M, Germany

**Introduction:** The sentinel lymph node biopsy (SLNB) has progressively replaced complete axillary lymph node dissection (CALND) in patients with negative sentinel node. Our study aims to determine the prevalence and predictive factors for recurrence after SLNB in our population.**Material and Methods:** We collected clinical data about all SLNBs performed between January 2002 and December 2010, and followed patients up, paying attention to any adverse event, including recurrence, death and cancer-related death. Data was analyzed by R(version 2.10.1), considering significant  $P < 0.05$ . Also multivariate analyses were performed.

**Results:** 1050 SLNBs were performed at a mean age of 61.14 years ( $\pm 11.92$ ), 23.33% (245/1050) of which underwent secondary CALND. At a mean follow up of 55 months ( $\pm 22$ ), the axillary recurrence prevalence among women who did not receive CALND results 0.75% (6/805), being all recurrences happened between the 3rd and the 6th year of follow up, and after 6 years of follow up, it is 1.2% (CI.95 0–2.5%). By monovariate analysis, significant risk factors for axillary recurrence ( $P < 0.05$ ) are pathological tumor size 20 mm, differentiation grading 2, lymphovascular invasion, and multifocality. By multivariate analysis, recurrence results independently influenced by tumor size 20 mm ( $P < 0.05$ ), multifocality ( $P < 0.05$ ), high grading ( $P < 0.066$ ), lymphovascular invasion ( $P < 0.176$ ), and by the presence of another mammarian or extramammarian cancer ( $P < 0.170$ ).

**Conclusion:** Although our axillary recurrence rate of 0.75% results acceptable and is comparable to the most data reported by the current literature, we join the most authors in reasonably cautioning that this rate may increase as the length of follow-up extends. However, considering the high SLNB accuracy by breast cancer staging and its low morbidity if compared with CALND, and the hypothesis that not removing healthy axillary lymph nodes may be beneficial to patients, further studies are required in order to evaluate the necessity of CALND by positive SLNB.

**Abstract ID: 0998**      Specific Field: **Breast Surgery**

**Mode of pres.: Prize Session FP**  
**ISW 2011 Session 47.04**

**Usefulness of preoperative morphological information by SPECT/CT lymphoscintigraphy for the intraoperative diagnosis of sentinel lymph node in a clinically node negative breast cancer**

T. Azumi [1], Y. Hashimoto [1], M. Fujishima [1], S. Maki [1], M. Yamato [2], T. Hojo [1], H. Inui [1], M. Watatani [1]

[1] Kinki University, Osaka-sayama, Japan, [2] Yamato Clinic, Osaka, Japan

**Introduction:** Background: Sentinel node (SN) mapping is widely used in patients in the early stage of breast cancer. Conventional lymphoscintigraphy is routinely used for preoperative SN detection. However, lymphoscintigraphy planar imaging lack anatomic landmarks permitting SN localization. Recent studies have shown that SPECT/CT lymphoscintigraphy is a more effective technique than conventional lymphoscintigraphy for the detection and localization of SN in the early stage of breast cancer. Objective: The aim of this study was to investigate the usefulness of preoperative information of SN obtained by SPECT/CT lymphoscintigraphy on estimating metastasis to SN.

**Material and Methods:** One hundred and thirty-nine invasive breast cancer patients who were clinically node negative underwent SN biopsy using  $^{99m}\text{Tc}$ -phytate SPECT/CT lymphoscintigraphy. We measured the greatest diameter of SN which was identified by SPECT/CT lymphoscintigraphy preoperatively, and calculated an area of a longitudinal section of SN using the greatest diameter and the greatest perpendicular distance. SNs were assessed postoperatively with routine stains at 2 mm intervals through the nod. mm intervals through the node.

**Results:** The average number of SN was 1.2, and the median greatest diameter of SN was 11.4 mm (5.2–22.2 mm). The median area of a longitudinal section of SN was 37.9 mm<sup>2</sup>. Final histological reports showed that 102 patients were pN0, 7 were pN1mi, and 30 were pN1. The relationship between the greatest diameter of SN and metastasis to axillary lymph node revealed that patients with SN less than 6 mm in diameter had negative SN. Analysis of the area of a longitudinal

section of SN showed that patients with pN1mi had an area of a longitudinal section of SN less than 57 mm<sup>2</sup>, and those more than 90 mm<sup>2</sup> appeared pN1.

**Conclusion:** Morphological information obtained by SPECT/CT lymphoscintigraphy was considered to be useful for the intraoperative diagnosis of SN in a clinically node negative breast cancer.

**Abstract ID: 0999**      Specific Field: **Breast Surgery**

**Mode of pres.: Prize Session FP**  
**ISW 2011 Session 47.05**

**Impact of internal mammary sentinel node biopsy on staging of breast cancer patients**

H. Jinno, M. Takahashi, T. Hayashida, M. Sakata, T. Nakahara, M. Mukai, Y. Kitagawa

Keio Univ Sch Med, Tokyo, Japan

**Introduction:** Internal mammary (IM) node dissection has not been routinely performed because it does not improve survival of breast cancer patients. However, there is a renewed interest in IM node status since the introduction of sentinel lymph node biopsy (SLNB). In this study we evaluated the incidence of SLN in the IM chain and its clinical relevance.

**Material and Methods:** From January 2001 to August 2010, 1420 clinically node-negative breast cancer patients with T1–2 tumors less than 3 cm had SLN biopsy at Keio University Hospital. SLN biopsy was performed using technetium-99m-labeled tin colloid (particle size: 200–400 nm in diameter) and blue dye. Intraoperative frozen examination was performed with hematoxylin and eosin (H&E) staining. All SLNs, fixed and embedded in paraffin, were additionally studied by H&E staining and immunohistochemical staining for cytokeratins (AE1/AE3, DAKO, Carpinteria, CA).

**Results:** Axillary SLNs were identified in 1397 patients (98.4%) and additional IM SLNs were found in 27 patients (1.9%). The incidence of IM SLNs was significantly correlated with the medial location of the tumor and the younger age. Of 27 patients with IM SLNs, 3 patients (11.1%) had metastatic IM SLNs on final pathologic examination and received IM chain radiotherapy. Two of these 3 patients had positive axillary SLNs and one patient had negative axillary SLNs.

**Conclusion:** IM SLNB is performed safely without serious complications. Evaluation of IM SLN status provides more precise staging and identifies patient subgroups that might benefit from altered adjuvant therapy.

**Abstract ID: 1000**      Specific Field: **Breast Surgery**

**Mode of pres.: Prize Session FP**  
**ISW 2011 Session 47.06**

**Screening mammography read by breast surgeons: an audit of 15049 examinations**

J. Apffelstaedt [1], K. Baatjes [1], V. Steenkamp [2]

[1] University of Stellenbosch, Cape Town, South Africa, [2] Private Practice, Cape Town, South Africa

**Introduction:** In comprehensive breast centers the majority of examinations if for screening; clinicians often see these images and the question arises, whether this alone may be sufficient as notably in resource limited countries, there is a lack of breast radiologists. To assess the quality of mammography reading by non-radiologists in

comparison to international bench-marks, we present the largest series of surgeon-read screening mammography to date.

**Material and Methods:** All mammography performed between 2003 and 2010 at a comprehensive breast centre was recorded prospectively. First assessment was by a mammographer and consensus established after 2nd reading by an experienced breast surgeon who took responsibility for the reading. Data recorded were: Age, hormonal replacement therapy, prior breast surgery, indications for mammography and outcomes. Outcomes were classified based on BIRADS. Indeterminate lesions were imaged further or underwent tissue acquisition. All BIRADS 5 lesions underwent tissue acquisition.

**Results:** Of 15,069 mammograms 670 were reported as indeterminate/compatible with malignancy; 302 biopsies were performed and 109 cancers diagnosed. In 40–49 year old women (6,262 mammograms), the recall rate was 4.2%, the biopsy rate was 1.6% and the malignancy rate of biopsy was 23.7%, the cancer diagnosis rate was 3.6/1000 examinations; for 50–69 year old women these figures were 8.231, 4.7, 2.2, 44.1% and 10.0/1000 and women older than 70 years 576, 5.6, 3.4, 33.3% and 11.2/1000. Of all cancers, 32.2% were non-invasive; of invasive cancers, 49.1% were 10 mm or less in diameter and 75% were node-negative.

**Conclusions:** These results are similar to those in high-quality organized screening programs. The role of breast surgeons in mammography interpretation should be expanded; the absence of breast radiologists must not prevent the establishment of breast units where breast surgeons are willing to be educated in mammography reading.

**Abstract ID: 1001**      Specific Field: **Breast Surgery**

**Mode of pres.: Prize Session FP**  
**ISW 2011 Session 47.07**

**Polyacrylamide gel injections for breast augmentation: management of complications in 106 patients**

D. Unukovych [1], V. Khrapach [2], M. Wickman [1], A. Liljegren [1], G. Patlazhan [3], K. Sandelin [1]

[1] Karolinska Institutet, Stockholm, Sweden, [2] National O. Bohomolets Medical University, Kiev, Ukraine, [3] Odessa State Medical University, Odessa, Ukraine

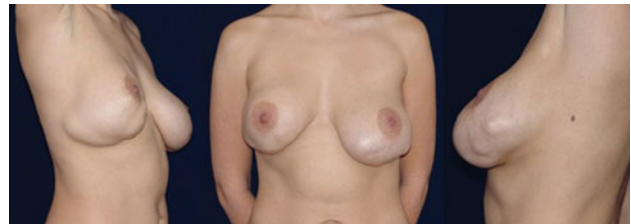**Introduction:** Polyacrylamide gel (PAAG) was first manufactured in Ukraine in the late 1980s and introduced as an injectable implant for “breast enlargement without surgery”. Being prohibited for clinical application in most countries, PAAG injections are still performed as the method is simple and less expensive than conventional breast augmentation. A retrospective multicenter study with the aim to describe the course of the patients with PAAG complications was conducted.

**Material and Methods:** We identified 106 patients operated for PAAG complications at three teaching Ukrainian hospitals from February 1998 to December 2008. All relevant clinical and treatment characteristics of breast surgery were collected. Forty-five (42%) patients were available for study follow-up.

**Results:** Patients presented after bilateral, 93 (88%), or unilateral, 13 (12%), PAAG injections. The mean volume of injected PAAG was 232 ml/breast (SD = 66). Patients’ mean age at injection was 29 years (range 17–49). The mean time from the injection to complications was 6.1 years (SD = 4.1). Patients’ symptoms preceding surgery were: pain 85 (80%), breast hardening 79 (74%), breast deformity 77 (73%), lumps 57 (54%), gel migration 39 (37%), fistulas 17 (16%), and gel leakage 12 (11%). Primary surgical treatment was PAAG evacuation alone 107 (54%) or in combination with: partial mastectomy 65 (33%), partial mastectomy and partial pectoralis muscle resection 12 (6%), or

subcutaneous mastectomy 15 (7%). Mean number of operations required for each breast was 1.8 (range 1–7). Of 199 operated breasts, 86 (43%) immediate and 58 (29%) delayed implant based breast reconstructions were performed. Of 45 women available for postoperative follow-up, 34 patients underwent breast ultrasonography, which revealed gel remnants in 37/60 (62%).

**Conclusions:** This study shows that injections of PAAG may cause irreversible damage to the breast in healthy women as they present with multiple symptoms necessitating complex cleansing operations, and even breast reconstruction. Despite numerous surgical interventions gel remnants are still found on subsequent breast imaging (Figure).



**Figure:** Patient with gel migration and gel lumps after bilateral PAAG injections

**Abstract ID: 1002**      Specific Field: **Breast Surgery**

**Mode of pres.: Prize Session FP**  
**ISW 2011 Session 47.08**

**Nipple-sparing mastectomy: results of a team approach and a collaborative operative technique**

J.K. Harness, A.H. Salibian, D.S. Mowlds

St. Joseph Hospital, Orange, CA, USA

**Introduction:** The use of areola-sparing (AS) or nipple-areola sparing (NAS) mastectomy for the treatment or risk-reduction of breast cancer has been the subject of increasing dialogue in the surgical literature over the past decade. We have developed a consistent approach for all potential candidates for nipple-sparing mastectomy: pre-operative evaluation at a multidisciplinary breast conference; consistent selection criteria; evaluation by the breast cancer team; and the plastic and breast surgeons operating together at the time of the mastectomies. We also employ an operative technique of thicker skin flaps and a primary approach of inframammary and axillary incisions, if at all possible.

**Material and Methods:** A retrospective chart review was performed of patients undergoing either AS or NAS mastectomies from November 2004 through July 2010. Data collected included: patient gender, age, family history, cancer type and stage, operative surgical details, complications, adjuvant therapies and follow-up.

**Results:** Sixty-three patients underwent 14 AS and 74 NAS mastectomies (88 total). Sixty-two patients were female and one was male. The average age was 49.7 years (range: 28–76 years). Sixty-two mastectomies were for breast cancer treatment and 26 were prophylactic. The types of cancers treated were: invasive ductal (37), invasive lobular (12), DCIS (16) and malignant phyllodes (1). Five patients had bilateral cancers and 2 patients had bilateral prophylactic mastectomies. Seventy mastectomies (79.5%) were performed using inframammary incisions. All patients underwent immediate reconstruction with either tissue expanders or permanent implants. There was a 4.5% incidence of full-thickness skin, areola or nipple tissue

loss. Three patients developed infections (3.4%) that required removal of their tissue expanders. The average follow-up of the series was 22.7 months (range: 5–74 months). Two patients developed mastectomy site recurrences (3.2%).

**Conclusions:** AS and NAS mastectomies can be safely performed with low complication rates and good short-term results utilizing a multi-disciplinary team approach. We believe that our tissue necrosis rate is low because we utilize thicker skin flaps and an inframammary approach.

**Abstract ID: 1003**      Specific Field: **Breast Surgery**

**Mode of pres.: Free Paper**  
**ISW 2011 Session 108.01**

**Can oncoplastic technique extend indication of breast conserving surgery?**

S.W.-W. Chan, L.L.-L. Chan, S.H. Lam

United Christian Hospital, China, People's Republic

**Introduction:** Although Breast Conserving Surgery is the preferred option of treatment to mastectomy, in patients with large or poorly situated tumor, cosmetic results can be poor and clear resection margins are difficult to be obtained. Oncoplastic breast conserving surgery integrates plastic techniques that allow wide excision of tumor and prevents breast deformity. The aim of this study is to evaluate the benefit of oncoplastic breast conserving surgery (OBCS) by comparing weight of tumor excision and surgical margins status of OBCS with standard lumpectomies (BCS).

**Material and Methods:** 80 consecutive patients undergoing OBCS (Nov 2007–May 2010) and 88 patients undergoing BCS (Jan 2004–Oct 2007) in United Christian Hospital (UCH) were retrospectively studied. Tumor size, weight of tumor excision, surgical margin status and re-excision rate was compared. Negative surgical margin was defined as margins > 2 mm. *P*-value < 0.05 was considered statistically significant.

**Results:** Patient who underwent OBCS have larger tumor size (median tumor size 2.6 cm) than patients who underwent BCS (median tumor size 1.7 cm; *p*).

**Conclusions:** OBCS allows larger extent tumor excision and is able to achieve lower re-excision rate. Its ability in achieving good cosmetic outcome in the same group of patients was published earlier (1). This benefit of OBCS might be useful in extending the indications for breast conservation surgery and might explain our higher breast conservation rate since the application of the technique.

**Abstract ID: 1004**      Specific Field: **Breast Surgery**

**Mode of pres.: Free Paper**  
**ISW 2011 Session 108.02**

**The accuracy of BRCA1/2 mutation prediction models in different ethnicity and gender: experience in a Chinese cohort**

M. Co [1], C.H.N. Wong [1], D.T.K. Suen [1], F.B.F. Law [2], A. Kurian [3], D.W. West [3], J.M. Ford [3], A. Kwong [1]

[1] Division of Breast Surgery, University of Hong Kong, Hong Kong, China, People's Republic, [2] Department of Molecular Pathology, Hong Kong Sanatorium and Hospital, Hong Kong, China, People's Republic, [3] Stanford University School of Medicine, Stanford, CA, USA

**Introduction:** Accuracy of risk prediction is important as it can affect the choice of risk management such as prophylactic mastectomy for high risk patients. Risk models (BRCA1/2, Myriad, Couch and Shattuck-Eidens, BOADICEA) are well established in Caucasian and African American cohorts to estimate the probability of BRCA1/2 mutation. Few studies have suggested its performance limitation in Asian cohorts. Most studies did not account for gender specific prediction. We aim to evaluate the performance of these models in a Chinese cohort who have breast/ovarian cancer at a pre-genetic test setting.

**Material and Methods:** Risk assessment models, Boadicea, BRCAPRO, Myriad, Couch and Shattuck-Eidens, were used to perform risk calculations to 217 non-BRCA carriers (198 females and 19 males) and 32 BRCA carriers (28 females and 4 males). Sensitivity, specificity and area under the receiver operator characteristic (ROC) curve were calculated for each model to evaluate for calibration, discrimination and accuracy in BRCA mutation prediction stratified by gender.

**Results:** The mean in prediction score in all models were statistically significantly higher in female BRCA mutation carriers. However, there were no statistically difference in mean prediction score between BRCA carriers and non-carriers in all models for male patients. BRCAPRO slightly over-estimated the total numbers of BRCA1 and BRCA2 female carriers (13 vs. 11 and 20 vs. 17), but underestimated the number of BRCA2 male carriers (2.8 vs. 4). While Myriad underestimated both the total numbers of BRCA1/2 male (3.1 vs. 4) and female (25.6 vs. 28) carriers. Boadicea did the closest estimation for both male (3.2 vs. 4) and female (1.5 vs. 11 for BRCA1 and 16.3 vs. 17 in BRCA2). BRCAPRO showed the greatest ROC area for BRCA1 (93%), BRCA2 (73%) and BRCA1/2 (79%) combination mutation prediction and highest sensitivity at conventional thresholds of 10% and 20% in female patients (71.4 vs. 60.7%). Boadicea had the greatest ROC area for BRCA2 and BRCA1/2 combination mutation prediction and the same sensitivity at conventional thresholds of 10% and 20% in male patients (92 vs. 93%).

**Conclusions:** All 4 models could perform reasonably well in female patients, but not in male. Boadicea has the best performance in male and female Chinese cohort. Whereas when comparing females alone, BRCAPRO is most accurate.

**Abstract ID: 1005**      Specific Field: **Breast Surgery**

**Mode of pres.: Free Paper**  
**ISW 2011 Session 108.03**

**Utility of biochemical bone turnover markers in prediction of bone metastases and monitoring therapy in breast cancer patients**

G. Agarwal, D. Sadacharan, V. Aggarwal, S. Kumar, P. Lal, S. Gupta, S. Mishra

SGPGIMS, Lucknow, India

**Introduction:** Skeleton is the commonest site for metastatic disease in breast cancer patients. This study was undertaken to evaluate the utility of biochemical bone-turnover markers in predicting bone metastases and monitoring systemic therapy in breast cancer patients.

**Material and Methods:** 90 IDC pts, 30 each in early (EBC), locally-advanced (LABC) & metastatic (MBC) groups were studied. Biochemical bone-turnover markers, namely serum Osteocalcin & serum Alkaline Phosphatase (both bone formation markers), and urinary n-telo-peptide cross links (u-Crosslaps<sup>TM</sup>, bone degradation marker) were measured before and 6 months after completion of



chemotherapy (CTx). Titers of markers were compared between 3 groups and with matched controls. Patients were treated with calcium & vitamin D supplements, hormonal agents if appropriate, and followed-up to detect any bone events (hypercalcemia, bone pain, fractures, bone metastases). Base-line and post-treatment bone turnover markers titers were correlated with occurrence of bone events. **Results:** Mean pre-treatment s-Al. Phos. in EBC, LABC and MBC groups were 73,117,208 IU/L respectively. Mean s-osteocalcin were 15.2, 24.2, 78.3 ng/ml, and mean u-crosslaps 563, 1982, 4678 µg/mmol-creatinine. 15% EBC, 35% LABC and 80% MBC patients had hyper-metabolic skeleton. Mean metabolic bone marker titers were significantly higher in LABC and MBC patients, but not in EBC as compared to matched controls. 5 EBC & 13 LABC patients developed bone metastases in follow-up (mean follow-up 73 months, min 62, max 96). EBC patients developing skeletal metastases had significantly higher bone markers, hinting a role of these in predicting skeletal metastases. Similar predictive role was not found in LABC. Markers regressed in 18/24 MBC patients after CTx.

**Conclusions:** There exists hyper-metabolic skeleton in LABC and MBC, and to lesser extent in EBC. Our investigations suggest role of biochemical bone-turnover markers in predicting bony metastases in EBC patients and in monitoring systemic therapy in MBC. Bone preservation therapies such as bis-phosphonates may be of value in EBC and LABC patients with high bone turnover markers, and may prevent future bone events in at least a sub-set of these patients.

**Abstract ID: 1006**      Specific Field: **Breast Surgery**

**Mode of pres.: Free Paper**  
**ISW 2011 Session 108.04**

#### The long-term results of a sentinel lymph node biopsy

K. Gonda, M. Yasuda, T. Otake, J. Ito, K. Watanabe, S. Takenoshita  
Fukushima Medical University, Fukushima, Japan

**Introduction:** Our department initiated sentinel lymph node biopsy (SNB) as a guide for further lymph node dissection from October, 2000. Herein is a report of nine consecutive years of treatment results. **Material and Methods:** Radioisotope injection (RI) of SNB used Technetium-Rhenium colloid. Migration of radioactivity guided subsequent 2 mm biopsies, which were sent for intraoperative frozen section diagnosis. Postoperative confirmatory diagnosis was obtained by permanent section analysis, including histochemical staining.

**Results:** Through September, 2009, a total of 596 breasts (including bilateral cases) were investigated. Unambiguous diagnosis was achieved in 99.8% of cases, with a single case being non-diagnostic. Metastatic disease was found in 162 cases (27.2%), of which 41% (91) were macrometastases, 29% (50) were micrometastases, and 16% (21) contained isolated tumor cells (ITC). One non-sentinel node was also found to contain ITC. A total of 447 SNB were negative by frozen section, of which 22 showed malignancy on permanent sections: macrometastases 1, micrometastases 6, and ITC 15. Excluding ITC cases, the frozen section false negative rate was 4.3%. Follow-up observation showed remote recurrence in 2.4% (11 of 447) of cases of lymph node dissection over an average of 54 months, and three examples (0.6%) through aspiration cytology. Five-year survival of 173 case through September, 2004 was 94.2%.

**Conclusions:** In micrometastatic SN, further metastases appeared in 30%, by lymph node dissection and axillary aspiration cytology. Long-term prognosis appears to be good when axillary aspiration or lymph node dissection is guided by SNB analysis in the treatment of type N0 breast cancer.

**Abstract ID: 1007**      Specific Field: **Breast Surgery**

**Mode of pres.: Free Paper**  
**ISW 2011 Session 108.05**

#### Individualized treatment strategy for HER2-negative breast cancer subtypes

T. Ishikawa [1], D. Shimizu [1], T. Sasaki [1], S. Morita [1], M. Tanabe [1], I. Ota [1], T. Chishima [2], I. Endo [2]

[1] Yokohama City University Medical Center, Yokohama, Japan,  
[2] Yokohama City University, Yokohama, Japan

**Introduction:** Background: As HER2-negative breast cancers are more heterogeneous than HER2 positive ones, tailored treatment strategy is important for subtypes of luminal A (LumA) and triple negative (TN). AIMS: To examine predictive factors of anti-cancer agents in each subtype, especially LumA and TN.

**Material and Methods:** Methods: 170 patients treated with standard regimens consisted of anthracycline and/or taxane prior to surgery. The overall pathological complete response (pCR) rates were examined in total and each subtype. The association of pCR with pathological factors including estrogen- and progesterone-receptor (ER and PgR), HER2, nuclear grade, Ki-67, P-53, Topoisomerase II $\alpha$ , CK5/6 and EGFR were examined.

**Results:** pCR rate was 24.2% (41/170) in total. That in LumA and TN were 5.6% (4/71) and 54.5% (24/44), respectively. In total, multivariate analysis with factors revealed that ER and nuclear grade were significantly associated with pCR. In LumA, the expression of PgR was inversely associated with pCR ( $P = 0.07$ ). In TN, cases lacking expression of CK5/6 and EGFR, defined as non-basal subtype, showed significantly higher pCR rates ( $P = 0.04$ ).

**Conclusions:** PgR may be a possible predictor for the efficacy of anti-cancer agents in LumA. TN is needed to be classified into basal- or non basal-subtype. New strategy may be required for treating basal-subtype.

**Abstract ID: 1008**      Specific Field: **Breast Surgery**

**Mode of pres.: Free Paper**  
**ISW 2011 Session 108.06**

#### Exploratory study about detection of breast cancer stem/progenitor cells by ALDH1 (Aldehyde dehydrogenase 1)/pan-cytokeratin/TWIST in sentinel lymph nodes

M. Kashiwaba [1], T. Inaba [2], G. Wakabayashi [1]

[1] Iwate Medical University, Morioka, Japan, [2] Iwate-Medical University, Japan

**Introduction:** There are some uncertain mechanisms of metastases with extensive experiments, because the processes of metastasis are too difficult to reproduce in vitro and seem to be involved in changes of phenotypes like EMT and stemness, not only in growth aggressiveness. Recent studies have revealed that CD44 $^{+}$ /24 $^{-}$  and ALDH1 are useful markers to detect breast cancer stem cells (BCSC) that might be essential to make colonies in different organs.

**Material and Methods:** Paraffin-embedded sections of twenty patients with node metastasis only in SN underwent breast surgery for primary breast cancers (BC) were stained with anti-ALDH1, -pCK and -TWIST antibodies. Patient's clinicopathological characteristics including TNM, ER/PgR, HER2 and histological grade were analyzed comparing to positivity of ALDH1/pCK/TRWIST in primary tumors/SNs.

**Results:** The positivity of ALDH1 in primary tumor was frequently observed in HER2+ and triple negative types than Luminal type.

Furthermore, ALDH1 expression with pCK was more frequently observed in SNs than primary tumors and was localized in small nests and near hilum with various TWIST expression levels.

**Conclusions:** BCSC might be involved in progression of initial metastasis and in forming metastatic lesion of breast cancer with EMT phenotypes.

**Abstract ID: 1009**      Specific Field: **Breast Surgery**

**Mode of pres.: Free Paper**  
**ISW 2011 Session 108.07**

**Oncologic outcome of nipple-sparing mastectomy in 248 patients in single institution**

A. Koike, K. Tsugawa

St. Marianna University School of Medicine, Kawasaki, Japan

**Introduction:** Nipple-sparing mastectomy (NSM) is one of the available surgical options for breast cancer, but it has not been positively recommended by the clinical practice guidelines. However, some investigators had reported that no difference in the local recurrence rates and overall survival rates compared with the conventional total mastectomy. We reported the oncologic outcome of 248 cases underwent NSM, and discuss the indication for NSM for primary breast cancer.

**Material and Methods:** In our institute, the indication of NSM is no suspicious infiltration to nipple-areolar complex by preoperative MRI imaging, and negative subareolar biopsy by intraoperative frozen section. We performed the NSM for 248 patients during January 2000 to February 2010. We reviewed these cases and analyzed the risk factors of the local recurrence.

**Results:** The local recurrence rate after NSM was 3.2% (8 cases), and it was low compared with that after conventional total mastectomies in the same periods, 5.2% (45 examples in 867 examples). Furthermore, the localized nipple-areolar recurrence rate after NSM was low, 1.6% (4 cases), remarkably. We had confirmed these subareolar biopsies were negative both on the frozen and permanent histologic diagnosis. Relapse-free survival was mean 21.7 months in the 4 cases. Three cases had large tumors, mean 5 cm, and invasive ductal carcinoma. Two cases were operated after chemotherapy. However, the all of nipple-areolar recurrence sites were able to be detected easily, the recurrence sites were able to be excised easily, and the good cosmetic results were kept in the implant reconstruction cases.

**Conclusions:** The local recurrence rate after NSM was very low, so, NSM is considered to be a proper surgical option for breast cancer patients needing total mastectomies. However, we should keep that in our mind, it was possible that the nipple recurrence was occurred even if subareolar biopsy was negative.

**Abstract ID: 1010**      Specific Field: **Breast Surgery**

**Mode of pres.: Free Paper**  
**ISW 2011 Session 108.08**

**HOXB9, a gene promoting tumor angiogenesis and proliferation, is a significant prognostic factor for clinical outcomes in breast cancer**

H. Seki, T. Hayashida, H. Jinno, S. Hirose, M. Takahashi, M. Sakata, M. Mukai, Y. Kitagawa

Keio University, Tokyo, Japan

**Introduction:** HOXB9 is overexpressed in breast cancers, specifically in cancers with high histological grades. HOXB9 expression

promotes tumor neovascularization and metastasis in mouse xenograft models. Our study evaluates the correlation between HOXB9 expression, clinical outcomes, and the clinicopathological variables in breast cancer patients, and the contribution of HOXB9 expression to tumor cell proliferation and angiogenesis in human breast cancer.

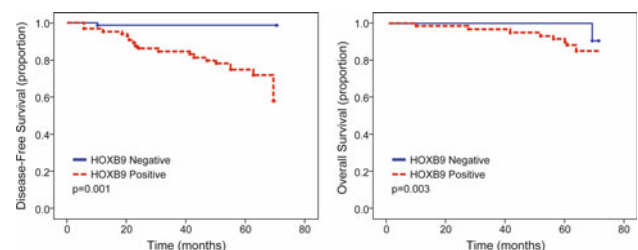
**Material and Methods:** A consecutive series of 141 patients with invasive ductal breast carcinoma who underwent surgical treatment from January 2004 to January 2005 were examined. HOXB9 protein expression in formalin-fixed, paraffin-embedded tumor sections was analyzed immunohistochemically using a rabbit anti-human HOXB9 polyclonal antibody. Immunohistochemical staining for Ki-67, CD31, and CD34 was performed to evaluate the association of tumor angiogenesis and proliferation with HOXB9 expression.

**Results:** Clinical outcomes significantly decreased in HOXB9-positive patients. Multivariate analysis indicated that HOXB9 expression was the only independent prognostic factor for disease-free survival. Larger primary tumor size, hormone-receptor negativity, HER2 positivity, higher nuclear grade, and the number of pathological nodal metastases are significant variables associated with HOXB9 expression. According to the intrinsic subtypes, basal-like breast cancer was significantly associated with HOXB9. In subgroup analysis, patients with strong HOXB9 staining showed a significant increase in the number of newly formed vasculature and the Ki-67 ratio in comparison with HOXB9-negative patients.

**Conclusions:** HOXB9 which enhances angiogenesis and proliferation in clinical tumor tissues can play a significant role as a molecular marker for the prognosis of breast cancer patients (Figure).

Correlation between HOXB9 expression, cell proliferation, and neovascularization

	HOXB9 negative N = 23	HNOXB9 strong staining N = 23	strong P value
Ki	4.5% (1–12.0%)	23% (8–70%)	0.016
CD31 median counts (range)	9.1 (3–20)	32.8 (16–70)	0.026
CD34 median counts (range)	16.7 (6.3–55.7)	46.2 (20.3–83.3)	



**Figure:** Kaplan

**Abstract ID: 1011**      Specific Field: **Breast Surgery**

**Mode of pres.: Free Paper**  
**ISW 2011 Session 108.09**

**Retrospective review of 251 cases of therapeutic mammoplasty for breast cancer from a multidisciplinary unit in South Africa: oncological and aesthetic outcomes**

A.V. Grubnik [1], C.A. Benn [1], G.R. Edwards [2]

[1] University of Witwatersrand, Johannesburg, South Africa,  
[2] Netcare Breast Care Centre, Milpark Hospital, Johannesburg, South Africa

**Introduction:** Therapeutic mammoplasty for breast cancer is a widely practiced oncoplastic technique. Recommendations on patient selection and method of margin assessment are not clearly established.

**Material and Methods:** Retrospective review of 251 consecutive breast cancer patients treated with therapeutic mammoplasty from 2002 to 2009 at Netcare Breast Care Centre. Patients with tumours less than 5 cm were included. Neo-adjuvant chemotherapy was used to downsize large tumours. All patients were referred for adjuvant radiotherapy. Intra-operative margin assessment was performed. Statistical analysis was performed using Kaplan-Meier estimates. Cosmetic outcomes were assessed by an independent review panel on photographic material.

**Results:** Mean age was 56.3 years (range 28–80). Mean tumour size was 15.4 mm. Mean resection weight was 237 g. Staging at presentation: T1 57, T2 29, T3 0.1, T4 2.8, Tis 10%. 64 (25.5%) patients received neo-adjuvant chemotherapy: decrease in size >50% in 24 cases, complete pathological response in 14 cases. Mean margin taken was 15 mm. Back to theatre rate was 2%. 222 patients underwent bilateral procedure. Contralateral occult disease was identified in 6 cases (2.4%). Early complication rate (<2 months) was 3.2%. Late complications related predominantly to adjuvant radiotherapy (20.7%). Mean follow-up was 39 months (range 8–97). 29 patients (11.5%) were lost to follow-up. Recurrence rate was 3.6%: locoregional recurrence in 6 patients with DCIS (2.4%); distant recurrence in 3 patients with high grade tumours (1.2%). Mortality rate was 3.2%: 7 patients had advanced breast cancer, 1 died of other causes. Overall survival was 96.8% metastasis-free survival was 95.2%. Excellent and good aesthetic results were achieved in 92.8% patients.

**Conclusions:** Neo-adjuvant chemotherapy allowed for therapeutic mammoplasty in patients with high tumour to breast ratio. Intra-operative margin assessment significantly decreased reoperation rate. Contralateral matching procedure resulted in histological detection of occult disease. Local recurrence was seen in patients with DCIS, in such patients an alternative procedure should be considered. Therapeutic mammoplasty is an oncologically appropriate and cosmetically favourable technique in breast conserving surgery.

**Abstract ID: 1012**      Specific Field: **Breast Surgery**

**Mode of pres.: Free Paper**  
**ISW 2011 Session 108.10**

**Evaluation of micrometastases in sentinel-node for breast cancer: results from Southeast-Sweden**

L.-G. Arnesson [1], H. Fohlin [1], S. Thorstensson [1], G. Tejler [2], M. Sundquist [2], B. Asking [2], P. Skogh [2], H. Olsson [2]

[1] Linköping University Hospital, Link, Sweden, [2] Surgical Department, University Hospital Linköping, Sweden

**Introduction:** When sentinel-node (SN) diagnostic was performed as standard in breast cancer surgery micrometastases in these sentinel-nodes got quite common. In Sweden we have handled them as macrometastases leading to further axillary surgery. A new discussion on axillary surgery after SN has started again but still longtime results are lacking on local relaps and survival without more surgery at positive SN.

**Material and Methods:** From the database on more than 12000 breast cancer patients going back from 1986 we have taken out data for sentinel-node operations the years 2003 to 2010. During these years 2553 sentinel-node procedures were done which is 63% of all axillary operations. 2003 only <30 mm tumours had SN surgery but

we have expanded possible SN-surgery to all tumours without any visible pathology on ultrasound in the axilla. The last 3 years 80% of axillary surgery had SN at the start.

**Results:** In 109 patients micrometastase was found in sentinel-node diagnostics as the only pathology (4%). Macrometastases in SN were shown in 446 cases (17.5%) and out of these 222 (50%) had no more positive nodes in the axilla at further surgery. Another 89 cases had only one positive non-sentinel node. Among the 109 patients with single micrometastases in SN 85 (78%) had no other mets at following surgery while 11 (46%) of the 24 remaining had only one positive non-sentinel node metastases. Comparing the two groups (85 no more mets and 24 with positive non-SN mets) we could not see any differences in the distribution of size, type of tumours or grade (NHG). For 53 cases data was available for vascular invasion but no difference was shown.

**Conclusions:** In our 109 cases with micrometastases as the only finding in the SN 22% had further non-sentinel node metastases and we still think this is a too high figure to leave the axilla with no more treatment. Probably some non-SN mets stay dormant or will be cured by adjuvant therapies but this should be proven in future randomised studies.

**Abstract ID: 1013**      Specific Field: **Breast Surgery**

**Mode of pres.: Poster Discussion**  
**ISW 2011 Session PW 10.01**

**Breast cancer in Southern Chinese: a population study by the Hong Kong Cancer Registry from 1996–2001**

A. Kwong [1], O.W.K. Mang [2], C.H.N. Wong [1], Hong Kong Breast Cancer Research Group [3], S.C.K. Law [2]

[1] The University of Hong Kong, Hong Kong, China, People's Republic, [2] The Hong Kong Cancer Registry, Hong Kong, China, People's Republic, [3] The University of Hong Kong, China, People's Republic

**Introduction:** The incidence of breast cancer in Hong Kong is 1 in 20 and is increasing being more noticeable in the younger age group. The more Westernized lifestyle may play a part to contribute to this. Understanding the epidemiological, disease pattern, treatment and outcome of these Chinese patients residing in Asia, based on population dataset is useful to provide a baseline study cohort for comparative studies of Asian Chinese in the West. This is the first comprehensive population based breast cancer study performed using the national database of the Hong Kong Cancer Registry.

**Material and Methods:** A retrospective review of medical records of breast cancer patients between 1st January 1997 to 31st December 2001 was performed. This was matched with the Cancer Registry's database, death register and Hospital Authority's data. Information obtained included risk factors, clinical management, pathology, date of diagnosis, last date seen, status last seen or cause of death. Multivariate analysis, t tests, chi-square and Fisher's exact tests were used for statistical analysis. Crude survival probabilities :overall survival, disease-free survival and disease-specific survival were calculated using the Kaplan-Meier method.

**Results:** A total of 8156 breast cancer patients's dataset were available during this period.7630 (94%) had invasive cancers and 526 (6%) were DCIS. Of the invasive cancers were diagnosed with breast cancer age 49 years old and below. The mean age of diagnosis being 55.3 and median age 52 years old. 81% had invasive ductal carcinomas and 3% had invasive lobular cancers. 39.2, 45.3 and 15.6% had Grade I, II, III cancer respectively. 4.8, 13, 55.4 and 26.5% had Stage 4, 3, 2 and 1 cancer respectively 61% were ER positive and 44% were HER2 positive cancers. 13.3% had triple negative cancers. 55.8% had



chemotherapy, 59% radiation therapy and 86% of those who had an ER positive cancer took tamoxifen. The 5 year overall survival, relative survival and cause-specific survival were 79.6, 84 and 85.2% respectively.

**Conclusions:** Cancer registries have been set up worldwide to provide information on cancers such as breast cancer. This information has been published in many Western countries but is much lacking in Asia. We performed a first comprehensive population based breast cancer epidemiology study in Southern China using the Hong Kong Cancer Registry database.

**Abstract ID: 1014**      Specific Field: **Breast Surgery**

**Mode of pres.: Poster Discussion**  
**ISW 2011 Session PW 10.02**

**Can preoperative breast MRI reduce re-excision rate in breast cancer and help decide extent of operation?**

Y. Law [1], P.S.Y. Cheung [2], S. Lau [2], G. Lo [3]

[1] Department of Surgery, Queen Mary Hospital, Hong Kong, China, People's Republic, [2] Breast Care Centre, Hong Kong Sanatorium & Hospital, Hong Kong, China, People's Republic, [3] Department of Diagnostic & Interventional Radiology, Hong Kong Sanatorium & Hospital, Hong Kong, China, People's Republic

**Introduction:** Breast MRI was emerging as a useful preoperative adjunct in determining exact disease extent. Recent COMICE trial concluded that MRI might be unnecessary to reduce repeat operation rates. Asian patients often have denser breast tissue than their counterparts. Usefulness of preoperative breast MRI in our locality is unclear.

**Material and Methods:** Total 712 breast cancer patients underwent operation by a single surgeon in Hong Kong Sanatorium and Hospital during the period 1/1/2006 till 31/12/2009. Those with (1) prior ipsilateral surgery except excisional biopsy ( $n = 14$ ); (2) neoadjuvant therapy ( $n = 37$ ); and missing data ( $n = 2$ ) were excluded, leaving 659 cases for analysis. Stratified into those received MRI (MRI+) and those not (MRI-), re-excision rates were compared as primary outcome.

**Results:** 147 had MRI done, most frequent indication being multiple indeterminate shadows on ultrasound (53.1%).

In the MRI-group, 16.3% needed re-excision after initial breast conservative surgery. In MRI+, this rate was 18.0% ( $P = 0.710$ ). All except one re-excision in MRI+ were due to touching DCIS margin rather than the main tumor. MRI+ had slightly higher final mastectomy rate compared to MRI- (39.5 vs. 31.8% respectively,  $P = 0.085$ ). However, MRI+ group had baseline characteristics of younger age ( $P < 0.001$ ), more premenopausal women ( $P < 0.001$ ), denser breast on mammogram ( $P = 0.003$ ) and more multi-focal tumor ( $P < 0.001$ ).

Within the MRI+ group, 66.0% (97 out of 147) had change in extent of operation, from lumpectomy to wider lumpectomy (23 out of 97), to mastectomy (47 out of 97), to bilateral lumpectomy (15 out of 97) and others (12 out of 97). Within this, 12 were considered inappropriately extensive due to false positive finding on MRI. Remaining 34.0% had no change in operation plan. In term of MRI detection of more extensive/multi-focal/multi-centric/contralateral disease, false positive rate was 12.8% and false negative rate was 7.5%, with corresponding sensitivity of 95.3% and specificity of 80.3%, if compared to final pathology.

**Conclusions:** Due to more complicated disease characteristics in MRI+ group, present study found no difference in term of re-excision rate. Management plan was modified in majority of MRI+ and most of it (87.6%) were considered appropriate. MRI demonstrated high sensitivity and moderate specificity in detection of more extensive/multi-focal/multi-centric/contralateral breast cancer.

**Abstract ID: 1015**      Specific Field: **Breast Surgery**

**Mode of pres.: Poster Discussion**  
**ISW 2011 Session PW 10.03**

**A qualitative study on psychosocial impact of contralateral prophylactic mastectomy among breast cancer female patients who underwent BRCA1 and BRCA2 genetic testing in Hong Kong China**

K.K. Ma, T.W. Chu, A. Kwong

The University of Hong Kong, Hong Kong, China, People's Republic

**Introduction:** To thoroughly examine the psycho-social impact of contralateral prophylactic mastectomy (CPM) among Hong Kong Chinese females with contralateral breast cancer history who underwent BRCA1/2 genetic testing. This aims to be first study of its kind in Chinese patients.

**Material and Methods:** 11 female BRCA1/BRCA 2 mutated gene carriers and 1 non-carrier with history of contralateral breast cancer and genetic testing performed by the Hong Kong Hereditary Breast Cancer Family Registry subsequently underwent CPM. They were surveyed by a face-to-face or telephone interview. Breast cancer history, types of prophylactic mastectomy and reconstruction, overall and cosmetic satisfaction, pain, body image and sexuality issues, cancer risk perception, with emphasis on exploring their perceptions were discussed. Retrieval of medical record using a prospective database was also obtained.

**Results:** Half of the participants who had CPM also underwent reconstruction. Most participants were satisfied with the overall results and 75% (9/12) thought they made the right decision. One-fourth of participants (3/12) expressed different extent of regrets. All opted for prophylaxis due to their reservation on the efficacy of surveillance. Most participants rated psychological relief and decreased breast cancer risk as major benefits. Sexually-inactive single participants appeared to adjust better to the cosmetic results of the surgery. Spouses' reactions and support were crucial for post-surgery sexual satisfaction.

**Conclusions:** Thorough education on cancer risk and realistic expectation of surgery outcomes are crucial for positive adjustment after CPM. Proper genetic and pre-and post-surgery psychological counseling were necessary and beneficial from patients' point of view. It may be helpful to involve spouses when counseling these patients.

**Abstract ID: 1016**      Specific Field: **Breast Surgery**

**Mode of pres.: Poster Discussion**  
**ISW 2011 Session PW 10.04**

**Information and rehabilitation needs of Indian breast cancer patients**

N. Kaur, R. Miglani, A. Gupta

UCMS & GTB Hospital, Delhi, India

**Introduction:** The diagnosis of breast cancer causes significant disruption to the quality of life (QOL). However in India, majority of breast cancers are still diagnosed at an advanced stage and achieving long term survival is the main priority. There has been little effort to address issues related to their QOL. This study was done to evaluate the QOL and information & rehabilitation needs of these patients

**Material and Methods:** This prospective cross sectional study was conducted at a University Hospital in Delhi. Women after treatment of breast cancer were enrolled. The quality of life was assessed by Functional assessment of cancer therapy-breast (FACT-B) version 4



and information and rehabilitation needs were enquired about in a semi-structured interview. Data was analysed using analysis of Variance (ANOVA) and multinomial logistic regression.

**Results:** A total of 154 patients were included and divided into three groups according to the follow up period (<2 years, 2–5 years and >5 years). The FACT-B mean scores improved over time. On analysis of individual items of different subscales, lack of energy and inability to meet the needs of the family, lack of support from friends, fear that the condition will get worse and loss of body image were significant factors contributing to poor quality of life. Analysis of semi-structured interview showed that these patients had many unmet information needs since they felt inhibited to discuss many issues with male surgeons. Sudden advice for expensive investigations also threw their financial planning out of gear. Their main rehabilitation needs were effective treatment of physical symptoms especially post-mastectomy pain, fatigue as well as menopausal symptoms induced by adjuvant therapies. They needed counselling about diet, exercise as well sexual dysfunctions which were experienced by 46% of patients. They also wanted counselling of their spouse (acute anxiety was noted in 32%). Advice for improvement of body image was also a major concern in the long term follow up.

**Conclusions:** A comprehensive follow up care program addressing information and rehabilitation needs will markedly improve the QOL of patients. Presence of a female member in the team is very desirable for conservative societies, so that women can discuss personal issues freely.

**Abstract ID: 1017**                      Specific Field: **Breast Surgery**

**Mode of pres.: Poster Discussion**  
**ISW 2011 Session PW 10.05**

**Incidence and risk factors of the intra-operative localization failure of non-palpable breast lesions by radio-guided occult lesion localization (ROLL): a retrospective analysis of 579 cases**

S. Bernardi [1], S. Bertozzi [1], A.P. Londero [2], V. Angione [3], G. Gentile [1], F. Giacomuzzi [4], A. Carbone [5], R. Petri [1]

[1] Department of Surgery, AOU “S M della Misericordia” of Udine, Udine, Italy, [2] Clinic of Obstetrics and Gynecology, AOU “S M della Misericordia” of Udine, Udine, Italy, [3] Department of Pathology, Azienda Ospedaliero-Universitaria di Udine, Udine, Italy, [4] Department of Nuclear Medicine, Azienda Ospedaliero-Universitaria di Udine, Udine, Italy, [5] Department of Radiodiagnostics, AOU “SM della Misericordia” of Udine, Udine, Italy

**Introduction:** The radio-guided occult lesion localization (ROLL) technique allows the identification of non-palpable breast lesions by means of the preoperative, intra- or perilesional injection of a radiotracer. Our study aims to determine the incidence and risk factors for the intra-operative localization failure of non-palpable breast lesions by ROLL.

**Material and Methods:** We collected data about all women who underwent ROLL in our Department from January 2002 to December 2009, focusing on patients’ characteristics such as breast size and density, lesion size, localisation, histology, radiologist and surgeon experience. Data was analyzed by R (version 2.10.1), considering significant  $P < 0.05$ . Also multivariate analysis was performed.

**Results:** 579 ROLLs were performed on 555 women with a mean age of 58.7 ( $\pm 10.96$ ). ROLL failure incidence at the first intervention was 4% (23/579). Through monovariate analysis, ROLL failure results significantly influenced by stereotactic mammography-guided procedure, invasive tumors, pathological and radiological lesion size 5 mm, and its location in the central or upper breast quadrants. Through multivariate analysis, the most predictive factors for ROLL failure are

as follows: lesion localization in the central quadrants, lesion radiological size 5 mm, and radiologist inexperience.

**Conclusions:** The literature lacks in data about ROLL failure. The main risk factors for ROLL failure are the radiologist inexperience, lesion size 5 mm, and its localization in the central quadrants, probably due to an unfavorable, radiological and surgical reaching of the breast area.

**Abstract ID: 1018**                      Specific Field: **Breast Surgery**

**Mode of pres.: Poster Discussion**  
**ISW 2011 Session PW 10.06**

**Expression of p53 protein in breast cancer: an immunohistochemical analysis of specimens in 334 Japanese women**

E. Akimoto, Kadoya, Noma, Itamoto

PrefecturalHiroshima Hospital, Hiroshima-ken, Japan

**Introduction:** p53 plays important roles on cellular functions such as cell cycle, apoptosis, DNA repair, and tumor vascularization. Since a mutation of p53 gene results in a prolonged half life of the p53 protein and accumulation of p53 protein in the nucleus, p53 protein expression has been identified as a poor prognostic factor in breast cancer. We investigate the value of p53 protein expression within 334 Japanese women with primary breast cancer.

**Material and Methods:** Estrogen receptor (ER), human epidermal growth factor receptor 2 (HER2) and p53 protein expression were determined by immunohistochemistry in primary invasive breast carcinoma of 334 Japanese patients diagnosed between 2001 and 2008 at Hiroshima prefectural hospital without distant metastasis at the time of surgery. The relationship between p53 protein expression and the disease free survival (DFS) was estimated by univariate and multivariate analyses.

**Results:** A cancer was classified as p53 positive when at least 50% of the tumor cell nuclei were immunoreactive. p53 protein expression was associated with tumor size, nodal status, ER status and Ki-67 LI on both univariate and multivariate analyses. Multivariate analysis for the DFS shows that p53 protein expression was not an independent prognostic factor.

**Conclusions:** Our findings indicated that the p53 protein expression was strongly related to tumor size, the nodal status, ER status and Ki-67 LI. But p53 protein expression in breast cancer is not an independent prognostic factor.

**Abstract ID: 1019**                      Specific Field: **Breast Surgery**

**Mode of pres.: Poster Discussion**  
**ISW 2011 Session PW 10.07**

**Three-dimensional virtual navigation biopsy of sentinel lymph node in patients with early breast cancer**

M. Funakoshi, Y. Fukuda

Hiroshima GeneralHospital, Hatsukaichi, Japan

**Introduction:** Before performing sentinel lymph node biopsy (SLNB) in breast cancer patients, metastasis of the axillary lymph node (LN) and the metastasis site need to be confirmed. For patients requiring SLNB, we performed a combination of three-dimensional computed tomography (3D-CT) and 3D-CT lymphography (3D-CTLG). We reimaged the 3D-CTLG image to the 3D virtual image for navigation surgery in order to increase the accuracy of breast cancer diagnosis.

**Material and Methods:** The adjustment stages for SLNB were Tis, T1-2, N0 patients. The pre operative treatment cases were out of adjustment. During 2009–2010, we studied 110 breast cancer patients. We diagnosed LN metastasis on the basis of laterality and LN size on the 3D-CT and 3D-CTLG scans. We classified the CTLG pattern into 3 types: uniform contrast, filling defect, and poor contrast. Iopamidol was injected subareolarly. Within 2 minutes of gentle massage of the injection site, we took 2 mm-thick cross-sectional CT images of the breast and the axilla. These images were reconstructed into 3D images by using Virtual Series (AZE company, Japan) to identify the location, size, and number of SLNs. 3D-CTLG with interstitial injection of the blue dye was used for the navigation of breast SLNB of all the subjects.

**Results:** The preoperative identification rate of SLNs by using both 3D-CT and 3D-CTLG was 94.5% (104/110). The preoperative identification rate of SLNs with blue dye and 3D-CTLG navigation was 96.3% (106/110). The average number of SLNs was 3.2. The false-negative identification rate was 5.5% (6/110). These 6 cases showed metastasis in only 1 SLN. Of these 6 cases, 1 case showed laterality in 3D-CT scan and poor contrast in 3D-CTLG image, 2 cases showed normal 3D-CT image and filling defect in 3D-CTLG image, and 3 cases showed normal 3D-CT and 3D-CTLG images.

**Conclusions:** 3D-CT and 3D-CTLG combined diagnosis of SLN are promising techniques for no diagnosis and identification of SLN location. Since false-negative cases show metastasis in only 1 SLN, we propose that axillary dissection in metastatic cases can be avoided after examining SLNB with 3D-CT and 3D-CTLG.

**Abstract ID: 1020**      Specific Field: **Breast Surgery**

**Mode of pres.: Poster Discussion**  
**ISW 2011 Session PW 10.08**

**Prognosis of breast cancer patients and non-sentinel lymph node status with micrometastatic sentinel lymph nodes**

T. Hayashida [1], H. Jinno [1], M. Takahashi [1], M. Sakata [1], M. Mukai [2], Y. Kitagawa [1]

[1] Keio University School of Medicine, Dept of Surgery, Tokyo, Japan, [2] Keio University School of Medicine, Dept of Pathology, Tokyo, Japan

**Introduction:** Sentinel lymph node biopsy (SLNB) is sensitive and accurate nodal staging procedure and its concept has been developed as a standard of care for patients with clinically node-negative breast cancer. Due to the improvement of pathological evaluation of SLNs, increased number of nodal micrometastases can be identified clinically. However, it remains controversial whether to perform ALND for patients with micrometastases in SLNs and their prognostic significance is also a matter of debate. The purpose of this study is to determine the non-sentinel lymph node (NSLN) status and prognosis of the patients with micrometastatic SLNs.

**Material and Methods:** A prospective database of 862 breast cancer patients with the tumor size less than 3 cm and clinical negative node, who underwent SLNB from January 2002 to Dec 2009 at Keio University Hospital was analyzed. SLNs were detected using a combined method of isosulfun blue dye and small-sized technetium-99m-labeled tin colloid. SLNs were diagnosed with standard hematoxylin and eosin (HE) staining and immunohistochemical (IHC) analysis.

**Results:** Micrometastases in SLNs were found in 65 (7.5%) of 862 patients. Thirty six (55.4%) of 65 patients with micrometastatic SLNs underwent ALND and revealed no NSLN metastasis. Among 29 (44.6%) patients with micrometastatic SLNs without ALND, 27 patients (93.1%) received adjuvant systemic therapy and no axillary lymph node recurrence has been observed during the median follow-up period of 43 months. In addition, there is no significant difference

in recurrence free survival between the patients with micrometastatic and negative SLNs (98.0 vs. 95.7%, respectively).

**Conclusions:** Our data suggests that it may not be necessary to perform ALND for the patients with micrometastases in SLNs. The presence of micrometastatic SLNs does not affect to patients' prognosis.

**Abstract ID: 1021**      Specific Field: **Breast Surgery**

**Mode of pres.: Poster Discussion**  
**ISW 2011 Session PW 10.09**

**Preliminary experiences of sentinel lymph node biopsy for breast cancer using a new camera for simultaneous capturing of color and near-infrared fluorescence indocyanine green**

N. Hokimoto, T. Sugimoto, T. Sato, T. Funakoshi, M. Ogawa, T. Namikawa, M. Kobayashi, K. Hanazaki

Kochi Medical School, Nankoku, Japan

**Introduction:** To compensate the limitations of conventional identification methods, using a colloid labeled with radio-isotope (RI) and blue dye, in sentinel lymph-node biopsy (SLNB) for early breast cancer, some new technologies had been developed in a recent time, including camera systems to visualize the near-infrared (NIR) fluorescence of indocyanine green (ICG) dye. It provides direct visual images of lymphatic pathway (LP), however; the anatomical relationship between ICG-enhanced structures and surrounding tissues could not be detected with previously available systems for capturing of monochrome images. To resolve these problems, we invented a new camera for simultaneous capturing of color and NIR fluorescence, named Hyper Eye Medical System (HEMS). The purpose of this study is to evaluate usefulness of HEMS in SLNB.

**Material and Methods:** Between April 2007 and March 2009, we performed SLNB using HEMS in consecutive 92 patients with histologically confirmed breast cancer, tumor size <3 cm and clinically node negative. After sub-dermal injection with ICG dye around the areola, the subcutaneous LPs were observed on the color monitor. The conventional combination methods of RI and indigo carmine dye were simultaneously performed.

**Results:** In all 92 patients, SLNs were successfully visualized by NIR fluorescence. Moreover, the images of HEMS can be used as a real-time intra-operative navigator. The sensitivity, positive predictive value and accuracy to predict plural SLNs by the number of LPs were 77.8, 45.2 and 70.8%, respectively, in 72 patients.

**Conclusions:** HEMS is expected to be a new identification method to compensate conventional methods.

**Abstract ID: 1022**      Specific Field: **Breast Surgery**

**Mode of pres.: Poster Discussion**  
**ISW 2011 Session PW 10.10**

**A phase I/II study of intraoperative radiotherapy for early breast cancer in Japan**

M. Sawaki [1], Y. Itoh [2], T. Imai [1], T. Kikumori [1], S. Sato [1], S. Ishihara [2], Y. Aoyama [2], A. Nakao [3]

[1] Department of Breast and Endocrine Surgery, Nagoya University School of Medicine, Nagoya, Japan, [2] Department of Radiology, Nagoya University School of Medicine, Nagoya, Japan, [3] Department of Surgery II, Nagoya University School of Medicine, Nagoya, Japan

**Introduction:** Intraoperative radiotherapy (IORT) is under evaluation in breast conserving surgery. We started our study; the first step has been a phase I–II study. This study was designed to identify the recommended dose and to test the feasibility and tolerance of IORT in Japanese patients.

**Material and Methods:** This is a single arm non-randomized phase I/II trial, which was approved by the research ethics review committee (Registry ID: UMIN00000918). A phase I study was designed using a scheme of dose-escalation from 19, 20, and 21 Gy. At the recommended dose, we designed the phase II study. Primary endpoint was early toxicity. Secondary endpoints were efficacy for a long period and late toxicity. Inclusion criteria: (i) T <2.5 cm, (ii) age >50 years, (iii) surgical margin >1 cm, (iv) intraoperative pathologically free margins, v) sentinel node negative. The operative procedures were performed as follows: (i) Sentinel lymph node biopsy. (ii) Partial resection with at least a one cm margin around the tumor. (iii) Microscopic assessment of margins by frozen sections. (iv) To protect the thoracic wall, an acrylic resin-Cu disk was placed between the gland and the pectoralis muscle.v) Radiation was delivered directly to the mammary gland employing a MOBETRON®. Toxicity was evaluated by the National Cancer Institute Common Terminology Criteria for Adverse Events (NCI CTCAE), version 3.0.

**Results:** Nine patients were enrolled for phase I study, and all patients were tolerable and then we recommend 21 Gy. The Following 23 patients were enrolled in a phase II study and received 21Gy. After a median follow up of 23.0 months (range: 8.0–36.5 months), their toxicities who received 21 Gy within 3 months were: deep connective tissue fibrosis (G1: 23/26, G2: 2/26), hematoma (G1: 9/26), infection in the musculo-skeletal soft tissue (G1: 4/26), soft tissue necrosis (G2: 3/26), and breast pain (G1: 22/26). After 21 Gy, there was no increased fibrosis, or necrosis compared to 19 or 20 Gy. There have been no local recurrence cases.

**Conclusions:** The first group of patients treated with IORT in the phase I/II study was tolerated very well in Japanese women. This constitutes a first report of feasibility of 21 Gy for Asian breast cancer patients. A longer follow up is needed for the evaluation of the late side effects and recurrences.

**Abstract ID: 1023**      Specific Field: **Breast Surgery**

**Mode of pres.: Poster Discussion**  
**ISW 2011 Session PW 10.11**

**The relevance of breast cancer subtypes in the response of neoadjuvant chemotherapy**

S. Takayama, J. Matsui, N. Ando, F. Asahara, S. Hoshimoto, H. Harada, S. Ogawa, M. Sato

Tokyo Dental College Ichikawa General Hospital, Chiba, Japan

**Introduction:** Neoadjuvant chemotherapy has been widely used for patients with operable breast cancer in Japan. A concept of intrinsic subtype in breast cancer has spread all over the world, and medicinal treatment against breast cancer has changed on the basis of the breast cancer subtypes. The purpose of this study was to assess the relationships between receptor-based subtypes and pathological evaluation after neoadjuvant chemotherapy.

**Material and Methods:** One hundred fifty five patients of primary breast cancer operated in our institution from April, 2008 to July 2010. A consecutive series of 35 patients(22.6%) treated with neoadjuvant chemotherapy was analyzed. Tumors were divided according to their receptor status in estrogen receptor (ER), Progesterone receptor (PgR), and HER2 status (HER2). ER positive and/or PgR positive, and HER2 negative is classified into luminal A type, ER

positive and/or PgR positive, and HER2 positive is luminal B type, ER negative and PgR negative, and HER2 negative is triple negative type, and ER negative and PgR negative, and HER2 positive is HER2 type. We studied the correlation of pathological evaluation and breast cancer subtypes.

**Results:** The overall pCR (Grade 3 only) rate was 28.5% (10 of 35). In luminal A type, there was no pCR case. And it was 36.4, 57.1, and 40.0% in luminal B, triple negative, and HER2 type, respectively. Quasi pCR (Grade 2b and Grade 3) was 56.5% (13 of 23) in the three groups except luminal A, and 64.3% (9 of 14) in the cases who were treated with trastuzumab.

**Conclusions:** Luminal B, triple negative and HER2 type patients have good response rate of neoadjuvant therapy compared with Luminal A. Breast cancer receptor-based subtypes might be predictive factors of response to neoadjuvant chemotherapy.

The Correlation of pathological evaluation and breast cancer subtypes

	Luminal A	Luminal B	Triple negative	HER2	Total
Grade 0	0	0	0	0	0
Grade 1	9	2	3	2	16
Grade 2a	2	2	0	1	5
Grade 2b	1	3	0	0	4
Grade 3	0 (0%)	4 (36.4%)	4 (57.1%)	2 (40.0%)	10 (28.5%)
Total	12	11	7	5	35

**Abstract ID: 1024**      Specific Field: **Breast Surgery**

**Mode of pres.: Poster Discussion**  
**ISW 2011 Session PW 10.12**

**The novel transporter, human nucleoside transporter 1 (hNT1), is a predictor of the effectiveness of combination therapy with-fluorouracil (5-FU) against advanced breast cancer**

T. Umemoto [1], Y. Kobayashi [2], A. Matsumiya [1], K. Hibi [1], T. Yamamoto [2]

[1] Showa University Fujigaoka Hospital, Yokohama, Japan,

[2] Showa University, Tokyo, Japan

**Introduction:** Combination therapy with fluoropyrimidine 5-fluorouracil (5-FU) is reportedly effective for the treatment of advanced breast cancer, but selection criteria for this therapy have not been clarified. In this study, we attempted to identify factors predicting the effectiveness of anticancer drug 5-FU.

**Material and Methods:** To search for a novel organic solute transport protein, we screened a human breast cancer cDNA library using an EST clone as a probe. To determine the functional characterization of the isolated transporter, we employed a *Xenopus laevis* (X.) oocyte expression system.

**Results:** After multiple rounds of screening, we isolated fifteen positive clones, and isolated a novel gene encoding human nucleoside transporter 1 (hNT1), from a human breast cancer cDNA library. Isolated hNT1 cDNA consisted of 246 base pairs that encoded a 82-amino acid protein. By RT-PCR analysis, hNT1 mRNA was detected in the normal breast and the breast cancer tissues. When expressed in X. oocytes, hNT1 mediated the high affinity transport of [<sup>3</sup>H]5-FU with a Km value of 69.2 ± 24.5 nM

in time- and pH-dependent, and Na<sup>+</sup>-independent manners. A cis-inhibition experiment revealed that hNT1 mediated transport of [<sup>3</sup>H]5-FU is strongly inhibited by antineoplastic agents (cisplatin and etoposide) and nucleic acids (pyrimidine, uracil, uridine, guanosine, inosine, thymidine, adenosine, cytidine and purine) suggesting that hNT1 may be involved in the membrane transport of these drugs and endogenous substrates. Immunohistochemical analysis revealed that the hNT1 protein is localized in the lactiferous duct epithelium.

**Conclusions:** A newly isolated hNT1 is a key molecule for the breast handling of 5-FU in humans, and a predictor of the therapeutic effect of 5-FU combination therapy against advanced breast cancer.

**Abstract ID: 1025**                      Specific Field: **Breast Surgery**

**Mode of pres.: Poster Discussion**  
**ISW 2011 Session PW 10.13**

**A survey of current knowledge and practices of general surgeons on hormonal treatment of breast cancer**

E. Novilla [1], S.S. Siguan [2], A. Arong [1], E. Castillo [2], A.F. Inot [2]

[1] Cebu Velez General Hospital-Perpetual Succour Hospital Consortium-Department of Surgery, Cebu City, Philippines,  
[2] Vicente Sotto Memorial Medical Center-Breast Center, Cebu City, Philippines

**Introduction:** Hormonal therapy is an important armamentarium in the management of breast cancer. General surgeons treating breast cancer patients must be adept with the various hormonal treatment strategies. No data has established the present level of knowledge and practices of general surgeons on hormonal treatment. The objective of this research is to determine the current knowledge and practices on hormonal treatment of breast cancer among general surgeons in the Philippines.

**Material and Methods:** This is a descriptive survey conducted in Cebu City and Metro Manila, Philippines on December 2009. A questionnaire embodying the vital questions is developed through a focused discussion by a group of general surgeons. Convenience sampling is utilized by administering these questionnaires to general surgeons and senior surgical residents present during the Annual Clinical Congress of the Philippine College of Surgeons. Incomplete questionnaires are excluded and responses are analyzed using descriptive statistics. A score of 75% in each category represents passing mark (knowledgeable or appropriate practices).

**Results:** A total of 389 respondents are included in the data analysis. Residency training is the most common contributor to their knowledge and practices regarding hormonal treatment (69.4%). Only 5.1% of the respondents are considered knowledgeable overall. A significant proportion are not knowledgeable with the clinical parameters on decision making and appropriate diagnostic tests to predict response (35.2%), the side effects of hormonal agents (20.8%) and on the spectrum and indication of hormonal agents (5.4%). Likewise, only 5.9% has appropriate practices on specimen preparation and biopsy techniques in determining hormonal status of the tumor, and 0.3% on the preferred hormonal manipulation/ablation techniques. Overall, only 3 surgeons (0.8%) have appropriate practices.

**Conclusions:** Majority of the respondent general surgeons are not knowledgeable on hormonal treatment in breast cancer and their practices are also inappropriate.

**Abstract ID: 1026**                      Specific Field: **Breast Surgery**

**Mode of pres.: Poster Discussion**  
**ISW 2011 Session PW 10.14**

**The role of sentinal lymph node biopsy in breast ductal carcinoma in-situ: a single institution review**

Z.J. Lo, E.Y. Tan

Tan Tock Seng Hospital, Singapore, Singapore

**Introduction:** Sentinal lymph node biopsy (SLNB) is the standard of care for patients with T1 and T2 invasive breast carcinoma without palpable lymph nodes. However, the role of performing SLNB in ductal carcinoma in-situ (DCIS) is still debatable. Although a positive SLNB has been reported in 6% to 13% of patients with DCIS, its clinical relevance remains undetermined. In this study, we aim to evaluate the status of SLNB in cases of surgery for DCIS where SLNB was done. We also aim to identify cases of DCIS where SLNB should be performed by determining how accurate a pre-op diagnosis of DCIS is and which factors may predict an upgrade of DCIS to invasive carcinoma.

**Material and Methods:** Retrospective review was performed for women diagnosed with DCIS who subsequently underwent wide excision or mastectomy at Tan Tock Seng Hospital, Singapore, during an 8-year period from 2001 to 2008. The clinical features and outcome of this group of patients were studied in detail. Cases of positive SLNB were described and multivariate analysis was used to identify relevant clinical, radiological and pathological factors that may identify cases of DCIS where an upgraded diagnosis of invasive carcinoma is likely.

**Results:** A total of 348 patients with DCIS on core-needle biopsy or excision biopsy were identified. Of 293 patients who underwent wide excision or mastectomy, 73 (24.2%) had a final diagnosis of invasive carcinoma. Multivariate analysis revealed that a palpable lesion, mass on mammography, microcalcification on mammography, suspicions of micro-invasion on pre-operative histology and necrosis on pre-operative histology were independent predictors of malignancy. Of the 127 patients who had SLNB, 5 (4%) had positive SLNB. Of these, 4 presented with palpable lump, 2 with mass on mammography, 2 with microcalcification on mammography, 2 with microcalcification on mammography, 2 had suspicious micro-invasive foci and 2 had necrosis on pre-operative histology.

**Conclusions:** Five factors: palpable lesion, mass on mammography, microcalcification on mammography, histological microinvasion and histological necrosis predict a post-surgical upgrade of DCIS to invasive carcinoma. These factors may be used to identify a subset of patients with DCIS who may benefit from SLNB.

**Abstract ID: 1027**                      Specific Field: **Breast Surgery**

**Mode of pres.: Poster Discussion**  
**ISW 2011 Session PW 10.15**

**Oncoplastic surgery in women over 70: a descriptive analysis of presentation and management**

A.V. Grubnik [1], C.A. Benn [1], G.R. Edwards [2]

[1] University of Witwatersrand, Johannesburg, South Africa,  
[2] Netcare Breast Care Centre, Milpark Hospital, Johannesburg, South Africa

**Introduction:** Women over 70 diagnosed with breast cancer are often offered radical methods of treatment for fear that reconstructive procedures will increase duration of operation and hospital stay, and thus morbidity. However, the paradigm is shifting towards assessing



the patients' physiological age, rather than chronological age. This retrospective analysis highlights oncoplastic surgery in women over 70 years.

**Material and Methods:** In a 10 year period (January 2000 to April 2010) 150 women aged over 70 were treated for breast cancer at Netcare Breast Care Centre. Data reviewed included: medical history, hormone replacement therapy (HRT) use, previous breast cancers, tumour size and biology. Patients undergoing primary chemotherapy or primary endocrine therapy were included. Patients undergoing breast cancer surgery were divided into those who had reconstruction (immediate and delayed), and those who elected not to have reconstruction. Therapeutic mammoplasty, expander-prosthesis, and latissimus dorsi flaps were the types of reconstruction performed. All patients had a pre-operative anaesthetic assessment.

**Results:** 39 patients had no medical history (26%). 100 patients were on HRT (66.7%). 16 patients had previous breast cancer in the opposite breast (9.1%). Tumour histology: DCIS—16 patients, Paget's disease—3, invasive lobular carcinoma—21, invasive ductal carcinoma—135.30 patients had primary chemotherapy, 19 had primary endocrine therapy. 10 patients had surgery elsewhere prior to presentation, 27 patients elected not to have reconstruction. Patients that underwent oncoplastic surgery: 29 had prosthetic reconstruction, 13 had latissimus dorsi flap, 65 had therapeutic mammoplasty, 1 patient had an advancement flap and 5 patients had delayed reconstruction. Complication rate was less than in patients under 70 in the same unit. Average duration of hospital stay was 2.2 days, and remained within the range of patients under 70 in the same unit.

**Conclusions:** The standard approach to surgery in patients over 70 should not be avoided based on concerns for prolonged hospital stay or increased morbidity. A wide variety of oncoplastic techniques can be safely used in these patients. Age alone should not preclude immediate breast reconstruction in suitable patients.

**Abstract ID: 1028**      Specific Field: **Breast Surgery**

**Mode of pres.: Poster Discussion**  
**ISW 2011 Session PW 10.16**

**Epidemiology of surgical breast disease in a resource-poor setting: an analysis of post-disaster Haiti**

C. Hughes [1], K. Nash [1], B. Alkire [1], T. Pauyo [2], D. Bayne [2], C. McClain [1], J. Meara [1]

[1] Childrens Hospital Boston, Boston, USA, [2] Harvard Medical School, Boston, USA

**Introduction:** The volume and types of surgical diseases of the breast is largely unknown in resource-poor settings. Given the high known burden of breast cancer and breast pathology throughout the world, the total need for breast surgery is likely high, especially in remote regions where advanced diagnosis is limited. The goal of this study is to describe the epidemiology of breast pathologies in a resource-poor setting, to describe the ability of an existing hospital system to respond to the need for breast surgery, and to determine trends in breast surgical volume in the setting of an acute natural disaster.

**Material and Methods:** A retrospective review of hospital operative logs was conducted at five main Partners in Health/Zanmi Lasante (PIH/ZL) delivery sites throughout Central Haiti. All consecutive procedures performed in the operating room were included from July 2009–August 2010.

**Results:** 155 of 4748 total surgical procedures were performed for diseases of the breast over the 12 month study period (3.2%). 120 of

155 patients were female (77.4%), and the mean age at operation was 35.5 years (SD = 14.9 years). The most common operative diagnosis was uncharacterized breast mass (42.6%), followed by a formal diagnosis of breast cancer (28.4%). Most patients received excisions (41.3%), partial mastectomies (28.4%), or biopsies (10.3%). There were nine axillary dissections performed and no recorded reconstructive procedures. In a univariate analysis, breast surgery comprised fewer total procedures in the six months after the earthquake than prior (2.7 vs. 4.1%, respectively;  $P = 0.006$ ). In a multivariable analysis, the first two months immediately following the earthquake had statistically fewer surgical breast procedures ( $P = 0.03$  for January and  $P = 0.003$  for February), but no individual month thereafter demonstrated a significant difference with respect to volume of breast surgery.

**Conclusions:** Surgical diseases of the breast constitute a significant and underestimated problem in resource-poor settings. Even in areas with an acute need for emergency services like post-earthquake Haiti, essential demand still exists for common surgical diseases. This likely represents a fraction of the true need within resource-poor communities, and systems that are already resource-limited may struggle to meet essential surgical demand in times of acute disaster.

**Abstract ID: 1029**      Specific Field: **Breast Surgery**

**Mode of pres.: Poster Discussion**  
**ISW 2011 Session PW 10.17**

**BRCA mutation detection rate in breast cancer patients at Tygerberg Hospital, Western Cape**

K.J. Baatjes, J.P. Appfelstaedt

University of Stellenbosch, Cape Town, South Africa

**Introduction:** Breast cancer remains one of the most frequent tumours in females. BRCA1 and BRCA2 genes play a major role in the hereditary susceptibility for this disease and accounts for approximately 5% of cases. In a developing country, lack of supporting services such as clinical genetics, means that surgeons often have to take the initiative in establishing such services in the management of breast cancer. We here present an audit of testing for disease causing BRCA mutations in a diverse patient population of Afrikaner, Xhosa and mixed ancestry with a high incidence of breast cancer.

**Material and Methods:** An audit was conducted for breast cancer patients undergoing BRCA diagnostic testing from March 2005 to November 2010. Initial testing was for 3 Afrikaner 'founder' mutations and occasionally for other common mutations. A subgroup underwent protein truncation testing (PTT) for selected exons. Indications for testing were age <35 years, bilateral breast cancer at any age, women with multiple family members with breast and/or ovarian cancer and all male patients with breast cancer.

**Results:** Two hundred and twenty-one patients were tested, 35 (15.7%) had BRCA mutations. Of the 221 patients tested for common mutations, 23 (10.3%) had Afrikaner 'founder' mutations (15 had the BRCA2 8162delG mutation) and 11 had one of the other 'less common mutations'. A positive PTT was observed in only 9 (7%) of 130 patients tested. None of the 7 patients who underwent full sequencing were found to have pathological mutations. Four of thirteen males tested positive for BRCA mutations.

**Conclusions:** The 10.3% detection rate for the common mutation testing is good, considering the broad clinical criteria applied, and the diverse patient population. The BRCA2 8162delG mutation was detected in 7.1% of all patients tested and was particularly common in

patients of Afrikaner and mixed ancestry. This study supports the use of non-stringent criteria for common mutation testing even in a diverse population, but PTT should be more carefully targeted. The rapid spread of the availability of genetic testing and the potential influences on the management of the individual patient make it imperative that surgeons know the indications and implications of genetic testing and be able to apply it in the management of breast cancer in a multi-disciplinary setting.

**Abstract ID: 1030**      Specific Field: **Breast Surgery**

**Mode of pres.: Poster Exhibition only**  
**ISW 2011 Session PE 403**

#### **Nipple discharge and breast carcinoma**

J. Gatek, P. Vazan, P. Kosac, L. Hnatek, B. Dudesek, J. Duben

Department of Surgery Atlas Hospital Zlin, University of Tomas Bata Zlin, Zlin, Czech Republic

**Introduction:** Nipple discharge is usually caused by benign lesion as ductectasia, fibrocystic changes and papilloma but also it could be first symptom of breast carcinoma. Especially single duct discharge requests special attention. Aim of this study was to review the pathological findings in our patients.

**Material and Methods:** Between January 2004 and December 2009 at Department of Surgery at Atlas hospital in Zlin 516 patients were operated on with breast cancer 516 and 385 with benign lesion. Nipple discharge was cause of the surgical procedure in 15 cases. Routinely there were preoperatively performed detailed clinical examination, cytology, sonography and mammography. Successful ductography was made in one third of the patients. Ductoscopy was unobtainable.

**Results:** Only patients, who were operated on, were included in the file. Mean age was 50, 5 years (from 35 to 68). No suspicious palpable and visible mass was detected on sonography and mammography. Ductography revealed intraductal papilloma 2×. Cytology was in 12 patients negative, atypical was 2×, malignant cell was detected only 1×-DCIS. Cytology of the patient with intraductal papillo Ca was negative. Nipple discharge was accompanied with one or more episode of sanguinary secretion in all patients. Histopathology results were 13× benign: Intraductal papilloma 6×, papillomatosis 2×, fibrocystic disease 3×, mastitis 1×, atypical ductal hyperplasia (DIN 1b) 1×, DCIS 1×, intraductalpapilloCa 1×. Dochectomy was performed 13× and 1× breast preserving procedure with sentinel node biopsy. Mastectomy and sentinel node biopsy was performed in patient with DCIS because we have not been able to rich free margins. We have recorded 1× recurrence discharge with papilloma situated direct in mamma.

**Conclusions:** Nipple discharge may cause anxiety, discomfort of the patients. Fear from breast carcinoma could influence quality of the life. Our results confirmed that nipple discharge, as first symptom of breast carcinoma is not so frequent. Cytology could set diagnosis but only surgery is able to exclude it.

**Abstract ID: 1031**      Specific Field: **Breast Surgery**

**Mode of pres.: Poster Exhibition only**  
**ISW 2011 Session PE 404**

#### **Skin sparing mastectomy and breast reconstruction for young women (<40 years) with breast cancer**

O.Z. Youssef

NationalCancer Institute, Cairo University, Cairo, Egypt

**Introduction:** Breast cancer is rare in women under 40 years and occurs in 2.5% in women younger than 35 years. Skin sparing mastectomy (SSM) has gained popularity over the last 15 years. The aim is to preserve the skin envelope in order to keep the natural look of the original breast including it's ptosis and contour.

**Material and Methods:** this is a retrospective study of 37 patients aged 40 years or less, who underwent SSM and immediate reconstruction from march 2005 to june 2009. Mean age of patients was 31 years (range 23–40 years) Types or reconstruction were: 14 extended latissimus dorsi (LD) myocutaneous flap, 13 pedicled transverse rectus abdominis myocutaneous (TRAM) flaps, 6 LD+ implants and 4 implants. Sixteen patients received preoperative chemotherapy while 27 patients received postoperative radiotherapy.

**Results:** Mean follow-up of patients was 23 months(range 7–67 months). Oncological results: six patients (16.2%) developed distant metastasis, one of them had also local recurrence (2.7%). Surgical complications: 3 patients developed breast skin flap necrosis, 1 TRAM flap partial necrosis, DVT (1), superior vena cava thrombosis (1).

**Conclusions:** Several studies have confirmed the oncological safety of skin sparing mastectomy compared to other types of mastectomy. It carries the same rate of surgical complications. It is a safe procedure for young women with breast cancer, but proper case selection is indicated.

**Abstract ID: 1032**      Specific Field: **Breast Surgery**

**Mode of pres.: Poster Exhibition only**  
**ISW 2011 Session PE 405**

#### **Estrogen progesterone receptor status in multiple fibroadenomas of breast in young females surgically resected by mammotome: initial results**

M. Baxi, R. Tangri, J. Baxi

International Oncology Centre, Fortis Hospital, Noida, Delhi, India

**Introduction:** Fibroadenomas classified as abnormality of normal development and Involution are benign but literature review reveal cases of malignancy in them. Unilateral/bilateral and multiple adenomas with chances of recurrence especially in young and middle ages are of great concern to patients due to fear of malignancy. Here is a study of multiple juvenile bilateral/unilateral fibroadenomas.

**Material and Methods:** 15 cases of multiple unilateral/bilateral ( $n = 5$ ) Breast fibroadenomaswere operated in young females (15–35 years) with the help of Mammotome (maximum 6–7 per breast). Hormone levels in blood and ER/PR receptor status of tumor was assessed in all of them. Patients were followed up 3 monthly with USG breast for recurrence. Short term Tamoxifen therapy (with close followup of endometrial thickening)was given to 12 patients.

**Results:** All tumors were positive for Estrogen and Progesterone receptors however serum hormone levels were normal. 15 months follow-up showed no recurrence or growth of residual tumors.

**Conclusions:** Assessing receptor status in benign tumors may be useful in selected cases as it can prevent recurrence of tumors by hormonal manipulation. Short term Tamoxifen may be controversial but useful for preventing recurrence as antiproliferative and need long followup in large number of patients. Surgery by Mammotome gives complete excision of tumors, biopsy diagnosis, excellent cosmesis and acceptance of surgery in young girls.

**Abstract ID: 1033**      Specific Field: **Breast Surgery****Mode of pres.: Poster Exhibition only**  
**ISW 2011 Session PE 406****A comparative study of partial versus total breast reconstruction: surgical, cosmetic and oncologic outcomes**

S.V.S. Deo, N.K. Shukla

All India Institute of Medical sciences, New Delhi, India

**Introduction:** Traditional surgical approaches for breast cancer include mastectomy, breast conservation surgery and Total-breast reconstruction (TBR). Recently with the introduction of breast oncoplasty newer surgical techniques like partial breast reconstruction (PBR) are increasingly being used. Currently there are no studies available comparing TBR versus PBR, hence this study was performed to evaluate the surgical, cosmetic and oncologic outcomes following TBR and PBR.

**Material and Methods:** A retrospective analysis of prospectively maintained breast cancer database of the department of Surgical Oncology, AIIMS, New Delhi was performed and the medical records of patients undergoing total and partial breast reconstruction between 2002 to 2007 were analyzed for clinical profile, operative details, adjuvant therapy details, cosmetic and oncologic outcomes.

**Results:** 45 patients had TBR using TRAM flap and 42 patients had PBR using Mini latissimus dorsi flap. The mean age in TBR was 44 years and PBR was 42 years. The mean tumor size was 3.2 cm in TBR and 3.6 cm in PBR group. Table 1 shows details of op-duration, hospital stay, morbidity and cosmetic outcomes in both groups. At a median follow-up of 32 months 1 patient each in TBR and PBR group developed local recurrence.

**Conclusions:** Similar group of breast cancer patients compete for TBR and PBR. Choice of procedure depends on the expertise and facilities available. Our experience has shown that the operative time, hospital stay and flap morbidity are higher for TBR. All the patients of PBR require post operative radiotherapy and majority will have some post radiation sequelae involving skin and breast parenchyma. Nipple areola preservation is a major advantage of PBR. Comparable loco-regional control rates can be obtained in PBR and TBR groups by adopting optimal oncosurgical techniques.

**Table 1:** Showing operative details, morbidity and cosmetic outcome

	Total breast reconstruction	Partial breast reconstruction
Mean operative duration (min)	340	220
Mean hospital stay (days)	12	8
Morbidity	Flap necrosis 5/45	Seroma 4/42
Cosmesis	Excellent/good 90%	Excellent/good 80%
Post RT skin/parenchymal changes	Nil	30/42 (70%)
Nipple areola preservation	8.8%	100%

**Abstract ID: 1034**      Specific Field: **Breast Surgery****Mode of pres.: Poster Exhibition only**  
**ISW 2011 Session PE 407****Is intramammary node a sentinel node?**

A. Dhar, A. Srivastava, P.K. Julka, M.C. Sharma

All India Institute of Medical sciences, New Delhi, India

**Introduction:** Wide local excision and preservation of the axillary nodes by SLNB has significantly decreased the morbidity seen post ALND. While planning for the patient we encounter difficult clinical situations where decision making becomes debatable. Two cases where WLE specimen had intra mammary lymph node (IMLN) with it, positive for metastasis along with SLNB negative.

**Material and Methods:** Two diagnosed case of breast cancer patients T1N0Mo for wide local excision and SLNB.

**Results:** Case 1 A 45 year female, diagnosed with breast cancer T1N0M0. WLE and sentinel lymph node biopsy identified with isotope and blue dye. Histopathology reported 2 cm tumor with tumor free margins along with a metastatic IMLN. Hot and blue SLN was negative for metastasis. Patient received whole breast radiotherapy and adjuvant chemotherapy. Patient is doing well after one year follow up. Case 2 A 38 year premenopausal with T1N0Mo, lump in upper outer quadrant of the left breast. Planned for WLE and SLNB. While doing the WLE, 2 cm away from the tumor edge a doubtful tissue was picked up for biopsy. Histopathology IDCof 2 cm size with tumor free margins, the doubtful tissue was reported as metastatic IMLN and blue and hot SLNB 4 (small cluster of nodes) in number were negative for metastasis. In this case ALND was done. To our surprise 8 out of 13 lymph nodes were reported positive. Patient was given whole breast radiotherapy and chemotherapy.

**Conclusions:** Consensus in literature with positive IMLN and negative SLNB is no further ALND required. Cases like above are debatable.

**Abstract ID: 1035**      Specific Field: **Breast Surgery****Mode of pres.: Poster Exhibition only**  
**ISW 2011 Session PE 408****Assessment of cosmetic outcome in Indian patients treated with breast conservative surgery**

A. Dhar, G. Adimulam, A. Srivastava, M. Singal

All India Institute of Medical sciences, New Delhi, India

**Introduction:** Breast conservative surgery along with radiotherapy has become now an alternative to mastectomy for breast cancer. But the aesthetic outcome was not satisfactory in 20–30% of patients. BCS has potential advantage of better cosmesis and body image but the results may due to loss in breast volume, length of scar, site of tumor, dose and timing of radiotherapy. Oncoplasty allows to remove large tumors with wider margins and better cosmetic results

**Material and Methods:** Thirty five patients with breast cancer were studied from November 2007 to October 2009. Patients with tumor size less than 4 cm, involving one quadrant of single breast without skin involvement or chest wall involvement were included. Various oncoplastic techniques were used to reconstruct after excision of tumor and adjuvant therapy given. Cosmetic outcome was assessed 6 months after surgery by nurse, plastic surgeon who were not involved

in treatment of patient and subjective assessment by the patient using a questionnaire.

**Results:** Of 35 patients studied 4 patients received neoadjuvant chemotherapy with tumor size less than 4 cm. Quadrantectomy was performed in 21 patients (60%), WLE in 14 patients (40%). 51% were extremely satisfied with cosmetic outcome, 48% were moderately satisfied, one woman was not satisfied because of radiation ulcer. 56% women were comfortable with bra, whereas 40% women were comfortable with minor adjustments.

**Conclusions:** Oncoplasty technique helps to give better satisfaction for patient preserving femininity.

## Abstract ID: 1036      Specific Field: Breast Surgery

**Mode of pres.: Poster Exhibition only**  
**ISW 2011 Session PE 409**

### A pragmatic approach towards management of benign breast lumps

N. Kaur [1], P. Pawar [1], N. Aggrawal [2]

[1] UCMS & GTB Hospital, Delhi, India, [2] UCMS & GTB Hospital, Delhi, India

**Introduction:** Despite a high prevalence of benign breast lumps, no clear cut protocols exist for their management. As a result, patients often undergo un-necessary investigations or surgery. This is largely attributed to multiplicity of classification systems and poor correlation between clinical, radiological and pathological features. Aberration of normal development and involution (ANDI) is the most comprehensive system of classification of benign breast diseases. We conducted this study on patients with benign breast lumps using ANDI to analyze data about their clinical, pathological and radiological features to define appropriate guidelines for management.

**Material and Methods:** This prospective observational study was conducted in the department of Surgery at a University hospital in Delhi. All patients with clinically benign Breast lumps were included and worked up with clinical details, USG/mammography and FNAC/Biopsy as indicated. Data collected was analyzed by simple descriptive statistics.

**Results:** A total of 186 patients with clinically Benign lumps were included. Their diagnosis were: 95 fibroadenomas (2 giant fibroadenomas), 60 mastalgia with nodularity (focal or diffuse), 9 only nodularity, 7 galactoceles, 6 breast cysts, 4 subareolar chronic abscess, 3 tubercular mastitis, 1 fat necrosis and 1 phyllodes tumor. For fibroadenomas diagnosis was confirmed by FNAC in 92%. Surgical excision was done in 73%. In none of the patients below 25, clinical diagnosis was wrong. In older patients 7 had proliferative breast disease on biopsy. All patients with diffuse nodularity underwent USG exam which showed either normal or prominent fibroglandular tissue. All 36 patients with focal lumpiness underwent triple assessment. FNAC was reported as proliferative lesion in 25, with atypia in 4. In 7 patients a malignancy was found. FNAC was diagnostic in all patients with galactocoele, tubercular mastitis, breast cysts and subareolar chronic abscess. Complex cyst required excision in 1 patient.

**Conclusions:** Fibroadenoma in women below 25 years as well as diffuse nodularity can be accurately diagnosed on clinical examination alone. Clinical exam combined with FNAC can accurately diagnose fibroadenomas (in older women), breast cysts, galactoceles, chronic subareolar abscess and tubercular mastitis. Triple assessment is required only for patients with focal lumpiness or dominant irregular lumps.

## Abstract ID: 1037      Specific Field: Breast Surgery

**Mode of pres.: Poster Exhibition only**  
**ISW 2011 Session PE 410**

### Cystosarcoma phylloides: a rare neoplasm but recurrent disease

A. Mishra, D. Singh, V. Jain

CSM Medical University, Lucknow, India

**Introduction:** Not even a single morphologic finding is reliable in predicting the clinical behavior of cystosarcoma phylloides (CP). Aim of this study was to explore the clinicopathologic factors associated with recurrent CP.

**Material and Methods:** We retrospectively reviewed records of 19 patients seen at single unit in department of surgery, CSM medical university hospital from July 2007 to October 2010. Demographic, clinical data were analyzed included age, symptoms and signs, tumor size, location, type of previous surgery, time to recurrence, and metastasis.

**Results:** All patients had first surgery at other hospital. Histopathology report of 13 patients with recurrent CP was benign and review of blocks ( $n = 11$ ) yielded 6 benign, 3 borderline and 2 malignant lesions. Mean age at was 30 years. Mean time to recurrence between the first surgery and consultation was 13 months. 5 patients had 3 previous surgery. Mean size was 9.5 cm. The majority of tumors were occupying the area below scar of previous surgery. Local wide excision and mastectomy was possible in 16 cases. Axilla was not dissected. Only 6 patients with malignant histopathology received locoregional RT. Three recurrence in mean FU of 6 months was noted.

**Conclusions:** Surgical approach, and inadequate surgical margin were correlated with recurrence. Local wide excision with passing in healthy tissue or mastectomy is the operation of choice.

## Abstract ID: 1038      Specific Field: Breast Surgery

**Mode of pres.: Poster Exhibition only**  
**ISW 2011 Session PE 411**

### Breast cancer-reversed axillary mapping (RAM): feasibility of a new technique

A.V. Pais, C.U. Poovamma

Mazumdar-Shaw Cancer Centre, Bangalore, India

**Introduction:** Surgical interventions for breast cancer has become progressively less morbid, radical mastectomy has been replaced with skin-sparing mastectomy or breast conserving surgery and complete axillary clearance has been replaced with sentinel node biopsy in women with clinically node negative breast cancer. But axillary dissection is still the standard of care for node positive cases. The incidence of upper limb edema is 10–20% when axillary dissection is carried versus 0–10% when sentinel biopsy is done. Lymph edema of the arm and hand impairs quality of life. Various studies have described the existence of distinct and nonoverlapping nodes for the arm and the breast, offering the possibility of resecting the breast nodes while sparing the arm nodes to bring down the incidence of lymph edema.

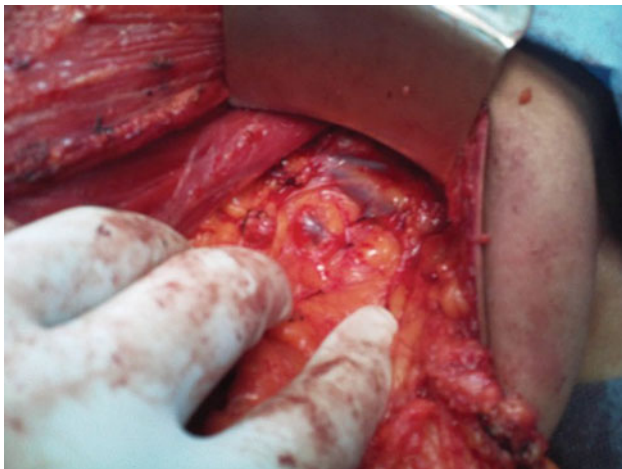
**Material and Methods:** Patients undergoing modified radical mastectomy were invited to participate in the study. Informed consent was taken. 1 ml of methylene blue was injected intradermally on the medial side of the arm. On opening the axilla, the site of the blue



colored nodes were noted and complete axillary dissection was carried out. The blue colored nodes were analyzed separately in addition to the axillary nodes.

**Results:** 30 patients were included in the study. 15 patients had LABC and had received neoadjuvant chemotherapy. RAM lymph nodes were identified in 100% of the patients. In early breast cancer patients none of the RAM lymph nodes were positive for malignancy. Among the patients with LABC, who received neoadjuvant chemotherapy, 6 pts had poor clinical response. In this group the RAM and breast nodes were positive for malignancy. In 8 pts who had good clinical response the RAM and breast nodes was negative for malignancy. 1 patient with CR had a positive breast node but negative RAM node. The RAM lymph nodes were in Level 1, situated along the superficial scapular vessels medial and lateral to it and inferior to axillary vessels. In 3 cases (20%) the nodes were above the axillary vessels.

**Conclusions:** In patients with early breast cancer and LABC with good clinical response to neoadjuvant chemotherapy, RAM lymph nodes may be preserved. However, due to the situation of these nodes it may not be possible to preserve them in all cases. However more clinical trials are required to validate these findings.



**Figure:** Axillary lymph node draining the arm

**Abstract ID: 1039**      Specific Field: **Breast Surgery**

**Mode of pres.: Poster Exhibition only**  
**ISW 2011 Session PE 412**

**The outcomes of sentinel lymph node biopsy in 110 patients with breast cancer**

Gh. Maddah [1], A. Abdollahi [2], M.N. Forghani [3], R. Sadeghi [4], H. Shaghayegh [1], A.R. Tavassoli [1], A. Jangjoo [2]

[1] Endoscopic and Minimally Invasive Surgery Research Center, Ghaem Hospital, Faculty of Medicine, Mashhad University of Medical Sciences, Mashhad, Iran, [2] Surgical Oncology Research Center, Imam Reza Hospital, Faculty of Medicine, Mashhad University of Medical Sciences, Mashhad, Iran, [3] Cancer Research Center, Omid Hospital, Faculty of Medicine, Mashhad University of Medical Sciences, Mashhad, Iran, [4] Nuclear Medicine Research Center, Imam Reza Hospital, Faculty of Medicine, Mashhad University of Medical Sciences, Mashhad, Iran

**Introduction:** Dissection of the axillary lymph nodes is considered as one of the common measures in management of breast cancer. Some complications such as edema, limitation in hand movement and seroma formation are observed with the dissection of these nodes. Thus, in case of negative sentinel lymph node, axillary lymph nodes dissection can be avoided.

**Material and Methods:** During a 3-year-study, 110 patients with stage I, II breast cancer were evaluated for sentinel lymph node in the Department of Surgery of Omid Hospital, Mashhad University of Medical Sciences. The patients were studied with two methods of injection of radioisotop TC99 and injection of patent blue.

**Results:** Overall, 90 patients had complete medical records and were included in the study. Frozen section was reported positive in 20 patients for whom the axillary dissection was performed. Frozen section was reported negative in 70 patients but permanent biopsy was positive in 3 patients, since these patients were in learning curves so axillary dissection was simultaneously performed for them. After learning curves no false negative cases were reported.

**Conclusions:** According to this study, approximately 20% of patients with stage I, II breast cancer require axillary dissection. With performing sentinel lymph node biopsy, the need for axillary dissection and its related high morbidity rate is decreased.

**Abstract ID: 1040**      Specific Field: **Breast Surgery**

**Mode of pres.: Poster Exhibition only**  
**ISW 2011 Session PE 413**

**Comparison between wire-hook localized breast biopsy and radio-guided occult lesion localization: a meta-analysis**

A.P. Londero [1], S. Bertozzi [2], S. Bernardi [2], R.J. Lell [3]

[1] Clinic of Obstetrics and Gynecology, AOU “S M della misericordia” of Udine, Udine, Italy, [2] Department of Surgery, AOU “S M della Misericordia” of Udine, Udine, Italy, [3] Clinic of Obstetrics and Gynecology, University, M, Germany

**Introduction:** Since the introduction of a mammographic screening program in many Countries, the detection of early-stage breast cancers has significantly increased, even though they are difficult to identify intra-operatively due to their little dimensions or anatomical location. As a consequence, different imaging guided procedures have been developed in order to accurately localize such non-palpable lesions. The most commonly used procedure is the wire-hook localized breast biopsy (WLBB), but alternative approaches have been described, because of its shortcomings. The radio-guided occult lesion localization (ROLL) represents an alternative to WLBB. Our aim is to compare WLBB with ROLL for the localization of non-palpable breast lesions.

**Material and Methods:** Three reviewers independently extracted data from randomized controlled trials included trials onto a standard form and assessed trial methodological quality. The data abstracted were relevant to predetermined outcome measures (technique failure incidence, disease-free margins, and prevalence of complications). Where appropriate, a summary statistic was calculated: a odds ratio for dichotomous data and a weighted mean difference for continuous data.

**Results:** Five eligible trials were identified. These included 546 women, 49% of whom were treated with ROLL. No significant differences were observed in technique failure incidence and prevalence of complications. Taking into consideration the lesion excision with disease-free margins, there was a statistically significant difference in favor of ROLL (OR 1.91, 95% CI 1.20–3.04, *P* 0.016).

**Conclusions:** The data comparing ROLL-guided procedures and WLBB remains too few to state a definitive answer, but the ROLL technique seems to be more effective in removing the lesion with disease-free margins, which is a really important result for the oncologic management. Therefore, in the perspective to avoid a second operative intervention, ROLL represents a promising approach for the resection of non-palpable breast lesions, and results at least equivalent if compared with WLBB in terms of easiness of the procedure, efficacy of lesion targeting and removing, and volume of the breast tissue excised.

**Abstract ID: 1041**      Specific Field: **Breast Surgery**

**Mode of pres.: Poster Exhibition only**  
**ISW 2011 Session PE 414**

**Combined fluorescence and dye method for sentinel node biopsy in early breast cancer**

A. Yamada [1], T. Chishima [1], M. Kimura [1], D. Shimizu [2], S. Hasegawa [1], T. Ishikawa [2], I. Endo [1]

[1] Yokohama City University, Yokohama, Japan, [2] Yokohama City University Medical Center, Yokohama, Japan

**Introduction:** Sentinel lymph node (SLN) dissection is now widely accepted for staging the axilla in patients with breast cancer. At present, several methods are used to detect SLN. A combination of blue dye and radioisotope (RI) has described as a superior method for detecting SLN in breast cancer patients. However, RI method requires expensive equipment, it can be used only certain institutions. SLN detection guided by indocyaninegreen (ICG) fluorescence could emerge as a new method for SLN biopsy (SLNB). The aim of this study was to evaluate SLNB using a combined fluorescence and dye method for breast cancer.

**Material and Methods:** Ninety-one patients with clinically node-negative breast cancer were examined between April 2009 and September 2010 at Yokohama City University Hospital. Intradermal injections of 20 mg/5 ml of indigocarmine and 0.5 mg/0.1 ml of ICG were performed in the upper-lateral region of the periareolar area. Subcutaneous lymphatic channels draining from the areola to the axilla can be visualized under fluorescence within a few minutes. SLNs were then dissected under direct vision supported by fluorescence navigation. Palpable lymph nodes around SLNs were also dissected. SLNs were histologically evaluated by HE stain at major axis in all patients. Patients with positive SLNs subsequently underwent axillary lymph node dissection (ALND), while patients with negative SLN did not.

**Results:** SLNs were identified in 90 patients (98.9%). ICG fluorescence imaging was compared with indigocarmine dye, and SLNs were identified in 89 and 85 patients, respectively (detection rate: ICG, 97.8%; dye, 93.4%). The mean number of dissected SLNs was 2.79. Mean numbers of lymph nodes showing fluorescence and blue stain from injected dye were 2.26 and 1.46, respectively. Fifteen of 91 patients (16.5%) had metastases detected in the SLN, so ALND were subsequently performed. Ten of these cases were without metastases at non-SLN that were dissected. Among all cases, 1 patient (1.1%) showed an SLN with neither fluorescence nor blue staining, and this case was detected by palpation only.

**Conclusions:** Combined use of fluorescence and dye method identified SLNs effectively. It would make a great benefit for institutes where the use of RI is limited.

**Abstract ID: 1042**      Specific Field: **Breast Surgery**

**Mode of pres.: Poster Exhibition only**  
**ISW 2011 Session PE 415**

**Impact of neoadjuvant endocrine therapy for patients with hormone receptor-positive breast cancer**

N. Hashimoto, K. Sugawara, Y. Ito, M. Kurushima, S. Nishikawa, K. Takahashi, T. Morita, F. Ota

Aomori Prefectural Central Hospital, Aomori, Japan

**Introduction:** High rate of pathological complete response (pCR) in patients with human epidermal growth factor receptor-2 (HER2)-positive breast cancer, and triple-negative breast cancer is reported. However, in patients with hormone receptor-positive breast cancer, pCR is difficult to achieve even with intensive neoadjuvant chemotherapy. We conducted this study to analyze the relationship between chemotherapy response and tumor characteristics to establish a clinical strategy for the treatment of luminal breast cancer.

**Material and Methods:** Between April 2009 and December 2010, 25 breast cancer patients treated with neoadjuvant chemotherapy or neoadjuvant endocrine therapy were evaluated in Aomori Prefectural Central Hospital. The patients with HER2-positive breast cancer received FEC100 followed by weekly paclitaxel and trastuzumab, and HER2-negative received FEC100 followed by taxane basically. The patients with hormone receptor-positive breast cancer were treated with chemotherapy combined with endocrine therapy or endocrine therapy alone.

**Results:** After neoadjuvant chemotherapy, 18 (72%) patients had partial response, 2 (8%) had stable disease clinically. 17 patients (68%) underwent breast-conserving surgery. After surgery, pathological complete response occurred in 3 patients (12%) who had all HER2-positive breast cancer. Because lower rate of pCR in ER-positive HER2-negative tumors had been observed, neoadjuvant endocrine therapy was performed in patients with hormone receptor-positive breast cancer since 2010. 3 patients with premenopausal breast cancer were treated with tamoxifen and LH-RH agonist, 5 patients with postmenopausal breast cancer were treated with anastrozole. Clinically 2 patients had progressive disease, and consequently underwent surgery. However, pathological partial response occurred in all patients with neoadjuvant endocrine therapy, which was comparable to the patients treated with both neoadjuvant endocrine therapy and chemotherapy.

**Conclusions:** Neoadjuvant chemotherapy is effective in patients with HER2-positive breast cancer. Neoadjuvant endocrine therapy benefits hormone receptor-positive breast cancer patients who have low rate of pCR with neoadjuvant chemotherapy. The response to neoadjuvant endocrine therapy will enable optimizing postoperative adjuvant therapy.

**Abstract ID: 1043**      Specific Field: **Breast Surgery**

**Mode of pres.: Poster Exhibition only**  
**ISW 2011 Session PE 416**

**A case of primary mammary malignant lymphoma successfully treated without partial mastectomy**

K. Hayashi, Y. Kosaka, N. Sengoku, T. Enomoto, M. Kuranami, M. Watanabe

Department of Surgery, Kitasato University School of Medicine, Sagami-hara, Japan

**Introduction:** Primary malignant lymphoma of the breast is a rare disease, accounting for 0.04 to 0.4% of all malignant breast tumors. The main treatments are mastectomy and chemotherapy. We describe our experience with a case of primary malignant lymphoma of the breast that was treated without performing partial mastectomy.

**Results:** A 61-year-old woman came to our hospital because of a mass in the right breast. The tumor measured 5.4 cm and was located in the lateral inferior region of the right breast. The nipple-tumor distance was 1 cm, and the mass was slightly soft and poorly demarcated. On palpation, the right axillary lymph nodes measured 2.2 cm. Ultrasonography revealed a clearly demarcated mass with a heterogeneous hyperechoic internal echo (4.9 3.8 2.1 cm) in the right breast; the axillary nodes measured 4.2 4.0 2.0 cm. Tumor markers such as carcinoembryonic antigen, CA15-3, and tissue polypeptide antigen were within normal ranges. The soluble interleukin-2 receptor level was high (2810). Malignant lymphoma was diagnosed on right axillary lymph node resection. The histopathological diagnosis was diffuse large B-cell lymphoma. The Ann Arbor classification was stage 2A. The diagnosis was a low-risk malignant lymphoma according to the international index. The patient was given R-CHOP therapy (rituximab, cyclophosphamide, Adriamycin, Oncovin, prednisolone). The tumor shrank remarkably from the first course of treatment, and the patient is still alive 7 years after chemotherapy.

**Conclusions:** Our experience suggests that primary malignant lymphoma of the breast might have a good response to chemotherapy alone, without partial mastectomy.

**Abstract ID: 1044**      Specific Field: **Breast Surgery**

**Mode of pres.: Poster Exhibition only**  
**ISW 2011 Session PE 417**

#### **Effect of exemestane on bone health of adjuvant treatment in postmenopausal women with early breast cancer**

A. Hirano, T. Shimizu, M. Kamimura, K. Ogura, N. Kim, Y. Setoguchi, F. Okubo, H. Inoue

Tokyo Women's Medical University Medical Center East, Tokyo, Japan

**Introduction:** Adjuvant therapy with aromatase inhibitors (AI) is associated with increased bone loss in postmenopausal women. We assessed changes in bone mineral density (BMD) from baseline to 48 months of treatment in patients receiving exemestane (EXE) as initial adjuvant therapy with/without oral bisphosphonates (Bis).

**Material and Methods:** Postmenopausal women with endocrine responsive breast cancer receiving EXE as adjuvant therapy at our hospital since 2004 were enrolled in this study. BMD was assessed by dual-energy X-ray absorptiometry at baseline and after 6, 12, 24, 36 and 48 months. Oral Bis (risedronate or alendronate) treatment was initiated when patients were diagnosed as having osteoporosis with a T-score of  $-2.5$  or lower.

**Results:** Eighty-six patients were enrolled in the study between 2004 and 2010. Patients' median age was 66.5 years and the median follow-up period was 640 days. Thirty-seven patients were administered Bis (risedronate in 22 patients, alendronate in 15 patients). Within 6 months of hormone therapy, BMD increased by 2.5% from baseline at the lumbar spine and BMD decreased by 0.6% at the femoral neck. However, BMD increased by 2.0% at the lumbar spine and decreased by 0.5% at the femoral neck for 3 years of treatment. In patients treated with upfront Bis ( $n = 19$ ), 5.0% BMD increase from baseline was noted at the lumbar spine whereas in those without Bis ( $n = 28$ ) BMD decrease by 0.8% from baseline within 12 months ( $P = 0.0057$ ). Fractures were observed in 5 patients (5.8%), and 4 patients (4.7%) had fragility fractures.

**Conclusions:** Oral Bis prevented EXE-induced bone loss, and upfront treatment of Bis significantly increased BMD at the lumbar spine.

**Abstract ID: 1045**      Specific Field: **Breast Surgery**

**Mode of pres.: Poster Exhibition only**  
**ISW 2011 Session PE 418**

#### **Phase II study on radiofrequency ablation for early breast cancer patients**

S. Imoto Graduate School of Medicine, Kyorin University, Mitaka, Japan

**Introduction:** We previously conducted phase I study on radiofrequency ablation (RFA) followed by breast-conserving surgery (BCS). Complete pathological ablation of breast tumor was shown in 26 of the 30 patients registered (87%). RFA was feasible and reliable for T1N0 breast cancer patients without extensive intraductal components (Breast, 18:130-4, 2009). To examine clinical utility of RFA instead of BCS, we are performing phase II study.

**Material and Methods:** T1 and sentinel node-negative breast cancer patients treated with or without primary chemotherapy are enrolled. Primary endpoint is breast deformity after RFA and secondary endpoints are ipsilateral breast tumor recurrence and quality of life examined with FACT-B. RFA is performed using a LeVein electrode and an RF-2000 generator (Boston Scientific Corporation, USA) following Izzo's protocol (Cancer, 92:2036-44, 2001). During and after RFA procedure, the skin surface on ablated tumor is cooled with crushed ice in a poly pack. Breast deformity and breast imaging are recorded at 3, 6 and 12 months after RFA.

**Results:** As of November 2010, 11 of the 13 eligible patients agreed to undergo RFA. There were no severe adverse events in all patients except pain relief with NSAID for a few days. Most patients received adjuvant therapy and breast irradiation. MR mammography showed degenerative change with ring enhancement that was consistent with red ring observed in the margin of ablated breast specimen at phase I study.

**Conclusions:** MR mammography is useful for monitoring ablated breast lesion. RFA is a promising technique for local control of breast cancer.

**Abstract ID: 1046**      Specific Field: **Breast Surgery**

**Mode of pres.: Poster Exhibition only**  
**ISW 2011 Session PE 419**

#### **Verification of surgical margin of breast conserving surgery after primary systemic chemotherapy by intrinsic subtypes**

T. Inaba, M. Kashiwaba, H. Komatsu, R. Kawagishi, N. Uesugi, G. Wakabayashi

Iwate Medical University, Morioka, Japan

**Introduction:** Primary Systemic Chemotherapy (PSC) seems common clinical practice increasing breast-conserving surgery (BCS) rate, however there are difficult cases to determine the surgical margins without residual diseases on the cut surfaces. In present study, we evaluated the relationship between optimal surgical margins and intrinsic subtypes in BCS.

**Material and Methods:** One hundred five patients who are >Stage IIA patients received PSC and were with complete pathological reports after BCS were analyzed. PSCs were performed as FEC100x4 followed by Docetaxel75 x4 q3W for HER2 negative and FEC100x4 q3W followed by Trastuzumab/Paclitaxel80mg qWx12 for HER2



positive. In brief, four directions of shaved edges determined by ultrasonography from resected tumor were pathologically diagnosed as surgical margin in operation until cancerous tissues were negative. Relationship between surgical margin status and intrinsic subtypes determined by immunohistochemistry were analyzed.

**Results:** In 1st set ( $n = 30$ ) with 1.5 cm margin, Luminal A (ER/PgR/HER2 +/+/-), Lumina B(+/+/-/+), HER2 (-/-/+) and Triple negative (-/-/-) showed positive margins at 33.3% (5/15), 0% (0/2), 33.3% (1/3) and 0% (0/5), respectively. In 2nd set ( $n = 75$ ) with 1.0 cm margin, each subsets showed 54.5% (18/33), 7.1% (1/14), 16.7% (2/12) and 20.0% (3/15), respectively.

**Conclusions:** Present study realized that surgical margin must be determined carefully after evaluation of residual patterns depending on intrinsic subtypes. Especially, Luminal subtypes tend to have not evaluable lesion ahead of ultrasonographically visible margin so that enough margin have to be designed to reduce frequency of examinations for additional margins and to shorten operation time. The latest results with additional cases will be presented at the meeting.

**Abstract ID: 1047**      Specific Field: **Breast Surgery**

**Mode of pres.: Poster Exhibition only**  
**ISW 2011 Session PE 420**

**The predictive precision of the effect of neoadjuvant chemotherapy for the breast cancer by CEUS, comparison between MRI**

S. Kanazawa [1], H. Ogata [1], S. Magoshi [1], F. Saito [1], A. Mitsuda [2], T. Hatori [2], K. Shibuya [2], H. Kaneko [1]

[1] Toho University School of Medicine, Tokyo, Japan, [2] Toho University Medical Center Omori Hospital, Tokyo, Japan

**Introduction:** Under the approval of our institutional review board, we conduct written informed consent to the patients and are performing contrast enhanced ultrasonography (CEUS) using the second generation ultrasound contrast agent Sonazoid in addition to ultrasonography (US) for the breast disease. We combine contrast-enhanced ultrasonography of the breast using Sonazoid (CEUS) with effect measurement of neoadjuvant chemotherapy (NAC) for the breast cancer. We conducted an effect prediction of NAC for the breast cancer by contrast-enhanced MRI (MRI) and CEUS and compared diagnosis precision of MRI and CEUS.

**Material and Methods:** Sonazoid, a half of recommended dose was administered intravenously and was flashed in the speed of 1 ml/s by saline of 10 ml. We employed Aplio XG (Toshiba, Japan) as diagnostic device and used 8 Mhz linear probe (PLT-805AT). We compared the precision in 15 invasive ductal carcinomas. Nine lesions were Luminal A, and five lesions were Basal like, and, among 15 lesions, HER2 type was one lesion. The definitive effect measurement was determined from tumor diameter on the postoperative pathology specimen.

**Results:** The actual effects of NAC, two lesions were complete response (CR), and 13 lesions were partial response (PR). The actual effects were all the same as the effects that were predicted by CEUS. The effects that were predicted by MRI underestimated four lesions and overestimated two lesions. As for the effects prediction by MRI, six lesions were incorrect among 15 lesions. Especially in Basal like, a wrong prediction were done at 4 lesions among 5 lesions.

**Conclusions:** As for the precision of the effect prediction of the neoadjuvant chemotherapy for the invasive ductal carcinoma of the breast, CEUS exceeded MRI. Especially, the effect prediction precision of the MRI was low in Basal like which may be difficult of the treatment.

**Abstract ID: 1048**      Specific Field: **Breast Surgery**

**Mode of pres.: Poster Exhibition only**  
**ISW 2011 Session PE 421**

**Sentinel lymph node biopsy in patients with breast cancer using superparamagnetic iron oxide and a magnetometer**

O. Katsube, M. Shiozawa, M. Takehara

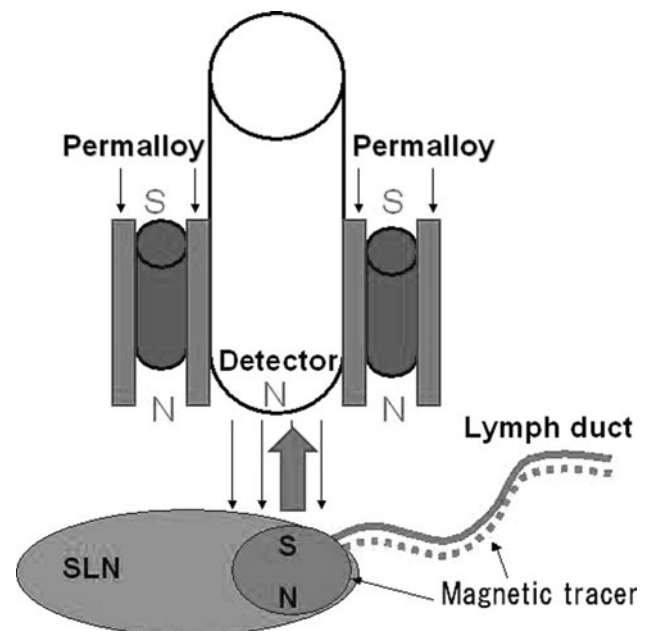
Jichi Medical University, Shimotsuke, Japan

**Introduction:** Sentinel lymph node biopsy (SLNB) is the standard of care for many patients with breast cancer, and is commonly done using a radioisotope (RI). However, throughout the world, many hospitals lack facilities for using RI. In this study, we developed a novel method using a superparamagnetic iron oxide (SPIO) tracer and a magnetometer instead of RI to perform SLNB.

**Material and Methods:** 30 patients were included in the study after obtaining IRB approval. Superparamagnetic iron oxide and patent blue dye were injected in the subareolar breast tissue. Following a few minutes of massage to promote migration of both magnetic tracer and dye, subcutaneous lymph nodes in the axilla were detected transdermally using the handheld magnetometer and harvested as the SLN. SLNB was followed by standard axillary dissection during the same operation in all patients.

**Results:** Of the 30 patients (mean age,  $58.2 \pm 11.3$  years), the rate of detection of SLN was 90% (27/30) by the combination of blue dye and the magnetic tracer. Seven cases had metastases to the SLN. There was one false negative, resulting in a sensitivity of 6/7 (85.7%) and an accuracy of 26/27 (96.2%). SLN were successfully identified by the magnetic method in 23/30 (76.7%).

**Conclusions:** This is the first study to evaluate the use of a magnetic tracer to identify SLN in patients with breast cancer, and demonstrates that the technique is safe and effective. In some institutions, this new technique may alter the role of RI with further refinement and experience.



**Figure:** Mechanism of Magnetometer



**Abstract ID: 1049**      Specific Field: **Breast Surgery****Mode of pres.: Poster Exhibition only**  
**ISW 2011 Session PE 422****Preoperative chemotherapy FEC100 followed by weekly paclitaxel for operable breast cancer**

H. Kawajiri, T. Takashima, S. Kashiwagi, N. Aomatsu, N. Onoda, B. Nakata, T. Ishikawa, K. Hirakawa

Dept. Surgical Oncology, Osaka City University Graduate School of Medicine, Osaka, Japan

**Introduction:** Sequential administration of anthracyclin and taxane in neoadjuvant chemotherapy (NAC) is now a standard treatment for operable breast cancer. Pathological complete response (pCR) is a significant predictor of overall survival (OS) regardless of treatment. We have retrospectively examined the pCR rate as efficacy and analyzed the characteristic of pCR cases.**Material and Methods:** Eighty-three female patients with locally advanced breast cancer who had been administered FEC100 followed by weekly paclitaxel in NAC, between December 2005 and December 2009 at the Osaka City University Hospital, were retrospectively reviewed. The patients were in the age range of 26–71 years (mean 52.1 years), in the tumor size range of 15–60 mm (mean 29.3 mm) and on stage 2A–3A. This study comprised 67 patients with axillary lymph node metastasis. Fifteen of HER-2 positive cases were administered weekly trastuzumab on paclitaxel. We evaluated the size of tumor and axillary lymph node by ultrasonography.**Results:** Thirty-three cases (40%) achieved pCR. Overall response rate was 90%. Only a case had progressive disease. Forty two out of 82 cases (51%) received breast conserving surgery. The pCR rate of patients with extensive lymph node metastasis and negative hormone receptor was significantly high. Febrile neutropenia occurred in 18 cases (22%) including 13 cases (16%) that required 3–7 days admission.**Conclusions:** FEC100 followed by weekly paclitaxel as a neoadjuvant chemotherapy regimen is very effective in the aspect of pCR rate especially in the patients with extensive lymph node involvement and negative hormone receptor.**Abstract ID: 1050**      Specific Field: **Breast Surgery****Mode of pres.: Poster Exhibition only**  
**ISW 2011 Session PE 423****Oncoplastic surgery combining partial mastectomy with reduction mammoplasty for Japanese patients with ptotic breasts**

Y. Kijima, H. Yoshinaka, S. Natsugoe, M. Hirata, T. Mizoguchi, A. Nakajo, H. Arima, S. Ishigami

Kagoshima University, Kagoshima, Japan

**Introduction:** Immediate volume replacement therapy using local flap or autologous graft according to tumor location is adequate technique for Japanese patients with small breasts. On the other hand, oncoplastic surgery combining partial mastectomy with reduction mammoplasty for Japanese patients with ptotic breasts is a new approach for patients with ptotic breasts. We here report an experience of it for Japanese patients.**Material and Methods:** Immediate volume replacement therapy using local flap or autologous graft according to tumor location is

adequate technique for Japanese patients with small breasts. On the other hand, oncoplastic surgery combining partial mastectomy with reduction mammoplasty for Japanese patients with ptotic breasts is a new approach for patients with ptotic breasts. We here report an experience of it for Japanese patients.

**Results:** Reduction types are J-mammoplasty (MP in 13 patients, lateral MP in 7, peri-areolar MP in 2, vertical-scar MP in 2, inverted-T in 2, and horizontal MP, amputation MP, radial MP, omega MP in one patient, respectively. Contralateral operation for a symmetry was done in 19 patients. Total operation period was 181 min (112–295) and 129 (67–210) min in bilateral group and ipsilateral group, respectively. Plastic period was 88 (40–230) min and 49 (31–66) min in each group. Resected amount of was 192 (69–306) g and contralateral tissue was 185 (70–302) g in bilateral group. Post-operative complications were axillary seroma in one, partial necrosis of nipple areola complex in 3, hemorrhage in 1, respectively. We could not detect any distortion, scar and calcifications on MG, US postoperatively.**Conclusions:** There are some problems to be solved; prolonged operation period and financial supports for cosmetic surgery of contralateral breasts. The procedure was done without any complications and cosmetic results are excellent.**Abstract ID: 1051**      Specific Field: **Breast Surgery****Mode of pres.: Poster Exhibition only**  
**ISW 2011 Session PE 424****Prognostic significance of p53 expression in the luminal type breast cancer**

S. Kikuchi [1], T. Osako [2], Y. Okumura [2], Y. Toyozumi [2], N. Arima [2], R. Nishimura [2]

[1] JSDF Kumamoto Hospital, Kumamoto, Japan, [2] Kumamoto City Hospital, Kumamoto, Japan

**Introduction:** The role of p53 expression in breast cancer is still unknown. It was reported that a Ki67 index was one of the markers to distinguish luminal A from luminal B subtypes.**Material and Methods:** A retrospective analysis was performed, including 1488 patients with primary breast cancer who received operations at our institution between 2001 and 2008. Among them, 1238 cases were luminal type (808 cases: luminal A type, 430 cases: luminal B type), 98 cases were HER2 enriched and 151 cases were triple negative (TN). Luminal A was defined as estrogen receptor (ER) positive cell rates 1% and HER2 negative, and luminal B was defined as ER and HER2 positive. Expressions of p53, HER2, Ki67 and ER/PgR were determined by immunohistochemistry. Moreover, tumor size, lymph node metastasis and nuclear grade were studied in relation to disease free survival (DFS) and overall survival (OS) by Cox univariate and multivariate regression analysis.**Results:** p53 overexpression was seen in 23% of the patients. In univariate analysis for DFS, p53, Ki67 and lymph node metastasis were significant, and for OS, p53, Ki67, tumor size and lymph node metastasis were significant in luminal type breast cancer. The patients with p53 overexpression had poorer prognosis. In multivariate analysis for DFS and OS, p53, Ki67 and lymph node metastasis were significant factors.**Conclusions:** The overexpression of p53 was a significant prognostic factor in luminal type breast cancer, suggesting that the p53 overexpression might be useful to distinguish luminal A from luminal B breast cancer subtypes.

**Abstract ID: 1052**      Specific Field: **Breast Surgery****Mode of pres.: Poster Exhibition only**  
**ISW 2011 Session PE 425****Endoscopic-assisted skin-sparing mastectomy with immediate reconstruction with muscle cutaneous flap**

N. Nagura [1], R. Uchida [2], M. Fujimori [1]

[1] Tokyo Medical University Ibaraki Medical Center Department of Breast Surgery, Ami Inashiki, Ibaraki, Japan, [2] Tokyo Medical University Ibaraki Medical Center Department of Plastic Surgery, Ami Inashiki, Ibaraki, Japan

**Introduction:** Breast-conserving surgery (BCS) is performed commonly for patients with early-stage breast cancer. However, residual tumors or deformation of the breast may occur after BCS for cases in which the tumor includes extended intraductal components. The purpose of this study was to perform endoscopic-assisted skin-sparing mastectomy (SSM) or skin-sparing partial mastectomy (SSPM) followed by immediate breast reconstruction with a muscle cutaneous flap for patients with this type of tumor.**Material and Methods:** Forty patients diagnosed with primary breast cancer underwent endoscopic-assisted SSM or SSPM at our hospital between April 2008 and January 2011. The patients had (1) widespread ductal carcinoma in situ (DCIS), (2) small invasive cancer with an extensive intraductal component, or (3) small multicentric cancer. All patients requested BCS, but were not eligible for standard BCS because of extensive intraductal cancer, the presence of multicentric tumors, or the possibility of severe breast deformation.**Results:** Immediate reconstruction was carried out with a latissimus dorsi flap in 36 patients and an abdominal rectus muscle flap in 4 patients. The postoperative pathological diagnoses were ductal carcinoma in situ in 16 patients and invasive ductal carcinoma in 24 patients. At the present time, neither locoregional recurrence nor distant metastasis has been detected in any cases.**Conclusions:** SSM or SSPM with immediate reconstruction with a muscle cutaneous flap provides high satisfaction and good visual effects for patients, and clinically gives good local control. Therefore, this procedure may be an effective treatment option for patients with widespread intraductal tumors.**Abstract ID: 1053**      Specific Field: **Breast Surgery****Mode of pres.: Poster Exhibition only**  
**ISW 2011 Session PE 426****Usefulness of salvage breast conserving therapy for patients with ipsilateral breast tumor recurrence**

S. Nishiya, H. Jinno, Y. Kitagawa

Keio University School of Medicine, Tokyo, Japan

**Introduction:** Mastectomy is considered the standard approach for ipsilateral breast tumor recurrence (IBTR) after breast conserving therapy (BCT). However, salvage BCT may be feasible for some patients with IBTR. The aim of this study is to elucidate the usefulness of a repeat attempt of BCT for patients with IBTR.**Material and Methods:** From January 1988 to December 2005, 877 patients with histologically confirmed breast cancer underwent BCT at Keio University Hospital. Among these 877 patients, 31 patients (3.5%) with IBTR were included in this study.**Results:** The mean size of the recurrent tumor was  $1.5 \pm 0.5$  cm. Twenty cases (64.5%) showed the recurrent tumor in the samequadrant as the primary tumor. Disease-free interval was 38.9 months (range: 5.2–165.4 months). Among the 31 patients with IBTR after BCT, 19 patients (61.3%) underwent salvage mastectomy and 9 patients (29.0%) underwent salvage BCT. Three patients (9.7%) do not undergo surgery because of their distant metastasis. Median follow-up period was 56.9 months. The 3-year overall survival in IBTR is 87.1%. Clinicopathological factors related to overall survival in patients with IBTR were nodal status (positive vs. Negative,  $P < 0.05$ ), disease-free interval (<2 years vs. >2 years,  $P < 0.05$ ), and vascular invasion (positive vs. Negative,  $P = 0.001$ ). There was no statistically significant difference of overall survival between patients treated with salvage mastectomy and salvage BCT ( $P = 0.238$ ).**Conclusions:** These data suggest that salvage BCT may be feasible for selected patients who are not candidates for a mastectomy.**Abstract ID: 1054**      Specific Field: **Breast Surgery****Mode of pres.: Poster Exhibition only**  
**ISW 2011 Session PE 427****Blood flow observation by Doppler ultrasound in the screening of breast diseases involving the nipple**

H. Ogata, Y. Suizu, Y. Kubota, F. Saito, S. Magoshi, S. Kanazawa, H. Kaneko

Toho University School of Medicine, Tokyo, Japan

**Introduction:** The diagnosis of breast diseases involving the nipple is often embarrassing because of their nonspecific clinical feature. We observed blood flow of nipple-areolar region by Doppler ultrasound and discussed the usefulness in the screening of breast diseases involving the nipple.**Material and Methods:** Subjects were 25 patients with the following diseases of the nipple: contact dermatitis ( $n = 4$ ), atopic dermatitis ( $n = 5$ ), mammillitis ( $n = 3$ ), Paget's disease ( $n = 4$ ), adenoma of the nipple ( $n = 1$ ), invasive ductal carcinoma ( $n = 4$ ) and normal control ( $n = 4$ ). Blood flow in the nipple was observed by color Doppler ultrasound (SSA-770A, Toshiba Medical Systems Corporation) and compared.**Results:** In the cases of contact dermatitis normal control, blood flow was not demonstrated with Doppler sound. In the case of atopic dermatitis, mild and symmetrical increases in blood flow were observed. For infectious breast disease, blood flow was increased on the affected side but decreased with improvement of infection symptoms. For Paget's disease and adenoma of the nipple persistent and marked increase in blood flow was observed in the affected nipple compared to the unaffected nipple. Increased blood flow was observed within the tumor for invasive ductal carcinoma, but the blood flow signals were weaker than those observed in Paget's disease and adenoma of the nipple.**Conclusions:** Doppler ultrasound enables simple and highly reproducible imaging of blood flow in small area of the nipple with only surface imaging. This method was considered to be particularly useful for the screening of breast diseases involving the nipple.**Abstract ID: 1055**      Specific Field: **Breast Surgery****Mode of pres.: Poster Exhibition only**  
**ISW 2011 Session PE 428****Ultrasound-guided axillary fine needle aspiration cytology is useful for making treatment decisions of primary breast cancer patients**

H. Oyama, K. Enokido, R. Sigenaga, N. Miwa, K. Suzuki, M. Mori, T. Sawada, S. Nakamura

Showa University, Tokyo, Japan

**Introduction:** Ultrasound-guided fine needle aspiration cytology (US-FNAC) is a minimally invasive technique which can detect metastasis. The aim of this study was to observe the preliminary results regarding the efficacy of FNAC to detect metastatic breast carcinoma in axillary lymph nodes, which is essential data for determining the staging.

**Material and Methods:** Among 2733 breast and axially ultrasonography examinations between January and December 2010 in Showa University Hospital, we reviewed the results of 48 US-FNACs of axillary lymph nodes of primary breast cancer patients. US-FNAC was performed on the presence of the following findings; 1) larger than 1.0 cm, 2) round or avoid shape, 3) absence of fatty hilum, 4) cortical thickening with eccentric lobulation of hypoechoic cortical rim.

**Results:** In the results of the FNAC of 48 cases, 18 cases were negative of metastasis, 26 cases were positive of metastasis, one case was difficult to differentiate, and three cases were insufficient for diagnosis. Surgery was performed in 8 cases of 18 negative cases of metastasis in FNAC. Five cases (62.5%) had no metastasis and three cases (37.5%) were revealed the metastasis in final pathological diagnosis (false negative = 37.5%). Among 26 positive cases, 16 cases were underwent preoperative chemotherapy (T1: one case, more than T2: 15 cases) and 10 cases were performed surgery. The pathological results in the 10 cases were all positive (false positive = 0%).

**Conclusions:** US-FNAC is a simple, inexpensive and safety technique. Based on our data, FNAC results were considered to be useful in determining the staging classification and the treatment plan of breast cancer patients in its positive cases.

**Abstract ID: 1056**      Specific Field: **Breast Surgery**

**Mode of pres.: Poster Exhibition only**  
**ISW 2011 Session PE 429**

#### **Long-term results of breast-conserving therapy after neo-adjuvant chemotherapy**

M. Sakata [1], H. Jinno [1], T. Hayashida [1], M. Takahashi [1], T. Sato [1], H. Seki [2], Y. Kitagawa [1]

[1] Keio University School of Medicine, Tokyo, Japan, [2] Keio University, Tokyo, Japan

**Introduction:** Neo-adjuvant chemotherapy (NAC) enables us to increase the possibility of breast-conserving therapy (BCT) for large tumors. However, several studies have reported that ipsilateral breast tumor recurrences (IBTRs) occur more frequently after NAC than originally envisaged. The objective of this study is to analyse loco-regional recurrence (LRR), disease free survival (DFS) and overall survival (OS) in patients undergoing BCT after NAC comparing with patients who had BCT without NAC.

**Material and Methods:** Fourteen hundred and sixty-three patients with invasive breast cancer undergoing BCT between 1995 and 2010 at Keio University Hospital were retrospectively analysed. Thirteen hundred and five patients had BCT without NAC (NAC-) and 158 patients were treated with BCT after NAC (NAC+). Regimens of chemotherapy were FEC (5-fluorouracil (5FU), epirubicin (EPIR), cyclophosphamide (CPA)), Doc+Cap/FEC (docetaxel and capecitabine followed by FEC), Doc+S1/FEC (docetaxel and S-1 followed by FEC), Doc+DFUR (docetaxel and doxifluridine) and others.

**Results:** Mean tumor diameter (T) of NAC- group and NAC+ group was 2.0 and 3.3 cm, respectively ( $P < 0.0001$ ). Clinical N0 rate of

NAC- group and NAC+ group was 95% and 52%, respectively ( $P < 0.0001$ ). At a median follow-up of 5.6 years, 45 patients (3.4%) in NAC- group developed LRR and 5 patients (3.2%) in NAC+ group ( $P = 1.000$ ). Five-year actuarial rates of LRR-free survival, disease free survival (DFS) and overall survival (OS) of NAC- group and NAC+ group were 97.4% and 92.0% ( $P = 0.09$ ), 89% and 74% ( $P < 0.0001$ ), and 97% and 93% ( $P = 0.001$ ), respectively.

**Conclusions:** Our data suggested BCT after NAC may achieve cosmesis without compromising local control and overall survival.

**Abstract ID: 1057**      Specific Field: **Breast Surgery**

**Mode of pres.: Poster Exhibition only**  
**ISW 2011 Session PE 430**

#### **Correlation of preoperative serum CA15-3 levels with other prognostic factors and recurrence of breast cancer**

K. Sakurai [1], W. Eiko [1], M. Kyoko [1], T. Maeda [1], M. Shibata [2], S. Fujisaki [3], K. Enomoto [1], S. Amano [1]

[1] Nihon University School of Medicine, Tokyo, Japan, [2] Fukushima Medical University, School of Medicine, Fukushima, Japan, [3] Fujisaki Hospital, Tokyo, Japan

**Introduction:** CA15-3 is an onco-fetal antigen expressed notably by breast cancer, and its clinical value has been reported as a prognostic marker. The aim of this study were to evaluate the association between serum CA15-3 levels and other biological and clinical variables and its prognostic role in primary invasive breast cancer in Japan.

**Material and Methods:** We evaluated 1121 patients operated for primary breast cancer in Nihon University Itabashi Hospital and Fujisaki Hospital from Feb 2002 to Nov 2008. Preoperative serum CA15-3 was measured by an immunoradiometric assay. We investigated the association between CA15-3 and other established prognostic markers (such as stage, grade, histological subtypes, receptor status, etc) and the prognostic role of preoperative serum CA15-3 level.

**Results:** Measured CA15-3 levels 1 to 191 U/ml (mean level:  $10.32 \pm 10.89$  U/ml) in cases. The number of cases above the normal reference value (0–30 U/ml) were 29 (2.6%). Serum CA15-3 level have significant correlations with TNM stage.

**Conclusions:** These results suggested that the proportion of high serum CA15-3 level is somewhat lower than other reports, and high serum CA15-3 level reflects the advanced stage and has a strong prognostic value in invasive breast cancer, and the risk of recurrence is significant from the cut-off value of 22 U/ml.

**Abstract ID: 1058**      Specific Field: **Breast Surgery**

**Mode of pres.: Poster Exhibition only**  
**ISW 2011 Session PE 431**

#### **The combined effect of paclitaxel and toremifene therapy for estrogen receptor positive and aromatase inhibitor resistant metastatic breast cancer**

K. Sakurai [1], M. Ogura [1], T. Hirano [1], Y. Ueda [1], K. Enomoto [1], S. Amano [1], S. Fujisaki [2], M. Shibata [3]

[1] Nihon University School of Medicine, Tokyo, Japan, [2] Fujisaki Hospital, Tokyo, Japan, [3] Fukushima Medical University, School of Medicine, Fukushima, Japan

**Introduction:** Multidrug resistance proteins such as P-glycoprotein (P-gp) are potential targets for improving the efficacy of paclitaxel (PXL), a mitotic inhibitor used in cancer chemotherapy. The selective estrogen receptor modulator Toremifene (TOR) moderate P-gp related drug resistance in vitro. A comparison of PXL alone with PXL + TOR in hormone-receptor-positive metastatic breast cancer patients (MBC) was conducted to determine the therapeutic value of adding TOR to a PXL regimen.

**Material and Methods:** Thirteen MBC patients received 80 mg/m<sup>2</sup> PXL weekly (PXL group) and fourteen MBC patients received the same weekly dose of PXL plus 120 mg/day TOR daily (PXL + TOR group). Patients were repeatedly treated with a combination of PXL and TOR as long as disease progression or unmanageable severe adverse events were defined.

**Results:** The PXL group was compared with PXL + TOR group with respect to best overall response, response rate, clinical benefit rate, time to progression, adverse events and toxic profile of PXL and TOR. No significant difference in response rate was observed between the PXL group and the PXL + TOR group. However, clinical benefit rate and time to progression improved significantly in the PXL + TOR group in comparison with the PXL group. TOR did not significantly enhance the adverse events of PXL.

**Conclusions:** These results suggested that combined treatment of PXL and TOR for MBC patients improves patient response over PXL alone.

**Abstract ID: 1059**      Specific Field: **Breast Surgery**

**Mode of pres.: Poster Exhibition only**  
**ISW 2011 Session PE 432**

**Usefulness of tartrate-resistant acid phosphatase bone-specific isozyme (TRACP-5b) as a marker of metastases from breast cancer**

N. Sengoku, Y. Kosaka, K. Hayahshi, T. Enomoto, M. Kuranami, M. Watanabe

Kitasato University, School of Medicine, Sagamihara, Japan

**Introduction:** Tartrate-resistant acid phosphatase bone-specific isozyme (TRACP-5b) is produced and secreted by osteoclasts. As compared with conventional markers of bone resorption such as amino- and carboxy-terminal cross-linking telopeptide of type I collagen (NTX and CTX, respectively), TRACP-5b is considered an index of osteoclast activity. Because TRACP-5b is minimally affected by renal function and physiologic variability, it is considered a promising marker of bone metastases. We measured TRACP-5b activity in patients with breast cancer and evaluated its usefulness.

**Material and Methods:** The study group comprised 41 women histologically confirmed to have a diagnosis of breast cancer in our hospital. From December 2009 through July 2010, blood samples were taken from patients in the outpatient clinic. The sensitivity, specificity, and diagnostic accuracy of TRACP-5b were compared with those of other tumor markers, and problems at the time of measurement were investigated.

**Results:** Among 9 patients who tested positive for TRACP-5b, 8 had bone metastases. Among 32 patients who tested negative for TRACP-5b, 9 had bone metastases. The sensitivity was 47.1%, the specificity was 95.8%, and the diagnostic accuracy was 75.6%. ICTP, measured at the same time, had a sensitivity of 37.5%, a specificity of 84.0%, and a diagnostic accuracy of 65.8%. Six patients who tested positive for TRACP-5b were also positive for carcinoembryonic antigen (CEA) or CA15-3; all of these patients had bone metastases. When

the results were analyzed according to demographic characteristics, the accuracy was 94.1% in patients without metastases, 14.3% in patients with only bone metastases, 12.5% in patients with only non-bone metastases, and 55.5% in patients with both bone and non-bone metastases. .

**Conclusions:** Our results suggest that TRACP-5b is at least as useful as ICTP as a marker of metastases from breast cancer. Diagnostic accuracy may be enhanced by concurrently measuring other tumor markers. Treatment with bisphosphonates can influence measurements of TRACP-5b activity. Further studies of factors related to false-negative and false-positive results and the analysis of additional cases are expected to increase the precision of TRACP-5b for the diagnosis of metastasis.

**Abstract ID: 1060**      Specific Field: **Breast Surgery**

**Mode of pres.: Poster Exhibition only**  
**ISW 2011 Session PE 433**

**Development of photodynamic therapy using verteporfin-MPC polymer aggregation as a new alternative treatment to axillary lymph node dissection**

K. Shimada, S. Matsuda, H. Jinno, M. Ueda, Y. Kitagawa

Dept Surgery, Keio University, School of Medicine, Tokyo, Japan

**Introduction:** Axillary lymph node dissection (ALND) is necessary for staging and regional control of breast cancer. However, it is associated with complications such as lymph edema, numbness and pain.

Photodynamic therapy (PDT) of cancer is a non-invasive optical therapeutic method in which the topical or systemic delivery of photosensitizing drugs is followed by irradiation with broadband red light. Verteporfin, a hydrophobic photosensitizer, and MPC polymer forms a soluble aggregate, which size ranged from 70 to 150 nm and was suitable for lymphatic mapping. In this study, the usefulness of PDT for treating lymph node metastasis was evaluated in animal model.

**Material and Methods:** pEGFP-N1 (Takara Bio, Japan) was transfected to human epithelial carcinoma cell line A431. 2.0 µl of  $1 \times 10^7$ /ml A431-GFP in PBS was injected to the front paw of BALB/cA nude mice. The brachial and axillary lymph nodes were harvested to evaluate metastasis by stereoscopic fluorescence microscope. The concentration of verteporfin was measured by the fluorescence intensity in extract from lymph node samples. MPC polymer and verteporfin were mixed in PBS at the ratio of 25:1, and sonicated to make the verteporfin-MPC aggregation. The tumor was irradiated with 640 nm Fiber Coupled LD model (Sony, Japan) at 1 h after the intravenous injection of 0.2 mg of the verteporfin-MPC aggregation at day 7. Total fluence was 75 J/cm<sup>2</sup>.

**Results:** At day 7, 12 and 18, lymph node metastases were found in 17% (1/6), 50% (3/6) and 75% (6/8), respectively.

The average verteporfin concentration in the brachial lymph nodes was 3 times higher than in the axillary lymph nodes (160 ng versus 56 ng).

Although 3 out of 10 mice injected with verteporfin-MPC without irradiation developed lymph node metastases, there are no lymph node metastases found in 10 mice infected with verteporfin-MPC and irradiation.

**Conclusions:** These data suggested that PDT with verteporfin-MPC aggregation may be effective and non-invasive alternative treatment to ALND in breast cancer patients.



**Abstract ID: 1061** Specific Field: **Breast Surgery**

**Mode of pres.: Poster Exhibition only**  
**ISW 2011 Session PE 434**

**Real-time magnetic resonance-guided microwave coagulation therapy for breast cancer: pre-clinical study using a 0.5 T open MR system**

T. Shimizu, H. Abe, T. Umeda, T. Mori, H. Cho, S. Morikawa, Y. Kurumi, T. Tani

Shiga University of Medical Science, Otsu, Japan

**Introduction:** Nonsurgical ablation therapy, such as radiofrequency ablation, high-intensity focused ultrasound ablation, or cryotherapy, have been described as safe and effective therapeutic options in the treatment of breast cancer. We have successfully treated 184 patients with liver tumors using real-time magnetic resonance-guided microwave coagulation therapy (MR-MCT) without major complications since January 2000. We have also attempted pre-clinical study to apply MR-MCT to the treatment of breast cancer.

**Material and Methods:** We conducted following three experiments; 1) Simulation: We simulate the detection in position of tumor and the insertion of ablation needle into the tumor using real time MR image before surgery. 2) ex vivo study: Five lesions of breast cancer were ablated by MCT under real time MR image using the resected specimens. We monitored the increase in the temperature of ablated area. The ablated specimens were evaluated by macroscopic and microscopic examination. 3) in vivo study: We performed MR-MCT against breast cancer before total mastectomy to confirm the basic feasibility of breast tumor ablation in human body. Tumors were ablated (60 W, 60 seconds  $\times$  3 times, one session) under general anesthesia. Thereafter total mastectomy was performed. The ablated specimens were evaluated as same as previous experiment.

**Results:** 1) We were able to detect the tumor location and simulate the insertion route of ablation needle into the tumor using real time MR image. 2) We were able to observe the position of tumor in the resected specimens. The ablation needle was inserted into the tumors watching real time MR image. The ablated area of resected specimens were 19  $\times$  27 mm as mean value. The temperature of tissue increased to approximately 60°C at 1.5 cm distance from ablation needle. The viability of tumor was disappeared in the ablated area by NADH staining. 3) The ablated area in the human body lost the viability of tumor (21  $\times$  33 mm), which was almost same as ex vivo study. No complication was observed in the punctured area of skin.

**Conclusions:** Although further study needed to clarify the safety and feasibility of MR-MCT for the breast-conserving therapy of breast cancer in the human body, our finding suggested that the MR-MCT for breast cancer might be feasible as one of the strategy for non-surgical ablation therapy.

**Abstract ID: 1062** Specific Field: **Breast Surgery**

**Mode of pres.: Poster Exhibition only**  
**ISW 2011 Session PE 435**

**The feasibility of sentinel lymph node biopsy after neoadjuvant chemotherapy for breast cancer patients**

M. Takahashi [1], T. Hayashida [1], M. Sakata [1], S. Hirose [2], H. Jinno [1], M. Mukai [2], Y. Kitagawa [1]

[1] Department of Surgery, Keio University School of Medicine, Tokyo, Japan, [2] Department of Plastic Surgery, Keio University School of Medicine, Tokyo, Japan

**Introduction:** Sentinel lymph node biopsy (SLNB) has become an accurate alternative to axillary lymph node dissection for clinically node negative breast cancer. However, the clinical relevance is still insufficient with regards to the combination of SLNB with neoadjuvant chemotherapy (NAC). In this study, the feasibility and accuracy of SLNB after NAC in Japanese patients are investigated.

**Material and Methods:** We enrolled 96 patients with stage II-III breast cancer who underwent NAC from January 2001 to July 2010. All patients underwent SLNB followed by complete axillary lymph node dissection (ALND). SLNs were detected using blue dye and radiocolloid injected peritumorally and subcutaneously, and evaluated by hematoxylin and eosin and immunohistochemical staining.

**Results:** The overall identification rate was 87.5% (84/96); false-negative rate (FNR), 24.5% (12/49); and the accuracy of SLNB, 85.7% (72/84). Before NAC, the FNR among clinically node-negative patients was significantly lower than that among node-positive patients (5.5% vs. 35.5%,  $P < 0.05$ ). The FNR among 46 node-positive patients who were node negative after NAC was 27.3%. Among patients with a complete response (CR), the FNR was 0% compared with 26.1% among those with other responses ( $P = 0.404$ ).

**Conclusions:** Although SLNB after NAC was associated with a high FNR, SLNB could replace ALND in patients who were clinically node-negative status before NAC and had a CR.

	Identification rate		False-negative rate		Accuracy	
	n	p	n	p	n	p
<b>Tumor size before NAC</b>						
T < 3 cm	24/28 (85.7)	0.715	5/15 (33.3)	0.339	19/24 (79.2)	0.127
T $\geq$ 3 cm	60/68 (88.2)		7/34 (20.6)		53/60 (88.3)	
<b>Clinical nodal status before NAC</b>						
No	36/41 (87.8)	0.961	1/18 (5.6)	0.001	35/36 (97.2)	0.009
N+	48/55 (87.3)		11/31 (35.5)		37/48 (77.1)	
<b>Clinical response</b>						
CR	11/12 (91.7)	0.392	0/2 (0)	0.404	11/11 (100)	0.143
PR + NC	72/83 (86.7)		12/46 (26.1)		60/72 (83.3)	

**Figure:** SLNB results based on clinical factors

**Abstract ID: 1063** Specific Field: **Breast Surgery**

**Mode of pres.: Poster Exhibition only**  
**ISW 2011 Session PE 436**

**Feasibility of nipple-sparing mastectomy**

M. Takahashi [1], H. Jinno [1], T. Hayashida [2], M. Sakata [1], T. Ogata [3], K. Kishi [3], Y. Kitagawa [1]

[1] Department of Surgery, Keio University School of Medicine, Tokyo, Japan, [2] Keio University School of Medicine, Japan, [3] Department of Plastic Surgery, Keio University School of Medicine, Tokyo, Japan

**Introduction:** Surgical treatment of breast cancer has evolved from radical mastectomy with routine removal of the nipple-areolar-complex (NAC) to breast conserving therapy with preservation of the breast and NAC. Although mastectomy is still required in case of large tumor, multifocal disease, and local recurrence, NAC could be saved in some patients without NAC involvement. For these patients, a nipple-sparing mastectomy (NSM) has evolved as an alternative to a mastectomy with a better cosmetic outcome. However the oncologic safety of these procedures are still to be elucidated. The purpose of this study is to investigate technical feasibility of NSM without increasing the risk of local recurrence and complications.

**Material and Methods:** Sixty-three stage 0-II breast cancer patients received NSM between January 2001 and Aug 2010. Eligible patient

criteria were multifocal disease or an extensive intraductal spread. NAC involvement was diagnosed intraoperatively and postoperatively by hematoxylin and eosin staining. Three hundred seventy-four breast cancer patients who received mastectomy were distributed as a control group.

**Results:** The median age was 47 years (range 29–67 years), and the mean clinical tumor size was  $3.6 \pm 1.3$  cm. NAC involvement was observed in 4.7% (3/63). Epidermal necrosis was seen in one case (1.5%). After a median follow-up period of 34.2 months, recurrence was observed in three patients (4.8%), including two local recurrence (3.2%) and one liver metastasis (1.6%). There was no statistically significant difference of local recurrence rate between NSM and mastectomy (3.2% vs. 2.6%;  $P = 0.16$ ). Immediate and delayed reconstruction was performed in two cases (3.2%) and 28 cases (44.4%), respectively.

**Conclusions:** Our results suggested NSM may provide oncologic safety for strongly motivated and carefully selected patients.

		NSM (n=63)	Mastectomy (n=374)	P value
Age(years)	median	49	57	0.007
	range	29-67	25-87	
Pathological tumor size (cm)	mean $\pm$ SD	2.8 $\pm$ 1.1	3.4 $\pm$ 1.4	0.20
	range	0-5.0	0.7-30	
Observation period (month)	median	34.2	45	0.28
	range	2-105	3-84	
local recurrence (%)		2 (3.1%)	10 (2.6%)	0.16

**Figure:** Comparison of clinicopathologic characteristics between NSM and mastectomy

**Abstract ID: 1064**

Specific Field: **Breast Surgery**

**Mode of pres.: Poster Exhibition only**  
ISW 2011 Session PE 437

#### Evaluation of Ki67 as a predictor of response to neoadjuvant chemotherapy for operable breast cancer

N. Wada [1], S. Asaga [1], C. Yamauchi [1], S. Fujii [2]

[1] National Cancer Center Hospital East, Kashiwa, Japan,

[2] Research Center for Innovative Oncology National Cancer

Center, Kashiwa, Japan

**Introduction:** The value of biological markers as a predictor of response to neoadjuvant chemotherapy (NAC) in breast cancer patients is still a matter of debate. Recently, Ki67 index has been attracting a considerable attention as a predictor. We evaluated the contribution of Ki67 in pathologic complete response (pCR) to NAC.

**Material and Methods:** A total of 320 patients with Stage II and III breast cancers, previously treated with NAC, were enrolled in the study. All patients were confirmed pathologically invasive cancer and the expression of biological markers (ER, PgR, HER2, Ki67) was assessed by immunohistochemistry using samples from core-needle biopsy before NAC. A pCR was defined as no pathologic evidence of residual invasive component in primary tumor. All p-values were two-sided with statistical significance set at  $P < 0.05$ .

**Results:** Of the 320 patients, pCR was achieved in 56 patients and non-pCR in 264 patients. In pre-treatment clinical characteristics, there were not significant differences in mean age, menopausal status, and clinical

nodal status between them. The mean tumor size in pCR ( $4.0 \pm 1.7$  cm) was significantly smaller than that of non-pCR ( $4.7 \pm 2.1$  cm). The mean Ki67 index in pCR and non-pCR were  $29.6 \pm 16.9\%$  and  $21.3 \pm 16.5\%$ , respectively. Negative ER, negative PgR, positive HER2 status and a higher Ki67 were found to be significantly predictive of a pCR. For NAC regimen, 63 patients received either anthracycline or taxane based regimen (A or T), and 257 patients received both of them (A + T). 18 patients were received concurrent trastuzumab with taxane. 51 (20%) of the patients treated with A + T regimen achieved pCR, while only 5 (8%) of the patients treated with A or T regimen. A significant difference between them was observed. In multivariate analysis, the probability of pCR was directly associated with tumor size [OR for one cm increase, 0.706, 95% confidence interval (CI), 0.564–0.883], Ki-67 index [OR for 10% increase in the percentage of positive cells, 1.023, CI, 1.002–1.044], ER [OR for negative 0.148, CI 0.042–0.522], HER2 [OR for positive 0.461, CI 0.213–0.999] and use of trastuzumab [OR for use 0.074, CI 0.018–0.306].

**Conclusions:** We conclude that the expression in primary tumors of Ki67, as well as well-known clinical and biological factors, is an independent predictor in patients receiving NAC.

**Abstract ID: 1065**

Specific Field: **Breast Surgery**

**Mode of pres.: Poster Exhibition only**  
ISW 2011 Session PE 438

#### The association of oncotype DX recurrence score and histological grade as a prognostic factor in Japanese women with estrogen receptor-positive, node-negative primary stage I or IIA breast cancer

K. Yorozuya [1], T. Takeuchi [2], J. Kousaka [1], Y. Mouri [1], M. Yoshida [1], K. Fujii [1], S. Nakano [1], T. Fukutomi [1]

[1] Aichi Medical University, Aichi-gun, Japan, [2] Marumo Hospital, Nagoya, Japan

**Introduction:** The purpose of this case-control study was to evaluate the utility of Oncotype DX in identifying Japanese women with ER-positive, node-negative Stage I or IIA primary invasive breast cancer who were candidates for adjuvant therapy and clarify the association of the Oncotype DX system and histological grade.

**Material and Methods:** A retrospective case-control study was conducted on 40 patients who underwent surgery between 2000 and 2008. Cases ( $n = 10$ ) were patients who had metastases after surgery. Controls ( $n = 30$ ) were patients who did not develop metastases and were individually matched to their case with respect to age. All patients were analyzed with regard to age, tumor size, histological grade, HER2 status, and the values of Recurrence Score (RS), ER score and PgR score generated by Oncotype DX. We also divided the patients into low, intermediate, or high-risk groups according to individual RS values.

**Results:** RS, risk category, and histological grade were associated with metastases in patients with ER-positive, node-negative Stage I or IIA breast cancer. However, ER status, tumor size, and PgR status were not associated with metastases. Histological grade was associated with RS value and the distribution pattern of risk category ( $P < 0.001$  for each). Histological grade was strongly associated with the RS value ( $P < 0.001$ ) and the distribution of RS category ( $P < 0.001$ ,  $\rho = 0.63$ ).

**Conclusions:** Our study suggests that patients with a tumor of histological grade 3 or an increased RS should be considered for adjuvant chemotherapy at diagnosis and histological grade was strongly associated with the Oncotype DX system. Patients with a tumor of histological grade 2 would be good indication for the Oncotype DX assay.

**Abstract ID: 1066**Specific Field: **Breast Surgery****Mode of pres.: Poster Exhibition only**  
**ISW 2011 Session PE 439****A variable presentation of phylloides tumor, with literature review**

A. Ghasoup, O. Sadih, Q. Al-Ani

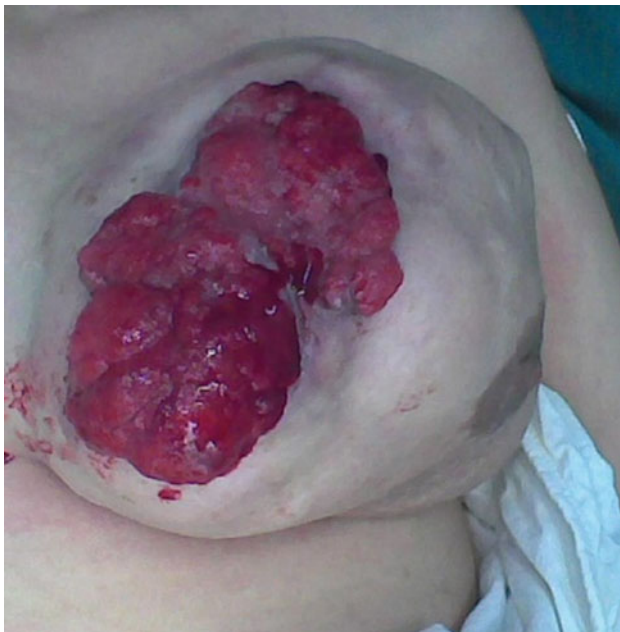AlBashir Hospital - MOH, Amman, Jordan

**Introduction:** Phylloides tumors are rare fibroepithelial tumors accounting 0.3–1% of malignant breast tumors and about 2.5% of all fibroepithelial lesions of the breast. Phylloides are typically large, fast growing masses that formed from the periductalstromal cells of the breast. Large tumors whether malignant or benign, may cause stretching and ulceration of the overlying skin with distension of the superficial veins. In general, approximately 15–30% of patients develop recurrence, mostly within 2 years after the diagnosis.

**Material and Methods:** Six patients treated for phylloides tumors at our institution from the period of March 2007 & March 2010. Five patients were female and one male, Age ranged from 26 to 50 years old. Size ranged from 3 to 20 cm. Cases were distributed equally in both breasts (50% in each breast). Type of presentation as follow; one case with nipple discharge, five cases with masses, three of them with painless mass, one ulcerating mass, and one with painful mass.

**Results:** Four cases underwent simple mastectomy. Two cases managed by wide local excision. However, one of the cases required simple mastectomy at later time as a result of the positive margin in the histopathology report. Axillary lymph nodes involvement in cases (2/6) is generally due to reactive changes.

**Conclusions:** Phylloide tumors can be presented variably in different patients, although it is an uncommon tumor but can be also presented with features of malignancy. Age, size and site are not predictor factors of malignancy.



**Figure:** Ulcerating phylloide tumor

**Abstract ID: 1067**Specific Field: **Breast Surgery****Mode of pres.: Poster Exhibition only**  
**ISW 2011 Session PE 440****Patient navigator: a solution to better compliance in work-ups and treatment among clinically diagnosed breast cancer in VSMC-breast center**

S.S. Siguan, C. Bodiongan, M.S.A. Visda, V. Serrano, G. Gonzaga, S.T.A. Baking

Vicente Sotto Memorial Medical Center-Breast Center, Cebu City, Philippines

**Introduction:** For patient's diagnosis and treatment to happen in an efficient and effective way, this requires organized management. Anyone needs an advocate to help the patient, and such an advocate is a "navigator". A patient navigator fulfills a critical role for many patients who are just diagnosed with breast cancer. What is usually meant by "navigating a patient", is that someone helps the patient move smoothly through the system, efficiently. The general objective of the study is to determine the effectiveness of a nurse navigator in improving the compliance of clinically diagnosed breast cancer patients to diagnostic and therapeutic interventions.

**Material and Methods:** Retrospective analytical study of clinically diagnosed breast cancer patients consulting at the VSMC, Breast Center, from July 24, 2009 to September 28, 2010 was conducted. During initial consultation, a patient navigator fills-up a tracking sheet. Patients who are clinically diagnosed with breast cancer should have a biopsy result within 2 weeks, should undergo an operation within 2 weeks after the confirmation, and should receive the intervention within 1 month from initial consult. Beyond these cut-off periods, the patient's clinical course was considered delayed. The mean number of days and *P*-value using *t*-test were computed.

**Results:** Charts of 92 patients were reviewed, 44 of which were navigated by a nurse while 48 were not navigated. The mean number of days interval between 2 groups, on each clinical course was computed. Seven patients from the intervention and 2 patients from the control group were operated within 30 days. The mean number of days interval difference from the time patient was suspected to have the disease to biopsy availability, from the biopsy to treatment, and from initial consult to treatment was 10, 29 and 50 days, respectively, between the control and intervention group. Financial problem ranks first (35%) as a factor causing the delay.

**Conclusions:** Significantly, patient navigator hastens the time frame from consult to treatment.

**Abstract ID: 1068**Specific Field: **Breast Surgery****Mode of pres.: Poster Exhibition only**  
**ISW 2011 Session PE 441****An 8 year experience of implementing a pro-active approach to early detection of breast cancer in a community**

S.S. Siguan, P.A. Merilles, S.T.A. Baking

Vicente Sotto Memorial Medical Center-Breast Center, Cebu City, Philippines

**Introduction:** Early cancer detection is the key to better survival. A community/outreach program may help detect breast cancer early.



The objectives of this study is to determine the demographic as well as clinical profile of patients participating in the breast cancer community outreach program and determine if the BCACop can successfully find breast cancer cases in the community.

**Material and Methods:** In 2001, a breast cancer community/outreach program was organized by the Vicente Sotto Memorial Medical Center – Breast Center. The program components are: breast cancer lay forum, breast self-examination (BSE) classes and breast clinic. Patients' data included a checklist with the relevant demographics, chief complaints, clinical breast examination findings, diagnosis, work-ups, and outcome.

**Results:** Twenty-seven breast cancer community outreaches were conducted in a span of eight years. There were 1719 participants with a mean age of 32.5 years. The most common reason for consultation was breast check-up (79.6%), majority had normal breast exam findings (75.9%) and breast cancer was identified in 19 out of 1719 (1.1%). Most of these were early breast cancer.

**Conclusions:** The BCACop is not only vital in providing on-site breast health education and services but is also effective in finding early breast cancer cases among women consulting at the community breast clinic.

**Abstract ID: 1069**      Specific Field: **Breast Surgery**

**Mode of pres.: Poster Exhibition only**  
**ISW 2011 Session PE 442**

**Sentinel lymph node biopsy using methylene blue dye in predicting axillary lymph node metastasis in breast cancer: the Vicente Sotto Memorial Medical Center experience**

S.S. Siguan, E. Castillo, H. Tagab, S.T.A. Baking

Vicente Sotto Memorial Medical Center-Breast Center, Cebu City, Philippines

**Introduction:** For nearly a century the standard of surgery for breast cancer in the Philippines includes an axillary lymph node dissection. Axillary dissection can result in significant morbidity. Sentinel lymph node biopsy is a minimally invasive method of assessing the axilla and is considered an important option in breast cancer management in other countries. This approach lessens the sequelae of standard axillary dissection. Methylene blue dye as a cheaper alternative compared to other dyes for SLNB could have cost-saving potentials in developing countries. The objective of the study is to determine the accuracy of SLNB using methylene blue dye in predicting axillary lymph node metastasis in breast cancer.

**Material and Methods:** Breast cancer patients consulting at the Breast Center were assessed if they can be included in the SLNB study using methylene blue dye with the following criteria: biopsy proven adenocarcinoma of the breast, a Tis, T1, T2 and T3 primary breast tumor and clinically negative ipsilateral axilla by palpation and ultrasound. Those eligible for the study were scheduled for breast surgery, either modified radical mastectomy or breast conserving surgery. Patients underwent a subareolar injection of 5 ml 1% methylene blue dye 5 min prior to sentinel lymph node biopsy. Three blue staining axillary lymph nodes were taken and sent to pathology for frozen section evaluation and after surgery, H & E staining. A completion axillary lymph node dissection was done in all patients. Variables were statistically analyzed.

**Results:** There were 20 patients included in this study. SLNB in this group had an accuracy, sensitivity, specificity, PPV, and NPV of 95.0%,

83.3%, 100%, 100%, and 93.3%, respectively. The false negative rate is 6.7%. On the average, the SLNs were identified in 14 min.

**Conclusions:** Sentinel lymph node dissection with methylene blue has an accuracy of 95% in the local setting.

**Abstract ID: 1070**      Specific Field: **Breast Surgery**

**Mode of pres.: Poster Exhibition only**  
**ISW 2011 Session PE 443**

**A prospective study on the quality of life after a palliative surgery on patients with advanced breast and gastrointestinal malignancies**

H. Tagab, S.S. Siguan, S.T.A. Baking

Vicente Sotto Memorial Medical Center-Breast Center, Cebu City, Philippines

**Introduction:** Quality of life measures have gained increasing attention as outcome variables in studies of cancer and its treatment. Palliative surgery is performed to alleviate symptoms of tumors or complications that can arise from tumors or their treatment. The goal of palliative surgery is to improve the quality of life for the patient. Thus, the objective of the study is to evaluate the quality of life (QOL) after palliative surgery of patients with advanced breast and gastrointestinal malignancies and to determine changes in the quality of life over time.

**Material and Methods:** Quality of Life (QOL) of 32 patients with advanced breast and gastrointestinal malignancies was evaluated before surgery (baseline), then 7 and 30 days after surgery using the Medical Outcomes Study Short form (SF-36v2 Questionnaire). Statistical significance of the difference in outcomes was tested using the two-tailed *T*-test at 95% CI.

**Results:** Preoperatively, the patients scored poorly (scores below the average mean of 50) in all eight subscales of the SF-36v2. Seven days after a palliative surgery, patients showed significant improvement in all subscales except Vitality and Social Functioning. A significant change in all subscales occurred 30 days after surgery compared to the baseline and 7 days post-op.

**Conclusions:** Patients with advanced breast cancer or advanced gastrointestinal tumors (stage IIIB up to Stage IV) experienced problems in multiple quality of life domains pre-operatively (baseline). The initial mean health quality of life subscale scores were lower at baseline and increased significantly post-operatively.

**Abstract ID: 1071**      Specific Field: **Breast Surgery**

**Mode of pres.: Poster Exhibition only**  
**ISW 2011 Session PE 444**

**One-site, one-stop outpatient breast service in a government hospital**

S.S. Siguan, H. Tagab, S.T.A. Baking

Vicente Sotto Memorial Medical Center-Breast Center, Cebu City, Philippines

**Introduction:** Women seeking breast consultation in a government hospital commonly has to go back and forth to the clinic many times



before a definitive diagnosis can be arrived at. This can lead to anxiety, inconvenience and financial burden. To offer them an expedient service would be most ideal. This study is to determine the feasibility of one-site, one-stop outpatient breast service in a government medical center.

**Material and Methods:** A review of all patients consulting at the Breast Center of Vicente Sotto Memorial Medical Center (VSMMC) from June 2006 to November 2010 was done to assess the feasibility of this kind of service. For a benign condition, one-site, one-stop service will be any combination of the following: consultation, breast ultrasound, aspiration or excision. For a clinically malignant diagnosis, any combination of the following: consultation, breast ultrasound, biopsy (Fine Needle Aspiration Biopsy-FNAB, Core Needle Biopsy-CNB, Punch Biopsy and Open Biopsy).

**Results:** There were a total of 8963 consultations of which 4339 (48.4%) comprised the new consults at the Breast Center. On-site breast ultrasound was performed in 1198 (27.6%) of the new consults. A total of 3618 (83.4%) of these patients were diagnosed with clinically benign breast masses while 721 (16.6%) were clinically malignant. Among the new consults, 1106 (25.5%) availed of the one-site, one-stop outpatient breast services. Six hundred twenty seven (comprising 17.3%) of those diagnosed to have a clinically benign breast condition) benefitted from the one-site, one-stop service. Among the patients diagnosed to have clinically malignant breast masses, 479 (66.4%) patients availed of the one-site, one-stop service. Though just recently made available, of the 152 patients who underwent FNAB, 2% had their results within the same visit.

**Conclusions:** A one-site, one-stop outpatient breast service is feasible even in a government hospital.

**Abstract ID: 1072**      Specific Field: **Breast Surgery**

**Mode of pres.: Poster Exhibition only**  
**ISW 2011 Session PE 445**

#### **Implementing an urban model of a community-based breast cancer control program**

S.S. Siguan, J.A. de Leon

Vicente Sotto Memorial Medical Center-Breast Center, Cebu City, Philippines

**Introduction:** Community-based Breast Cancer Control Program (CBCCP) has 2 models for implementation- urban and rural. The specific objectives of CBCCP are to: 1) increase the number of breast consultations; 2) increase the proportion of early stages of breast cancer (diagnosed and treated); and 3) increase the survival of breast cancer patients.

**Material and Methods:** This is a retrospective descriptive study of all patients who participated in the implementation of an urban model of CBCCP at Vicente Sotto Memorial Medical Center (VSMMC) from April 1, 2001 to March 31, 2010. Patients' data to include statistics on consultations, cancer stages and follow-ups were extracted from the breast center database, reviewed and analyzed.

**Results:** Over this time period, 8706 patients consulted at VSMMC breast center. As baseline number of consultation per year, 828 were seen in the year 2002. Increased percentages of consults ranged from 12%-31% with a mean of 18.6%. A total of 467 patients were diagnosed to have breast cancer from 2001 to 2010. Sixty seven percent were in the early stages while 33% were advanced which reversed to the study of EJACC cancer registry on Metro Cebu breast cancer incidence & mortality report 1998-2000 wherein early stages comprised only 146 (40%) out of 362 patients and 60% were

late stages. In an unpublished study in this same institution on 45 breast cancer patients from January 2006 to March 2008 (27 months), twenty- seven percent (12/45) belong to stage III B. Overall survival rate was 50% (6/12). Worst case scenario mortality rate reached 67% (8/12). Compared to our previous experience with the management of 34 stage III-B breast cancer patients from January 1, 2000 to December 31, 2003 (48 months), the overall mortality rate was 24%. However, there were 24 patients lost to follow-up and this makes the worst case scenario overall mortality rate 70.6%. The mortality rate of the rest of the cancer stages could not be computed due to poor patient follow-up. With active patient follow-up, a baseline survival rate of 45 patients (January 2006 to March 2008) was established at 73% (33/45).

**Conclusions:** Community-based breast cancer control program can increase the number of breast consultations, attain reversal of early to advanced stage proportion.

**Abstract ID: 1073**      Specific Field: **Breast Surgery**

**Mode of pres.: Poster Exhibition only**  
**ISW 2011 Session PE 446**

#### **Clinical features of brain metastasis in breast carcinoma: a single institution review**

K.W. Li, J.J.C. Chen, E.Y. Tan

Tan Tock Seng Hospital, Singapore, Singapore

**Introduction:** Breast carcinoma is the most common cancer among women in Singapore with more than 1000 new cases diagnosed each year. In spite of the implementation of nationwide breast cancer screening and advances in systemic treatment, a significant proportion of our patients present still with advanced disease. Breast cancer specific mortality arise almost exclusively from metastatic disease. While the bones, liver and lungs are the most common site of metastatic disease, brain metastases are increasingly reported as the first site of relapse in women with breast carcinoma. Brain metastasis are usually diagnosed late as a brain scan is not part of the routine metastatic work-up. In this study, we aim to review the incidence and management of patients with brain metastasis and to identify a group of patients who may be more likely to develop brain metastasis.

**Material and Methods:** Retrospective review was performed of 31 women with brain metastases secondary to breast carcinoma and who received treatment at Tan Tock Seng Hospital, Singapore, during a 8-year period from 2001 to 2008. The clinical features and outcome of this group of patients were studied in detail.

**Results:** The median interval between the time of breast carcinoma diagnosis and detection of brain metastases is 17 months. Majority of the patients (30 out of 31) were symptomatic at the point of diagnosis of brain metastases, with headache being the commonest symptom. 2 patients underwent craniotomy and excision of brain metastases while 24 patients underwent whole brain radiation therapy (WBRT). The median survival of patient with solitary brain metastasis is 19 months while patient with multiple brain metastases had a median survival of 28 months.

Comparison was made between these 31 patients and 2165 patients without brain metastasis who were diagnosed during the same 8-year period. The development of brain metastasis was significantly correlated with hormone unresponsiveness, HER2 positivity and high tumour grade.

**Conclusions:** Patients with brain metastases secondary to breast carcinoma face a poor prognosis, especially in patients with multiple

brain lesions. Given that almost all these patients were diagnosed with brain metastasis only after having developed symptoms, there may be a role to include a CT scan of the brain as part of the staging work-up in patients at high risk of developing brain metastasis.

**Abstract ID: 1074**      Specific Field: **Breast Surgery**

**Mode of pres.: Poster Exhibition only**  
**ISW 2011 Session PE 447**

**Are cut-off values of one-step nucleic acid amplification (OSNA) assay for breast cancer sentinel lymph node biopsy applicable among the Singapore Asian Population?**

R.M. Singaporewalla [1], S.A. Buhari [2]

[1] Khoo Teck Puat Hospital, Singapore, Singapore, [2] National University Health System, Singapore, Singapore

**Introduction:** Molecular techniques based on reverse transcription-polymerase chain reaction have reported high sensitivity in detection of metastasis in sentinel lymph nodes of breast cancer patients. Recently, an automated one-step nucleic acid amplification (OSNA) assay was developed for intraoperative diagnosis of metastases using levels of CK-19 mRNA in the lymph node. Our aim was to determine if cut-off values of the OSNA assay applied to the Singapore Asian population

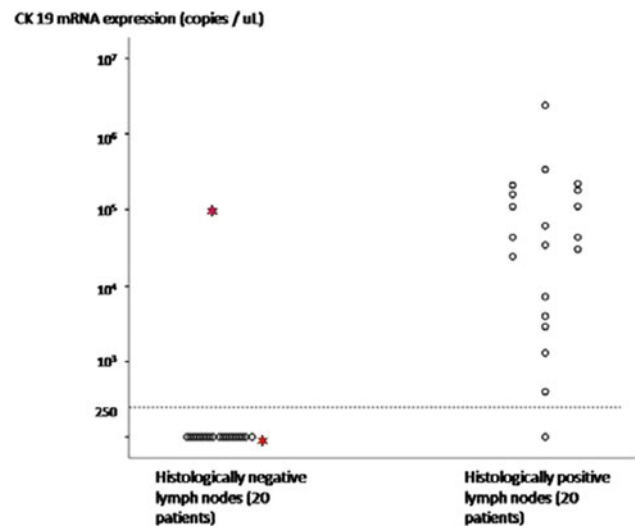
**Material and Methods:** Over a 6 month period, 17 patients with early breast cancer who were clinically node negative were recruited for this pilot study. The patients comprised a mixed racial population of Chinese, Malay and Indian ethnicity. A total of 20 histologically proven positive and 20 negative lymph nodes were analysed to determine the CK 19 mRNA levels in the 2 groups of lymph nodes using the automated one-step nucleic acid amplification (OSNA) technique to determine if the levels match with pre-determined cut-off values. We defined macrometastasis (++) as  $> 5 \times 10^3$  copies/ $\mu$ l of CK19 mRNA, micrometastasis (+) as  $2.5 \times 10^2$  to  $5 \times 10^3$  copies/ $\mu$ l, and non-metastasis (-) as  $< 2.5 \times 10^2$  copies/ $\mu$ l. All lymph nodes were sectioned in a similar fashion using a special lymph node cutter.

**Results:** Overall sensitivity and specificity was 95% among the 2 groups of positive and negative sentinel lymph nodes. Of the 2 discordant cases, the first was false negative due to a non-CK19 expressing breast tumor confirmed by immunocytochemistry. The second case was false positive where histologically a single focus of micrometastasis  $< 0.4$  mm was identified but OSNA was negative. This was likely due to sampling error.

**Conclusions:** Cut-off values of the OSNA assay are applicable in the Singapore Asian population. CK-19 cytoexpression from the primary breast tumor during biopsies will help in detecting the few cancers that do not express CK-19 mRNA and thus prevent false negative results.

Correlation of OSNA and histology results among 20 negative and positive nodes

	Macrometastasis	Histology micrometastasis	ITC present	Negative
OSNA ++	15	0	0	1
OSNA +	4	0	0	0
OSNA -	1	0	0	19



**Figure:** correlation of OSNA cut-off values and histology results

**Abstract ID: 1075**      Specific Field: **Breast Surgery**

**Mode of pres.: Poster Exhibition only**  
**ISW 2011 Session PE 448**

**Follow-up mammography after breast conservation: can it detect recurrence early?**

J. Apffelstaedt, N. Kasvosve, K. Baatjes

University of Stellenbosch, Cape Town, South Africa

**Introduction:** Annual mammography belongs to the recommended procedures in the follow-up after primary therapy for breast cancer despite there being only very few data to support this practice; there are even less data for mammography in conserved breasts. In order to contribute to the discussion and to provide for the first time data from a developing country, we here report a large series of mammograms after breast conservation according to standard performance parameters.

**Material and Methods:** From a prospective databases on all mammography at a tertiary breast centre in Cape Town data were extracted for all mammography performed after breast conserving therapy for breast cancer. Mammography was performed annually as part of a standard protocol for the follow-up of patients after primary therapy of breast cancer. Standard craniocaudal, mediolateral oblique views were taken as well as special views if indicated. Data recorded were the age of the patient, stage at initial diagnosis, current hormonal therapy, prior breast surgery, the indication for and outcome of mammography and further work-up. The outcome of the mammography was classified according to the Breast Imaging and Reporting Data System (BIRADS). The method of further imaging and/ or tissue acquisition, histology and clinical staging were recorded.

**Results:** Of a total number of 12 506 mammograms performed between January 2003 and June 2010, 2250 were done after breast conservation; 21 after bilateral breast conservation. Fifty-three were done for special indications. Of 2197 mammograms, 2163 were done for asymptomatic patients and 34 for patients presenting with a mass. The average age of the patients was 60 years.

## Performance analysis

Examination	<i>n</i>	BIRADS 3–5	Biopsies	Cancer <i>n</i>	Cancer rate	Average tumor size
Asymptomatic conserved breast	2182	71 (3.2%)	41 (1.9%)	23	10.5/1000	18 mm (11 cases)
Asymptomatic contralateral breast	2104	51 (2.4%)	21 (1.0%)	16	7.6/1000	24 mm (8 cases)
Mass in the conserved breast	31	19 (62%)	16 (51%)	15	48	24 mm (8 cases)
Mass in the contralateral breast	3	2	1	1	–	–

**Conclusions:** Follow-up mammography presents a complex problem for performance parameter analysis due to the presence of a number of selection biases. In the conserved as well as the contralateral breast, the detection rate is higher than in standard screening mammography. Mammography can detect asymptomatic recurrence early.

**Conclusions:** In Thai women, Luminal A was majority of IDC. Percentages of HER-2 and Basal-like IDCs were higher, comparing with a recent study from the USA. The findings may highlight biological difference between IDC occurred in Asian and Western women.

**Abstract ID: 1076**      Specific Field: **Breast Surgery**

**Mode of pres.: Poster Exhibition only**  
**ISW 2011 Session PE 449**

**Breast cancer subtypes identifying by ER, PR and HER-2 status in Thai women**

W. Permsapaya, S. Chuthapisith

Faculty of Medicine Siriraj Hospital, Mahidol University, Bangkok, Thailand

**Introduction:** Expression of estrogen-receptor (ER), progesterone-receptor (PR) and HER-2 has become markers determining invasiveness and prognosis of invasive ductal carcinoma of the breast (IDC). These biomarkers have recently been linked with various breast cancer subtypes identifying by gene microarray. This study aims to document breast cancer subtypes, using ER, PR and HER-2 status in Thai women, where expression of these subtypes may not be similar to those evidenced in the Western.

**Material and Methods:** Histological findings from 321 women who were diagnosed with 324 IDCs at Siriraj Hospital during November 2009 and June 2010 were studied. Various subtypes of IDC were identified according to expression of ER, PR and HER-2: Luminal-A (ER+; PR+/-; HER-2-), Luminal-B (ER+; PR+/-; HER-2+), HER-2 (ER-; PR-; HER-2+) and Basal-like (ER-; PR-; HER-2-). As well, associations between tumor size, tumor grade, nodal status, angiolymphatic invasion (ALI) and multifocality and different breast cancer subtypes were studied.

**Results:** Of 317 IDCs, 143 (45.1%), 147(46.4%), 15(4.7%) and 12(3.8%) were T1, T2, T3 and T4, respectively. Most tumors were grade 2 (178/318, 56%) and had no nodal involvement (173/323, 53.6%). ALI was evidenced in 82/269 (30.5%) tumors. ER, PR and HER-2 positivity were identified in 232 (71.6%), 209 (64.5%) and 83 (25.6%) of 324 IDCs. According to three biomarkers, 192 (59.3%), 40 (12.3%), 43 (13.3%) and 49 (15.1%) tumors were Luminal-A, Luminal-B, HER-2 and Basal-like subtypes. HER-2 subtype presented with large tumor ( $P = 0.04$ , ANOVA). Luminal-A IDC was associated with single foci ( $P < 0.01$ , Chi-square). HER-2 and Basal-like subtypes were likely to have grade 3 tumors ( $P < 0.01$ , Chi-square). In addition, HER-2 subtype had higher number of N2 and 3 diseases (nodal involvement 4) ( $P = 0.048$ , Chi-square).

**Abstract ID: 1077**      Specific Field: **Breast Surgery**

**Mode of pres.: Poster Exhibition only**  
**ISW 2011 Session PE 450**

**Ultrasound-guided fine needle aspiration cytology versus ultrasound guided core biopsy in pre-operative axillary staging of early breast cancer**

J. Maalo, A. Suri, S. Monib, L.M. Lai, S. Thomson

West Hertfordshire Breast Unit, St Albans, United Kingdom

**Introduction:** Pre-operative axillary staging is widely performed in patients diagnosed with early breast cancer. For patients found to have nodal involvement, axillary clearance can be performed without prior sentinel node biopsy. Ultrasound (US) alone has low sensitivity, but is useful in guiding needle biopsy. We compared the sensitivity, specificity and accuracy of US-guided fine needle aspiration cytology (USFNAC) and US-guided core biopsies (USCB) in our unit.

**Material and Methods:** A retrospective and prospective review was performed between November 2007 and May 2010 of all newly diagnosed breast cancer patients who underwent routine pre-operative axillary US. Patients whose nodes appeared benign or normal on US underwent sentinel node biopsy (SNB). Suspicious nodes were subjected to USFNAC or USCB, according to accessibility of the lymph node. Patients with positive cytology or histology underwent axillary node clearance (ANC), those with benign cytology or histology were offered SNB. The final histology results were correlated to pre-operative histology or cytology.

**Results:** Of 559 Axillary US scans performed, 229 were of patients with clinically node-negative breast cancer. Of these 46 had USFNAC, 44 had USCB and 139 had normal/benign US. 70% of USFNAC and 79% of USCB groups had positive postoperative histology, allowing direct comparisons to be made. Seventeen of the 46 (37%) USFNAC patients had positive cytology (all concordant with axillary clearance final histology). 15 of the 29 (52%) USFNAC patients with negative cytology had positive histology on sentinel node biopsy. The sensitivity of USFNAC was 53% and specificity 100%. Of the 44 USCB patients, 26 (59%) were positive (all concordant with postoperative histology). Of the remaining 18 USCB-negative patients, 7(39%) had positive nodes on axillary clearance. The sensitivity of USCB was 79% and the specificity 100%. 42 of the 139 (30%) patients with normal US had positive sentinel node biopsies. Sensitivity was 61% and specificity 80% for US alone.

**Conclusions:** US staging of the axilla is superior to clinical staging. For patients with US indeterminate axillary nodes, our data supports routine use of ultrasound core biopsy (USCB) over Ultrasound fine needle aspiration cytology (USFNAC) for preoperative staging of the axilla.

**Abstract ID: 1078**      Specific Field: **Breast Surgery**

**Mode of pres.: Poster Exhibition only**  
**ISW 2011 Session PE 451**

#### Breast cancer surgery in Vietnam

T.D. Nguyen

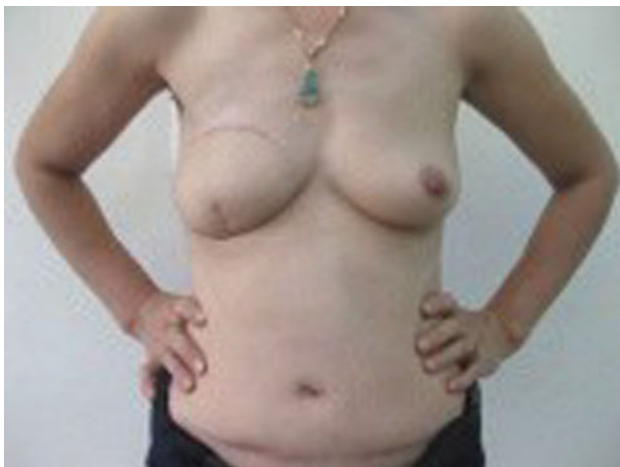Hue Central Hospital, Hue, Vietnam

**Introduction:** Breast cancer is leading cancer in Vietnamese women. From 2001–2007, Vietnam have been performed the cancer population-based registry in the 5 provinces. We aim to estimate the breast cancer incidence and assess the situation of breast surgery in 3 main hospitals in Vietnam.

**Material and Methods:** This was a retrospective follow-up of 3 hospitals in Vietnam. The breast cancer registry used by the CAN-REG system version 4 for data entry and management. Overall and 5 years disease-free survival rates was calculated by SPSS 16.0.

**Results:** There was 4,715 new cancer cases based on the cancer registries of 5 provinces in Vietnam. The Age Standard Rate per 100,000 habitants (ASR) is 30.2 in Hanoi, 21.0 in Hue and 19.4 in HoChiMinh City. The common age is 55–60 (128/100,000 habitants). Stage I: 10.9%, Stage II: 24.9%, Stage III& IV: 64.2% (N = 1071). A total of 3,684 cases was treated in HoChiMinh Cancer Hospital and Hue Central Hospital from 2004–2008. Patients who underwent mastectomy was 94.6% with 40.06% lymph node metastasis. Sentinel lympho node biopsy has the appearance rate was 97.8% in Hanoi, 88.% in Hue and 98.6% in HoChiMinh City (N = 226). Breast reconstruction for stage I and II with LD flap and TRAM flap was performed in HoChiMinh Cancer Hospital and Hue Central Hospital with aesthetic good results as 80%, local recurrence 3.6%, distant metastasis 9.1%, the 5 years overall survival rate was 95% and 5 years free-disease survival rate was 80.7% (N = 110).

**Conclusions:** Breast cancer is common disease in Vietnam and most of patients often admitted hospital with stage III and IV. However, this study also suggest that early diagnosis and curative treatment of breast cancer patients can improve quality of life and long-term survival .



**Figure:** TRAM flap breast reconstruction

**Abstract ID: 1079**      Specific Field: **Breast Surgery**

**Mode of pres.: Poster Exhibition only**  
**ISW 2011 Session PE 452**

#### Does the presence of ductal carcinoma-in-situ (DCIS) affect re-excision rate following breast conserving surgery %3F

A. Hassan, J. Lee, S. Monib, C.L. Edwards, S. Baldota, S. Raymond, L.M. Lai, S. Thomson

West Hertfordshire Breast Unit, St Albans, United Kingdom

**Introduction:** In carefully selected patients, breast conserving surgery is well established as a safe treatment for both ductal carcinoma-in-situ (DCIS) and invasive breast cancer. The benefits of improved cosmesis and reduced psychological morbidity do not compromise overall mortality rates. However, incomplete excision of the tumour at the initial operation negates much of this benefit and risks local recurrence. Re-excision is therefore necessary in such cases. Current published literature report incomplete excision in 10–25% of cases. We investigate whether the presence of DCIS influences re-excision rate in our unit.

**Material and Methods:** A retrospective review was performed on all patients undergoing wide local excision of breast cancer in our unit between November 2008 and December 2009. All surgery were performed by surgeons of West Hertfordshire breast unit. All patients were discussed in multidisciplinary meetings and the histology reports of all excised tumour specimens reviewed.

**Results:** 159 patients of median age 58 (range 32–93) underwent wide local excision (70 wire-guided). Of these, 87 patients had DCIS, either alone or mixed with invasive carcinoma. There was a significant difference in the re-excision rate of patients with DCIS compared to those without (35 of 87 vs 11 of 72,  $P = 0.0006$ ,  $\chi^2$ ). Moreover, there was a trend in patients with DCIS being more likely to require a completion mastectomy (3 of 72 with no DCIS vs 11 of 87 with DCIS;  $P = 0.06$ ,  $\chi^2$ ). However, there was no significant difference in operative specimen weight between DCIS and no DCIS groups: 38 (6–218) g vs 36.5 (8.5–225) g ( $P = 0.43$ , Mann-Whitney U). On the other hand, there was significant difference between the clear vs re-excision groups in terms of specimen weight: 42 (8–225) g vs 34.9 (6–160) g ( $P = 0.047$ , Mann-Whitney U).

**Conclusions:** In our patient cohort, the presence of DCIS is associated with an increased risk of incomplete or close excision margins following breast conserving surgery. Patients needing re-excision also had smaller operative specimens by weight. Thus, if the patient is known to have DCIS pre-operatively, then a more generous resection may reduce the need for further re-excision surgery.

**Abstract ID: 1080**      Specific Field: **Metabolism/ Nutrition/Critical Care**

**Mode of pres.: Best Paper Session FP**  
**ISW 2011 Session 70.01**

#### Modulation of cancerous signal transduction and improvement of clinical outcome by perioperative BCAA administration in liver cancer patients

S. Haji [1], H. Ohyanagi [2], T. Nishio [1], M. Kudo [1], Y. Takeyama [1]

[1] Kinki University School of Medicine, Osaka-Sayama, Japan,  
[2] Kindai-himeji University, Himeji, Japan



**Introduction:** It is little known whether nutritional intervention influences cancerous signaling pathway and improves the prognosis in surgical cancer patients. Recently, the oral administration of branched-chain amino acid (BCAA) has been reported to reduce the event of carcinogenesis due to insulin resistance (IR) in cirrhotic patients. Herein, We designed this study to investigate the change of the cancerous signal transduction associated with mammalian target of rapamycin (mTOR), and the clinical outcome by perioperative BCAA administration for surgical patients with hepatocellular carcinoma (HCC).

**Material and Methods:** Ninety-four HCC patients scheduled to undergo curative liver resection were prospectively divided into two groups as following; BCAA group ( $n = 48$ ), given oral granular BCAA 12 g/day from 30th day prior to operation, and Control group ( $n = 46$ ), without supplementation. BCAA, glucose and insulin levels were measured perioperatively, and HOMA-IR (glucose  $\times$  insulin/405) was calculated as the index of IR. The clinical outcome was investigated. Moreover, quantitative mRNA expression of cancerous mTOR-associated signaling pathway (mTOR, Raptor, Rictor, Rheb, EIF4E, TSC1, S6K) and apoptosis-associated protein (BAD and bcl-2) were analyzed by RT-PCR of total RNA extracted from resected cancer specimens of the both group patients (BCAA;  $n = 20$ , Control:  $n = 19$ ).

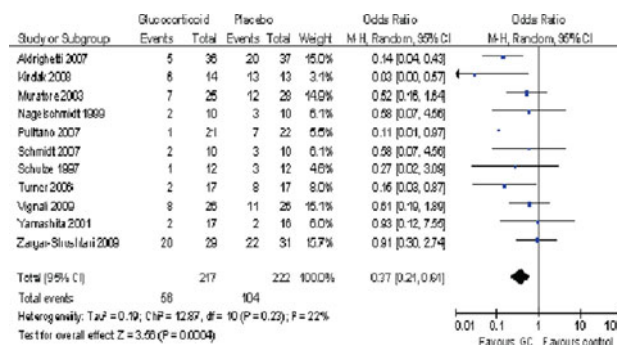
**Results:** Background date of both group were well matched. Blood BCAA level on 0 POD were higher, in contrast, insulin levels and HOMA-IR on 1, 3 POD were lower in BCAA group than Control group. The frequency of postoperative infectious complications was lower in BCAA group. High mRNA expression of mTOR, Raptor, and BAD were observed in BCAA group with statistical significance, although there was no difference in tumor size, differentiation, and stage of both group. Moreover, Bad mRNA expression was significantly correlated with blood BCAA level ( $r = 0.52$ ,  $P = 0.001$ ). Consequently, the survival rate of BCAA group was higher than Control group.

**Conclusions:** Perioperative nutritional intervention with BCAA for HCC patients is considered to be promising for better clinical outcome after curative resection, by modulating the cancerous signaling pathway associated with apoptosis and the host metabolic condition including IR.

**Material and Methods:** A systematic review and meta-analysis was conducted of all RCTs exploring preoperative GC administration in major abdominal surgery for the endpoints of complications, hospital length of stay (LOS) and serum cytokine release. Subset analyses by procedure were planned 'a-priori.'

**Results:** Eleven RCTs of moderate quality, comprising 439 patients in total, were included in the analysis. Preoperative GC use decreased complications (OR = 0.37; 95% CI: 0.21, 0.64;  $P < 0.01$ ), infectious complications in particular (OR = 0.35; 95% CI: 0.18, 0.67;  $P < 0.01$ ), LOS (Mean = 1.97 days; 95% CI: -3.33, -0.61;  $P = 0.01$ ) and serum IL-6 (Mean: -55 pg/ml; 95% CI: -82.30, -27.91;  $P < 0.01$ ). Preoperative GCs decreased complications (OR = 0.28; 95% CI: 0.14, 0.55;  $P < 0.01$ ) and mean LOS (mean LOS: -2.66; 95% CI: -5.01, -0.32;  $P = 0.03$ ) in hepatic resection. GCs reduced mean LOS in patients undergoing colorectal surgery (mean LOS: -0.98; 95% CI: -1.67, -0.27;  $P = 0.01$ ). There was no difference in overall complication rates (OR: 0.45; 95% CI: 0.16, 1.32;  $P = 0.15$ ) nor anastomotic leaks specifically.

**Conclusions:** Preoperative administration of GCs decreases complications and LOS after major abdominal surgery as a likely consequence of attenuating the post-surgical inflammatory response. There is no evidence of increased complications in colorectal surgery.



**Figure:** Total complications

**Abstract ID: 1081**

Specific Field: **Metabolism/  
Nutrition/Critical Care**

Mode of pres.: Best Paper Session FP  
ISW 2011 Session 70.02

**Preoperative glucocorticoid administration in major abdominal surgery: systematic review and meta-analysis of randomised trials**

S. Srinivasa, A. Kahokehr, T.C. Yu, A.G. Hill

Department of Surgery, University of Auckland, Auckland, New Zealand

**Introduction:** The metabolic response to major abdominal surgery is partially mediated by the excessive release of pro-inflammatory cytokines, which is associated with adverse outcomes. Previous randomised controlled trials (RCTs) in major abdominal surgery have produced conflicting results regarding the short-term benefits of preoperative glucocorticoid (GC) administration to attenuate this metabolic response and the safety of this intervention has not been conclusively determined. Thus, we wished to determine the clinical safety and efficacy of preoperative administration of GC in major abdominal surgery with regards to short term outcomes.

**Abstract ID: 1082**

Specific Field: **Metabolism/  
Nutrition/Critical Care**

Mode of pres.: Best Paper Session FP  
ISW 2011 Session 70.03

**Galactooligosaccharide (GOS) prebiotic supplementation increases the severity of injury after intestinal ischaemia/reperfusion (I/R) injury: analysis by global metabolic profiling in a rat model**

J. Kinross [1], E. Deaville [2], R. Barton [1], D. Silk [1], R. Goldin [1], E. Holmes [1], J. Nicholson [1], A. Darzi [1]

[1] Imperial College London, London, United Kingdom, [2] Reading Food Biosciences Unit, Reading, United Kingdom

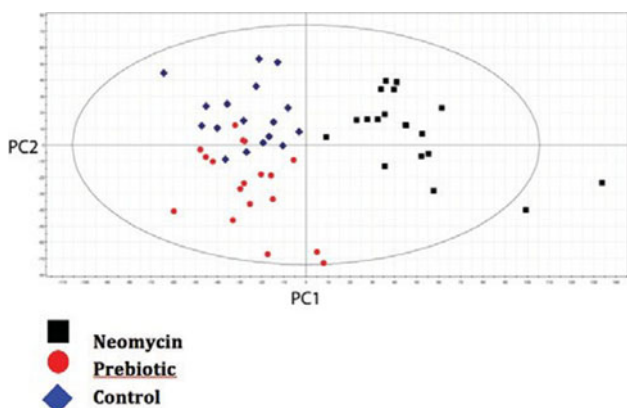
**Introduction:** Modulation of the gut flora may improve outcome after surgery. We assessed the effect of a GOS prebiotic compared to selective decontamination of the gut prior to I/R injury.

**Material and Methods:** A double blinded randomised control study dosed Wistar rats with a placebo ( $n = 20$ ), GOS ( $n = 20$ ; 3.5 g/Kg/day) and Neomycin (NM) ( $n = 20$ ; 400 mg/Kg/day). An SMA tie off model delivered 20 mins of ischaemia and 90 min of reperfusion. Urine, plasma and stool samples were taken for 5 days. Samples were analysed

by 600 MHz  $^1\text{H}$  Nuclear Magnetic Resonance and multivariate analysis. Denaturing Gel Electrophoresis of microbial 16S rDNA measured variation in the large bowel gut microbiota. Plasma cytokine concentrations were obtained using the Meso Scale Discovery multi cytokine platform. Univariate data were analysed by ANOVA.

**Results:** There was no significant difference in mortality between groups ( $P < 0.403$ ). GOS animals had a raised histological score of ischaemic injury ( $P < 0.001$ ). GOS ( $260 \text{ g} \pm 22.48$ ,  $P < 0.001$ ) and NM ( $243.85 \text{ g} \pm 17.41$ ,  $P < 0.0001$ ) animals lost more weight than controls. The GOS elicited raised levels of post dose, preoperative plasma TNF $\alpha$  and IL-1 ( $P < 0.05$ ). Principal component analysis of small bowel tissue, urine and stool analysed by  $^1\text{H}$ NMR demonstrated significant metabolic variability between treatments ( $R^2 = 0.723, 0.78$  and  $0.729$  respectively). Urine and stool PLS-DA had greatest predictive capacity for nutritional class description on day 1 ( $Q^2 = 0.504, 0.41$ ). Microbial co-metabolites hippurate, butyrate and acetate were responsible for GOS and NM class description. Decreased levels of LDL and VLDL, and raised lactate, choline and glycolytic intermediates were found in urine, stool and plasma of the NM group. These data correlated with a significant variance in the microbial ecology between groups (Simpson's diversity index  $P > 0.001$ ). Sequencing of DGGE bands suggested variation of *Bacteroides*, *E. Coli*, *lactobacillus* and *Ruminococcus* species between GOS and NM treated animals.

**Conclusions:** Preoperative GOS exacerbates the injurious effect of intestinal I/R and neomycin is deleterious for mammalian post-operative energy metabolism. Systems metabolism permits individualised analysis of the responses to surgical nutrition.



**Figure:** PLS-DA Scores plot of urine samples analysed by  $^1\text{H}$ NMR spectroscopy

**Abstract ID: 1083**

Specific Field: **Metabolism/  
Nutrition/Critical Care**

Mode of pres.: **Free Paper**  
ISW 2011 Session 80.01

### Impact of the ACERTO project in postoperative outcome in a university hospital

A. Bicudo-Salomao, M. Bertocco Meirelles, C. Caporossi, J.E. Aguilar-Nascimento

Federal University of Mato Grosso, Cuiaba, Brazil

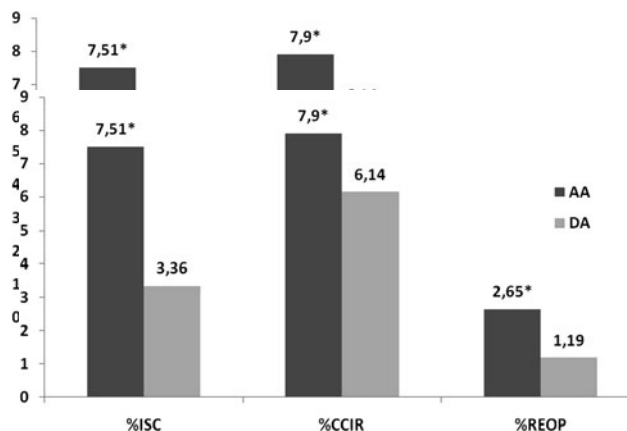
**Introduction:** Traditional care of surgical patients is most guided by empirism. Evidence based routines are not usually followed by many institutions around the world. In 2005 we initiated a multimodal protocol (ACERTO project) in the Julio Muller University Hospital,

in Brazil. The following routines were implemented: 1. preoperative fasting of 2 h, no mechanical bowel preparation, reduction of intravenous fluids, no use of nasogastric tubes and drains, early postoperative feeding, preoperative information, early postoperative mobilization, and improvement in perioperative nutrition. The aim of this study was to evaluate the postoperative results of patients underwent two different routines of perioperative care: traditional care or the ACERTO protocol.

**Material and Methods:** Prospective cohort study of involving 5824 patients. We compared two periods: from January 2002 to December 2004 (before the implementation of the ACERTO project; AA period;  $n = 1987$ ) and from January 2005 and December 2008 (after the implementation of the ACERTO project; DA period;  $n = 3987$ ). The endpoints were length of stay, blood transfusions units, surgical site infections, postoperative complications, and deaths.

**Results:** The two groups were homogeneous in age, sex, type of operations, duration of operations, and ASA score. There was a decrease in one day of hospitalization between AA and DA periods (median [range]: 4 [0–137] vs. 3 [0–126] days, and mode: 3 vs. 2 days;  $P < 0.001$ ). The number of blood units transfused per patient dropped from 2.53 to 0.77 between the periods ( $P < 0.001$ ). Outcome results can be seen in Figure 1. A significant decrease in surgical site infections (AA: 7.51% vs. DA: 3.36%;  $P < 0.001$ ; RR = 2.23; 95% CI: 1.73–2.89), postoperative complications (AA: 7.9% vs. DA: 6.14%;  $P = 0.02$ ; RR = 1.29; 95% CI: 1.03–1.60), re-operations (AA: 2.65% vs. DA: 1.19%;  $P < 0.001$ ; RR = 2.22; 95% CI 1.43–3.44), and deaths (2.81% vs. 1.73%;  $P < 0.01$ ; RR = 1.63; 95% CI: 1.15–2.31) was found when AA period was compared to DA period.

**Conclusions:** The implementation of the ACERTO project in this University Hospital impacted in surgical outcome showing a decreased length of hospital stay, morbidity, units of blood transfusion, and deaths.



**Figure:** Rates of surgical site infections (%ISC), postoperative complications (%CCIR), and re-operations (%REOP) before (AA) and after (DA) the ACERTO project (\* $P < 0,05$  vs. DA)

**Abstract ID: 1084**

Specific Field: **Metabolism/  
Nutrition/Critical Care**

Mode of pres.: **Free Paper**  
ISW 2011 Session 80.02

**Compensatory anti-inflammatory response syndrome (CARS) is present in cachectic patients with gastric and colorectal cancer and correlates to nutritional impairment, immune suppression and poor prognosis**

M. Shibata [1], K. Sakurai [2], S. Fujisaki [2], T. Shimura [1], K. Gonda [1], S. Ohki [1], R. Tomita [2], S. Takenoshita [1]

[1] Fukushima Medical University, Fukushima, Japan, [2] Nihon University School of Medicine, Tokyo, Japan

**Introduction:** Compensatory anti-inflammatory response syndrome (CARS) is commonly seen in patients with surgical stress such as post-surgery condition, severe infection or burn. This mechanisms of inflammatory reaction has been reported to be characterized by high serum levels of anti-inflammatory complex such as soluble receptor for interleukin (IL)-2 (sIL-2R), tumor necrosis factor (sTNF-R1) or IL-1 receptor antagonist (IL-1ra), and has been reported to participate in developing cachexia.

**Material and Methods:** These 3 molecules were measured by enzyme immunoassay in sera of 36 patients with gastric cancer, 66 with colorectal cancer, 34 with benign diseases and 10 normal volunteers in this study. Nutritional parameters including prealbumin, transferrin and retinol binding protein were measured and, thymidine uptake of lymphocytes and surface markers of CD3, CD4 were studied for immunologic parameters.

**Results:** The concentrations increased with the advance of diseases and showed highest levels in patients with cachexia. These levels were inversely correlated with serum concentrations of albumin ( $P < 0.05$ ), prealbumin ( $P < 0.05$ ), transferrin ( $P < 0.05$ ), retinol-binding protein ( $P < 0.05$ ) and zinc ( $P < 0.05$ ). These serum levels were also inversely correlated to markers of immune response including thymidine incorporation of T cells ( $P < 0.05$ ) and percentage of CD3(+) cells ( $P < 0.05$ ). The survival of cachectic patients with gastric cancer was longer in patients with sIL-2 levels of higher than 1000 U/ml ( $P < 0.05$ ) or with sTNF-R1 of higher than 1300 pg/ml ( $P < 0.05$ ).

**Conclusions:** CARS, underlying in cancer cachexia, seemed to be important for patient care, and sIL-2R, sTNF-R1 and IL-1ra are useful markers for nutritional damage and poor prognosis. A new strategy using immune alteration may need to be tried to treat patients with cancer cachexia.

**Abstract ID: 1085**

Specific Field: **Metabolism/  
Nutrition/Critical Care**

**Mode of pres.: Free Paper  
ISW 2011 Session 80.03**

**The effect of parenteral nutrition with n-3 PFAs-enriched lipids on neutrophil apoptosis in the PB and BM during endotoxin-induced systemic Inflammation**

M. Terashima [1], J. Kotani [1], A. Hagi [2], M. Aoyama [3], K. Kohama [1], M. Nakayama [2]

[1] Department of Emergency and Critical Care, Hyogo College of Medicine, Nishinomiya, Japan, [2] R&D Center, Otsuka Pharmaceutical Factory, Inc., Naruto, Japan, [3] Department of Biophysics, Kobe University School of Medicine, Kobe, Japan

**Introduction:** Decreased neutrophil (PMN) apoptosis (Apo) is implicated in persistent inflammation leading to organ injury. Leukotrien (LT) B<sub>4</sub>, the final product of n-6 polyunsaturated fatty acids (PUFAs), is among the mediators that decrease PMN Apo. Although dietary supplementation with n-3 PUFAs decreases n-6 PUFAs products, in general less than 20% of ICU patients can be given the full dose of enteral nutrition.

**Material and Methods:** SD male rats were fed with fat-free chow for 2 weeks, then received fat-free parenteral nutrition (PN) (NF group), n-3 PUFAs-rich PN (n-3 group, 20% fat, n-6/n-3 ratio = 1) or n-6

PUFA-rich PN (n-6 group, 20% fat, n-6/n-3 ratio = 10) for 3 days thorough an intravenous tube placed in the internal jugular vein. All the rats were i.p. injected with saline or LPS (5 mg/kg) followed by collecting peripheral (PB) and bone marrow cells(BM) after 24-h. PMNs were defined with PMN- specific antibody and then apoptosis was assessed by annexin V and propidium iodide staining using two-color flow cytometry after 6-h whole blood or whole cell culture, respectively. Fatty acids (FA) composition and LT B<sub>4</sub> and B<sub>5</sub> production in peritoneal exudate cells (PECs) were also measured by gas chromatography and HPLC, respectively. Statistics were assessed using repeated measures ANOVA and Neuman-Keuls post-hoc test.

**Results:** PMN Apo was significantly decreased after LPS injection in both PB and BM. Among LPS-injected groups, Apo was significantly higher in the n-3 group than in the NF and n-6 group in both PB and BM although the difference was more significant in BM than PB. Microscope examination using Giemsa staining revealed over 95% of PECs were PMNs. PEC production of LT B<sub>5</sub> was significantly higher and LT B<sub>4</sub> production was significantly lower in the n-3 group than in other two groups. The amount of n-3 PUFAs in PMNs was 3-times more in the n-3 group than in other two groups, and EPA/AA ratio in PB was well correlated with LT B<sub>5</sub>/B<sub>4</sub> production ratio of PECs.

**Conclusions:** Only 3-days parenteral nutrition with n-3 PUFAs-enriched lipids resulted in a significant increase in n-3 PUFAs content and LTB<sub>5</sub> production in PMNs and restored inhibited Apo in PB PMNs and BM PMNs during systemic inflammation.

**Abstract ID: 1086**

Specific Field: **Metabolism/  
Nutrition/Critical Care**

**Mode of pres.: Free Paper  
ISW 2011 Session 80.04**

**Perioperative fluid boluses for oliguria constitute a significant fluid load in elective colorectal surgery**

J. Puckett, M. Soop

University of Auckland, Auckland, New Zealand

**Introduction:** Perioperative intravenous fluid overloading is an important cause of postoperative morbidity. Fluid boluses are currently used to treat perioperative oliguria and hypotension. We hypothesised that such fluid boluses constitute a significant fluid load.

**Material and Methods:** Data on 100 consecutive patients undergoing elective colorectal surgery in traditional perioperative care were obtained from a prospective perioperative database. Additional data was collected on continuous intravenous fluid volumes, number of fluid boluses (250 ml) and their indication, and number of episodes of oliguria (intraoperative urine output  $< 0.5$  ml/kg/h during surgery;  $< 2$  ml/kg/4 h after surgery) during surgery and the subsequent 48 h.

**Results:** 44 patients were male; mean (SD) age was 67 (17) yrs; body weight was 75.9 (18.2) kg; 24 had ASA score 3. Duration of surgery was 3 h 23 min (1 h 14 min); 39 operations were completed laparoscopically. 54 patients received thoracic epidural analgesia 24 h. During surgery, 2459 (987) ml fluids were given as continuous infusion; during the first 48 h after surgery, 3658 (1598) ml were given. During surgery, 43 patients received 1–6 fluid boluses (mean, 2.7 boluses or 675 ml), 42 of whom for oliguria. After surgery, 66 patients received 1–16 fluid boluses (mean, 3.6 boluses or 900 ml), 51 of whom for oliguria. During and after surgery, 4 (mean, 2.8 episodes) and 85 (mean, 6.6 episodes) patients had oliguria per study definition, respectively. Urine output during surgery was 526 (371) ml; during the 48 h after surgery, 3759 (1244) ml. Mean serum creatinine concentrations on

day 2 were unchanged from preoperatively; 5 patients developed transient acute kidney injury (serum creatinine increase by 50%). The change in creatinine was not correlated to urine output during or after surgery.

**Conclusions:** Despite high volumes of perioperative fluid infusion, nearly all patients had oliguric episodes as traditionally defined after surgery. Most patients therefore received fluid boluses; boluses constituted approximately 20% of intravenous fluids, significantly contributing to perioperative fluid overloading. Perioperative urine output was not correlated to postoperative changes in serum creatinine, and may be an overemphasised target in current practice.

**Abstract ID: 1087**

Specific Field: **Metabolism/  
Nutrition/Critical Care**

**Mode of pres.: Free Paper  
ISW 2011 Session 80.05**

**Utilization of endogenous fat and exogenous administered long chain fatty acid (LCFA) and middle-chain fatty acid (MCFA) during the early phase after surgery**

J. Kotani [1], T. Inoue [1], M. Usami [2], A. Miyawaki [1], M. Kawai [1], T. Osako [1], M. Ohya [1], K. Kuboyama [1]

[1] Hyogo College of Medicine, Nishinomiya, Japan, [2] Kobe University Faculty of Health Sciences & Graduate School of Medicine, Kobe, Japan

**Introduction:** Middle-chain fatty acid (MCFA) may be utilized more effectively than long chain fatty acid (LCFA) after surgery because it can be taken into the cells without carnitine that is often lack during systemic inflammation. The purpose of this study was to elucidate utilization of exogenous long chain fatty acid (LCFA) and middle-chain fatty acid (MCFA) administered intravenously during the early phase after surgery.

**Material and Methods:** A prospective case-control study of 13 patients underwent elective surgery for carcinoma. The patients received parenteral supply of adequate glucose and amino acids through central venous catheter after surgery equally. The group LCFA was given 250 ml of 10% LCFA emulsion whereas the group MCFA was given 250 ml of 5% LCT and 5% MCFA emulsion at the rate of 50 ml/h. Inflammatory cytokines such as TNF-alpha, IL-1 and IL-6, stress hormones such as norepinephrine, glucagon and insulin, and fuel utilization and hypermetabolism variables such as resting energy expenditure (REE), CRP, free fatty acid, respiratory quotient, the calculated rates of glucose and fat oxidation using indirect calorimetry were measured serially (the day before operation, the end of surgery, and postoperative day (POD) 1, 2 and 5).

**Results:** All the measured parameters were not different between the groups, indicating surgical stress was similar in both groups. Energy expenditure increased on POD 2 (LCT:  $107.7 \pm 5.6$  vs MCT:  $117.9 \pm 9.7$  kcal/day) and then decreased to supra-normal level by POD 5, and there was no difference between the groups. Although utilization of endogenous fat was significantly increased on POD 1 in both groups, it was higher in the group MCFA than in the group LCFA. Exogenous fat was utilized most effectively on POD 5 in both groups and there was no difference between the groups during the study period (1POD:  $13.5 \pm 4.0$  vs  $0.5 \pm 7.9$ , 2POD:  $1.7 \pm 1.6$  vs  $0.1 \pm 0.1$ , 5POD:  $25.7 \pm 5.2$  vs  $22.8 \pm 4.6$  mg/min  $m^2$ ).

**Conclusions:** Despite of enough supply of glucose and amino acids, endogenous fat is preferentially utilized. Exogenous LCFA and MCFA was equally utilized, however, utilization of both LCFA and MCFA were limited early phase after surgery.

**Abstract ID: 1088**

Specific Field: **Metabolism/  
Nutrition /Critical Care**

**Mode of pres.: Free Paper  
ISW 2011 Session 80.06**

**Could be replaced liver biopsy by the non-invasive markers in non-alcoholic fatty liver disease diagnosis?**

G. Ianosi [1], D. Neagoe [1], M.X. Calbureanu-Popescu [2], M. Popescu [1], M. Dinca [1], V. Comanescu [3], C. Popescu [3]

[1] University of Medicine and Pharmacy, Craiova, Romania, [2] University, Craiova, Romania, [3] Emergency Hospital, Craiova, Romania

**Introduction:** The gold standard in diagnosis of non-alcoholic fatty liver disease (NAFLD) is liver biopsy. During the last years there are several non-invasive methods that tried to replace liver biopsy. The aim of our study was to find the concordance between liver biopsy and non-invasive methods.

**Material and Methods:** We included 54 patients with NAFLD (31 females and 23 males) with mean age 54.1 years. Patients with other conditions known to be associated with hepatic steatosis (including alcohol consumption) were excluded from this prospective study. In all patients we measured: BMI, waist circumference, aminotransferases (ALT, AST), triglycerides, gamma-glutamyltranspeptidase ( $\gamma$ -GT), alkaline phosphatase (AP) and serum adipokines (leptin, adiponectin). We calculated the BAAT score as a sum of categorical variables: BMI, age, levels of ALT and serum triglycerides, ranging from 0 to 4. A score of 0 or 1 would suggest patients without septal fibrosis. Steatosis was evaluated by US and we used a semiquantitative scale of 1 (mild) to 3 (severe). All patients benefit from a liver biopsy and we used Matteoni's classification for the histological samples. Liver biopsy was performed during laparoscopy for associated diseases or by percutaneous puncture.

**Results:** Aminotransferases and US description didn't correlated with histological classification. Adiponectin correlated negatively with histological features ( $P = 0.000$ ) but we found no relationship between leptin level and histological classification. BAAT score correlated positively with histological features ( $P = 0.000$ ) and leptin level ( $P = 0.002$ ) and negatively with adiponectin ( $P = 0.000$ ). We didn't find any correlation with US classification ( $P = 0.955$ ). BMI correlated positively with histological classification ( $P = 0.001$ ), leptin ( $P = 0.000$ ), US ( $P = 0.02$ ) and negatively with adiponectin ( $P = 0.013$ ), but no correlation between BMI and aminotransferases. Waist circumference didn't correlate with histological features and adiponectin level but correlated with leptin ( $P = 0.000$ ).

**Conclusions:** 1. In our study liver biopsy could not be replaced by the association between anthropometric measures, US steatosis and biochemical markers. 2. Some association like BMI, high levels of triglycerides, high BAAT score and low level of adiponectin represent non-invasive markers for the selection of patients who require liver biopsy.

**Abstract ID: 1089**

Specific Field: **Metabolism/  
Nutrition/Critical Care**

**Mode of pres.: Free Paper  
ISW 2011 Session 80.07**

**Features of nutritional status of the patients in surgery ward: results of the Nutrition Day Project**

T. Inaba [1], R. Fukushima [1], N. Hanaue [2], H. Asakura [2], M. Hayasaki [2], T. Kurosaki [2], Y. Takemaru [2]



[1] Department of Surgery, Teikyo University School of Medicine, Tokyo, Japan, [2] Nutrition Support Team, Teikyo University Hospital, Tokyo, Japan

**Introduction:** European Society for Clinical Nutrition and Metabolism promoted the Nutrition Day Project, that was one-day cross-sectional screening test of nutritional status in hospitals, world-widely in 2010. We performed this study in our hospital and found some features of nutritional status of patients hospitalized in surgery ward. **Material and Methods:** We investigated 215 Japanese patients totally, including 74 in internal medicine ward, 66 in surgery ward, 52 in orthopedics ward, 16 in otolaryngology ward and 7 in plastic surgery ward. The study headings were background of the patients, disease, food intake before and on the Nutritional Day, nutritional status including the change of their body weight, nutritional support including the usage of parenteral and/or enteral nutrition (line of tube feeding).

**Results:** About 80% of the patients in the surgery ward were cancer patients. They lost their body weight before the study and ate less on the Nutrition Day than the amount before admission. Many of them had lines and/or tubes and received parenteral or enteral nutrition support. Many of the patients in otolaryngology ward did not have nutritional problem, however some did not eat enough and received parenteral nutrition. Most of the patients in the internal medicine ward did not lose their body weight, however patients with malignant diseases (lung cancer and leukemia were the majority of them) lost their body weight before surgery. In contrast with the other wards, almost all of the patients in orthopedics ward ate well and did not need nutritional support.

**Conclusions:** The nutritional status of the many patients in surgery ward was not good comparing with patients in other wards, and they needed nutrition support. Not only the surgical stress and operation of the gastrointestinal tract but also the fact that many of them had malignant diseases might affect their nutritional status.

**Abstract ID: 1090**

Specific Field: **Metabolism/  
Nutrition/Critical Care**

**Mode of pres.: Free Paper  
ISW 2011 Session 80.08**

**Modified enhanced recovery after surgery (mERAS) program:  
improving patients outcomes for colorectal surgical patients**

T. Sasatomi [1], K. Shirouzu [2], Y. Ogata [1]

[1] Kurume University Medical Center, Kurume, Japan,  
[2] Kurume University, School of Medicine, Kurume, Japan

**Introduction:** A recent development in elective large bowel surgery is the introduction of fast track peri-operative care, also referred to as enhanced recovery after surgery (ERAS). Since April 2009, we have adopted modified ERAS program, as perioperative care, for colorectal surgical patients and report the outcomes compared with conventional peri-operative care program.

**Material and Methods:** From April 2009, 88 elective patients receiving colorectal surgery (excluding defunctioning stoma formation and ileostomy reversals procedures) were examined. 41 of 88 patients (mERAS group: male/female 22/19, average age  $68.1 \pm 12.7$  years old) were cared with mERAS program and the other 47 of 88 patients (Conventional care group: male/female 19/28, average age  $68.6 \pm 12.1$  years old) were cared with conventional peri-operative care program after surgery. And the averages of hospital stay after surgery and the incidences of complications were comparatively investigated between two groups. The each program of two groups as follows:

Modified ERAS group

- (1) 1 day before operation No fast of feeding, no bowel preparation
- (2) Four hours after surgery Stomach tube was removed and Intake of water was started
- (3) 1 day after operation Consumption of a liquid diet was started
- (4) 2 days after operation Consumption of food diet was started program completed rate  $28/41 = 68.3\%$
- (5) Conventional care group program completed rate  $31/47 = 66.0\%$

**Results:** Hospital stay after surgery were 25.0 days at mERAS group and 32.1 days at conventional care group. Hospital stay after surgery (excluding duration of chemotherapy) were 21.0 days at mERAS group and 24.5 days at conventional care group. At the both kind of hospital stay, the durations of mERAS group were shorter than those of control group. But there was no significant between two groups. Incidents of surgical site infection (SSI) were no significant between two groups. Modified ERAS group 19.5% vs conventional care group 21.3%. On the other hand, patients with SSI had significantly longer hospital stay after surgery than those without SSI. 37.0 days vs 19.2 days  $P = 0.0001$

**Conclusions:** The peri-operative care with mERAS program indicates about three days reduction of hospital stay after surgery. And it is more important that the SSI incidence will contribute to reduction of hospital stay after surgery.

**Abstract ID: 1091**

Specific Field: **Metabolism/  
Nutrition/Critical Care**

**Mode of pres.: Free Paper  
ISW 2011 Session 80.09**

**Results of laparoscopic sleeve gastrectomy as a single stage  
bariatric procedure in Japanese patients**

A. Umemura, A. Sasaki, G. Wakabayashi

Iwate Medical University School of Medicine, Morioka, Japan

**Introduction:** The Japanese Society for the Study of Obesity designed new criteria for obesity with comorbidities under the term "obesity disease," with obesity defined as a BMI  $25 \text{ kg/m}^2$ . This threshold is lower than that in some Western countries because Japanese people have obesity-related morbidities at a lower BMI than people in the USA and Europe. Between 2000 and 2009, bariatric surgery was performed for only 340 cases in Japan. The recognition of the need for obesity treatment and experience with bariatric surgery is still undeveloped in Japan. Here we report our short-term outcomes of LSG as a single-stage bariatric procedure.

**Material and Methods:** A prospective database of patients treated within a single institution was studied retrospectively. Between June 2008 and November 2010, a total of eight consecutive patients underwent LSG at Iwate Medical University Hospital in Morioka, Japan. The study contained six men and two women, with a median age of 29 years (range, 24–42 years). The median weight and BMI were 147 kg (range, 99–180 kg) and  $48 \text{ kg/m}^2$  (range, 41–56  $\text{kg/m}^2$ ), respectively. The median number of comorbidities was 5 (range, 4–7). In this report, we will also discuss the examination of genetic polymorphism related to insulin resistance and the adipocytokine secretion capacity of isolation-cultured primary visceral fat cells. The report will also include methylation analyses of obesity-associated genes and the results of the microarray analyses using m-RNA that were conducted to analyze the molecular mechanism involved in the pathogenesis of obesity patients.

**Results:** A Late gastric leak occurred in one patient and was treated with an endoscopic mucosal closure after failed attempts to treat the percutaneous abdominal drainage. The median postoperative body

weight loss and percentage excess weight loss at 1 year were 43 kg (range, 22–45 kg) and 69% (range, 49–87%), respectively. Resolution or improvement rates of comorbidities in seven out of eight patients, who had follow up for more than 1 year were 100% for type 2 diabetes, hypertension, hyperuricemia, and dyslipidemia.

**Conclusions:** For Japanese patients with morbid obesity, LSG may represent an effective weight loss method that can resolve comorbidities in a single-stage bariatric procedure.

**Abstract ID: 1092**                      Specific Field: **Metabolism/  
Nutrition/Critical Care**

**Mode of pres.: Free Paper**  
**ISW 2011 Session 80.10**

#### **Dream & reality in sleeve gastrectomy**

A.H. AlAni, A. Al Dumour, A.H. AlBreizat

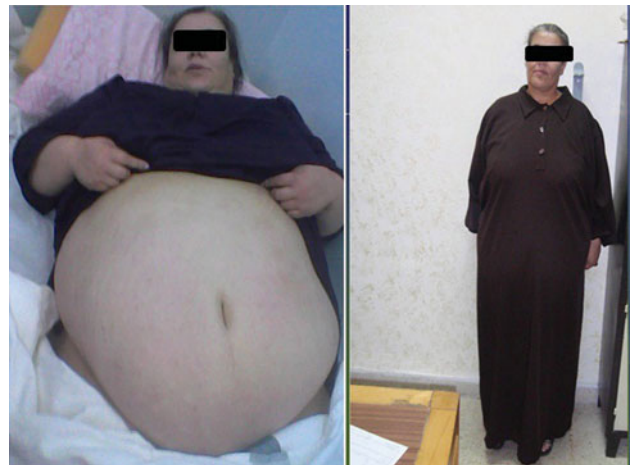AlBashir Teaching Hospital, Amman, Jordan

**Introduction:** Morbid Obesity affects as much as 10% of the American population. The morbidly obese are subject to social stigma & to increased risk of sudden death due to heart attack, stroke & several concomitant health problems. Bariatric procedures are used to treat Morbid Obesity. Sleeve gastrectomy is one of the restrictive bariatric procedures. It includes resection of the fundus and body of stomach to create a long, tubular conduit along the lesser curve (leaving 20–30% of the stomach). Open or laparoscopic approach, can be used. The mechanisms of weight loss and improvement in comorbidities seen after Sleeve gastrectomy might be related to gastric restriction, Neuro-Humoral changes, or some other unidentified factors. Sleeve gastrectomy is not free of problems, It needs a team work, a careful patient preparation & investigation to avoid early & late post operative complications. The Aim of this study is to present our early experience in Sleeve gastrectomy.

**Material and Methods:** 35 patients were selected, 32 females & 3 males, the age range was between 17–49 year. Their weight were between 105–170 kg (mean 147.7 kg) and their waist circumference (mean 117.7 cm) was significantly smaller than that of non-pCR (4.7 ± 2.1 cm). The mean Ki67 index in pCR and non-pCR were 29.6 ± 16.9% and 21.3 ± 16.5%, respectively. Negative ER, negative PgR, positive HER2 status and a higher Ki67 were found to be significantly predictive of a pCR. For NAC regimen, 63 patients received either anthracycline or taxane based regimen (A or T), and 257 patients received both of them (A + T). 18 patients were received concurrent trastuzumab with taxane. 51 (20%) of the patients treated with A + T regimen achieved pCR, while only 5 (8%) of the patients treated with A or T regimen. A significant difference between them was observed. In multivariate analysis, the probability of pCR was directly associated with tumor size [OR for one cm increase, 0.706, 95% confidence interval (CI), 0.564–0.883], Ki-67 index [OR for 10% increase in the percentage of positive cells, 1.023, CI, 1.002–1.044], ER [OR for negative 0.148, CI 0.042–0.522], HER2 [OR for positive 0.461, CI 0.213–0.999] and use of trastuzumab [OR for use 0.074, CI 0.018–0.306].

**Results:** An average of 10 kg loss per month were noted & a marked improvement in weight related co-morbidities (DM, Hypertension, Sleep Apnea, Dyslipidemia) were reported. Wound infection, B12 & Iron deficiency, Hair fall, Vomiting, Port Hernia & GERD were the post operative complication. One patient needed a redo operation (bypass procedure). One patient died because of Guillain-Barré syndrome (not related to the procedure).

**Conclusions:** Sleeve gastrectomy as first step or the only step in treating morbid obesity is a safe procedure, with accepted weight loss, yet it is not without side effects.



**Figure:** A lady before & 3 months after sleeve gastrectomy

**Abstract ID: 1093**                      Specific Field: **Metabolism/  
Nutrition/Critical Care**

**Mode of pres.: Poster Discussion**  
**ISW 2011 Session 100.01**

#### **The mRNA expression of fatty acid amide hydrolase in human whole blood may correlate with recovery in patients with sepsis: assessment with APACHE II and SOFA score**

M. Hamaguchi [1], Y. Murao [1], M. Tanaka [2], N. Tsuda [1], T. Uejima [1], K. Maruyama [1], I. Yanagihara [3], I. Sakata [1]

[1] Department of Emergency and Critical Care Medicine, Kinki University Faculty of Medicine, Osakasayama, Japan, [2] Aishinkai Nakae Hospital, Wakayama, Japan, [3] Department of Developmental Medicine, Research Institute, Osaka Medical Center for Maternal and Child Health, Izumi, Japan

**Introduction:** An excessive accumulation of anandamide (*N*-arachidonyl ethanolamine, AEA) is associated with septic shock. Results of previous studies have suggested that mRNA coding for the AEA degrading enzyme fatty acid amide hydrolase (FAAH), which converts AEA into arachidonic acid and ethanolamine, might be down-regulated in septic shock.

**Material and Methods:** We used real-time reverse transcription PCR assays to measure relative FAAH mRNA concentrations in the whole blood of 30 healthy donors and eight patients with severe sepsis or septic shock to ascertain whether such down-regulation takes place. Since most of patients with sepsis were sedated after hospitalization on the 7th day, evaluation of consciousness level of APACHE II and SOFA score as an index of disease severity were deleted. IL-6 and IL-8 were measured by ELISA. Cytokines of septic patients were measured on admission and at the 7th day after admission.

**Results:** The levels of APACHE II score (without GCS), SOFA score (without GCS), IL-6 and IL-8 were significantly reduced from 13.13 ± 1.91, 6.38 ± 1.22, 264.20 ± 50.85 pg/dl and 82.95 ± 40.19 pg/dl on admission to 9.00 ± 1.68, 5.63 ± 1.08, 78.23 ± 24.18 pg/dl and 25.28 ± 9.47 pg/dl at the 7th day after admission, APACHE II score: *P* < 0.05, SOFA score: no significant difference, IL-6 and IL-8: *P* < 0.01. The levels of the FAAH mRNA were 14.23 ± 7.30 in healthy male and 11.20 ± 3.62 in healthy female. On the contrary, the

levels of the FAAH mRNA in patients with sepsis was significantly reduced to  $0.16 \pm 0.05$  at the admission ( $P < 0.01$ ). At the 7th day after admission, the levels of the FAAH mRNA in patients with sepsis was increased to  $0.33 \pm 0.05$  (not significant compared to admission day levels).

**Conclusions:** These findings indicate that mRNA expression of FAAH in human whole blood may correlate with sepsis, and may be an interesting biomarker for predicting the onset of septic shock. Further investigation should be carried out to determine the relevance of FAAH and cytokines.

**Abstract ID: 1094**

Specific Field: **Metabolism/  
Nutrition/Critical Care**

**Mode of pres.: Poster Discussion  
ISW 2011 Session 100.02**

**Preoperative immunonutrition and postoperative early enteral feeding for patients underwent esophageal cancer surgery**

M. Mizutani, O. Hachiya, H. Isobe, Y. Kamio, W. Kimura

Gastroenterological, General, Breast and Thyroid Surgery Yamagata University, Yamagata, Japan

**Introduction:** Esophageal cancer surgery still results in high morbidity. It is the most important that reduce postoperative infectious complication. Recently, it is reported that preoperative immunonutrition and postoperative early enteral nutrition are useful for reducing such complications.

**Material and Methods:** From 2003 to 2009, 72 patients were performed esophageal cancer surgery in our institution. 50 of these cases, which underwent subtotal esophagectomy with lymphadenectomy were enrolled in this study. Preoperative immunonutrition was given to 33 patients (IED group). Postoperative early enteral nutrition was given to 32 patients (EN group). Both of these treatments were given to 26 patients (IED + EN group). IED group was asked to drink 750 ml/day of IMPACT (Ajinomoto, Japan) for five consecutive days before surgery. EN group was distributed the normal enteral diet delivered through the jejunostomy catheter on POD 1. We investigated postoperative infectious complications and hospital stay.

**Results:** The incidence of infectious complications in IED group and non-IED group were 26.9% and 41.2%, respectively. Postoperative hospital stay was not shorter in IED group. There were no significant differences between EN group and non-EN group about postoperative infectious complications. IED + EN group was lower rate than any other groups in infectious complications.

**Conclusions:** It was suggested that preoperative immunonutrition and postoperative early enteral nutrition could reduce the postoperative infectious complications.

**Abstract ID: 1095**

Specific Field: **Metabolism/  
Nutrition/Critical Care**

**Mode of pres.: Poster Discussion  
ISW 2011 Session 100.03**

**The efficacy of Immuno-modulating diet for perioperative patients of esophageal cancer**

M. Suzuki, H. Inoue, H. Satodate, N. Odaka, H. Ito, S. Kudo

Digestive Disease Center, Showa University Northern Yokohama Hospital, Yokohama, Japan

**Introduction:** From 1990's, Immuno-enhancing diet (IED) containing  $\omega$ -3 fatty acid, glutamine and arginine has been widely used in perioperative patients because many studies have reported that IED decreases perioperative infectious complication such as pneumonia and anastomotic leakage. But from 2000's, it has become clear that IED worsen organ dysfunction instead of improving infection in patients with severe pneumonia or sepsis. So new concept called Immuno-modulating diet (IMD) appeared. IMD contains anti-inflammatory nutrient such as whey-hydrolyzed peptide, antioxidative vitamins, probiotics in addition to  $\omega$ -3 fatty acid and glutamine. IMD is expected to decrease complications in patients with acute inflammatory state such as operation and sepsis. We used IMD to patients of esophageal cancer and retrospectively examined its efficacy.

**Material and Methods:** In this retrospective study, 27 patients with esophageal carcinoma who underwent thoracoscopic esophagectomy with prone position from March 2009 to May 2010 were assigned. First 21 patients received standard EN (standard group), and last 6 patients received IMD (IMD group). Serum WBC count, serum lymphocyte count, serum CRP, body temperature in operative day, post operative day(POD)1, POD5 and incidence of complications were compared between two groups.

**Results:** WBC in POD5 was significantly lower in IMD group. Other parameters had no significant difference between two groups. In IMD group, one severe anastomotic leakage and one aspiration pneumonia occurred. In normal group, seven anastomotic leakage (five cases are mild, two cases are severe) and two aspiration pneumonia occurred. In IMD group, complications are relatively less than normal group, but no significant difference existed.

**Conclusions:** IMD seems to decrease perioperative complications, but no significant difference is detected. Randomized controlled trials are needed to confirm the efficacy of IMD.

**Abstract ID: 1096**

Specific Field: **Metabolism/  
Nutrition/Critical Care**

**Mode of pres.: Poster Discussion  
ISW 2011 Session 100.04**

**Parenteral nutrition infusion during septicemia**

V. Patel, N. Shimizu

Brigham and Women's Hospital, Boston, USA

**Introduction:** Most nutritionists aggressively feed malnourished patients as it is known that critically-ill patients have worse outcomes with increased caloric debt (ICM 2009). Enteral over parenteral feeding is preferred because parenteral nutrition (PN) via a central venous catheter (CVC) can be complicated by bloodstream infection (CRBSI). Septicemia from non-catheter sources in patients who coincidentally have a CVC can also occur. Although some advocate similar management, the US CDC endorses removing a CVC when CRBSI is highly suspected, but doesn't recommend replacement if the infection is thought to be non-catheter related (MMWR 2002). There is a paucity of recommendations from national and international societies regarding the practice to withhold PN during septicemia regardless of etiology. We recently queried a nutritionists' listserv to determine practice regarding PN infusion during septicemia when the line isn't the culprit.

**Material and Methods:** The American Society for Parenteral and Enteral Nutrition Medical Practice Section listserv, the ASPENet listserv, and directed emails were queried, "We have a policy to hold



TPN for 48 h for bacteremia. Do you have the same practice or do you infuse TPN even when you have positive blood cultures?” in April 2009.

**Results:** Of 21 responses, 57% were physicians and 67% were clinicians who work in US academic medical centers >500 beds. 71% don't hold PN for positive blood cultures. However, there was significant heterogeneity in the practice (picture).

**Conclusions:** The consensus among these respondents favors continuing PN during septicemia as long as there is access and the CVC is not the source. The impact of macronutrient infusion, particularly intravenous lipid and glucose, on human immunity has long been debated. Barkowski and Chu found that lipid infusion does delay Staphylococcal blood clearance and depresses granulocytic function in rats (Nutr Research 1989). In contrast, Lenssen et al found no correlation between lipid dose and incidence of bacteremia and fungemia in patients undergoing bone marrow transplantation (AJCN 1998). There is still no consensus among experts on the impact of hyperglycemia and insulin therapy in the critically ill (JAMA 2010). As a result of this literature review and query there is clearly equipoise in PN infusion management in patients with positive blood cultures.

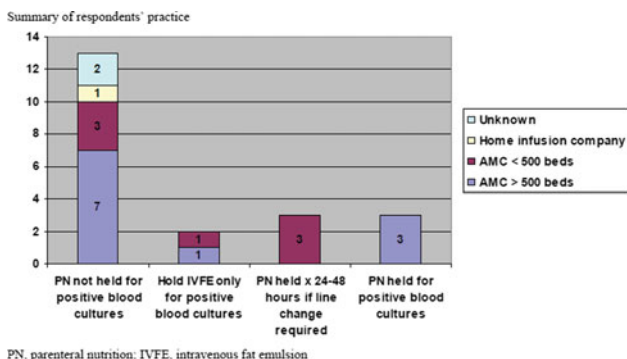


Figure: Summary of respondents' practice

**Abstract ID: 1097** Specific Field: **Metabolism/ Nutrition/Critical Care**

**Mode of pres.: Poster Discussion**  
**ISW 2011 Session 100.05**

**Gastric bypass: a model of metabolic surgery?**

J.Ph.M.m.K. Magesa

Centre Hospitalier de Dinant, Dinant, Belgium

**Introduction:** It is well known that Gastric Bypass has an early and powerful effect of the evolution of Type II diabetes. Other mechanisms than simple weight loss are concerned. We reviewed the literature. We developed and summed up the different studies on the metabolic effects of Gastric Bypass. Alimentary intake, GLP-1, insulinosensitivity, intestinal neoglucogenolysis are among the implicated factors.

**Material and Methods:** The core of this work is to try and understand the mechanisms behind the improvement of type II diabetes secondary to Gastric Bypass. The Metabolic Syndrome,

**Results:** The different studies we reviewed clearly showed it has an important and well documented metabolic effect on type II diabetes. Gastric bypass improves glucose homeostasis, by

mechanisms that go beyond the excess weight loss. In our own experience we are by now ending the collection of data from 212 patients with metabolic co-morbidities. Preliminary results have the same trends.

**Conclusions:** Further studies will be needed to elucidate a number of mysteries, such as why does Gastric Bypass induces intestinal gluconeogenesis. The role of Gastric Bypass on the intestinal neoglucogenesis is not yet well established. All these results are very exciting but we should be careful about eventual unexpected long term consequences?

**Abstract ID: 1098** Specific Field: **Metabolism/ Nutrition/Critical Care**

**Mode of pres.: Poster Discussion**  
**ISW 2011 Session 100.06**

**Post-gastrectomy spleen enlargement and esophageal varices: distal versus total gastrectomy**

T. Oida [1], K. Mimatsu [1], H. Kano [2], A. Kawasaki [1], Y. Kuboi [1], N. Fukino [1], K. Kida [1], S. Amano [3]

[1] Social Insurance Yokohama Central Hospital, Yokohama, Japan, [2] Social Insurance Yokohama Central Hospital, Japan, [3] Nihon University School of Medicine, Tokyo, Japan

**Introduction:** Esophageal varices (EVs) are one of the major life-threatening complications of liver cirrhosis, and its prevalence rate is approximately 40% at the time of diagnosis, and 60% of those with decompensated disease. When EVs rupture, the mortality rate ranges from 17 to 57%. Therefore, screening of all patients diagnosed with liver cirrhosis for the presence of EVs is recommended. However, spleen enlargement is frequently observed during follow-up of non-cirrhotic patients who have undergone gastrectomy. Thus, we studied the relationship between the platelet count-to-spleen diameter ratio and the development of EVs, and compared distal and total gastrectomy with regard to these variables in patients without liver cirrhosis or hepatitis.

**Material and Methods:** We retrospectively studied 92 patients who underwent gastrectomy. They were divided into 2 groups on the basis of the surgical treatment: the distal gastrectomy (DG) group and total gastrectomy group (TG). The incidence of esophageal varices was determined and postoperative platelet counts, spleen diameters, and platelet count-to-spleen diameter ratios were compared between the 2 groups.

**Results:** Esophageal varices were not detected during the first 6 months after the surgery in both groups; however, at 12 months after surgery, esophageal varices were detected in 2 patients (3%) in the

Clinical data on postoperative 12 months

	DG group (n = 64)	TG group (n = 28)	P value
Platelet count	26.8	27.5	0.4358
Spleen diameter (mm)	102.4	105.9	0.0843
Platelet count/spleen diameter ratio	2628	2604	0.7887
Esophageal varices			
Grade 1	2 (3%)	1 (3.6%)	1.00
Grade 2	0 (0%)	0 (0%)	1.00
Grade 3	0 (0%)	0 (0%)	1.00
Total occurrence rate	2 (3%)	1 (3.6%)	1.00



DG group and in 1 patient (3.6%) in the TG group; their mean platelet count-to-spleen diameter ratio was  $2628 \pm 409$ , and  $2604 \pm 360$ , respectively.

**Conclusions:** Endoscopy should be performed to detect esophageal varices when the platelet count-to-spleen diameter ratio is  $<2600$ .

#### Abstract ID: 1099

Specific Field: **Metabolism/  
Nutrition/Critical Care**

Mode of pres.: **Poster Discussion**  
ISW 2011 Session 100.07

#### Early implantation of Denver shunt

T. Oida [1], K. Mimatsu [1], H. Kano [1], A. Kawasaki [1],  
Y. Kuboi [1], N. Fukino [1], K. Kida [1], S. Amano [2]

[1] Social Insurance Yokohama Central Hospital, Yokohama, Japan,  
[2] Nihon University School of Medicine, Tokyo, Japan

**Introduction:** The Denver peritoneovenous shunt is useful in the resolution of refractory ascites, because it alleviates symptoms and allows effective palliation. However, this shunt did not prolong the life expectancy of patients with decompensated liver cirrhosis. Therefore, when deciding whether or not to implant a Denver shunt, it is important to determine the condition of the patient with refractory ascites. Here, we determined the appropriate time for Denver shunt implantation.

**Material and Methods:** We retrospectively studied 21 patients who underwent Denver shunt implantation for hepatic failure-related ascites. The patients were divided into 2 groups: the PC group in which paracentesis was performed before implantation of the Denver shunt and the WPC group in which paracentesis was not performed before shunt implantation.

**Results:** The mean interval from hospital admission to Denver shunt implantation was significantly shorter in the WPC group ( $9.0 \pm 2.2$  days) than in the PC group ( $25.9 \pm 5.9$  days) ( $P 0.0001$ ). The mean survival time was significantly longer in the WPC group ( $8.4 \pm 2.5$  months) ( $P 0.0071$ ) than in the PC group ( $5.6 \pm 1.7$  months).

**Conclusions:** Early implantation of a Denver shunt should be considered for the treatment of ascites that is resistant to conservative medical therapy.

#### Outcomes

	PC group ( <i>n</i> = 10)	WPC group ( <i>n</i> = 11)	<i>P</i> value
Peritoneal centesis			
Once	5 (50%)	–	–
Twice	5 (50%)	–	–
Interval from admission to implantation of Denver shunt (day)	25.9	9.0	0.0001*
Operative time (min)	43.6	47.6	0.3183
Complication: Wound infection	1 (10%)	1 (9.1%)	1.00
Patency (month)	5.3	7.8	0.0103*
Survival (month)	5.6	8.4	0.0071*

#### Abstract ID: 1100

Specific Field: **Metabolism/  
Nutrition/Critical Care**

Mode of pres.: **Poster Discussion**  
ISW 2011 Session 100.08

#### Primary versus secondary anastomosis for superior mesenteric arterial occlusion

T. Oida [1], K. Mimatsu [1], H. Kano [1], A. Kawasaki [1],  
Y. Kuboi [1], N. Fukino [1], K. Kida [1], S. Amano [2]

[1] Social Insurance Yokohama Central Hospital, Yokohama, Japan,  
[2] Nihon University School of Medicine, Tokyo, Japan

**Introduction:** Superior mesenteric arterial occlusion (SMAO) often requires massive bowel resection. We compared primary anastomosis with open abdominal surgery and secondary anastomosis after enterostomy creation for the management of SMAO.

**Material and Methods:** We retrospectively studied 27 patients who underwent massive bowel resection for SMAO; the patients were divided into 2 groups depending on the operative procedure: primary anastomosis with open abdominal surgery (P group) and secondary anastomosis after enterostomy creation (S group).

**Results:** The mean duration from the initial operation to final operation (closure of open abdomen or closure of enterostomy) was significantly shorter in the P group ( $4.6 \pm 0.9$  days) than in the S group ( $26.8 \pm 9.4$  days) ( $P 0.0001$ ). No disease recurrence was observed in either group; however, 2 patients died of multiple organ failure in the S group.

**Conclusions:** Primary anastomosis with open abdominal surgery is useful for patients with low acute physiology and chronic health evaluation (APACHE) II scores, and secondary anastomosis should be performed in patients with high APACHE II scores. Further, it is important to perform timely enterostomy closure on the basis of precise examination of blood flow in the remnant bowel to avoid deterioration in the patients' quality of life.

#### Outcomes

	Primary group ( <i>n</i> = 12)	Secondary group ( <i>n</i> = 15)	<i>P</i> value
Remnant intestine (cm)	105	154	0.0001#
Complications			
Hypoproteinemia	12 (100%)	2 (13.3%)	0.0001#
Delirium	12 (100%)	4 (26.7%)	0.0002#
Wound infection	2 (16.7%)	1 (6.7%)	0.5692
Pneumonia	1 (8.3%)	1 (6.7%)	1.00
MOF	0 (0%)	2 (13.3%)	0.4872
Interval of initial ope. and final ope. (day)	4.6	26.8	0.0001#
Recurrence of the disease	0 (0%)	0 (0%)	1.00
Mortality	0 (0%)	2 (13.3%)	0.4872
Hospitalization (day)	23.4	40.3	0.0001#

**Abstract ID: 1101**Specific Field: **Metabolism/  
Nutrition/Critical Care****Mode of pres.: Poster Discussion  
ISW 2011 Session 100.09****Gene transfer of a box domain from high mobility group box 1  
in rat acute liver failure model**

M. Shinoda [1], M. Tanabe [1], A. Takayanagi [2], R. Nishiyama [1], G. Oshima [1], H. Yagi [1], I. Maruyama [3], Y. Kitagawa [1]

[1] Surgery, Keio University School of Medicine, Tokyo, Japan, [2] Molecular Biology, Keio University School of Medicine, Tokyo, Japan, [3] Kagoshima University, Kagoshima, Japan

**Introduction:** High-mobility group box 1 (HMGB1) is a monocyte derived late-acting inflammatory mediator. A domain of HMGB1, the A box, competes with HMGB1 for binding receptors and attenuates HMGB1-induced inflammation. In this study, we investigated if gene transfer of HMGB1 inhibitor, A box, is beneficial for the treatment of acute liver failure (ALF) in rat model.**Material and Methods:** We established an adenovirus vector encoding HMGB1 A box (Adex-Abox). (i) in vitro study. We transfected Adex-Abox to the Hela cells and the culture supernatant was subjected to western blot analysis for A box protein. The supernatant was also subjected to an in vitro test of TNF release inhibition from macrophage (RAW 264.7); macrophage was cultured with recombinant HMGB1 or both recombinant HMGB1 and the supernatant containing A box protein. (ii) in vivo study. We injected Adex-Abox or Adex-LacZ (control vector) into the portal vein of male Sprague-Dawley rats, weighing 250–350 g, and the liver was subjected to immunohistochemical staining for A box. Twenty four hours after Adex-Abox or Adex-LacZ injection ( $5 \times 10^8$  pfu/body,  $n = 5$  in each group), D-galactosamine was injected into the penile vein to induce ALF. Survival was observed for 7 days.**Results:** Western blot analysis showed a clear expression of A box protein in the culture supernatant of transfected Hela cells. The expression was the highest at 48 h after transfection. TNF release from macrophage was significantly suppressed in the culture of both HMGB1 and A box compared to that of HMGB1 only ( $401 \pm 22$  in A box(-) vs  $248 \pm 16$  in A box (+), pg/ml,  $P < 0.05$ ). Immunohistochemical staining showed that the liver injected with Adex-Abox was positive for A box. Survival was significantly improved in the rats transfected with Adex-A box compared to the rats transfected with Adex-LacZ (80% alive in Adex-Abox vs 0% alive in Adex-LacZ at 48 h after ALF induction,  $P < 0.05$ ).**Conclusions:** Gene transfer of HMGB1 inhibitor, A box, may be beneficial for the treatment of ALF in rat model.**Abstract ID: 1102**Specific Field: **Metabolism/  
Nutrition/Critical Care****Mode of pres.: Poster Discussion  
ISW 2011 Session 100.10****Thrombocytosis following splenectomy:  
with or without additional organ resection**

N. Fukino [1], T. Oida [1], K. Mimatsu [1], H. Kano [1], A. Kawasaki [1], Y. Kuboi [1], K. Kida [1], S. Amano [2]

[1] Social Insurance Yokohama Central Hospital, Yokohama, Japan, [2] Nihon University School of Medicine, Tokyo, Japan

**Introduction:** Splenectomy is one of the main causes of reactive thrombocytosis. In most cases, thrombocytosis found incidentally is harmless and resolves spontaneously; however, extreme thrombocytosis may result in thrombotic events such as acute myocardial infarction, mesenteric vein thrombosis, and pulmonary embolism. Thus, there are no clear indications for determining which patients with reactive thrombocytosis require treatment. In this study, we evaluated reactive thrombocytosis that developed after splenectomy with or without additional organ resection.**Material and Methods:** We retrospectively studied 70 patients who underwent splenectomy. These patients were divided into 2 groups: the only splenectomy group (group A) and the splenectomy with additional organ resection group (group B).**Results:** Both the platelet count at 1 week and 1 month after the operation ( $P < 0.01$  and  $P < 0.001$ , respectively) and the incidence rate of thrombocytosis at 1 week and 1 month ( $P < 0.4089$  and  $P < 0.0007$ , respectively) were significantly higher in the group A than in the group B. All the patients in both the groups recovered from thrombocytosis without any platelet reduction therapy, and there was no postoperative thrombosis.**Conclusions:** Splenectomy often results in reactive thrombocytosis; however, platelet reduction therapy is not required for treating post-splenectomy reactive thrombocytosis.

## The incident rate of thrombocytosis

	Group A ( $n = 24$ ) (%)	Group B ( $n = 46$ ) (%)	<i>P</i> value
1 week after operation	17 (70.8)	28 (60.9)	0.4089
1 month after operation	10 (41.7)	3 (6.5)	0.0007#
6 months after operation	0 (0)	0 (0)	1.00
1 year after operation	0 (0)	0 (0)	1.00

**Abstract ID: 1103**Specific Field: **Metabolism/  
Nutrition/Critical Care****Mode of pres.: Poster Discussion  
ISW 2011 Session 100.11****Effects of thrombomodulin  $\alpha$  in patients with disseminated  
intravascular coagulation (DIC) during the course of sepsis**

T. Ishibe, Y. Murao, T. Ueshima, K. Maruyama, T. Matsushima, T. Kimura, K. Yokoyama, I. Sakata

Kinki University Faculty of Medicine, Osakasayama, Osaka, Japan

**Introduction:** Thrombomodulin  $\alpha$  is a membrane protein that prevents disseminated intravascular coagulation (DIC). Thrombomodulin  $\alpha$  is a therapeutic drug for DIC which exhibits an antithrombin effect by binding to it, and inhibits excessive coagulation reactions by promoting protein C activation. We administered thrombomodulin  $\alpha$  to treat DIC in patients with sepsis, and compared it against conventional treatment.**Material and Methods:** Thrombomodulin  $\alpha$  was administered to 9 DIC patients between April 2009 and April 2010. DIC was diagnosed with standard guidelines set by the Japanese Association for Acute Medicine criteria (JAAM DIC criteria) and the outcome was

investigated. This was compared with the group ( $n = 24$  patients) who underwent conventional treatment (conventional group).

**Results:** JAAM DIC scores at the diagnosis of DIC were  $5.1 \pm 0.6$  and  $5.2 \pm 0.4$  in the groups of thrombomodulin  $\alpha$  and conventional treatment, respectively, showing no significant difference. However, after treatment the scores were  $2.5 \pm 0.5$  and  $5.0 \pm 0.4$ , respectively, showing a significant improvement in the thrombomodulin  $\alpha$  treatment group ( $P < 0.05$ ).

**Conclusions:** Although the number of patients was small, the results suggest that thrombomodulin  $\alpha$  was more effective than conventional treatment for DIC patients with sepsis.

**Abstract ID: 1104**

Specific Field: **Metabolism/  
Nutrition/Critical Care**

**Mode of pres.: Poster Discussion  
ISW 2011 Session 100.12**

#### **Management of immune system in surgical and critical care patients**

J. Kotani, A. Hashimoto, T. Yamada, C. Fuse, T. Inoue, K. Kohama, T. Ueda, I. Yamada

Hyogo College of Medicine, Nishinomiya, Japan

**Introduction:** In critically ill patients, the gut barrier is impaired followed by bacterial translocation (BT) by which intestinal microflora remote to systemic circulation and lymphoid duct leading to systemic infection and inflammation. Early initiation of enteral nutrition has been shown to prevent BT and reduces infectious complication rate, however, it does not seem to improve survival. Rather, EN is also important to control immune system as many immune-modulating nutrients such as arginine, n-3 polyunsaturated fatty acids (PUFAs) and antioxidants can be given to the patients via enteral route but not intravenously. It is also critical where to place a feeding tube and when to start EN. Because less than 20% of ICU patients can be given full dose of energy via enteral route, we have been investigating the effects of parenterally administered PUFAs on anti-inflammatory immune response such as apoptosis. Nutritional management in critically ill patients will be discussed.

**Abstract ID: 1105**

Specific Field: **Metabolism/  
Nutrition/Critical Care**

**Mode of pres.: Poster Discussion  
ISW 2011 Session 100.13**

#### **Utility of bed-side upper gastrointestinal endoscopy in surgical intensive care unit**

V.G. Shelat, A.D. Rao, B.C. Toh

Tan Tock Seng Hospital, Singapore

**Introduction:** To evaluate the role and outcomes of bedside endoscopy for upper gastro-intestinal haemorrhage in the intensive care setting.

**Material and Methods:** Retrospective study to evaluate thirty three bedside oesophago-gastro-duodenoscopy (OGD) cases was done. The parameters studied were age, sex, number of ulcers, reason for ICU admission, nutritional status, use of gastroprotective agents, blood

transfusion requirements, length of pre-endoscopy ICU stay, reason for bedside endoscopy, renal function, endoscopy findings, haemostasis methods, rebleeding, interventions, in-hospital mortality and death related to bleeding.

**Results:** Thirty three patients (M:F 19:14) were evaluated retrospectively. Peptic ulcer disease accounted for 21 patients (12 erosive gastritis, 9 gastric or duodenal ulcer), while variceal bleeding was noted in 10 patients. No obvious cause could be seen in two patients. All the patients were on proton pump inhibitor therapy upon admission. Nine patients were on parenteral nutrition and four patients were on hemodialysis. Haematemesis was the most common presenting complaint (54.5%). The commonest reason to do urgent OGD was gastrointestinal bleed requiring blood transfusion (63.6%). Three patients required OGD for hemodynamic instability. Eleven patients (33.3%) underwent OGD within one day of admission; including all the three unstable patients. Endotherapy was performed in 15 patients (45.5%). Rebleeding was noted in total eleven patients including seven patients with endotherapy (46.7%). Sixteen cases of in hospital mortality were noted of which the death was directly related to bleeding in three patients ( $P < 0.05$ ). Of the deaths directly due to bleeding, one patient had Forrest I type duodenal ulcer, one patient had grade II varices and a specific diagnosis could not be reached in one patient.

**Conclusions:** Urgent bedside endoscopy is a feasible treatment option in the intensive care setting. Primary haemostasis rate is high (97%). Overall rebleeding rate with or without endotherapy is high (33.3%) as is rebleeding after endotherapy (45.5%). Initial endoscopy can miss lesions. The overall mortality rate was 45.5% with a direct attributable rate of 18.7%. Bedside endoscopy in surgical intensive care unit is resource intensive and is a valuable tool for management of upper gastrointestinal bleeding patients.

**Abstract ID: 1106**

Specific Field: **Military Surgery**

**Mode of pres.: Free Paper  
ISW 2011 Session 151.01**

#### **The open abdomen 2011 in war and catastrophes: indication, strategies and modern temporary closure techniques**

H.P. Becker, A. Willms

Central Military Hospital, Koblenz, Germany

**Introduction:** In war and catastrophes, abdominal injuries occur in 10–15% of the cases. A greater part of them sustain life-threatening injuries requiring damage control procedures including the open abdomen. Over the last 15 years, the contemporary strategies to treat the open abdomen have increased the overall survival rate of the patients. Systematic intensive care and modern wound management in conjunction with a plastic barrier to protect the viscera and topical negative pressure on the soft tissues have reduced the development of lethal complications. The aim of the presentation is to give a systematic overview of the indications and the different technical solutions for the open abdominal treatment with respect to war and disaster situations. The literature selected and the results of our own cases show that the surgical handling of the exposed bowel, the choice of the material for temporary coverage and early progressive closure of the defect are crucial for the prevention of fistulas and further complications. At present, surgeons worldwide have adopted these principles leading to an increase of primary or delayed closure rates. This progress in surgical techniques has influenced the methods of war and catastrophe surgery as well.

**Abstract ID: 1107**      Specific Field: **Military Surgery****Mode of pres.: Free Paper**  
**ISW 2011 Session 151.02****Negative pressure topical wound therapy in complex war injuries: update 2011**

C. Willy Bundeswehr Hospital, Ulm, Germany

**Introduction:** The recent conflicts in Afghanistan and Iraq have demonstrated that body armor has led to increase survival of combatants but the extremity injuries have been alarming. The increased numbers of extremity injuries have led to the necessity for new technologies in managing complex war wounds. Unique characteristics of a war theater such as environmental contamination, varying evacuation procedures and differing levels of medical care, add to this complexity.

Wartime injuries are frequently high-energy wounds that devitalize and contaminate tissue, with high risk for infection and wound complications. In modern warfare wounds involve in many cases the musculoskeletal system and therefore military orthopaedic surgeons have assumed a pivotal role in the frontline treatment of these injuries. Providing battlefield orthopaedic care poses special challenges; not only are many wounds unlike those encountered in civilian practice:

- Most wartime injuries were due to high-energy blast or ballistic mechanisms. The majority of injuries were caused by exploding ordnance (frequently, improvised explosive devices, IEDs; blast: approximately 55 percent) and approx. 20 percent were from gunshot wounds.
- The extremities were the site of injury in 75 percent of patients, with lower extremity wounds outnumbering upper extremity wounds approximately 2:1.
- Most wartime injuries are devastating in the scope of soft-tissue and bony injury,
  - show devitalized and contaminated tissue,
  - and a high risk for infection and wound complications.
- They endure prolonged medical evacuation, often involving ground, helicopter, and fixed-wing transport across continents (18–72 h).

Treatment guidelines, or doctrine, are the result of lessons learned in conflicts over the past few centuries dating back to early nineteenth century Europe. The patients must be triaged and treated in an austere and dangerous environment. The medical treatment requires a team approach using hypotensive resuscitation, new or rediscovered techniques of hemostatic and intravenous hemorrhage control, first-line surgical treatment of bone and soft tissue. Fundamental principles for the management of these injuries are aggressive surgical debridement, irrigation, antibiotic protocol, internal fixation of the fracture and no closure by primary intention and no occlusive dressings. The goals of orthopedic injury management are to prevent infection, promote fracture healing, and restore function. In the civilian setting, for over the past decade, more than one million civilian patients have been treated for chronic and abdominal wounds, diabetic ulcers as well as acute civilian trauma wounds with negative pressure wound therapy with reticulated open cell foam.

In warfare situations recent experiences in field hospitals, rescue centers and particularly from long-distance evacuations show that as the census increased to more and more patients, it became necessary to develop alternate forms of wound management. Sometimes, due to massive secretion, dressing changes were necessary twice daily. Therefore, starting 2003 negative pressure wound therapy (NPWT) dressings were instituted to treat the complex war injury. However, the use of NPWT for the care of complex war wounds at battlefield trauma hospitals and/or in the aeromedical evacuation transport system aboard aircraft is still a new application of this wound treatment not yet accepted as doctrine. Thus, an overview of the types of

injuries emerging from the current conflicts in Iraq and Afghanistan, the importance of NPWT in the treatment of war wounds and the potential of prevention of infection will be presented.

**Material and Methods:** Own experiences of deployment activities between 2002–2010 (ISAF, Afghanistan) and Medline search. Keywords (negative pressure wound therapy”, VAC”, vacuum assisted wound therapy”, soldier”, war”, combat”, casualty”).

**Results:** 31 papers dealing with NPWT were published between 2002 and 2010. In most of the cases the papers have an Evidence-based Medicine level of IV and V. In Afghanistan, since end of 2001 1896 soldiers were killed in action or died of wounds and 6623 were wounded (as of July 8th 2010). VAC therapy is a part of standard treatment in every medical facility in regional commands North and East. The experience with complex war wounds suggests that conventional wound management doctrine may be improved with the wound VAC, resulting in earlier more reliable primary closure of wartime injuries. Patients required an average of 4 to 9 irrigation and debridement procedures and concurrent VAC dressings operations from the initial injury to definitive wound closure or prior to placement of Integra/split-thickness skin grafting. Use of NPWT during aeromedical evacuation appears safe, hygienic and feasible in a large cohort of patients with high-energy injuries. In no case was failure of the NPWT device in flight specifically implicated in the genesis of a recorded complication.

From the civilian side an additional help in the treatment of severe wounds, particularly to prevent wound infection, is given due to the possibilities created by the instillation therapy. Particularly in devastating soft tissue injuries continuous instillation therapy showed a deep impact. Authors showed in a prospective randomized study that there was a significant difference between the two groups for total infections (moist wound treatment and NPWT). The relative risk for an infection in the NPWT group was significant lower, suggesting that patients with severe open fractures treated with NPWT were only one-fifth as likely to have an infection compared with patients randomized to the control group.

**Conclusions:**

- New therapeutic approaches in war surgery are the use of methyl methacrylate antibiotic beads, new prosthetic technologies and the NPWT.
- NPWT represents a promising new therapy for complex war wounds after high-energy blast trauma being more and more incorporated in a strict wound management strategy.
- There exists some evidence, that NPWT reduces markedly the infection rate of severe open wounds. Particularly, the instillation therapy allows a benefit in prevention of infection.
- The lessons learned in Afghanistan suggest that conventional wound management doctrine may be improved with the NPWT, resulting in earlier more reliable primary closure of wartime injuries and reduced infection rate. NPWT allows the hygienic occlusion of aggressively debrided wartime injuries.
- Advantages in the treatment of complex war wounds are not important only for moderne warfare. The terrorist attacks in New York, Madrid and London show, that the civilian trauma surgeon can be involved in the treatment of war” wounds too.

**Abstract ID: 1108**      Specific Field: **Military Surgery****Mode of pres.: Free Paper**  
**ISW 2011 Session 151.03****Surgical tactics for gunshot penetrating thoracic wounds in military and peace time**

P.G. Brusov

Main Military Hospital, Moscow, Russian Federation



**Introduction:** Gunshot penetrating thoracic wounds (GPTW) remain the most serious type of a combat trauma. In severe injuries the choice of optimal surgical tactics presents certain difficulties. Therefore, the indications for urgent thoracotomy are quite often overestimated, while the number unnecessary thoracotomies in chest injuries range from 15 to 56%.

**Material and Methods:** Results of treatment of 277 wounded were analyzed. The first group consisted from 167 casualties with combat thoracic trauma (82—with GPTW). They were taken in the leading hospital in 2–6 h ( $4.1 \pm 0.3$ ) after the injury.

In a peace time 110 wounded with GPTW were taken to the hospital in 20–90 min ( $34.8 \pm 12.7$ ) after wounding.

**Results:** In the first group the 58 wounded (70.7%) underwent a tube thoracostomy, 2—thoracotomy, 22 (13.2%)—operative videothoracoscopy (OVTS). The frequency of conversion was 9.1%, while the overall frequency of thoracotomies—6.9%. Mortality rate—2.4%. In the 2 group the 51 (46.4%) patients underwent a tube thoracostomy, 10 (9.1%)—thoracotomy, 59 (53.6%)—OVTS, 8 (13.6%)—emergency laparotomy. Conversion to thoracotomy was required in 20 (33.9%) patients. The reasons for conversion were wounds of heart (2), vena cava superior (2), trachea (1), the main bronchi (6), the first zone of a lung (5), as well as massive destruction of lung (4). The overall incidence of thoracotomies was 27.3%, mortality rate—10%.

**Conclusions:** Noted distinctions in two groups due to the lack of cardiac injuries in arriving at hospital with Battle thoracic trauma. Probably, these wounded were among killed in the battlefield, that because of GPTW amounted to 33.6%. In peace time possibility of fast delivery of the wounded to hospital and rendering the urgent surgical care within 20–30 min after injury explains the increase the frequency of wounds of heart and mediastinal organs. All this explains the high frequency of thoracotomy and conversion into it. The use of OVTS allowed to revise the existing traditional approaches for gunshot penetrating chest injuries and to minimize the number thoracotomies. OVTS at non cardiac trauma is an alternative to thoracotomy.

**Abstract ID: 1109**      Specific Field: **Military Surgery**

**Mode of pres.: Free Paper**  
**ISW 2011 Session 151.04**

**Repairing injuries at the origin of the profunda femoris artery with a graft from the cephalic vein: a novel approach**

K.M. Kosala Somaratne [1],  
H.M. Thilanka Wasumathi Seneviratne [2], K.J. Senanayake [3]

[1] Teaching Hospital Peradeniya, Peradeniya, Sri Lanka, [2] Base Hospital Gampola, Gampola, Sri Lanka, [3] university of Rajarata, Mihintale, Sri Lanka

**Introduction:** During the last stages of humanitarian operations of Sri Lanka Armed forces against the terrorists of the LTTE, the incidence of vascular injuries among military casualties was quite high. This was presumably due to the intense close quarter fighting that took place. We intend to present the results of 05 cases of vascular injuries at the origin of Profunda Femoris Artery (PFA) repaired in a novel method hitherto non described in literature.

**Material and Methods:** In the traditional method the PFA and SFA had to be repaired separately with grafts which in turn are to be joined with an end to side anastomosis. Instead of this we used a graft from Cephalic vein (CV) at the Cubital fossa where it gives off the sizable branch called vena mediana cubiti (VMC). Part of the Cephalic vein with this branch and part of the Basilic vein (BV) with which the VMC joins was harvested. The CV was reversed and anastomosed

with the SFA and the VMC with the Basilic vein was anastomosed to the PFA.

**Results:** All 05 anastomoses gave successful results with palpable distal pulses.

**Conclusions:** With the method we describe an injury at the origin of PFA can be repaired with 03 anastomoses which saves the time of a difficult end to side anastomosis. This method was quite useful in war surgery where time factor plays a huge role.

**Abstract ID: 1110**      Specific Field: **Military Surgery**

**Mode of pres.: Free Paper**  
**ISW 2011 Session 151.05**

**Blast injury of the hand and upper limb: classification and management in role 2**

M. Levadoux

Teaching Naval Hospital Ste Anne, Toulon, France

**Introduction:** The modern conflicts have demonstrated the increasing role of high velocity and energy devices. Because of the passive individual protection realized by the body armor the most important lesions are located on the upper and lower limbs. The hand and the upper limb are often injured and the blast injury takes an important place in the pathogenic analyze. The authors describe the necessity to identify, classify and treat the blast injury of the hand and the upper limb.

**Material and Methods:** The authors analyze the blast injuries that they had managed on the upper limb in role II in Chad, Ivory Cost and Afghanistan. After a short presentation of the clinical aspects of the lesions, they insist on the importance of the classification and especially on Allieu Classification. The cases are presented and analyzed. **Results:** A decisional Algorithm is proposed in case of blast injury of the hand.

**Conclusions:** The upper limb is frequently injured. Hand also can be severely damaged. Modern warfare provoke often Blast injuries. Management of the blast injury of the hand necessitates to know the Allieu Classification in order to decide at best how to manage each case.

**Abstract ID: 1111**      Specific Field: **Military Surgery**

**Mode of pres.: Free Paper**  
**ISW 2011 Session 151.06**

**Training the military surgeons: French experience**

F. Pons

Department of Thoracic and Visceral Surgery, Military Hospital Percy, Clamart, France

**Introduction:** In an era of increasing surgical sub-specialization the deployed military surgeon needs to acquire and maintain a wide range of skills including a variety of surgical fields. The current education of the French Civilian surgeons does not allow them to be really trained in general Trauma and Emergency Surgery (General Surgery as a specialty is due to disappear; Trauma or Emergency surgery is not a recognized specialty; in most of civilian Hospitals Trauma patients are managed by several surgical specialists)

**Material and Methods:** French military surgeons teams always involve at least two surgeons: one orthopaedic surgeon and one visceral surgeon. To deploy a surgeon from various specialty (vascular,

urologist, neurosurgeon) is not possible in each military theatre. Therefore the deployed surgeon must be trained in general Trauma surgery.

**Results:** A medical curriculum has been created to try to educate them for Trauma Surgery in a variety of surgical fields. This course (Cachirmex: “Cours Avancé de Chirurgie en Mission Extérieure” or Advanced Course for Deployment Surgery) includes five sessions of 3-days modules (in two years), delivering about 110 h. Each Module involves: “Lessons learned” from experienced surgeons coming back from different theatres; lectures and hands on skill stations either on cadavers either on animal models. Every Trauma surgery (Head, Neck, Chest, Abdomen, Vascular, Extremities) is taught. In addition humanitarian care for civilian people and ethics are also part of the program.

### Abstract ID: 1112      Specific Field: Military Surgery

**Mode of pres.: Free Paper**  
**ISW 2011 Session 151.07**

#### Training the military surgeons: German experience

C. Willy

Bundeswehr Hospital, Ulm, Germany

**Introduction:** The German Bundeswehr Joint Medical Service need to adapt to the challenges represented by the act instituted in 2004 for the purpose of reforming the German health system (Gesundheitsmodernisierungsgesetz). There are necessarily consequences as the result with regard to the qualifications and training that future military surgeons will require. A concept is outlined in this part of the article that, when implemented, will ensure that surgical personnel trained in accordance with the needs of the current civilian qualification requirements will be available for service abroad, while the new generation of surgeons will be adequately prepared to adapt to the changing health market and have the skills necessary to conform to civilian medical requirements long term.

**Material and Methods:** In an era of increasing surgical sub-specialization the deployed military surgeon needs to acquire and maintain a wide range of skills including a variety of surgical fields. In order to create this kind of military surgeon the so-called “DUO plus” model for the training of military surgeons (specialization general surgery plus a second sub-specialization either in visceral surgery or orthopedics/trauma surgery) has been developed in the Joint Medical Service of the German Bundeswehr. Other relevant skills, such as emergency neurotraumatology, battlefield surgery with integrated oral and craniomaxillofacial surgery, and emergency gynecology are also integrated into this concept and will be addressed in special courses.

**Results:** Log books have to be kept in accordance with the training curricula to register the progress of training. Teaching personnel will document the completion of each training phase by medical officers. On successful completion of the programme, medical officers will be officially appointed as Medical Officer “Einsatzchirurg” by their commanding officers. This appointment will be for a maximum of five years and it will be necessary to renew it after this period.

**Conclusions:** On successful completion of this training program military surgeons will be officially appointed as “Einsatzchirurg” for a duration of 5 years. After this time it will be obligatory to renew this combat ready” status. The refresher programs will require participation in visiting physician programs in the complementary surgical disciplines in order to retain the essential specific skills.

### Abstract ID: 1113      Specific Field: Military Surgery

**Mode of pres.: Free Paper**  
**ISW 2011 Session 151.08**

#### Training US military surgeons using simulation: present and future

M. Bowyer

The Norman M. Rich Department of Surgery, Uniformed Services University, Bethesda, Maryland, USA

**Introduction:** The modern combat surgeon is confronted with complex wounds and wounding patterns unlike any seen in civilian trauma care and the vast majority of newly deploying military surgeons are not current or proficient in the management of polytraumatized patients with blast or other war injuries. Pre-deployment training must teach the principles of managing combat casualties with an emphasis on difficult vascular exposures and the concepts of damage control surgery to include craniectomy by non-neurosurgeons, laparotomy, thoracotomy, and management of extremity injuries. Traditional training utilizes live porcine and human cadaver models to teach with the limitations inherent to each. Though animals are good for teaching the management of bleeding tissue they are not faithful representations of important human anatomy, and there is huge pressure to find suitable alternatives. Cadavers are much better for human anatomy, but they are often poorly represent the tissue of young healthy soldiers, and are expensive and availability is variable. There is a real need for realistic models of human tissue that represent realistic combat wounds and allow standardized and evaluable training using actual surgical instruments. The technology to create these models exists and we have been developing models that can be used for training military surgeons. The current status of these training modalities and the anticipated future development and application will be presented.

### Abstract ID: 1114      Specific Field: Burns

**Mode of pres.: Free Paper**  
**ISW 2011 Session 69.01**

#### A rationale for significant cost savings in patients suffering home oxygen burns: despite many comorbid conditions, only modest care is necessary

G.A. Vercruyse, W.L. Ingram, D.V. Feliciano

Emory University Department of Surgery, Atlanta, USA

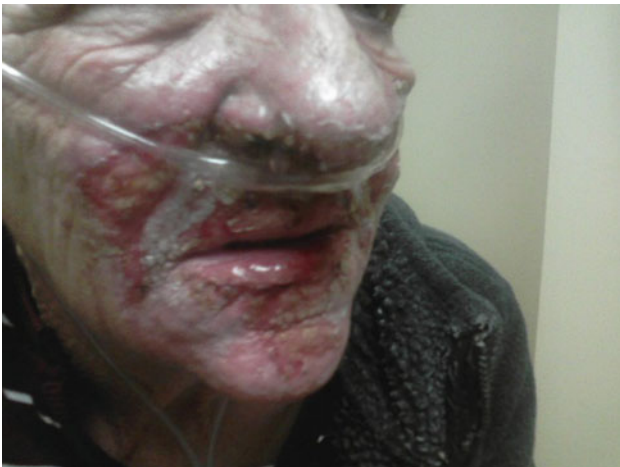**Introduction:** 1.25% of all patients admitted to our facility are evaluated for burns related to home oxygen use. While the vast majority of these burns are minor, referral to a burn unit regardless of depth or size is still very common. Care of this population was reviewed to determine the feasibility and potential economic saving if such patients could be managed by physicians trained acute care or general surgery.

**Material and Methods:** Prospectively collected data on 5103 consecutive patients admitted to an urban tertiary burn center was reviewed. Data collected included age, Total Body Surface Area (%TBSA) burned, comorbidities, mode of admission, distance transported, mode of transport, number requiring surgery, length of stay (LOS) and outcome.

**Results:** Of 5103 admissions, 1.25% (64) were for home Oxygen burns. Patients had a mean age of 62.5 years (range 34–84 years) and

5 comorbidities (range 1–8). They suffered a mean 4% TBSA burn (range 1–9%) and, in all but one, (early fatality) the burns were mostly superficial, partial thickness and healed without surgery. (Two required minor peri-oral contracture releases months later, and one suffered corneal abrasions treated with ophthalmic antibiotics). Patients had a mean LOS of 2 days and required 1 clinic visit. 27% were transferred from another facility after initial care and, of those 28% arrived intubated. 22% were transported by helicopter, and of those 61% arrived intubated. 80% of ventilated patients were extubated within 8 h and all within 24 h. Average helicopter transport was 57 miles, and cost \$12,500.

**Conclusions:** Those suffering home Oxygen burns have multiple comorbid conditions, yet do very well. Surgery is not required, but rather local wound debridement, pain control, assessment, and dressing changes. Transfers are due to a lack of basic skills in assessment and care of burn wounds. Those transported by helicopter or transferred from another facility are more likely to be intubated unnecessarily, have delays in receiving care with multiple workups, and incur significant transfer and care costs. Large savings could be realized if these patients were cared for by local doctors trained in basic burn care supplemented with burn center consultation on an as needed basis.



**Figure:** Typical home oxygen burn

**Abstract ID: 1115**      Specific Field: **Abstract ID: 1115**

**Mode of pres.: Free Paper**  
**ISW 2011 Session 69.02**

#### **Organizing burn patient hospitalisation and transfer at a developing country**

A.C. Yasti, O. Koc, I. Sencan

Ankara Numune Education and Research Hospital, Ankara, Turkey

**Introduction:** In developing countries, burns are frequent however treatment facilities are limited. The organization algorithm applied in Turkey, initiated by a comity under supervision of the ministry of health, will be discussed.

**Material and Methods:** All burn admittances to emergency departments and hospitalizations were gathered in Turkey for Jan 2007 to Dec 2008. Data were mapped to see the distribution country-wide. As burns are not among the notifiable diseases, it is impossible to have

exact number. Estimations were made using coefficients regarding previous population based studies.

Burn management is an expensive treatment modality. It needs sophisticated physical construction and experienced staff and multi-disciplinary approach. It is not feasible to construct sophisticated burn centers all over the country. Therefore, in Turkey, burn treatment facilities are divided into three categories: burns room, burns unit, and burns treatment center. Burns rooms are planned to accept at least two victims with minor and moderate burns that could be managed with the index hospital's facilities where a general, plastic or pediatric surgeon exist. Burn units are planned to manage moderate burns by at least eight beds and a trained burn team. Burns treatment centers are organized to have at least four ICU beds to accept major burns. The team members of the units and centers are general or plastic or pediatric surgeon and nurses all of whom a post graduate training program is applied.

Having approximate patient numbers let incidence projections to proceed. Than taking into the consideration of patient transfer times, burns treatment facilities are planned all over Turkey.

**Results:** With monthly fashion, demographic data are gathered by the ministry of health for burn patients for the year 2010. The patient transfer algorithm is settled and facilities are serving health services to patients with appropriate burn severity. With this program, unnecessary patient transfers are avoided and also workload of the centers and units are diminished.

**Conclusions:** Every country has its own burn incidences regarding cultural, social and economic factors. A unique country-wide health care program can not be applied at burn management worldwide. A sort of algorithm like Turkey's should be applied in developing countries where burn incidence is high and facilities are limited.

**Abstract ID: 1116**

Specific Field: **Burns**

**Mode of pres.: Free Paper**  
**ISW 2011 Session 69.03**

#### **Evaluation of an ultra-thin poly-L-lactic acid nanosheet as a new dressing in the management of partial thickness burn wounds**

H. Miyazaki [1], M. Kinoshita [2], F. Toshinori [3], A. Saito [3], Y. Okamura [2], S. Ono [1], S. Takeoka [3], D. Saitoh [1]

[1] Division of Traumatology, Research Institute, National Defense Medical College, Tokorozawa, Japan, [2] Department of Immunology and Microbiology, National Defense Medical College, Tokorozawa, Japan, [3] Department of Life Science and Medical Bioscience Faculty of Science and Engineering, Waseda University, Tokyo, Japan

**Introduction:** Burn wounds are highly susceptible to bacterial infection due to the impairment of skin integrity and reduction in cell mediated immunity. Therefore, in the management of burn wounds, prevention of bacterial colonized/infected wounds are critical during wound healing. Although, many commercially available dressings are currently used in the burn wounds, management of the burn wound still remains a matter of debate. For biomedical applications, we recently developed a free-standing biocompatible polysaccharide nanosheet (thickness;  $60 \pm 6$  nm) such as poly-L-lactic acid (PLLA), with sufficient flexibility, transparency, adhesiveness and robustness in the manner of wound dressing. PLLA nanosheets have many useful and advantageous biological properties for its application as a wound dressing. The objective of this study was to investigate the suitability of the PLLA nanosheets as a wound dressing for partial-thickness burn wounds in vivo.

**Material and Methods:** The mice dorsal skin was immersed in 70°C water for 4 s to achieve a partial-thickness scald burn. Burn wound was covered with PLLA nanosheet or not covered as a negative control, and then were inoculated with *Pseudomonas aeruginosa* ( $1 \times 10^8$  CFU/wound area) 1 day after injury. Wounds without infection were used as controls. Wound healing was observed up to 7 days after infection. Burn wounds were traced and areas of healing were calculated by image analysis.

**Results:** Infection induced by inoculation of *Pseudomonas aeruginosa* caused significant delay in re-epithelization of burn wounds compared to controls. However, dressing with PLLA nanosheet prevented bacterial infection and promoted the normal wound healing process in partial-thickness burn wounds. It showed that PLLA nanosheets represented excellent barrier ability for protection against burn wound infections.

**Conclusions:** These findings indicate that ultra-thin PLLA nanosheets could be beneficial applications in vivo as a wound dressing for prevention of post-burn infection.

**Abstract ID: 1117**

Specific Field: **Burns**

**Mode of pres.: Free Paper**  
**ISW 2011 Session 69.04**

**A randomized controlled trial comparing autologous platelet rich plasma (PRP) versus standard burn wound treatment**

M. Vehmeijer [1], R. Breederveld [2], R. Marck [2],  
W. Tuinebreijer [2]

[1] VUMC, Amsterdam, Netherlands, [2] Rode Kruis Ziekenhuis,  
Beverwijk, Netherlands

**Introduction:** Platelet rich plasma which consists of different growth factors may play a role in wound healing, maturation and scar formation of transplanted burn wounds. Application of autologous platelet rich plasma has been reported to increase wound healing. However, in burn wound surgery no randomized controlled trial has been performed. The primary objective is to examine the effect of PRP on the time in days to complete healing of paired grafted burn wound sites.

**Material and Methods:** Double blind intervention study. Patients aged 18 years and older admitted at the Burn Center of the Red Cross Hospital Beverwijk are included. Two equal wound areas of at least 1% of every patient are treated, one wound area is treated with PRP and one other wound area is treated with only standard treatment.

**Results:** The main study endpoint is the effect of PRP on the times in days to complete healing of the paired grafted burn wound sites. Secondary objectives are infection rate of transplanted burn wounds, the effect of PRP on pain and the scar assessment after one year.

**Conclusions:** The first patients have been included from may 2010 onwards and preliminary results will be discussed. An increase in wound healing might be expected and therefore leading to better end results.

**Abstract ID: 1118**

Specific Field: **Burns**

**Mode of pres.: Poster Discussion**  
**ISW 2011 Session 69.05**

**Efficacy of ozonized olive oil in the treatment of infected burn wounds**

A.C. Yasti, A.A. Kabalak, O. Koc

Ankara Numune Education and Research Hospital, Ankara, Turkey

**Introduction:** The mechanism of the ozonized oil at the tissue repair has not yet been clarified enough. The disinfection effect of ozonized olive oil has already been reported. Ozone has been recognized to have stimulating effects on leukocytes, and induction of many cytokines was clearly confirmed. It is well known that ozonized oil increases the formation of granulation tissue and epidermal epithelium. Therefore, ozonized oil treatment modalities are applied in the treatment of burns, superficial infections, decubitus ulcers and abscesses. We aimed to determine the efficacy of ozonized oil in the treatment of infected burn wounds.

**Material and Methods:** A total of twelve burn patients with deep 2nd degree infected burn wounds referred to our clinic at the late course of treatment were studied. Inclusion criteria include to have wound in both extremities to have homogenization of the group. Four patients were female and the mean age of group was 48 (23–71) years of age. All patients were undergone to debridement of necrotic tissues and escharectomy. For each patient hospitalized randomization was done as using ozonized oil in one extremity and conventional wound care to the other. The usual treatment methods were compared with ozonized oil in terms of wound healing process and infection.

**Results:** Ozonized oil treated wounds had less infection and faster wound healing ( $P < 0.05$ ). Nevertheless, grafting necessitated in four patients. Postoperative treatments of graft and donor sites were continued with ozonized oil. The healing time for the STSG donor sites were also shorter and better in ozonized oil group ( $P < 0.05$ ).

**Conclusions:** Infection is an ongoing problem in burn wounds. To our study, application of ozonized oil treatment decreases the infection, increases granulation tissue formation and makes a smooth epithelialization at the burn wound. Regarding our study, we propose using ozonized oil in the treatment of infected burn wounds however confirmation with large number series is needed.

**Abstract ID: 1119**

Specific Field: **Burns**

**Mode of pres.: Poster Discussion**  
**ISW 2011 Session 69.06**

**The effects to clinical process of noninvasive positive pressure ventilation inhalation injury**

A.A. Kabalak, A.C. Yasti

Ankara Numune Education and Research Hospital, Ankara, Turkey

**Introduction:** Pulmonary dysfunction is a common complication of the burn-injured patient and the aetiology is multi-faced. Respiratory complications may result from smoke inhalation, direct airway burn from superheated smoke particles, the effect of the systemic inflammatory response to a burn or a combination of these factors. Endotracheal intubation and positive pressure ventilation are commonly used to prevent or treat hypoxia to secure a patent airway. However, the presence of the endotracheal tube introduces problems bypassing the protective mechanisms of the upper airway. Mechanical ventilation increases the incidence of nosocomial pneumonia. Non-invasive Positive Pressure Ventilation (NIPPV) augment alveolar ventilation without an endotracheal airway. The purpose of this study is to report on our initial experience with NIPPV in a series of burn-injured patient.

**Material and Methods:** The medical records of all patients treated with NIPPV as part of their burns management at the Ankara Numune Hospital, Burn Treatment Center between March 2009 and January 2011 were reviewed. NIPPV was not applied the patients with acute upper airway obstruction because of laryngeal edema, hemodynamic



instability and unconscious. We report our experience with NIPPV in 26 burn patients with acute and chronic respiratory failure.

The mean PaO<sub>2</sub>/FiO<sub>2</sub> ratio prior to institution of NIPPV was 26.78 KPa (range 8.75–52). Ventilator settings to be performed within the normal range of blood gas parameters (PaO<sub>2</sub>% 55–80 mmHg, SpO<sub>2</sub>% 85–90, PaCO<sub>2</sub> 70, pH 7.30).

**Results:** Mean age was 46.72 years (range 21–76). Four patients were female. Mean burn size was 35.6% total body surface area (range 18–54). A positive diagnosis of pneumonia was made in 22 patients.

**Conclusions:** NIPPV is a safe and effective means to improve gas exchanges in selected patients with acute burn-injury and concomitant acute/chronic respiratory failure. NIPPV appears to be effective in supporting respiratory function such that endotracheal intubation can be avoided in most cases.

**Abstract ID: 1120** Specific Field: **Paediatric Surgery**

**Mode of pres.: Free Paper**  
**ISW 2011 Session 61.01**

**Prenatal administration of retinoic acid induces upregulation of pulmonary rho-associated kinase gene expression in the nitrofen model of pulmonary hypoplasia**

T. Doi, P. Comfort, J. Gosemann, P. Puri

National Children's Research Centre, Our Lady's Children's Hospital, Dublin, Ireland

**Introduction:** Nitrofen-induced congenital diaphragmatic hernia (CDH) model demonstrates pulmonary hypoplasia (PH) with impaired differentiation of the alveolar epithelial cells (AECs), similar to human condition of CDH. Retinoic acid (RA) improves PH by stimulating alveogenesis. However, precise mechanisms by which RA acts remain unclear. Rho-associated kinase (ROCK) is essential for lung morphogenesis. ROCK inhibitor interferes with alveogenesis, inhibiting AECs differentiation. We hypothesized that ROCK gene is downregulated during alveogenesis in the nitrofen-induced PH, and to evaluate the effect of prenatal RA treatment on pulmonary ROCK gene expression in this model.

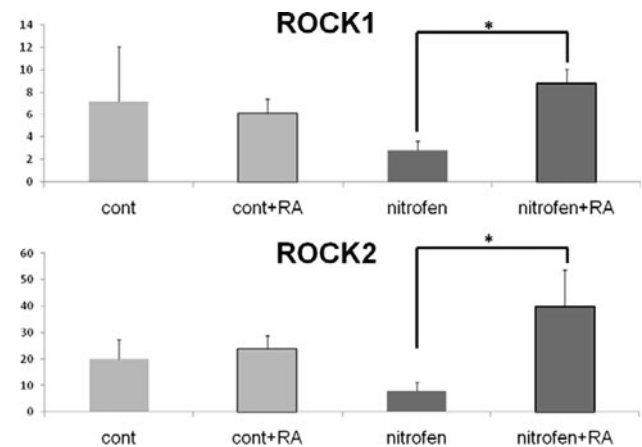
**Material and Methods:** Pregnant rats were exposed to olive oil or nitrofen on day 9 of gestation (D9). Fetal lungs were harvested on D15, D18 and D21 and divided into control, nitrofen with or without CDH (CDH(+) or CDH(-)). In addition, RA was given from D18, D19 and D20, and fetal lungs were harvested and divided into control + RA and nitrofen + RA on D21. ROCK1/2 gene expression was evaluated by RT-PCR and statistically analyzed. Immunohistochemistry was performed to examine protein expression/distribution of ROCKs.

**Results:** The gene expression levels of ROCK1/2 were significantly downregulated in nitrofen groups compared to controls at D21 ( $P < 0.05$ / $P < 0.01$ ), whereas there were no significant differences at D15 and D18 (Table). Prenatal treatment with RA upregulates ROCK1/2 gene expression levels significantly in nitrofen + RA ( $8.81 \pm 1.27/39.96 \pm 13.64$ ) compared to nitrofen ( $2.79 \pm 0.83/8.09 \pm 3.22$ ) ( $*P < 0.05$ ) (Figure). Immunoreactivity of ROCKs was diminished in nitrofen lungs compared to controls, and markedly increased after prenatal RA administration.

**Conclusions:** Downregulation of ROCK genes on D21 (alveolar stages) may impair alveogenesis causing PH. Upregulation of pulmonary ROCK gene expression after prenatal treatment with RA may stimulate ROCK mediated AECs differentiation resulting in lung maturation.

Relative mRNA levels of pulmonary ROCK1/2

	ROCK1 (D15)	ROCK2 (D15)	ROCK1 (D18)	ROCK2 (D18)	ROCK1 (D21)	ROCK2 (D21)
Control	3.12	9.01	4.20	15.58	7.23	20.05
CDH (-)	3.62	9.43	5.31	14.86	2.63	7.15
CDH(+)			4.81	17.74	2.96	9.59



**Figure:** Effect of RA on ROCK1/2 (D21)

**Abstract ID: 1121** Specific Field: **Paediatric Surgery**

**Mode of pres.: Free Paper**  
**ISW 2011 Session 61.02**

**Effect of insulin-like growth factors on lung development in connexin 43 knockout mice**

Y. Oka [1], K. Masumoto [1], M. Nakamura [1], A. Iwasaki [1], G. Esumi [2], T. Taguchi [2], H. Yamaza [3], K. Nonaka [3]

[1] Department of Thoracic, Endocrine, and Pediatric Surgery, Faculty of Medicine, Fukuoka University, Fukuoka, Japan, [2] Department of Pediatric Surgery, Reproductive and Developmental Medicine, Graduate School Medical Sciences, Kyushu University, Fukuoka, Japan, [3] Department of Pediatric Dentistry, Division of Oral Health, Growth and Development, Kyushu University, Fukuoka, Japan

**Introduction:** Congenital diaphragmatic hernia (CDH) is often associated with hypoplastic lungs. The prognosis of severe CDH patients is poor due to the associated severe hypoplastic lungs. Therefore, prenatal treatment for hypoplastic lungs is required for improving the survival in CDH patients. We have examined the insulin-like-growth factors (IGFs), which are known to accelerate the maturation of the fetal lungs. We also found that connexin43 (Cx43) knockout mice have severe hypoplastic lungs, therefore demonstrating that Cx43 knockout mice are a suitable for an animal model of hypoplastic lungs. The aim of the present study was to investigate whether IGFs can improve fetal hypoplastic lungs in Cx43 knockout mice.

**Material and Methods:** Male and female heterozygous Cx43 mice (Cx43<sup>+/-</sup>) were mated overnight and the day that the vaginal plug

was confirmed was designated as embryonic day 0. Fetuses were obtained by cesarean section on the embryonic day 17, and the fetal lungs were dissected out and divided into the following three groups: IGF-1, IGF-2, and Control. These fetal lungs were incubated for 48 or 72 h in three types of mediums supplemented with IGF-1, IGF-2, or in the absence of IGFs. The lungs from homozygous Cx43 fetuses (Cx43<sup>-/-</sup>) were investigated by immunohistochemistry and for the mRNA expression of T1 alpha protein (T1 $\alpha$ ), surfactant protein-C (Sp-C), and alpha smooth muscle actin ( $\alpha$ -SMA).

**Results:** Both the number of positive cells and the mRNA expression of T1 $\alpha$ , Sp-C, and  $\alpha$ SMA were observed to increase in the IGF-1 and IGF-2 groups compared to control group, but there were no significant differences between the IGF-1 group and the IGF-2 groups.

**Conclusions:** The present results suggest that IGFs might induce the maturation of severe fetal hypoplastic lungs in Cx43 knockout mice. Therefore, the administration of IGFs to the fetus during the late gestational period may be effective for improving the development of severe hypoplastic lungs in CDH.

**Abstract ID: 1122** Specific Field: **Paediatric Surgery**

**Mode of pres.: Free Paper**  
**ISW 2011 Session 61.03**

**Prenatal risk stratification for isolated congenital diaphragmatic hernia**

N. Usui [1], Y. Kitano [2], H. Okuyama [3], K. Masumoto [4], M. Kawataki [5], K. Nose [6], M. Saito [2], H. Sago [2]

[1] Osaka University Graduate School of Medicine, Osaka, Japan, [2] National Center for Child Health and Development, Tokyo, Japan, [3] Hyogo College of Medicine, Hyogo, Japan, [4] Kyushu University, Fukuoka, Japan, [5] Kanagawa Children's Medical Center, Yokohama, Japan, [6] Osaka Medical Center and Research Institute for Maternal and Child Health, Osaka, Japan

**Introduction:** The aim of this study was to establish a prenatal prognostic classification system for risk-stratified management in fetuses with isolated congenital diaphragmatic hernia (CDH) based on prenatal ultrasonographic findings.

**Material and Methods:** A multi-institutional retrospective cohort study of isolated CDH, diagnosed prenatally in fetuses delivered during the 2002–2007 period at 5 participating institutions in Japan, was conducted. Our prenatal prognostic classification was formulated based on the odds ratios of prenatal parameters for 90-day survival. Duration of respiratory management, need for circulatory support, operative findings, morbidity, and mortality were compared among risk groups based on liver position and the contralateral lung to thorax transverse area ratio (L/T ratio).

**Results:** Patients were classified into the 3 risk groups: A ( $n = 48$ ) consisted of infants showing liver-down with L/T ratio 0.08, B of infants showing liver-down with L/T ratio  $<0.08$  or liver-up with L/T ratio 0.08 ( $n = 35$ ), and C of infants showing liver-up with L/T ratio  $<0.08$  ( $n = 20$ ). The 90-day survival rates in groups A, B, and C were 100.0%, 80.0%, and 35.0%, respectively. This classification accurately reflected the need for circulatory support, duration of respiratory management and operative findings, as well as morbidity and mortality (Table 1).

**Conclusions:** Our novel prenatal prognostic classification based on combining liver position and the L/T ratio accurately predicted CDH severity in these infants, suggesting this system to be applicable to risk-stratified management in fetuses with isolated CDH.

**Table 1** Need and duration for management, morbidity and mortality in isolated CDH patients

	Group A	Group B	Group C	P
Need for ECMO (%)	2.1	14.3	40.0	$<.001$
Need for prostaglandin E1 (%)	14.6	40.0	70.0	$<.001$
Duration of nitric oxide inhalation (days)**	8 (5)	11 (7)	34 (22)	$<.001$
Duration of ventilation (days)**	14 (9)	30 (21)	545 (30)	$<.001$
Duration of O <sub>2</sub> administration (days)**	23 (15)	43 (37)	555 (529)	$<.001$
Need for patch closure (%)	20.8	71.0	92.3	$<.001$
Survival to discharge (%)	100.0	74.3	20.0	$<.001$
Intact discharge (%)	95.8*, $P < .05$ A vs B	60.0	5.0	$<.001^{**}$ , median (interquartile range)

**Abstract ID: 1123** Specific Field: **Paediatric Surgery**

**Mode of pres.: Free Paper**  
**ISW 2011 Session 61.04**

**Intralesional steroid injection in small infants is capable and effective for esophageal anastomotic stricture**

S. Nakahara, A. Hatanaka, K. Ishida

Japanese Red Cross Medical Center, Tokyo, Japan

**Introduction:** Anastomotic stricture after surgical treatment of congenital esophageal atresia is relatively common complication. In the cases of refractory and resistant to balloon dilation, intralesional steroid injection (ISI) is reported effective. We performed ISI in five children including three small infants. In all cases, ISI was accomplished safely and was quite effective.

**Material and Methods:** ISI was performed in five cases (4 male and 1 female). All the patients were received surgical correction for congenital esophageal atresia (Gross C), and the anastomotic stricture was symptomatic. Under general anesthesia, endoscopic wire-guided balloon bougie was done with/without intralesional injection of triamcinolone acetate (0.3–0.5 ml into each quadrant at the concentration of 8 mg/ml).

**Results:** Case 1. 2 year-old girl. Before reference to our hospital, twice balloon bougie, laparoscopic fundoplication, second esophago-esophagostomy was performed to avoid the refractory stricture but in vain. Single ISI following just after balloon bougie was dramatically effective and the stricture has never been recurred. Case 2. 11 month-old boy. We performed balloon bougie for dysphagia. Three weeks after the first balloon dilation, another dilatation was needed, and ISI was added. He didn't need any more treatment. Case 3. 3 year-old boy. We augmented ISI at the first balloon dilatation. In this case, the

stenotic segment was longer and he needed ISI twice. After second injection, no recurrence was developed. Case 4. 1 month-old boy. ISI was not applied at the first balloon dilation, because the patient was too small. Every 2 to 3 weeks he needed repeated dilatation. At 3 month-old of age, his weight was 5.2 kg and ISI was done safely with the fourth dilation. No more dilation was needed after injection. Case 5. 1 month-old boy. The first balloon dilation was done at 3.2 kg. Two weeks later, he needed the second dilation. ISI was capable at this time. His weight was 3.8 kg. He has been asymptomatic since then. **Conclusions:** ISI increases efficacy of bougie dilation and decreases the requirement for repetition of bougie dilatation. And it is possible to be accomplished safely even in small infants.

**Abstract ID: 1124** Specific Field: **Paediatric Surgery**

**Mode of pres.: Free Paper**  
**ISW 2011 Session 61.05**

#### Firearm injuries in children <3 years of age

J. Allerdice-Snedden, H. Willis, D.W. Vane

Cardinal Glennon Children's Medical Center, Saint Louis University, Saint Louis, Missouri, USA

**Introduction:** Penetrating wounds in children are uncommon representing less than 15% in most Children's Hospitals. In our center the incidence of penetrating trauma far exceeds this number. We evaluated the incidence and demographics of wounds from firearms in children <13 years of age in order to develop a more specific injury prevention program based on current injury patterns.

**Material and Methods:** A 7-year (Jan 1 2002–July 31 2009) IRB approved retrospective review analyzed patients less than 13 years of age presenting to our institution with the ICD-9 code of Accident caused by firearm and air gun missile (E922.0, E922.1, E922.2, E922.3, E922.4, E922.5, E922.8, E922.9).

**Results:** Sixty-six children were identified with an age range of 9 months to 12 years (Mean = 9.03 years). There were 60 males and 6 females in this study. Injuries were caused by air guns (47), handguns (10), shotguns (5) and paintball guns (4). All cases were reported as accidental; the distribution was stratified into self-inflicted wounds (19), projectile devices fired by another child (38), projectile devices fired by adults (5) and from an unknown source (4). Eye injuries were the most common reason for presentation (24), followed by extremity injuries (16), torso injuries (15) and head and neck injuries excluding the eye (11). Thirty-eight patients were discharged from the ER while 28 patients were admitted. There were no deaths. The incidence increased with age. Surprisingly, winter months had the highest number of presentations while summer months were among the lowest.

**Conclusions:** Accidental firearm injuries are a significant mechanism of injury in this patient population. All of the injuries in this study were preventable and reportedly caused by accidental discharge of a projectile device. Injuries were overwhelmingly sustained in unsupervised settings. This study emphasizes the necessity of securing firearms from children of all ages and demonstrates a need for legislation mandating adult supervision of children (<13) using firearms of any type.

**Abstract ID: 1125** Specific Field: **Paediatric Surgery**

**Mode of pres.: Free Paper**  
**ISW 2011 Session 61.06**

#### Hangings in children: lessons learned from a city in crisis

N. Hamilton [1], D. Carpentier [1], D. Kraus [1], C. Green [1], M.S. Keller [1], D.W. Vane [2]

[1] Saint Louis University, Cardinal Glennon Children's Medical Center, USA, [2] Cardinal Glennon Children's Medical Center, Saint Louis University, Saint Louis, Missouri, USA

**Introduction:** To identify risk factors and prognostic indicators for children attempting suicide by hanging (SBH).

**Material and Methods:** Following IRB approval, the records for all children (ICD-9 mechanism of injury code = non-accidental hanging) managed at the 2 city level 1 pediatric trauma centers were reviewed.

**Results:** Thirty children were identified during the 5-year study period. Overall, 40% (12) survived to discharge. Management was supportive in all cases. X-ray imaging practices were highly variable. Plain radiographs of the cervical spine (c-spine) and head computed tomography (CT) were obtained in all children. Twenty-five children (83%) underwent c-spine CT despite normal plain radiographs. Additional cerebral vascular imaging (CT angiography, duplex ultrasound) was obtained in 10 (30%). Survival was predicted by presenting Glasgow Coma Score (GCS) and pH. All children who experienced a cardiopulmonary arrest died due to anoxic brain injury. Most survivors were discharged to inpatient psychiatric facilities. Multiple pre-injury risk factors were identified. Eighty-three percent (25) of the children were from single parent households. Ongoing treatment for mental illness was common (17 children, 57%) as was a strong family history for mental illness (37%, more than two family members). Three children had prior suicide attempts. All drug screens were negative. Forty-three percent (13) attempted SBH within one month of their birthday (~3× expected frequency), 3 children attempted SBH within 1 week of a Holiday or anniversary of a personal tragedy.

**Conclusions:** Cardiopulmonary arrest, low GCS and low pH on arrival predict mortality in children who attempt SBH. Associated cervical spine and cerebral vascular injuries are infrequent and an extensive workup appears unwarranted. The high prevalence of mental illness in these children and their families and a temporal relationship to significant life events are warning signs of high risk for this tragic event.

\*C2 subluxation and C2-3 listhesis, both diagnosed by plain radiograph

	Survived	Deceased	Significance
N	12(40%)	18(60%)	
AGE	14+/- 0.58	13.3+/- 0.5	n.s.
Male:Female	10:2	12:6	n.s.
White:Black:Hispanic	8:3:1	9:8:1	n.s.
Presenting GCS	11+/- 1.39	3+/- 0	<i>P</i> < 0.05
Presenting pH	7.32 +/- 0.03	7.01 +/- 0.05	<i>P</i> < 0.05
CT C spine	12 (100%)	15 (83%)	
Vascular Imaging	0 (0%)	2 (8%)*	
Vascular Injury	0 (0%)	0 (0%)	

**Abstract ID: 1126** Specific Field: **Paediatric Surgery**

**Mode of pres.: Free Paper**  
**ISW 2011 Session 61.07**

#### Expression of WT1 gene in a variety of pediatric tumors

T. Oue, S. Uehara, H. Yamanaka, Y. Takama, Y. Oji, M. Fukuzawa  
Osaka University Graduate School of Medicine, Osaka, Japan

**Introduction:** Wilms tumor 1 (WT1) gene was first identified as a tumor suppressor involved in the development of Wilms' tumor. Recently, WT1 has been reported to overexpressed in many types of neoplasms, suggesting that WT1 has oncogenic properties. Therefore WT1 became a molecular target for cancer therapy. The objective of this study was to evaluate the WT1 gene expression in various pediatric tumors and elucidate that WT1 can be a target of cancer therapy in pediatric malignancies.

**Material and Methods:** The expression of WT1 protein was examined in 65 cases of primary pediatric tumors, including 20 neuroblastomas, 18 rhabdomyosarcomas, 9 hepatoblastomas and 9 Wilms tumors by immunohistochemistry using polyclonal (C-19) and monoclonal (6F-H2) antibodies against WT1 protein. Levels of WT1 mRNA expression were examined by quantitative real-time RT-PCR analysis in frozen tissue samples from 56 cases with pediatric tumors. Various clinical factors were analyzed for correlations with WT1 expression levels.

**Results:** Immunohistochemical staining revealed that WT1-protein was detected in 25% of neuroblastoma, 83% of rhabdomyosarcoma, 78% of hepatoblastoma and 67% of Wilms tumor. A majority of the positive cases showed diffuse or granular staining in the cytoplasm. Alveolar rhabdomyosarcoma showed extremely strong cytoplasmic staining as compared with embryonal tumors. In neuroblastoma, differentiating cells showed strong cytoplasmic staining. WT1 mRNA expression was positive (more than 10–3 levels of normal kidney) in 55% of neuroblastoma, 45% of rhabdomyosarcoma, 33% of hepatoblastoma and 94% of Wilms tumor. No significant correlation was observed between the level of WT1 expression and clinical factors including clinical stage, distant metastasis and prognosis.

**Conclusions:** WT1 expression was broadly detected in various pediatric neoplasms. These results may indicate that WT1 can be a therapeutic target in the majority of pediatric malignancies.

**Abstract ID: 1127** Specific Field: **Paediatric Surgery**

**Mode of pres.: Free Paper**  
**ISW 2011 Session 61.08**

#### **Characterization of CD133+ cancer stem like cells in rhabdomyosarcoma cell lines**

Y. Fuchimoto [1], K. Fukuda [1], Y. Saikawa [1], Y. Yamamoto [1], Y. Kitagawa [1], Y. Morikawa [2]

[1] Keio University School of Medicine, Tokyo, Japan,  
[2] Keio University School of Medicine, Japan

**Introduction:** Recent progress in the isolation and identification of stem cells in normal organs has been utilized in several biological and medical fields to explore new procedures and therapies, including tissue regeneration. Some evidence suggests that CD133/Prominin1 is a marker for a subset of cancer stem-like cells in solid tumors. However, the proliferative and drug resistance properties of CD133/Prominin1-positive cancer stem cells in rhabdomyosarcoma (RMS) remain unknown.

**Material and Methods:** Cell Culture: Human RMS cell lines (RMS-YM, Rh30, RD, KYM-1) were obtained from the Japanese Cancer Research Resources Bank. Flow Cytometry Analysis: To identify and isolate the RD CD133<sup>+high</sup> and CD133<sup>-low</sup> fractions, The cells were analyzed and sorted using a mouse monoclonal antibodies (CD133-PE). Assay of Chemo-resistance Activity RD CD133<sup>+high</sup> and CD133<sup>-low</sup> cells were incubated and treated with cisplatin, endoxan, and cosmegen, and analyzed using a WST-8 method. Expression of

ABC transporter gene was analyzed using selective inverse PCR (SIPCR). Transplantation Experiment :Sorted RD CD133<sup>+high</sup> and CD133<sup>-low</sup> cells were subcutaneously injected into SCID mice ( $n = 5$ ).

**Results:** In this study, we determined the percentage of CD133<sup>+high</sup> cells in four rhabdomyosarcoma cell lines and xenografts established from RMS patients. Compared to CD133<sup>-low</sup> cells, CD133<sup>+high</sup> cells were significantly resistant to a number of chemotherapeutic agents, including cisplatin, endoxan, and cosmegen. We also determined the mRNA levels of markers associated with chemo-resistance. PXR, MPR4, MPR5, MPR7, and MPR9 mRNAs in CD133<sup>+high</sup> cells were increased compared to CD133<sup>-low</sup> cells. Additionally, the growth evaluation in culture showed that CD133<sup>+high</sup> cells consistently grew at a greater rate than did CD133<sup>-low</sup> cells. CD133<sup>+high</sup> cells also demonstrated higher *in vivo* than did CD133<sup>-low</sup> cells. Finally, CD133<sup>+high</sup> cells showed evidence for self-renewal, generating both CD133<sup>+high</sup> and CD133<sup>-low</sup> cells.

**Conclusions:** Our study for the first time provides evidence that CD133<sup>+high</sup> cancer stem-like cells display enhanced resistance to chemotherapy and increased tumorigenicity. Future treatment should target this small population of CD133<sup>+high</sup> cancer stem cells to improve the survival of RMS patients.

**Abstract ID: 1128** Specific Field: **Paediatric Surgery**

**Mode of pres.: Free Paper**  
**ISW 2011 Session 61.09**

#### **The increase of segmental chromosomal abnormalities in proportion to age at diagnosis in neuroblastoma without MYCN amplification**

R. Souzaki [1], T. Tajiri [1], Y. Kinoshita [1], R. Teshiba [1], R. Yosue [1], K. Kohashi [2], Y. Oda [2], T. Taguchi [1]

[1] Department of Pediatric Surgery, Kyushu University, Fukuoka, Japan, [2] Department of Anatomic Pathology, Kyushu University, Fukuoka, Japan

**Introduction:** In neuroblastoma (NBs) without MYCN amplification, the segmental chromosome aberrations (SGA) such as 1p loss, 11q loss and 17q gain was suggested to be associated with the prognosis of the patients. We assessed the correlation between the number of SGA and other biological factors in neuroblastoma primary samples.

**Material and Methods:** The status of SGA in 54 primary NBs was analyzed using a SNP array (Human CMV370-Duo, Illumina). The status of MYCN amplification was determined by SNP array and FISH method. The DNA ploidy was determined by flow cytometry.

**Results:** Nine of 54 samples showed MYCN amplification by SNP array and FISH method. All 9 samples with MYCN amplification and 20 of 45 samples without MYCN amplification showed diploid/tetraploid tumor. The most frequently SGA was 17q gain (26/54; 48.1%), 11q loss (16/54; 29.6%) followed by 1p loss (15/54; 27.8%). One or more SGA were detected in 37 (68.5%) of all 54 samples. All 9 samples with MYCN amplification and 28 (62.2%) of 45 samples without MYCN amplification showed one or more SGA. The number of SGA in NBs with MYCN amplification was  $4.78 \pm 2.82$  and those in NBs without MYCN amplification was  $4.02 \pm 2.82$  ( $P = 0.22$ ). In NBs without MYCN amplification, the number of SGA in diploid/tetra samples showed  $7.00 \pm 4.67$  and those in aneuploid samples showed  $1.64 \pm 2.78$ . There was significant difference ( $P \leq 0.001$ ). In



diploid/tetraploid samples without MYCN amplification, there was the significant difference between age at diagnosis less than 12 months ( $n = 7$ ) and over 12 months ( $n = 13$ ) ( $4.14 \pm 3.63$  v.s.  $8.54 \pm 4.54$ ;  $P = 0.04$ ). Moreover, the number of SGA correlated with the age at diagnosis in diploid/tetraploid tumors without MYCN amplification ( $r = 0.70$ ,  $P = 0.006$ ). In NBs with MYCN amplification, the number of SGA did not correlate with the age at diagnosis. **Conclusions:** Based on this result, the number of SGA significantly increased in proportion to age at diagnosis in diploid/tetraploid NBs without MYCN amplification. The age at diagnosis is one of poor prognostic factors in NBs. On the other hand, the SGA such as 17q gain, 11q loss and 1p loss is also one of poor prognostic factors in NBs. These SGA may play an important role in the prognosis of the patients without MYCN amplification over 12 months of age.

### Abstract ID: 1129 Specific Field: Paediatric Surgery

Mode of pres.: Free Paper  
ISW 2011 Session 122.01

#### Toll-like receptor mRNA expression in liver tissue from biliary atresia patients

T. Saito, T. Hishiki, Y. Sato, T. Mitsunaga, E. Terui, E. Saito, H. Yoshida

Chiba University, Chiba City, Japan

**Introduction:** Inappropriate host immunological reactions against unknown ligands via the Toll-like receptor (TLR) cascades may trigger progressive inflammatory biliary destruction that manifests as biliary atresia (BA) in newborns or infants. The purpose of this study is to clarify the role of the innate immune system in the development of BA.

**Material and Methods:** Liver tissue was obtained from 49 patients with pediatric hepatobiliary disease comprising 19 with BA, 21 with choledochal cysts (CC), and 9 with other hepatobiliary diseases. BA samples obtained during the initial portoenterostomy, and during reoperation or liver transplantation (LT) were classified as early and late BA, respectively. Of the early BA group cases, those requiring LT were designated as the LT group, and the others were designated as the non-LT group. The mRNA expression levels of TLRs 2, 3, 4, 7 and 8 were determined by real-time quantitative reverse transcription-PCR (QRT-PCR) and compared among groups. The correlation between TLR mRNA expression level and age at sampling was examined for each TLR in the BA patients.

**Results:** TLR 8 mRNA, encoding the receptor for single-stranded RNA, was significantly higher in the BA group, compared with non-BA groups ( $P = 0.008$ ). Within the BA groups, mRNA levels of TLRs 2 and 8 were significantly higher in the early group than in the late group ( $P = 0.02$  and  $0.006$ , respectively), despite there being no significant correlation between TLR mRNA expression and age at sampling, except for TLR 7 ( $r = 0.77$ ,  $P = 0.001$ ). Compared to the non-LT group, the LT group demonstrated significantly higher mRNA expression of TLRs 3 and 7 ( $P = 0.02$  and  $0.01$ , respectively).

**Conclusions:** Innate immune responses might contribute to the initiation and progression of BA. Severe inflammation characteristic of BA around the time of the first operation may abate postoperatively, but determination of selected TLR mRNA expression levels in the liver at the time of Kasai portoenterostomy may assist in predicting the prognosis of BA patients.

### Abstract ID: 1130 Specific Field: Paediatric Surgery

Mode of pres.: Free Paper  
ISW 2011 Session 122.02

#### The usefulness of high speed 3D image analysis system (SYNAPSE VINCENT) in pediatric living donor liver transplantation

K. Mochizuki, S. Eguchi, M. Obatake, M. Takatsuki, A. Soyama, M. Hidaka, T. Tokunaga, T. Kanematsu

Nagasaki University Graduate School of Biomedical Sciences, Nagasaki, Japan

**Introduction:** CT volumetry is used to calculate graft volume in living donor liver transplantation (LDLT). We have used high speed 3D image analysis system (SYNAPSE VINCENT; Fuji Photo Film Co., Ltd.) to calculate graft volume in LDLT since March, 2010. It can extract each vessel territory in the liver using contrast enhanced CT images and display 3D images simply (one click), quickly (within a few minutes) and accurately. There is a possibility of becoming large-for-size grafts especially in infant LDLTs and monosegment grafts or reduced grafts may have to be introduced. In monosegment graft, the perfusion area of hepatic venous tributaries poses a problem. In order to overcome the problem, the usefulness of SYNAPSE VINCENT in pediatric LDLT was investigated.

**Material and Methods:** In three pediatric patients with biliary atresia SYNAPSE VINCENT was used to calculate graft volume in LDLT. Case 1: 10-month-old boy (height/weight at LDLT: 66 cm/6.7 kg), donor: father (height/weight at LDLT: 167 cm/63 kg); Case 2: 6-month-old girl (61.2 cm/6.4 kg), donor: mother (156 cm/57.2 kg); Case 3: 7-year-old boy (124.5 cm/23.8 kg), donor: father (166 cm/58 kg). In two infants, the possibility of monosegment grafts was assessed and taken into consideration when calculating graft volumetry of segment 3.

**Results:** Preoperative graft volumetry of the left lateral segment in case 1 was 377 ml (5.6% in the graft recipient weight ratio; GRWR); case 2, 278 ml (4.3%); and case 3, 427 ml (1.8%). Graft volumetry of segment 3 in case 1 was 157 ml (2.3% in the GRWR); case 2, 129.4 ml (2.0%). In case 2, it was feasible to extract each segmental hepatic venous perfusion area using SYNAPSE VINCENT. In this case, since donor V2 and V3 were independent branching, monosegment graft according to the venous perfusion could be evaluated pre-operatively. Actual graft weight in case 1 was 324 g (4.8% in the GRWR); case 2, 281 g (4.4%); and case 3, 407 g (1.7%). The each postoperative course was uneventful; neither blood vessel nor bile duct complications were detected.

**Conclusions:** Graft volumetry using SYNAPSE VINCENT was useful to plan LDLT operative procedure, especially in infants possibly needing monosegment graft.

### Abstract ID: 1131 Specific Field: Paediatric Surgery

Mode of pres.: Free Paper  
ISW 2011 Session 122.03

#### Activating transcription factor 3 is not up-regulated in hypospadias patients in Japan

T. Takahashi, A. Shimotakahara, K. Miyahara, G. Miyano, H. Koga, A. Yamataka

Juntendo University School of Medicine, Tokyo, Japan

**Introduction:** Hypospadias is one of the most common urogenital malformations, but its etiology is largely uncharacterized. Environmental factors such as in utero exposure to estrogenic or anti-androgenic compounds have been considered to be associated with the development of this anomaly, and some researchers have advocated the potential role for up-regulation of activating transcription factor 3 (ATF3), an estrogen-responsive gene. Here, we studied the expression of ATF3 protein in Japanese hypospadias patients.

**Material and Methods:** We examined the expression of ATF3 protein in prepuce specimens taken from patients undergoing curative surgery for hypospadias and elective circumcision for phimosis. In all cases, prepuce was obtained at the time of surgery and was prepared for paraffin-embedded sectioning. ATF3 protein was stained immunohistochemically. Two researchers blindly evaluated immunoreactivity and scored it semiquantitatively as nil = 0, weak = 1, and strong = 2, to give a final staining intensity score (SIS). Results were expressed as mean  $\pm$  SD. Data was analyzed by the use of chi-square, two-way ANOVA and Mann-Whitney tests. A P value of less than 0.05 was considered significant.

**Results:** All subjects lived in metropolitan Tokyo, Japan. Prepuce specimens were obtained from 18 hypospadias patients and 17 phimosis patients. Mean ages at surgery were  $2.9 \pm 1.0$  and  $3.9 \pm 2.4$ , respectively ( $P > .05$ ). SIS in stromal cell nuclei and vascular endothelium were not statistically different between hypospadias patients ( $1.4 \pm 0.5$ ) and controls ( $1.5 \pm 0.5$ ), ( $P > .05$ ).

**Conclusions:** We found the expression of ATF3 at the time of surgery was not up-regulated in a cross-section of hypospadias patients living in urban Tokyo.

**Abstract ID: 1132** Specific Field: **Paediatric Surgery**

**Mode of pres.: Free Paper**  
**ISW 2011 Session 122.04**

**The use of cyanoacrylate dressing for proximal hypospadias repair: a simple solution to a vexing problem**

H.L. Tan

National University of Malaysia, Kuala Lumpur, Malaysia

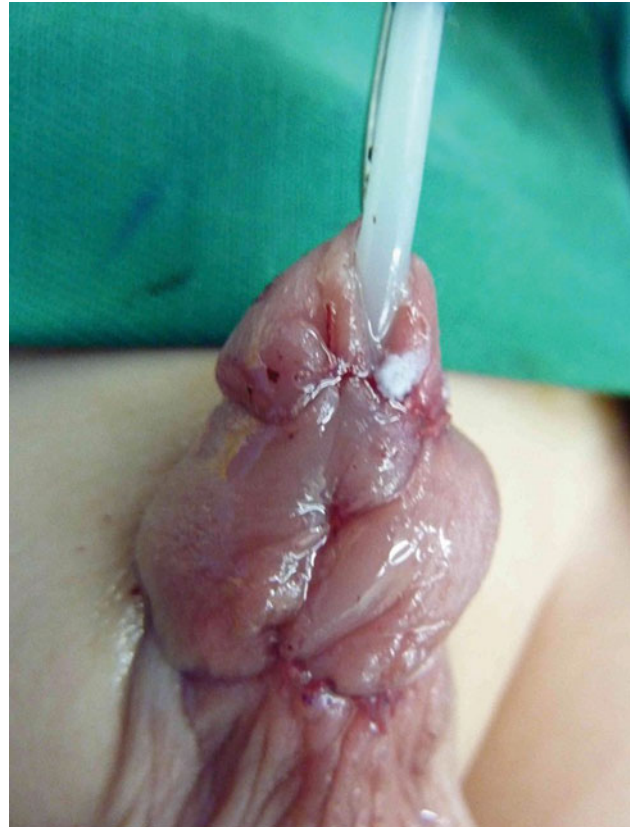**Introduction:** The surgery for proximal hypospadias presents many challenges especially with regards to the post operative management. An ideal dressing that adequately protects the complex contours and provide a clean impermeable barrier has yet to be described. Cyanoacrylate tissue glue has been used for many years to approximate skin lacerations. We report the novel use of Cyanoacrylate for as the primary dressing for complex hypospadias. Its use in proximal hypospadias surgery has not been previously described.

**Material and Methods:** This is a retrospective audit of all hypospadias repairs from July 2008 to July 2010. Of 40 cases, only eight (8) had distal hypospadias. The remainder (32) had severe proximal hypospadias requiring staged repair. In all cases, Cyanoacrylate was initially applied onto the suture line to ensure accurate skin apposition before coating the entire Penis to act as a protective barrier. The urethral stent was also deliberately glued to the neo meatus to completely encase it, to reduce the risk of accidental dislodgment. Patients were discharged the following day and reviewed one week later when the stent was removed.

**Results:** There was no wound infection. One patient had partial wound dehiscence. There was one “accidental” dislodgement of the stent on the fifth postoperative day. Three children developed post operative fistula.

**Conclusions:** Cyanoacrylate is an effective, safe, impermeable and waterproof dressing for hypospadias surgery. It is easy to keep clean

and does not smell. The technique of gluing the urethral stent to the neourethra is a novel approach not previously described. This appears to be effective in preventing accidental dislodgement. In our experience, Cyanoacrylate is an ideal dressing for hypospadias repair.



**Figure:** Completed Cyanoacrylate dressing for complex hypospadias

**Abstract ID: 1133** Specific Field: **Paediatric Surgery**

**Mode of pres.: Free Paper**  
**ISW 2011 Session 122.05**

**New technique of ileostomy for extremely low birth weight infant**

K. Ohashi, T. Koshinaga, T. Ikeda

Nihon University School of Medicine, Tokyo, Japan

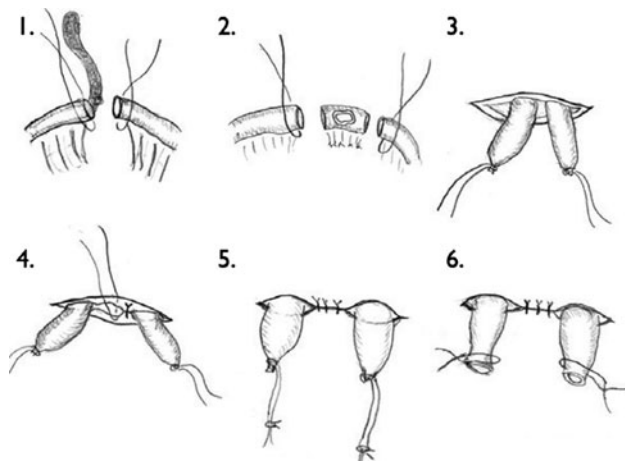
**Introduction:** In recent years, the survival rates have significantly improved in the extremely low birth weight infants (ELBWI). Meconium obstruction of the small bowel (MOSB) and spontaneous localized intestinal perforation (SLIP) have been reportedly increased in number in the clinical settings. We frequently face to the decision to construct ileostomy in such ELBWI. Many serious stoma related complications have been reported: stoma side perforation, prolapse, falling, surgical site infection and skin sores. Once these complications occur, it would be difficult to give patients optimal enteral nutrition. A safe surgical procedure without complications is mandatory. We introduce a newly improved technique of ileostomy construction particularly for ELBWI.

**Material and Methods:** Patients: Group A (Conventional procedure) 10 patients (MOSB 5, SLIP 5) with birth weight of  $656 \pm 162$  g ( $M \pm SD$ ). Group B (New procedure) 7 patients (MOSB 3, SLIP 2,

NEC 2) with birth weight of  $646 \pm 108$  g. Main points of procedures: (1) To prevent stoma side perforation and necrosis caused by suturing thin intestinal wall: Do not fix abdominal wall to intestinal tract. (2) To prevent stoma prolapse: two single outlet ileostomies are made. Close an abdominal wall between two outlets. (3) To prevent stoma from falling into abdominal cavity: Hook stumps in front of abdominal wall. (4) To prevent surgical site infection: Do not open intestinal stumps for a few days after the surgery. We decompress the intestine if it is markedly dilated. To elucidate the feasibility and safety of the procedure, we examine an incidence of surgical complications, operating times and survival rates compared between the two groups.

**Results:** Incidence of stoma related complications: Prolapse: Group A (A) 40%: Group B (B) 0%, Fall (or necrosis): A 10%: B 0%, Surgical site infection: A 10%: B 0%. Operating time: A  $52 \pm 19$  min: B  $60 \pm 21$  min. Survival rates: A 40%: B 28.5%.

**Conclusions:** Our new technique is safe and have lower risk of stoma related complications. It is an ideal procedure for the ELBWI.



**Figure:** Main points of the procedures

#### Abstract ID: 1134 Specific Field: Paediatric Surgery

**Mode of pres.: Free Paper**  
ISW 2011 Session 122.06

##### **Retroperitoneoscopic adhesiolysis of fibrotic tissue between aberrant crossing lower renal vessels and the ureteropelvic junction remedies renovascular ureteropelvic junction obstruction: A Case report**

N. Nakazawa, H. Koga, H. Nakamura, G. Miyano, G. Lane, T. Okazaki, A. Yamataka

Juntendo University School of Medicine, Tokyo, Japan

**Introduction:** We report a unique experience of retroperitoneoscopic surgery in a child with ureteropelvic junction obstruction (UPJO) due to aberrant crossing lower renal vessels (ACLRV). Adhesiolysis alone was effective without pyeloplasty.

**Material and Methods:** A 6-year-old boy with episodes of recurrent severe right and mild left flank pain due to bilateral UPJO was referred to us. At ultrasonography, left UPJO was grade 4, and right was grade 2. Diethylenetriamine pentaacetic acid (DTPA) renography revealed an obstructive pattern on the left, but a non-obstructive pattern on right. ACLRV at the UPJO were shown on magnetic

resonance imaging (MRI) angiography. Open dismembered pyeloplasty was performed for the left UPJO. A double-J stent tube was placed on the right with resolution of recurrent severe right flank pain. Retroperitoneoscopic surgery was planned for the right renovascular UPJO. Under retroperitoneoscopy, ACLRV were found obstructing the ureteropelvic junction (UPJ) because of fibrotic tissue adhesions between the UPJ and ACLRV. So, the double J stent placed in the right ureter was removed and the fibrotic adhesions released retroperitoneoscopically using 3 trocars. After adhesiolysis, the UPJ appeared not to be kinked, and the double J stent tube was not replaced.

**Results:** The postoperative course was uneventful, and at follow-up of 12 months later he is well without bilateral flank pain.

**Conclusions:** In our cases, open surgery was avoided for the right kidney, and the right flank wound was cosmetic. Retroperitoneal surgery should be considered for a child with ACLRV.

#### Abstract ID: 1135 Specific Field: Paediatric Surgery

**Mode of pres.: Free Paper**  
ISW 2011 Session 122.07

##### **Efficacy of colon patch grafting for TPN-dependent hypoganglionosis**

N. Shimojima, H. Tomita, F. Takasato, Y. Yamamoto, M. Mori, Y. Fuchimoto, K. Hoshino, Y. Morikawa

Keio University School of Medicine, Tokyo, Japan

**Introduction:** Hypoganglionosis is a congenital gastrointestinal motility disorder revealing constipation, abdominal distention, and vomiting. Pathological findings show decreased number of ganglion cells and their immaturity. Affected area is often extensive in small and large bowels. The principles of treatment are prevention of enterocolitis and adaptation of residual bowels. If the adaptation was not achieved, small bowel transplantation would be the only therapeutic option.

**Material and Methods:** Subjects were two cases of hypoganglionosis. Oral intake was limited and total parenteral nutrition (TPN) was necessary in both cases. An extensive resection of small bowel with ascending colon patch grafting was performed to prevent enteritis and increase oral intake tolerance.

**Results:** Case 1: A 1-year-old girl with hypoganglionosis was referred to our hospital as a candidate for small bowel transplantation. She had an ileostomy at 30 cm proximal from ileocecal valve and required irrigation from stoma routinely. At 3 years of age weighing 7.3 kg, she underwent extensive resection of small bowel with colon patch grafting. Jejunostomy was placed at 50 cm from Treitz ligament and 10 cm graft from ascending colon was attached at distal lesion of residual jejunum. After the operation, frequency of enteritis is decreased and irrigation became unnecessary. Oral intake tolerance gradually increased and TPN has been weaned off at 1 year after the operation.

Case 2: A 6-months-boy with total intestinal aganglionosis was referred to our hospital. He only had a gastrostomy and was completely TPN-dependent. Soon after the referral, he underwent extensive resection of small bowel. Length of residual jejunum was 27 cm. Pathological diagnosis was hypoganglionosis. After the operation, oral feeding turned into possible, however stoma output increased as well. At 1 year and 7 months of age weighing 6.6 kg, he underwent laparotomy for colon patch grafting. Currently, 8 months after the operation, oral intake tolerance is increasing and weaning from TPN is in progress.

**Conclusions:** The management for hypoganglionosis is often intractable due to frequent enteritis. Chances of enteritis decrease by



extensive bowel resection, yet absorption ability is largely sacrificed. Combination of colon patch grafting makes absorption area larger and seems to be helpful for weaning from TPN.

**Abstract ID: 1136** Specific Field: **Paediatric Surgery**

**Mode of pres.: Free Paper**  
**ISW 2011 Session 122.08**

**Complete urorectal septum malformation sequence: two surviving cases at our institution**

M. Shinkai, S. Honda, Y. Hirata, Y. Ohhama, H. Take, N. Kitagawa, Y. Usui, Y. Yamazaki

Kanagawa Children's Medical Center, Yokohama, Japan

**Introduction:** Complete urorectal septum malformation (URSM) sequence is an extremely rare and lethal anomaly including absence of perineal and anal openings associated with ambiguous genitalia and urogenital anomalies. Widespread application and advances in fetal imaging and intervention have recently led to saving a small number of patients with this anomaly. We herein report the survival of two cases of complete URSM sequence treated at our institution.

**Material and Methods:** Retrospective chart review of neonates with complete URSM sequence at our institution was done. There were two survivors and four neonatal deaths.

**Results:** Case 1: After fetal vesical drainage was done, a female neonate was born at 37 weeks of gestation by cesarean section as one of the twins. She had lax and redundant abdominal wall with giant urinary bladder, bilateral hydronephrosis and hydroureter, left hypoplastic lung, and no anal, vaginal, or urethral openings. Uterus and bilateral ovaries were identified in the pelvis. Vesicostomy and colostomy were constructed at 1 day of age. Posterior sagittal anorectoplasty was done at 2 years of age. Vesicoureteroneostomy, appendicovesicostomy, and vaginoplasty using ileal conduit was done at 6 years of age. She is now 8 years of age and needs scrupulous bowel management. Case 2: After placement of vesicoamniotic shunt at 17 weeks of gestation, a female neonate was born at 41 weeks of gestation by vaginal delivery. She had lax and redundant abdominal wall with giant urinary bladder, left dysplastic kidney, a phallic-like structure without anal, vaginal, or urethral openings. Laparoscopically identifying uterus and bilateral ovaries, we constructed cutaneo-vesicostomy and sigmoid colostomy at 1 day of age. After confirming rectovesical fistula, right vesicoureteral reflux, external anal sphincter and puborectal muscle, we performed sacro-abdomino-perineal rectoplasty at 14 months of age. She is now 1.5 years of age and maintained normal renal function.

**Conclusions:** Early fetal intervention for urinary obstruction may save lives of the neonates with complete URSM sequence, though correct prenatal diagnosis of this anomaly remains a challenge. Postnatal survival is good, however, associated with considerable morbidity which requires multidisciplinary approach.

**Abstract ID: 1137** Specific Field: **Paediatric Surgery**

**Mode of pres.: Poster Discussion**  
**ISW 2011 Session 122.09**

**Neonatal intussusception mimicking meconium obstruction in a premature infant**

N. Morikawa [1], S. Ueno [1], K. Murakami [1], J. Nishikata [2], T. Kobayashi [2], N. Sugiyama [2], A. Fukumura [2], H. Mochizuki [3]

[1] Division of Pediatric Surgery, Tokai University, Kanagawa, Japan, [2] Division of Neonatology, Department of Pediatrics, Tokai University, Kanagawa, Japan, [3] Department of Pediatrics, Tokai University, Kanagawa, Japan

**Introduction:** Intussusception in premature neonates (IPN) is an extremely rare entity. Its rarity and difficulty to differentiate IPN from necrotizing enterocolitis often delays its diagnosis. IPN is not commonly associated with a definite leading pathology, and there were only two anecdotal reports of IPN with a lead point of meconium in the literature.

**Material and Methods:** We report on the case of IPN with a lead point of inspissated meconium plug mimicking meconium obstruction of prematurity.

**Results:** A 1290 g infant was born at 28 weeks' gestation by cesarean section due to preterm labor and rupture of membrane. The mother with cervical incompetence had been treated with magnesium sulfate since 16 weeks' gestation for tocolysis. The prenatal sonography detected no abnormalities of ascites or dilated bowel loops. He was immediately intubated, given surfactant, and placed on mechanical ventilation with the diagnosis of respiratory distress syndrome. Myocardial dysfunction was also notified requiring catecholamine support. He passed a small amount of bloody stool on day 2, but his general condition was good with normal X-ray findings and laboratory data. Although bilious nasogastric aspirate and mild abdominal distention persisted, he continued to pass small amounts of meconium plug stool with a normal level of serum C-reactive protein. Because of mild progression of bowel obstruction and maternal treatment with magnesium sulfate, meconium obstruction was highly suspected. Gastrografin enemas in aliquots of 10 ml revealed a microcolon, but failed in resolution of bowel obstruction. On day 19, an extensive Gastrografin enema was challenged for a therapeutic purpose to delineate the inspissated meconium under general anesthesia in the operating room with preparation of ileostomy. Gastrografin enema showed a long filling defect in the ileum suggesting meconium obstruction; however, intestinal perforation developed during the procedure requiring emergent laparotomy. On exploration, ileoileal intussusception with a lead point of meconium plug was identified and resection of the invaginated segment including perforation sites with ileostomy was performed. The postoperative course was uneventful thus far.

**Conclusions:** Although rare, one should be aware that intussusception could occur and mimic meconium obstruction in premature neonates.

**Abstract ID: 1138** Specific Field: **Paediatric Surgery**

**Mode of pres.: Poster Discussion**  
**ISW 2011 Session 122.10**

**Loss of carcinoembryonic antigen-related cell adhesion molecule 1 expression predicts metachronous pulmonary metastasis and poor survival in patients with hepatoblastoma**

M. Tsukada, T. Wakai, Y. Matsuda, P. Korita, Y. Shirai, Y. Ajioka, K. Hatakeyama, M. Kubota

Niigata University Graduate School of Medical and Dental Sciences, Niigata, Japan

**Introduction:** Carcinoembryonic antigen-related CAM 1 (CEACAM1), also known as biliary glycoprotein, CD66a and pp120, is a member of the carcinoembryonic antigen family of immunoglobulin-like adhesion molecules. The aim of this study was to test the hypothesis that loss of CEACAM1 expression in hepatoblastoma cells

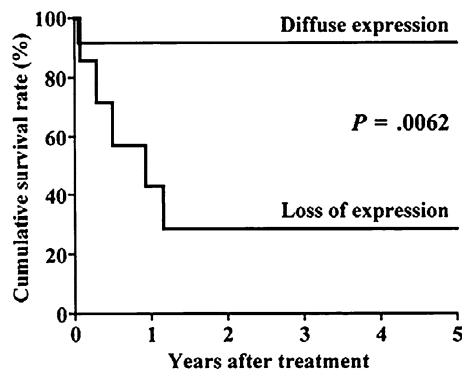


may promote hematogenous metastasis and function as an adverse prognostic factor.

**Material and Methods:** Immunohistochemical expression of CEACAM1 in surgically resected specimens from 19 patients with hepatoblastoma was examined retrospectively. The CEACAM1 expression in the epithelial area of the tumor was classified into 2 categories as follows: diffuse expression, characterized by positive staining throughout the tumor specimen, or loss of expression, in which there were distinct areas of negative staining within the tumor specimen.

**Results:** Twelve patients had tumors with diffuse CEACAM1 expression, whereas 7 had tumors with loss of CEACAM1 expression. The CEACAM1 expression in tumor cells was significantly associated with 2 tumor-related factors. Vascular invasion ( $P = 0.010$ ) and large tumor size ( $>10$  cm;  $P = 0.017$ ), indicative of aggressive tumor biology, were more frequent in tumors with loss of CEACAM1 expression. The other factors were comparable between the 2 groups according to the pattern of CEACAM1 expression. Survival after treatment was significantly worse in patients with tumors with loss of CEACAM1 expression (cumulative 5-year survival rate, 29%) than in patients with diffuse CEACAM1 expression (cumulative 5-year survival rate, 92%;  $P = 0.0062$ ). Loss of CEACAM1 expression was a significant risk factor for metachronous pulmonary metastases ( $P = 0.0105$ ).

**Conclusions:** Loss of CEACAM1 expression in the primary tumors of hepatoblastoma is associated with the subsequent development of metastatic disease. Loss of CEACAM1 expression may reflect a high metastatic potential and thus indicate a poor prognosis for patients with hepatoblastoma.



No. of patients at risk

Diffuse expression	12	11	11	11	10	10
Loss of expression	7	3	2	2	2	2

**Figure:** Kaplan-Meier overall survival estimates. 1294249059\_01ek8B.jpg

**Abstract ID: 1139** Specific Field: **Paediatric Surgery**

**Mode of pres.: Poster Discussion**  
**ISW 2011 Session 132.01**

**Leech infestation in children through body orifices: experience in a hospital in Bangladesh**

M.J. Hannan [1], M.M. Hoque [2]

[1] Chattagram Maa-O-Shishu Hospital, Bangladesh, [2] Chattagram Maa-O-Shishu Hospital Medical College, Chittagong, Bangladesh

**Introduction:** Bangladesh, as a tropical country harbors plenty of leeches in its vast wetlands. Leeches have a tendency to attach to

body surfaces for blood-sucking. They also enter into body cavities through urethra, anus, vagina and other body orifices; give rise to confusing and anxious situations for the parents and often life threatening consequences.

**Material and Methods:** Between 1st January 2004 and 31st December 2010, 17 cases of leech infestation through body orifices in children were managed. This is a retrospective study and age, sex, route of leech entry, investigation and treatment were evaluated.

**Results:** Age ranged from 4 years 6 months to 11 years (Mean 6.441  $\pm$  1.887 years) and females accounted for over 70% of cases. The orifices through which leeches entered into body cavities include urethra, vagina and rectum. Fifteen cases presented with bleeding through orifices of leech entry. Duration of bleeding prior to admission ranged from 3 h to 48 h (Mean 15.88  $\pm$  13.36 h). Hb% measured in all cases and blood transfusion given in 5 cases with Hb% below 7 gm/dl. Two boys presented with acute retention of urine. USG revealed elongated structures within the urinary bladder. Both these cases needed Suprapubic exploration of bladder to extract the leech. In 3 cases leeches were retrieved from vagina under general anesthesia. Leeches in the vagina came out after instillation of normal saline on 3 occasions. In the remaining 9 cases instillation of normal saline was sufficient to stop bleeding.

**Conclusions:** Leech infestation is common in the children of rural Bangladesh. Prompt diagnosis of leech infestation into lower body cavities is of paramount importance and application of common salt is effective in most cases. Sometimes surgical intervention is required.

Route of leech entry and treatment given

	Saline instillation	Extraction under anesthesia	Bladder exploration
Urethra	6	0	2
Vagina	3	3	0
Rectum	2	1	0
Total	11	4	2

**Abstract ID: 1140** Specific Field: **Paediatric Surgery**

**Mode of pres.: Poster Discussion**  
**ISW 2011 Session 132.02**

**Life-threatening large hepatic hemangioendothelioma in infancy: report of seven cases**

N. Suzuki [1], Y. Yamamoto [1], F. Toki [1], A. Nishi [1], S. Hatakeyama [2], K. Maruyama [3], M. Park [4], J. Hirato [5]

[1] Department of Surgery, Gunma Children's Medical Center, Shibukawa-city, Gunma, Japan, [2] Department of Radiology, Gunma Children's Medical Center, Shibukawa-city, Gunma, Japan, [3] Department of Neonatology, Gunma Children's Medical Center, Shibukawa-city, Gunma, Japan, [4] Department of Hematology/Oncology, Gunma Children's Medical Center, Shibukawa-city, Gunma, Japan, [5] Department of Pathology, Gunma Children's Medical Center, Shibukawa-city, Gunma, Japan

**Introduction:** Hepatic hemangioma can produce life-threatening complication of cardiac failure, Kasabach-Merritt syndrome or respiratory distress as a result of massive hepatomegaly. Prednisone, irradiation, hepatic artery embolization or ligation, and hepatic resection have been treatments of choice. We report seven cases of our experience with huge hepatic hemangioendothelioma in infancy.

**Material and Methods:** Seven infants (5 male, 2 female) with large liver hemangioma were treated between 1989 and 2010. They

presented with abdominal distention and showed signs of abdominal tumor. Cases 1, 2, 3 and 4 have already been reported in ISW99, Vienna, Austria.

**Results:** Gastric or retroperitoneal teratoma was suspected prenatally in two patients (case 3, 5), and one of them (Case 5) died by severe cardiac failure and DIC without any prophylactic treatment. Two patients (cases 1 and 4) complicated with cardiac failure and respiratory distress were treated by emergency hepatic artery embolization, and the post-operative course has been complicated with MOF in case 1. Including a prenatally diagnosed case, 2 of 7 patients (case 2 and 3) were treated by right segmental lobectomy (case 2), and by left segmental lobectomy (case 3). Open biopsy by laparotomy resulted massive increase of multiple liver hemangioma in case 6, followed by liver transplantation, but hemangioma is recurred in transplanted liver. In case 7, hemangioma was regressed after steroid and radiation therapy.

**Conclusions:** In cases of hepatic hemangioendothelioma with life-threatening cardiac decompensation, definitive treatment by hepatic artery embolization or ligation should be carried out urgently, and early excision is recommended for a resectable lesion confined to one lobe. Spontaneous resolution of hemangioma can be expected, and conservative treatment is also to be considered. In case 6, angiosarcoma has been suspected, although hemangioendothelioma type 2 was diagnosed pathologically. She died with all body metastasis at two years two months after the liver transplantation.

**Abstract ID: 1141** Specific Field: **Paediatric Surgery**

**Mode of pres.: Poster Discussion**  
**ISW 2011 Session 132.03**

#### **Lymphatic cyst formation potency of human lymphangioma derived lymphatic endothelial cell**

A. Fujino, T. Kuroda, N. Morikawa, Y. Kitano, H. Tanaka, T. Watanabe, N. Takeda, H. Makino

National Center for Child Health and Development, Tokyo, Japan

**Introduction:** Lymphangioma is a challenging disease in some difficult cases. We don't have any good therapeutic option for such cases. To improve therapeutic strategy, further understanding of this disease by basic and biological approach is essential. The aim of this study is to characterize human lymphangioma derived lymphatic endothelial cells (HL-LECs) from lymphatic cyst of lymphangioma and elucidate its difference with normal LEC, and finally to find out biological characteristics that could be targeted for therapy.

**Material and Methods:** The research project was approved by the Ethics Committee of National Center for Child Health and Development. Lymphangioma tissues were obtained from patients at surgical resection with informed consent. Human lymphangioma derived LECs (HL-LECs) were grown from tissue explants, isolated and cultured. Normal human dermis derived LECs (HMVEC-dLy) were used as a control LEC. Gene expressions and endothelial features were examined by immunofluorescence, RT-PCR, tube formation assay, FACS and microarray. HL-LECs and HMVEC-dLy were transplanted into immunodeficient NOG mice subcutaneously or intramuscularly; tissues at injection site were harvested after 4 weeks and then examined by immunohistochemistry.

**Results:** HL-LECs showed lymphatic endothelial characteristics as HMVEC-dLy did *in vitro*; expression pattern of LEC markers and endothelial cell markers were similar in these LECs, and both formed tubular network in tube formation assay. However, when transplanted in NOG mouse, HL-LECs formed multiple small cystic lymphangioma-like tissue, while HMVEC-dLy only formed small lymphatic vessels that elongated in the mouse tissue.

**Conclusions:** The fact that HL-LECs have abnormal pathogenic potency, cyst formation, suggests that LECs could be the direct target for lymphangioma treatment. In addition, NOG mouse transplanted with HL-LEC could be a useful experimental model to investigate biology and pathogenesis of lymphangioma and it might help develop new therapeutic methods to treat human lymphangioma.

**Abstract ID: 1142** Specific Field: **Paediatric Surgery**

**Mode of pres.: Poster Discussion**  
**ISW 2011 Session 132.04**

#### **Inguinal hernias containing uterus, fallopian tube and ovary in female infants**

H. Takayasu, K. Tanaka, N. Takeda, M. Watanabe

Kitasato University, Sagamihara, Japan

**Introduction:** The sliding hernia which contains the ovary with or without the fallopian tube occurs occasionally in female patients. However, sliding hernias containing ovary and uterus are extremely rare.

**Material and Methods:** All charts of patients with a diagnosis of inguinal hernia who underwent surgery from 2004 to 2010 in Kitasato University Hospital were reviewed. Of 343 female children diagnosed with inguinal hernias treated with herniotomy, 34 cases (10%) were with hernias fallopian tube and/or ovary and 3 cases had hernia containing uterus, fallopian tube and ovary. We present three such cases and review 14 other cases previously reported.

**Results:** Case 1: A 40-day-old female infant was presented with a large tender mass in the left groin. A mobile mass and unmobile mass was palpated within the swelling. The swelling was not reducible. Ultrasonography (US) showed ovary-like structure and homogenous echogenic mass with a central hyper echoic line without peristalsis herniated through inguinal canal. That was thought to be the uterus herniated in to the sac. Surgical exploration revealed a sliding hernia containing the uterus, both ovaries and tubes. Case 2: A female neonates was presented with a tender mass in the left groin. Physical and US findings of groin were similar to those of the case 1. At surgical exploration, on opening the sac, body of uterus, both ovaries and fallopian tubes were found. Case 3: A 7-month-old female infant was presented with a large tender mass in the left groin. US revealed an inguinal hernia contained fallopian tube and left ovary. At surgical exploration, the sac contained a body of uterus, left ovary, and fallopian tube. We could collect the precise clinical data of 14 cases previously reported. Almost all of the cases were left-sided hernia. The incidence of hernias containing uterus, ovary and fallopian tube decreases with age. Previous reports recommended preoperative US pointed out the same findings.

**Conclusions:** We should consider the possibility of inguinal hernia contains uterus and ovary when we see the left-sided irreducible inguinal hernia in infants especially less than 3 months of age. Elective surgery based on accurate diagnosis achieved by US is recommended when the patients is well without any symptom of incarceration.

**Abstract ID: 1143** Specific Field: **Paediatric Surgery**

**Mode of pres.: Poster Discussion**  
**ISW 2011 Session 132.05**

#### **BCG osteomyelitis of the femur mimicking a musculoskeletal tumor: a case report and literature review**

M. Hatanaka [1], A. Igarashi [1], F. Junko [1], M. Suzuki [1], Y. Ishimaru [1], K. Tahara [1], H. Ikeda [1], T. Miyagawa [2]

[1] Dokkyo Medical University Koshigaya Hospital, Saitama, Japan, [2] Tokyo Metropolitan Children's Medical Center, Fuchu-shi, Japan

**Introduction:** Adverse reactions associated with Bacille Calmette-Guérin (BCG) vaccine have been well-documented and are more common in younger children. They also may vary with the BCG strain, and include both local reactions such as suppurative adenitis or localized abscess, and systemic reactions such as osteomyelitis and disseminated BCG infection. Recently, we encountered a case of osteomyelitis of the femur mimicking a musculoskeletal tumor that was thought to be a complication of BCG vaccination.

**Material and Methods:** The patient was a 17-month-old boy presenting with a painless soft tissue mass of the right knee. It was a fluctuating, non-mobile mass without signs of redness or hyperemia, and was 5 cm in diameter. The mass was depicted as an irregular hyperechoic lesion with surrounding fluid collection by ultrasonography. Plain radiographs of the femur showed an osteolytic lesion with a pathologic fracture in the distal metaphysis. On MRI, the mass showed a low signal intensity on T1-weighted images and a high signal intensity on T2-weighted images, and extended to the extraosseous space with cyst formation.

**Results:** Radiological diagnosis was a Brodie abscess which is generally regarded as the result of an infection of a low-virulent organism. Finally, surgical drainage was performed and an acid-fast bacillus was identified in the specimen. Since interferon- $\gamma$  release assay (QuantiFERON<sup>®</sup>) was negative, we considered that the lesion was most likely due to vaccination of BCG given more than 14 months prior to presentation.

**Conclusions:** We also reviewed cases of BCG osteomyelitis presented in the Japanese literature, and stress that not only pediatricians but also pediatric surgeons should recognize, although rare, the presence of BCG osteomyelitis in children that may be encountered in daily practice.

**Abstract ID: 1144** Specific Field: **Paediatric Surgery**

**Mode of pres.: Poster Discussion**

**ISW 2011 Session 132.06**

**Role of interval appendectomy in pediatric patients with acute appendicitis with inflammatory mass or abscess: analysis based on histology of appendix and appendicolith formation**

S. Otake [1], A. Takahashi [1], N. Suzuki [2], F. Toki [2], A. Nishi [2], H. Yamamoto [2], M. Kuroiwa [2], H. Kuwano [1]

[1] Department of General Surgical Science, Gunma University, Graduate School of Medicine, Maebashi, Japan, [2] Department of Surgery, Gunma Children's Medical Center, Shibukawa, Japan

**Introduction:** To clarify the role of interval appendectomy (IA) in pediatric patients with acute appendicitis with appendiceal inflammatory mass or abscess after successful conservative management.

**Material and Methods:** We treated 355 consecutive patients with acute appendicitis during the past 24 years and reviewed the admission records of patients with appendiceal inflammatory mass or abscess who underwent routine IA after conservative management. We also examined the histology of the appendix taken at the IA. The relationships among clinical features, appendicolith formation, and histopathological findings were examined by multivariable analysis.

**Results:** (1) Forty-eight patients (13.5%) underwent conservative management. Four patients (8.3%) revealed recurrence of appendicitis or its complication before IA. One patient did not receive IA. The other 43 patients underwent routine IA after conservative management. (2) Twenty-two patients received laparoscopic IA, and there were no major complications related to it. (3) The main histopathological changes in the appendix were fibrosis, mucosal defect, and inflammatory reaction, and 58% of patients had strong histopathological changes. (4) In the multivariable analysis, the body temperature and leukocyte number at diagnosis were significant dependent factors to predict the degree of fibrosis. The body temperature at diagnosis was a dependent factor to predict appendicolith formation.

**Conclusions:** IA may be indicated for patients with strong inflammatory responses at the initial diagnosis because these patients may have strong histopathological changes and/or appendicolith in the appendix, which predict the recurrence of appendicitis. If IA is planned, laparoscopic appendectomy should be performed.

**Abstract ID: 1145** Specific Field: **Paediatric Surgery**

**Mode of pres.: Poster Discussion**

**ISW 2011 Session 132.07**

**Preperitoneal approach for retroperitoneal tumor**

K. Ise, M. Yamashita, H. Shimizu, S. Ishii, M. Gotoh

Fukushima Medical University, Fukushima, Japan

**Introduction:** Laparoscopic (LS) instead of transperitoneal approach (TP) is spreading as minimally invasive surgery for management of retroperitoneal tumor. Recently, we adapted preperitoneal approach (PP) without opening the peritoneum for biopsy or resection of retroperitoneal tumor. The cases undergoing three different approaches were retrospectively compared for their postoperative complications and invasiveness to patients.

**Material and Methods:** Between 1990 and 2010, there were 30 tumor biopsy performed in 28 patients and 64 tumor resection performed in 64 patients. A total of 30 tumors included TP ( $n = 14$ ), LS ( $n = 4$ ) and PP ( $n = 12$ ) for tumor biopsy. A total of 64 patients included TP ( $n = 42$ ), LS ( $n = 4$ ) and PP ( $n = 18$ ) for tumor resection. Operating time, blood loss, postoperative morbidity, initiation of oral feeding/postoperative chemotherapy were compared between the groups according to approach.

**Results:** For biopsy, operating time in PP group ( $116 \pm 23$  min) was significantly shorter than the LS group ( $145 \pm 44$  min). Oral feeding after biopsy was commenced earlier in LS group and PP group than in TP group. There were two ileus cases in TP group, but not in other groups. For resection, blood loss in LS ( $13 \pm 21$  g) was significantly low as compared with that in TP ( $205 \pm 172$  g) or PP ( $244 \pm 276$  g) group. Oral feeding was commenced earlier in LS group and PP group than in TP group. There were several morbidity including ileus (1), wound infection (1), drain infection (1) and incisional hernia (1) in TP group, but not in other groups. Initiation of oral feeding/postoperative chemotherapy in each group was TP:  $5.1 \pm 1.8$  day/ $15.7 \pm 6.0$  day, LS:  $1.5 \pm 0.5$  day/ $7.0 \pm 1.0$  day, PP:  $1.8 \pm 0.8$  day/ $16 \pm 10$  day, respectively.

**Conclusions:** PP has advantage over TP because of less morbidity associated with peritoneal incision and earlier recovery from operative invasiveness. The superiority of PP over LP needs to be further determined in prospective randomized study.

**Abstract ID: 1146** Specific Field: **Paediatric Surgery****Mode of pres.: Poster Discussion**  
**ISW 2011 Session 132.08****hepatoportal arteriovenous fistula in a 4 month old girl: a case report**

H. Tanaka, Y. Kitano, T. Kuroda

National Center for Child Health and Development, Tokyo, Japan

**Introduction:** Congenital hepatoportal arteriovenous fistula (HPAVF) presenting with heart failure has been rarely reported.**Material and Methods:** A 4 month-old girl with 21 trisomy, presenting with failure to thrive was found to have pulmonary hypertension and heart failure. Her initial chest X-ray revealed her cardiothoracic ratio (CTR) on admission was 73%. Abdominal doppler ultrasonographic examination revealed arterial waveform in the cavernous vessels in her hepatoduodenal ligament, leading to the huge fistula in the left hepatic lobe. Celiac and superior mesenteric angiogram showed multiple feeding arteries directing towards the huge fistula in her liver first and directly to the right atrium. She was diagnosed with congenital HPAVF. Cardiac catheterization revealed mean pulmonary arterial pressure (mPA) to be 54 mmHg. The excessive flow to the heart through the fistula was considered to cause the pulmonary hypertension and heart failure. Radiological intervention to the fistula was not possible because of the multiple feeding arteries. Since the infant was hemodynamically unstable, we decided to perform two-staged operation on her.**Results:** In the first operation, the multiple feeding arteries were ligated to reduce the shunt flow directing to the heart to treat the heart failure. CTR decreased to 47% and the mPA decreased to 43 mmHg in the cardiac catheterization one month after the first operation. The intrahepatic fistula also decreased in size, but still there was considerable flow in the shunt. The extended left lateral segmentectomy was performed to excise the intrahepatic fistula completely 3 months after the first operation. The pathology of the resected liver showed a thickened wall of the dilated shunt vessel and absence of portal veins in some peripheral portal triads. She developed refractory ascites and esophageal varices due to portal hypertension thereafter, which have been treated with diuretics and endoscopic management, respectively. She has been well for 3 years except for malnourishment and recurrent intestinal bleeding.**Conclusions:** The two-staged operation seems clinically relevant to treat the HPAVF with heart failure. The remnant liver may also have congenital absence of portal veins in peripheral portal triads, and this explains the development of the portal hypertension after the hepatectomy.**Abstract ID: 1147** Specific Field: **Paediatric Surgery****Mode of pres.: Poster Exhibition only**  
**ISW 2011 Session PE 453****Rhabdomyosarcoma arising in a giant congenital melanocytic nevus: case report**S. Furuta [1], W. Munechika [1], H. Shima [1], T. Aoba [1],  
A. Kinoshita [2], K. Kondoh [2], M. Takagi [3], H. Kitagawa [1]

[1] St. Marianna University School of Medicine, Division of Pediatric Surgery, Kawasaki, Japan, [2] St. Marianna University School of Medicine, Division of Pediatrics, Kawasaki, Japan, [3] St. Marianna University School of Medicine, Division of Pathology, Kawasaki, Japan

**Introduction:** A variety of malignancies have been reported to arise within congenital melanocytic nevus (CMN), most commonly malignant melanoma, but rarely rhabdomyosarcoma, liposarcoma, and malignant peripheral nerve sheath tumors also. There are five cases of rhabdomyosarcoma (RMS) originating from a CMN in the literature.**Material and Methods:** A 7-month-old boy, was born with a pigmented nevus extending from his lower back onto right inguinoscrotal region, presented with a large, hard, subcutaneous nodule that rapidly developed within a congenital melanocytic nevus (CMN) on his lower back and para-testicular regions.**Results:** Surgical biopsies were taken from his right back and right inguinal masses including the CMN. Embryonal rhabdomyosarcoma (RMS) was found in the right inguinal region. Intensive chemotherapy (VAC: 50% dose of intermediate risk protocol of Japanese RMS Study Group) was started. One week later, he developed hypovolemic shock due to tumor rupture. He was salvaged by emergency transarterial embolization. Six months after this treatment the tumor ruptured again and the tumor was re-embolized and excised together with his genitalia. Complete excision was obtained with cystostomy and urethrostomy. The patient then underwent radiation therapy (50.4 Gy) and postoperative chemotherapy (ICE). He is disease free at 6 months. Histological examination showed a lesion with two distinct components. There was a proliferation of blue cells within a fibromyxoid stroma, with spindled neoplastic cells some of which abundant eosinophilic globular cytoplasm with occasional cross-striations characteristic of rhabdomyoblasts. They expressed desmin and myoglobin and were negative for S-100 protein and HMB-45. The RMS tumor merged and overlapped with an adjacent congenital melanocytic nevus.**Conclusions:** The finding of both rhabdomyoblastic and melanocytic differentiation within the same lesion suggests their derivation from common pluripotential stem cells or neural crest cells. We conclude that patients with a giant nevus require close observation and a biopsy when any change is noticed. This is the sixth case in the literature.**Abstract ID: 1148** Specific Field: **Paediatric Surgery****Mode of pres.: Poster Exhibition only**  
**ISW 2011 Session PE 454****Application of high dose rate <sup>60</sup>Co remote after loading system for local recurrent neuroblastoma**T. Furuya, K. Sugito, A. Soga, H. Kaneda, K. Ohashi, M. Inoue,  
T. Ikeda, T. Koshinaga

Nihon University, Tokyo, Japan

**Introduction:** Remote After Loading System (RALS) treatment is brachytherapy using the source of the high dose rate (HDR), and it is a method to send source into patient body by remote control. RALS treatment can correctly deliver large amount of radiation to cancer and minimize the amount of normal tissue exposed to irradiation, and its usefulness has been reported in adult malignant tumor. However, there is no report in pediatric solid tumors. Here, we report the first case of using HDR-<sup>60</sup>Co- RALS treatment for abdominal local recurrent neuroblastoma (NB) arising from right upper retroperitoneum.**Material and Methods:** A 20-month-old boy was referred to our hospital due to abdominal distention. Physical examination and following abdominal ultrasonography (US) and computed tomography (CT) confirmed a solid mass in right upper abdomen. After an open



biopsy, he was diagnosed stage 4 NB originating in right adrenal gland with metastasis of the bone and bone marrow. He received induction chemotherapy, high-dose chemotherapy (HDC) with peripheral blood stem cell transplantation (PBSCT), complete gross total tumor resection, and external beam radiation therapy (EBRT) against final shrunk tumor fields and regional lymph nodes area. After intensive therapies, he had discharged with complete remission (CR). Over 5 months' CR after primary treatment, the tumor makers were elevated, and abdominal magnetic resonance imaging (MRI) confirmed a solid mass in the primary tumor fields, which was outside right hepatic lobe through right upper retroperitoneum. This field was outside of the EBRT fields.

**Results:** We performed open biopsy, and obtained diagnosis of recurrent NB without distant metastasis. After induction chemotherapy and PBSCT, we performed tumor resection and inserted four catheters to use as applicators for irradiation. The total dose of 16 Gy was postoperatively given for three days. After RALS, he received cord blood cell transplantation (CBSCT), and had discharged with second CR. He has remained well to date, and NB re-recurrence-free for one year.

**Conclusions:** A case of NB treated with HDR-<sup>60</sup>Co-RALS proved the effectiveness and safety of the modality. More experience with additional case is desired to further establish the treatment protocol and efficacy of intra-abdominally irradiation for NB patients.

**Abstract ID: 1149** Specific Field: **Paediatric Surgery**

**Mode of pres.: Poster Exhibition only**  
ISW 2011 Session PE 455

**RAMP1 essentialize protect roles for mouse DSS-induced colitis: implications of effect of CGRP via TRPV1 in inflammatory bowel disease**

N. Kawashima-Takeda [1], K. Tanaka [2], M. Watanabe [2], M. Majima [3]

[1] National Center for Child Health and Development, Surgical Specialties, Tokyo, Japan, [2] Kitasato University School of Medicine, Dept. of Surgery, Kanagawa, Japan, [3] Kitasato University School of Medicine, Dept. of Pharmacology, Kanagawa, Japan

**Introduction:** Growing evidence suggests a involvement extrinsic sensory neurons in the aberrant immune response in colitis. Activated sensory neurons release the calcitonin gene-related peptide (CGRP), be involved in the modulation of intestinal motility. A receptor activity-modifying protein (RAMP) 1 composes the CGRP<sub>1</sub> and CGRP<sub>2</sub> receptor with a calcitonin receptor- like receptor (CRLR) or a calcitonin receptor 2 (CTR2). The physiological functions of CGRP that are mediated through the CGRP<sub>1</sub> and the CGRP<sub>2</sub> receptors remain to be clarified.

**Material and Methods:** The roles of CGRP during experimental colitis in the mouse was showed by the CGRP receptor antagonists (CGRP<sub>8-37</sub>, 3 μg/h continuous subcutaneous infusion) which inhibits the CGRP<sub>1</sub> receptor, mutant mice lacking RAMP1. The colitis was induced by adding 1% of dextran sodium sulfate (DSS) to the drinking water. The severity of inflammation increased markedly after 7 days in the CGRP<sub>8-37</sub> group and the RAMP1(−/−) group compared with the vehicle as determined by the scoring parameters.

**Results:** Body weight loss ratio ( $3.252 \pm 1.761$ ,  $17.758 \pm 10.644$  vs.  $0.400 \pm 0.693$ ), stool consistency (diarrhea, diarrhea vs. loose),

bleeding (mild, gross vs. slightly), hematocrit change (%) ( $-12.400 \pm 1.517$ ,  $-13.400 \pm 4.099$  vs.  $-5.800 \pm 1.924$ ), colon length ( $5.000 \pm 0.354$ ,  $4.800 \pm 0.274$  vs.  $5.540 \pm 0.288$ ), pathological grade ( $1.800 \pm 0.274$ ,  $2.000 \pm 0.000$  vs.  $0.900 \pm 0.224$ ), level of cytokine TNFα ( $4.578 \pm 1.037$ ,  $7.645 \pm 2.304$  vs.  $3.063 \pm 1.186$ ) and IL-1β ( $7.630 \pm 2.020$ ,  $13.964 \pm 1.623$  vs.  $1.835 \pm 0.581$ ). The RAMP1(−/−) group presented severity of colitis compared with CGRP<sub>8-37</sub> group, which data suggest that CGRP exerts mucosal protection, and that both of CGRP<sub>1</sub> and CGRP<sub>2</sub> receptor play a protective role in the colitis. In additional experimentation of isoforms of CGRP, the αCGRP(−/−) group did not significantly alter the severity of colitis compared with vehicle. This data suggest that βCGRP play a protective role in the colitis

**Conclusions:** Extrinsic sensory neurons express the irritant receptors a transient receptor potential vanilloid type 1 (TRPV1) and release the CGRP. Irritant TRPV1 on nociceptive sensory neurons by a vanilloid as a capsaicin have implications of effects in treating the experimental colitis. These finding highlight a new role of sensory neurons via TRPV1 with vanilloids in chronic intestinal inflammation and suggest the new treats for IBD.

**Abstract ID: 1150** Specific Field: **Paediatric Surgery**

**Mode of pres.: Poster Exhibition only**  
ISW 2011 Session PE 456

**Fulminant omphalitis progressing to necrotizing fasciitis: a case series and treatment algorithm**

S.M. Siddiqui, D.M. Alterman, A.P. Kennedy, C.A. Angel

University of Tennessee, Knoxville, USA

**Introduction:** Our objectives are to describe our recent experience with omphalitis progressing to necrotizing fasciitis, provide a review of the literature of this disease, and to offer a proposal for an omphalitis diagnostic algorithm for this highly morbid disease.

**Material and Methods:** We report five recent cases of neonatal omphalitis that progressed to fatal NF with only two survivors. We also provide a review of literature that summarizes data from 310 cases of omphalitis treated in a hospital setting.

**Results:**

Our five recent patients with omphalitis that progressed to necrotizing fasciitis presented with sepsis and expired despite surgical debridement and broad spectrum antibiotic therapy. We summarize data from 310 cases of omphalitis treated in a hospital setting. Progression to NF was 17.4% (54/310). Overall mortality of omphalitis was 13.9% (43/310) and of those who progressed to NF 79.6% (43/54) died. Several risk factors have been identified that may predict progression to NF. The cluster of induration, tachycardia, and white blood cell count greater than twenty thousand are markers of complicated omphalitis. The appearance of coagulopathy or thrombocytopenia is concerning for progression to severe sepsis and NF.

**Conclusions:** Treatment goals for NF include aggressive surgical debridement, broad spectrum antibiotic coverage, hemodynamic and nutritional support. Delay of operation for more than 24 h has been associated with almost double the mortality rate. Given the time dependency in treatment success in this unique population, an algorithm which allows rapid identification of complicated omphalitis is indicated.

**Abstract ID: 1151** Specific Field: **Paediatric Surgery**

**Mode of pres.: Poster Exhibition only**  
**ISW 2011 Session PE 457**

**Extended perineal anorectoplasty to avoid damaging the rectal branch of pelvic plexus of imperforate anus with rectoprostatic urethral fistula**

M. Kohno, H. Ikawa, H. Masuyama, T. Oshikiri, Y. Yasui, S. Takahashi, T. Kuwahara

Kanazawa Medical University, Japan

**Introduction:** Although posterior sagittal anorectoplasty (PSARP) for anorectal malformation is an accepted procedure for most pediatric surgeons, the occurrence of constipation after PSARP is the one of the frequent patient complaints. Constipation after PSARP may be caused by a disturbance in the colonic motility due to damage to the rectal branch of the pelvic plexus during surgery. For cases of intermediate and high type imperforate anus, we therefore mainly perform extended perineal anorectoplasty (EPARP) in order to avoid damaging the rectal branch of the pelvic plexus. We conducted clinical and objective assessments to investigate and compare postoperative bowel function in this and other surgical procedures for rectoprostatic urethral fistula.

**Material and Methods:** The subjects comprised 14 cases of rectourethral fistula aged 5 years old or older, excluding cases of lost follow-up, delayed mental development, and spina bifida. The surgical procedure involved an abdominoperineal pull-through (APPT) in 4 cases, abdominosacroperineal pull-through in 1 case, a sacroperineal approach (SPA) in 3 cases, and EPARP in 6 cases. In order to assess postoperative bowel function, we performed clinical evaluations at the age of 5 years, performed objective MRI assessments, Barium enema, and anorectal manometry.

**Results:** Assessments were successfully conducted for 3 cases of APPT, 3 cases of SPA, and 6 cases of EPARP. The mean CS at the age of 5 was 1.8 in the cases of APPT, 4.0 in the cases of SPA, and 4.8 in the cases of EPARP. In the contrast enema, leakage of the contrast agent was observed in all cases of APPT. Leakage was observed in 1 case of SPA. No instances of leakage were observed in the cases of EPARP. Rectoanal reflex was positive in 1 out of 3 cases of APPT, 2 out of 3 cases of SPA, and 5 out of 6 cases of EPARP. The mean resting anal pressure was 13.7 cm H<sub>2</sub>O in the cases of APPT, 50.0 cm H<sub>2</sub>O in the cases of SPA, and 58.8 cm H<sub>2</sub>O in the cases of EPARP.

**Conclusions:** In the clinical and objective assessments, the outcome was best in the cases undergoing EPARP, and it is showed that this surgical procedure is therefore a useful surgical procedure for treating rectoprostatic urethral fistula.

**Abstract ID: 1152** Specific Field: **Paediatric Surgery**

**Mode of pres.: Poster Exhibition only**  
**ISW 2011 Session PE 458**

**Pitfalls in antenatal diagnosis of ovarian cysts**

T. Shinkai, H. Komuro, Y. Urita, J. Fujishiro, C. Goto, N. Hoshino, K. Ono

University of Tsukuba, Tsukuba, Japan

**Introduction:** Over the last two decades, the widespread application and advances in fetal imaging have led to remarkable increase in antenatal detection of congenital malformations. Fetal abdominal

cysts, especially fetal ovarian cysts, most commonly detected on antenatal ultrasound examination, are challenging in accurate antenatal diagnosis, which is important for appropriate postnatal management of the cystic lesions. The aim of this study is to evaluate the accuracy of antenatal diagnosis ovarian cysts.

**Material and Methods:** We retrospectively reviewed the charts of patients diagnosed antenatally with ovarian cysts from 2001 to 2010 in our institute. Analyses were made of the collected data including the gestational age at diagnosis, the number and the types of cysts, the postnatal diagnosis, and the clinical outcomes.

**Results:** Fetal ovarian cysts were diagnosed in twenty-two fetuses, and all of which were unilateral. The mean gestational age at diagnosis was 31.3 weeks (range 23–39 weeks). Simple ovarian cysts were found in 16 fetuses, and complex cysts were found in 6 fetuses. Three simple ovarian cysts were disappeared antenatally. Postnatal findings confirmed that 13 cysts were ovarian with the correct diagnosis and that the diagnosis was incorrect for the remaining 6 cysts. The final diagnosis of these six cysts were ovarian mature teratoma, left adrenal neuroblastoma, retroperitoneal lymphangioma, duodenal stenosis, left hydronephrosis, and vaginal atresia, respectively. The accuracy of antenatal diagnosis of ovarian cysts was 68.4% (13/19). Four of 13 ovarian cysts required postnatal surgical intervention. Other nine cysts were followed-up conservatively and all the cysts were disappeared 8.9 month (range 2–30 months) after birth. The mature ovarian teratoma was removed at 10 days after birth. The left adrenal neuroblastoma was observed following a tumor biopsy at 10 month of age. The retroperitoneal lymphangioma and duodenal stenosis were treated conservatively. The left hydronephrosis eventually required by left nephrectomy at 11 month of age. The vaginal atresia was treated with a surgical unroofing.

**Conclusions:** Our experiences have demonstrated that there is a notable discrepancy between antenatal diagnosis of ovarian cysts and their actual diagnosis. Careful postnatal assessment of antenatally diagnosed ovarian cysts is mandatory.

**Abstract ID: 1153** Specific Field: **Paediatric Surgery**

**Mode of pres.: Poster Exhibition only**  
**ISW 2011 Session PE 459**

**Operative management of blunt pancreatic trauma in children**

K. Maeda, Y. Tazuke, T. Yanagisawa, K. Baba

Jichi Medical University, Shimotsuke, Tochigi, Japan

**Introduction:** Blunt abdominal trauma is the most common cause of pancreatic injury in children. Although in adults the surgical management of AATS grade III

**Material and Methods:** The case records of two children (2 male, 12-year-old and 6-year-old) treated for blunt pancreatic injury (AATS grade III) in our department were reviewed.

**Results:** The treatment modalities were selected according to the grade of the pancreatic injury, hemodynamic status and associated injuries. Two patients underwent successful diagnostic endoscopic retrograde cholangiopancreatography (ERCP) in which duct injury was identified. In all two patients, pancreatic pseudocysts arose within 3 or 4 weeks after the injury. Following open drainage of pseudocysts, operative management was considered. After ENPD under ERCP, the patients underwent successful end-to-end anastomosis of disrupted pancreatic duct. Postoperative courses were uneventful.

**Conclusions:** The status of the main pancreatic duct and the location of the pancreatic injury constitute the basis of the AAST scoring system may serve as a useful diagnostic modality for guiding operative management decisions. ERCP is fundamental for exact

diagnosis. End-to-end anastomosis of disrupted pancreatic duct combined with ENPD under ERCP is useful surgical procedure to avoid the distal pancreatectomy in children.

**Abstract ID: 1154** Specific Field: **Paediatric Surgery**

**Mode of pres.: Poster Exhibition only**  
**ISW 2011 Session PE 460**

**Gaining Sensation at defecation after in two-flap anoplasty for mucosal prolapse following anorectoplasty**

H. Sato, H. Kitagawa

St. Marianna University School of Medicine, Kawasaki, Japan

**Introduction:** The symptoms of soiling and staining sometimes occur following anorectoplasty for anorectal malformation due to the complication of mucosal prolapse. The major cause of mucosal prolapse is considered to be the direct anastomosis of the colon to the perineal skin causing a “flat anus”. Physiologically, from the anal verge to the upper part of the anal canal there is somatic sensation that enables sampling to distinguish between faeces or gas. In patients with a flat anus, the lack of this somatic sensation may partly explain the soiling. In 1982 Millard et al reported the Two-flap anoplasty that creates an anal canal using two perineal pedicle skin flaps to form a “deep anus”. It is considered this deep anus provides a normal sensation at defecation for these patients. We have used this procedure for mucosal prolapse since 1990. The aim of this study was to evaluate the long-term benefits for this procedure.

**Material and Methods:** From 1990 to 2010, the long term clinical follow-up (maximum of 21 years) was done by the review of medical records against 1) the occurrence of preoperative symptoms after the procedure, 2) the gaining of sensation at defecation for 14 patients suffering mucosal prolapse following anorectoplasty for high imperforate anus which were treated using a two-flap anoplasty (TFARP).

**Results:** Of the 14 patients 6 presented with simple mucosal prolapse, 2 with bleeding, 3 with staining, 2 with soiling, and 1 with pain. During the maximum 21 years follow up, there were no recurrences and their preoperative symptoms resolved completely after procedure. Furthermore, 3 patients gained sensation prior to defaecation. Two of them received the TFARP at over 10 years old after suffering soiling and staining since their pull-through, but the other one received the TFARP at 1 year old because of constipation associated with a neurogenic bladder.

**Conclusions:** Although It is depends on the patient’s subjectivity, the advantages of this procedure were provision of the possibility of gaining sensate defaecation, possibly because the skin flap around the anus might help develop sensation. Moreover, there were no recurrences and complete resolution of the preoperative symptoms in the long term after this procedure.

**Abstract ID: 1155** Specific Field: **Paediatric Surgery**

**Mode of pres.: Poster Exhibition only**  
**ISW 2011 Session PE 461**

**Fetal lung interstitial tumor (FLIT): a case in Japanese newborn boy**

T. Onoda [1], T. Emura [2], H. Ota [2], N. Kato [3], H. Ohizumi [2], A. Hill [4], K. Hayasaka [1], M. Sadahiro [2]

[1] Department of Pediatrics, Yamagata University School of Medicine, Yamagata, Japan, [2] Department of 2nd Surgery, Yamagata University School of Medicine, Yamagata, Japan, [3] Department of Pathology, Yamagata University School of Medicine, Yamagata, Japan, [4] Division of Pathology, Children’s National Medical Center, Washington DC, USA

**Introduction:** Recently, fetal lung interstitial tumor (FLIT) was proposed as a new pathological concept of lung tumor of infancy. It is known as a differential diagnosis for congenital pulmonary lesions. The clinical courses vary, concerning its malignancy, FLIT is distinguishable from the lung mass as represented by pleuropulmonary blastoma (PPB) or congenital peribronchial myofibroblastic tumor (CPMT). Here we first report a case diagnosed as FLIT in Japanese newborn boy.

The patient was born at term and presented mild apnea at birth. The chest X-ray showed the tumor located at the left lower lobe without atelectasis. Contrast enhanced MRI revealed a solid mass (25 × 18 × 26 mm) with some cystic components in left thoracic cavity as representing iso in T1-WI and high signal intensity in T2-WI, FLAIR and Diffusion-WI. Blood or biochemistry data were normal and no tumor marker elevations including urinary VMA, HVA and NSE were found. The wedge resection with negative margins was carried out at 11 days of age. Macroscopically, tumor was surrounded by supportive normal lung tissue and did not involve the chest wall. In the pathology report, the tumor was not cystic, but a little mucoid, and discretely progressed mesenchymal cells occupied preferentially with epithelial cell lining. Immunohistochemically, tumor had 2 major components. One was epithelial cell dominant and positive for Cytokeratin (CAM5.2, AE1/AE3), EMA, TTF-1 and SP-A suggesting the differentiated pulmonary epithelial cells. The other was unepithelial cell dominant and positive for Vimentine. Neither rhabdomyosarcomatous nor cartilaginous components were found in it. Basically 1–2% (and 20% in some parts) of the tumor cells were Ki-67 positive. Some tumor cells revealed 46XY, t(2;12) (p23;p13). He is now in good condition with a half year disease free interval without any adjuvant chemotherapy, and no signs of recurrence were identified by follow up contrast enhanced CT.

Thus, congenital lung lesions include lung tumors, especially PPB is thought to be malignant and ordinary composed of poorly differentiated blastomatous cells. So far, lung tumor as represented by FLIT was categorized in subtype of classical PPB, however, due to its differences in clinical and pathological features, it is supposed to be important to diagnose exactly to avoid the overtreatment in this neonatal period.

**Abstract ID: 1156** Specific Field: **Stomach/Duodenum**

**Mode of pres.: Free Paper**  
**ISW 2011 Session 103.10**

**Analysis of prognostic factors in hepatic resection of metastatic gastric cancer**

D.S. Han [1], S.Y. Oh [1], T.K. Yoo [1], M.J. Kim [1], H.J. Lee [2], W.H. Kim [3], K.U. Lee [1], H.K. Yang [2]

[1] Department of Surgery, Seoul National University College of Medicine, Seoul, Korea, Republic of, [2] Department of Surgery and Cancer Research Institute, Seoul National University College of Medicine, Seoul, Korea, Republic of, [3] Department of Pathology, Seoul National University College of Medicine, Seoul, Korea, Republic of

**Introduction:** The aim of this study is to analyze the prognostic factors and determine the indications of hepatic resection in gastric cancer with liver metastasis.

**Material and Methods:** Forty three patients underwent a hepatic resection for gastric cancer with liver metastasis at the Seoul National University Hospital from Jan, 1986 to Dec, 2009. Resectable primary lesion and no other distant metastasis were the candidates for hepatectomy.

**Results:** Thirty four patients had synchronous liver metastasis and 9 patients had metachronous liver metastasis. Post-operative morbidity and mortality rate were 32.7% and 0%. The median survival time and overall 5-year survival rate were 14 months and 14.6%. In multivariate analysis, variables associated with overall survival were N0 ~2 (TNM/AJCC 7th) of primary lesion and chemotherapy. Variables associated with disease-free survival were unilobar metastasis and N0 ~2. Favorable indications in synchronous metastasis were unilobar metastasis and clinical lymph node negative. The median survival time and 5-year survival rate in this group were 37.2 months and 42.9%. In metachronous metastasis, patients of unilobar metastasis and time to metachronous metastasis 1-year showed 15.6 months of median survival and 33.3% of 5-year survival rate.

**Conclusions:** Although the number of cases is limited, hepatic resection can be done with acceptable morbidity and mortality. The overall survival in this study was dismal. But in selected patients with suggested indications, hepatic resection in gastric cancer with liver metastasis showed favorable outcome.

**Abstract ID: 1157**      Specific Field: **Colon and Rectum**

**Mode of pres.: Poster Exhibition only**  
**ISW 2011 Session PE 462**

**Defining an optimal surgical strategy for colorectal liver metastasis: staged or synchronous resection%3F**

W.H. She, A.C.Y. Chan, T.P. Poon

Queen Mary Hospital, The University of Hong Kong, Hong Kong, China, People's Republic

**Introduction:** There is yet consensus on the best surgical strategy to deal with resectable synchronous colorectal liver metastasis. Our aim was to assess if synchronous resection confers any survival benefit in comparison with staged resection of colorectal liver metastasis

**Material and Methods:** From January 1990 to December 2008, 116 patients with synchronous colorectal liver metastasis received surgical treatments in the Department of Surgery, Queen Mary Hospital. Among these 116 patients, 88 of them underwent staged resections of colorectal cancer and liver metastasis (Group I), whilst the remaining 28 patients underwent synchronous resections (Group II). Patient characteristics, clinicopathological data, and perioperative outcomes were reviewed.

**Results:** There were no significant differences in terms of patient and tumor characteristics between the two groups. Major hepatectomy was performed in 54 patients (61%) in Group I and 12 patients (43%) in Group II ( $P = 0.09$ ). The median blood loss (0.7 l vs. 0.8 l) was similar between the two groups but the operative morbidity (15.9% vs 25.0%) and mortality (1.1% vs 7.1%) rate tend to be higher in Group II, although

it did not reach statistical significance. Nonetheless, the total length of hospital stay was shorter in Group II patients (18.0 vs. 11.5 days,  $P = 0.009$ ). The 1-, 3- and 5-year overall survival rates for Group I were 90.7%, 47.1% and 33.3% respectively, and the corresponding survival rates for Group II were 75.0%, 25.0% and 0% respectively ( $P = 0.003$ ).

**Conclusions:** A staged resection approach seems to offer better oncological outcome than synchronous resections. Our result in staged resection is comparable to others' reports. Further studies are required to identify a subgroup of patients with more favorable tumor biology that could benefit from synchronous resection.

**Abstract ID: 1158**      Specific Field: **Breast Surgery**

**Mode of pres.: Poster Exhibition only**  
**ISW 2011 Session PE 463**

**Ultrasound features of breast cancer in Asian women**

W.H. She [1], P.S.Y. Cheung [2], S.S.S. Lau [2]

[1] Queen Mary Hospital, The University of Hong Kong, Hong Kong, China, People's Republic, [2] Breast Care Centre, Hong Kong Sanatorium & Hospital, Hong Kong, China, People's Republic

**Introduction:** Ultrasound has been used as an important modality in evaluation of the breast in both screening and diagnostic procedure. We aim to identify the most useful feature seen in ultrasound for diagnosis of breast cancer.

**Material and Methods:** From February 2009 to August, 2010, 934 patients were diagnosed to have carcinoma of breasts in the Breast care centre, Hong Kong Sanatorium & Hospital (HKSH). Among these patients, 358 were operated by one single breast surgeon. Ultrasound was used as one of the investigations and it was used by the surgeon pre or intra-operatively. All the specimens were examined by a designated experienced pathologist. Patients' characteristics, ultrasound features and the histopathology of the lesions were reviewed.

**Results:** Total 780 patients had ultrasound examination of the breast either pre or intra-operatively. The diagnosis of breast cancer was confirmed in 320 patients by ultrasound with an accuracy of 83.5%. Ultrasound was not diagnostic in 53 patients in which they showed either false positive and false negative results. Specific features of breast cancers including the shadow, homogeneity, shape, margin and posterior wall changes were studied with different pathologies and tumor grading. Tumor pathologies were categorized into invasive ductal, invasive lobular and tubular/papillary/mucinous carcinoma. Individual's ultrasound examinations reviewed that tubular/papillary/mucinous carcinoma had higher probability of posterior wall enhancement ( $P < 0.005$ ); while increasing tumor grading had higher probability of being flat in shape ( $P = 0.04$ ).

**Conclusions:** Ultrasound is an important modality in evaluating breast cancer. Accurate interpretation of the ultrasound is utmost important in making correct diagnosis. Hypoechoic lesion, irregular margin and heterogeneity are useful, though not statistically significant, ultrasound features for suspicious lesion. Tubular/papillary/mucinous carcinoma had higher probability of posterior wall enhancement, while increasing tumor grading had higher probability of being flat in shape.



Disclaimer: The information in this Abstract Book shows the abstracts as submitted by the authors. The International Society of Surgery and the Congress Organization do not take any responsibility for the contents of the submitted work.

Index of Presenting, First and Second Authors of the Abstracts for Free Paper, Poster and Video Sessions The abstracts are printed as submitted and accepted for presentation at International Surgical Week ISW 2011 in Yokohama, Japan, August 28 - September 1, 2011.

Name	Abstract ID	Name	Abstract ID	Name	Abstract ID
Abdollahi, A.	1039	Al Dumour, A.	1092	Arima, N.	1051
Abdujapparov, S.B.	0302	Al Ani, A.	0232	Arita, S.	0623
Abe, H.	0253, 1061	Al Ani, A.H.	1092	Arita, T.	0518
Abe, N.	0077, 0832	Al Ani, K.	0232	Arkadopoulos, N.	0555
Abe, Y.	0548, 0615	Al Breizat, A.H.	1092	Arnesson, L.-G.	1012
Abel, F.	0885	Al-Ani, A.	0107	Asadi, M.	0223, 0653
Adimulam, G.	1035	Al-Ani, Q.	1066	Asaga, S.	1064
Adisa, A.O.	0090	Al-Ani, Q.S.M.	0544, 0603, 0793	Asahara, F.	0415
Adolf, D.	0201	Al-Sabah, S.	0212, 0313	Asai, K.	0702
Agarwal, A.	0865	Al-Thani, H.	0170	Asakage, N.	0483
Agarwal, G.	1005	Alatise, O.	0090	Asakuma, M.	0032, 0546
Agarwal, S.	0865	Alesina, P.F.	0864	Asakura, T.	0576, 0640
Aggrawal, N.	1036	Alex, G.	0901	Asami, S.	0060, 0484, 0835
Aguilar-Nascimento, J.E.	1083	Aliakbarian, M.	0223, 0247	Ashrafi, A.N.	0163, 0359
Ahlman, H.	0109, 0921	Alkire, B.	0237	Asomah, F.K.	0238
Aiboshi, J.	0937	Allerdice-Snedden, J.	1124	Aung, M.O.	0257
Aikawa, M.	0065, 0818	Alterman, D.M.	1150	Awad, Z.T.	0629
Aikou, S.	0776, 0794	Amano, K.	0283	Azuma, T.	0108, 0756
Aiura, K.	0137	Amano, S.	0130, 1057, 1058	Azumi, T.	0998
Akabori, H.	0100	Amemiya, T.	0826	Baatjes, K.	1000
Akagi, Y.	0378, 0422, 0434	An, W.	0009	Baatjes, K.J.	1029
Akahoshi, T.	0013	Anderson, F.	0649	Baba, H.	0249, 0316, 0457, 0462, 0495, 0569, 0573, 0580, 0586, 0616, 0654, 0658, 0780
Akai, R.	0309	Ando, J.	0423	Baba, S.	0390
Akamatsu, H.	0017, 0543, 0632	Ando, N.	0415, 0695, 1023	Baba, Y.	0462
Akaraviputh, T.	0222, 0312, 0485, 0578	Ando, T.	0116	Baking, S.T.A.	1067, 1068, 1069, 1070
Akari, I.	0249	Andrews, E.J.	0269	Balalaa, N.	0022
Akasu, T.	0308	Angel, C.A.	1150	Balogh, Z.	0957
Akatsu, T.	0038	Annerbo, M.	0909	Balogh, Z.J.	0951
Akbarov, E.T.	0302	Aoki, M.	0672, 0826, 0840	Bando, E.	0006, 0744, 0766, 0777
Akerström, G.	0853	Aoki, T.	0560	Bando, H.	0087, 0274, 0332
Akiharu, K.	0443	Aoyagi, K.	0749, 0833, 0843	Barczynski, M.	0854, 0923
Akimoto, E.	1018	Aoyama, T.	0747	Barry, R.	0638
Akira, T.	0747	Apffelstaedt, J.P.	1000, 1075, 1029	Baschera, D.	0235
Akiyama, G.	0018	Appasamy, V.	0989	Baumann, A.	0192, 0193, 0940
Akiyoshi, T.	0385	Arai, K.	0894		
Akutsu, Y.	0498, 0499, 0536, 0537	Arakawa, S.	0116		
		Aramaki, T.	0478		
		Ariake, K.	0915		
		Arigami, T.	0129, 0757		

Name	Abstract ID	Name	Abstract ID	Name	Abstract ID
Baumann, G	0192	Chen, T.L.	0220, 0949	Deo, S.V.S.	1033
Bautz, P.	0979	Cheng, S.B.	0550	Devaud, M.	0954
Baxi, J.	1032	Cheng, S.P.	0859	Dhar, A.	0190, 1034, 1035
Baxi, M.	1032	Cheung, C.	0995	Di Saverio, S.	0227, 0972
Becker, H.P.	1106	Cheung, P.	0995	Dias, V.	0269
Bejrananda, T.	0265	Cheung, P.S.Y.	1014, 1158	Dinets, A.	0917
Bekku, E.	0478	Cheung, Y.S.	0315	Djurisic, I.	0918
Beliard, A.	0883	Chichom Mefire, A.	0167, 0988	Doherty, G.M.	0863, 0886
Bellantone, R.	0868, 0889	Chijiwa, K.	0097, 0102, 0365, 0622	Doi, K.	0693, 0731
Benn, C.A.	1011, 1027	Chikamoto, A.	0586	Doi, T.	1120
Beppu, T.	0580, 0586, 0616	Chinswangwatanakul, V.	0485	Doki, Y.	0459, 0753
Bernardi, S.	0997, 1017, 1040	Chinswangwatanakul, V.I.	0312	Dong, J.	0559, 0566
Bertelson, N.L.	0263	Chiotasso, P.	0248, 0768	Dunn, E.	0944
Bertocco Meirelles, M.	1083	Chishima, T.	1041	Dzodic, R.	0857, 0918, 0919
Bertozzi, S.	0997, 1017, 1040	Chiu, M.T.	0956, 0985, 0986, 0989, 0990	Ebihara, Y.	0813
Bicudo-Salomao, A.	1083	Cho, D.H.	0924	Edwards, G.R.	1011, 1027
Bohner, C.	0023	Chong, C.-S.	0188	Efron, D.	0941, 0975
Boland, J.P.	0961	Chong, C.S.	0241	Egawa, S.	0541
Boonpipattanapong, T.	0265	Chooklin, S.	0729	Eguchi, S.	1130
Borel Rinkes, I.H.M.	0881	Chu, T.W.	1015	Eigo, O.	0703
Botsios, D.	0229, 0267	Chun, K.W.	0934	Elf, A.K.	0921
Bowyer, M.	1113	Chung, C.C.	0315	Emura, T.	1155
Bradshaw, A.	0769	Chung, W.Y.	0899, 0927	Endo, I.	0003, 0008, 0285, 0307, 0633, 0668, 0841, 1041
Braghetto, I.	0470	Chuthapisith, S.	1076	Endo, S.	0275, 0372, 0392, 0433
Branco, B.	0947	Cipolla, J.	0969	Endo, T.	0309
Brand, M.	0792	Civil, I.	0954	Endo, Y.	0413
Brauckhoff, M.	0892	Clark, D.E.	0966	Enokido, K.	1055
Briezat, A.B.	0544	Clifton-Bligh, R.J.	0922	Enomoto, K.	0130, 0858, 0920, 1057, 1058
Briezat, A.S.	0603	Co, M.	1004	Enomoto, T.	0349, 0640
Brusov, P.G.	1108	Cohnert, T.	0192	Enomoto, Y.	0858
Buchel, O.	0638	Cohnert, T.U.	0193, 0940	Ericzon, B.G.	0179
Burusapat, C.	0146	Comfort, P.	1120	Erkol, H.	0706, 0733
Buta, M.	0857, 0919	Cornwell, E.	0975	Eslick, G.D.	0295, 0959
Campos, A.A.	0200	Cox, M.R.	0295	Favara, D.M.	0171
Carlander, J.	0861	Cox, M.R.	0959	Feliciano, D.V.	1114
Carling, T.	0860	D'Souza, R.B.	0959	Fenton-Lee, D.	0539
Carnaille, B.	0870	Darzi, A.	1082	Ferko, A.	0547, 0608
Cecka, F.	0547	Davenport, E.	0256	Ferrerres, A.R.	0166, 0592
Chadbunchachai, W.	0964	De Crea, C.	0869	Ferrerres, A.T.	0166
Chan, A.C.Y.	1157	de Meer, S.G.A.	0881	Ferri, L.E.	0212
Chan, S.W.-W.	1003	de Mestral, C.	0939, 0962	Fijimoto, J.	0728
Chan, T.Y.	0315	de Wailly, P.	0893	Fiscon, V.	0317
Chandra, R.	0273	DeLuca, J.A.	0961	Fisichella, P.M.	0473, 0477
Chang, W.K.	0095	Demetrashvili, Z.	0228	Florez Nicollini, F.	0604
Chen, H.	0931	Demetriades, D.	0947	Fohlin, H.	1012
Chen, J.J.C.	1073			Fragulidis, G.P.	0596
Chen, L.Q.	0463				
Chen, R.J.	0942, 0946				

Name	Abstract ID	Name	Abstract ID	Name	Abstract ID
Fried, G.M.	0212, 0313	Funahashi, H.	0136	Haga, Y.	0272, 0751
Friese, R.S.	0943	Funaki, H.	0468	Hagiike, M.	0027
Frigo, F.	0317	Funakoshi, M.	1019	Hagiwara, A.	0106
Frilling, A.	0855	Furnes, B.	0337, 0352	Hagiwara, K.	0812
Fruhmann, J.	0192	Furuhata, T.	0066	Hagiwara, N.	0507
Fu, C.Y.	0942, 0948	Furukawa, T.	0243	Haider, A.	0941, 0975
Fuchimoto, Y.	0175, 1127	Furuta, K.	0258, 0619	Haier, J.	0118, 0121
Fueldner, F.	0734	Furuta, S.	1147	Haji, S.	1080
Fujii, M.	0322	Furutani, A.	0503	Haji, Y.	0645
Fujii, S.	0008, 0285, 0307, 0375, 0407	Furuya, T.	0597, 1148	Hakala, T.	0098, 0191, 0211
Fujii, T.	0196	Fushiki, M.	0448	Halloul, Z.	0201
Fujii, Y.	0097	Futawatari, N.	0010	Halonen, J.	0209, 0211
Fujimori, M.	1052	Galeev, S.I.	0705, 0717	Hamadani, F.	0974
Fujimoto, D.	0797	Gardovskis, J.	0120, 0630	Hamaguchi, M.	1093
Fujimoto, J.	0124, 0690, 0718	Gatek, J.	0996, 1030	Hamano, K.	0110
Fujimoto, Y.	0884	Gauger, P.G.	0863	Hamilton, N.	1125
Fujimura, T.	0808	Genc, H.	0911	Han, D.S.	1156
Fujino, A.	1141	Ghasoup, A.	0107, 1066	Hanai, T.	0321
Fujisaki, H.	0137	Gilbert, E.W.	0466	Hanari, N.	0498, 0499
Fujisaki, M.	0628	Gill, H.	0960, 0971	Haneda, S.	0364
Fujishima, M.	0998	Giorgini, E.	0227, 0972	Hannan, M.J.	0047, 1139
Fujita, H.	0451	Go, K.T.S.	0981	Hap, A.	0330
Fujita, S.	0308	Go, T.S.	0956	Hara, H.	0903
Fujita, T.	0189, 0958, 0968, 0970, 0987	Goble, S.	0963	Hara, M.	0261
Fujiwara, F.	0533	Gocho, T.	0180	Harada, H.	0046, 0202, 0214
Fujiwara, H.	0469, 0496, 0502, 0503, 0504, 0506, 0509, 0511, 0518, 0519, 0521, 0530, 0531, 0752, 0842	Godai, T.	0407	Harness, J.K.	1002
Fujiwara, M.	0048, 0783	Goh, M.H.	0985, 0989	Harris, C.C.	0126
Fujiwara, N.	0082	Goldenring, J.R.	0755	Harvey, A.	0926
Fujiwara, S.	0807	Goldfarb, M.	0913	Hanazaki, K.	0461, 0822
Fukada, T.	0694	Gomez, D.	0962	Haneda, S.	0364
Fukazawa, A.	0439	Gonda, K.	1006	Hannan, M.J.	0047, 1139
Fukino, N.	0804, 1102	Gondek, S.	0913	Hap, A.	0330
Fukuda, K.	0151, 1127	Gotanda, Y.	0422	Hara, H.	0903
Fukuda, Y.	1019	Gotley, D.C.	0476	Hara, M.	0261
Fukumoto, K.	0663	Goto, M.	0183	Harada, H.	0046, 0202, 0214
Fukumoto, T.	0720	Gotoh, M.	0545, 0848, 1145	Harness, J.K.	1002
Fukunaga, M.	0383, 0387	Govender, T.	0792	Harris, C.C.	0126
Fukunaga, T.	0016, 0035, 0067	Groeneveld, K.M.	0945, 0973	Harvey, A.	0926
Fukunaga, Y.	0304, 0385	Grubbs, E.G.	0875	Hase, K.	0122, 0354
Fukunari, N.	0894	Grubnik, A.V.	1011, 1027	Hasegawa, H.	0280, 0297, 0298, 0299, 0326, 0345, 0350
Fukushima, R.	0092, 1089	Grubnik, V.	0019	Hasegawa, J.	0276, 0342
Fukushima, T.	0912	Grubnik, V.V.	0481	Hasegawa, S.	0254, 0340
Fukutomi, T.	1065	Gruen, R.L.	0955	Hasegawa, Y.	0642
Fukuzawa, M.	1126	Gupta, A.	1016	Hashiguchi, T.	0158
		Gust, L.	0883, 0890	Hashimoto, A.	1104
		Haas, B.	0963	Hashimoto, M.	0612
		Hachiya, O.	0781, 1094	Hashizume, M.	0007, 0063, 0079
		Haciyani, M.	0911	Hashizume, Y.	0351

Name	Abstract ID	Name	Abstract ID	Name	Abstract ID
Hassan, A.	1079	Hirooka, S.	0134	Igarashi, S.	0380, 0437, 0626
Hassan, I.	0022, 0933	Hirose, N.	0806	Ignatoski, K.M.	0886
Hata, F.	0301	Hirose, Y.	0693, 0731	Iiai, T.	0417, 0419, 0445, 0446, 0448
Hatakeyama, K.	0004, 0143, 0417, 0445, 0446, 0448	Hirukawa, H.	0044, 0599, 0715	Iida, A.	0031
Hatakeyama, S.	1140	Hisamatsu, Y.	0014	Iida, M.	0344, 0618, 0643
Hatakeyama, T.	0401	Hisashi, I.	0703, 0713	Iida, S.	0425
Hatanaka, M.	1143	Hishiki, T.	1129	Iida, T.	0823
Hatkeyama, K.	0419	Hishinuma, S.	0626	Iihara, M.	0882, 0888
Hatori, T.	0570, 0716	Ho, S.Y.M.	0994	Iimuro, Y.	0124, 0610, 0690
Hattori, K.	0036	Ho, Y.M.S.	0162	Iino, S.	0081
Hattori, M.	0351	Hoff, W.S.	0969	Iitaka, D.	0532
Havlik, R.	0735	Hokimoto, N.	1021	Ikawa, H.	1151
Hayakawa, T.	0613	Honda, S.	1136	Ikdeda, T.	0084
Hayasaki, M.	1089	Honda, Y.	0426	Ikeda, I.	0014
Hayashi, K.	0034, 1043	Hoque, M.M.	0047, 1139	Ikeda, A.	0114
Hayashi, M.	0032	Hori, T.	0076	Ikeda, H.	1143
Hayashi, N.	0033	Horiguchi, A.	0651	Ikeda, M.	0279, 0306
Hayashida, M.	0173	Horikoshi, K.	0363	Ikeda, N.	0536
Hayashida, T.	1010, 1020	Horino, K.	0658	Ikeda, S.	0301
Hazama, S.	0115, 0360	Hoshimoto, S.	0695	Ikeda, T.	0380, 0437, 0903, 1133
Hellman, P.	0853, 0909	Hoshino, G.	0255	Ikenaga, M.	0272
Heppert, V.	0093	Hoshino, H.	0350	Ikoma, H.	0101, 0677, 0678, 0805
Herrera, M.F.	0879	Hoshino, K.	0176, 1135	Ikuta, Y.	0569
Hibi, K.	1024	Hoshino, Y.	0299	Ilyashenko, V.V.	0481
Hibi, Y.	0904	Hosoda, K.	0398	Imada, S.	0278
Hida, J.	0311, 0376, 0377	Hosoya, S.	0727	Imai, S.	0394, 0436, 0438
Hidaka, E.	0402, 0433	Hotokezaka, M.	0365	Imai, T.	0904, 0935, 1022
Hiki, N.	0761, 0776, 0794, 0814, 0824	Hotomi, M.	0884	Imamura, N.	0622
Hill, A.G.	0089, 0095, 0271, 0282, 0293, 0357, 1081	Hotta, T.	0270	Imoto, S.	1045
Hino, H.	0720, 0781	How, K.Y.	0165, 0773	Imura, S.	0587
Hirai, K.	0647	Hranat, O.	0729	Inaba, K.	0947
Hirai, Y.	0406	Hsee, Li	0954	Inaba, T.	0092, 1008, 1046, 1089
Hirakawa, K.	0384, 0737, 0816	Hsieh, C.H.	0948	Inabnet, W.B.	0874
Hiramatsu, Y.	0464	Hu, Y.	0215	Inagaki, H.	0607
Hiramitsu, T.	0898	Huang, Y.C.	0948	Inamoto, O.	0851
Hirano, A.	1044	Hughes, C.0237,	1028	Inchauste, S.	0867
Hirano, S.	0631, 0688, 0712	Hughes, M.B.	0867	Ingram, W.L.	1114
Hirano, Y.	0351	Hulchiy, M.	0917	Inomata, M.	0141, 0144, 0323, 0367
Hirashita, T.	0795	Hultin, H.	0908	Inoue, H.	0070, 0266, 1095
Hirata, K.	0066, 0666	Hung, W.K.	0995	Inoue, M.	0143
Hirata, M.	0197, 0203, 0206, 0208	Hunter, J.G.	0466	Inoue, T.	0071, 1087
Hirata, Y.	1136	Hyde, J.	0655	Inoue, Y.	0043, 0142, 0207, 0251, 0382, 0732
Hiratsuka, T.	0367	Ianos, G.0242,	1088	Inuzuka, K.	0691
Hirokawa, F.	0032	Ichihara, T.	0033	Ip, W.K.	0582
Hirono, S.	0135	Ichikawa, D.	0456, 0677, 0678, 0743, 0778, 0779, 0830, 0831		
Hirono, Y.	0796, 0797	Idani, H.	0060, 0279, 0484, 0835		
		Ide, M.	0647		
		Ide, Y.	0334		



Name	Abstract ID	Name	Abstract ID	Name	Abstract ID
Ise, K.	1145	Johanson, V.	0921	Kano, H.	0501, 0526, 0684, 0707, 0708, 0801, 0803, 1098, 1099, 1100
Ishibe, A.	0373, 0403	Johnson, M.A.	0564, 0624, 0982, 0993	Kano, N.	0648
Ishibe, T.	1103	Jon, B.	0608	Kanzaki, A.	0549
Ishida, A.	0194	Joseph, B.A.	0943	Kapoor, A.	0590
Ishida, F.	0275	Jukes, A.	0979	Karikome, K.	0483
Ishida, Y.	0467, 0662, 0765	Julka, P.K.	1034	Kashimura, S.	0848
Ishigami, S.	0784, 0840	Juvonen, P.	0217	Kashiwaba, M.	1008
Ishihara, S.	0303, 0328, 0341, 0348	Kabalak, A.A.	1118, 1119	Kashiwagi, S.	1049
Ishii, J.	0700	Kabeshima, Y.	0042	Kasugai, H.	0620
Ishii, K.	0609	Kadota, Y.	0177	Kasuya, K.	0560
Ishii, T.	0305, 0397	Kadoya	1018	Kasvosve, N.	1075
Ishikawa, H.	0916	Kagawa, T.	0041	Katada, N.	0493
Ishikawa, K.	0765	Kahn, D.	0171	Katagiri, H.	0001, 0355
Ishikawa, T.	0327, 1007	Kahokehr, A.	0089, 0282, 0293, 1081	Kataoka, K.	0412
Ishimaru, M.	0329	Kahokehr, A.A.	0268	Kataoka, Y.	0096
Ishimoto, T.	0831	Kainiemi, K.	0802	Katayama, M.	0035
Isobe, T.	0843	Kaiwa, Y.	0037	Katayanagi, S.	0847
Isogaki, J.	0479	Takeji, Y.	0292	Kato, H.	0535
Itabashi, T.	0440	Kamata, H.	0159	Kato, S.	0108, 0756
Itamoto	1018	Kameoka, S.	0283	Kato, Y.	0041, 0565, 0589, 0634, 0680, 0689
Itatsu, K.	0670	Kamer, E.	0911	Katsube, O.	1048
Ito, K.	0905	Kameyama, H.	0445, 0446	Katsube, T.	0821
Ito, R.	0667	Kameyama, N.	0015, 0061	Katsuda, M.	0800
Ito, T.	0614	Kamimura, M.	1044	Katsuno, G.	0383
Ito, Y.	0891	Kamiya, K.	0464	Kaur, N.	1016, 1036
Itoh, M.	0980	Kamiya, S.	0760	Kaushal, R.	0190
Itoh, Y.	1022	Kamiya, Y.	0036	Kawabata, T.	0762
Iwadate, M.	0153, 0369	Kan, H.	0429	Kawabe, N.	0583
Iwahashi, M.	0064, 0800, 0823	Kanai, T.	0038, 0246, 0394, 0438, 0838	Kawaguchi, T.	0774, 0778
Iwai, T.	0260	Kanazawa, A.	0051, 0319, 0412, 0585, 0665, 0719	Kawaguchi, Y.	0131
Iwamoto, H.	0182, 0270	Kanazawa, S.	1047, 1054	Kawahara, H.	0040
Iwamoto, S.	0338	Kaneda, K.	0671	Kawai, M.	0581, 0709
Iwasaki, Y.	0236	Kanehira, E.	0771	Kawajiri, H.	1049
Iwase, K.	0057, 0904	Kaneko, H.	0426, 0606, 0700, 0791, 1047, 1054	Kawamata, H.	0644
Iwatsuki, M.	0780	Kaneko, N.	0980	Kawamoto, K.	0050
Iwaya, T.	0452	Kaneko, Y.	0142	Kawano, Y.	0605, 0639
Izumi, K.	0898	Kaneya, Y.	0611	Kawasaki, A.	0849
Jaffer, I.H.	0238	Kang, B.	0897	Kawase, J.	0029
Jain, A.K.	0961	Kang, S.-W.	0899	Kawashima-Takeda, N.	1149
Jain, V.	0967, 1037			Kayatama, K.	0796
Jangjoo, A.	0247, 0653, 1039			Kebebew, E.	0867, 0887
Janikow, C.	0604			Keerl, A.	0023, 0024
Jayasuriya, K.	0990			Kenig, J.	0289
Jayatilleke, I.N.	0959			Kenjo, A.	0545
Jeong, J.J.	0899, 0927				
Jindo, O.	0701				
Jinno, H.	0999, 1010, 1020, 1053, 1056, 1062				

Name	Abstract ID	Name	Abstract ID	Name	Abstract ID
Khan, J.S.	0318, 0449	Kitajima, M.	0111, 0346	Konosu, M.	0452, 0497
Khomyak, I.V.	0538	Kitamura, M.	0002, 0968	Konturek, A.	0854, 0923
Khrapach, V.	1001	Kitamura, T.	0371	Koo, D.H.	0873
Khuhaprema, T.	0331	Kitano, S.	0080, 0141, 0144, 0323, 0367, 0795	Kopchak, K.V.	0538
Khunpugdee, S.	0331	Kitano, Y.	1122, 1146	Kopsombut, G.	0874
Khwaja, K.	0974	Klos, D.	0735	Korita, P.V.	0125, 0636
Kida, K.	0030	Knai, T.	0436	Korn, O.	0470
Kielan, W.	0330	Ko, K.	0648	Kosac, P.	1030
Kijima, Y.	1050	Kobayashi, M.	0058, 0103, 0161, 0461, 0822	Kosaka, T.	0468, 0767
Kikuchi, H.	0117	Kobayashi, N.	0059	Kosala Somaratne, K.M.	0187, 0635, 1109
Kikuchi, M.	0607	Kobayashi, S.	0588, 0601	Koshinaga, T.	1133, 1148
Kikuchi, S.	0827, 1051	Kobayashi, T.	0044, 0281, 0286, 0599, 0715, 0937	Kosuga, T.	0456
Kikumori, T.	0935	Koc, O.	1115, 1118	Kosumi, K.	0654
Kim, J.-H.	0924	Kocher, Th.	0023	Kotake, K.	0371
Kim, J.S.	0924	Kodai, S.	0051	Kotake, M.	0087, 0274, 0332
Kimihiko, F.	0443	Kodera, Y.	0048, 0783	Kotanagi, H.	0597
Kimura, A.	0106, 0964	Koeda, K.	0752, 0842	Kotani, J.	1085, 1087, 1104
Kimura, K.	0458, 0737	Koenderman, L.	0945	Koter, S.	0940
Kimura, M.	0249	Koga, H.	1134	Kotoc, J.	0996
Kimura, W.	0577, 0650, 0720, 0723, 0781, 1094	Kohno, M.	1151	Koufuji, K.	0843
Kimura, Y.	0452, 0497	Koide, Y.	0418	Kouhujji, K.	0749, 0833
Kinami, S.	0468, 0808	Koike, A.	1009	Koval, L.	0476, 0977
Kinoshita, A.	1147	Koike, N.	0623	Kow, A.W.C.	0241
Kinoshita, M.	1116	Koizumi, S.	0588	Koyama, I.	0584, 0722, 0818, 0844
Kinross, J.	1082	Kojima, M.	0398, 0826	Koyanagi, K.	0455, 0517, 0844
Kinugasa, T.	0378	Kojima, T.	0329	Kraimps, J.L.	0893
Kinugasa, Y.	0374	Kojima, Y.	0085	Kubo, N.	0505
Kiribayashi, T.	0216	Kokuba, Y.	0039, 0052, 0140, 0395, 0400	Kubo, S.	0671, 0679, 0683, 0738
Kirino, I.	0614	Koller, H.	0951	Kubochi, J.	0698
Kirkby-Bott, J.	0870, 0910	Kolosovsky, J.V.	0705, 0717	Kubota, K.	0074
Kise, Y.	0486	Komatsu, S.	0743, 0830	Kubota, M.	1138
Kishida, S.	0471	Komeda, K.	0546	Kubota, T.	0824
Kishiki, T.	0410	Komuro, H.	1152	Kudo, S.	0070, 0392, 0402, 0433, 0620, 1095
Kishimoto, I.	0050	Kondo, K.	0102, 0389	Kudo, T.	0207
Kishine, K.	0346	Kondo, S.	0688	Kulig, J.	0138, 0571, 0656, 0759
Kita, Y.	0049	Kong, S.H.	0746	Kumagai, K.	0814
Kitagawa, H.	0461, 1147, 1154	Konishi, F.	0731	Kumagai, Y.	0527
Kitagawa, M.	0496, 0779	Konishi, T.	0304	Kumamoto, Y.	0001, 0652
Kitagawa, Y.	0015, 0059, 0105, 0154, 0195, 0196, 0198, 0205, 0243, 0298, 0299, 0326, 0345, 0350, 0451, 0460, 0617, 0760, 0799, 0819, 1053, 1056, 1062, 1101	Konno, A.	0428	Kumashiro, R.	0292
Kitahara, K.	0682	Konno, H.	0117, 0464, 0561, 0562, 0663	Kumiko, I.	0900
		Konno, S.	0991	Kunisaki, C.	0003, 0008, 0633, 0767, 0841
		Kono, E.	0169	Kurahashi, Y.	0820, 0851
		Kono, M.	0970	Kuranami, M.	1059
		Kono, T.	0522, 0523	Kurashima, Y.	0168
		Kono, Y.	0141, 0319		

Name	Abstract ID	Name	Abstract ID	Name	Abstract ID
Kurauchi, N.	0598	Liu, H.M.	0981	Mataki, Y.	0230
Kurita, A.	0771	Livingston, R.	0977	Matoba, S.	0021, 0056, 0322, 0386, 0393
Kurita, N.	0396, 0405, 0846	Lo, C.M.	0582	Matsubara, H.	0381, 0435, 0498, 0499, 0522, 0523, 0536, 0537, 0748
Kuriu, Y.	0039, 0052, 0073	Lo, G.	1014	Matsubara, K.	0195
Kuroda, N.	0718, 0728	Lo, H.Y.	0956	Matsuda, C.	0057
Kurosaki, I.	0004	Lo, Z.J.	1026	Matsuda, K.	0303, 0328, 0341, 0348
Kurose, Y.	0279	Lochman, P.	0356	Matsuda, M.	0612, 0812
Kuroyanagi, H.	0021, 0056, 0320, 0322, 0386, 0393	Lombardi, C.P.	0868, 0869, 0889	Matsuda, T.	0930
Kusachi, S.	0216, 0349, 0702, 0836	Londero, A.P.	0997, 1017, 1040	Matsueda, S.	0839
Kusunoki, M.	0103	Loong, T.H.	0199	Matsui, J.	0202, 0415, 0695, 1023
Kuwano, H.	0535, 0574, 0811	Lostoridis, E.	0128	Matsumata, T.	0556
Kwak, H.N.	0026	Lv, W.P.	0559	Matsumoto, M.	0148
Kwong, A.	1004, 1013, 1015	Ma, K.K.	1015	Matsumoto, S.	0425, 0429
Lada, P.E.	0604	Maalo, J.	1077	Matsumoto, T.	0080, 0340, 0827
Lai, I.-R.	0185, 0186	Maarros, M.	0211	Matsumoto, Y.	0647
Laird, A.M.	0863	Maddah, Gh.	1039	Matsunaga, A.	0345
Lairmore, T.C.	0906	Maeda, D.	0628	Matsuo, Y.	0127, 0736
Lang, B.B.H.	0928	Maeda, K.	0321, 0384, 0404, 0418, 1153	Matsuoka, H.	0104, 0286, 0310, 0410
Lang, B.H.	0925	Maeda, T.	0053, 0606	Matsushita, H.	0508
Lau, S.S.S.	1158	Maehara	0014	Matsutani, T.	0510, 0514
Law, S.	0450	Maehara, Y.	0007, 0145, 0178, 0292, 0554	Matsuura, T.	0173
Law, Y.	0928, 1014	Maemura, K.	0054	Matthys, R.	0957
Lawal, O.O.	0090	Mafune, K.	0287	Matueda, S.	0699
Lawanlakkana, P.	0976	Magema, J.Ph.M.m.K.	0739, 1097	Matyja, A.	0284
Lee, C.R.	0927	Magishi, A.	0018	Mazeh, H.	0931, 0932
Lee, C.W.	0199	Majima, M.	0119, 1149	Mazzaglia, P.J.	0871
Lee, H.J.	0746, 0755, 1156	Maki, T.	0712	Mbuagbaw, J.	0167
Lee, J.	0929, 1079	Makino, H.	0488, 0507	McMurrick, P.J.	0269, 0294
Lee, J.C.	0922	Makino, I.	0465	McQuay, N.	0969
Lee, J.E.	0875	Makizumi, R.	0347	Meara, J.	0237, 1028
Lee, S.	0471	Makuuchi, H.	0480	Mees, S.T.	0118, 0121
Lee, S.J.	0978	Malik, K.A.	0600	Megumi, K.	0534
Leelakusolwong, S.	0485	Malonga, E.	0213	Meissner, A.J.	0231
Leenen, L.P.H.	0938, 0945, 0973	Malonga, E.E.	0167	Mekata, E.	0441
Lehtim T.	0217	Malynovskyy, A.V.	0481	Melino, G.	0273
Lejonklou, M.H.	0880	Mamada, Y.	0674, 0685	Meyer, F.	0201, 0724, 0734
Lemanu, D.P.	0268	Manabe, T.	0055, 0336	Mieno, H.	0815
Levadoux, M	1110	Manukyan, G.	0710	Miettinen, P.	0217, 0802
Lew, J.I.	0913	Mardin, W.A.	0118, 0121	Miglani, R.	1016
Lewis, M	0895	Markovic, I.	0857, 0918, 0919	Mihara, K.	0617
Li, K.W.	0315, 1073	Maruyama, T.	0697	Mikami, S.	0016
Li, T.-S.	0110	Masaki, T.	0281, 0286, 0410	Miller, B.S.	0886
Liao, C.-C.	0220, 0949	Masataka, M.	0159		
Liao, G.-S.	0673	Masuda, M.	0416		
Liau, K.H.	0241	Masuda, T.	0616		
Liberman, A.S.	0313	Masumoto, K.	1121		
Lin, H.-C.	0185				

Name	Abstract ID	Name	Abstract ID	Name	Abstract ID
Mimatsu, K.	0030, 0501, 0526, 0684, 0707, 0708, 0801, 0803, 0804, 0849, 1098, 1099, 1100, 1102	Moolla, Z.	0649	Nagasaki, K.	0105
Mimori, K.	0123, 0266	Moore, J.W.	0273	Nagase, T.	0246, 0838
Minagawa, M.	0004	Moosa, M.A.	0953	Nagata, K.	0517
Minami, K.	0557	Mori, H.	0027	Nagata, Y.	0787
Minamimura, K.	0287	Mori, K.	0453	Nagayama, A.	0059
Minehara, H.	0991	Mori, M.	0062, 0088, 0123, 0314, 0333, 0342, 0427, 0537, 0681	Nagino, M.	0324, 0343, 0670
Mise, Y.	0553	Mori, R.	0668	Nagino, N.	0125, 0636
Mishima, H.	0115	Moriguchi, M.	0478	Nagura, N.	1052
Mishra, A.	0914, 1037	Morii, Y.	0245	Naito, M.	0005, 0046, 0442
Misumi, K.	0214	Morikawa, N.	1137, 1141	Naitoh, T.	0335
Mitchell, C.	0944	Morikawa, T.	0621	Nakagawa, M.	0038, 0246, 0394, 0490
Mitsui, J.	0431	Morikawa, Y.	0176, 1135	Nakagawa, S.	0524
Miura, K.	0113	Morimoto, S.	0405	Nakahara, S.	0964, 1123
Mixter, C.G.	0218	Morimura, K.	0515	Nakajima, A.	0319
Miyagi, M.	0749, 0833	Morise, Z.	0029, 0583, 0637	Nakajima, M.	0687
Miyajima, N.	0290, 0347, 0355, 0363	Morishita, K.	0937	Nakamori, S.	0726
Miyakawa, S.	0651	Morita, Y.	0561	Nakamoto, M.	0732
Miyake, T.	0253	Moriya, H.	0772	Nakamura, K.	0730
Miyamoto, A.	0726	Moriyama, J.	0393	Nakamura, M.	1121
Miyamoto, H.	0841	Moriyama, M.	0152	Nakamura, R.	0829
Miyamoto, K.	0153	Mosquera, D.	0256	Nakamura, S.	1055
Miyamoto, Y.	0316, 0546	Motilall, S.R.	0965	Nakamura, T.	0078, 0388, 0391, 0408, 0819
Miyano, T.	0082	Motoi, F.	0183, 0621, 0915	Nakanishi, M.	0395, 0400
Miyashita, M.	0472, 0528	Mowlds, D.S.	1002	Nakano, A.	0373, 0403
Miyatani, T.	0396	Mueller, A.-K.	0724	Nakano, H.	0113, 0164
Miyauchi, A.	0916	Muguruma, K.	0816	Nakano, K.	0060, 0484, 0876, 0912
Miyauchi, H.	0381, 0435	Mullen, D.G.	0234	Nakano, M.	0894
Miyauchi, K.	0771	Munakata, Y.	0034	Nakao, A.	0048, 0160, 0549, 0567, 0657, 0783
Miyazaki, H.	1116	Murai, S.	0664	Nakayama, H.	0672
Miyazaki, M.	0687, 0694	Murakami, K.	1137	Nakayama, S.	0254
Miyazaki, S.	0788	Murao, Y.	1093, 1103	Nakazawa, K.	0970
Miyazawa, M.	0065, 0252, 0818	Murata, K.	0334	Nakazawa, N.	1134
Miyoshi, A.	0682	Murata, S.	0852	Nallathamby, V.	0162, 0994
Mizuguchi, T.	0666	Murayama, S.	0540	Namikawa, T.	0822
Mizuma, M.	0645, 0646	Murayama, Y.	0140, 0805	Nanashima, A.	0552
Mizuno, M.	0058, 0161	Museru, L.	0971	Narasaki, H.	0770
Mizushima, T.	0427	Muth, A.	0885	Narimatus, H.	0754
Mizutani, M.	1094	Muto, J.	0554	Narushima, K.	0150
Mochiki, E.	0811	Nagahama, M.	0905	Nashimoto, A.	0524
Mochizuki, H.	0354	Nagahara, H.	0384, 0404	Nasu, Y.	0631
Mochizuki, K.	1130	Nagai, E.	0063, 0789, 0817	Nathens, A.B.	0962, 0963
Mofokeng, T.G.	0638	Nagakari, K.	0383, 0387	Natsugoe, S.	0054, 0129, 0148, 0230, 0513, 0669, 0757, 0784, 0840, 1050
Mohri, Y.	0103	Nagano, H.	0681	Natsume, T.	0748
Monib, S.	1077, 1079	Nagao, G.	0104		
Moo-Young, T.	0907	Nagao, J.	0216		
		Nagao, S.	0836		
		Nagaoka, M.	0788		



Name	Abstract ID	Name	Abstract ID	Name	Abstract ID
Navruzov, S.N.	0302	Obioha, C.B	0769	Okajima, M.	0264
Nemoto, M.	0493	Obuchi, T.	0061	Okamoto, K.	0722
Nerome, Y.	0513	Ochi, N.	0127, 0736	Okamoto, T.	0888
Nezu, R.	0233, 0276	Ochiai, H	.0297, 0691, 0701	Okamura, H.	0530
Ngo Nonga, B.	0213	Ochiai, T.	0101, 0111, 0158, 0344, 0346, 0527, 0618, 0643, 0677, 0678, 0713, 0774, 0992	Okamura, R.	0820
Ngu, F.	0539	Ogasawara, S.	0156	Okamura, S.	0504
Nguyen, J.	0567	Ogata, H.	1047, 1054	Okano, K.	0083
Nguyen, T.D.	1078	Ogata, M.	0072	Okazaki, I.	0154
Nice, E.	0294	Ogata, H.	0364	Okinaga, K.	0092
Niihara, M.	0454, 0494, 0525	Ogawa, H.	0370, 0430	Okita, K.	0034, 0066
Nilsson, B.	0109	Ogawa, K.	0358	Okuda, J.	0262, 0389
Nilsson, O.	0109	Ogura, N.	0358	Okumura, N.	0837
Nilubol, N.	0887	Ohashi, K.	1133	Okumura, T.	0149, 0487, 0489, 0492
Ninomiya, I.	0465	Ohashi, N.	0567	Okuno, K.	0311, 0376, 0377
Nishida, N.	0123	Ohashi, Y.	0037	Okuyama, H.	1122
Nishida, T.	0017, 0543	Ohdan, H.	0264	Omori, T.	0042
Nishikawa, K.	0057, 0825	Ohira, G.	0381	Omoto, I.	0148
Nishimaki, H.	0203	Ohira, M.	0505, 0816	Omoto, T.	0210, 0372
Nishimaki, T.	0399	Ohki, A.	0832	Omura, T.	0050
Nishimura, J.	0276, 0342	Ohki, T.	0189, 0194, 0251	Ono, S.	0205
Nishimura, R.	1051	Ohkubo, H.	0197	Ono, Y.	0930
Nishio, T.	1080	Ohnishi, T.	0157	Onoda, K.	0414
Nishiyama, S.	1053	Ohno, K.	0675	Onoda, T.	1155
Nishiyama, R.	0181	Ohno, T.	0811	Onozato, W.	0388, 0391
Nishiyama, Y.	0727	Ohshima, Y.	0623	Oohashi, T.	0686
Nishizuka, S.	0112	Ohta, F.	0406	Ooki, A.	0845
Nitta, H.	0156, 0172, 0642, 0692	Ohta, M.	0795	Ooki, S.	0423
Noda, E.	0404	Ohta, T.	0465, 0808	Ootubo, T.	0414
Noda, S.	0935	Ohtsuka, M.	0062, 0687	Osada, S.	0660, 0661
Noguchi, H.	0920	Ohuchida, J.	0097, 0622	Osamu, S.	0390
Noguchi, T.	0807	Ohuchida, K.	0063	Osawa, G.	0430
Nomoto, S.	0657	Ohue, M.	0278, 0379, 0409	Osawa, H.	0233
Nomura, E.	0763	Ohyanagi, H.	1080	Oshima, R.	0601
Nomura, T.	0472, 0488, 0528	Oida, T.	0030, 0501, 0526, 0684, 0707, 0708, 0801, 0803, 0804, 0849, 1098, 1099, 1100, 1102	Oshima, T.	0368
Nonaka, K.	0411	Oishi, T.	0425	Osuch, C.	0138
Norberto, L.	0028	Oizumi, Y.	0512	Osugi, H.	0471
Norlen, O.	0853	Ojima, T.	0064	Ota, F.	1042
Noshiro, H.	0682	Oka, M.	0115, 0360, 0491, 0572, 0782	Ota, K.	0333
Noura, S.	0278, 0379, 0409	Oka, Y.	1121	Ota, M.	0375
Nowak, W.	0300, 0854, 0923	Okabe, H.	0580, 0741	Otake, S.	1144
Nozato, E.	0399	Okabe, M.	0614	Otake, T.	1006
Nozawa, K.	0339	Okada, K.	0065, 0709	Otani, T.	0370
Nunobe, S.	0761, 0776			Otsubo, T.	0016, 0035, 0067, 0113, 0164, 0290, 0347, 0355, 0363, 0576, 0588, 0601, 0640
Obama, K.	0741			Otsuka, Y.	0053, 0606, 0700
Obara, H.	0105, 0195, 0196, 0198				
Obara, S.	0011				
Obatake, M.	1130				

Name	Abstract ID	Name	Abstract ID	Name	Abstract ID
Ottomo, S.	0541	Rajagopal, S.	0475, 0551, 0568, 0742	Sakamoto, K.	0572
Otuji, E.	0052	Ramirez, M.I.	0200	Sakamoto, M.	0075
Ouchi, S.	0597	Rao, A.D.	0165, 0773, 1105	Sakamoto, T.	0958, 0968, 0987
Oue, T.	1126	Rao, J.K.	0165, 0773	Sakamoto, Y.	0258
Owaki, T.	0513	Rayner, A.V.	0218	Sakata, I.	1093, 1103
Oyama, H.	1055	Razek, T.	0960, 0971, 0974	Sakata, J.	0593, 0594, 0641, 0686, 0697
Oyama, T.	0460	Reddy, J.R.	0595, 0625	Sakata, M.	1056
Ozawa, H.	0447	Research Collaborators, A.F. .C.E.	0870	Sakata, N.	0183, 0646
Ozawa, S.	0116, 0480, 0500	Retnam, M.S.	0914	Sako, H.	0151
Paajanen, H.	0020, 0224	Rhee, P.	0943	Sakoda, M.	0081, 0557, 0669
Pais, A.V.	1038	Riahon, N	0901	Sakurai, J.	0067
Paral, J.	0356	Riansuwan, W	0420, 0421	Sakurai, K.	0130, 1057, 1058, 1084
Park, C.S.	0934	Richards, M	0872	Sakuramoto, S.	0010, 0068, 0815
Park, J.H.	0878	Richards, W	0769	Salibian, A.H.	1002
Park, M.	1140	Richter, P	0289	Sallinen, V.	0045
Park, M.S.	0936	Rino, Y	0416, 0809	Salveridis, N.	0128
Parphentyeva, N.D.	0019	Rivera, M	0936	Sammour, T.	0089, 0293
Parvaiz, A.C.	0318, 0449	Roh, M.R.	0934	Samura, H.	0399
Pasieka, J.L.	0926	Rolfs, T.	0864	Sandelin, K.	1001
Patel, V.	1096	Romaniszyn, M.	0300	Sangkhathat, S.	0265
Pattou, F.	0862	Rond A.	0592	Santti, H.	0045
Pawar, P.	1036	Rubtsov, M.A.	0717	Sapidis, N.	0267
Peralta Rosario, R.	0170, 0952	Rudnicki, J	0091	Sasaki, A.	0011, 0390, 1091
Perez, B.	0879	Rudno-Rudzinska, J	0330	Sasaki, H.	0069, 0157, 0361, 0699, 0835, 0839
Permsapaya, W.	1076	Ryu, Y	0434, 0337, 0352	Sasaki, I.	0335, 0364, 0444
Perrier, N.D.	0875, 0901, 0902, 0906	Sadacharan, D.	1005	Sasaki, R.	0106
Phalanusitthepha, C.	0222	Sadahiro, M.	1155	Sasaki, T.	1007
Phanthabordeekorn, W.	0240	Sadieh, O.	0232	Sasako, M.	0827
Phung, J.	0294	Sadieh, O.	0107, 1066	Sasatomi, T.	1090
Pillay, S.P.	0238	Sagae, S.	0438	Satake, M.	0718
Pinnagoda, K.	0012	Saikawa, Y.	0151, 0799, 0829, 1127	Sato, H.	0321, 0418, 0454, 0490, 0494, 0525, 1154
Pitigala Arachchi, P.	0225	Saimanen, E.	0191	Sato, K.	0085
Plósz J.	0758	Saito, J.	0154	Sato, T.	0114, 0158, 0277, 0408, 0809, 1021
Polese, L.	0028	Saito, M.	0126	Satodate, H.	0070
Poon, T.P.	1157	Saito, T.	0069, 0903, 1129	Satoh, K.	0037
Portale, G.	0317	Saitoh, D.	1116	Satoh, S.	0785
Pougouras, K.	0128	Saitou, T.	0361	Satoi, S.	0132, 0134, 0542, 0711, 0714
Prapasrivorakul, S.	0420, 0421	Saji, O.	0414	Sawada, T.	0056
Pringle, K.	0775	Sakae, M.	0683	Sawada, Y.	0285
Prinz, R.	0907	Sakaguchi, T.	0561, 0562, 0663	Sawaki, M.	1022
Puckett, J.	1086	Sakai, T.	0791	Saxena, R.	0590, 0625
Puolakka, V.-M.	0045	Sakai, Y.	0254, 0340	Schweiger, S.	0193
Puolakkainen, P.	0750	Sakakibara, T.	0500	Sebag, F.	0883, 0890
Puri, P	1120	Sakamoto, A.	0888		
Raffaelli, M.	0868, 0869, 0889				
Rahman, S.	0022, 0933				

Name	Abstract ID	Name	Abstract ID	Name	Abstract ID
Sebastian, M.	0091	Shinkawa, H.	0696	Srinivasa, S	0095, 0268, 0271, 0282, 1081
Seki, H.	1010	Shinno, N.	0632	Srivastava, A.	0190, 1034, 1035
Sekikawa, K.	0002	Shinoda, M.	0181, 1101	Srovnal, J.	0735, 0880, 0909
Sekimoto, M.	0088, 0306, 0314, 0427	Shinohara, H.	0820, 0851	Steenkamp, V.	1000
Senanayake, K.J.	0187, 0635, 1109	Shinohara, K.	0992	Stoll, S.J.	0931
Senanayake, W.S.M.K.J.	0225	Shinto, E.	0354	Storli, K.	0337, 0352
Sencan, I.	1115	Shiomi, A.	0374	Strumfa, I.	0120, 0630
Sengoku, N.	1043, 1059	Shiozaki, A.	0456, 0509, 0511, 0518, 0519, 0521, 0532	Subramaian, C.	0982
Seo, Y.	0280	Shiozaki, S.	0533	Subramaniam, C.	0564, 0624
Setoguchi, T.	0117	Shiozawa, M.	1048	Subramanian, C.	0993
She, W.H.	1157, 1158	Shirabe, K.	0178	Subrt, Z.	0356, 0547, 0608
Shelat, V.G.	0219, 0602, 0978, 0983, 1105	Shirai, Y.	0593, 0594, 0641, 0697	Suda, A.J.	0093
Shen, T.-L.	0186	Shiraishi, N.	0144, 0323	Suda, K.	0467
Shenfine, J.	0476	Shirakawa, H.	0626	Sudo, Y.	0071
Sheppard, B.C.	0466	Shirouzu, K.	0378, 0422, 1090	Suehiro, T.	0556
Shiba, H.	0662, 0676	Shukla, N.K.	1033	Sugae, T.	0160
Shibata, K.	0721	Shundo, Y.	0049	Sugawara, K.	1042
Shibata, M.	1084	Shuto, K.	0150, 0522, 0523, 0748	Sugihara, K.	0325, 0327
shibata, T.	0482	Siddiqui, N.	0318	Sugimoto, T.	1021
Shichinohe, T.	0770	Siddiqui, S.M.	0234, 1150	Sugino, K.	0905
Shigeta, K.	0326	Sidhu, S.B.	0922	Sugioka, A.	0041, 0565, 0589, 0634, 0637, 0680, 0689
Shimada, H.	0458, 0791	Sierzega, M.	0571, 0656	Sugitani, I.	0856, 0884
Shimada, K.	1060, 0846	Sifrim, D.	0474	Sugito, K.	1148
Shimada, N.	0426	Siguan, S.S.	1025, 1071, 1072	Sugiyama, M.	0077, 0104, 0281, 0832
Shimada, R.	0339	Sim, E.	0978	Suh, Y.S.	0755
Shimada, Y.	0139, 0149, 0152, 0487, 0489, 0492	Sim, H.L.	0984	Suri, A.	1077
Shimamura, T.	0290	Singaporewalla, R.M.	1074	Susa, M.	0424
Shimazu, M.	0548, 0560, 0615	Singh, D.	1037	Suwa, T.	0483
Shimizu, A.	0575	Singh, P.P.	0357	Suzuki, H.	0072, 0362
Shimizu, D.	1007	Singh, R.K.	0590, 0595	Suzuki, K.	0137
Shimizu, H.	0469, 0508, 0664, 0694	Sippel, R.S.	0932	Suzuki, M.	1095
Shimizu, N.	1096	Skogseid, B.	0880	Suzuki, N.	0782, 1140
Shimizu, S.	0585, 0665, 0719	Smachylo, R.M.	0591	Suzuki, S.	0439, 0562, 0691, 0701, 0856, 0876, 0912
Shimizu, T.	0100, 0413, 0441, 1044, 1061	Smirnov, D.M.	0094	Suzuki, Y.	0027, 0083
Shimojima, N.	1135	Smyrniotis, V	0555	Suzumura, K.	0728
Shimomura, M.	0264	Soeno, M.	0599	Szczepanik, A.B.	0231
Shimono, R.	0474	Soh, E.Y.	0929	Szczepanik, A.M.	0231, 0759
Shimotakahara, A.	1131	Solecki, R.	0284, 0296	Szura, M.	0284, 0296
Shimura, T.	0574	Soma, K.	0991	Tóth, D., Török, M	0758, 0758
Shinchi, H.	0230	Sommer, T.	0810	Tabiri, S.	0025
Shindo, Y.	0360	Son, S.	0428	Tabuchi, S.	0455, 0517, 0844
Shingai, T.	0379, 0409	Soop, M.	1086	Tachibana, K.	0369
Shinkai, M.	1136	Sotiropoulos, G.C.	0855	Tada, H.	0073
Shinkai, T.	1152	Souzaki, R.	1128	Tada, T.	0044, 0715

Name	Abstract ID	Name	Abstract ID	Name	Abstract ID
Tagaya, N.	0074	Tanahashi, Y.	0689	Tominaga, Y.	0896, 0898
Taguchi, T.	0173, 1128	Tanaka, E.	0712, 0770	Tomisawa, Y.	0156
Tahara, K.	1143	Tanaka, H.	0147, 0505, 0573, 1146	Tomita, M.	0015, 0061
Taieb, D.	0890	Tanaka, J.	0275, 0392, 0402, 0620	Tomita, R.	0380, 0437
Tajima, M.	0245	Tanaka, K.	0262, 0389, 0668, 1142, 1149	Tomita, Y.	0459, 0753
Tajima, Y.	0417	Tanaka, M.	0336, 0789, 0817	Tomonaga, Y.	0900
Tajiri, T.	0579, 0704, 1128	Tanaka, N.	0535, 0553	Tong, D.	0450
Takahara, T.	0692	Tanaka, S.	0675, 0679	Tong, W.H.	0250, 0764, 0786
Takahashi, A.	1144	Tangoku, A.	0520	Tonouchi, H.	0084
Takahashi, M.	0172, 1062, 1063	Tangri, R.	1032	Tori, M.	0017, 0543, 0632
Takahashi, T.	0236, 0411, 0799, 1131	Tani, M.	0135, 0252, 0575, 0581	Toshima, T.	0178
Takahashi, Y.	0619, 0730	Tani, T.	0100, 0253, 0413, 0441, 0852, 1061	Toshimasa, I.	0432
Takaki, Y.	0747	Taniai, N.	0605, 0639	Toshimitsu, Y.	0722
Takamori, H.	0569, 0573, 0654, 0658	Tanigawa, N.	0262, 0763	Toya, N.	0189
Takano, K.	0548, 0615	Taniguchi, K.	0785	Toyofuku, T.	0207
Takao, S.	0054	Tanimura, S.	0761	Toyokawa, H.	0542, 0711, 0714
Takashima, T.	1049	Tanizawa, Y.	0777	Toyoshima, A.	0309
Takayama, S.	0075, 0261, 1023	Tashiro, J.	0305, 0432	Trakarnsga, A.	0578
Takayama, T.	0672, 0812	Tay, G.S.	0219	Triantafyllidis, I.	0229, 0267
Takayasu, H.	1142	Tazuke, Y.	1153	Truitt, M.S.	0944
Takeda, S.	0160, 0491	Teo, L.T.	0981, 0983, 0984, 0986, 0990	Tsai, C.-C.	0185, 0186
Takehara, M.	1048	Terachi, T.	0930	Tsang, S.H.	0582
Takemasa, I.	0062, 0314, 0333	Terashima, M.	0006, 0744, 0766, 0777, 1085	Tsubaki, M.	0291
Takemoto, Y.	0110	Tewari, P.	0865	Tsuboi, K.	0529
Takemura, M.	0076, 0515	Tezuka, K.	0650	Tsubosa, Y.	0454, 0494, 0525
Takemura, S.	0738	Thanapongsathorn, W.	0239	Tsuchikawa, T.	0631
Takenishita, S.	0423	Theodoraki, K.	0555	Tsuchiya, M.	0053
Takenoshita, S.	0126, 0153, 0369, 0574, 0876, 1084	Thilanka Wasumathi Seneviratne, H.M.	0187, 0635, 1109	Tsuda, I.	0598
Takeshima, K.	0698	Thompson, G.B.	0872, 0895	Tsugawa, K.	1009
Taketomi, A.	0554	Thomson, S.R.	0649	Tsujie, M.	0726
Takeuchi, H.	0077, 0460, 0751, 0760	Thorstensson, S.	1012	Tsujimoto, H.	0122, 0516, 0828, 0850
Takeuchi, T.	1065	Toda, S.	0021, 0320	Tsukada, K.	0149, 0152, 0487, 0492
Takeyama, H.	0075, 0261	Todo, T.	0533	Tsukada, M.	1138
Takeyama, M.	0036	Toh, B.C.	1105	Tsukada, T.	0489
Takeyama, Y.	0725	Tokoro, T.	0377, 0680	Tsukamoto, T.	0051, 0585, 0665, 0719
Taki, K.	0495	Tokuhara, K.	0338	Tsunoda, S.	0741
Takigawa, Y.	0628	Tokuhara, T.	0763	Tsuruma, T.	0428
Takii, Y.	0139	Tokunaga, M.	0006, 0744, 0766	Tsutsui, A.	0078
Tamoto, E.	0688	Tokunaga, Y.	0069, 0157, 0361, 0699, 0839	Tsutsumi, N.	0079
Tamura, Y.	0206	Toma	0055	Turtiainen, J.	0191
Tan, E.K.	0983	Tomikawa, M.	0007, 0079	Turtiainen, M.J.	0098
Tan, E.Y.	1073			Uchida, E.	0072, 0260, 0429, 0472, 0488, 0507, 0510, 0514, 0528, 0579, 0611, 0613, 0674, 0685, 0704
Tan, H.L.	1132			U. chida, H.	0080
Tan, W.S.	0985			U. chida, R.	1052
Tanabe, M.	0181, 0198, 0617, 1101			Uchino, S.	0858, 0916, 0920



Name	Abstract ID	Name	Abstract ID	Name	Abstract ID
Uchiyama, K.	0563	Villegas, C.	0941	Williams, R.T.	0907
Uchiyama, S.	0365	Viriyaraj, V.	0259	Willms, A.	1106
Uchiyama, T.	0245	Vorotyntseva, K.O.	0019	Willy, C.	1107, 1112
Udd, M.	0802	Vriens, M.R.	0881	Woll, M.L.	0932
Udelsman, R.	0860	Vu, T.	0902	Wong, K.	0655
Ueda, J.	0789	Wada, N.	0243, 1064	Wong, K.P.	0925
Ueda, M.	0633	Wada, O.	0436	Wu, C.-Y.	0558
Uehara, K.	0324, 0343	Wada, Y.	0272, 0751	Wu, C.C.	0550
Uehara, S.	1126	Wademan, B.	0775	Wu, Q.	0725
Ueki, T.	0055, 0336	Wakabayashi, G.	0011, 0058, 0112, 0161, 0172, 0440, 0497, 0642, 0692, 0752, 0842, 1008, 1091	Wu, S.C.	0942
Uematsu, D.	0018	Wakai, T.	0125, 0143, 0593, 0594, 0636, 0641, 0686, 1138	Wullschlegler, M.	0950
Uenishi, T.	0671, 0683	Wakiyama, S.	0180, 0184, 0667, 0676	Xu, H.T.	0866
Ueno, M.	0304, 0385, 0563	Walega, P.J.	0289, 0300	Xu, Q.R.	0463
Ueno, S.	0081, 0557, 0669, 1137	Walz, M.K.	0864	Yabe, N.	0664
Ueno, T.	0572	Wang, K.N.	0463	Yabusaki, H.	0524, 0790
Uenosono, Y.	0129, 0757	Wang, Q.	0250, 0764, 0786	Yabushita, Y.	0798
Uetake, H.	0325, 0327	Wang, W.	0009, 0174	Yagi, H.	0177
Umehara, S.	0502	Wang, W.J.	0745	Yagi, M.	0434
Umemoto, S.	0029, 0583, 0637	Wang, Y.	0009, 0174	Yagi, Y.	0419
Umemoto, T.	1024	Wangberg, B.	0885	Yaguchi, Y.	0122
Umemura, A.	1091	Waraya, M.	0133	Yajima, S.	0458
Unno, M.	0288, 0541, 0621, 0915	Warnecke, C.	0902	Yakubu, A.	0226
Uno, A.	0439	Watanabe, G.	0612	Yamabe, K.	0788
Unukovych, D.	1001	Watanabe, H.	0084	Yamada, A.	1041
Uranues, S.	0951	Watanabe, K.	0307, 0407, 0444	Yamada, N.	0737
Urao, M.	0082	Watanabe, M.	0046, 0068, 0078, 0114, 0119, 0133, 0159, 0197, 0206, 0208, 0258, 0358, 0388, 0391, 0408, 0442, 0447, 0457, 0495, 0512, 0619, 0644, 0652, 0702, 0754, 0772, 0780, 0815, 0845, 1059	Yamada, R.	0155, 0809, 0834
Urata, Y.	0738	Watanabe, T.	0111, 0303, 0328, 0339, 0341, 0348, 0577, 0723	Yamada, S.	0108, 0549, 0648, 0756
Urita, Y.	1152	Watanabe, Y.	0085, 0086	Yamada, T.	0274, 1104
Urrutia, R.E.	0200	Watatani, M.	0998	Yamafuji, K.	0698
Usami, M.	1087	Wathanaoran, P.	0222, 0312	Yamagishi, S.	0373, 0403
Ushigome, M.	0244	Weber, C.	0473, 0477	Yamaguchi, A.	0031, 0796, 0797
Usui, N.	1122	Weledji, P.E.	0988	Yamaguchi, K.	0732, 0837
Usuki, H.	0083	Wierzbicki, J.	0091	Yamaguchi, R.	0958
Utsunomiya, T.	0587	Wilczek, H.E.	0179	Yamaguchi, S.	0305, 0316, 0432
Uyama, I.	0467, 0589, 0762, 0765, 0785	Will, U.	0724, 0734	Yamaguchi, T.	0374, 0794, 0814, 0824, 0852
Uyama, N.	0124			Yamakawa, K.	0233
Valladares, H.	0470			Yamaki, S.	0542
van Wessem, K.J.P.	0938			Yamamoto, D.	0087, 0332
Vanags, A.	0120, 0630			Yamamoto, H.	0088
Vane, D.W.	1124, 1125			Yamamoto, K.	0266
Vazquez, B.	0872			Yamamoto, M.	0142, 0251, 0570, 0716
Vehmeijer, M.	1117			Yamamoto, S.	0179, 0308, 0459, 0753
Velayutham, V.	0475, 0551, 0568, 0742			Yamamoto, T.	0132, 0675, 0679
Vercruysse, G.A.	1114			Yamamoto, Y.	0520
Verla, V.S.	0988			Yamanaka, N.	0817
Veidakis, A.	0596			Yamasaki, Y.	0169
Vijayan, A.	0219			Y. amashita, H.	0453

Name	Abstract ID	Name	Abstract ID	Name	Abstract ID
Yamashita, K.	0068, 0133, 0512, 0644, 0754, 0845	Yeh, H.Z.	0550	Yoshino, S.	0491, 0782
Yamashita, M.	1145	Yen, A.H.	0295	Yoshio, H.	0221
Yamashita, Y.	0214	Yeo, D.	0659	Yoshioka, Y.	0324, 0343
Yamataka, A.	1131, 1134	Yiengpruksawan, A.	0578	Youn, Y.K.	0873
Yamauchi, C.	1064	Yokoyama, K.	0431	Young, W.F.	0895
Yamauchi, J.	0288	Yokoyama, T.	0607	Young-Fadok, T.M.	0263
Yamauchi, S.	0325	Yokoyama, Y.	0670	Youssef, O.Z.	1031
Yamaue, H.	0064, 0135, 0252, 0270, 0563, 0575, 0581, 0709, 0800, 0823	Yoneda, M.	0531	Yuan, Y.	0215
Yamazaki, S.	0344, 0527, 0618, 0643, 0992	Yoneyama, Y.	0435	Yui, R.	0714
Yanaga, K.	0040, 0180, 0184, 0662, 0667, 0676	Yorozuya, K.	1065	Yukawa, N.	0416
Yanagimoto, H.	0132, 0134, 0711	Yoshida, A.	0598, 0856	Yukihito, K.	0703
Yanagisawa, S.	0040	Yoshida, H.	0260, 0431, 0510, 0514, 0605, 0611, 0613, 0639, 0674, 0685, 1129	Yukio, T.	0203
Yang, H.K.	0746, 1156	Yoshida, J.	0634	Yumiba, T.	0169, 0825
Yang, Z.	0566	Yoshida, K.	0411, 0515, 0660, 0661, 0837	Zafar, H.	0953
Yano, F.	0529	Yoshida, M.	0740, 0819	Zafar, S.N.	0953
Yano, T.	0145	Yoshida, T.	0145	Zajac, A.	0296
Yasti, A.C.	1115, 1118, 1119	Yoshifuji, T.	0311, 0376	Zarate, X.	0879
Yasuda, M.	1006	Yoshikawa, K.	0846	Zedenius, J.	0917
Yasuda, T.	0725	Yoshimasu, T.	0406	Zeidan, S.	0449
Yatsuoka, T.	0366	Yoshimatsu, G.	0646	Zellweger, R.	0235
Yau, T.	0925	Yoshimatsu, K.	0370, 0430	Zhang, G.	0099
Yazaki, E.	0474	Yoshinaka, H.	1050	Zhang, J.	0745, 0866
Yeh, C.-C.	0558	Yoshino, O.	0957	Zhang, W.E.B. Z.H.I.	0559
				Zhang, X.	0099
				Zhao, Y.F.	0215
				Zhou, H.	0174, 0745, 0866