

UC Davis
Pediatrics

Title

Diagnostic Challenges of Fever of Unknown Origin Case Report of a Rare Hepatic Abscess in a 2-year-old

Permalink

<https://escholarship.org/uc/item/5939w1ws>

Authors

Mora, Adriana

Anciro, Stephanie

Ginwalla, Cherie

et al.

Publication Date

2023

Data Availability

The data associated with this publication are not available for this reason: N/A

Adriana Mora, BS¹, Stephanie Anciro, MD², Cherie Ginwalla, MD³, Natasha Nakra, MD, MS^{3,4}School of Medicine, University of California, Davis¹, Travis Family Medicine Residency Program, Travis AFB², Department of Pediatrics, University of California, Davis³, Pediatric Infectious Disease⁴

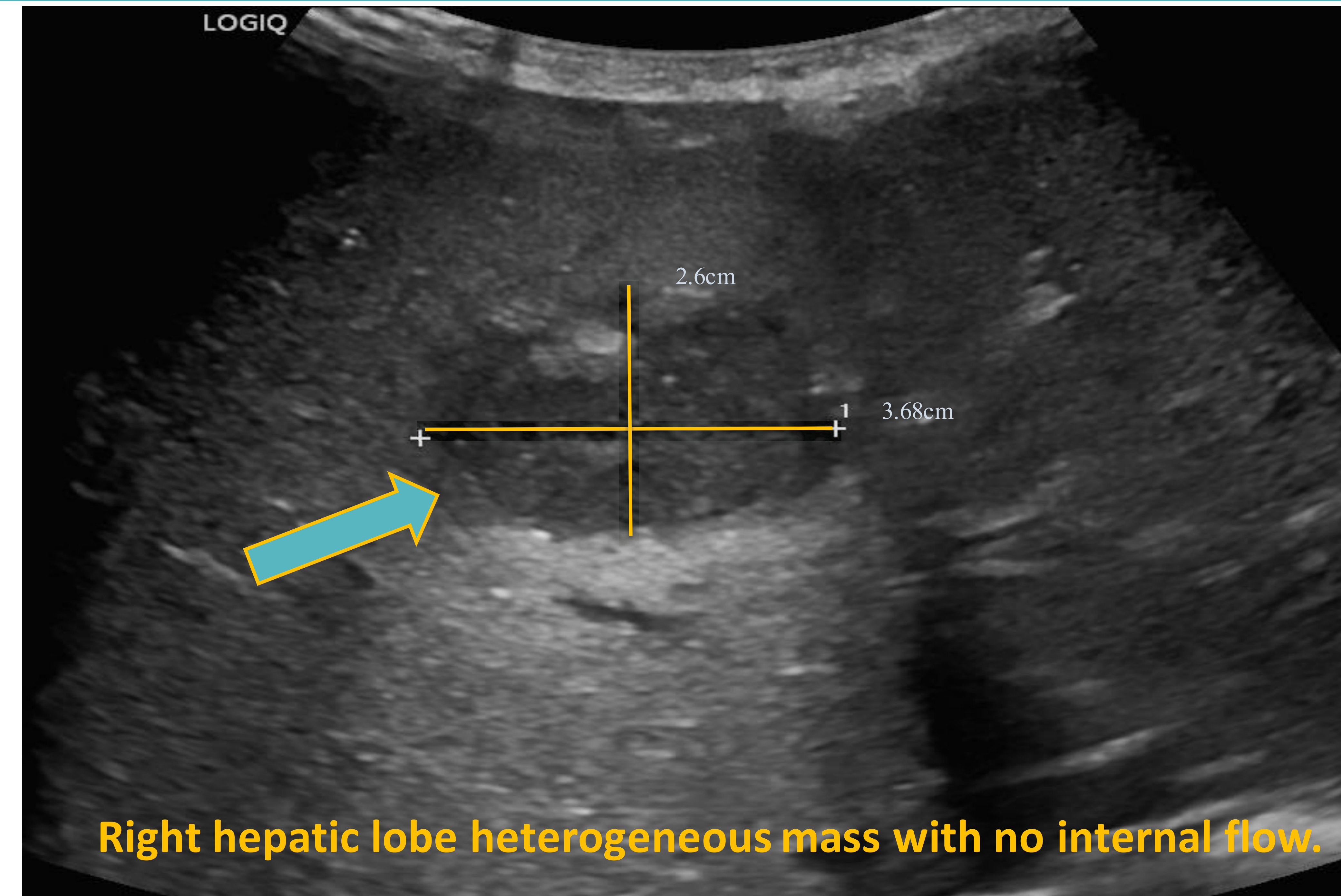
Introduction

- Atypical presentations of conditions make identifying source of Fever of Unknown Origin (FUO) challenging.
- Incidence of hepatic abscesses (HA) in the pediatric population in the U.S. is 25 per 100,000 admissions.
- Most cases occur in children with predisposing factors such as appendicitis or immunocompromised state.

Case presentation

- 2 y.o. presents with 8 days of fever after workup with PCP. Had COVID-19 3 weeks prior.
- Complained of: decreased appetite, fatigue, diaphoresis.
- No cough, no joint swelling and no abdominal pain was present.
- Initial FUO workup was negative including evaluation for bacteremia, pneumonia, MIS-C, Kawasaki Disease, or another intercurrent virus.
- CRP 12.7, ESR 91 and PCT 1.07
- Infectious Disease (ID) was consulted.
- An abdominal ultrasound ultimately revealed the diagnosis.

Abdominal Ultrasound



Clinical Course and Treatment

- Started on empiric antibiotics(abx) for HA coverage: vancomycin, ceftriaxone(CTX) & metronidazole.
- Interventional Radiology placed a hepatic drain. It was removed after 8 days.
- Cultures grew *Streptococcus anginosus*, susceptible to penicillin and CTX, and all other abx were discontinued.
- Patient was successfully transitioned to oral amoxicillin 90mg/kg/day for 2 weeks following recommendations from ID.
- Follow-up US 18 days post discharge showed resolution of abscess.

Conclusions

- 50% of FUO cases end up being infectious, no diagnosis is made in a significant number of cases. Malignancy and collagen vascular diseases are less likely.
- This patient did not show GI symptoms and had no risk factors for HA which made diagnosis challenging.
- Current guidelines for work-up of fevers in children do not include abdominal ultrasound.
- An interdisciplinary team was key in guiding treatment of a rare presentation of FUO such as HA.

References

