

## **UC Irvine**

### **Western Journal of Emergency Medicine: Integrating Emergency Care with Population Health**

#### **Title**

Asymmetrical Bilateral Hip Dislocation

#### **Permalink**

<https://escholarship.org/uc/item/58m9s5cz>

#### **Journal**

Western Journal of Emergency Medicine: Integrating Emergency Care with Population Health, 14(5)

#### **ISSN**

1936-900X

#### **Author**

Lo, Bruce M

#### **Publication Date**

2013

#### **DOI**

10.5811/westjem.2013.2.15968

#### **Copyright Information**

Copyright 2013 by the author(s). This work is made available under the terms of a Creative Commons Attribution-NonCommercial License, available at <https://creativecommons.org/licenses/by-nc/4.0/>

Peer reviewed

# Asymmetrical Bilateral Hip Dislocation

Bruce M. Lo, MD

Eastern Virginia Medical School, Sentara Norfolk General Hospital, Department of  
Emergency Medicine, Norfolk, Virginia

Supervising Section Editor: Sean O. Henderson, MD

Submission history: Submitted January 22, 2012; Accepted February 11, 2013

Full text available through open access at [http://escholarship.org/uc/uciem\\_westjem](http://escholarship.org/uc/uciem_westjem)

DOI: 10.5811/westjem.2013.2.15968

[West J Emerg Med. 2013;14(5):452–452.]

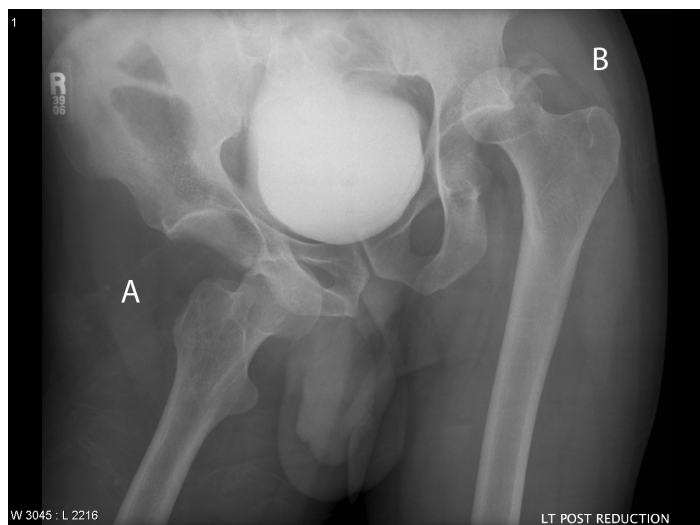
A previously healthy 36-year-old male who was a restrained driver presented with bilateral hip pain after a motor vehicle collision (MVC) put his vehicle in a ditch. On examination, the patient was alert and oriented with stable vitals. His right hip was externally rotated and abducted, and his left hip was internally rotated and adducted. Distal sensation and motor function were intact in both lower extremities. A plain radiograph of his pelvis showed an anterior right hip dislocation and a posterior left hip dislocation with an acetabular fracture (Figure). Patient was taken to the operating room where he underwent successful closed reduction under general anesthesia.

Traumatic hip dislocations are often due to high impact forces, such as occur in a MVC. Posterior hip dislocations are more common (90% of hip dislocations) and occur when force is applied to a hip when adducted, internally rotated and flexed. Anterior dislocations (10% of hip dislocations) are subdivided into inferior and superior. Anterior-inferior hip dislocations (90% of anterior dislocations) occur when force is applied to a hip that is abducted, externally rotated and flexed, whereas anterior-superior hip dislocations (10% of anterior dislocations) occur similarly but with the hip in extension.<sup>1</sup>

Bilateral hip dislocations are unusual and are thought to be associated with a high force of impact in one direction. When asymmetrical dislocations occur, one posterior and one anterior, it is believed that forces in two opposite directions are needed, making it an extremely rare injury.<sup>2,3</sup>

Once a hip dislocation is diagnosed, closed reduction should be attempted. If closed reduction is unsuccessful, open reduction should be performed. Avascular necrosis of the femoral head and major nerve injury, such as sciatic or peroneal can occur, but are more likely to occur if reduction is delayed.<sup>4</sup>

*Address for Correspondence:* Bruce M. Lo, MD, Eastern Virginia Medical School/Sentara Norfolk General Hospital, 600 Gresham Dr. Room 304, Norfolk, VA 23507. Email: [brucelo1@yahoo.com](mailto:brucelo1@yahoo.com).



**Figure.** Right anterior hip dislocation (A) and left posterior hip dislocation (B) with acetabular fracture.

*Conflicts of Interest:* By the WestJEM article submission agreement, all authors are required to disclose all affiliations, funding sources and financial or management relationships that could be perceived as potential sources of bias. The authors disclosed none.

## REFERENCES

1. Clegg TE, Roberts CS, Greene JW, et al. Hip dislocations- Epidemiology, Treatment, and Outcomes. *Injury*. 2010;41:329-334.
2. Sahin O, Ozturk C, Dereboy F, et al. Asymmetrical Bilateral Traumatic Hip Dislocation in an Adult with Bilateral Acetabular Fracture. *Arch Orthop Trauma Surg*. 2007;127:643-646.
3. Pascarella R, Maresca A, Cappuccio M, et al. Asymmetrical Bilateral Traumatic Fracture Dislocation of the Hip: A Report of two Cases. *Chir Organi Mov*. 2008;92:109-111.
4. Tornetta P, Hamid MR. Hip Dislocation: Current Treatment Regimens. *J Am Acad Orthop Surg*. 1997;5:27–36.