

UC Davis

UC Davis Previously Published Works

Title

Sports Hernia

Permalink

<https://escholarship.org/uc/item/565051qt>

Journal

JBS Reviews, 5(9)

ISSN

2329-9185

Authors

Hopkins, Justin Neal
Brown, William
Lee, Cassandra Alda

Publication Date

2017-09-01

DOI

10.2106/jbjs.rvw.17.00022

Copyright Information

This work is made available under the terms of a Creative Commons Attribution-NonCommercial-NoDerivatives License, available at <https://creativecommons.org/licenses/by-nc-nd/4.0/>

Peer reviewed

SPORTS HERNIA: DEFINITION, EVALUATION, AND TREATMENT

Justin Neal Hopkins, MD

William Brown, MD

Cassandra Alda Lee, MD

Investigation performed at the Department of Orthopaedic Surgery, University of California Davis, Sacramento, California

Abstract

» Sports hernia is a non-anatomic, non-diagnostic term that has been attributed to many different causes of groin pain.

» Sports hernia is better described as pain localized anatomically to the inguinal region of an athlete without an actual hernia.

» Nonoperative management including core stability while avoiding extreme hip range of motion should be attempted for at least 2 months prior to any operative intervention.

» Associated pathology such as femoroacetabular impingement or adductor tear should be addressed.

» If a sports hernia is not responsive to rehabilitation, referral to a general surgeon is appropriate.

The sports physician commonly encounters athletes with groin pain. The differential diagnosis is broad, including both orthopaedic disease and visceral disease more appropriately treated by a general surgeon. Sports hernia is one such cause of groin pain, although it is “one of the least understood, poorly defined, and under-researched conditions in medicine.”¹ Much of the evidence that is available stems from outside the orthopaedic literature. However, the orthopaedic team physician should be highly experienced in both recognizing and appropriately treating the spectrum of groin pathology. Furthermore, if nonoperative measures fail, the orthopaedic surgeon should refer the patient appropriately for definitive treatment. Because of the broad differential diagnosis, attempts have been made to standardize the terminology and actual diagnosis of a sports hernia. With more precise terminology, treatment algorithms may be developed.

Definition and Epidemiology

The definition of a sports hernia ranges from a syndrome including chronic groin

pain¹ to a groin disruption resulting from functional pelvic instability². Nonspecific terms include sportsman’s hernia, sportsman’s groin, athletic pubalgia, sports pubalgia, incipient hernia, Gilmore groin, and hockey groin³⁻⁸. Athletes presenting with groin symptoms often come in with one of these generalized diagnoses; however, the best way to target a good outcome is to clarify a more anatomic diagnosis for their symptoms. One such classification system uses adductor, iliopsoas, pubic, or inguinal-related groin pain, with inguinal-related pain most closely representing a sports hernia³ (Fig. 1). Furthermore, the term inguinal disruption has been coined to replace sports hernia, because no true hernia exists⁵.

The epidemiology of sports hernia is difficult to elucidate, given the lack of a consistent definition. In patients with chronic groin pain, sports hernia was found to be the primary diagnosis in 95 (50%) of 189 patients⁹; 40 (80%) of 50 patients with groin pain of unknown etiology were found to have a bulge in the posterior inguinal wall at the time of the surgical procedure¹⁰. Therefore, sports hernia

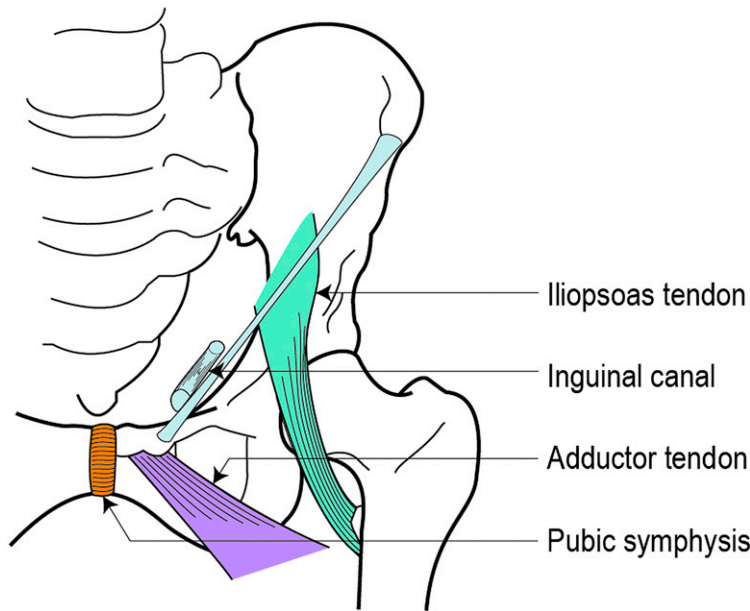


Fig. 1

Illustration showing the anatomic locations of groin pain including the adductor tendon, iliopsoas tendon, pubic symphysis, and inguinal-related locations. Inguinal-related pain most closely represents a sports hernia.

accounts for substantial debilitation given the prevalence of groin pain being approximately 6% of all athletic injuries¹¹. The majority of symptomatic sports hernias requiring operation occur in male patients who play soccer, hockey, football, basketball, cricket, or rugby^{1,2,7,9,12}. The median age of athletes with sports-related groin pain ranges from 26 to 28 years, and only 11 (5%) of 207 patients with sports-related groin were female¹³.

Pathology and Mechanism

In attempting to define the underlying pathology for sports hernias, several different hypotheses have emerged. The most commonly cited mechanism is increased tension in the groin due to high levels of “twisting, turning, sprinting and kicking.”⁵ This tension appears to cause tears or attenuation of inguinal structures that manifests as pain.

Furthermore, loss of hip internal or external rotation may contribute to the etiology of sports hernias given the correlation between loss of range of motion and ipsilateral sports hernia in athletes¹⁴. Loss of motion of the hip may stress the pubic symphysis and lead to instability, suggesting a target of focus for nonoperative treatment. Similarly, femoroacetabular impingement places stress on the hip, which could also predispose to an inguinal injury¹⁵.

Nerve compression or conjoined tendon inflammation may also be the source of pain as a series of patients had been treated successfully without addressing the posterior abdominal wall itself¹⁶. Instead, these 36 patients received radiofrequency denervation of the ilioinguinal nerve and inguinal ligament, with considerable relief compared with corticosteroid injection and prior surgical attempt at repair. However, this treatment is more aimed at the symptoms rather than the underlying pathology.

Muscular balance offers another dimension. During 1-leg stance, as occurs in multiple sports, the adductor muscles work with the abdominal muscles to control and stabilize the pelvis as the hip rotates, adducts, and flexes. Weakness of any of these structures may lead to either instability, stress, or overuse in these soft-tissue structures^{6,7}. For that reason, sports hernia may be approached as a syndrome that includes abdominal and adductor pain, in addition to the inguinal pain¹⁷.

A single pathology does not define sports hernia; abnormal tension exists in the inguinal canal, causing pain. This tension may manifest as posterior abdominal wall weakness, superficial inguinal ring dilation, and tears of the conjoined tendon, external oblique muscle, or inguinal ligament⁵. Although these specific processes may not be

present, they all point to a deficit of the inguinal canal without true herniation.

Anatomy

The anatomy of the groin is complex, with a coalescence of muscles, tendons, and nerves¹², which is why sports hernia is so confusing. All of these structures have proximity to the pubic symphysis and the balance point between the adductor and abdominal muscles.

Beginning superficially in the abdomen, the external oblique muscle originates on the ribs and inserts on the iliac crest, anterior superior iliac spine, and pubic tubercle. The inferior aponeurosis runs from the anterior superior iliac spine to the pubic tubercle and is termed the inguinal ligament. The internal oblique muscle originates on the rib costocartilage, iliac crest, and lateral inguinal ligament, serving as the superior portion of the inguinal canal and wrapping around the spermatic cord or round ligament as it runs through the inguinal canal. The transversus abdominis originates on the thoracolumbar fascia, rib costocartilage, iliac crest, and lateral inguinal ligament. The transversus abdominis and internal oblique muscles combine to form the conjoined tendon at the medial aspect of the inguinal canal. The deepest structure of the abdominal wall is the transversalis

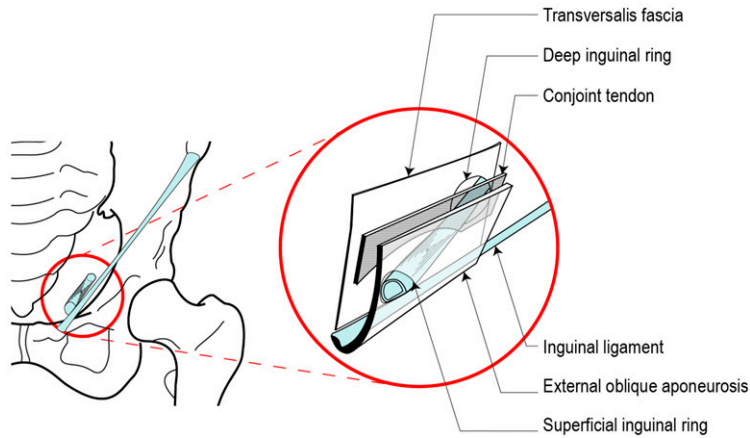


Fig. 2
Illustration of the abdominal wall layers and their contributions to the inguinal canal.

fascia⁷. Superficially at the superior lateral pubic tubercle lies the external inguinal ring where the spermatic cord or round ligament exit the external oblique muscle. The pubic aponeurosis is a combination of the rectus abdominis, conjoint tendon, and external oblique muscle, and it also connects these structures to the adductor origin⁷, thus

creating the most critical structural balance between the adductors and abdominal muscles⁸ (Fig. 2).

The ilioinguinal nerve runs deep to the external oblique muscle to innervate the medial aspect of the thigh and scrotum or labia majora. The iliohypogastric nerve runs superior to the ilioinguinal nerve. After piercing the transverse

abdominis muscle, it innervates the hypogastric area and iliac crest. Lastly, the genitofemoral nerve runs anteriorly to the psoas major muscle before splitting and innervating the skin of the upper thigh and anterior scrotum or mons. The genital branch of the genitofemoral nerve and the ilioinguinal nerve run through the inguinal canal along with

Fig. 3
Illustration showing the iliohypogastric, ilioinguinal, and genitofemoral nerve pathways and corresponding dermatomes.

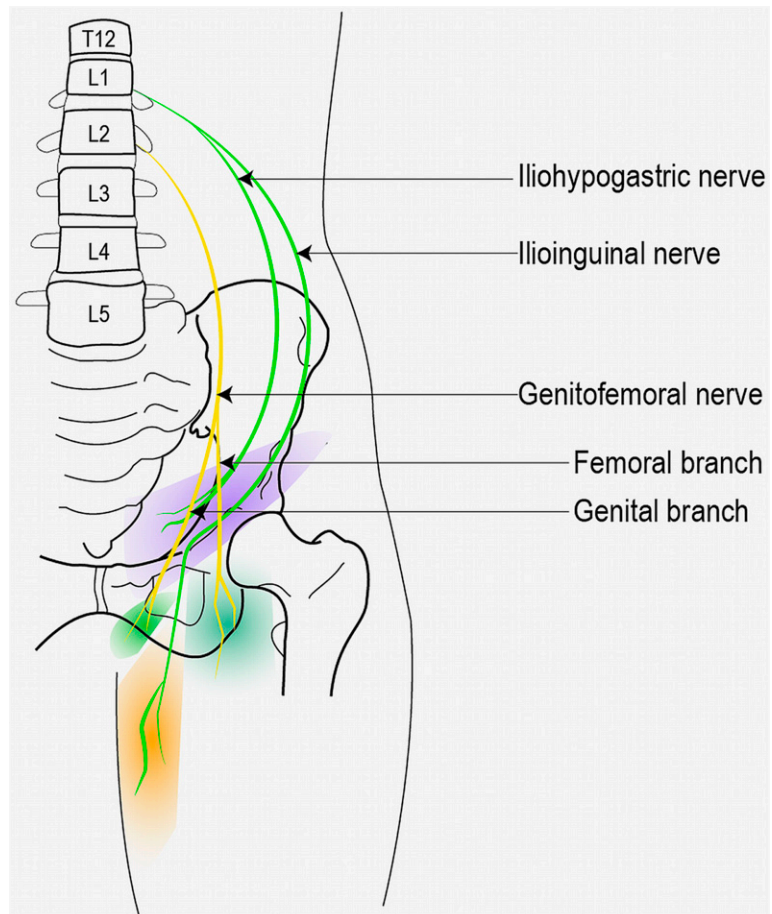


TABLE I Differential Diagnosis of Inguinal Pain

Proposed causes of sports hernia
Conjoined tendon inflammation or tear ^{5,16}
Inguinal ligament tear ⁵
External oblique muscle tear ⁵
Posterior abdominal wall attenuation ^{5,10}
Superficial inguinal ring dilation ⁵
Inguinal location not attributable to sports hernia
Inguinal hernia ¹¹
Nerve compression ^{11,16}
Other key diagnoses or associated pathology
Pubic instability ¹⁴
Osteitis pubis ¹³
Adductor strain or tear ¹³
Femoroacetabular impingement ²¹
Iliopsoas strain or tear ^{11,13}
Snapping iliopsoas ^{11,13}
Rectus abdominis strain or tear ^{11,13}

the spermatic cord or round ligament¹⁸ (Fig. 3).

Differential Diagnosis

The differential for groin pain includes intra-abdominal disorders, inguinal hernia, urogenital pathology, lumbar disc disease, intra-articular hip pathology, muscle or ligament strain, nerve entrapment, bursitis, fracture, sacrotuberal ligament pain, sacroiliac joint dysfunction, piriformis-related pain, pelvic floor-related pain, and a soft-tissue mass^{12,13,16,19}. It is important to distinguish a sports hernia from other causes of inguinal pain that are derived from different anatomic locations or may occur concurrently with it (Table I).

Furthermore, 69 (33%) of 207 athletes with groin-related pain were found to have a secondary or tertiary clinical entity in addition to their primary diagnosis. Commonly adductor, rectus, and iliopsoas-related pain were found together, further confounding the anatomic classification scheme (Fig. 1). Osteitis pubis and adductor-related pain may even be a part of the same clinical entity or syndrome given the close interplay of these structures^{13,17}.

Other important concurrent pathology in sports hernia includes

femoroacetabular impingement. Underlying femoroacetabular impingement has been found to be present in 37 (86%) of 43 patients treated for sports hernia. Those patients had continued groin pain despite treatment for the hernia alone. Femoroacetabular impingement on imaging may be predictive of poor outcomes after groin surgery; however, perhaps concomitant orthopaedic treatment of impingement could lead to a more successful outcome²⁰.

Presentation

Sufficient time should be allotted with the patient to obtain a good history and perform a careful physical examination. Often, the diagnosis can be determined without the need for advanced imaging or ultrasound.

History

Patients report groin pain that is primarily at the pubic symphysis and radiates through the rectus abdominis or adductor tendon. Symptoms are worsened by athletic activity such as kicking, cutting, or sprinting, especially with acceleration and deceleration, and are alleviated by rest^{2,21}. Coughing may cause pain, and the pain may radiate into the thigh or testicles given nearby nerve distributions²¹.

Physical Examination

For sports hernia, examination often reveals tenderness to palpation of the inguinal region just above the inguinal ligament and near the pubis²². The crunch test (resisted sit-up) produces pain at the pubic crest². Also, there may be tenderness at the superficial inguinal ring without appreciation of a frank hernia². Hip internal and external rotation may be decreased^{2,14}. Other anatomic sources of pain should also be assessed through physical examination. Palpation of the adductor origin and assessment of resisted adduction are important to assess for adductor-type pain. Iliopsoas-type pain is assessed with palpation of the abdomen just proximal and distal to the inguinal ligament, as well as pain with passive extension of the hip. There may be snapping of the iliopsoas tendon as well.

Palpation of the insertion of the rectus abdominis on the pubic bone and pain in the abdominal musculature with resisted contraction are diagnostic techniques to assess for rectus abdominis-type pain and may be a more specific diagnosis than pubic pain. A visible or palpable inguinal mass, if present, points to a frank hernia compared with a sports hernia.

Our Suggestions for Clinical Workup of a Suspected Sports Hernia

Begin by eliciting the patient's history to determine the most likely location of the pain.

Pubic Symphysis

Osteitis pubis is the most likely etiology. This patient is often a distance runner. Rolling over in bed is painful. With rest, the pain improves. The pain is usually insidious in onset. There is usually pain with direct pressure over the symphysis pubis and the edges of the joint are irregular. To confirm the diagnosis, inject the symphysis with lidocaine. In underweight or normal-weight patients, this can be easily done with palpation. In overweight or obese patients, ultrasound can serve as a guide. In patients with osteitis pubis, the joint is damaged and will easily accept 10 mL of lidocaine, whereas a normal, undamaged joint will accept only

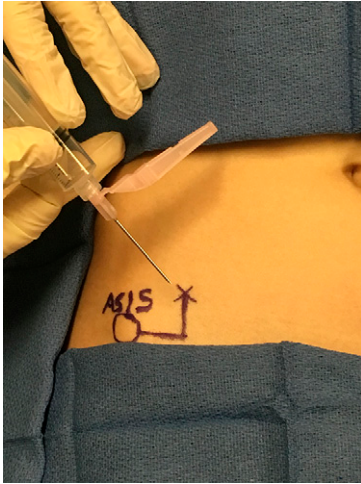


Fig. 4

A photograph showing that pain secondary to ilioinguinal and iliohypogastric nerves can be confirmed by performing a lidocaine injection using the anterior superior iliac spine (ASIS) as a landmark. If positive, vague pain radiating toward the groin from the lower abdomen will be relieved.

a few milliliters of lidocaine. The athlete should be warned that the injection is usually painful. After receiving the lidocaine injection, the athlete will experience a fairly immediate relief of pain and may resume athletic activities. However, because lidocaine is short-acting, the injection is for diagnostic purposes and is not a long-term solution.

External Inguinal Ring (Lateral Border of the Origin of the Rectus Abdominis Muscle)

This often involves an injury to the external oblique muscle. The patient

participates in a sport that requires rapid change of direction such as soccer or hockey. The onset is usually insidious. Pressure over the external ring with contraction of the core muscles will often reproduce the pain. When the scrotum is digitally inverted, a normal external inguinal ring will usually only accept the tip of the finger. However, in athletes with a tear of the external oblique muscle, the external ring is enlarged and the tip of the finger passes easily into the inguinal canal. Coughing with the scrotum inverted in this manner will reproduce the patient's pain. To confirm the diagnosis, lidocaine can be injected just deep to the external oblique muscle at the external inguinal ring. As above, the athlete will experience a fairly immediate relief of pain after receiving the lidocaine injection and may resume athletic activities, but only for a short period of time.

Pubic Tubercle

This often represents an injury to the inguinal ligament. The athlete reports chronic pain at that site that is aggravated by acceleration and cutting. The pain usually has a slow onset. Direct pressure over the pubic tubercle and the medial attachment of the inguinal ligament causes pain. The pubic tubercle is often thickened when compared with the contralateral side. To confirm, lidocaine can be injected into the medial attachment of the inguinal ligament. Again, the lidocaine injection, although short-acting, will result in the athlete experiencing a fairly immediate relief of pain

and being able to resume athletic activities, but only for a short period of time.

Vague or Diffuse Lower Abdomen Pain

Nerve pain often runs from near the anterior superior iliac spine toward the pubic symphysis. It will often involve the inside of the thigh and the lateral aspect of the scrotum or mons pubis. The pain is aggravated by twisting motions and insidious in onset. Often, there will be sensory changes as well. Occasionally, there is a trigger point, but more commonly the examination is benign. Perform an ilioinguinal and iliohypogastric nerve block using the anterior superior iliac spine as a landmark to confirm the diagnosis by relief of the pain (Fig. 4).

Adductor Longus Tendon

Pain high on the medial aspect of the thigh is almost always an injury to the adductor longus tendon. The athlete will report pain with cutting, with kicking a ball with the inside of the foot, and with acceleration. Often, the athlete will remember a pop at the time of the original injury. The pain is located at the origin or approximately 10 cm below and pain will be reproduced with resisted hip adduction. Often, the tendon will be of small caliber but remain attached. To inject the origin of the adductor longus, the patient should lie supine. The knee should then be flexed and the hip should be abducted to identify the origin. Again, the athlete

TABLE II Criteria for the Diagnosis of Sports Hernia as Described by the British Hernia Society^{5*†}

1	Pain that is described as dull or diffuse and radiates to the medial aspect of the thigh, perineum, or contralateral side
2	Tenderness to palpation over the pubic tubercle at the insertion of the inguinal ligament
3	Tenderness to palpation of the deep inguinal ring
4	Tenderness to palpation of the adductor longus tendon
5	Tenderness or dilation of the superficial inguinal ring

*Three criteria must be met for diagnosis. †Data for this table were obtained from: Sheen AJ, Stephenson BM, Lloyd DM, Robinson P, Fevre D, Paajanen H, de Beaux A, Kingsnorth A, Gilmore OJ, Bennett D, MacLennan I, O'Dwyer P, Sanders D, Kurzer M. Treatment of the sportsman's groin: British Hernia Society's 2014 position statement based on the Manchester Consensus Conference. *Br J Sports Med.* 2014 Jul;48(14):1079-87. Epub 2013 Oct 22.

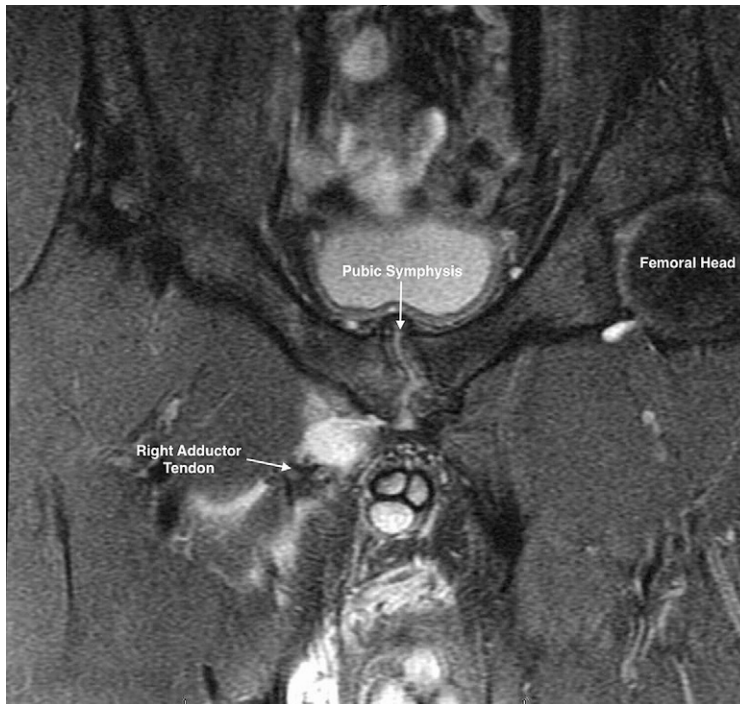


Fig. 5
Oblique axial fat-suppressed MRI showing a complete avulsion and retraction of the right adductor longus tendon. The pubic symphysis has hypertrophic changes and irregularity.

should be able to briefly resume athletic activities nearly pain-free after the injection.

Criteria for Diagnosis

Overall, the sports hernia diagnosis can be made on the basis of 3 of the following 5 signs: (1) pain that is described as dull or diffuse and radiates to the medial aspect of the thigh, perineum, or contralateral side; (2) tenderness to palpation over the pubic tubercle at the insertion of the inguinal ligament; (3) tenderness to palpation of the deep inguinal ring; (4) tenderness to palpation of the adductor longus tendon; and (5) tenderness or dilation of the superficial inguinal ring⁵ (Table II).

Imaging

Radiographs of the pelvis and hip are an important first step to evaluate the osseous structures and to rule out other diagnoses in the differential²¹. Ultrasound and computed tomography (CT) may also be used to show an inguinal bulge that is not appreciated on examination²¹⁻²³. Magnetic resonance imaging (MRI) remains the primary tool in diagnosis, as it is able to rule out or to identify associated pathologies. It is

therefore important that the field of view is sufficiently large.

The most common MRI finding is an ipsilateral rectus abdominis strain or tear from the pubic ramus and a partial or complete adductor longus detachment^{1,21} (Fig. 5). MRI had a sensitivity of 68% and specificity of 100% for rectus abdominis tendon injury (91 patients) and a sensitivity of 86% and specificity of 89% for adductor tendon injury (74 patients)⁴. Pubic symphysis bone edema may be present^{20,22} and may increase after surgical intervention. However, up to one-third of patients may not have any noted pathology on MRI¹.

CT arthrography with injection into the pubic symphyseal fibrocartilaginous disc may elucidate tears of the rectus or adductors not appreciated by MRI²³. CT arthrography may be therapeutic, in relieving groin pain, as well as diagnostic.

Such injections can also be made through fluoroscopic or ultrasound-guided means, again allowing visualization of the dye if it were to track into the rectus abdominis or adductor aponeurosis²¹.

In contrast to the above studies for sports hernia, femoroacetabular

impingement must also be evaluated. A labral tear can also be present. Deep pain or impingement on examination may indicate the need for false-profile and modified Dunn radiographs²⁴. Furthermore, MR arthrography may be warranted to further assess this common concurrent pathology⁷.

Treatment and Outcomes

Given the variety of treatment options in the literature, the British Hernia Society recommends that the choice of surgery and operative approach be based on surgeon experience⁵. A minimum of 2 months of rehabilitation prior to any surgical intervention should be attempted first, whereas other studies have recommended waiting 3 to 6 months prior to surgical treatment in athletes^{7,22}.

The initial nonoperative management protocol should include postural and range-of-motion assessment. Specific exercises should include strengthening of the gluteus medius and maximus, transversus abdominis, erector spinae, lateral abdominals, hip flexors, and hamstrings. Focus should be on core strengthening with avoidance of

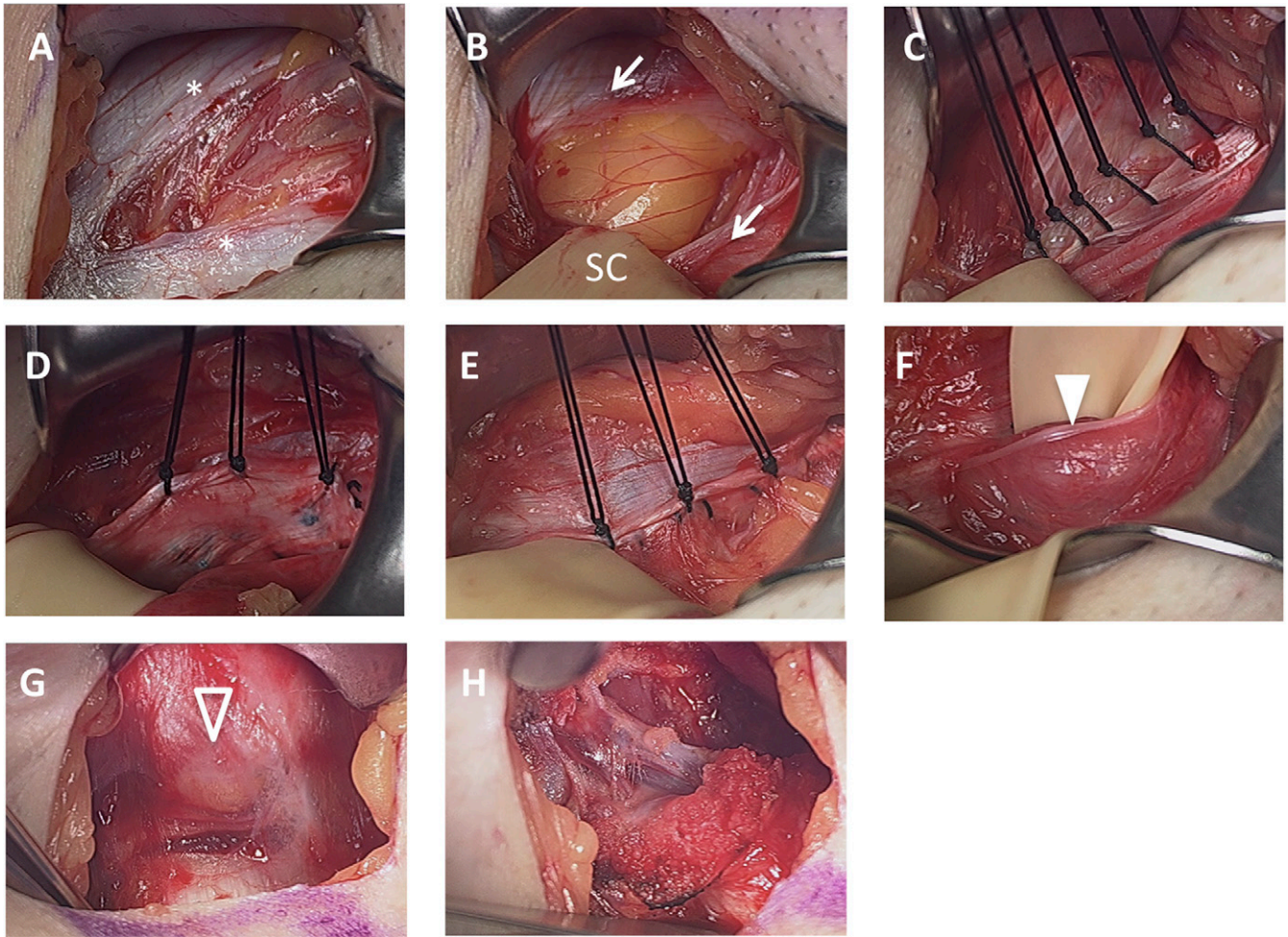


Fig. 6

Figs. 6-A through 6-H Intraoperative photographs from open sports hernia repair and adductor tenotomy. **Fig. 6-A** The external oblique muscle, indicated by the asterisks, is torn with the underlying spermatic cord between the upper and lower edges. **Fig. 6-B** A Penrose drain is placed around the spermatic cord (SC), retracting it inferiorly to show the transversalis fascia (arrows) torn with fat underneath. **Fig. 6-C** The transversalis fascia is repaired back to the inguinal ligament with sutures to reconstruct the floor of the inguinal canal. **Fig. 6-D** The lower edge of the external oblique muscle is pulled up for the first layer of repair. **Fig. 6-E** The upper edge of the external oblique muscle is pulled down for the second layer of repair. **Fig. 6-F** The spermatic cord is brought back into place over the external oblique muscle with the ilioinguinal nerve intact (arrowhead). **Fig. 6-G** A separate incision shows the adductor longus insertion with a scar (arrowhead) consistent with a chronic tear. Inferiorly, the adductor longus tendon is visible with healthier-appearing tissue. **Fig. 6-H** The adductor longus tenotomy has been completed.

deep hip flexion. Modalities used can include Swiss balls, core exercises, medicine balls, pulleys and clinibands, dynamic posture stability, stretching, swimming, and yoga. The overall goal of nonoperative management is to emphasize the stabilizers of functional movement and posture. Furthermore, it is important to make the treatment as sport-specific as possible^{5,7}. Given the high correlation between sports hernia and femoroacetabular impingement, stretching and range-of-motion regimens can sometimes exacerbate symptoms²¹.

Other nonoperative treatment protocols described include an initial rest, activity modification, and core muscle strengthening incorporating a transition from non-weight-bearing positions to functional upright postures²⁵. As the patient demonstrates appropriate form, resistance is gradually added. Eventually, speed and plyometric activities are included when the patient can perform a supine crunch without pain. A return to sport-specific activities is also added at this time.

If pain continues after 2 to 6 months of nonoperative rehabilitation, a

surgical procedure is indicated. A surgical procedure for sports hernia can be performed through open, minimally invasive, or laparoscopic repair techniques (Fig. 6). A laparoscopic approach with extraperitoneal inguinal hernia-type repair with synthetic mesh and concomitant adductor longus tenotomy has been shown to return athletes to sports-related activity at a mean time of 24 days postoperatively¹. Adductor tenotomy has also been used in isolation²⁶.

In contrast, Mei-Dan et al. conducted a retrospective, nonrandomized

study of 155 soccer players diagnosed with sports hernia on ultrasound who also had adductor tendon pain⁸. No significant difference was found between the 96 patients treated with adductor tenotomy only compared with combined adductor tenotomy with laparoscopic hernia treatment with mesh in terms of time to return to play, subjective outcomes, and activity level. Adductor release may correct the imbalance across the pubic symphysis, and, for that reason, patients in this series all underwent bilateral adductor releases.

With regard to hernia repair, both open and minimally invasive methods are supported^{16,21,27,28}. A retrospective study compared an open modified-type repair to an open minimally invasive repair²⁹. The modified technique employed plicating the rectus abdominis fascia to the pubis and inguinal ligament to strengthen the posterior abdominal wall. However, the newer minimally invasive technique incorporated decompression of the genital branch of the genitofemoral nerve and opening the posterior abdominal wall with repair of the transversalis fascia. The authors found that athletes returned to play at a mean time of 5.6 weeks with the minimal repair, compared with 25.8 weeks for those who underwent the larger open repair. The authors suggested that the minimal iatrogenic soft-tissue damage and the nerve decompression were important for the early return. Similarly, endoscopic repair using mesh was shown to provide significantly lower pain scale scores compared with nonoperative treatment²⁷. Because of chronic pain, 7 (23%) of 30 patients switched over to the operatively treated group.

For National Hockey League players undergoing various surgical procedures for sports hernia, Jakoi et al. showed that players were often able to return to a similar level of performance after the surgical procedure²⁸. Those players with >7 years of experience who underwent an operation played in fewer games, scored fewer goals, obtained

fewer assists, and had less mean time on the ice. Younger players only saw a difference in the number of games played. Productivity, as defined by minutes per goal, did not change in either group. This supports the statement that the overall surgical approach should be based on surgeon preference and experience.

Nerve decompression can also be performed without opening the posterior abdominal wall. As previously mentioned, in a randomized clinical trial, the authors compared radiofrequency denervation of the ilioinguinal nerve and ligament with local anesthetic injection¹⁶. Radiofrequency denervation was successful in treating groin pain up through 6 months and also successfully treated pain in those patients with failed surgical treatment, whereas injection only relieved symptoms for 1 week. The authors questioned the need to address the posterior abdominal wall surgically and also provided a treatment that could defer a definitive treatment until offseason. This could also potentially prevent complications of surgical procedures and allow continued performance.

Finally, as discussed earlier, Economopoulos et al. showed femoroacetabular impingement to be a poor predictor of successful surgery²⁹. Larson et al. supported this conclusion in their retrospective study of 37 patients with symptomatic sports hernia-type pathology and intra-articular hip pathology⁷. They found that 11 (69%) of 16 patients who underwent a sports hernia surgery subsequently required hip arthroscopy and 3 of 8 patients who underwent a hip arthroscopy eventually needed a sports hernia procedure. Furthermore, either concurrent or staged surgical procedures incorporating both procedures led to an improved Harris hip score, with 24 (89%) of 27 patients returning to unrestricted sports, and no difference if the procedures were staged or concurrent. This calls for a multidisciplinary approach between general and orthopaedic surgeons. The ultimate surgical choice should be based on surgeon

preference, but most importantly, all pathologic structures involved should be addressed.

Conclusions

Groin pain is a commonly encountered symptom for the orthopaedic team physician; it is important to understand the anatomy that clarifies the differential and diagnostic criteria for sports hernia. Although a variety of definitions exist in the literature, pain centered at the inguinal canal, without frank hernia, best defines a sports hernia. Multiple injuries can fall within this non-diagnostic term. Upon diagnosis, nonoperative treatment should be initiated, followed by referral to a general surgeon if recalcitrant to therapy. Associated conditions should also be treated, such as femoroacetabular impingement or adductor tears. If appropriately managed, sports hernia treatment can be successful, and therefore it is important for the orthopaedic surgeon to be knowledgeable of this pathology.

NOTE: The authors would like to acknowledge Michelle Hecht for creating the medical illustrations for this manuscript for Figures 1, 2, and 3.

Justin Neal Hopkins, MD¹,
William Brown, MD²,
Cassandra Alda Lee, MD¹

¹Department of Orthopaedic Surgery,
University of California Davis,
Sacramento, California

²SportsHernia.com, Fremont, California

E-mail address for J.N. Hopkins:
hopkins@ucdavis.edu
E-mail address for W. Brown:
drbrown@sportshernia.com
E-mail address for C.A. Lee:
casslee@ucdavis.edu

ORCID iD for C.A. Lee: [0000-0003-2610-9584](https://orcid.org/0000-0003-2610-9584)

References

1. Rossidis G, Perry A, Abbas H, Motamarry I, Lux T, Farmer K, Moser M, Clugston J, Caban A, Ben-David K. Laparoscopic hernia repair with adductor tenotomy for athletic pubalgia: an established procedure for an obscure entity.

- Surg Endosc. 2015 Feb;29(2):381-6. Epub 2014 Jul 2.
2. Garvey JF, Hazard H. Sports hernia or groin disruption injury? Chronic athletic groin pain: a retrospective study of 100 patients with long-term follow-up. *Hernia*. 2014;18(6):815-23. Epub 2013 Oct 12.
 3. Weir A, Brukner P, Delahunty E, Ekstrand J, Griffin D, Khan KM, Lovell G, Meyers WC, Muschaweck U, Orchard J, Paajanen H, Philippon M, Reboul G, Robinson P, Schache AG, Schilders E, Serner A, Silvers H, Thorborg K, Tyler T, Verrall G, de Vos RJ, Vuckovic Z, Hölmich P. Doha agreement meeting on terminology and definitions in groin pain in athletes. *Br J Sports Med*. 2015 Jun;49(12):768-74.
 4. Zoga AC, Kavanagh EC, Omar IM, Morrison WB, Koulouris G, Lopez H, Chaabra A, Domesek J, Meyers WC. Athletic pubalgia and the "sports hernia": MR imaging findings. *Radiology*. 2008 Jun;247(3):797-807.
 5. Sheen AJ, Stephenson BM, Lloyd DM, Robinson P, Fevre D, Paajanen H, de Beaux A, Kingsnorth A, Gilmore OJ, Bennett D, MacLennan I, O'Dwyer P, Sanders D, Kurzer M. Treatment of the sportsman's groin: British Hernia Society's 2014 position statement based on the Manchester Consensus Conference. *Br J Sports Med*. 2014 Jul;48(14):1079-87. Epub 2013 Oct 22.
 6. Farber AJ, Wilckens JH. Sports hernia: diagnosis and therapeutic approach. *J Am Acad Orthop Surg*. 2007 Aug;15(8):507-14.
 7. Larson CM, Pierce BR, Giveans MR. Treatment of athletes with symptomatic intra-articular hip pathology and athletic pubalgia/sports hernia: a case series. *Arthroscopy*. 2011 Jun;27(6):768-75.
 8. Mei-Dan O, Lopez V, Carmont MR, McConkey MO, Steinbacher G, Alvarez PD, Cugat RB. Adductor tenotomy as a treatment for groin pain in professional soccer players. *Orthopedics*. 2013 Sep;36(9):e1189-97.
 9. Lovell G. The diagnosis of chronic groin pain in athletes: a review of 189 cases. *Aust J Sci Med Sport*. 1995 Sep;27(3):76-9.
 10. Malycha P, Lovell G. Inguinal surgery in athletes with chronic groin pain: the 'sportsman's' hernia. *Aust N Z J Surg*. 1992 Feb;62(2):123-5.
 11. Suarez JC, Ely EE, Mutnal AB, Figueroa NM, Klika AK, Patel PD, Barsoum WK. Comprehensive approach to the evaluation of groin pain. *J Am Acad Orthop Surg*. 2013 Sep;21(9):558-70.
 12. Nam A, Brody F. Management and therapy for sports hernia. *J Am Coll Surg*. 2008 Jan;206(1):154-64. Epub 2007 Oct 18.
 13. Hölmich P. Long-standing groin pain in sportspeople falls into three primary patterns, a "clinical entity" approach: a prospective study of 207 patients. *Br J Sports Med*. 2007 Apr;41(4):247-52; discussion 252. Epub 2007 Jan 29.
 14. Rambani R, Hackney R. Loss of range of motion of the hip joint: a hypothesis for etiology of sports hernia. *Muscles Ligaments Tendons J*. 2015 Mar 27;5(1):29-32.
 15. Strosberg DS, Ellis TJ, Renton DB. The role of femoroacetabular impingement in core muscle injury/athletic pubalgia: diagnosis and management. *Front Surg*. 2016 Feb 12;3:6.
 16. Comin J, Obaid H, Lammers G, Moore J, Wotherspoon M, Connell D. Radiofrequency denervation of the inguinal ligament for the treatment of 'sportsman's hernia': a pilot study. *Br J Sports Med*. 2013 Apr;47(6):380-6. Epub 2012 Sep 5.
 17. Biedert RM, Warnke K, Meyer S. Symphysis syndrome in athletes: surgical treatment for chronic lower abdominal, groin, and adductor pain in athletes. *Clin J Sport Med*. 2003 Sep;13(5):278-84.
 18. Dimitrakopoulou A, Schilders E. Sportsman's hernia? An ambiguous term. *J Hip Preserv Surg*. 2016 Feb 24;3(1):16-22.
 19. Mullens FE, Zoga AC, Morrison WB, Meyers WC. Review of MRI technique and imaging findings in athletic pubalgia and the "sports hernia". *Eur J Radiol*. 2012 Dec;81(12):3780-92. Epub 2011 Sep 3.
 20. Economopoulos KJ, Milewski MD, Hanks JB, Hart JM, Diduch DR. Radiographic evidence of femoroacetabular impingement in athletes with athletic pubalgia. *Sports Health*. 2014 Mar;6(2):171-7.
 21. Larson CM. Sports hernia/athletic pubalgia: evaluation and management. *Sports Health*. 2014 Mar;6(2):139-44.
 22. Kuikka L, Hermunen H, Paajanen H. Effect of pubic bone marrow edema on recovery from endoscopic surgery for athletic pubalgia. *Scand J Med Sci Sports*. 2015 Feb;25(1):98-103. Epub 2013 Dec 18.
 23. McArthur TA, Narducci CA, Lopez-Ben RR. The role of pubic symphyseal CT arthrography in the imaging of athletic pubalgia. *AJR Am J Roentgenol*. 2014 Nov;203(5):1063-8.
 24. Meyer DC, Beck M, Ellis T, Ganz R, Leunig M. Comparison of six radiographic projections to assess femoral head/neck asphericity. *Clin Orthop Relat Res*. 2006 Apr;445:181-5.
 25. Becker LC, Kohlireser DA. Conservative management of sports hernia in a professional golfer: a case report. *Int J Sports Phys Ther*. 2014 Nov;9(6):851-60.
 26. Akermark C, Johansson C. Tenotomy of the adductor longus tendon in the treatment of chronic groin pain in athletes. *Am J Sports Med*. 1992 Nov-Dec;20(6):640-3.
 27. Paajanen H, Brinck T, Hermunen H, Airo I. Laparoscopic surgery for chronic groin pain in athletes is more effective than nonoperative treatment: a randomized clinical trial with magnetic resonance imaging of 60 patients with sportsman's hernia (athletic pubalgia). *Surgery*. 2011 Jul;150(1):99-107. Epub 2011 May 5.
 28. Jakoi A, O'Neill C, Damsgaard C, Fehring K, Tom J. Sports hernia in National Hockey League players: does surgery affect performance? *Am J Sports Med*. 2013 Jan;41(1):107-10. Epub 2012 Oct 29.
 29. Economopoulos KJ, Milewski MD, Hanks JB, Hart JM, Diduch DR. Sports hernia treatment: modified Bassini versus minimal repair. *Sports Health*. 2013 Sep;5(5):463-9.