

# UC Davis

## Dermatology Online Journal

### Title

Mycoplasma-induced pustulosis with perifollicular involvement

### Permalink

<https://escholarship.org/uc/item/5584k6b1>

### Journal

Dermatology Online Journal, 24(3)

### Authors

Chao, Kevin  
Balin, Samuel  
Worswick, Scott

### Publication Date

2018

### DOI

10.5070/D3243038610

### Copyright Information

Copyright 2018 by the author(s). This work is made available under the terms of a Creative Commons Attribution-NonCommercial-NoDerivatives License, available at <https://creativecommons.org/licenses/by-nc-nd/4.0/>

Peer reviewed

# Mycoplasma-induced pustulosis with perifollicular involvement

Kevin Chao BS<sup>1</sup>, Samuel Balin MD<sup>2</sup>, Eric Sorenson MD<sup>2</sup>, Scott Worswick MD<sup>2</sup>

Affiliations: <sup>1</sup>David Geffen School of Medicine at UCLA, <sup>2</sup>Department of Medicine, Division of Dermatology, David Geffen School of Medicine at UCLA, Los Angeles, California, USA

Corresponding Author: Kevin Chao, 2137 Kerwood Avenue, Los Angeles, CA, 90025, Tel: (916) 475-4222, Email: [kychao@mednet.ucla.edu](mailto:kychao@mednet.ucla.edu)

## Abstract

*Mycoplasma pneumoniae*-induced rash and mucositis (MIRM) is a disease characterized by mucosal involvement with variable cutaneous manifestations induced by *M. pneumoniae* infection. Previously reported rash morphologies include vesiculobullous, targetoid, papular, macular, and morbilliform lesions. Pustulosis is a rare presentation of MIRM that has been described only once before in the literature to our knowledge. We report a case of a 13-year-old boy presenting with a pustular skin eruption induced by *Mycoplasma* infection. Ours' is the second report of MIRM, to our knowledge, presenting with pustulosis and the first, to our knowledge, to first to describe the histopathologic finding of perifollicular neutrophilic infiltration in MIRM.

**Keywords:** *Mycoplasma pneumoniae*-induced rash and mucositis, MIRM, pustulosis

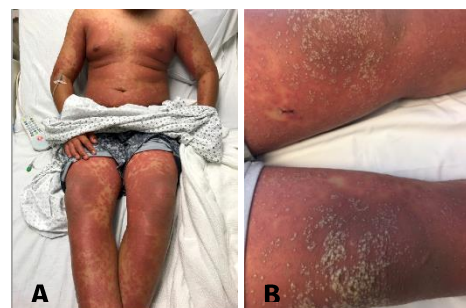## Introduction

*Mycoplasma pneumoniae*-induced rash and mucositis is a clinical entity recently described as distinct from erythema multiforme (EM), Stevens-Johnson syndrome (SJS), and toxic epidermal necrolysis (TEN) based on an association with *M. pneumoniae* and unique clinical characteristics [1]. We report a unique case of a 13-year-old boy with *Mycoplasma pneumoniae*-induced pustulosis with histopathologic findings demonstrating

perifollicular neutrophilic infiltration and subcorneal pustules.

## Case Synopsis

A previously healthy 13-year-old boy presented with a six-day history of a progressive rash associated with pruritus and burning sensation. He also had fevers, arthralgias, and recent nonproductive cough and rhinorrhea. Physical examination revealed pink-to-dusky macules coalescing into patches, scattered targetoid lesions, and erythematous indurated plaques with multiple overlying one millimeter (mm) pustules distributed diffusely on the back, chest, axillae, abdomen, arms, and legs (**Figure 1**). Erythematous macules on the buccal mucosa and a small erosion on the hard palate were also noted. An ophthalmology exam revealed conjunctival injection with diffuse flecks of subconjunctival hemorrhage and no fluorescein staining.



**Figure 1.** **A)** Diffusely distributed erythematous patches and indurated plaques on the abdomen, arms, and legs. **B)** Diffuse erythematous indurated plaques studded with multiple pustules on the lower extremities.

Prior to admission, the patient had been given loratadine, diphenhydramine, triamcinolone 0.1% cream, and a five-day course of oral prednisone 50 milligrams (mg) daily with no improvement. No other medications had been introduced prior to the eruption.

A dermatology consult was requested and skin biopsy demonstrated acute suppurative folliculitis and perifolliculitis with subcorneal pustule formation and neutrophilic spongiosis with eosinophils (**Figure 2**). Direct immunofluorescence studies were negative. Laboratory tests showed an increased white cell count and neutrophilia in the setting of systemic steroids prior to admission. A chest X-ray showed interstitial infiltrates suggestive of an atypical pneumonia. Complete metabolic panel, anti-streptolysin O, and anti-DNAse B were within normal limits. The patient was initiated on intravenous vancomycin and clindamycin. The day following admission, conjunctival erythema was noted. At this time, dermatology recommended treatment with doxycycline or erythromycin given concern for *Mycoplasma*-induced skin, pulmonary, and mucosal disease.

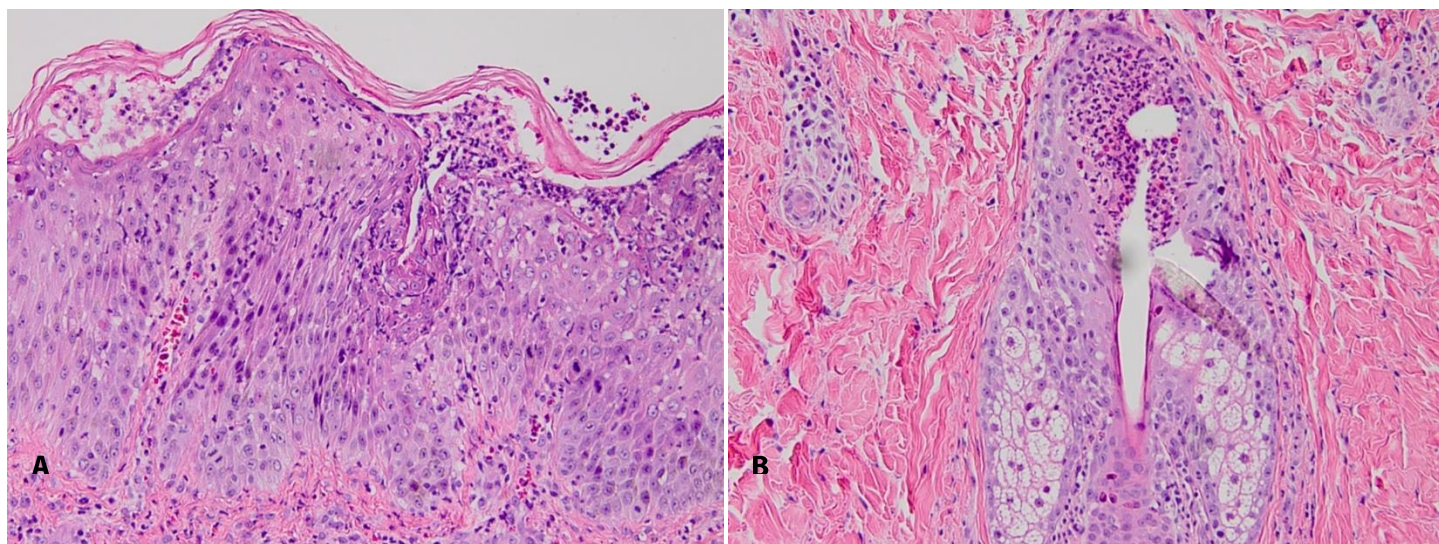
The rash did not respond to IV vancomycin or clindamycin. *Mycoplasma* IgG and IgM and cold agglutinins returned positive, at which time treatment was initiated with doxycycline 100 mg

twice daily with significant improvement of the rash, fever, and arthralgias within two days.

### Case Discussion

*Mycoplasma pneumoniae*-induced rash and mucositis is characterized predominantly by mucosal involvement, and can have variable cutaneous involvement [1, 2]. It typically has an excellent prognosis when compared with outcomes for TEN. Affected patients are often young, male, and present with prodromal cough, malaise, and fevers. The rash is frequently polymorphic, with vesiculobullous, targetoid, papular, macular, and/or morbilliform lesions. Oral and ocular involvement are present in 94% and 82% of cases, respectively [1]. Our case is unique in that in addition to the more classic findings of MIRM, multiple foci of overlying pustules were also present.

Sneddon described a similar case in which a 24-year-old man presented with fever, arthralgias, malaise, and a productive cough [3]. Physical exam demonstrated targetoid lesions, severe oral, ocular, and genital erosions, and scattered pustules. Skin biopsy demonstrated subcorneal pustules. Laboratory tests showed slightly elevated total IgM and positive cold agglutinins at a titer of 1:32. The patient was treated with ampicillin and prednisolone with resolution by day 13.



**Figure 3. A)** Epidermis with subcorneal pustule formation and neutrophilic spongiosis. H&E, 20x. **B)** Acute suppurative folliculitis. H&E, 20x.

To our knowledge the only other similar case in the literature was reported by Reichert-Penetrat et al. [4]. However, in their case a pustular eruption developed 2 weeks after josamycin, acyclovir, and erythromycin had been initiated and after the initial eruption of MIRM had resolved, making a pustular drug eruption more likely.

Ours' is therefore the second report to reliably describe MIRM in association with pustulosis and the first to describe the histopathologic finding of perifollicular neutrophilic infiltration in MIRM, to our knowledge. We suggest that in the differential diagnosis of a patient with rapid-onset pustulosis, in addition to acute generalized exanthematous pustulosis (AGEP), pustular psoriasis, subcorneal

pustular dermatosis, Sweet syndrome, and disseminated cutaneous infection, dermatologists also consider MIRM, particularly in pediatric cases or in cases demonstrating mucosal involvement or targetoid lesions in addition to pustules.

## Conclusion

Pustulosis is a rare manifestation of MIRM and may present with perifollicular neutrophilic infiltration on histologic examination. *Mycoplasma pneumoniae*-induced rash and mucositis should be considered in patients presenting with a rapid-onset pustular pustulosis.

## References

1. Canavan TN, Mathes EF, Frieden I, Shinkai K. Mycoplasma pneumoniae-induced rash and mucositis as a syndrome distinct from Stevens-Johnson syndrome and erythema multiforme: a systematic review. *J Am Acad Dermatol*. 2015;72:239-245. [PMID: 25592340].
2. Frieden I, Mu A. 19-Year-Old Woman With Fever, Cough, and a Rash. *Clin Infect Dis*. 2016;62(7):906-7, 945-6. [PMID: 26969747].
3. Sneddon IB. Subcorneal pustules in erythema multiforme. *Br J Dermatol*. 1973;88(6):605-7. [PMID: 4717417].
4. Reichert-Penetrat S, Barbaud A, Antunes A, Borsa-Dorion A, Vidailhet M, Schmutz JL. An unusual form of Stevens-Johnson syndrome with subcorneal pustules associated with Mycoplasma pneumoniae infection. *Pediatr Dermatol*. 2000;17(3):202-4. [PMID: 10886752].