

UCSF

UC San Francisco Previously Published Works

Title

Deep sequencing analysis of clinical samples from patients with acute infectious conjunctivitis during the COVID-19 delta surge in Madurai, India

Permalink

<https://escholarship.org/uc/item/54d4h46k>

Authors

Lalitha, Prajna
Prajna, N Venkatesh
Gunasekaran, Rameshkumar
[et al.](#)

Publication Date

2022-12-01

DOI

10.1016/j.jcv.2022.105318

Peer reviewed




Since January 2020 Elsevier has created a COVID-19 resource centre with free information in English and Mandarin on the novel coronavirus COVID-19. The COVID-19 resource centre is hosted on Elsevier Connect, the company's public news and information website.

Elsevier hereby grants permission to make all its COVID-19-related research that is available on the COVID-19 resource centre - including this research content - immediately available in PubMed Central and other publicly funded repositories, such as the WHO COVID database with rights for unrestricted research re-use and analyses in any form or by any means with acknowledgement of the original source. These permissions are granted for free by Elsevier for as long as the COVID-19 resource centre remains active.



Contents lists available at ScienceDirect

Journal of Clinical Virology

journal homepage: www.elsevier.com/locate/jcv

Short communication

Deep sequencing analysis of clinical samples from patients with acute infectious conjunctivitis during the COVID-19 delta surge in Madurai, India



Prajna Lalitha^a, N Venkatesh Prajna^a, Rameshkumar Gunasekaran^a, Gonugunta Vishnu Teja^a, Sankalp S. Sharma^a, Armin Hinterwirth^b, Kevin Ruder^b, Lina Zhong^b, Cindi Chen^b, Michael Deiner^c, ChunHong Huang^d, Benjamin A. Pinsky^{d,e}, Thomas M. Lietman^{b,c}, Thuy Doan^{b,c,*}, Gerami D. Seitzman^{b,c}, on behalf of the SCORPIO (Seasonal Conjunctivitis Outbreak Reporting for Prevention and Improved Outcomes) Study Group

^a Aravind Eye Hospital, Madurai, India^b Francis I. Proctor Foundation, University of California San Francisco, San Francisco, CA, United States^c Department of Ophthalmology, University of California, San Francisco, CA, United States^d Department of Pathology, Stanford University School of Medicine, Stanford, CA, United States^e Department of Medicine, Division of Infectious Diseases and Geographic Medicine, Stanford University School of Medicine, Stanford, CA, United States

A B S T R A C T

Background: Seasonal outbreaks of infectious conjunctivitis remain a public health issue. Determination of outbreak etiologies in the context of a worldwide pandemic may provide useful information to guide public health strategies. The aim of this study was to identify pathogens associated with outpatient infectious conjunctivitis during the COVID-19 Delta surge.

Methods: This prospective study was conducted from April 2021 to September 2021. All outpatients presenting to the Aravind Eye Center (Madurai, India) with signs and symptoms consistent with acute infectious conjunctivitis were eligible. Three swabs were obtained from each participant: one from each conjunctiva and one from the anterior nares. Samples were processed for metagenomic RNA deep sequencing (RNA-seq).

Results: Samples from 106 study participants were sequenced. The most common presenting symptoms were tearing (86%) and itching (71%). Preauricular lymphadenopathy was present in 38% of participants. 20% of participants had close contacts with similar symptoms. Systemic symptoms such as coughing, runny nose, vomiting or diarrhea were uncommonly reported. 60% of all participants used some medicated eye drops upon enrollment. 75% of study participants demonstrated infection with human adenovirus D (HAdV-D). 11% of conjunctivitis was associated with SARS-CoV-2. 15% had no definitive pathogen detected. 8% of all participants had codetection of more than one pathogen on RNA-seq.

Conclusions: During the COVID-19 Delta surge in India, HAdV-D was the most common pathogen associated with infectious conjunctivitis. SARS-CoV-2 was the second most common associated pathogen. Seasonal surveillance may be necessary for the determination of emerging and reemerging pathogens responsible for infectious conjunctivitis.

1. Introduction

Worldwide epidemics of infectious conjunctivitis occur regularly [1, 2]. Episodes of infectious conjunctivitis continued despite the widespread implementation of nonpharmaceutical interventions designed to mitigate the COVID-19 pandemic, such as mask-wearing, hand-washing, and social distancing. We know infectious conjunctivitis etiology varies by location and season [3]. Pathogens driving infectious conjunctivitis during a COVID-19 pandemic have not been studied in a prospective manner.

As worldwide interest in emerging infectious disease increases, our

collective ability to rapidly screen for and diagnose etiologies of any contagious process has wide reaching implications. SCORPIO (Seasonal Conjunctivitis Outbreak Reporting for Prevention and Improved Outcomes) is a UCSF based international study aimed to determine the causes of infectious conjunctivitis worldwide. The Aravind Eye Hospital in Madurai, India, is one of the participating sites. This manuscript describes the pathogens responsible for infectious conjunctivitis during the COVID-19 Delta surge in Madurai, India, as determined by metagenomic RNA deep sequencing analysis (RNA-seq). A companion paper in this issue provides more details on the patients presenting specifically with SARS-CoV-2 conjunctivitis [4].

* Corresponding author.

E-mail address: thuy.doan@ucsf.edu (T. Doan).<https://doi.org/10.1016/j.jcv.2022.105318>

Received 12 August 2022; Received in revised form 23 September 2022; Accepted 30 September 2022

Available online 5 October 2022

1386-6532/© 2022 Elsevier B.V. All rights reserved.

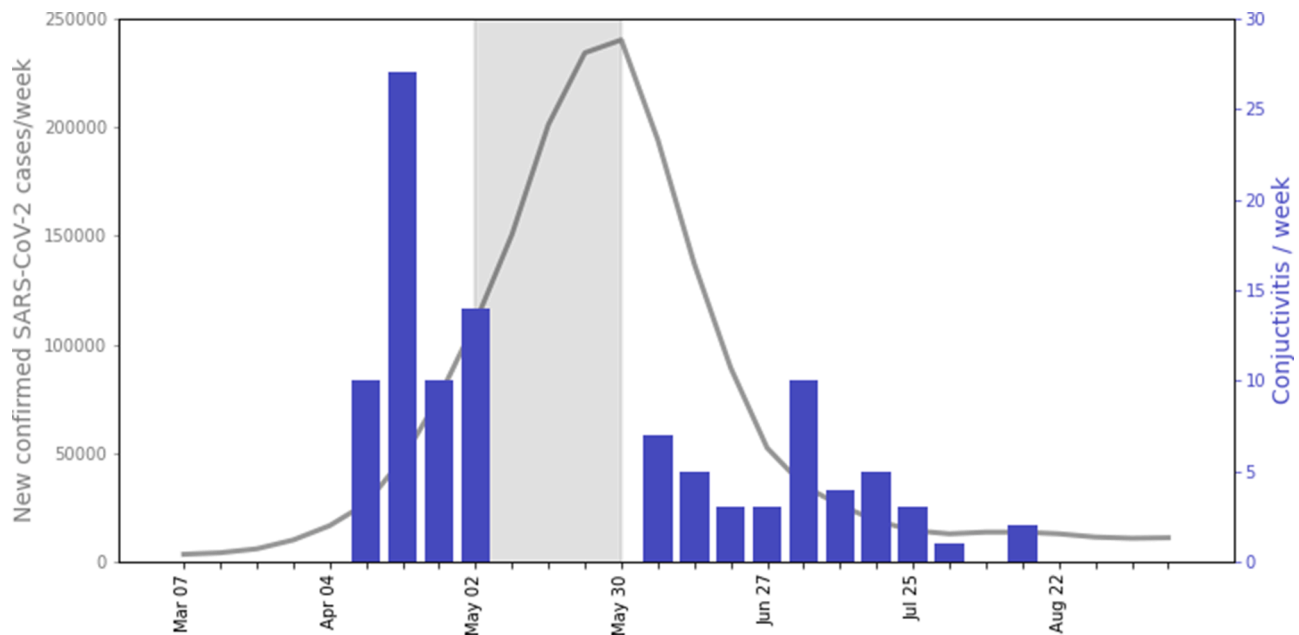


Fig. 1. Cases of infectious conjunctivitis during the Delta coronavirus variant surge at the Aravind Eye Center in Madurai, India. The y-axis on the left represents numbers of new and confirmed SARS-CoV-2 cases in the population in the Tamil region of India during the Delta surge in 2021 [13]. This is represented by the solid gray line. The bar graph represents number of conjunctivitis cases enrolled in the study, per week, over the study time period. The y-axis on the right indicates the number of conjunctivitis cases. The solid gray bar represents the stoppage of clinical activities at the Aravind Eye Center.

Table 1
Demographics, Signs, and Symptoms of Patients Presenting with Presumed Infectious Conjunctivitis During the Delta Variant Surge in Madurai, India.

		n = 106	%	(95% CI)
Gender	Female	39	37	(28, 46)
	Male	67	63	(54, 72)
Age	Years	39 ± 16		
Both Eyes Affected	Yes	49	46	(37, 56)
Duration of Symptoms	Days	6 ± 3		
Contacts affected	Yes	20	19	(12, 27)
Ocular symptoms	Tearing	91	86	(78, 91)
	Itching	75	71	(61, 79)
	Purulence	61	58	(48, 67)
Exam findings	Sub-epithelial infiltrates	11	10	(6, 18)
	Membranes	23	22	(15, 31)
	Preauricular adenopathy	39	38*	(29, 48)

Plus-minus values are mean ± standard deviation.

95% Confidence intervals were calculated by an Adjusted Wald method.

* Preauricular adenopathy was evaluated in 103 of 106 participants.

2. Materials & methods

This study adhered to the tenets of the Declaration of Helsinki. The Institutional Review Board of the University of California, San Francisco and Aravind Eye Hospital in Madurai, India, approved the study. Informed written consent was obtained from all patients. Guardians were consented for all children. Children older than 18 years of age provided assent. Conjunctival swabs were obtained from patients who presented to the Aravind Eye Hospital in Madurai, India from April 1 to May 1, 2021 and from June 1 to September 17, 2021. The gap in sample collection represented the lockdown period in which all research activities at Aravind were placed on-hold due to the Delta surge. Inclusion criteria required acute conjunctivitis symptoms for less than 14 days. Exclusion criteria were presumed allergic conjunctivitis or chemical conjunctivitis. Sterile polyester applicators (Puritan) were used to swab the lower conjunctival fornix of each eye. The most affected eye was swabbed first. A third swab of both nares was collected. All swabs were immediately placed in DNA/RNA-Shield (Zymo Research) and transferred to a -80°C freezer for long-term storage until tested. Details of

sequencing, library preparation, and bioinformatics analyses are described and summarized in the SARS-CoV-2 companion in this issue [4].

3. Results

The highly contagious Delta variant of SARS-CoV-2 surged in southern India in the spring of 2021 [5]. Peak numbers necessitated a cessation of elective clinical visits from May 10, 2021 through May 24, 2021. Elective clinical study participation stopped on May 1, 2021 and resumed June 1, 2021. During this time period of sample collection, 106 patients were consented for study participation (Fig. 1).

Demographics of infectious conjunctivitis study participants are summarized in Table 1. The mean age was 39 years old. 37% of study participants were female. Bilateral conjunctivitis was present in 46% of the population (95% confidence interval (CI): 37% to 56%). Only the right eye was affected in 22% (95% CI: 15% to 31%). Signs and symptoms in the left eye only were present in 32% (95% CI: 24% to 41%). The mean duration of ocular symptoms prior to presentation was 6 days (standard deviation: +/- 3 days). 102 of 106 participants (96%) provided information regarding close contacts. Of this group, 20% (95% CI: 13% to 28%) reported similar symptoms of ocular redness and irritation in family members and/or close contacts. The most commonly reported subjective symptom from participants was tearing, present in 86% (95% CI: 78% to 91%). Itching was the next most common symptom, presented in 71% (95% CI: 61% to 79%). Purulent discharge was reported in 58% (95% CI: 48% to 67%).

Upon examination, a membranous conjunctivitis (differentiation between membranes and pseudo-membranes was not required) was present in 22% (95% CI: 15% to 31%) of all participants. Slit lamp examination demonstrated corneal sub-epithelial infiltrates in 10% (95% CI: 6% to 18%). 103 of 106 participants (97%) were evaluated for preauricular adenopathy which was present in 38% (95% CI: 29% to 48%). Comorbid systemic symptoms were not frequently reported. 8% reported a runny nose (95% CI: 6% to 18%), 7% (95% CI: 3% to 13%) had a sore throat, 2% had coughing (95% CI: 0% to 7%), and 1% (95% CI: 0% to 16%) had diarrhea. 60% (95% CI: 51% to 70%) of study

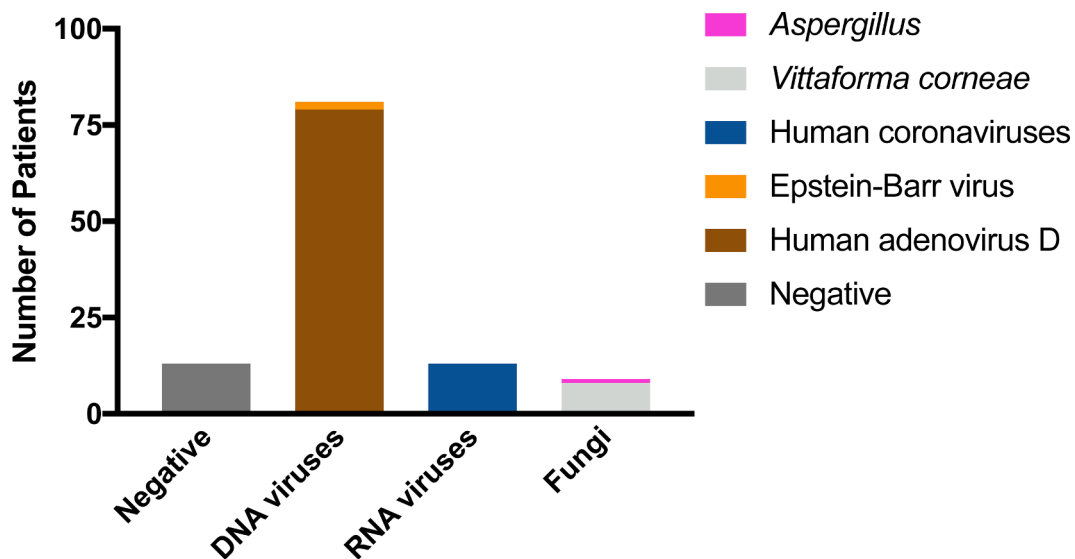


Fig. 2. Distribution of type of pathogens identified as associated agents of infectious conjunctivitis during the Delta coronavirus variant surge in Madurai, India. The majority of DNA viruses mapped to sequences of human adenovirus type D (HAdV-D), with a few Epstein-Barr Virus (EBV) also present. RNA viruses included SARS-CoV-2 and human coronavirus OC43. Fungal etiologies were mostly *Vittaforma corneae* with one case of *Aspergillus*.

participants were using one or more medicated eye drops upon enrollment. Of those using medicated drops, 89% presented on antibacterial drops, (95% CI: 79% to 95%), and 20% (95% CI: 12% to 32%) were using a steroid drop. Anti-fungal, anti-viral and antihistamine drops were each used by 2% (95% CI: 0% to 9%).

In all patients with presumed infectious conjunctivitis, RNA-seq analysis identified an associated pathogen in 88% of cases. The most common pathogen identified (Fig. 2) was human adenovirus species D (HAdV-D), present in 75% (95% CI: 65% to 82%) of cases. The second most common pathogen recovered was SARS-CoV-2, presented in 11% (95% CI: 6% to 19%). *Vittaforma corneae* (microsporidia) was detected in 8% (95% CI: 4% to 15%). Epstein-Barr Virus (EBV) was detected in two cases. *Aspergillus* and human coronavirus OC43 were each identified as pathogens in 1 case, representing 1% of all cases (95% CI: 0% to 6%). Co-infection, samples meeting definitional criteria for more than one associated organism of conjunctivitis, was present in 7 participants. Additional details describing the coinfection cases are presented in the companion paper.

4. Discussion

The overall effects of the novel COVID-19 pandemic on the frequency, etiologies, and geographic variability of worldwide, recurrent, and seasonal conjunctivitis epidemics are unknown. With the onset of the COVID-19 pandemic, circulation of other respiratory viruses, in many countries decreased early on [6] [7]. As respiratory viruses are also common etiologies of infectious conjunctivitis, there was some suggestion of decreased rates of infectious conjunctivitis during the early pandemic [8] [9]. However, by spring of 2021, detection of many different viruses returned to pre-pandemic normal and others were rising, but in months atypical for their presentation [10]. As time passed, the timeline and prevalence of typical pathogen reemergence varied based on geography and season [11,12]. In this study, we demonstrate human adenovirus, specifically type 54, was still the most common etiology of infectious conjunctivitis in Madurai, India during the months that corresponded to the Delta surge of COVID-19. SARS-CoV-2, however, was the second most common associated etiology. There were no clear clinical distinguishing features between the two and they can occur together as a co-infection. Pathogens vary by location and continued surveillance is required to determine how and if the frequency of conjunctivitis pathogens change with time.

5. Limitations

54% of all participants were using an antibacterial drop at the time of sample collection. This may be the reason why no bacterial conjunctivitis pathogens were identified. However, this also emphasizes the overuse of topical antibiotics for infectious conjunctivitis which may be predominantly viral in etiology. Additionally, the pathogens identified on the clinical swabs are suggestive for symptom causality, however comparative control swabs from unaffected patients were not obtained so an analysis of comparative risk of disease could not be assessed.

6. Conclusions

This study emphasizes the importance of repeated regional and seasonal surveillance of causes of infectious diseases. The unbiased nature of deep sequencing allows for the detection of unanticipated pathogens and unexpected co-infections. RNA sequencing may be a useful diagnostic tool for the comprehensive surveillance of all viruses, including the RNA virus SARS-CoV-2, that can cause conjunctivitis.

Funding

Research reported in this manuscript was supported by the National Eye Institute of the National Institutes of Health under Award Number R01EY032041 (T.D.), a Research to Prevent Blindness Unrestricted Grant, and the Peierls Foundation. The content is solely the responsibility of the authors and does not necessarily represent the official views of the National Institutes of Health.

Non-author contribution

Seasonal Conjunctivitis Outbreak Reporting for Prevention and Improved Outcomes (SCORPIO) Study Group

Aravind Eye Hospital, Madurai, India – Lalitha Prajna, N. Venkatesh Prajna, Ramesh Gunasekaran, Sankalp Singh Sharma, Vishnu Teja; B.P Koirala Lions Center for Ophthalmic Studies, Kathmandu, Nepal – Meenu Chaudhary, Sanjeeta Sitaula; centre de Recherche en Sante de Nouna, Nouna, Burkina Faso – Ali Sié, Boubacar Coulibaly, Mamadou Bountogo; Chulalongkorn University, Bangkok, Thailand – Thanapong Somkijrungrong, Vannarut Satitpitakul; Hai Yen Vision Institute, Ho Chi Minh City, Vietnam – Huy Tran, Linh Hoàng Mai, Thảo Hạ Xuân, Yen Tran; Hospital

Clinico Universidad de Chile, Santiago, Chile – Cristhian A. Urzua, Fabian Vega, Felipe Salgado, Loreto Cuitino; *Hospital Universitario Austral* – Emiliano Sebastian Lopez, Federico Luengo Gimeno, Tomas Jaeschke; *Instituto Mexicano de Oftalmología, Santiago de Querétaro, Mexico* – Fernando Pérez, Jaime Macías Martínez, Van Charles Lansingh; *Khon Kaen University, Khon Kaen, Thailand* – Sukhumal Thanapaisal, Wipada Lao-virojjanakul; *National Eye Institute* – George McKie (Program Officer); *Oregon Health and Science University, Portland, Oregon, USA* – Kenia Chavez, Travis Redd, Winston Chamberlain; *Pacific Vision Institute of Hawaii, Honolulu, Hawaii, USA* – Angel Cheng, Vivien Tham; *Phramongkutklao Hospital, Bangkok, Thailand* – Wiwan Sansanayudh; *Programme National de Santé Oculaire, Niamey, Niger* – Abba Kaka Hajia Yakoura, Abdou Amza, Abdoul Salam Youssoufou Souley, Adam Nouhou Diori, Beido Nassirou, Boubacar Kadri, Boubacar Mariama, Cissé Mamadou Ibrahim, Lamyne Aboubacar Roufaye, Ramatou Boulhassane, Saley Ali, Zakou Abdou; *Rabin Medical Center, Petah Tikva, Israel* – Lee Goren, Ruti Sella; *Sinai Hospital, Baltimore, Maryland, USA* – Clare Kelliher, Laura Green; *Singapore Eye Research Institute, Singapore* – Hon Shing Ong, Jod Mehta, Yu-Chi Liu; *Stanford University School of Medicine* – Benjamin A. Pinsky; *Taipei Veterans General Hospital, Taipei, Taiwan* – De-Kuang Hwang, Nai-Wen Fan; *The University of Sydney, Save Sight Institute, Sydney, Australia* – Hong Sheng Chiong, Javier Lacorzana, Maria Cabrera-Aguas, Stephanie Watson; *University of California Los Angeles Stein Eye Institute, Los Angeles, California, USA* – Edmund Tsui, Joana Ramirez, Nina M. Cherian, Rachel Feit-Leichman, Reginald E. Hughes Jr, Tania Onclinx; *University of California San Diego Shiley Eye Institute, La Jolla, California, USA* – Carol Yu, Esmeralda McClean, Iliana Molina; *University of California San Francisco Francis I. Proctor Foundation, San Francisco, California, USA* – Armin Hinterwirth, Cindi Chen, Danny Yu, David Liu, Elodie Lebas, Emily Colby, Gerami Seitzman, Kevin Ruder, Lina Zhong, Michael Deiner, Thomas Abraham, Thomas Lietman, Thuy Doan (Principal Investigator), Travis Porco, Stephen McLeod; *University of California Berkeley School of Optometry, Berkeley, California, USA* – Kuniyoshi Kanai, Meredith Whiteside; *University of Nebraska Medical Center Truhlsen Eye Institute, Omaha, Nebraska, USA* – Steven Yeh, Tolulope Fashina; *University of New Mexico, Albuquerque, New Mexico* – James Chodosh; *University of Papua New Guinea School of Medicine and Health Sciences, Port Moresby, Papua New Guinea* – Bridgit Tarkap, Jambi N. Garap, Magdalene Mangot; *Vanuatu Eye Program,*

Ministry of Health, Vanuatu – Edwin Amel, Fasihah Taleo, Johnson Kasso, Kalbule Willie, Madopule Nantu, Prudence Rymill; *World Health Organization* – Anthony W. Solomon

Declaration of Competing Interest

None.

References

- [1] C.H. Chang, K.H. Lin, M.M. Sheu, et al., The change of etiological agents and clinical signs of epidemic viral conjunctivitis over an 18-year period in southern Taiwan, *Graefes Arch. Clin. Exp. Ophthalmol.* 241 (7) (2003) 554–560.
- [2] A. Sié, A. Diarra, O. Millogo, et al., Seasonal and temporal trends in childhood conjunctivitis in Burkina Faso, *Am. J. Trop. Med. Hyg.* 99 (1) (2018) 229–232.
- [3] M.S. Deiner, S.D. McLeod, J. Wong, et al., Google searches and detection of conjunctivitis epidemics worldwide, *Ophthalmology* 126 (9) (2019) 1219–1229.
- [4] Venkatesh. N Prajna, Prajna Lalitha, Gonugunta Vishnu Teja, Rameshkumar Gunasekaran, Sankalp S. Sharma, Armin Hinterwirth, Kevin Ruder, Lina Zhong, Cindi Chen, Michael Deiner, ChunHong Huang, Benjamin A. Pinsky, Thomas M. Lietman, Gerami D. Seitzman, Thuy Doan, Outpatient human coronavirus associated conjunctivitis in India, *Journal of Clinical Virology*, Volume 157, 2022.
- [5] A.E. Rosato, E. Msiha, B. Weng, et al., Rapid detection of the widely circulating B.1.617.2 (Delta) SARS-CoV-2 variant [published online ahead of print, 2022 Jan 31], *Pathology* S0031-3025 (22) (2022) 00035–00036, <https://doi.org/10.1016/j.pathol.2022.01.001>.
- [6] K.Y. Park, S. Seo, J. Han, J.Y. Park, Respiratory virus surveillance in Canada during the COVID-19 pandemic: an epidemiological analysis of the effectiveness of pandemic-related public health measures in reducing seasonal respiratory viruses test positivity, *PLoS ONE* 16 (6) (2021 Jun 18).
- [7] M.N. Boschiero, A. Duarte, C.V.C. Palamim, et al., Frequency of respiratory pathogens other than SARS-CoV-2 detected during COVID-19 testing, *Diagn. Microbiol. Infect. Dis.* 102 (2) (2022), 115576.
- [8] J.M. Lavista Ferres, T. Meirick, W. Lomazow, C.S. Lee, A.Y. Lee, M.D. Lee, Association of public health measures during the COVID-19 pandemic with the incidence of infectious conjunctivitis, *JAMA Ophthalmol.* (2022).
- [9] M.S. Deiner, G.D. Seitzman, S.D. McLeod, et al., Ocular signs of COVID-19 suggested by internet search term patterns worldwide, *Ophthalmology* 128 (1) (2021) 167–169, <https://doi.org/10.1016/j.ophtha.2020.06.026>.
- [10] S.J. Olsen, A.K. Winn, A.P. Budd, et al., Changes in influenza and other respiratory virus activity during the COVID-19 pandemic – United States, 2020–2021, *MMWR Morb. Mortal. Wkly. Rep.* 70 (2021) 103–1019.
- [11] J.A. Mott, A.M. Fry, R. Kondor, et al., Re-emergence of influenza virus circulation during 2020 in parts of tropical Asia: implications for other countries, *Influenza Other Respir. Viruses* 15 (2021) 415–418.
- [12] S. Yum, K. Hong, S. Sohn, et al., Trends in viral respiratory infections during COVID-19 pandemic, South Korea, *Emerging Infect. Dis.* 27 (6) (2021) 1685–1688.
- [13] Retrieved March 20,2022 from <https://coronavirus.jhu.edu/map.html>.