

## **UC Davis**

### **UC Davis Previously Published Works**

#### **Title**

Applied feline oral anatomy and tooth extraction techniques: an illustrated guide.

#### **Permalink**

<https://escholarship.org/uc/item/54b265bd>

#### **Journal**

Journal of Feline Medicine and Surgery, 16(11)

#### **Authors**

Reiter, Alexander

Soltero-Rivera, Maria

#### **Publication Date**

2014-11-01

#### **DOI**

10.1177/1098612X14552365

Peer reviewed



# APPLIED FELINE ORAL ANATOMY AND TOOTH EXTRACTION TECHNIQUES

## An illustrated guide

Alexander M Reiter and Maria M Soltero-Rivera

**Practical relevance:** Tooth extraction is one of the most commonly performed surgical procedures in small animal practice.

**Clinical challenges:** The clinician must be familiar with normal oral anatomy, utilize nomenclature accepted in dentistry and oral surgery, use the modified Triadan system for numbering teeth, identify normal structures on a dental radiograph, understand the tissues that hold the teeth in the jaws, know the biomechanical principles of tooth extraction, be able to choose the most appropriate instrument for removal of a tooth, extract teeth using closed and open techniques, and create tension-free flaps for closure of extraction sites.

**Audience:** This review is intended to familiarize both the general and referral practitioner with feline oral anatomy and tooth extraction techniques.

**Patient group:** Tooth extraction is predominantly performed in cats with tooth resorption, chronic gingivostomatitis and periodontal disease.

**Equipment:** The basic contents of a feline tooth extraction kit are explained.

**Evidence base:** The guidance contained within this review is based on a combination of the published literature, the authors' personal experience and the experience of colleagues.

Permanent teeth of young cats have a much wider pulp cavity and thinner dentinal walls compared with permanent teeth of old cats.

### Feline oral anatomy

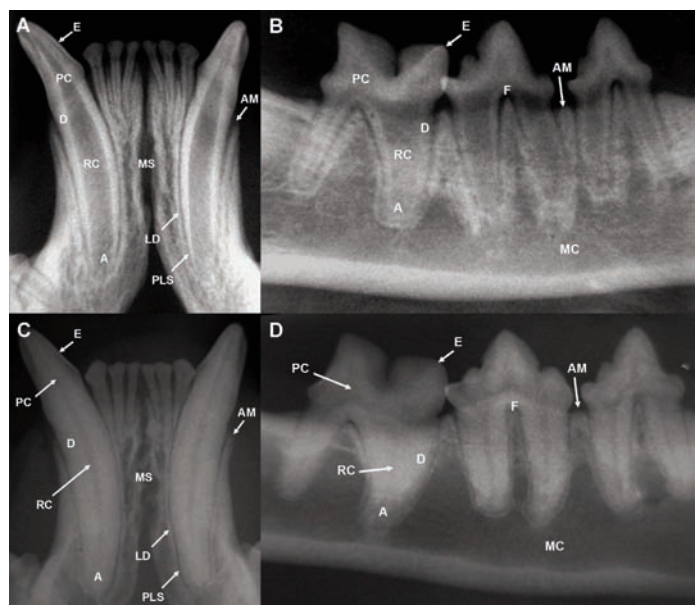
#### Eruption and types of teeth

The kitten's 26 deciduous teeth erupt at between 2 and 6 weeks of age. The cat's 30 permanent teeth erupt at between 3 and 6 months of age. Cats have incisors for cutting, prehending and grooming, canines for penetrating, grasping and defense, and cheek teeth (premolars and molars) for holding, carrying, breaking and tearing food. The maxillary fourth premolar and mandibular first molar are the carnassial teeth.<sup>1–3</sup>

#### Tooth structure

Enamel covers the crown and cementum covers the root. These hard tissue layers meet at the cemento-enamel junction near the cervical

**Figure 1** Radiographs of the mandibular incisors and canines, and the right mandibular cheek teeth in a cat less than 1 year of age (A and B) and in a cat over 3 years of age (C and D). E = enamel; PC = pulp chamber; D = dentin; RC = root canal; A = apex; MS = mandibular symphysis; AM = alveolar margin; LD = lamina dura; PLS = periodontal ligament space; F = furcation; MC = mandibular canal



Alexander M Reiter  
Dipl Tzt Dr med vet DAVDC DEVDC\*  
Maria M Soltero-Rivera  
DVM DAVDC

Department of Clinical Sciences, School of Veterinary Medicine, University of Pennsylvania, 3900 Delancey Street, Philadelphia, PA, USA



\*Corresponding author: reiter@vet.upenn.edu



## Tooth formulas and directional terms

The anatomical names of teeth are (right or left), (maxillary or mandibular), (first, second, third or fourth), (incisor, canine, premolar or molar), as applicable, either written out in full or abbreviated.

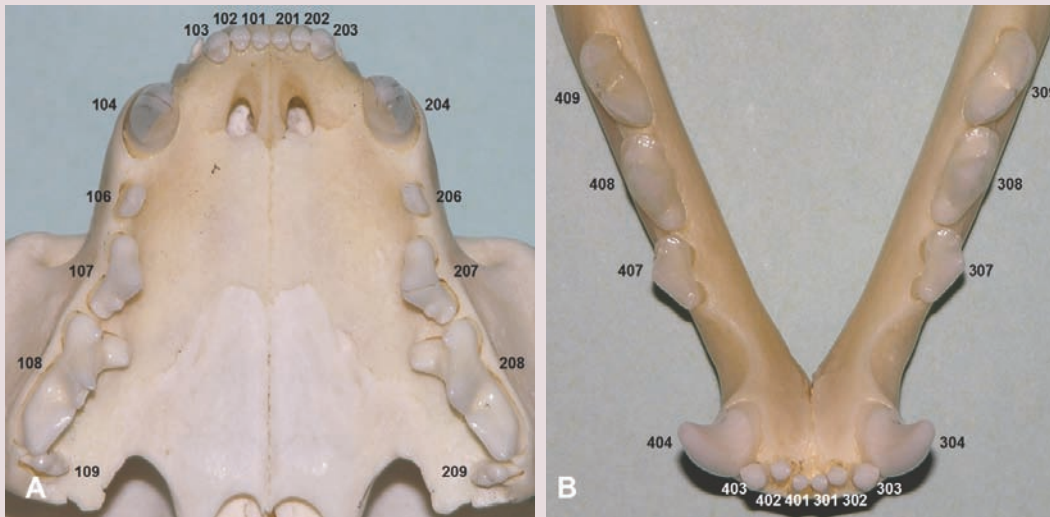
### Modified Triadan system

The modified Triadan system numbers each jaw quadrant as follows:

- ✦ Right maxillary quadrant 100 (500 when referring to deciduous teeth)
- ✦ Left maxillary quadrant 200 (600 when referring to deciduous teeth)

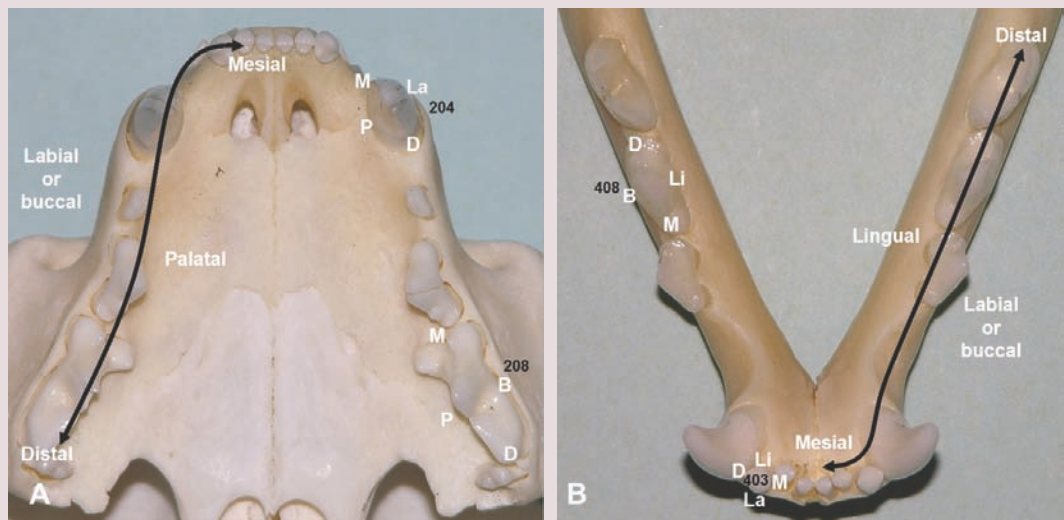
- ✦ Left mandibular quadrant 300 (700 when referring to deciduous teeth)
- ✦ Right mandibular quadrant 400 (800 when referring to deciduous teeth)

Beginning with the first incisor (01), teeth are numbered from mesial to distal along the dental arch. Evolutionarily missing teeth result in gaps in the numbering sequence (Figure 2). The maxillary first (05) premolars and mandibular first (05) and second (06) premolars are absent in the cat. The maxillary and mandibular canines (04), maxillary fourth premolars (08) and mandibular first molars (09) are large reference teeth that allow counting forward or backward when numbering all other teeth.<sup>1-3</sup>



**Figure 2** Modified Triadan tooth numbering system for the maxillary (A) and mandibular (B) permanent teeth in the cat

The directional terminology that is used is illustrated in Figure 3 and tabulated below.



**Figure 3** Directional terminology for maxillary (A) and mandibular (B) teeth in the cat. M = mesial; La = labial; B = buccal; D = distal; P = palatal; Li = lingual

<b>Rostral</b>	Towards the tip of the nose	<b>Lingual</b>	Facing the tongue
<b>Caudal</b>	Towards the tail	<b>Palatal</b>	Facing the hard palate
<b>Ventral</b>	Towards the lower jaw	<b>Occlusal</b>	Facing an opposing dental arch
<b>Dorsal</b>	Towards the top of the head or the muzzle	<b>Coronal</b>	Towards the tip of the crown
<b>Mesial</b>	Towards the midline along the dental arch	<b>Apical</b>	Towards the apex of a root
<b>Distal</b>	Away from the midline along the dental arch	<b>Subgingival</b>	Apical to the gingival margin
<b>Labial</b>	Facing the lip	<b>Supragingival</b>	Coronal to the gingival margin
<b>Buccal</b>	Facing the cheek		



portion of the tooth. Dentin makes up the bulk of the mature tooth. The pulp cavity, which contains the pulp, is divided into the pulp chamber in the crown and the root canal(s) in the root(s). The feline pulp connects with periapical tissues through several foramina in the root apex (apical delta). Non-apical ramifications exist in the furcation and other areas of the root. Odontoblasts at the pulp's periphery produce dentin throughout life in a vital tooth. Therefore, permanent teeth of young cats have a much wider pulp cavity and thinner dentinal walls (Figure 1) compared with permanent teeth of old cats.<sup>1-3</sup>

Incisors and canines are single-rooted teeth. Permanent maxillary second premolars and first molars often have two roots fused to each other (allowing them to be extracted without tooth sectioning). Permanent mandibular third and fourth premolars and first molars have two roots, while the maxillary fourth premolars have three roots. The two-rooted permanent maxillary third premolars occasionally have a third root.<sup>4</sup> The furcation is where two or more roots meet at the crown.<sup>1-3</sup>

### Periodontium and oral mucosa

The periodontium is made up of gingiva, periodontal ligament, cementum and alveolar bone. The inelastic gingiva attaches to the cervical portion of the tooth and most coronal portion of the alveolar bone. Its most coronal edge is called the gingival margin. The space between the tooth and the free gingiva is the gingival sulcus, which should not be deeper than 0.5 mm in cats.<sup>3</sup> The periodontal ligament attaches the root to alveolar bone. Cementum is produced by cementoblasts, and its width increases with age. Alveolar bone surrounds the alveolar socket. The most coronal edge of the alveolar bone is the alveolar margin. The periodontal ligament space appears radiographically as a dark line surrounding the root. Immediately adjacent to it is the radiopaque lamina dura, an extension of cortical bone into the alveolus.<sup>2,3</sup>

Alveolar mucosa is elastic, faces the alveolar bone and is separated from the gingiva by the mucogingival junction. Labial and buccal mucosae cover the inside of the lip and cheek (Figure 4). Together with the tongue, the loose sublingual mucosa covers the floor of the mouth. The mucosa at the dorsal and ventral tongue surfaces contains many different papillae. The inelastic mucosa of the hard palate is firmly attached to the palatine processes of the maxillae and the palatine bones. Finally, the mucosa of the muscular soft palate contains small salivary glands. The oral mucosa is separated from the skin by the mucocutaneous junction.<sup>3</sup>

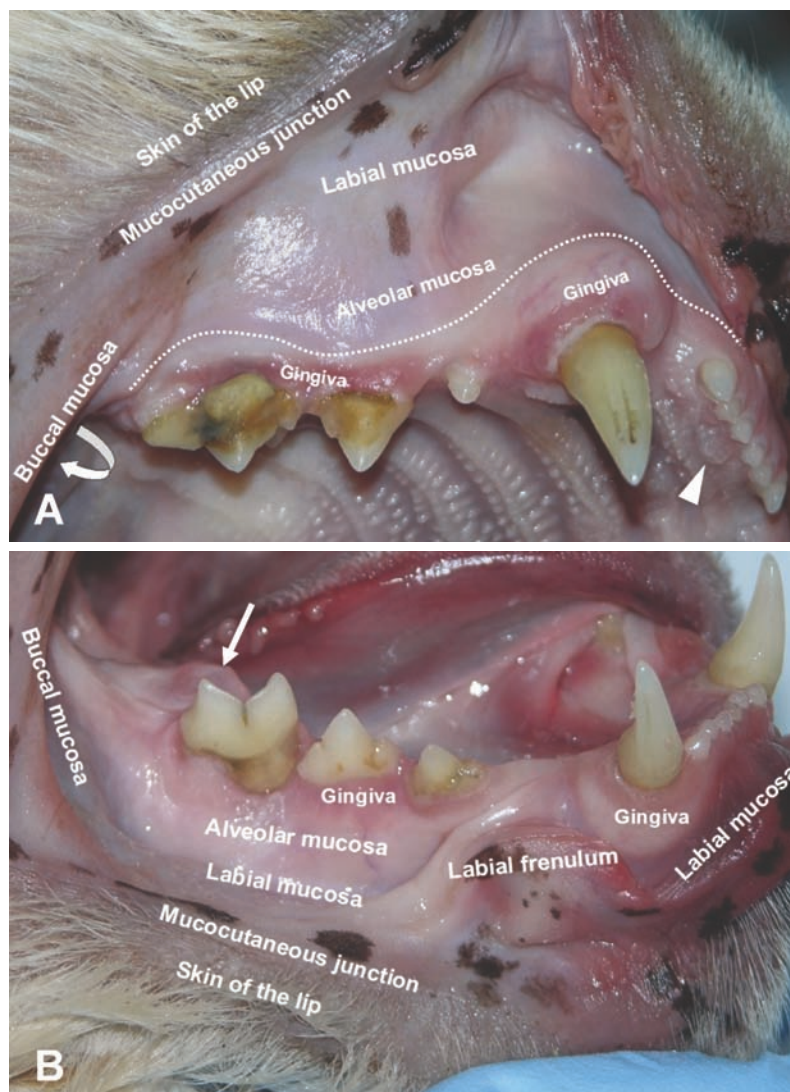
### Bones, joints and muscles

Mesaticephalic cats have a head of medium proportions. Persians are brachycephalic with a short, wide head. Siamese are dolichocephalic with a long, narrow head.

The upper jaw and face consist of the paired incisive bones, maxillae, palatine, nasal, zygomatic and temporal bones, and the unpaired vomer bone. The incisive bones carry the maxillary incisors, and the maxillae carry the maxillary canines, premolars and molars. The infraorbital canal contains the infraorbital artery, vein and nerve (sensory), and lies dorsal to the maxillary fourth premolar and first molar; the neurovascular bundle exits the canal at the infraorbital foramen about 1 cm dorsal to the maxillary third premolar.<sup>1,3</sup>

The lower jaw consists of the paired mandibulae, carrying all the mandibular teeth. The mandibular canal contains the inferior alveolar artery, vein and nerve (sensory), which exit at the caudal, middle and rostral mental foramina. The mandibular symphysis,

**Figure 4** Different types of oral mucosa in the upper (A) and lower (B) jaws of a cat. Note the unpaired incisive papilla immediately caudal to the maxillary first incisor teeth (arrowhead) and the lingual molar gland contained within a membranous pad caudolingual to the mandibular first molar tooth (arrow). The dotted line depicts the approximate course of the mucogingival junction



a fibrocartilaginous synchondrosis, connects the two mandibles rostrally. The condylar process of the mandible and the mandibular fossa and retroarticular process of the temporal bone form the temporomandibular joint.

The masseter, temporal and pterygoid (medial and lateral) muscles close the mouth. The digastricus muscles open the mouth.<sup>1,3</sup>

### Lips and cheeks

The upper and lower lips meet at the commissure. The dorsal and ventral buccal branches of the facial nerve (for motor innervation) run over the masseter muscle in a caudorostral direction into the cheek. Traversing in between the two nerves is the parotid duct, which opens into the mouth at the parotid papilla in the buccal mucosa near the maxillary fourth premolar.<sup>1-3</sup>

### Palate

The roof of the mouth is divided into non-elastic hard palate and elastic soft palate. The hard palate mucosa has several transverse ridges (palatine rugae). The unpaired incisive papilla is immediately caudal to the maxillary first incisor teeth. The paired major palatine arteries course from the major palatine foramina at the level of the maxillary fourth premolars rostrally to the palatine fissures. Palatoglossal folds emerge when the tongue is withdrawn from the mouth, running from the body of the tongue to the rostralateral aspect of the soft palate.<sup>1,3</sup>

### Tongue

The cat uses its muscular tongue to lap fluids, form food boluses and groom the fur. The rostral two-thirds are the body of the tongue; the caudal one-third is the root of the tongue. The rough dorsal tongue surface has firm papillae pointing caudally. The lingual frenulum connects the lingual body to the floor of the mouth. The mandibular and sublingual ducts open at the sublingual caruncles at the rostroventral base of the frenulum. The paired lingual arteries supply the tongue. The lingual and facial nerve provide sensory function, while the hypoglossal nerve is responsible for motor function.<sup>1,3</sup>

### Salivary glands, lymph nodes and tonsils

Cats have four pairs of major salivary glands (parotid, sublingual, mandibular and zygomatic). Scattered glandular tissue is present submucosally in the lips, cheeks and soft palate. Caudolingual to each mandibular first molar tooth is a small lingual molar gland contained within a membranous pad.<sup>2,5</sup> There are three lymph centers in the head (parotid, mandibular and retropharyngeal). The palatine tonsils are attached to the dorsal aspect of the lateral pharyngeal walls, which are also called the fauces.<sup>1-3</sup>

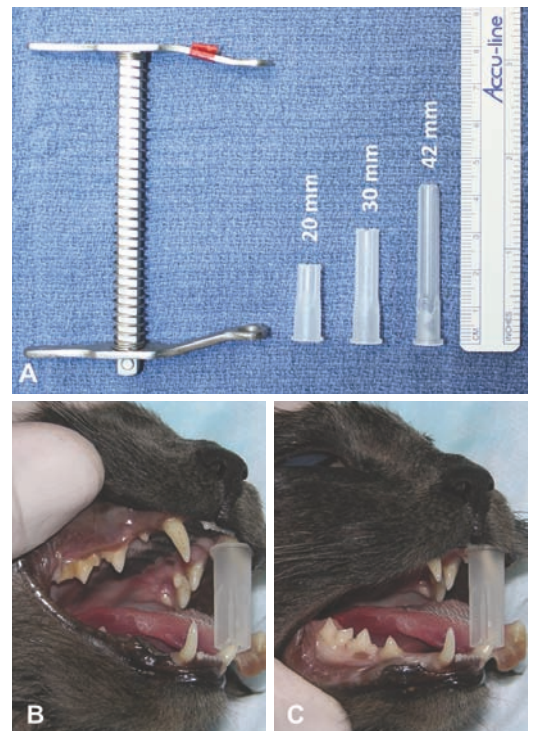
### Indications for tooth extraction

The most common indications for tooth extraction in cats include tooth resorption and stomatitis, followed by retained roots and teeth with periodontal or endodontic/periapical disease.<sup>6</sup>

### Equipment, instruments and materials for tooth extraction


Keeping a cat's mouth open wide for a prolonged period of time can reduce maxillary artery blood flow, which may result in temporary or permanent blindness post-anesthesia.<sup>7,8</sup> Rather than using spring-loaded mouth gags, 30 mm or 20 mm plastic gags that are custom-made from a needle cap can be placed between maxillary and mandibular canines to enable adequate mouth opening for performance of extraction procedures (Figure 5).

Air-powered systems are equipped with irrigating mechanisms to cool the burs used in high- and low-speed dental handpieces.<sup>9</sup> High-speed handpieces are used for sectioning multi-rooted teeth into single-rooted crown-root segments and for removing and shaping alveolar bone; low-speed handpieces are used for cutting bone only. An assortment of round (to remove alveolar bone), cross-cut

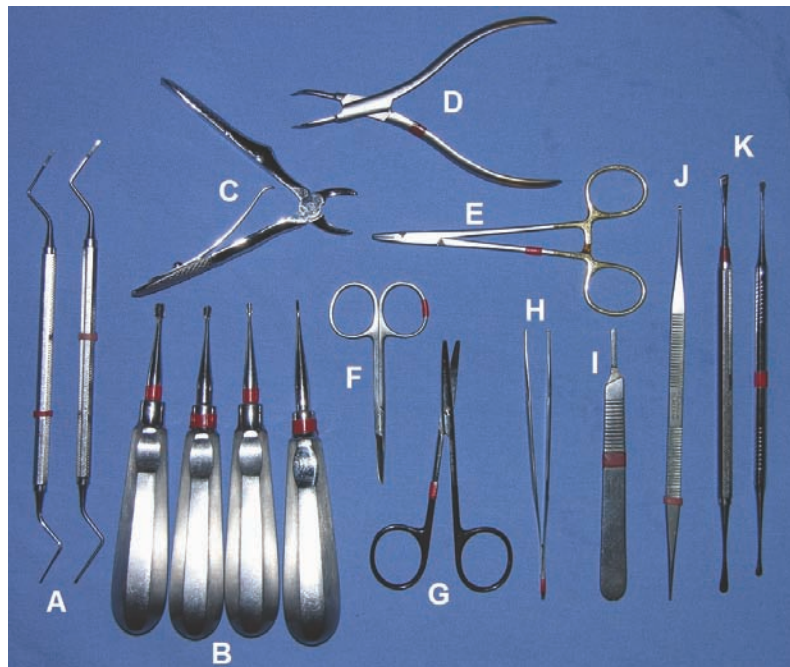


**Figure 5** (A) Spring-loaded mouth gag, 20 mm custom-made plastic gag, 30 mm custom-made plastic gag and 42 mm common 1 inch needle cap. (B and C) A 20 mm custom-made plastic gag placed between maxillary and mandibular canines enables adequate mouth opening for performance of tooth extraction in the upper and lower jaw quadrants





**Figure 6** Assortment of friction-grip burs for use in a high-speed dental handpiece; round carbide burs (left), cross-cut fissure burs (middle) and round medium-coarse diamond burs (right). S = surgical (ie, the shank is longer than normal); L = long (ie, the working end is longer than normal)



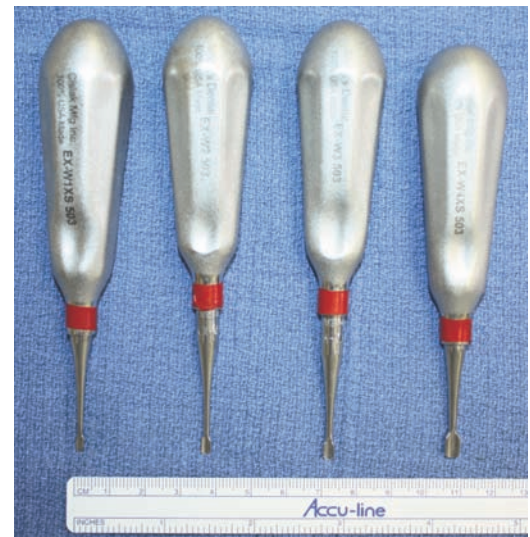**Figure 7** Feline tooth extraction kit. Root fragment elevators (A), winged luxating elevators (B), extraction forceps (C), root tip forceps (D), needle holder (E), suture scissors (F), curved Metzenbaum scissors (G), Adson thumb forceps (H), scalpel handle (I), surgical curette (J) and periosteal elevators (K)

**Luxators and elevators are grasped with the butt of the handle seated in the palm, and the index finger extended along the blade to act as a stop in case of slippage.**

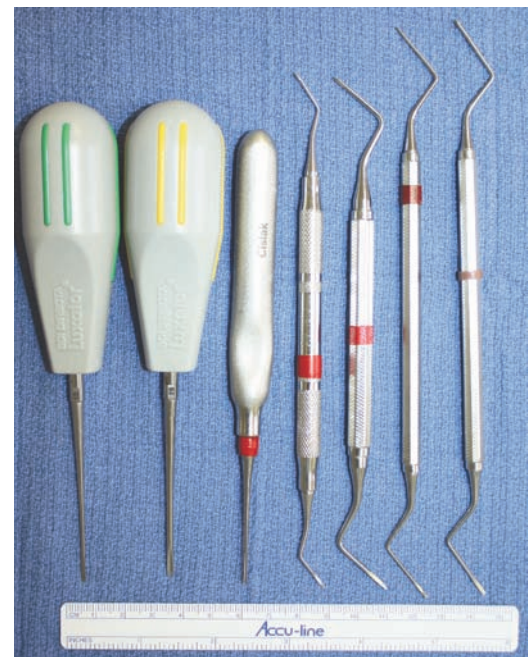fissure (to section multi-rooted teeth) and round diamond burs (to smooth alveolar bone) should be available (Figure 6).

Numbers 3 (with metric ruler markings) and 5 scalpel handles accept numbers 10, 11, 15 and 15C blades.<sup>10</sup> Adson 1 x 2 forceps provide a fine rat tooth grip, causing minimal trauma to delicate oral tissues. It is suggested that oral flaps are grasped on their connective tissue side rather than at their margins so as not to traumatize the latter prior to suturing. Sharp and narrow-tipped periosteal elevators (such as Glickman 24G or Periosteal EX-9) are used to raise oral flaps and should always be part of a feline tooth extraction kit (Figure 7). The flat or concave side of the blade is used against the bone and the convex side against the soft tissue, reducing the risk of tearing or puncturing the elevated soft tissue.<sup>9</sup>

Dental luxators have sharp, flat-tipped blades for penetrating and cutting the periodontal ligament between the tooth and alveolar bone. Dental elevators have less sharp, more curved blades (Figure 8), fitting the circumference of the tooth to exert a rotational force, thus tearing the periodontal ligament fibres. These instruments are grasped with the butt of the handle seated in the palm, and the index finger extended along the blade to act as a stop in case the instrument slips.<sup>9</sup> Small root tip luxators, elevators and forceps are available for removal of root remnants (Figure 9). The beaks of extraction forceps should not



**Figure 8** Winged dental elevators (sizes 1-4, from left to right), the curved blades of which are designed to fit the circumference of a tooth



**Figure 9** Small root tip luxators and root tip elevators ('teasers') for removal of root remnants

fully close but still fit the circumference of feline teeth, thus reducing the risk of tooth fracture when a tooth or crown–root segment is grasped as far apically as possible for its removal.<sup>11</sup>

Surgical curettes are used for removal of debris and granulation tissue from an alveolar socket after tooth extraction. Curved, blunt-ended Metzenbaum scissors with serrated blades are used for dissecting the connective tissue side of oral flaps and fine cutting of their edges prior to wound closure. Specific suture scissors or a designated pair of Mayo scissors should be reserved for cutting sutures.<sup>10</sup> Halsey or DeBaKey needle holders with serrated jaws are used to lock onto curved needles by a ratchet mechanism. The authors prefer a size 5-0 synthetic, absorbable monofilament material with a swaged-on, taper-point round, non-cutting needle for suturing tooth extraction sites in cats (Figure 10). Square or surgeon's knots should be followed by four more throws to ensure knot security.<sup>9</sup>

Chlorhexidine gluconate (0.12%) is used for rinsing the mouth prior to tooth extraction. The results of a study conducted on canine fibroblasts suggest that the least toxic solution for rinsing open wounds is lactated Ringer's solution.<sup>9</sup> Autogenous bone (cancellous bone and cortical bone chips) as well as allograft-based (demineralized bone of the same species) and ceramic-based (calcium phosphate, calcium sulfate and bioglass) bone graft substitutes are most commonly used in veterinary dentistry, although they are not routinely needed in extraction sites.<sup>12,13</sup> Gauze swabs (size 3 x 3 inches, 7.5 x 7.5 cm) allow digital control of hemorrhage during tooth extraction procedures. Lavage with refrigerated lactated Ringer's solution may also provide good hemostasis. Excessive bleeding from tooth extraction sites near tubular structures such as the mandibular and infraorbital canals can effectively be controlled by packing the alveolar sockets with a small amount of bone wax (a sterile beeswax-based compound).<sup>9</sup>



**Figure 10** Size 5-0 synthetic, absorbable monofilament material with a swaged-on, taper-point round, non-cutting needle

#### Practical considerations

- ✦ If a tooth needs to be extracted in the area of previous radiation therapy, the procedure should be performed soon after the acute side effects have worn off (eg, after 6–8 weeks) rather than waiting months or years, as the potential for wound healing will not improve but become progressively worse.
- ✦ Obtaining signed or witnessed verbal consent from the client about the number of teeth to be removed is important prior to performing any tooth extraction.

## Tooth extraction techniques

### Closed extraction

Closed extraction in the cat is primarily performed for maxillary and mandibular incisors, maxillary second premolars, maxillary first molars, and mobile teeth presenting with significant attachment loss. Employing a closed extraction technique for other teeth risks their fracture, which then warrants an open extraction technique in order to remove root remnants.

The gingival attachment around the tooth is incised with a number 15 scalpel blade. A dental elevator with a curved blade that best fits the circumference of the tooth is selected. The instrument is inserted into the periodontal ligament space between the tooth and alveolar bone. Careful and steady rotation of its handle will create pressure on the tooth and causes the periodontal ligament to stretch and tear.<sup>3</sup> (Note that performing a 'wiggling' motion has the potential to crush adjacent alveolar bone.) As the periodontal ligament space is widened, the dental elevator can be advanced apically and rotational pressure is repeated. The instrument should be inserted at other sites around the tooth until it is mobile enough for retrieval with an extraction forceps. The apex of the extracted tooth is inspected and palpated, ensuring no fracture has occurred. The extraction site is debrided with a surgical curette, and sharp bony edges are smoothed. The wound is rinsed and then sutured closed in a simple interrupted pattern.<sup>6,14</sup>

Sectioning of multi-rooted teeth provides two or more single-rooted crown–root segments that are extracted as if they were single-rooted teeth. Gentle reflection of the gingiva with a periosteal elevator will reveal the exact location of the furcation, decreasing the risk of damage to the gingiva during tooth sectioning. Sectioning is accomplished with a fissure bur, starting from the furcation and progressing through the crown.<sup>3</sup> Two-rooted teeth are separated into two single-rooted crown–root segments. The three-rooted maxillary fourth premolar tooth is separated into three one-rooted crown–root segments. In addition to vertical advancement of a dental elevator into the periodontal ligament space, the instrument can also be inserted horizontally in between the sectioned crown–root segments to lever them out of their alveoli.<sup>6,14</sup>



**Closed extraction is primarily performed for maxillary and mandibular incisors, maxillary second premolars, maxillary first molars, and mobile teeth presenting with significant attachment loss.**



**Open extraction**

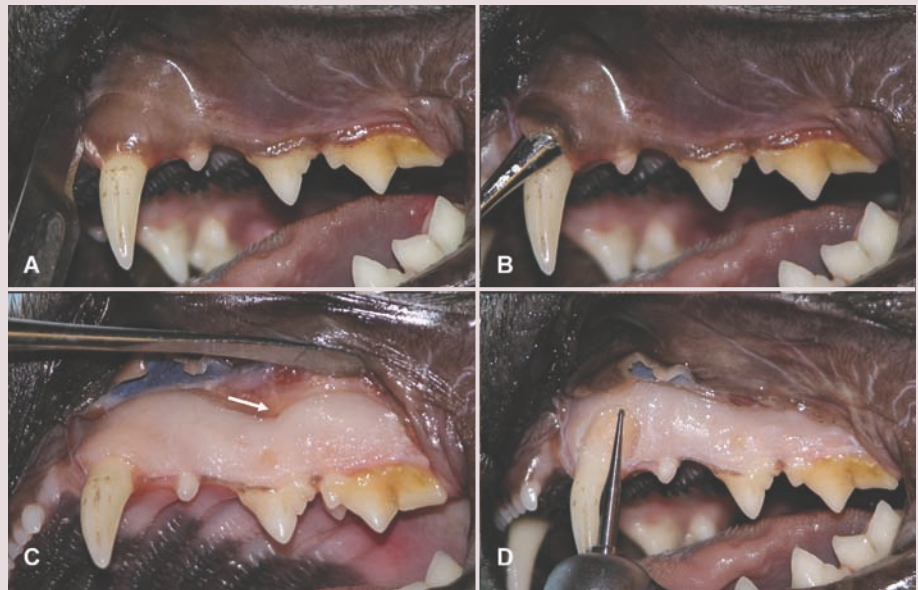
Feline teeth are quite delicate due to their small size and become even more brittle when affected by resorption. An open extraction technique is employed particularly when multiple teeth in one jaw quadrant require removal. Other indications for open extraction include large and periodontally intact permanent teeth, unerupted teeth and – rather rare in the cat – firmly seated deciduous canine teeth. Extraction of maxillary and mandibular canine and cheek teeth in a cat is illustrated in Figures 11–23.

The gingival attachment around the tooth is incised with a number 15 scalpel blade. One

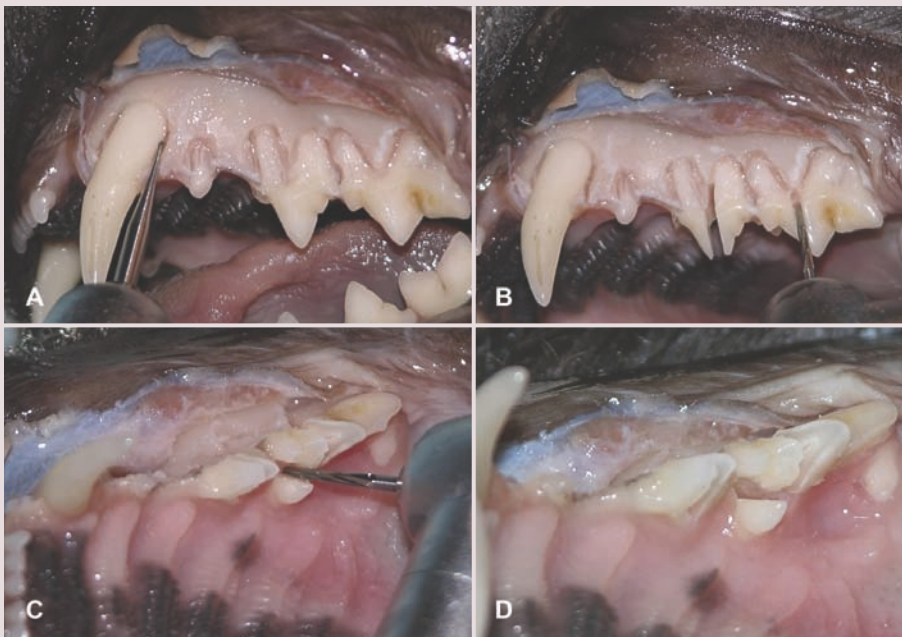
or two releasing incisions, extending from the gingival margin over the mucogingival junction 3–7 mm (depending on flap location) into alveolar mucosa, are made and a full-thickness (mucoperiosteal) flap is raised. Smaller to mid-sized, round carbide burs attached to a water-cooled dental handpiece are used to remove alveolar bone at the labial and buccal tooth surface by as much as one- to two-thirds of the length of each root.<sup>3</sup> Septal bone does not have to be removed, except when approaching the mesiopalatal root of the maxillary fourth premolar. Narrow slots can be created at mesial and distal aspects of each root to allow for better elevator purchase.

**Open extraction of left maxillary canine (204) and cheek teeth (206–209) in a cat**

**Figure 11** A vertical releasing incision is made into gingiva and alveolar mucosa at the mesial aspect of the canine tooth (A). A triangular oral flap is raised with a periosteal elevator (B and C); note the position of the infraorbital neurovascular bundle as it exits the infraorbital canal at the infraorbital foramen (arrow). Alveolectomy is performed with a round bur (D)



**Figure 12** Narrow slots are created with a round carbide bur at mesial and distal aspects of each root (A). Multi-rooted teeth are sectioned with a cross-cut fissure bur (B). The mesiopalatal crown-root segment must be separated from the mesiobuccal crown-root segment of the fourth premolar tooth (C and D)



Continued on pages 907–910



**Open extraction is performed principally when multiple teeth in one jaw quadrant require removal, as well as for large and periodontally intact permanent teeth and unerupted teeth.**



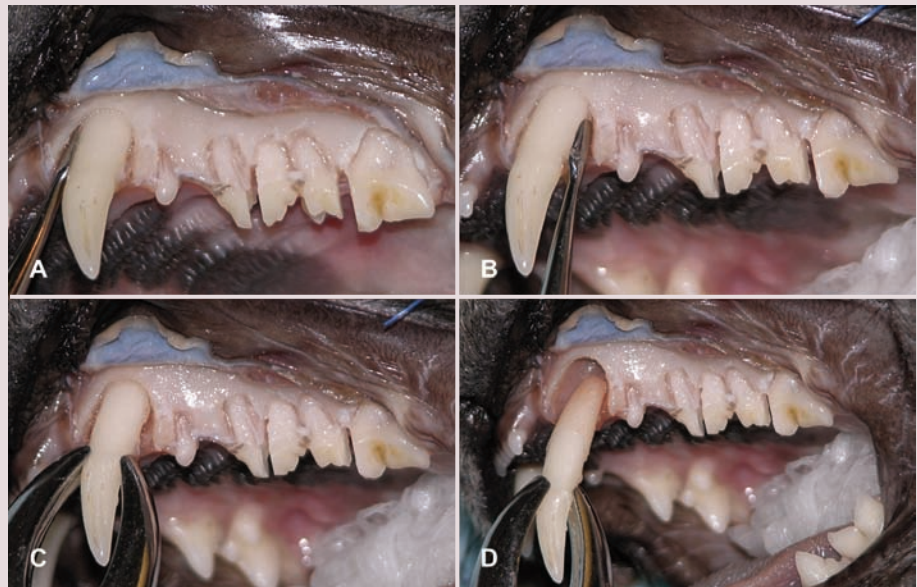Sectioning of multi-rooted teeth, extraction of crown–root segments, debridement and rinsing of the wound are performed as described for the closed extraction technique. Slight deflection of lingually/palatally located gingiva allows for safe smoothing of alveolar bone and avoids iatrogenic injury to soft tissues.<sup>3,6,14</sup>

Irregular or necrotic flap margins are trimmed with Metzenbaum scissors. The con-

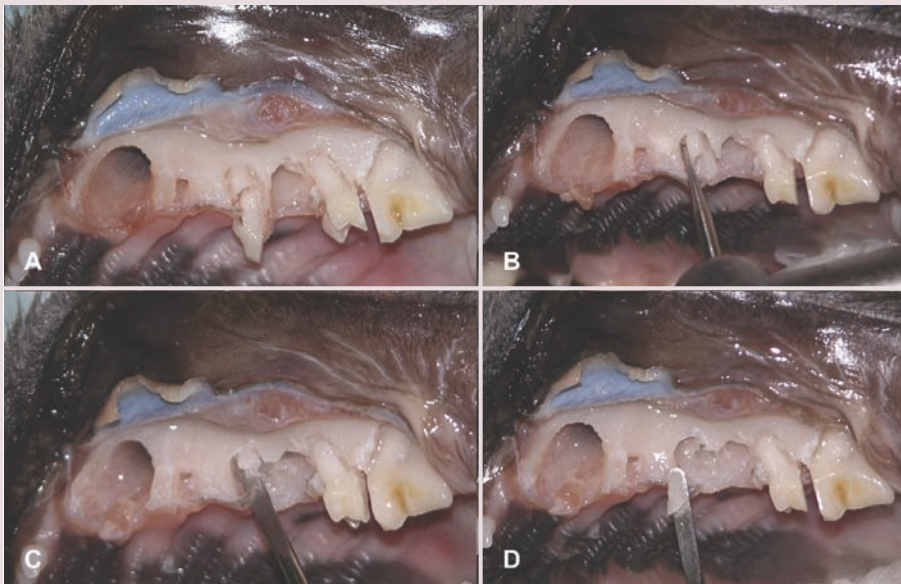
nective tissue side of the flap is debrided with a surgical curette, ensuring removal of infected and inflamed granulation tissue. Utilizing stay sutures or grasping a flap on its connective tissue side with a thumb forceps will minimize iatrogenic trauma to the flap margin. The periosteum at the base of the flap is incised in a distomesial direction, allowing the flap to become mobile.<sup>15</sup> The back of a scalpel blade can be used to ‘strum’ and weaken the periosteal layer, followed by blunt dissection with scissors. A small stab incision might also be made in the periosteum through which the blade tips of closed scissors are inserted and opened to undermine the periosteal layer. The wound is rinsed and the flap sutured to the palatal/lingual gingiva in a simple interrupted pattern.<sup>3,16,17</sup>

Continued from page 906

**Figure 13** A dental elevator is inserted into the periodontal ligament space between the canine tooth and alveolar bone, and rotated to stretch and tear the periodontal ligament (A and B). Once the tooth is mobile enough, it is grasped as far apically as possible with an extraction forceps and removed (C and D)



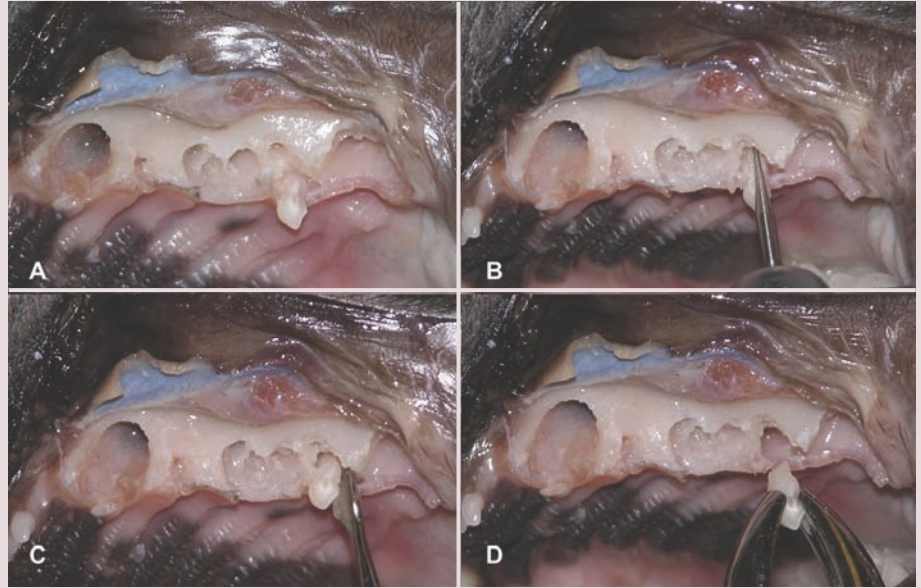
**Figure 14** Fracture of the mesial crown–root segment of the third premolar has occurred (A). Additional alveolar bone around the root remnant is removed with a round carbide bur (B). A special root tip elevator is used to elevate and retrieve the root remnant (C and D)



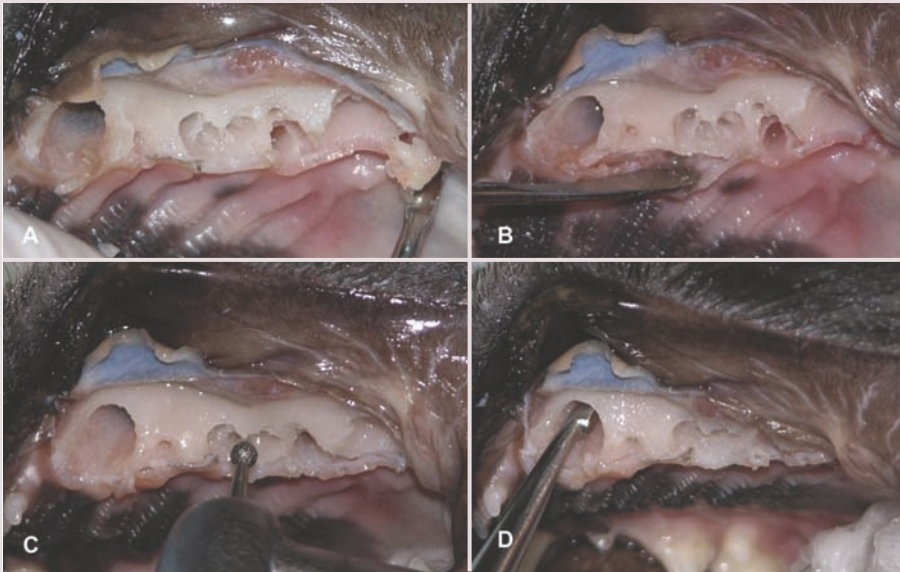


Continued from pages 906–907

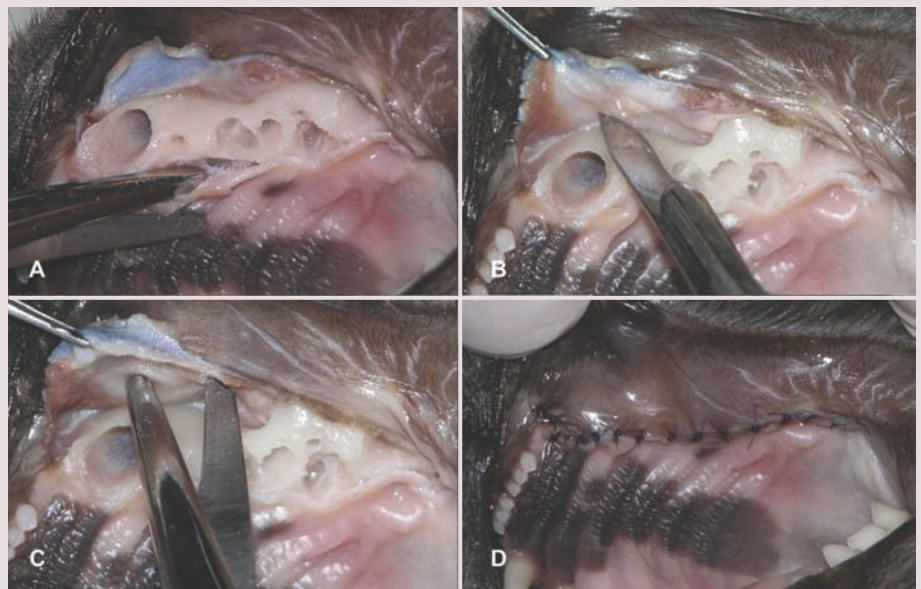
**Figure 15** The mesiopalatal crown-root segment of the fourth premolar is still in place (A). The septal bone separating the already extracted mesiobuccal crown-root segment from the mesiopalatal crown-root segment is reduced with a round carbide bur (B). The mesiopalatal crown-root segment is elevated and removed (C and D)



**Figure 16** The first molar tooth is extracted (A). The gingiva on the palatal aspect is elevated (B). Sharp bony edges are smoothed with a round medium-coarse diamond bur (C), and the alveolar sockets are debrided with a surgical curette (D)

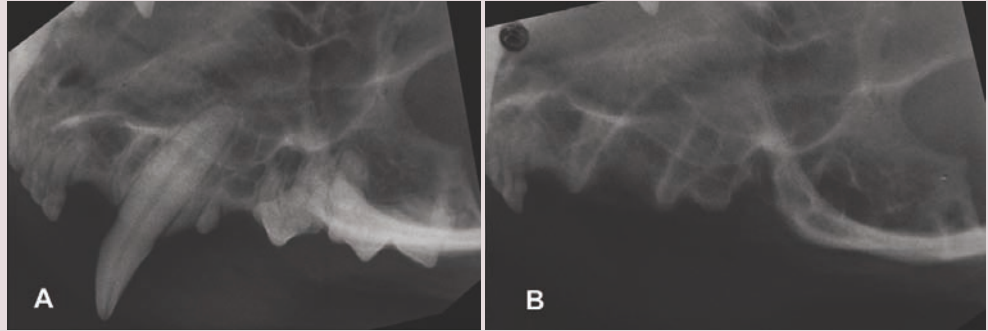


**Figure 17** Irregular wound margins are trimmed with tissue scissors (A). The periosteum at the base of the flap is incised with a blade (B) and bluntly dissected with tissue scissors (C). The flap is sutured to the palatal gingiva in a simple interrupted pattern (D)

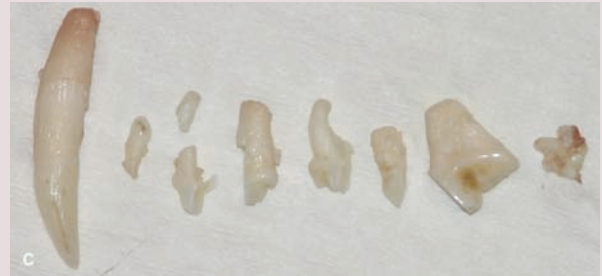



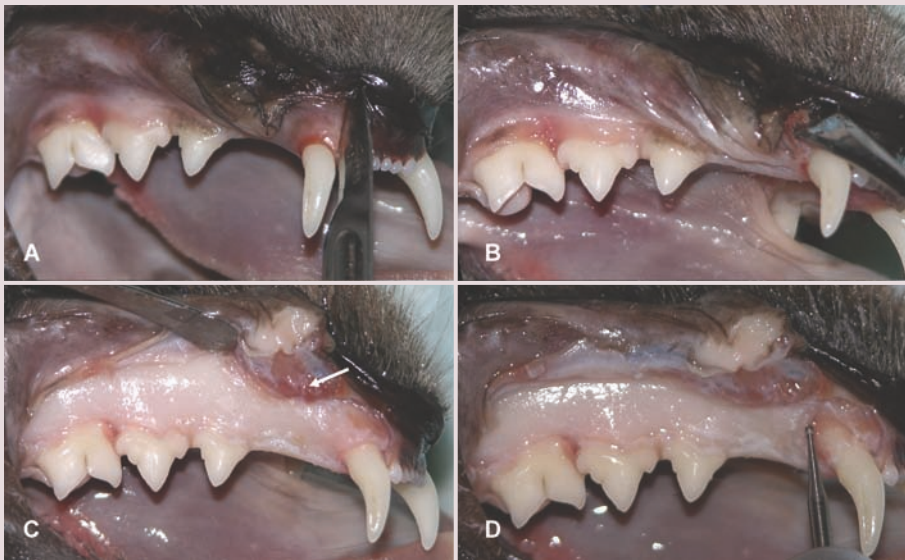Continued from pages 906–908



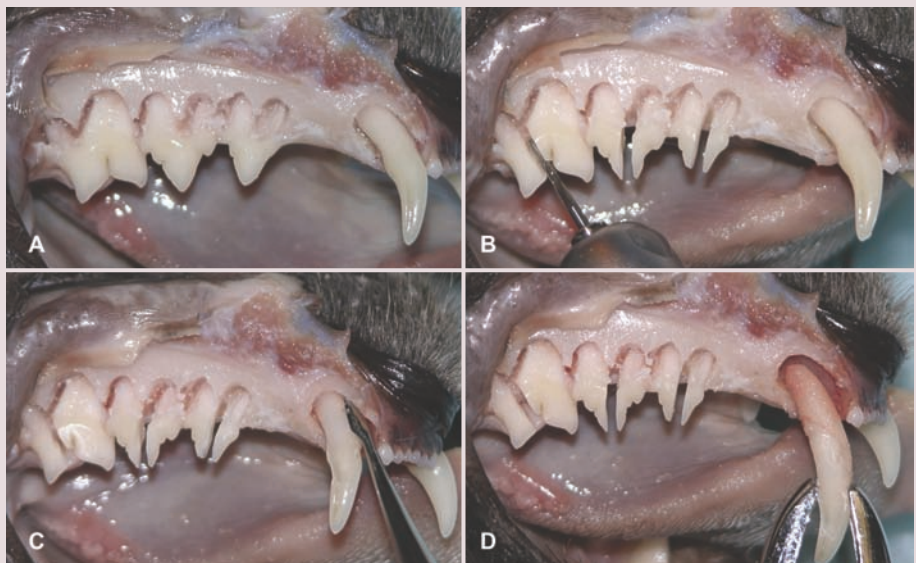**Figure 18** Dental radiographs obtained before (A) and after (B) tooth extraction. The extracted teeth are lined up (C)



**Figure 19** A vertical releasing incision is made into gingiva and alveolar mucosa at the mesial aspect of the canine tooth (A). A triangular oral flap is raised with a periosteal elevator (B and C); note the position of the middle mental neurovascular bundle as it exits the mandibular canal at the middle mental foramen (arrow). Alveolotomy is performed with a round bur (D)

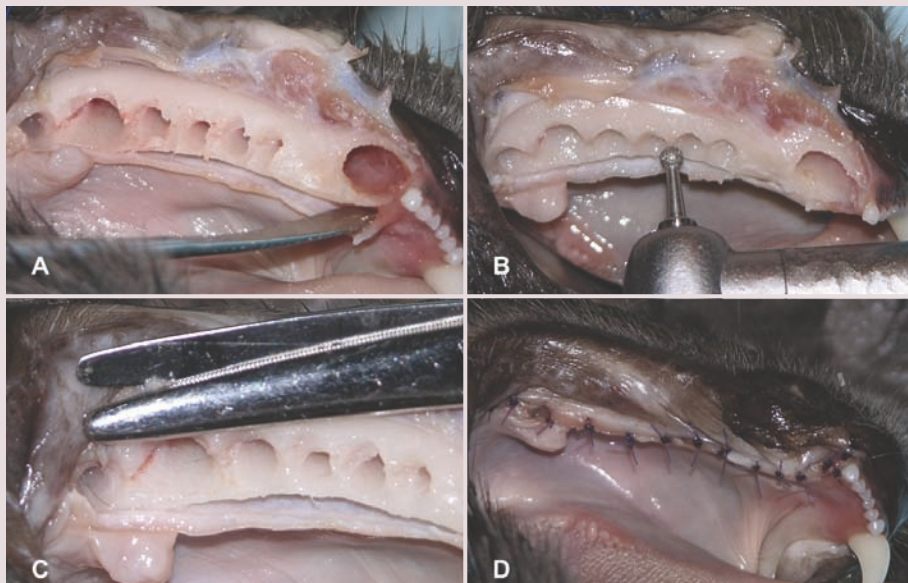
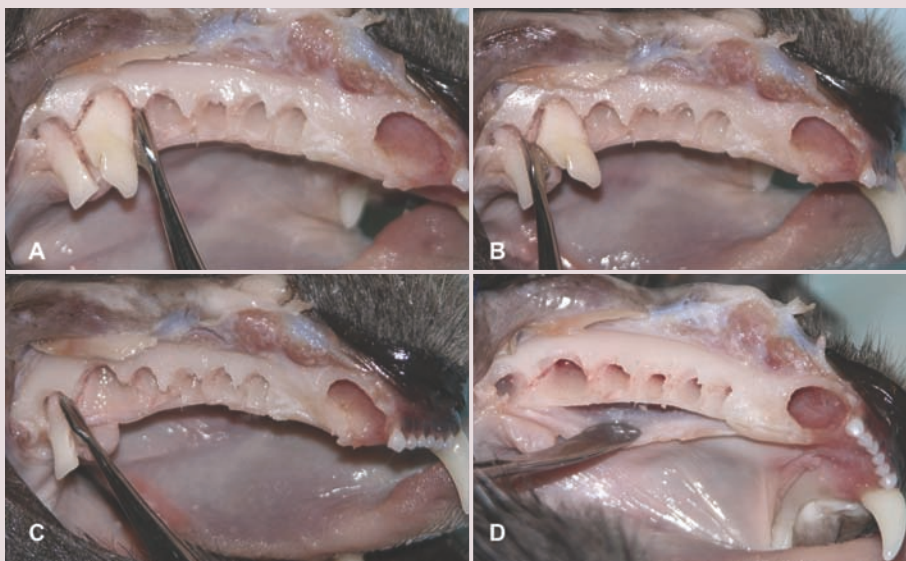

**Figure 20** Narrow slots have been created with a round bur at mesial and distal aspects of each root (A). Multi-rooted teeth are sectioned with a cross-cut fissure bur; note that the furcation of the first molar is distal to the middle of its M-shaped crown (B). The canine tooth is elevated and removed (C and D)

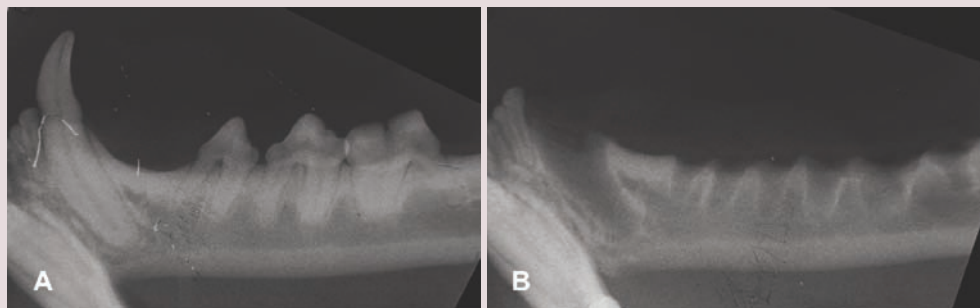


Continued from  
pages 906–909

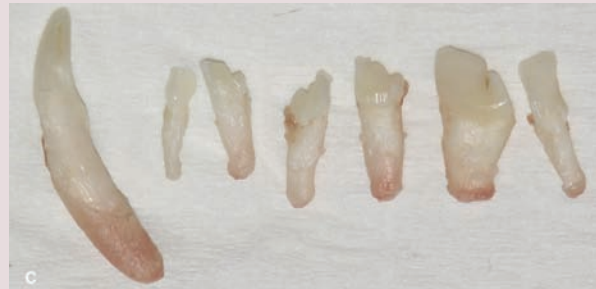**Figure 21** The sectioned crown-root segments of the first molar are elevated and removed (A–C). The gingiva on the lingual aspect is elevated (D)



**Figure 22** The gingiva on the lingual aspect is elevated up to the empty alveolus of the extracted canine tooth to facilitate suture placement (A). Sharp bony edges are smoothed with a round medium-coarse diamond bur (B). Irregular wound margins are trimmed with tissue scissors (C). The flap is sutured to the lingual gingiva in a simple interrupted pattern (D)



**Figure 23** Dental radiographs obtained before (A) and after (B) tooth extraction. The extracted teeth are lined up (C)





### Extraction of root remnants

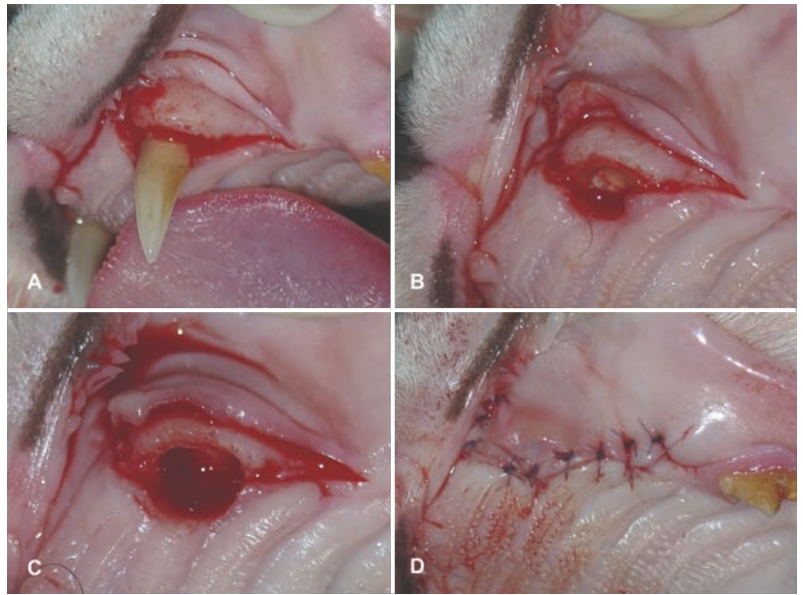
Root remnants under healthy gingiva and embedded within normal bone (eg, no periapical pathology) may be left where they are. In cats, they often appear clinically as a small gingival bulge in the area of a missing tooth. Retained roots that 'poke' through the gingiva, root remnants with sinus tracts, roots fractured during the extraction procedure, and roots remaining after mandibulectomies and maxillectomies must be removed to prevent infection and inflammation of the bone.<sup>3,18,19</sup>

The temptation to utilize a bur in a dental handpiece to 'pulverize' or 'drill out' a retained root must be resisted. Complications associated with this amateurish technique include incomplete removal of dental tissue, alveolar bone damage, injury to inferior alveolar and infra-orbital neurovascular bundles, transportation of root tissue into the mandibular canal, infra-orbital canal or nasal cavity, and subcutaneous and sublingual emphysema and air embolus.<sup>6</sup>

Special root tip elevators and root tip forceps are available for removal of small root remnants. If removal in a closed fashion is not possible, a mucoperiosteal flap and partial alveolectomy should be performed to facilitate complete tooth extraction.<sup>20</sup> If the tooth fractures during open extraction, additional alveolar bone (if necessary, the entire alveolar bone labial or buccal to the root remnant) is removed so that the root remnant can safely be retrieved. An endodontic file can be threaded into the root canal of a root remnant to help retrieve it.<sup>21</sup> Retrieval of root remnants from the mandibular canal, infraorbital canal or nasal cavity after accidental repulsion into these spaces must be carefully planned to avoid significant hemorrhage.<sup>3</sup>

### Crown amputation

Many teeth in cats undergo dentoalveolar ankylosis and root replacement resorption. Such teeth have lost their periodontal ligament space and the roots are fused to alveolar bone. Therefore, in the absence of tooth mobil-



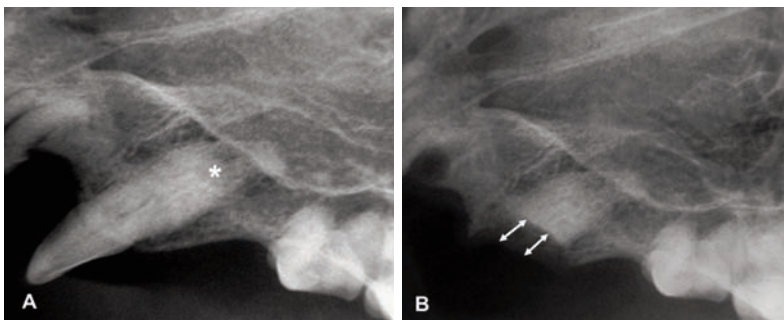
**Figure 24** Clinical photographs showing crown amputation of the left maxillary canine tooth (204) with intentional retention of resorbing root tissue in a cat. A mucoperiosteal flap is raised (A). The crown is amputated with a cross-cut fissure bur at the level of the cervical portion of the tooth (B). The resorbing root is reduced with a round medium-coarse diamond bur to about 1–2 mm below the level of the alveolar margin (C). The gingiva is sutured closed over the wound (D)

**Root remnants under healthy gingiva and embedded within normal bone may be left where they are.**



ity, periodontitis, endodontic disease, periapical pathology and stomatitis, teeth with dentoalveolar ankylosis and root replacement resorption can be managed by crown amputation with intentional retention of resorbing root tissue. This procedure should only be employed when closed or open extraction cannot be accomplished on teeth with radiographic confirmation of dentoalveolar ankylosis and root replacement resorption.<sup>3</sup>

The procedure begins by incising the gingival attachment around the tooth. A mucoperiosteal flap with or without releasing incisions is made. The crown is severed from the remainder of the tooth with a round or fissure bur attached to a high-speed handpiece. The resorbing root is further reduced with a round diamond bur to about 1–2 mm below the level of the alveolar margin (Figures 24 and 25). This allows a blood clot to form over the remaining root tissue into which alveolar bone can grow during healing. The flap is sutured over the wound, and postoperative radiographs are obtained.<sup>3,22</sup>



**Figure 25** (A) Preoperative radiograph of the left maxillary canine tooth from Figure 24, showing root replacement resorption (asterisk). (B) Postoperative radiograph following crown amputation, showing reduction of the resorbing root to about 1–2 mm below the level of the alveolar margin (double-ended arrows)

### Postoperative management

Pain control and wound care are accomplished with analgesic medications and antiseptic oral gels. Cats seem to tolerate the taste of zinc ascorbate gel better than that of chlorhexidine gluconate products.<sup>3</sup> Soft food should be given for 2 weeks. Cats with stomatitis undergoing partial or full-mouth tooth extraction may benefit from placement of an oesophagostomy feeding tube.<sup>23</sup>

## Avoidance and management of complications

The entire tooth must be removed in order to avoid complications such as local or systemic infection.<sup>18,19</sup>

❖ **Retained root remnants** If a root remnant cannot be retrieved, a note is made in the dental record and the client informed about the complication. The surgical site should be evaluated periodically by means of clinical and radiographic follow-up examinations.<sup>11</sup>

❖ **Hemorrhage** Bleeding can usually be controlled by means of digital pressure with a gauze swab. Severe bleeding is rare and likely due to injury of vessels in the mandibular or infraorbital canal or the mucosa of the nasal cavity. Packing a small amount of bone wax into an alveolus is usually sufficient to stop excessive bleeding.<sup>3</sup>

❖ **Iatrogenic trauma** Repeated brief 'wiggling' motions during tooth extraction will crush and soften adjacent alveolar bone, making elevation of a tooth more difficult. Excessive leverage against adjacent teeth should be avoided to prevent their elevation or fracture. Developing permanent teeth could be injured when extracting adjacent deciduous teeth.<sup>3</sup> Instrument slippage could cause local or distant soft tissue trauma or injury to the operator or assistant.<sup>24-26</sup>

❖ **Sublingual edema** Iatrogenic trauma or excessive pharyngeal packing can result in sublingual edema. Intravenous dexamethasone may be administered if respiratory compromise is present.

❖ **Sublingual sialocele** Injury to salivary ducts in sublingual tissues occasionally causes a sublingual sialocele (ranula), which is treated by marsupialization or resection of the sublingual and mandibular glands.<sup>3</sup>

❖ **Mandibular fracture** Mandibular fracture is usually due to insufficient preparation prior to extraction (eg, important pathology remaining undetected because radiographs were not obtained) or the use of excessive

Repeated  
'wiggling'  
motions during  
tooth extraction  
will crush and  
soften adjacent  
alveolar bone,  
making  
elevation of  
a tooth  
more difficult.



force. It is more likely in the presence of severe periodontitis or other pathology that has weakened the jaw bone. When occurring near the mandibular canine,<sup>27</sup> the fracture often is non-displaced, and creating two intraosseous sutures may be sufficient for healing.

❖ **Oronasal fistula** Oronasal communication in the area of a missing maxillary canine tooth is rare in the cat. An acute oronasal fistula may be encountered during extraction of maxillary teeth and is managed by suturing a flap over the extraction site.<sup>3</sup>

❖ **Bite trauma** After extraction of a maxillary canine tooth, the tight upper lip may position more palatally, allowing the ipsilateral mandibular canine tooth to bite into it. Reducing the pointed tip of the mandibular canine by 1 mm (be careful about pulp exposure!) is usually sufficient to solve the problem; exposed dentin should be treated with a layer of unfilled resin (dental adhesive) to reduce postoperative sensitivity.

❖ **Emphysema** Emphysema sometimes occurs after tooth sectioning or alveolectomy with air-driven high-speed equipment. This usually resolves spontaneously within days. Air must never be blown into alveolar sockets or onto bleeding surfaces, as it can cause air emboli.<sup>3,28</sup>

❖ **Wound breakdown** Wound dehiscence is primarily caused by tension on suture lines. The wound can be resutured or is left to granulate and epithelialize. A blood clot remaining in the alveolus, regardless of whether or not the extraction site is sutured closed, will avoid local infection and inflammation such as alveolar osteitis ('dry socket').

❖ **Non-healing extraction site** If an extraction site is not healing, a biopsy is warranted to rule out neoplasia.

Note that temporary bacteremia during and after tooth extraction procedures is not an indication for the perioperative use of systemic antibiotics in an otherwise healthy patient.<sup>3</sup>

### KEY POINTS

- ❖ The veterinarian should be familiar with the tissues that hold the teeth in the jaws.
- ❖ The client must consent to the number of teeth to be removed prior to the procedure being performed.
- ❖ Proper instrument handling is paramount in avoiding iatrogenic injury.
- ❖ Feline teeth are quite delicate and become brittle when affected by resorption.
- ❖ The entire tooth must be removed in order to avoid local or systemic infection.
- ❖ Tension is the most common reason for flap dehiscence.
- ❖ Roots remaining in the jaws must be recorded in the patient's medical record.





## Funding

The authors received no specific grant from any funding agency in the public, commercial or not-for-profit sectors for the preparation of this article.

## Conflict of interest

The authors do not have any potential conflicts of interest to declare.

## References

- 1 Gracis M. **Orofacial anatomy and physiology.** In: Tutt C, Deepprose J and Crossley D (eds). *BSAVA manual of canine and feline dentistry*. 3rd ed. Gloucester: BSAVA, 2007, pp 1–21.
- 2 Orsini P and Hennes P. **Anatomy of the mouth and teeth of the cat.** *Vet Clin North Am Small Anim Pract* 1992; 22: 1265–1277.
- 3 Reiter AM. **Dental and oral diseases.** In: Little SE (ed). *The cat: clinical medicine and management*. St Louis, MO: Saunders, 2012, pp 329–370.
- 4 Verstraete FJ and Terpak CH. **Anatomical variations in the dentition of the domestic cat.** *J Vet Dent* 1997; 14: 137–140.
- 5 Okuda A, Inoue E and Asari M. **The membranous bulge lingual to the mandibular molar tooth of a cat contains a small salivary gland.** *J Vet Dent* 1996; 13: 61–64.
- 6 Reiter AM. **Dental surgical procedures.** In: Tutt C, Deepprose J and Crossley D (eds). *BSAVA manual of canine and feline dentistry*. 3rd ed. Gloucester: BSAVA, 2007, pp 178–195.
- 7 Martin-Flores M, Scriveri PV, Loew E, et al. **Maximal and submaximal mouth opening with mouth gags in cats: implications for maxillary artery blood flow.** *Vet J* 2014; 200: 60–64.
- 8 Stiles J, Weil AB, Packer RA, et al. **Post-anesthetic cortical blindness in cats: twenty cases.** *Vet J* 2012; 193: 367–373.
- 9 Reiter AM. **Oral surgical equipment for small animals.** *Vet Clin North Am Small Anim Pract* 2013; 43: 587–608.
- 10 Lipscomb V and Reiter AM. **Surgical materials and instrumentation.** In: Brockman DJ and Holt DE (eds). *BSAVA manual of canine and feline head, neck and thoracic surgery*. Gloucester: BSAVA, 2005, pp 16–24.
- 11 Smith MM. **Exodontics.** *Vet Clin North Am Small Anim Pract* 1998; 28: 1297–1319.
- 12 Da Silva AM, Souza WM, Souza NT, et al. **Filling of extraction sockets with autogenous bone in cats.** *Acta Cir Bras* 2012; 27: 82–87.
- 13 Da Silva AM, Astolpho RD, Perri SH, et al. **Filling of extraction sockets of feline maxillary canine teeth with autogenous bone or bioactive glass.** *Acta Cir Bras* 2013; 28: 856–862.
- 14 DeBowes LJ. **Simple and surgical exodontia.** *Vet Clin North Am Small Anim Pract* 2005; 35: 963–984.
- 15 Smith MM. **The periosteal releasing incision.** *J Vet Dent* 2008; 25: 65–68.
- 16 Blazejewski S, Lewis JR and Reiter AM. **Mucoperiosteal flap for extraction of multiple teeth in the maxillary quadrant of the cat.** *J Vet Dent* 2006; 23: 200–205.
- 17 Smith MM. **Extraction of teeth in the mandibular quadrant of the cat.** *J Vet Dent* 2008; 25: 70–74.
- 18 Moore JI and Niemiec B. **Evaluation of extraction sites for evidence of retained tooth roots and periapical pathology.** *J Am Anim Hosp Assoc* 2014; 50: 77–82.
- 19 Reiter AM, Brady CA and Harvey CE. **Local and systemic complications in a cat after poorly performed dental extractions.** *J Vet Dent* 2004; 21: 215–221.
- 20 Woodward TM. **Extraction of fractured tooth roots.** *J Vet Dent* 2006; 23: 126–129.
- 21 Gengler B. **Extraction of teeth in the dog and cat.** *Vet Clin North Am Small Anim Pract* 2013; 43: 573–585.
- 22 DuPont GA. **Crown amputation with intentional root retention for dental resorptive lesions in cats.** *J Vet Dent* 2002; 19: 107–110.
- 23 Fink L, Jennings M and Reiter AM. **Placement of esophagostomy feeding tubes in cats and dogs.** *J Vet Dent* 2014; 31: 133–138.
- 24 Paiva SC, Froes TR, Lange RR, et al. **Iatrogenic nasolacrimal duct obstruction following tooth extraction in a cat.** *J Vet Dent* 2013; 30: 90–94.
- 25 Smith MM, Smith EM, La Croix N, et al. **Orbital penetration associated with tooth extraction.** *J Vet Dent* 2003; 20: 8–17.
- 26 Westermeyer HD, Ward DA, Whittemore JC, et al. **Actinomyces endogenous endophthalmitis in a cat following multiple dental extractions.** *Vet Ophthalmol* 2013; 16: 459–463.
- 27 Volker MK and Luskin IR. **Surgical extraction of the mandibular canine tooth in the cat.** *J Vet Dent* 2012; 29: 134–137.
- 28 Gunew M, Marshall R, Lui M, et al. **Fatal venous air embolism in a cat undergoing dental extractions.** *J Small Anim Pract* 2008; 49: 601–604.

Available online at [jfms.com](http://jfms.com)

Reprints and permission: [sagepub.co.uk/journalsPermissions.nav](http://sagepub.co.uk/journalsPermissions.nav)  
For reuse of images only, contact the corresponding author