

# UC Irvine

## UC Irvine Previously Published Works

### Title

Language recovery after epilepsy surgery of the Broca's area.

### Permalink

<https://escholarship.org/uc/item/53v2b41h>

### Authors

Mnatsakanyan, Lilit  
Vadera, Sumeet  
Ingalls, Christopher W  
et al.

### Publication Date

2018


### DOI

10.1016/j.ebcr.2017.06.002

### Copyright Information

This work is made available under the terms of a Creative Commons Attribution License, available at <https://creativecommons.org/licenses/by/4.0/>

Peer reviewed



## Case Report

## Language recovery after epilepsy surgery of the Broca's area

Lilit Mnatsakanyan <sup>a,\*</sup>, Sumeet Vadera <sup>b</sup>, Christopher W. Ingalls <sup>c</sup>, Jie Zheng <sup>d</sup>, Mona Sazgar <sup>a</sup>, Frank P. Hsu <sup>b</sup>, Jack J. Lin <sup>a</sup><sup>a</sup> Department of Neurology, University Of California, Irvine, United States<sup>b</sup> Department of Neurological Surgery, University of California, Irvine, United States<sup>c</sup> Long Beach, CA, United States<sup>d</sup> Department of Biomedical Engineering, University Of California, Irvine, United States

## ARTICLE INFO

## Article history:

Received 3 May 2017

Received in revised form 23 May 2017

Accepted 7 June 2017

Available online 17 June 2017

## Keywords:

Epilepsy surgery

Eloquent cortex

Language and epilepsy

Refractory epilepsy

Electrocorticography

## ABSTRACT

Epilepsy surgery is indicated in select patients with drug-resistant focal epilepsy. Seizure freedom or significant reduction of seizure burden without risking new neurological deficits is the expected goal of epilepsy surgery. Typically, when the seizure onset zone overlaps with eloquent cortex, patients are excluded from surgery. We present a patient with drug-resistant frontal lobe epilepsy who underwent successful surgery with resection of Broca's area, primarily involving the pars triangularis (BA 45). We report transient expressive aphasia followed by recovery of speech. This case provides new insights into adult neuroplasticity of the language network.

© 2017 The Authors. Published by Elsevier Inc. This is an open access article under the CC BY-NC-ND license (<http://creativecommons.org/licenses/by-nc-nd/4.0/>).

## 1. Introduction

Surgical treatment can provide a potential cure for drug-resistant focal epilepsy [1]. Accurate localization of the seizure onset zone (SOZ) prior to resection is required to delineate surgical margins and achieve postoperative seizure control. Up to 40% of patients with drug-resistant focal epilepsy may not qualify for surgery because of the inability to localize the SOZ, multiple seizure foci or the overlap of the SOZ with eloquent cortex [2]. Palliative therapies such as vagus nerve stimulation, and more recently, and more recently, responsive neurostimulation are alternatives to surgical resection. The increasing experience with the surgical techniques, neuroimaging, and intracranial EEG allows better patient selection, more accurate identification of the seizure onset region, thus higher rate of successful resective surgery [3–5]. Furthermore, direct stimulation of the subdural electrodes provides a map of the functional cortex and define resection margins. Ten to 40% of the left-handed individuals may be right hemisphere dominant for language. Language may be more bilaterally distributed in the left-handed than in the right-handed people. Individuals with epilepsy have a higher rate of atypical language representation than the healthy population. Predictors of atypical language organization include left-handedness, and left hemisphere lesions, age at seizure onset and presence of brain pathology, i.e. hippocampal atrophy [6].

Here we report a young woman who underwent intracranial EEG monitoring, with successful localization of the seizure onset zone. Her functional cortical mapping determined that the SOZ overlapped with the frontal language area. Despite counseling against epilepsy surgery given the high risk of postoperative language deficits, the patient elected to undergo surgical resection. Post-operatively, she had expressive aphasia but language abilities recovered in approximately 3 months. We discuss potential mechanisms for the functional recovery.

## 2. Case history

We studied a 30-year-old left-handed Hispanic woman with nonlesional focal epilepsy. Without antecedent risk factors, she experienced the first seizure at 16 years old during her first pregnancy and the seizures persisted at a rate of approximately 3 times per month. The seizure semiology consisted of an aura of “unintelligible voices” followed by left face distortion and bilateral tonic-clonic convulsions. Was referred to our center on 3 anti-seizure drugs (ASD): lacosamide, levetiracetam and lamotrigine. Brain MRI and FDG-PET were normal. However, video-EEG monitoring suggested that the seizure onset was in the right frontotemporal region, and magnetoencephalography (MEG) showed a cluster of spikes in the right inferior frontal and insular regions (Fig. 1B). Wada test showed right hemisphere dominance for language. She underwent invasive EEG monitoring with right frontotemporal subdural grid coverage. The SOZ was identified in the inferior frontal area (Fig. 1A, C). Functional language mapping was performed at bedside using a cortical stimulator (Astro-Med, Inc., Grass

\* Corresponding author.

E-mail address: [mnatsakl@uci.edu](mailto:mnatsakl@uci.edu) (L. Mnatsakanyan).

Technologies) with real time monitoring of after discharges. The following parameters were used for stimulation: stimulus frequency = 50 Hz, pulse duration = 500 ms, intensity = 2 mA, increments of 2 mA until speech arrest or a maximal intensity of 15 mA. The language tasks consisted of auditory responsive naming and Boston naming tasks. The functional mapping results showed that language responsive electrodes overlapped with the SOZ (Fig. 1D).

Although the patient was informed that a localized resection of the frontal lobe carried a high risk of expressive aphasia, she was resolute in her decision to undergo the procedure. A tailored cortical resection of SOZ in the right inferior frontal lobe (pars triangularis, BA 45) was performed, targeting the most active contacts in the seizure onset zone (Fig. 1E). Following the operation, the patient was mute. After one month of aggressive speech therapy, the muteness was overcome by aphasic speech. Subsequently, she demonstrated gradual improvement of the expressive aphasia, transitioning from unintelligible speech to severe dysarthria, with continual refinement of speech articulation. She showed dramatic recoveries with residual word finding difficulties and mild speech slowness after one year. Her neuropsychological test performance at that time was comparable to her pre-surgical assessment except for a decline in the picture-naming task (Table 1). Finally, there was an improvement of the Beck Depression score.

She continued to report subjective improvements of speech articulation and has remained seizure free at 3.5 year follow up after surgery except for a single breakthrough seizure 3 months postoperatively after rapid discontinuation of ASDs due to termination of the medical insurance. She was able to successfully discontinue one ASD and lower maintenance doses of the two remaining ASDs.

### 3. Discussion

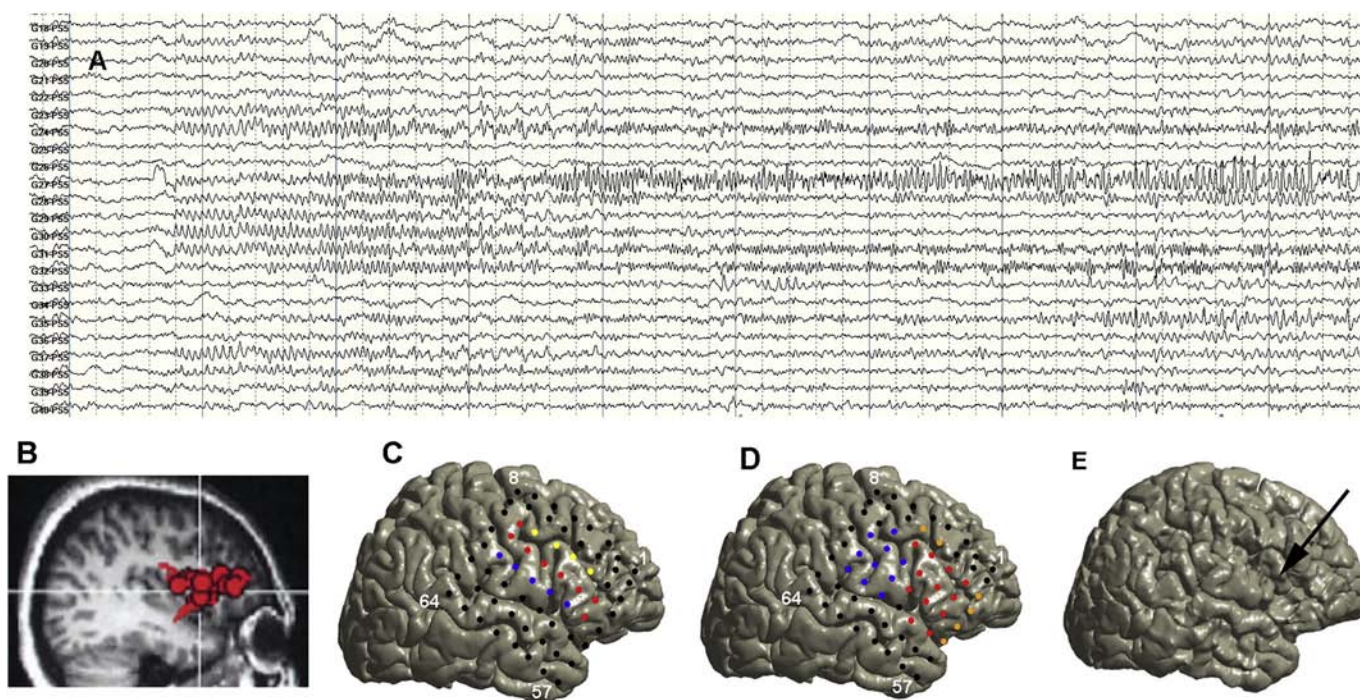
In the mid 1800s, Paul Broca treated patients with speech production deficits; autopsies of these patients revealed lesions in the posterior inferior frontal gyrus, now referred to as “Broca’s area” [7]. More recent

**Table 1**

Neuropsychological testing: preoperative and postoperative testing T-score comparison.

Test employed completed 8th grade	Initial exam T scores	Follow up exam T scores
<b>WASI-II FSIQ T score</b>	<b>27</b>	<b>35</b>
<b>Verbal comprehension T score</b>	<b>26</b>	<b>35</b>
Perceptual reasoning T score	31	38
Vocabulary T score	14	39
Block design T score	34	36
Matrix reasoning T score	32	42
Peabody picture vocabulary test-4	37	42
<b>RBANS total scale index</b>	<b>21</b>	<b>29</b>
Immediate memory index	34	37
List learning	37	41
Story memory	26	31
<b>Visuospatial constructional index</b>	<b>25</b>	<b>45</b>
Figure copy	26	57
Line orientation	27	37
Language index	14	19
<b>Picture naming</b>	<b>13</b>	<b>–15</b>
Semantic fluency	21	37
Attention index	23	18
Digit span	23	31
Coding	41	23
Delayed memory index	38	46
Delayed list recall	53	42
Delayed list recognition	38	38
Delayed story recall	26	40
Delayed figure recall	26	50
FAS initial PMR follow-up (raw score)	[15]	[17]
Boston naming	25	
Trails A	22	39
Trails B	13	21
<b>Beck depression inventory 2 raw</b>	<b>36/63 severe</b>	<b>3/63 minimal</b>
<b>Beck anxiety inventory raw score</b>	<b>19/63 moderate</b>	<b>9/63 mild</b>

studies using functional imaging and electrocortical stimulation show that Broca’s area contains anatomical subdivision with distinct functions in the service of language processing. The posterior part, the pars



**Fig. 1.** A. Intracranial EEG from the frontal subdural grid showed seizure onset with low voltage fast activity in the electrode contacts 23.24. 27–32, 37, 38). B. MEG Spikes localized to the right inferior frontal region. C. Three-dimensional cortical models of the patient was generated using pre-operative structural magnetic resonance (MR) imaging and co-registered with the post-operative CT images using to identify electrode locations. Red dots denote seizure onset with low voltage fast activity; blue dots denote early propagation; yellow dots denote late sporadic propagation. D. Functional language mapping results: red denotes naming pauses; orange denotes naming hesitancy; blue indicates face and tongue motor regions. E. Three-dimensional rendering of postoperative MRI, with arrow indicating the area of resection in the right inferior frontal area.

opercularis, is critical for phonological processing; the superior part, pars triangularis, is implicated in syntactic processing, and the anterior part, pars orbitalis, is involved in a large semantic network integrated with the inferior frontooccipital fasciculus [8]. Following surgical resection of the primary expressive language areas, our patient demonstrated a marked loss and subsequent rehabilitation of speech production and fluency. Although the mechanisms of her speech recovery are unknown, we suggest several possibilities including reorganization, transfer of function, and redistribution of the connectivity network, activation of other language areas or enhanced compensatory performance of the nearby non-resected cortex possibly due to cerebral plasticity.

Indefrey and Levelt proposed that Broca's area accesses a phonological word representation that is then forwarded to motor regions where it is transformed into an articulatory (i.e., phonetic) code [9]. Models of speech production [10,11] do not limit the articulatory transformation to motor cortices but rather implicate Broca's area in processing articulatory representations. More recently, using direct cortical surface recordings in neurosurgical patients, Flinker and colleagues studied the evolution of activity in cortical neuronal populations, and found that, Broca's area mediates a cascade of activation from sensory representations of words in temporal cortex to their corresponding articulatory gestures in motor cortex, but it is surprisingly quiescent during articulation [12]. The premotor area was implicated during speech production. Contrary to classic notions of this area's role in speech, these results indicated that Broca's area does not directly participate in production of individual words, but coordinates the transformation of information processing across large-scale cortical networks involved in spoken word production, prior to articulation. Other regions, such as the insula, have also been implicated in the coordination of the speech [13,14]. In brain tumor surgery, participation of the anterior insular cortex in the dominant hemisphere during language tasks was reported using functional neuroimaging [15]. Therefore, resection of the Broca's area might disrupt coordination of sensory representations without directly impacting speech articulations.

Another potential mechanism of speech recovery is functional reorganization of the language network. Essential cortical sites are usually found in a spatially confined (approximately 1 cm<sup>2</sup>) cortical areas, and often are directly adjacent to sites that do not have any apparent effect from stimulation [16,17]. The likelihood of long-term postoperative language deficit appears to be correlated with the distance between the resection margin and essential cortical site. Resections have been tolerated up to 1 cm from these essential language sites without inducing permanent morbidity, and recent reports suggest equivalent rates of permanent deficits when resections are performed without leaving a margin from positive stimulation sites [17–20]. A cohort of 309 patients with glioma, when guiding the resection based on intraoperative mapping, showed that the risk of postoperative neurological decline was significantly less in patients with brain regions mapped negative for language function compared to those with positive mapping [20]. Interestingly, Southwell et al. [21] demonstrated during repeat glioma surgeries 1.1% of sites tested negative for function during initial surgery was found to be positive during the repeat surgery while the mapping techniques remained the same. Forty percent of sites that were initially mapped positive had become negative for function. Loss of function at these sites was not associated with neurological impairment at the time of repeat surgery, suggesting that neurological function was preserved through neural circuit reorganization or activation of latent functional pathways. Gert et al. found functional variability in brain areas close to the tumor when comparing functional MRI before and after the surgery suggesting that transient post-surgical language recovery involves restoration of functioning of the presurgical language system, and cannot be linked to functional reorganization in language homolog brain areas [22]. A greater patient-to-patient variability in functional localization [16,23–25] and the preexisting pathology is also thought to play a role in the brain plasticity. A reorganization, and cerebral plasticity were contemplated for recovery from SMA syndrome

and hemispherectomy case series. A possible recruitment of the areas in the vicinity of the lesion, or nonlesioned SMA have been suggested, but the transfer of SMA activity from the affected hemisphere to the intact hemisphere was not sufficient to prevent the occurrence of postoperative functional deficit. Resections of the supplementary motor area may result into speech deficits that are known to resolve within weeks to months time. And the initial mutism may be due to transient circulatory changes in the adjacent speech areas [26–29]. A similar time course was noted in our patient's recovery.

Patients with early onset epilepsy (<5 years old) and left hemisphere lesion are more likely to demonstrate atypical language dominance [30]. It has been proposed that chronic seizures alter brain function and structure over time, leading to a shift of language pathways during development from the left to the right hemisphere. Our patient did not have early onset epilepsy or a left hemispheric lesion. Therefore it is unlikely that the right hemisphere language dominance noted in this patient was a result of chronic epileptic activity. Whether the right language dominance indicates additional sites for language representation, or larger area of functional representation, is unknown.

It is important to note that the common practice is to exclude patients with localized drug-resistant epilepsy from the potentially curative surgery if the seizure onset zone (defined by extensive intracranial monitoring) overlaps or is within 1–2 cm area of eloquent language or motor areas. Neuromodulation therapies have become important alternatives and further ASD adjustments could provide efficacy however will not be curative. At the time of the intracranial invasive evaluation in this particular patient, the FDA had not approved the responsive neurostimulation.

#### 4. Conclusion

A satisfactory epilepsy surgery was performed involving eloquent language centers. Although our patient had expected profound expressive aphasia, she showed significant recovery over one year and remained satisfied with her functional state and quality of life. The functional recovery demonstrated in our patient might be due to reorganization of language network, activation of other language areas or enhanced compensatory performance of the nearby non-resected cortex. The epilepsy surgery involving speech production areas as well as better understanding of the “eloquent” brain regions, such as Broca's area deserve further investigation. While there was satisfactory outcome and improved quality of life, our findings may not be applicable to other patients with co-localization of language and ictal onset zone.

#### References

- [1] Engel Jr J, Wiebe S, French J, Sperling M, Williamson P, Spencer D, et al. Practice parameter: temporal lobe and localized neocortical resections for epilepsy: report of the Quality Standards Subcommittee of the American Academy of Neurology, in Association with the American Epilepsy Society and the American Association of Neurological Surgeons. *Neurology* 2003;60:538–47.
- [2] DeGiorgio CM, Krahl SE. Neurostimulation for drug-resistant epilepsy. *Continuum* 2013;19(3):743–55.
- [3] Najm I, Jehi L, Palmieri A, Gonzalez-Martinez J, Paglioli E, Bingaman W. Temporal patterns and mechanisms of epilepsy surgery failure. *Epilepsia* 2013;54(5):772–82.
- [4] Holtkamp M, Sharan A, Sperling MR. Intracranial EEG in predicting surgical outcome in frontal lobe epilepsy. *Epilepsia* 2012;53(10):1739–45.
- [5] Kim DW, Kim HK, Lee SK, Chu K, Chung CK. Extent of neocortical resection and surgical outcome of epilepsy: Intracranial EEG analysis. *Epilepsia* 2010;51(6):1010–7.
- [6] Połczyńska M, Benjamin C, Moseley B, Walshaw P, Eliashiv D, Vigil C, et al. Role of the Wada test and functional magnetic resonance imaging in preoperative mapping of language and memory: two atypical cases. *Neurocase* 2015;6:707–20.
- [7] Broca P. Remarks on the seat of the faculty of articulated language, following an observation of aphemia (loss of speech). *Bull Mem Soc Anat Paris* 1861;36:330–57.
- [8] Duffau H, Gatignol P, Mandonnet E, Peruzzi P, Tzourio-Mazoyer N, Capelle L. New insights into the anatomo-functional connectivity of the semantic system: a study using cortico-subcortical electrostimulations. *Brain* 2005;128:797–810.
- [9] Indefrey P, Levelt WJ. The spatial and temporal signatures of word production components. *Cognition* 2004;92(1–2):101–44.
- [10] Hickok G. Computational neuroanatomy of speech production. *Nat Rev Neurosci* 2012;13(2):135–45.

- [11] Hickok G, Poeppel D. The cortical organization of speech processing. *Nat Rev Neurosci* 2007;393–402.
- [12] Flinker A, Korzeniewsk A, Shestyuk A, Franaszczuk PJ, Dronkers NF, Knight RT, et al. Redefining the role of Broca's area in speech. *PNAS* 2015;112:2871–5.
- [13] Dronkers NF. A new brain region for coordinating speech articulation. *Nature* 1996;384(6605):159–61.
- [14] Trupe LA, Varma DD, Gomez Y, Race D, Leigh R, Hillis AE, et al. Chronic apraxia of speech and Broca's area. *Stroke* 2013;44(3):740–4.
- [15] Wise RJ, Greene J, Büchel C, Scott SK. Brain regions involved in articulation. *Lancet* 1999;353(9158):1057–61.
- [16] Ojemann GA. Cortical organization of language. *J Neurosci* 1991;11:2281–7.
- [17] Gil-Robles S, Duffau H. Surgical management of World Health Organization grade II gliomas in eloquent areas: the necessity of preserving a margin around functional structures. *Neurosurg Focus* 2010;28:E8.
- [18] Chang EF, Kunal P, Raygor AB, Berger MS. Contemporary model of language organization: an overview for neurosurgeons. *J Neurosurg* 2015;122:250–61.
- [19] Voss J, Meier TB, Freidel R, Kundu B, Nair VA, Holdsworth R, et al. The role of secondary motor and language cortices in morbidity and mortality: a retrospective functional MRI study of surgical planning for patients with intracranial tumors. *Neurosurg Focus* 2013;34(4):E7.
- [20] Kim SS, McCutcheon IE, Suki D, Weinberg JS, Sawaya R, Lang FF, et al. Awake craniotomy for brain tumors near eloquent cortex: correlation of the intraoperative cortical mapping with the neurological outcomes in 309 patients. *Neurosurgery* 2009;64:836–46.
- [21] Southwell DG, Hervey-Jumper SL, Perry DW, Berger MS, et al. Intraoperative mapping during repeat awake craniotomy reveals the functional plasticity of adult cortex. *J Neurosurg* 2015;124:1460–9.
- [22] Kristo G, Raemaekers M, Rutten G, Gelder B, Ramsey N. Inter-hemispheric language functional reorganization in low-grade glioma patients after tumour surgery. *Cortex* 2015;64:235–48.
- [23] Gould L, Mickleborough MJ, Wu A, Tellez J, Ekstrand C, Lorentz E, et al. Presurgical language mapping in epilepsy: using fMRI of reading to identify functional reorganization in a patient with long-standing temporal lobe epilepsy. *EBCR* 2016;5:6–10.
- [24] Sanai N, Mirzadeh Z, Berger MS. Functional outcome after language mapping for glioma resection. *N Engl J Med* 2008;358:18–27.
- [25] Duffau H, Denvil D, Capelle L. Long term reshaping of language, sensory, and motor maps after glioma resection: a new parameter to integrate in the surgical strategy. *J Neurol Neurosurg Psychiatry* 2002;72:511–6.
- [26] Rosenberg K, Nossek F, Liebling R, Fried I, Shapira-Lichter I, Hendlert T, et al. Prediction of neurological deficits and recovery after surgery in the supplementary motor area: a prospective study in 26 patients. *J Neurosurg* 2010;113:1152–63.
- [27] Bannur U, Rajshekhar V. Post operative supplementary motor area syndrome: clinical features and outcome. *Br J Neurosurg* 2000;14(3):204–10.
- [28] Krainik A, Duffau H, Capelle L, Cornu P, Boch A, Mangin J, et al. Role of the healthy hemisphere in recovery after resection of the supplementary motor area. *Neurology* 2004;62:1323–32.
- [29] Schramm J, Delev D, Wagner J, Elger C, von Lehe M. Seizure outcome, functional outcome, and quality of life after hemispherectomy in adults. *Acta Neurochir* 2012;154:1603–14.
- [30] Duffau H, Capelle L, Denvil D, Sichez N, Gatignol P, Lopes M, et al. Functional recovery after surgical resection of low grade gliomas in eloquent brain: hypothesis of brain compensation. *J Neurol Neurosurg Psychiatry* 2003;74:901–7.