

# UC San Diego

## UC San Diego Previously Published Works

**Title**

Spontaneous Intracranial Hypotension May Be an Under-recognized Cause of Endolymphatic Hydrops.

**Permalink**

<https://escholarship.org/uc/item/51v902dh>

**Journal**

Otology & Neurotology, 41(7)

**ISSN**

1531-7129

**Authors**

Sakano, Hitomi  
Jafari, Aria  
Allehaiby, Wisam  
et al.

**Publication Date**

2020-08-01

**DOI**

10.1097/mao.0000000000002665

Peer reviewed

# Spontaneous Intracranial Hypotension May Be an Under-recognized Cause of Endolymphatic Hydrops

\*†Hitomi Sakano, †Aria Jafari, †‡Wisam Allehaiby, and †Jeffrey P. Harris

\*Department of Otolaryngology, University of Rochester, Rochester, New York; †Department of Otolaryngology; and ‡Department of Health Science International, University of California San Diego, San Diego, California

**Objective:** We describe three rare cases of spontaneous intracranial hypotension (SIH) presenting with symptoms of endolymphatic hydrops (EH) and perform a literature review to bring attention to a rare link between SIH and EH.

**Patient:** A 59-year-old female presented with postural headache, aural fullness, vertigo, hearing loss, and abnormal electrocochleography after being diagnosed with SIH by magnetic resonance imaging. The site of cerebrospinal fluid leak was identified in this individual. Two additional patients with vertigo, hearing loss, and SIH were identified by retrospective chart review.

**Intervention:** All patients underwent blood patches. One patient also had diuretic treatment while another had fibrin glue injection.

**Main Outcome Measures:** The outcomes of interest were resolution of headache, vertigo, aural fullness, and hearing loss.

**Results:** All patients eventually improved with time. Literature review suggests that overall outcome is excellent.

**Conclusions:** SIH may be an under-recognized cause of EH. We support the theory that negative intracranial pressure transmitted through the cochlear aqueduct and perilymph leads to EH. Despite the variations in treatments, the overall prognosis is excellent. **Key Words:** Endolymphatic hydrops—Menière’s—Pachymeningitis—SIH—Spontaneous intracranial hypotension—Vertigo.

*Otol Neurotol* 41:e860–e863, 2020.

We present three cases of spontaneous intracranial hypotension (SIH) presenting with Menière’s-like symptoms and propose that SIH may be an under-recognized cause of endolymphatic hydrops (EH). The original discussion of SIH is attributed to Schaltenbrand in 1938; the cardinal symptom is postural headache. This is an uncommon condition with an incidence of 5 per 100,000 (1). SIH is presumed to be due to either low cerebrospinal fluid (CSF) production or leak but a leak is identified in only 26 to 55% of patients, typically in the spine (1). The diagnosis is supported by characteristic magnetic resonance imaging (MRI) features such as downward displacement of the aqueduct and tonsil and enhancement of the meninges (pachymeningitis) (2). Menière’s disease is an idiopathic disorder characterized by the presence of vertigo, tinnitus, and hearing loss first described by Prosper Menière. In 2015, the Classification Committee of the Bárány Society published a new criterion for definite Menière’s disease (3). The pathophysiology has been attributed to increased pressure and

volume of the scala media (4–6) (or EH) which is observed in a majority, but not all cases, of Menière’s. What triggers Menière’s is unknown but likely variable in etiology. EH is not specific to Menière’s and can be caused by other disorders such as trauma, viral labyrinthitis, or autoimmune inner ear disease. We present three cases of SIH presenting with Menière’s-like symptoms and summarize all 10 patients reported in the literature thus far (including this study).

## METHODS

Case 1 presented in the outpatient clinic. Two additional patients with SIH were identified by retrospective review of 2169 patients with Menière’s diagnosis (Cases 2, 3).

### Case 1

A healthy 59-year-old female developed postural headache, right-sided hearing loss and tinnitus, and vertigo with head movement. She presented to otology clinic with a recent diagnosis of SIH with a known C7 and T1 spinal CSF leak for which she had undergone blood patch procedure. MRI showed pachymeningitis (Fig. 1) consistent with SIH. Audiogram revealed a low-frequency sensorineural hearing loss in the right ear (Fig. 2, left) and elevated SP/AP ratio of 0.96 on electrocochleography (Fig. 2, middle), consistent with EH. The patient underwent a second blood patch and over time her symptoms gradually improved and electrocochleography also normalized (Fig. 1, right). We did not prescribe diuretics

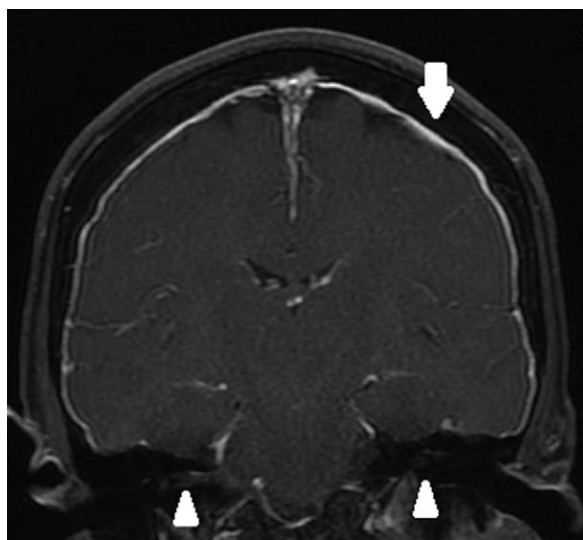
---

Address correspondence and reprint requests to Hitomi Sakano, M.D., Ph.D., Assistant Professor, Department of Otolaryngology, 601 Elmwood Avenue, Box 629, Rochester, NY 14642; E-mail: Hitomi\_sakano@urmc.rochester.edu

J.P.H. has equity interest in Otonomy, Inc.

The authors disclose no conflicts of interest.

DOI: 10.1097/MAO.0000000000002665

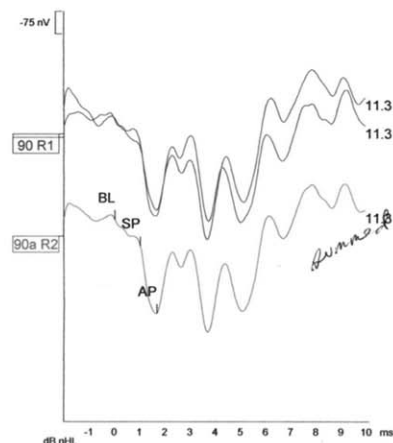
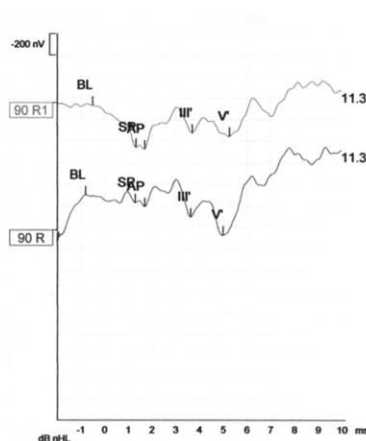
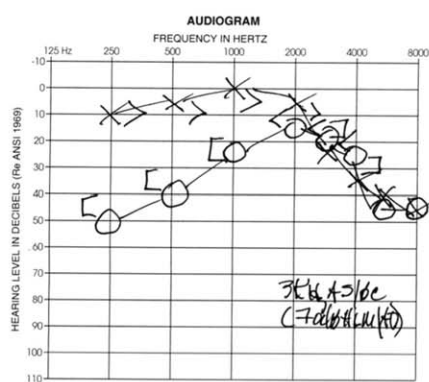


**FIG. 1.** MRI T1 with contrast. Arrow shows pachymeningitis. There is no enhancement of the vestibulocochlear nerves (arrowheads). MRI indicates magnetic resonance imaging.

because of concern it may exacerbate the intracranial hypotension.

### Case 2

A 58-year-old male presented with exertional headache, bilateral, fluctuating, rumbling tinnitus and hearing loss, and intermittent whirling vertigo lasting >3 hours. He was found to have fluctuating sensorineural hearing loss across frequencies on the left and in the low frequencies on the right. He had been diagnosed with SIH on MRI which showed pachymeningitis. Myelogram identified a suspicious region on T1 on myelogram but no active spinal CSF leak. He was treated with steroids which helped with hearing loss and tinnitus temporarily. He underwent three blood patch procedures and a fibrin glue injection. He also started turmeric supplements which he thought helped. His symptoms eventually improved.



**FIG. 2.** Audiogram (left) shows low-frequency sensorineural hearing loss in the right ear. Electrocochleography (middle) reveals SP/AP ratios are elevated at 0.66 (R) and 0.96 (R1). After blood patch treatment of CSF leak the SP/AP ratios normalized (right). CSF indicates cerebrospinal fluid.

### Case 3

A 63-year-old female presented with nonpostural headache, fluctuating bilateral hearing loss, roaring tinnitus in the right ear, and aural fullness. She later developed daily vertigo lasting 2 hours. MRI showed pachymeningitis and low hanging cerebellar tonsil. She had a lumbar puncture with an opening pressure of 5.5 cm (low) and was diagnosed with SIH. Serial audiograms showed fluctuating low-frequency sensorineural hearing loss in both ears. No CSF leak was ever identified but she eventually had one blood patch procedure at L3–4 which dramatically improved her headaches. Post procedure audiogram showed improved bone conduction in her left ear to baseline. Her right ear bone conduction thresholds remained stable but her speech discrimination score in this ear improved from 20 to 44%. She continued to have some aural symptoms for which she was treated on and off with hydrochlorothiazide/triamterene without much effect. She was then lost to follow-up.

### DISCUSSION

We present three patients with concomitant symptoms and findings of SIH and EH, supported at the very least by objective findings of pachymeningitis on MRI and fluctuating low-frequency hearing loss documented on serial audiograms. Case 1 was further supported by a known CSF leak and electrocochleography changes. All the patients underwent blood patch procedures. Symptoms improved for Case 1 and Case 2. For Case 3, headache and left-sided aural symptoms improved but not the right before being lost to follow-up.

A review of the literature identified seven additional cases of SIH with symptoms or signs of EH (7–13). A summary of the characteristics of all 10 total known cases is given (Table 1). All the patients had hearing loss, headache, and evidence of pachymeningitis on MRI. Although SIH is presumed to be due to CSF leak, it is occult in a majority of cases (1). CSF leak was identified or suspected in six (60%). Treatments vary widely from bedrest, diuretics, blood patch to spinal injections of various materials, but the overall outcome was excellent

**TABLE 1.** Summary of patients with intracranial hypotension presenting with endolymphatic hydrops

Reports	Age, Sex	PM	HA	HL	T	V	CSF Leak Identified?	Treatment	Symptom Resolution
Portier et al. 2002 (12)	37, M	✓	✓	✓	✓	✓	Not mentioned	Blood patch	Resolution
Miller et al. 2006 (11)	38, F	✓	✓	✓ <sup>b</sup>	✓	✓	T7-8	Blood patch ×4 bedrest, caffeine, steroids	Persistent symptoms Resolution
Street et al. 2009 (13)	60, F	✓	✓	✓	✓	✓	Could not find	Bed rest, caffeine, hydration	Resolution
Isildak et al. 2010 (10)	29, F	✓	✓	✓ <sup>b</sup>	✓	✓	Thoracolumbar	Blood patch, bedrest	Resolution
Fontaine et al. 2012 (8)	47, M	✓	✓	✓	✓	✓	C12	Acetazolamide, betahistine	Subdural hematoma needing craniotomy
								blood patch Glue patch	Persistent symptoms Resolution
Botica et al. 2016 (7)	54, M	✓	✓	✓	✓	✓	T6-9	Betahistine, cinnarazine, diuretics	Resolution
Fukushima et al. 2018 (9)	41, F	✓	✓	✓		✓	Could not find	Saline and isosorbide injection	Resolution
Sakano et al. 2020	59, F	✓	✓	✓	✓	✓	C7-T1	Blood patch ×2	Resolution
	58, M	✓	✓	✓ <sup>b</sup>	✓	✓	Suspected T1	Steroids, blood patch ×3, fibrin glue injection, tumeric	Resolution
	63, F	✓	✓	✓ <sup>b</sup>	✓	✓	Could not find	Dyazide, blood patch	HA resolved, aural symptoms partially improved, lost to follow-up

✓<sup>b</sup> indicates bilateral hearing loss specified; F, female; HA, headache; HL, hearing loss; M, male; PM, pachymeningitis on MRI; T, tinnitus; V, vertigo.

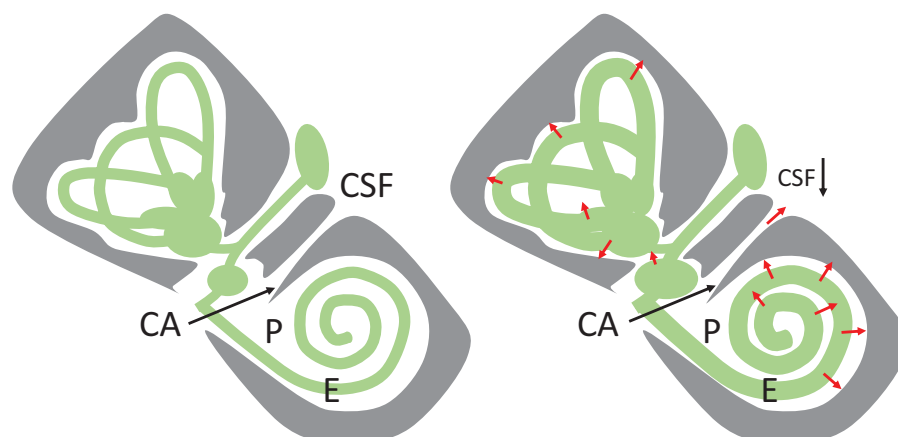
(>90%). Eight cases (80%) had some form of invasive procedure with or without conservative treatment and half of those required more than one procedure. Only two (20%) had conservative treatment only with bedrest with or without medications including diuretics. Diuretics were provided to Case 2 with minimal effect. We intentionally avoided diuretics in Case 1 due to concern that it would worsen her intracranial hypotension. Indeed, there is one reported case where diuretics resulted in subdural hematoma requiring evacuation (8). This patient eventually recovered after blood patch and conservative treatment. Overall, we are reassured by the excellent outcome of these patients. Because of the rarity of the condition, we cannot conclude whether the excellent outcome is reflective of the treatment or natural course of the disease.

Does SIH cause EH? Case 1 demonstrated electrocochleography changes consistent with EH. All three cases had low-frequency hearing fluctuations and intermittent vertigo that are certainly supportive. On literature review, there is one case (9) demonstrating enlargement of the endolymph by high-resolution MRI of the cochlea. There are new MRI methods of identifying EH, using a 4-hour delayed intravenous contrast-enhanced three-dimensional fluid attenuated inversion recovery MRI on a 3 Tesla scanner with 32-channel array head coil (14). However, this is available experimentally and is not yet standard practice. Although we cannot conclude that SIH causes EH based on a limited case series, 2 of 10 cases to date have objective findings consistent with EH. Future studies measuring EH by MRI on SIH patients and correlating it with audiovestibular symptoms will be

helpful in making a more conclusive link between SIH and EH.

What is the underlying pathophysiology? We support the existing theory that negative pressures transmitted through a patent cochlear aqueduct cause a reduction in the volume of perilymph within the cochlear turns (8,12,15,16). This would result in a concomitant expansion of the endolymphatic compartment to occupy the void (Fig. 3). It has been experimentally demonstrated in cats that a patent cochlear aqueduct transmits CSF pressures to the perilymph (15). Also, there have been reports of reversible hearing loss induced by iatrogenic losses of CSF (16). Although SIH and EH are not common, the two conditions are likely related and not coincidental. This is supported by the fact that many patients' aural symptoms improved as their headaches improved. Of course, it is possible that these two conditions both arose independently of each other and due to the rarity of SIH the association cannot be proven.

Not all patients with SIH develop EH. This may be explained by the high variability of the cochlear aqueduct anatomy as described by many studies over the past 80 years (17). It is a funnel-shaped structure with length of ~12.9 mm. The caudal end ranges from 0 to 11 mm and the narrower cochlear end is undetectable to not more than 2 mm in diameter (18). The narrowest portion is 200 to 300 μm from the cochlear end, bony blockage is seen in 4% and obliteration of the aqueduct in 3% (17). However, bony measurements may not correlate well with actual patency of the cochlear aqueduct. In 59% of cases the lumen is filled with connective tissues and the narrowest portion can measure as little as 138±58 μm



**FIG. 3.** Schematic diagram of the membranous labyrinth. Left represents the normal condition. Right represents endolymphatic hydrops secondary to spontaneous intracranial hypotension: low CSF pressures transmitted through a patent cochlear aqueduct (CA) and perilymph system (P) which causes expansion of the endolymph system (E). CSF indicates cerebrospinal fluid.

(17). Postmortem histology in future studies may be helpful in determining why only a subset of SIH patients develops EH.

### CONCLUSION

We propose that spontaneous intracranial hypotension may be a rare cause of endolymphatic hydrops. We support the theory that negative intracranial pressure transmitted through a patent cochlear aqueduct and perilymph leads to endolymphatic hydrops. It is important to screen Menière's patients for possible spontaneous intracranial hypotension diagnosis because the commonly used diuretic treatment may not be appropriate in this population. Overall, if the condition is recognized, the prognosis is excellent despite the variation in treatments rendered. More study however will be needed to understand the prevalence, natural course, and optimal treatment of this disorder.

### REFERENCES

- Kranz PG, Gray L, Amrhein TJ. Spontaneous intracranial hypotension: 10 myths and misperceptions. *Headache* 2018;58:948–59.
- Pannullo SC, Reich JB, Krol G, et al. MRI changes in intracranial hypotension. *Neurology* 1993;43:919–26.
- Lopez-Escamez JA, Carey J, Chung WH, et al. Diagnostic criteria for Meniere's disease. *J Vestib Res* 2015;25:1–7.
- Hallpike CS, Cairns H. Observations on the pathology of Meniere's syndrome (Section of otology). *Proc R Soc Med* 1938;31:1317–36.
- Yamakawa K. Über die pathologische Veränderung bei einem Menière-Kranken. Proceedings of 42nd Annual Meeting Oto-Rhino-Laryngol Soc Japan. *J Otolaryngol Soc Jpn* 1938;4: 2310–2.
- Merchant SN, Adams JC, Nadol JB Jr. Pathophysiology of Meniere's syndrome: Are symptoms caused by endolymphatic hydrops? *Otol Neurotol* 2005;26:74–81.
- Botica I, Vrca A, Spero M, et al. A thin line between Meniere's disease and spontaneous intracranial hypotension syndrome. *Med Glas (Zenica)* 2016;13:31–5.
- Fontaine N, Charpiot A, Debry C, et al. A case of spontaneous intracranial hypotension: From Meniere-like syndrome to cerebral involvement. *Eur Ann Otorhinolaryngol Head Neck Dis* 2012; 129:153–6.
- Fukushima M, Matsukawa N, Akahani S, et al. Secondary endolymphatic hydrops associated with spontaneous intracranial hypotension. *JAMA Otolaryngol Head Neck Surg* 2019;145:191–3.
- Isildak H, Albayram S, Isildak H. Spontaneous intracranial hypotension syndrome accompanied by bilateral hearing loss and venous engorgement in the internal acoustic canal and positional change of audiography. *J Craniofac Surg* 2010;21:165–7.
- Miller RS, Tami TA, Pensak M. Spontaneous intracranial hypotension mimicking Meniere's disease. *Otolaryngol Head Neck Surg* 2006;135:655–6.
- Portier F, de Minteguiga C, Racy E, et al. Spontaneous intracranial hypotension: A rare cause of labyrinthine hydrops. *Ann Otol Rhinol Laryngol* 2002;111:817–20.
- Street S, Fagan P, Roche J. Spontaneous intracranial hypotension presenting to the ENT surgeon: Case report. *J Laryngol Otol* 2009;123:804–6.
- Barath K, Schuknecht B, Naldi AM, et al. Detection and grading of endolymphatic hydrops in Meniere disease using MR imaging. *AJNR Am J Neuroradiol* 2014;35:1387–92.
- Carlborg BI, Farmer JC Jr. Transmission of cerebrospinal fluid pressure via the cochlear aqueduct and endolymphatic sac. *Am J Otolaryngol* 1983;4:273–82.
- Walsted A. Effects of cerebrospinal fluid loss on hearing. *Acta Otolaryngol Suppl* 2000;543:95–8.
- Gopen Q, Rosowski JJ, Merchant SN. Anatomy of the normal human cochlear aqueduct with functional implications. *Hear Res* 1997;107:9–22.
- Jackler RK, Hwang PH. Enlargement of the cochlear aqueduct: Fact or fiction? *Otolaryngol Head Neck Surg* 1993;109:14–25.