

# UCLA

## UCLA Previously Published Works

### Title

Percutaneous catheter interventions for cardiac transplant patients

### Permalink

<https://escholarship.org/uc/item/51v8q1sv>

### Journal

Journal of the American College of Cardiology, 39(5)

### ISSN

0735-1097

### Authors

Takano, Yuzuru

Guttman, Oren T

Currier, Jesse W

et al.

### Publication Date

2002-03-01

### DOI

10.1016/s0735-1097(02)80834-8

### Copyright Information

This work is made available under the terms of a Creative Commons Attribution License, available at <https://creativecommons.org/licenses/by/4.0/>

Peer reviewed

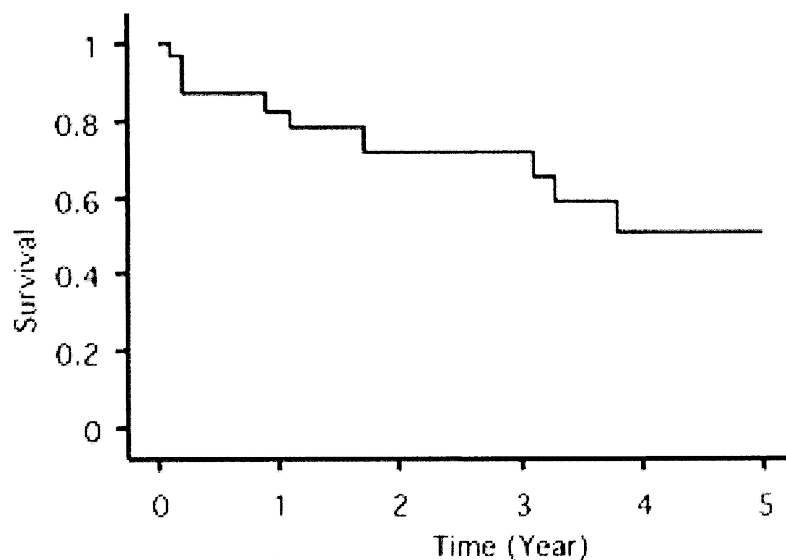
**Percutaneous Catheter Interventions for Cardiac Transplant**

**Patients.** *Y. Takano, J.M. Tobis, L.A. Yeatman, J.A. Kobashigawa, D. Marelli, M. Grise, J.R. Higgins, S. Miller, J.W. Currier. University of California at Los Angeles Center for Health Science, Los Angeles, California, USA.*

**Background:** Accelerated allograft arteriopathy limits the survival of patients who undergo orthotopic heart transplantation (OHT). Various interventional methods for revascularization have been used for treatment in these cases, but to date there have been few reports that assess the longitudinal results of these procedures. The purpose of this study was to analyze the contemporary outcome of percutaneous revascularization procedures for coronary stenosis in heart transplant patients.

**Methods:** A retrospective analysis was done on 96 coronary artery lesions from 31 patients who had OHT and were referred for percutaneous revascularization for allograft arteriopathy between March 1995 and March 2001. Procedural success was defined as a postprocedural lumen diameter stenosis <50%. Patient outcomes were based on yearly angiographic follow-up for restenosis. Allograft survival was defined as the absence of re-OHT or death. Angiographic restenosis at follow-up was defined as the return of >50% diameter stenosis.

**Results:** The procedural success rate was 97% without a major complication. Coronary stenting was performed in 50 lesions (52%). Angiographic follow-up in 55 lesions at  $9.1 \pm 6.7$  months showed a restenosis rate of 53%. The restenosis rate of de novo lesions (47%) was significantly less than that of repeat revascularization lesions (88%,  $p < 0.05$ ). The restenosis rate (43%) of stented lesions tended to be less than that of nonstented lesions (64%,  $p < 0.13$ ). The allograft survival rate was 51% at 5 years after intervention (re-OHT 7, death 3).



**Conclusion:** Percutaneous coronary intervention can be an effective and safe method of treatment for allograft arteriopathy or can act as a temporizing measure until re-OHT in patients with diffuse arteriopathy. The angiographic restenosis rate still remains high, even in stented lesions.