

UC Davis

UC Davis Previously Published Works

Title

Atypical presentation of Angelman syndrome with intact expressive language due to low-level mosaicism.

Permalink

<https://escholarship.org/uc/item/50x235vb>

Journal

Molecular genetics & genomic medicine, 10(10)

ISSN

2324-9269

Authors

Punatar, Ruchi
Egense, Alena
Mao, Rong
et al.

Publication Date

2022-10-01



DOI

10.1002/mgg3.2018

Peer reviewed

CLINICAL REPORT

Atypical presentation of Angelman syndrome with intact expressive language due to low-level mosaicism

Ruchi Punatar^{1,2}  | Alena Egense^{2,3} | Rong Mao^{4,5} | Melinda Procter⁴ | Michelle Bosworth⁴ | Denise I. Quigley⁴ | Kathleen Angkustsiri^{1,2} | Suma P. Shankar^{2,3} 

¹Division of Developmental Behavioral Pediatrics, Department of Pediatrics, University of California Davis, Sacramento, California, USA

²MIND Institute, University of California Davis, Sacramento, California, USA

³Division of Genomic Medicine, Department of Pediatrics, University of California Davis, Sacramento, California, USA

⁴ARUP Laboratories, Salt Lake City, Utah, USA

⁵Department of Pathology, University of Utah, Salt Lake City, Utah, USA

Correspondence

Suma P. Shankar, Division of Genomic Medicine, Department of Pediatrics, University of California Davis, Sacramento, CA, USA.
Email: spshankar@ucdavis.edu

Abstract

Background: Angelman syndrome (AS) occurs due to a lack of expression or function of the maternally inherited *UBE3A* gene. Individuals with AS typically have significant developmental delay, severe speech impairment with absent to minimal verbal language, gait abnormalities including ataxia, and an incongruous happy demeanor. The majority of individuals with AS also have seizures and microcephaly. Some individuals with mosaic AS have been reported to have expressive language and milder levels of developmental delay.

Case Report: We report a male patient presenting with mild to moderate intellectual disability, hyperphagia, obesity, and the ability to communicate verbally. His phenotype was suggestive of Prader-Willi syndrome. However, methylation testing was positive for Angelman syndrome and additional methylation specific multiplex ligation-dependent amplification (MS-MLPA) study revealed low-level mosaicism for AS.

Conclusion: A broader phenotypic spectrum should be considered for AS as patients with atypical presentations may otherwise elude diagnosis.

KEYWORDS

Angelman syndrome, case report, expressive language, mosaicism, MS-MLPA

1 | INTRODUCTION

Angelman syndrome (AS) and Prader-Willi syndrome (PWS) are two distinct disorders involving the imprinted region of chromosome 15q11.2-q13. In AS, the maternally inherited *UBE3A* allele is not expressed. Defects can be due to deletion, uniparental disomy (UPD), imprinting center defect, or a pathogenic variant in the *UBE3A* gene. Genetic testing with DNA methylation analysis will detect abnormalities associated with deletions of the maternally inherited *UBE3A* allele, UPD of the paternal chromosome 15, and imprinting defects. AS is typically characterized

by severe-to-profound developmental delay or intellectual disability, absent or minimal speech, gait abnormalities (such as toe-walking, prancing, movement disorder with a broad-based stance and arms upheld, ataxia, and tremulousness of limbs), behavioral phenotype of happy demeanor, and frequent laughing. Microcephaly and seizures are also common. (Buiting et al., 2016; Dagli & Williams, 2017; Smeets et al., 1992). PWS is caused by loss of expression of the paternally contributed 15q11.2-q13 region, which is most effectively detected by methylation testing. PWS is characterized by hypotonia and feeding difficulties in early infancy, followed by hyperphagia and

This is an open access article under the terms of the [Creative Commons Attribution-NonCommercial-NoDerivs](https://creativecommons.org/licenses/by-nc-nd/4.0/) License, which permits use and distribution in any medium, provided the original work is properly cited, the use is non-commercial and no modifications or adaptations are made.

© 2022 The Authors. *Molecular Genetics & Genomic Medicine* published by Wiley Periodicals LLC.

development of obesity in childhood. Motor and language development are delayed, but impairment tends to be milder in PWS as compared to AS (Driscoll et al., 2017; McCandless et al., 2011; Smeets et al., 1992).

AS and PWS are often taught as classic examples of genetic disorders from the same chromosome region affected by imprinting with distinct phenotypes. Here, we report on an individual with a clinical suspicion for PWS, who was found to instead have AS with low-level mosaicism.

2 | CLINICAL REPORT

A 16-year-old boy initially presented to a developmental behavioral pediatrician with early life hypotonia, obesity, hyperphagia, and intellectual disability. PWS was suspected due to these clinical concerns. Initial testing included negative cytogenomic SNP microarray with no evidence of uniparental isodisomy and normal fragile X (FMR1) studies. Angelman/Prader-Willi syndrome DNA methylation studies via methylation-specific polymerase chain reaction (MS-PCR) technology was positive for AS. He was referred to genomic medicine for further management.

This patient was born at term. He was noted to have significant hypotonia at birth, but no difficulty with feeding. His early motor milestones were appropriate with walking at 11 months. His language milestones were severely delayed. He never babbled, but he used sign language and a picture exchange communicate system to communicate during early childhood. At the age of 7 years, he had his first word and now predominately uses verbal language to communicate. He speaks in three to five word sentences, answers questions appropriately, and asks questions. He is able to follow two to three step instructions.

He has a history of gastroesophageal reflux disease since infancy and chronic diarrhea since childhood. He has been diagnosed with irritable bowel syndrome and is followed by a pediatric gastroenterologist. Around 3 years of age, he developed hyperphagia, and by 7 years of age, he was obese. He has a normal gait, but is hypotonic and is easily fatigued with physical activity. He is not able to jump or run. There is no history of seizures. He was diagnosed with intellectual disability and adaptive impairments during his early childhood using standardized testing. His Weschler Intelligence Scales for Children–Fourth Edition (WISC-IV) Perceptual Reasoning Index standard score was 51 and General Adaptive Composite on the Adaptive Behavior Assessment System–Third Edition (ABAS-3) standard score was 49. He has received special education services in school. Additionally, he has anxiety, ADHD predominantly inattentive presentation, and sleep difficulties. His family describes his demeanor

as “usually happy”, but also has some behavioral issues with aggression.

On exam, his growth parameters include weight: 98.2 kg (98th percentile, $Z = 2.16$), height: 176 cm (58th percentile, $Z = 0.21$), BMI: 31.6 kg/m² (98th percentile, $Z = 2.10$), and head circumference: 58 cm (97th percentile, $Z = 1.95$). He had rounded facies with mild bitemporal narrowing, almond shaped palpebral fissures, intermittent exotropia of the right eye, normal eyebrows, nose and ears, slightly thin upper lip, gynecomastia, and normal hands and feet other than hyperextensible fingers (Figure 1). He had low muscle tone with normal bulk, and he had a normal gait with no other significant neurological characteristic.

Given his history of hypotonia in infancy, obesity, hyperphagia, mild–moderate intellectual disability, intelligible speech, normal gait, and lack of seizures, classic AS did not match the patient's phenotype (summarized in Table 1).

3 | GENETIC ANALYSIS

Methylation specific-PCR (MS-PCR) for Prader-Willi syndrome and Angelman Syndrome was performed on the DNA extracted from patient's peripheral blood. The results showed paternal unmethylated allele detected, which indicated the patient's diagnosis was Angelman syndrome.



FIGURE 1 Photograph of patient with low-level mosaic Angelman syndrome.

TABLE 1 Phenotype and behavioral characteristics of Prader-Willi syndrome, Angelman syndrome, mosaic Angelman syndrome, and our patient

	Prader-Willi syndrome	Angelman syndrome	Mosaic Angelman syndrome	Our patient
Cognitive	Mild developmental delay or intellectual disability	Severe developmental delay or intellectual disability	Mild-to-moderate developmental delay or intellectual disability	Mild-to-moderate intellectual disability
Motor	Delayed early motor development	Gait ataxia, hypermotoric behavior	Ability to walk, though milestones are often delayed	Normal milestone for walking, but unable to run and jump due to hypotonia
Language	Delayed language milestones, articulation difficulties	Severe language impairment with absent or minimal speech	Expressive verbal language with often more than 20 words	Severe delay in early language milestones, now speaking in sentences
Neonatal Features	Neonatal hypotonia, feeding difficulty	Developmental delays noted around 6 months	Not known	Neonatal hypotonia
Feeding/Growth	Hyperphagia, morbid obesity, short stature	Some develop obesity	Hyperphagia, obesity	Hyperphagia, obesity
Behavior	Temper tantrums, controlling behavior, compulsivity	Happy demeanor, frequent laughing, sleep difficulties	Anxiety, hyperactivity, sleep difficulties	Anxiety, hyperactivity, sleep difficulties
Physical Characteristics	Genital hypoplasia, almond-shaped palpebral fissures, down turned corners of mouth	Microcephaly, macrostomia with multiple diastemata, protruding tongue	Not known	Exotropia of his right eye, almond shaped palpebral fissures, gynecomastia
Other	Hypogonadism	Seizure	Not applicable	Irritable bowel syndrome

Note: References: (Carson et al., 2019; Dagi & Williams, 2017; Driscoll et al., 2017).

The assay was repeated on a new blood specimen to rule out any sample swap error, and the results were consistent with the original test. Constitutional genomic SNP microarray (GMA) analysis was performed on peripheral blood using the CytoScan HD™ platform and analyzed using chromosome analysis suit software (ChAS) (Applied Biosystems/Thermo Fisher Scientific, Santa Clara, CA). GMA results showed no clinically significant copy number variations, with two copies of the 15q11.2-q13 region and no evidence for UPD of chromosome 15. Note that complete heterodisomy would not be detected by GMA. Subsequently, methylation specific multiplex ligation-dependent amplification (MS-MLPA) (SALSA MLPA Probemix ME028, MRC-Holland, Netherlands) was performed (Figure 2). The MS-MLPA “undigested” copy number detection reaction showed copy number neutral results, (Figure 2a), while the MS-MLPA methylation status “digested” reaction showed approximately 10% mosaicism for an unmethylated product (maternal), (Figure 2b). Combining both results, MS-MLPA indicated that this patient has low-level mosaicism for paternal UPD 15/imprinting defect consistent with Angelman Syndrome with mosaicism.

4 | DISCUSSION

Angelman syndrome is an imprinting disorder caused by multiple genetic mechanisms and has a well described genotype–phenotype correlation. More severe phenotypes are associated with 15q11.2-q13 deletion and truncating variants in *UBE3A*, while individuals with uniparental disomy of chromosome 15 or an imprinting defect typically

have milder phenotypes (Bindels-de Heus et al., 2020; Lossie et al., 2001). Interestingly, hyperphagia has been seen across all genetic subtypes of AS (Bindels-de Heus et al., 2020).

The phenotypic presentation of mosaic AS, similar to our patient, has been described before. Gillessen-Kaesbach et al. (1999) discussed seven patients who presented with obesity, muscular hypotonia, and mild intellectual disability. These patients lacked ataxia and microcephaly. A few of these patients also used speech to communicate. They were initially suspected to have PWS, but DNA methylation analysis was consistent with AS. More specifically, while the more significantly affected patients had typical abnormal methylation patterns for AS, five less severely affected patients were noted to have a weak maternal band. The authors hypothesized that the phenotype may be explained by incomplete imprinting defect or cellular mosaicism.

Le Fevre et al. (2017) described three individuals with AS who had mosaic imprinting defects, who had hyperphagia, obesity, vocabulary up to 100 words, and ability to communicate in sentences. This atypical, milder phenotype for AS has been described for other individuals with mosaicism (Brockmann, 2002; Camprubí et al., 2007; Fairbrother et al., 2015; Le Fevre et al., 2017). A recent 2019 study of 22 individuals with mosaic AS again found similarities across the cases which included mild–moderate developmental delay, preserved expressive language, ability to manage activities of daily living, anxiety, and ADHD. Microcephaly, ataxia, and seizures were also less common than in non-mosaic individuals (Carson et al., 2019). Mosaicism in AS is believed to occur due to a postzygotic error leading to abnormal

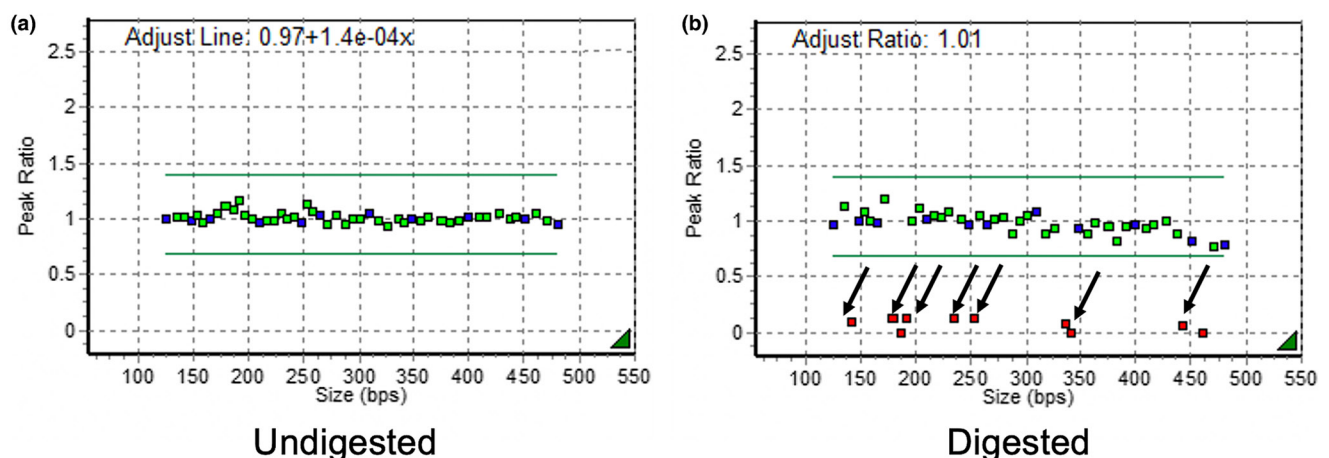


FIGURE 2 MS-MLPA detects paternal uniparental Disomy 15/imprinting defect low-level mosaicism. (a) Probe height ratio pattern after ligation reaction only. It showed two copies of PWS/AS alleles. (b) Probe height ratio pattern after both ligation and restriction digestion reactions. The black arrows indicate methylation specific probes. The results showed these loci were mostly unmethylated, but in mosaic status (did not reach “0”). bps: Base pair size.

methylation of the in the 15q11.2-q13 region in some cell lines (Buiting, 2010; Horsthemke & Buiting, 2006). The abnormal methylation pattern can vary across tissues, such as cerebral cortex, which could account for phenotypic variation of AS.

5 | CONCLUSION

Our patient fits the clinical characteristics of mosaic AS with his strong expressive language skills and mild-moderate intellectual disability, instead of the phenotype of classic AS. This is consistent with the additional MS-MLPA genetic analysis showing low-level mosaicism for AS. Our patient highlights the importance of considering a broader phenotypic spectrum for AS during a genetic evaluation. Typically, DNA methylation studies are ordered if there is a clinical suspicion for AS or PWS based on classically described phenotypic features of the syndromes. As a result, individuals with atypical phenotypes, similar to our patient, are likely often undiagnosed. Further, this case emphasizes the need for additional evaluation when confronted with atypical clinical features of a well described genetic syndrome. By pursuing further genetic evaluation using MS-MLPA technology for our patient, we were able to better correlate his phenotype with his genotype, allowing the family to have a more complete understanding of his condition.

ACKNOWLEDGMENTS

We acknowledge the thoughtful discussions, which occurred with the members of the Division of Genomic Medicine and Division of Developmental Behavioral Pediatrics at U.C. Davis as we investigated this case.

Maternal Child Health Bureau Grant HRSA T77MC25733 is supporting the Developmental Behavioral Pediatric Fellowship for Dr. Ruchi Punatar.

ETHICS STATEMENT

Study participant was recruited after obtaining appropriate IRB review and approval and consent for University of California Davis and ARUP Laboratory.

AUTHOR CONTRIBUTIONS

Ruchi Punatar, Alena S Egense, Kathleen Angkustsiri and Suma P Shankar contributed to the conception, acquisition of data, writing original draft and review. Rong Mao, Melinda Procter, Michelle Bosworth and Denise I Quigley contributed to the acquisition & analysis of laboratory data and review. All authors contributed to drafting the work, reviewed and approved the final submitted version and agree to be accountable for all aspects of the work.

CONFLICT OF INTEREST

Dr. Suma Shankar holds the Children's Miracle Network endowed chair of pediatric genetics and receives salary support from it. Rong Mao, Melinda Procter, Michelle Bosworth, and Denise I Quigley are employed by ARUP Laboratory.

DATA AVAILABILITY STATEMENT

Data sharing is not applicable to this article as no new data were created or analyzed in this study.

ORCID

Ruchi Punatar  <https://orcid.org/0000-0003-0247-3322>

Suma P. Shankar  <https://orcid.org/0000-0001-7100-5691>

REFERENCES

- Bindels-de Heus, K. G. C. B., Mous, S. E., Hooven-Radstaake, M., Iperen-Kolk, B. M., Navis, C., Rietman, A. B., Hoopen, L. W., Brooks, A. S., Elgersma, Y., Moll, H. A., & Wit, M. Y. (2020). An overview of health issues and development in a large clinical cohort of children with Angelman syndrome. *American Journal of Medical Genetics Part A*, 182(1), 53–63. <https://doi.org/10.1002/ajmg.a.61382>
- Brockmann, K. (2002). Exceptionally mild Angelman syndrome phenotype associated with an incomplete imprinting defect. *Journal of Medical Genetics*, 39. <http://www.jmedgenet.com/cgi/content/full/39/9/e51>
- Buiting, K. (2010). Prader-Willi syndrome and Angelman syndrome. *American Journal of Medical Genetics, Part C: Seminars in Medical Genetics*, 154(3), 365–376. <https://doi.org/10.1002/ajmg.c.30273>
- Buiting, K., Williams, C., & Horsthemke, B. (2016). Angelman syndrome—insights into a rare neurogenetic disorder. *Nature Reviews Neurology*, 12(10), 584–593. <https://doi.org/10.1038/nrneurol.2016.133>
- Camprubí, C., Coll, M. D., Villatoro, S., Gabau, E., Kamli, A., Martínez, M. J., Poyatos, D., & Guitart, M. (2007). Imprinting center analysis in Prader-Willi and Angelman syndrome patients with typical and atypical phenotypes. *European Journal of Medical Genetics*, 50(1), 11–20. <https://doi.org/10.1016/j.ejmg.2006.10.001>
- Carson, R. P., Bird, L., Childers, A. K., Wheeler, F., & Duis, J. (2019). Preserved expressive language as a phenotypic determinant of mosaic Angelman syndrome. *Molecular Genetics and Genomic Medicine*, 7(9), e837. <https://doi.org/10.1002/mgg3.837>
- Dagli, A. I., & Williams, C. A. (2017). NCBI Bookshelf—GeneReviews™. Angelman Syndrome. *Scielo*, 2, 2–5. <http://www.ncbi.nlm.nih.gov/books/NBK1144/>
- Driscoll, D. J., Miller, J. L., & Schwartz, S. (2017). NCBI Bookshelf—GeneReviews™. Prader-Willi Syndrome. *GeneReviews* [Intranet]. <https://www.ncbi.nlm.nih.gov/books/NBK1330/>
- Fairbrother, L. C., Cytrynbaum, C., Boutis, P., Buiting, K., Weksberg, R., & Williams, C. A. (2015). Mild Angelman syndrome phenotype due to a mosaic methylation imprinting defect. *American Journal of Medical Genetics, Part A*, 167(7), 1565–1569. <https://doi.org/10.1002/ajmg.a.37058>

- Gillessen-Kaesbach, G., Demuth, S., Thiele, H., Theile, U., Lich, C., & Horsthemke, B. (1999). A previously unrecognised phenotype characterised by obesity, muscular hypotonia, and ability to speak in patients with Angelman syndrome caused by an imprinting defect. *European Journal of Human Genetics*, 7(6), 638–644. <https://doi.org/10.1038/sj.ejhg.5200362>
- Horsthemke, B., & Buiting, K. (2006). Imprinting defects on human chromosome 15. *Cytogenetic and Genome Research*, 113(1–4), 292–299. <https://doi.org/10.1159/000090844>
- Le Fevre, A., Beygo, J., Silveira, C., Kamien, B., Clayton-Smith, J., Colley, A., Buiting, K., & Dudding-Byth, T. (2017). Atypical Angelman syndrome due to a mosaic imprinting defect: Case reports and review of the literature. *American Journal of Medical Genetics, Part A*, 173(3), 753–757. <https://doi.org/10.1002/ajmg.a.38072>
- Lossie, A. C., Whitney, M. M., Amidon, D., Dong, H. J., Chen, P., Theriaque, D., Hutson, A., Nicholls, R. D., Zori, R. T., Williams, C. A., & Driscoll, D. J. (2001). Distinct phenotypes distinguish the molecular classes of Angelman syndrome. *Journal of Medical Genetics*, 38(12), 834–845. <https://doi.org/10.1136/jmg.38.12.834>
- McCandless, S. E., Saal, H. M., Braddock, S. R., Enns, G., Gruen, J. R., Perrin, J. M., Saul, R. A., & Tarini, B. A. (2011). Clinical report—Health supervision for children with Prader-Willi syndrome. *Pediatrics*, 127(1), 195–204. <https://doi.org/10.1542/peds.2010-2820>
- Smeets, D. F. C. M., Hamel, B. C. J., Nelen, M. R., Smeets, H. J. M., Bollen, J. H. M., Smits, A. P. T., Ropers, H.-H., & van Oost, B. A. (1992). Prader-Willi syndrome and Angelman syndrome in cousins from a family with a translocation between chromosomes 6 and 15. *New England Journal of Medicine*, 326(12), 807–811. <https://doi.org/10.1056/nejm199203193261206>

How to cite this article: Punatar, R., Egense, A., Mao, R., Procter, M., Bosworth, M., Quigley, D. I., Angkustsiri, K., & Shankar, S. P. (2022). Atypical presentation of Angelman syndrome with intact expressive language due to low-level mosaicism. *Molecular Genetics & Genomic Medicine*, 10, e2018. <https://doi.org/10.1002/mgg3.2018>