

# UC Davis

## Dermatology Online Journal

### Title

Not French manicure but onycholysis

### Permalink

<https://escholarship.org/uc/item/50g1d2s5>

### Journal

Dermatology Online Journal, 20(9)

### Authors

Chiriac, Anca  
Stanciu, Roxana  
Brzezinski, Piotr  
et al.

### Publication Date

2014

### DOI

10.5070/D3209023924

### Copyright Information

Copyright 2014 by the author(s). This work is made available under the terms of a Creative Commons Attribution-NonCommercial-NoDerivatives License, available at <https://creativecommons.org/licenses/by-nc-nd/4.0/>

**Letter**

**Not French manicure but onycholysis**

**Anca Chiriac<sup>1</sup>, Roxana Stanciu<sup>2</sup>, Piotr Brzezinski<sup>3</sup>, Steven R. Feldman<sup>4</sup>**

**Dermatology Online Journal 20 (9): 17**

**<sup>1</sup>Head of Department of Dermatology, Nicolina Medical Center, Iasi, Romania**

**<sup>2</sup>Department of Endocrinology, Nicolina Medical Center, Iasi, Romania**

**<sup>3</sup>Head of Department of Dermatology, 6th Military Support Unit, os. Ledowo 1N, 76-270 Ustka, Poland**

**<sup>4</sup>Center for Dermatology Research, Departments of Dermatology, Pathology and Public Health Sciences; Wake Forest School of Medicine; Winston-Salem, North Carolina**

**Corresponding author:**

Piotr Brzezinski, MD PhD  
Department of Dermatology,  
6th Military Support Unit,  
os. Ledowo 1N,  
76-270 Ustka,  
Poland  
Tel. 692121516  
e-mail: brzezoo@wp.pl

**Abstract**

French manicure, a simple and elegant manicure style, caught the public's attention by the 19<sup>th</sup> century in French nail salons. Now this style has spread all over the world and is the first choice of 80% of women in the USA and Europe. It consists of a natural, pink, beige, or nude base tipped with pure white at the distal end.

Onycholysis is a disease of the nails characterized by separation of the nail plate from the nail bed, with variable causes. We present 2 cases of onycholysis that resemble the beautiful and elegant French manicure.

**Key words: onycholysis; manicure; nails**

**Introduction**

French manicure is a simple and elegant manicure style that is now the first choice of 80% of women in the USA and Europe. It combines a natural, pink, beige, or nude base with a distal tip of pure white (Figure 1).

Onycholysis is a disease of the nails characterized by separation of the nail plate from the nail bed, with variable causes. We present 2 cases of onycholysis that resemble the beautiful and elegant French manicure.

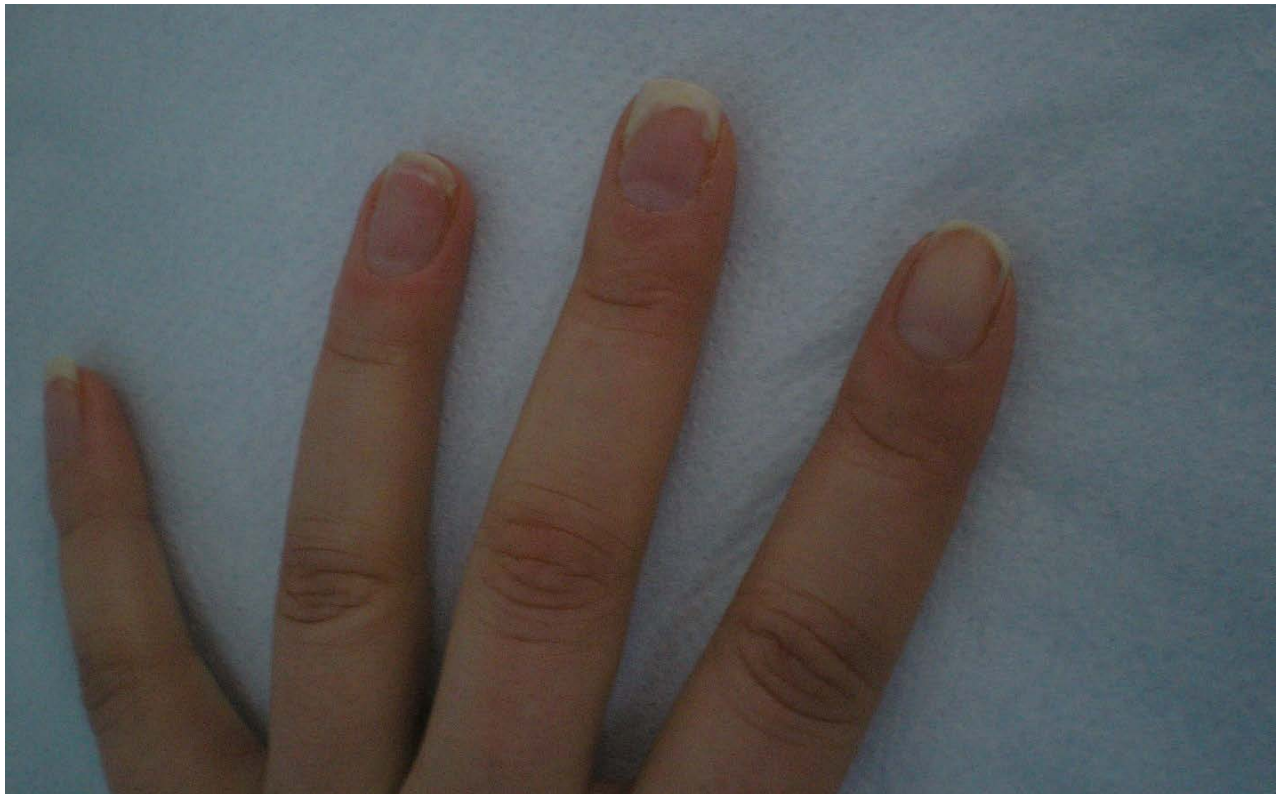


**Figure 1.** French manicure

## **Case Synopsis**

### *Case 1*

Allergic contact dermatitis induced by acrylates in a professional manicurist (Figure 2)



**Figure 2.** Allergic contact dermatitis induced by acrylates in a professional manicurist

A previously healthy young woman, a professional nail beautician specializing in artificial and painted nails, consulted the dermatology department for abnormalities of her fingernails, observed 3 weeks prior to consultation.

On clinical examination, white discoloration of the distal margins of the left fingernails were noticed, most prominent at the 3rd digit; no periungual or subungual erythema or hyperkeratosis were observed. No skin lesions on the body or other complain were noted.

She was a left handed women, working in a salon. She handled artificial nails, including sculptured nails, photobonded nails, and preformed nails, which usually contain glue with acrylates. No history of atopic dermatitis and no allergic reactions had been reported in her past medical history. A clinical diagnosis of allergic contact dermatitis with onycholysis induced by acrylates was suspected.

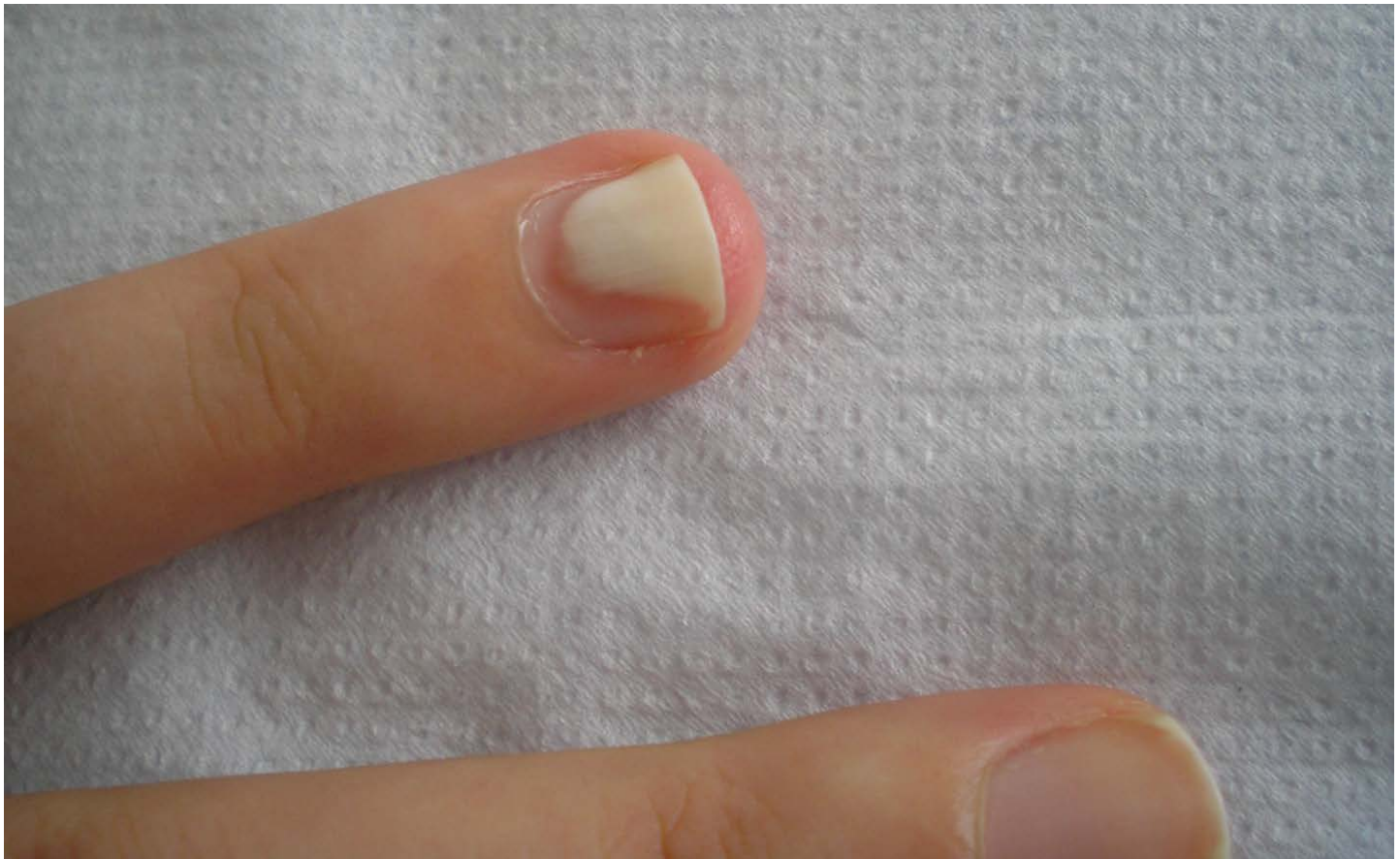Routine lab investigations were within normal limits, IgE also turned to be normal. Direct mycological exam, culture for fungus and bacteria proved to be negative.

A positive result on patch testing performed with nail glue from work confirmed the diagnosis.

Avoidance of contact with the allergen is essential to clearing. This can be aided by wearing gloves, careful local hygiene,

*Case 2*

A 22 year old woman came to the dermatology department worried about the peculiar aspect of her 3rd fingernail of the right hand. She noticed the alteration of the nail 5 weeks prior to the medical consult (Figure 3).

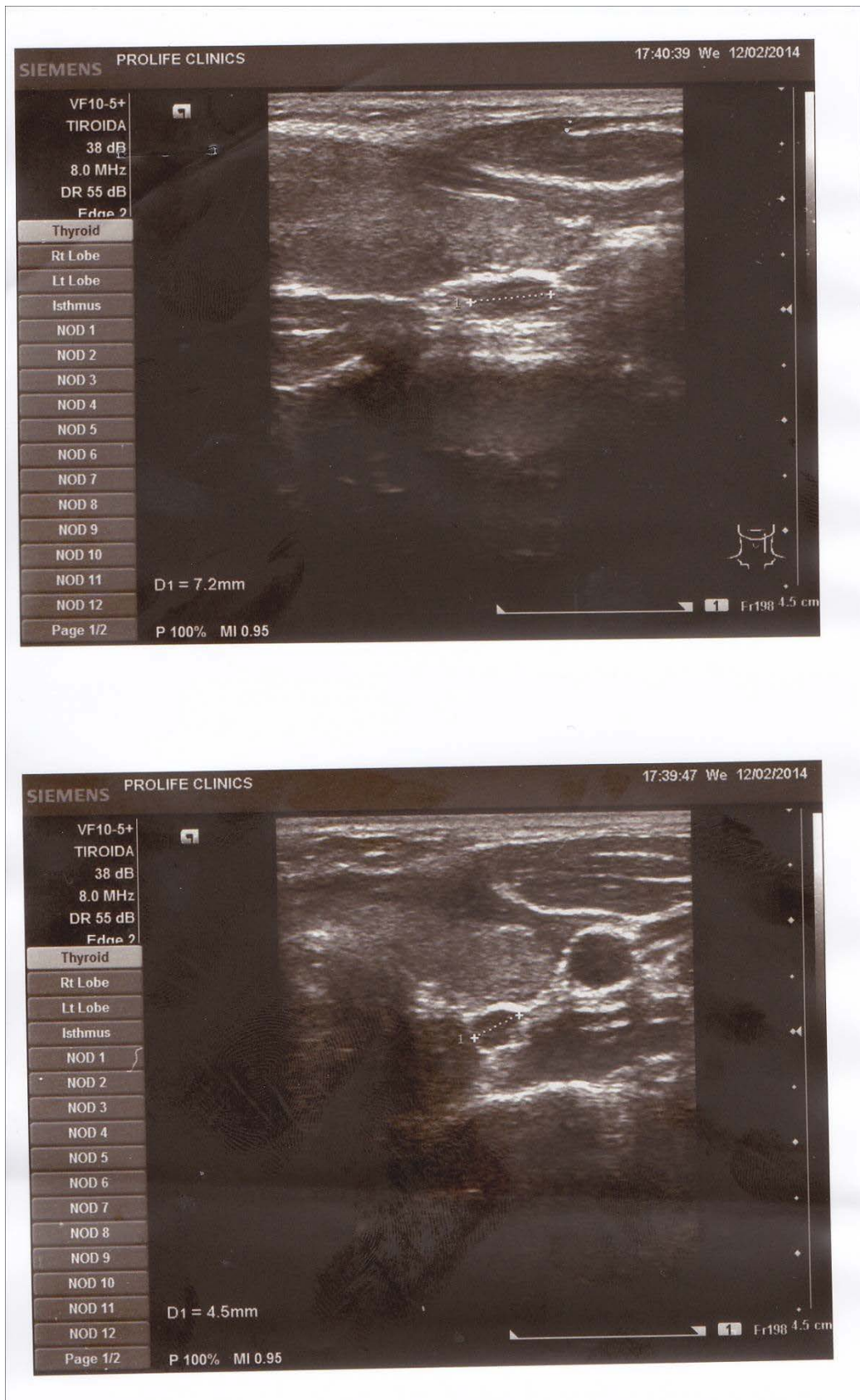

**Figure 2.** Clinical aspect of the nail

On clinical examination, very well demarcated white discoloration (chalky like) at the distal end of the nail was noted. On palpation, the nail seemed to be firm and rigid. No symptoms were related by the patient and general examination failed to identify any other problems. The patient was a healthy young student who did not have a manicure history. She had no allergic background and no personal or familial history of psoriasis or other skin diseases. She denied drug intake or repeated local trauma.



An endocrinology consultation was requested. Thyroid status proved to be normal but high levels of parathyroid hormone were detected. Ultrasonography evidenced a parathyroid adenoma (Figure 4), but a normal thyroid gland.



**Figure 4.** Ultrasound-parathyroid adenoma (arrow); normal aspect of thyroid gland

## Discussion

Onycholysis is characterized by the separation of the nail plate from the nail bed; it begins at the distal part of the nail with disruption of a portion of nail plate. The onycholytic portion of the nail appears white owing to the air accumulated beneath the

nail plate that causes light refraction [1]. The space created beneath the nail plate can be secondarily infected with *Candida albicans*, *Pseudomonas*, and *Staphylococcus* spp, aggravating the onycholytic process.

Different causes and associations have been reported as triggering factors inducing onycholysis: these include psoriasis, onychomycosis, yellow nail syndrome, contact dermatitis, medications (doxycycline), endocrine disorders, or local repeated trauma [1]. Sparse reports about the association of onycholysis and vitiligo [2] or heart transplantation [3] are published.

We present two cases of onycholysis: one induced by allergic contact dermatitis to acrylates and one with a possible association with a parathyroid adenoma.

## References

1. Phoebe R. An Atlas of diseases of the nail. 2005 p.49
2. Anbar T, Hay RA, Abdel-Rahman AT, Mofteh NH, Al-Khayyat MA. Clinical study of nail changes in vitiligo. *J Cosmet Dermatol*. 2013 Mar;12(1):67-72.
3. Nabai H. Nail changes before and after heart transplantation: personal observation by a physician. *Cutis*. 1998 Jan;61(1):31-2.