

UC Davis

Dermatology Online Journal

Title

Linear atrophy and vascular fragility following ultrasoundguided triamcinolone injection for DeQuervain tendonitis

Permalink

<https://escholarship.org/uc/item/4zj1n2rq>

Journal

Dermatology Online Journal, 23(1)

Authors

Willardson, Hal B
Buck, Shannon
Neiner, James

Publication Date

2017

DOI

10.5070/D3231033683

Copyright Information

Copyright 2017 by the author(s). This work is made available under the terms of a Creative Commons Attribution-NonCommercial-NoDerivatives License, available at <https://creativecommons.org/licenses/by-nc-nd/4.0/>

Peer reviewed

Linear atrophy and vascular fragility following ultrasound-guided triamcinolone injection for DeQuervain tendonitis

Hal B Willardson MD, Shannon Buck MD, James Neiner MD

Affiliations: San Antonio Uniformed Services Health Education Consortium, San Antonio, TX

Corresponding Author: Hal B Willardson MD, Transitional Intern, San Antonio Uniformed Services Health Education Consortium, San Antonio, TX, Tel. (907)360-2103, Email: hal.willardson.1@us.af.mil

Abstract

A 64 year-old woman presented with a one-year history of purpuric, atrophic, linear patches along the left lateral forearm. The patient had received two ultrasound-guided triamcinolone injections one year earlier into her left extensor pollicis brevis and abductor pollicis longus tendon sheaths for DeQuervain tendonitis. In the seven months following the second injection, the patient developed atrophy, purpura, and telangiectasias starting at the site of injection and extending proximally, following the course of her left cephalic vein. The patient was treated initially with amlactin and moisturizing cream containing alpha-hydroxy acid cream to aid in dermal repair. Despite treatment, she continued to have proximal progression of the atrophy and purpura. A 4mm punch biopsy revealed a normal-appearing epidermis overlying horizontal dermal fibrosis, along with atrophic-appearing adipocytes with accentuated capillaries in the subcutaneous fat, consistent with a diagnosis of corticosteroid atrophy. These gross and microscopic changes presumably resulted from lymphatic uptake and spread of the corticosteroid following the injections for tendonitis. Although local atrophy and vascular fragility are well-documented side effects of corticosteroid injections, linear spread of these symptoms is rarely reported, and to this point has not been demonstrated in the literature following ultrasound-guided steroid injection for DeQuervain tendonitis.

Keywords: steroid, atrophy, linear, triamcinolone injections, tendonitis, ultrasound

Introduction

Triamcinolone injections have been used for decades in the fields of rheumatology, orthopedics, and

dermatology to treat a variety of cutaneous and musculoskeletal maladies. Although cutaneous side effects, such as localized hypopigmentation and atrophy, following triamcinolone injections are well-documented, linear atrophy in a lymphovascular distribution is rare. In this report, we present a rare case of linear atrophy and vascular fragility following ultrasound-guided triamcinolone injection for DeQuervain tendonitis.

Case Synopsis

A 64-year-old woman, with no prior history of connective tissue disease or atopy presented with a one-year history of fixed patches of purpura, erythematous telangiectasia, and lipoatrophy extending 10cm in a linear fashion along the left lateral forearm (**Figure 1**). The patient had received two ultrasound-guided triamcinolone injections one year earlier into her left extensor pollicis brevis and abductor pollicis longus tendon sheaths for a diagnosis of DeQuervain tendonitis. The first injection contained 1ml of triamcinolone acetonide 40mg/ml,

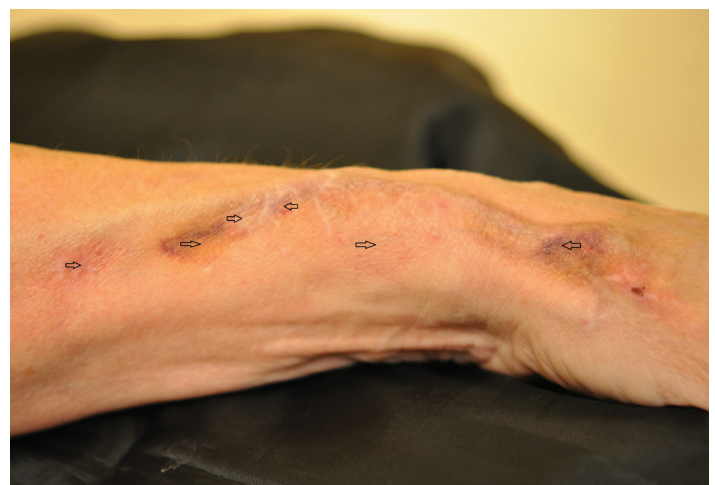

Figure 1. Linearly-arranged atrophic patches with associated telangiectasias, purpura, and ecchymosis, along the course of the left cephalic vein; right-pointing arrows denote areas of atrophy; left-pointing arrows denote telangiectasias and purpura.

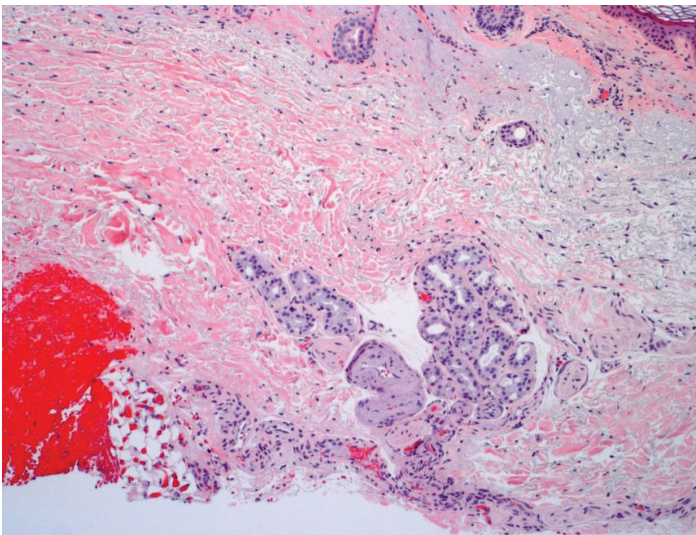


Figure 2. Horizontal dermal fibrosis, solar elastosis, and atrophic appearing adipocytes with accentuated capillaries in a small portion of subcutaneous fat, consistent with steroid atrophy in the setting of sun-damaged skin. H&E, 40x.

for a total dose of 40mg. Owing to inadequate relief of her tendonitis, the patient received a subsequent 0.5ml injection of triamcinolone acetonide 40mg/ml, for a total dose of 20mg. The patient's tendonitis resolved within several weeks following the second injection.

In the six months following the second injection, the patient developed atrophy, purpura, and erythematous telangiectasias starting at the site of injection and extending proximally, following the course of her left cephalic vein. The patient was treated initially with amlactin and over-the-counter moisturizing cream with alpha-hydroxy acid to promote and accelerate dermal repair. However, she continued to have proximal progression of the linear atrophy, purpura, and telangiectasias.

A 4mm punch biopsy of the linear, atrophic lesion revealed a normal-appearing epidermis overlying prominent dermal solar elastosis, horizontal dermal fibrosis, and atrophic appearing adipocytes with accentuated capillaries in the subcutaneous fat, consistent with a diagnosis of steroid atrophy and chronic sun-damage (**Figure 2**). Features of morphea were not identified in the biopsy specimen. The patient started pulsed-dye laser therapy (595nm) and experienced a noticeable decrease in the number and prominence of her purpuric patches and erythematous telangiectasias in the area of linear atrophy.

Case Discussion

Although corticosteroid injections for cutaneous lesions are considered very safe, with very little risk of systemic complications, there are many reports of local hypopigmentation and atrophy occurring at the site of injection [1, 2, 3]. Very rarely corticosteroid injections can result in a linear distribution of steroid-induced atrophy and hypopigmentation through uptake of steroid by the superficial lymphatic vessels, and subsequent leakage of the steroid during proximal transport [4]. These side effects will typically resolve with time [5, 6], though there have been cases reported in which symptoms will persist up to a year or longer [2,7].

Corticosteroids lead to cutaneous and subcutaneous atrophy by decreasing the mitotic rate of fibroblasts and keratinocytes, leading to decreased production of vital extracellular matrix and epidermal proteins, such as keratin and collagen [3]. Corticosteroids also decrease production of extracellular lipids such as ceramides, cholesterol, and fatty acids, contributing to atrophy of the dermis and subcutaneous fat [3]. These effects lead to prominent and fragile blood vessels within the subcutaneous fat, as was demonstrated in our patient's skin biopsy.

Cutaneous complications related to corticosteroid injections are seen less commonly when performed for musculoskeletal injuries, such as arthritis and tendonitis, as the corticosteroid is typically injected directly into a joint space or tendon sheath (both of which have poor vascularity); this is often done under ultrasound guidance. Review of the literature reveals only a few cases of atrophy and hypopigmentation following corticosteroid injections for DeQuervain tendonitis (DQT), a tendonitis involving the abductor pollicis longus and extensor pollicis brevis tendon sheaths of the wrist [8-10]. Only two cases of linear spread of atrophy and hypopigmentation have been documented, neither of which involved ultrasound guidance of the injection [8, 10]. A thorough search of the literature regarding cutaneous complications following ultrasound-guided corticosteroid injections for DQT revealed only 4 patients who reported self-resolving local hypopigmentation, without linear spread or atrophy [11, 12]. Therefore, not only is our case just the third documented case of linear atrophy following corticosteroid injections

for DQT, it is the first such documented case in which ultrasound guidance was utilized to perform the injections.

Although our patient's corticosteroid injections were done under ultrasound guidance, with good visualization of drug injection into the tendon sheaths, extravasation of the triamcinolone likely occurred into the surrounding tissue. The corticosteroid was likely then absorbed into the patient's superficial lymphatic system coursing alongside the cephalic vein, leading to atrophy, telangiectasia, and purpura from the resultant vascular fragility. We hypothesize that the degree of our patient's symptoms was a product of the concentration of triamcinolone used, as 40mg/ml or greater of triamcinolone acetonide (which was the dose used in our patient) has been shown to result in higher rates of cutaneous complications as compared to lower doses [1].

Although hypopigmentation, cutaneous atrophy, telangiectasias, and vascular fragility are a known complication of corticosteroid injections, linear spread of these complications is rare and has not been described in the literature following ultrasound-guided injection for DeQuervain tendonitis until now. Our case highlights the importance of continuing to inform patients of the potential complications of corticosteroid injections. Care must be taken to ensure that patients understand that these complications can occur even when ultrasound guidance is being used to ensure proper delivery of the medication. And while the majority of patients who experience vascular fragility, hypopigmentation, and atrophy following corticosteroid injections will experience resolution of these complications over time, our case and this article serves to remind physicians and patients alike that corticosteroid injections can have long-lasting, even permanent, side effects.

References

1. Firooz A, Tehranchi-Nia Z, Ahmed AR. Benefits and risks of intralesional corticosteroid injection in the treatment of dermatological diseases. *Clin Exp Dermatol.* 1995;20:363-70. [PMID:8593711]
2. Okere K, Jones MC. A case of skin hypopigmentation secondary to a corticosteroid injection. *South Med J.* 2006; 99:1393-1394. [PMID:17233199]
3. Schoepe S, Schäcke H, May E, Asadullah K. Glucocorticoid therapy-induced skin atrophy. *Exp Dermatol.* 2006;15:406-420. [PMID:16689857]

4. Kikuchi I, Horikawa S. Letter: Perilymphatic atrophy of the skin. *Arch Dermatol.* 1975;111:795-6. [PMID:1137430]
5. Kaur S, Thami GP. Intralesional corticosteroid induced perilesional and perilymphatic hypopigmentation. *Indian J Dermatol Venereol Leprol.* 2002;68:356-357. [PMID:17657002]
6. P. Kumar, S. Adolph. Hypopigmentation along subcutaneous veins following triamcinolone injection: a case report and review of the literature. *Burns.* 1998 Aug;24(5):487-488. [PMID:9725695]
7. Woo Sun Jang, M.D, et al. Branch-shaped Cutaneous Hypopigmentation and Atrophy after Intralesional Triamcinolone Injection. *Ann Dermatol Vol. 23, No. 1, 2011.* [PMID:21738379]
8. Venkatesan P, Fangman WL. Linear hypopigmentation and cutaneous atrophy following intra-articular steroid injections for de Quervain's tendonitis. *J Drugs Dermatol.* 2009 May;8(5):492-3. [PMID:19537375]
9. Evans AV, McGibbon DH. Symmetrical hypopigmentation following triamcinolone injection for de Quervain's tenosynovitis. *Clin Exp Dermatol.* 2002 May;27(3):247-51. [PMID:12072019]
10. Cantürk F, Cantürk T, Aydın F, Karagöz F, Sentürk N, Turanlı AY. Cutaneous linear atrophy following intralesional corticosteroid injection in the treatment of tendonitis. *Cutis.* 2004 Mar;73(3):197-8. [PMID:15074349]
11. Hajder E, de Jonge MC, van der Horst CM, Obdeijn MC. The role of ultrasound-guided triamcinolone injection in the treatment of de Quervain's disease: treatment and a diagnostic tool? *Chir Main.* 2013 Dec;32(6):403-7. [PMID:24139754]
12. McDermott JD, Ilyas AM, Nazarian LN, Leinberry CF. Ultrasound-guided injections for de Quervain's tenosynovitis. *Clin Orthop Relat Res.* 2012 Jul;470(7):1925-31. [PMID:22552767]