

# UC Irvine

## UC Irvine Previously Published Works

### Title

Hemophagocytic Lymphohistiocytosis in the Emergency Department: Recognizing and Evaluating a Hidden Threat

### Permalink

<https://escholarship.org/uc/item/4z61s48z>

### Journal

Journal of Emergency Medicine, 60(6)

### ISSN

0736-4679

### Authors

Morrisette, Katelin  
Bridwell, Rachel  
Lentz, Skyler  
[et al.](#)

### Publication Date

2021-06-01

### DOI

10.1016/j.jemermed.2021.02.006

Peer reviewed



Since January 2020 Elsevier has created a COVID-19 resource centre with free information in English and Mandarin on the novel coronavirus COVID-19. The COVID-19 resource centre is hosted on Elsevier Connect, the company's public news and information website.

Elsevier hereby grants permission to make all its COVID-19-related research that is available on the COVID-19 resource centre - including this research content - immediately available in PubMed Central and other publicly funded repositories, such as the WHO COVID database with rights for unrestricted research re-use and analyses in any form or by any means with acknowledgement of the original source. These permissions are granted for free by Elsevier for as long as the COVID-19 resource centre remains active.



<https://doi.org/10.1016/j.jemermed.2021.02.006>

## Clinical Review

### HEMOPHAGOCYtic LYMPHOHISTIOCYTOSIS IN THE EMERGENCY DEPARTMENT: RECOGNIZING AND EVALUATING A HIDDEN THREAT

Katelin Morrissette, MD,\* Rachel Bridwell, MD,† Skyler Lentz, MD,‡ Elizabeth Brem, MD,§  
 Karla Olmedo Gutierrez, MD,§ Manpreet Singh, MD,|| Alex Koyfman, MD,¶ and Brit Long, MD\*

\*Division of Pulmonary and Critical Care Medicine, Department of Medicine, University of Vermont Medical Center, Burlington, Vermont, †Department of Emergency Medicine, Brooke Army Military Medical Center, Fort Sam Houston, Texas, ‡Division of Emergency Medicine and Division of Pulmonary and Critical Care Medicine, Department of Medicine and Surgery, University of Vermont Medical Center, Burlington, Vermont, §Division of Hematology/Oncology, Department of Medicine, University of California Irvine, Irvine, California, ||Department of Emergency Medicine, Harbor–University of California Los Angeles Medical Center, Torrance, California, and ¶Department of Emergency Medicine, University of Texas Southwestern, Dallas, Texas

Corresponding Address: Brit Long, MD, Brooke Army Medical Center, 3841 Roger Brooke Dr, Fort Sam Houston, TX 78234

**Abstract—Background:** Hemophagocytic lymphohistiocytosis (HLH) is a life-threatening hematologic disorder resulting from an ineffective and pathologic activation of the immune response system that may mimic common emergency department presentations, including sepsis, acute liver failure, disseminated intravascular coagulation, and flu-like illnesses such as coronavirus disease 2019 (COVID-19). **Objective:** This narrative review provides a summary of the disease and recommendations for the recognition and diagnostic evaluation of HLH with a focus on the emergency clinician. **Discussion:** Though the condition is rare, mortality rates are high, ranging from 20% to 80% and increasing with delays in treatment. Importantly, HLH has been recognized as a severe variation of the cytokine storm associated with COVID-19. Common features include a history of infection or malignancy, fever, splenomegaly or hepatomegaly, hyperferritinemia, cytopenias, coagulopathies, abnormal liver enzymes, and hypertriglyceridemia. Using specific features of the history, physical examination, laboratory studies, and tools such as the HScore, HLH-2004/2009, and hyperferritinemia thresholds, the emergency clinician can risk-stratify patients and admit for definitive testing. Once diagnosed, disease specific treatment can be initiated. **Conclusion:** This review describes the relevant pathophysiology, common presentation findings, and a framework for

risk stratification in the emergency department. Published by Elsevier Inc.

**Keywords—COVID-19; cytopenia; hemophagocytic lymphohistiocytosis; hepatosplenomegaly; HLH; hyperferritinemia; immunology**

#### CLINICAL SCENARIO

A 45-year-old man with a history of testicular cancer presents with fever, shortness of breath, and myalgias. He is febrile to 39°C and tachycardic to 118 beats/min. On abdominal examination, the patient is noted to have generalized tenderness and splenomegaly. Chest radiography reveals a right-sided consolidation, and laboratory assessment reveals anemia, thrombocytopenia, hypoalbuminemia, elevated aminotransferase levels, elevated bilirubin, and elevated D-dimer. Subsequent testing demonstrates prolonged partial thromboplastin time and international normalized ratio.

#### INTRODUCTION

Hemophagocytic lymphohistiocytosis (HLH) is an uncommon but deadly disease that requires a high degree

Reprints are not available from the authors.

RECEIVED: 23 September 2020; FINAL SUBMISSION RECEIVED: 4 January 2021;  
 ACCEPTED: 6 February 2021

of suspicion. Unfortunately, as the clinical scenario suggests, it can present with nonspecific signs and symptoms, delaying diagnosis and definitive management. Common features of HLH include fever, splenomegaly, hyperferritinemia, cytopenias, coagulopathies, abnormal liver enzymes, and hypertriglyceridemia. The presentation may mimic common emergency department (ED) presentations, including sepsis, acute liver failure, disseminated intravascular coagulation, and flu-like illnesses such as coronavirus disease 2019 (COVID-19). Diagnostic evaluation tools have been established to risk-stratify patients, and the majority of necessary screening can be initiated in the ED if the clinician recognizes HLH as part of the differential diagnosis (1). While much of the initial management is standard resuscitation for underlying precipitating factors, disease-targeted therapies can be considered early if discussion with a hematologist is initiated (2). By increasing awareness, understanding the pathology, and developing a thoughtful approach to screening and early management, emergency clinicians can play an important role in HLH diagnosis and treatment.

The underlying pathology of HLH is a malignant overresponse of the inflammatory system resulting in hyperactive macrophages, lymphocytes, cytokine activity, hemophagocytosis, and life-threatening multiorgan failure (3,4). Despite these complexities, the syndrome of HLH can be investigated without specialized testing or tools, and evaluation algorithms have been developed to guide use of definitive testing. These pathways for recognition can be initiated in the ED to aid in the admission to an appropriate medical service, expedite definitive testing, consultation with hematology, and prompt consideration of aggressive management, such as corticosteroids and chemotherapeutic agents.

## METHODS

This is a narrative review of adult HLH in the context of the initial ED evaluation in undiagnosed adult patients. We conducted a literature review of PubMed and Google Scholar using keywords of “hemophagocytic lymphohistiocytosis,” “HLH,” “macrophage activation syndrome,” and “cytokine release syndrome,” from 2002 to May 2020. In a [PubMed.gov](https://pubmed.ncbi.nlm.nih.gov/) search for article containing the specific phrases “adult” and “hemophagocytic lymphohistiocytosis,” there were approximately 6 results in the years 2000 to 2001 and 183 results in 2018 to 2019, representing an increase in awareness and reporting of this disease. We evaluated retrospective and prospective studies, systematic reviews and meta-analyses, other narrative reviews, and case reports and series. Authors also reviewed guidelines and supporting citations of included articles. Given the limited availability of ran-

domized controlled trials and prospective studies, we used retrospective studies, case reports, and other narrative reviews in addition to expert consensus guidelines. We decided on the inclusion of studies through consensus and included a total of 49 resources: 6 systematic reviews, 3 registry survey studies, 16 retrospective studies and case reports, 9 expert commentaries or editorial, 6 narrative reviews, 1 validation of a scoring tool, 3 expert consensus guidelines, and 5 commentaries on the possible connection to the evolving understanding of COVID-19.

## DISCUSSION

### *Epidemiology*

The exact incidence of HLH remains unknown, particularly in the adult population in whom literature, until recently, has been sparse. Acquired forms of the condition overlap with symptoms of many underlying comorbidities, contributing to ambiguity in true incidence figures. The published literature suggests an incidence of approximately 1.2 to 1.5 per million, largely composed of pediatric cases (5–7). Adult disease incidence is challenging to establish because of overlap with other hematologic abnormalities. For example, macrophage activation syndrome is a subtype of HLH caused by an autoimmune/rheumatologic process, though discussion continues as to whether these may actually be distinct entities (8). In addition, HLH may represent a spectrum of disease processes, making the diagnosis challenging (9).

HLH is an underrecognized disease entity, but a rapidly developing body of adult and pediatric literature is emerging. In 1 registry study, 21.8% of HLH diagnoses were made >21 days after the initial patient presentation, potentially worsening patient prognosis (10). In addition, recent evidence suggests coronaviruses, such as Middle East respiratory syndrome may lead to HLH or similar syndromes (11). Given the recent outbreak of COVID-19, an improved understanding of these entities is salient to current practice (12).

### *Pathophysiology*

HLH is a hematologic disorder resulting from overactivation of the immune response system; this hyperactive state is ineffective and pathologic, resulting in systemic harm (3). In normal physiology, natural killer (NK) cells are key initiators of a cytotoxic immune response. In HLH, this NK cell activity is impaired, and the ineffective NK cell response overactivates macrophages and cytotoxic T cells, specifically CD8<sup>+</sup> T cells. These T cells and macrophages then begin to phagocytize other cell

lines (2). In addition, the T cells and NK cells release cytokines, causing a severe inflammatory reaction that can present with a wide spectrum of clinical features (Figure 1).

HLH can broadly be categorized as primary (pHLH; inherited or genetic) or secondary (sHLH). pHLH is most commonly identified in infancy caused by an underlying genetic factor, while sHLH most often occurs as a result of a significant physiologic stressor (4). Several genes have been identified in association with pHLH; these mutations affect genes involved in cytotoxic activity (2). All prospective studies to date in HLH have been completed in pediatric pHLH populations (3). pHLH is nearly universally fatal without treatment, which includes etoposide and dexamethasone (2). Etoposide is a chemotherapy agent that inhibits topoisomerase II and is frequently used in the treatment of lung cancer. The use of etoposide and dexamethasone was described in the HLH-94 with the addition of cyclosporine to the HLH-2004 therapeutic guidelines (13–15). These medical therapies may be followed by allogeneic bone marrow transplantation depending on risk of recurrence or response to therapy (2). The interleukin-1 antagonist anakinra has also been investigated in adult patients with sHLH (16).

In contrast, sHLH is most commonly associated with malignancy (typically hematologic malignancies), infection, or autoimmune disorders (10). Systemic lupus erythematosus, adult-onset Still disease, and juvenile rheumatoid arthritis are commonly associated with HLH, while rheumatoid arthritis and ankylosing spondylitis are less frequently associated with the disease. The most commonly associated malignancy associated with sHLH is lymphoma (both B- and T-cell lymphomas), while several infectious associations have also been identified, including viruses (Epstein–Barr virus, adenovirus, parvovirus B19, HIV, and hepatitis B and C), bacteria (*Ehrlichia* spp., *Bartonella* spp., and mycobacteria), fungal infections (histoplasma), and parasites (toxoplasma) (17–19). Severe immunodeficiency states are also associated with development of HLH, including HIV, transplant patients, and those taking immunosuppressive medications (17–19). In sHLH, management of the underlying condition is the mainstay of therapy, with the addition of corticosteroid therapy (3). When sHLH is refractory to correction of the underlying condition, pediatric regimens for pHLH are often used (3). The mortality from sHLH is difficult to estimate, but mortality in the first month can be as high as 44%, and overall mortality may be 50% to 75% (2).

plasma) (17–19). Severe immunodeficiency states are also associated with development of HLH, including HIV, transplant patients, and those taking immunosuppressive medications (17–19). In sHLH, management of the underlying condition is the mainstay of therapy, with the addition of corticosteroid therapy (3). When sHLH is refractory to correction of the underlying condition, pediatric regimens for pHLH are often used (3). The mortality from sHLH is difficult to estimate, but mortality in the first month can be as high as 44%, and overall mortality may be 50% to 75% (2).

### Initial Evaluation

The primary challenge for the emergency physician is considering this specific disease entity, as its presentation can be nonspecific. Other conditions that appear similar to HLH or that present concurrently with HLH include sepsis, severe liver disease, toxic ingestion, catastrophic antiphospholipid syndrome, and drug rash with eosinophilia and systemic symptoms. Figure 2 is a proposed schema for approaching this evaluation based on the best available evidence for clinical presentation of adults diagnosed with HLH and risk stratification based on laboratory findings. This is not a validated algorithm but a rather a proposed guide for the ED setting based on the following evidence for diagnostic criteria and clinical presentations.

The first important step is resuscitation, followed by a targeted medical history if possible. Infection and malignancy are commonly present in sHLH. A registry study found that approximately 35% of patients with HLH had a known malignancy, and 44.5% were found to have an infection (10). Of these infection-associated cases, viral causes were the single largest group (28.5%) (10). These patients were noted to be at high risk of developing HLH, specifically in those with HIV (10). Epstein–Barr virus was identified in 15.3% of

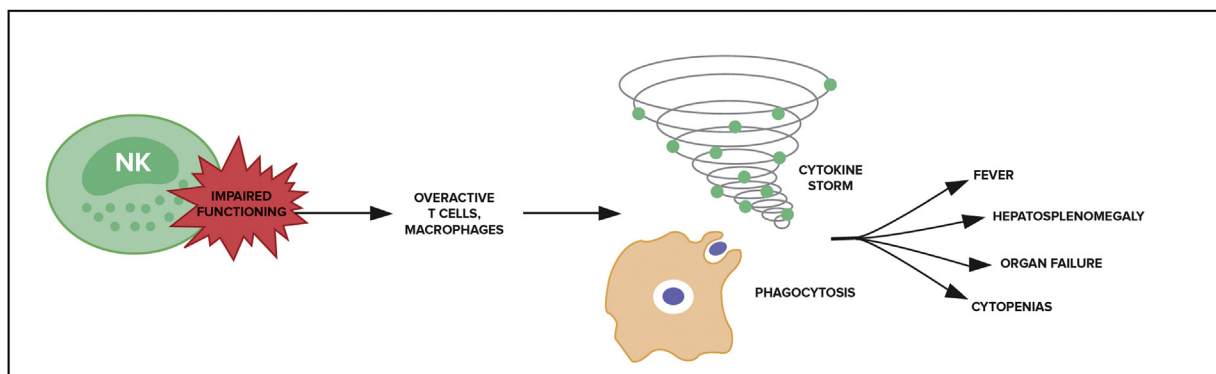


Figure 1. Suspected mechanism of hemophagocytic lymphohistiocytosis pathophysiology. NK = natural killer.

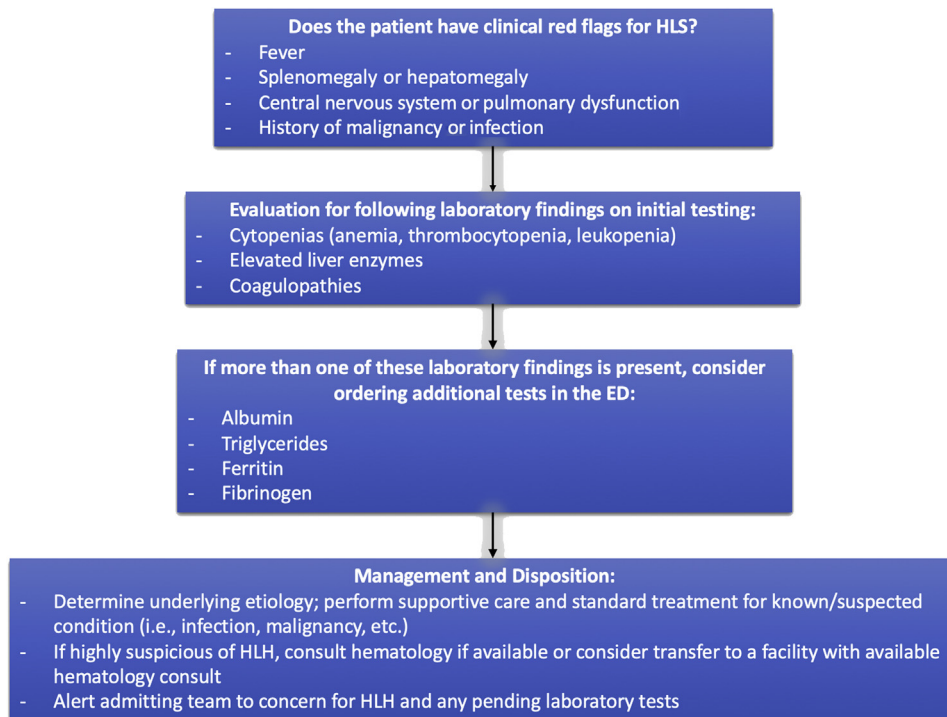
patients and was the most commonly isolated virus in infection related cases (10).

The physical examination should also include specific attention to high-risk features that could distinguish sHLH from alternative diagnoses. While these patients can present with nonspecific signs and symptoms, notable high-risk features include fever, splenomegaly, hepatomegaly, central nervous dysfunction (e.g., altered mental status, ataxia, dysarthria, seizures), and pulmonary symptoms, such as hypoxemia (20). Much of the information regarding physical examination characteristics come from a registry study of 137 patients with HLH and retrospective case reviews (10,21). Fever  $>38.5^{\circ}\text{C}$  was reported in 90% to 98% of patients with HLH and is often refractory to antibiotics (10,21,22). Despite the near ubiquity of fever in HLH, the prevalence of fever in many inflammatory states limits the utility of fever as a discriminatory element. Splenomegaly occurs in approximately 86% of patients with HLH, and hepatomegaly is identified in approximately 61% (10,23). Coagulopathies are common in patients with HLH, with disseminated intravascular coagulation reported in 32% (10). Neurologic complications, such as altered mental status, ataxia, dysarthria, or seizures, may occur in 31% (10). Pulmonary involvement, defined as “respiratory insufficiency,” was documented in 33% of registry patients, though like other features this is not specific to HLH (10). Lymphadenopathy was also present in 33%

of patients (10); however, recommendations from the North American Consortium for Histiocytosis recognize that lymphadenopathy is not common and likely suggests another disease entity (20). Shock, acute respiratory distress syndrome, acute kidney injury, and multiorgan failure may occur. Therefore, HLH should be considered in patients with fever, splenomegaly, hepatomegaly, and central nervous system or pulmonary dysfunction.

Laboratory testing can assist clinicians in evaluating for HLH in the ED. The complete blood cell count will demonstrate depression in most cell lines (anemia, leukopenia, and thrombocytopenia). Cytopenias in  $\geq 2$  lineages were present in 73% of patients in 1 study, including thrombocytopenia (82%) and anemia (73%) (10). Liver enzyme elevation often occurs early, and while sensitive with alanine aminotransferase elevation in 85% of patients with HLH, it is not specific (9,24). Bilirubin elevation and hypertriglyceridemia may also be present (20). Macrophage activation increases fibrinolysis, which can lead to elevated D-dimer, low fibrinogen, and prolonged coagulation panel results (24).

More specialized laboratory testing can be obtained if available, which can improve diagnosis. Ferritin can provide important information, as it is regulated by cytokines and secreted by splenic macrophages, acting as an acute phase reactant (25). The normal range for ferritin varies by laboratory cutoffs but is generally 10  $\mu\text{g/L}$  to 250  $\mu\text{g/L}$ . Values as low as 500  $\mu\text{g/L}$  have been used to



**Figure 2. Suggested emergency department (ED) workflow to evaluate potential hemophagocytic lymphohistiocytosis (HLH).**



risk stratify for HLH (1,14). However, this is primarily based on pediatric literature, and there are a variety of causes of ferritin elevation, including hemolysis, iron overload, liver disease (i.e., cirrhosis and hepatitis), renal failure, and systemic inflammation (i.e., infection, malignancy, rheumatologic disease, etc) (25–30). A retrospective study identified 2623 critically ill patients with hyperferritinemia, 40 of whom were diagnosed with HLH. The authors suggest a ferritin cutoff of 9083  $\mu\text{g/L}$ , which yielded a 92.5% sensitivity and 91.9% specificity in predicting sHLH in an adult intensive care unit population (23). Other laboratory findings include decreased fibrinogen and hypertriglyceridemia without specific threshold values agreed upon at this time (1). Ferritin levels alone should not be used for diagnosis, but significantly elevated values in combination with other factors (i.e., fever, splenomegaly, and cytopenias) support the diagnosis.

Lumbar puncture may be performed to evaluate for meningitis or encephalitis, as patients can present with fever, headache, and toxic appearance (9). However, HLH is associated with the hemorrhagic form of disseminated intravascular coagulation, which can increase the risk of bleeding. If patients demonstrate coagulopathy, reduced fibrinogen, or thrombocytopenia, lumbar puncture should likely be avoided. If performed, cerebrospinal fluid may demonstrate lymphocytic pleocytosis and elevated protein levels, which are nonspecific findings.

#### *Previously Developed Diagnostic Metrics*

History, examination, and laboratory findings have been structured into several scoring tools. The first is known as the HLH-2004 Diagnostic Guidelines and includes many features described as well as definitive molecular

testing (i.e., genetic confirmation) and laboratory values that are not often available in the ED, such as soluble CD25 and NK cell activity levels and tissue biopsy (Table 1) (14). The 2004 criteria were also developed for use in pediatric HLH and have not undergone validation in an adult population. These criteria were modified in 2009, which resulted in increased sensitivity but reduced specificity (Table 2) (31). The HScore includes risk stratification guidance but requires a bone marrow aspiration for complete evaluation (Table 3) (1,32). In addition, a decision tree based on hyperferritinemia levels has been proposed as an additional screening tool to differentiate hyperferritinemia of sepsis from that of HLH; however, this tool has not been externally validated (33). The authors of this decision tree suggest that a ferritin level  $>2000 \mu\text{g/L}$  in a patient with fever, cytopenias, and splenomegaly should prompt investigation for HLH (33).

Figure 2 is a compilation of these assessment tools broken into a stepwise approach that can be achieved in most ED settings. Though all measurements are not part of routine ED evaluations, these assessments may facilitate early detection of patients who are most at risk for HLH. By referencing this flow chart and tools such as the HScore, HLH-2004/2009, and hyperferritinemia thresholds, the emergency clinician can risk-stratify patients to advocate for expedited definitive testing, which may include procedures such as obtaining a bone marrow biopsy specimen and treatment directed at both the underlying cause and HLH specific management.

#### *ED Management and Disposition*

Once a patient has been identified as being at high risk for HLH, or if the emergency clinician suspects HLH, the

**Table 1. HLH-2004 Guidelines for HLH Diagnosis (14)**

The Diagnosis of HLH can be Established if Criterion 1 or 2 is Fulfilled	
Criterion 1	A molecular diagnosis consistent with HLH
Criterion 2	Diagnostic criteria for HLH fulfilled (5 of the 8 criteria below)
	Fever
	Splenomegaly
	Cytopenias (affecting $\geq 2$ of 3 lineages in the peripheral blood)
	Hemoglobin $<90 \text{ g/L}$ (hemoglobin $<100 \text{ g/L}$ in infants $<4$ weeks)
	Platelets $<100 \times 10^9/\text{L}$
	Neutrophils $<1.0 \times 10^9/\text{L}$
	Hypertriglyceridemia or hypofibrinogenemia
	Fasting triglycerides $\geq 3.0 \text{ mmol/L}$ ( $\geq 265 \text{ mg/dL}$ )
	Fibrinogen $\leq 1.5 \text{ g/L}$
	Hemophagocytosis in bone marrow or spleen or lymph nodes (no evidence of malignancy)
	Low or no NK cell activity (according to local laboratory reference)
	Ferritin $\geq 500 \mu\text{g/L}$
	sCD25 (soluble IL-2 receptor) $\geq 2400 \text{ U/mL}$

HLH = hemophagocytic lymphohistiocytosis; NK = natural killer.

**Table 2. Modified 2009 Hemophagocytic Lymphohistiocytosis Criteria (31)**

<p>≥3 of the following:</p> <ul style="list-style-type: none"> <li>Fever</li> <li>Splenomegaly</li> <li>Cytopenia of ≥2 cell lines (hemoglobin, platelets, or absolute neutrophil count)</li> <li>Hepatitis</li> </ul> <p>≥1 of the following:</p> <ul style="list-style-type: none"> <li>Ferritin elevation</li> <li>Elevated soluble CD25</li> <li>Hemophagocytosis on tissue biopsy specimen</li> <li>Low/absent natural killer cell activity</li> </ul> <p>Other supporting features, but not required</p> <ul style="list-style-type: none"> <li>Hypertriglyceridemia</li> <li>Hypofibrinogenemia</li> <li>Hyponatremia</li> </ul>
---

patient should be admitted, likely to the intensive care unit setting with hematology consultation if available. The hematologist can assist with further testing and management strategies. Transfer to a center with hematology

availability may be warranted to assist with further testing and treatment. The first-line treatment for sHLH is management of any underlying condition, but early recognition of HLH from the ED may help expedite

**Table 3. The HScore and Probabilities of HLH Based on the Score (1,32)**

Finding	No. of Points
Known underlying immunosuppression (HIV or receiving long-term immunosuppressive medications)	No (0 points)
	Yes (18 points)
Temperature (°C)	<38.4 (0 points)
	38.4–39.4 (33 points)
	>39.4 (49 points)
Organomegaly	No (0 points)
	Hepatomegaly or splenomegaly (23 points)
	Hepatomegaly and splenomegaly (38 points)
No. of cytopenias	1 lineage (0 points)
	2 lineages (24 points)
	3 lineages (34 points)
Hemoglobin level of ≤9.2 g/dL or Leukocyte count of ≤5000 cells/mm <sup>3</sup> /or Platelet count of ≤110,000/mm <sup>3</sup>	1 lineage (0 points)
	2 lineages (24 points)
	3 lineages (34 points)
Ferritin (μg/L)	<2000 (0 points)
	2000–6000 (35 points)
	>6000 (50 points)
Triglycerides (mg/dL)	<132.7 (0 points)
	132.7–354 (44 points)
	>354 (64 points)
Fibrinogen (mg/dL)	>250 (0 points)
	<250 (30 points)
	<30 (0 points)
Aspartate aminotransferase (U/L)	>30 (19 points)
	<30 (0 points)
Hemophagocytosis features on bone marrow aspirate	No (0 Points)
	Yes (35 points)
HScore at representative intervals	Probability of HLH (%)
90	<1
150	25
170	54
190	80
200	88
210	93
240	99
250	>99

HLH = hemophagocytic lymphohistiocytosis; NK = natural killer.



communication with the hematology specialist, promote definitive testing, and expedite access to targeted therapies. For an underlying malignancy, chemotherapy may be needed, while antimicrobial therapy is needed for suspected infection with or without systemic corticosteroids or other immunosuppressive regimens. Corticosteroids are the foundation of therapy for HLH, though other targeted therapies included anakinra (interleukin 1 antagonist), ruxolitinib (Janus kinase inhibitor), and etoposide (14,24,34–38). Though corticosteroids are considered first-line therapy for confirmed cases, these do not need to be started in the ED and should be discussed with the hematology specialist before use, because corticosteroids can mask alternate diagnoses, such as lymphoma. Emergency clinicians should focus on managing the underlying condition and discussion with the hematology specialist.

### *HLH and COVID-19*

The incidence of true sHLH in COVID-19 remains debated. While there is a striking overlap in features of severe COVID-19 and the HLH syndromes, key diagnostic criteria such as cytopenias are less common than expected in HLH (39,40). Cytokine storm has been recognized in COVID-19 as contributing to many conditions that mimic rheumatologic conditions (41). The inflammatory cascade has been postulated to be a primary cause of capillary leakage, coagulopathies, and even death (42–44). In addition, the degree of inflammatory dysregulation has been identified as a marker of disease and viral burden; likely, a complex combination of these factors contributes to the development of sHLH in COVID-19 (40,45–47). In addition, genes associated with pHLH were identified as related to inflammatory dysregulation in severe H1N1 influenza, and it is possible that these genetic factors contribute to variability in the COVID-19 inflammatory response as well (48,49). This suggests that identification of features of HLH in a patient suspected of having COVID-19 may be associated with disease severity, whether this is caused by underlying genetic features or a symptom of viral progression (48).

### CONCLUSIONS

HLH is a dangerous yet underrecognized disease entity. Emergency clinicians can serve a critical role in the prompt recognition and initiation of appropriate testing to expedite treatment. Severe COVID-19 infections may present with features of HLH and should prompt early evaluation for this highly fatal complication. There remains a significant need for data collection and study on the adult disease population, subpopulations of

malignancy-associated cases, genetic variants, and viral-mediated cytokine release syndromes. An increased awareness of HLH will likely contribute to improved understanding of physiology and improve outcomes over time.

### CLINICAL BOTTOM LINE

Further testing reveals elevated ferritin and decreased fibrinogen. The clinical presentation and diagnostic studies suggest pneumonia with HLH. The patient has received fluid resuscitation and broad-spectrum antibiotics. The physician recognizes the potential diagnosis of HLH and speaks with the intensive care specialist and hematologist, who recommend admission to the intensive care unit for further testing and continued resuscitation.

*Acknowledgments*—Figures courtesy of Jillian Smith graphic design ([www.jilliansmith.org](http://www.jilliansmith.org)). KM, AK, and BL came up with the idea for the narrative review. All authors assisted with writing and editing. This review does not reflect the views or opinions of the U.S. government, Department of Defense or its Components, U.S. Army, U.S. Air Force, or SAUSHEC EM Residency Program.

### REFERENCES

1. Fardet L, Galicier L, Lambotte O, et al. Development and validation of the HScore, a score for the diagnosis of reactive hemophagocytic syndrome. *Arthritis Rheumatol* 2014;66:2613–20.
2. Schram AM, Berliner N. How I treat hemophagocytic lymphohistiocytosis in the adult patient. *Blood* 2015;125:2908–14.
3. Hayden A, Park S, Giustini D, Lee AY, Chen LY. Hemophagocytic syndromes (HPSs) including hemophagocytic lymphohistiocytosis (HLH) in adults: a systematic scoping review. *Blood Rev* 2016;30:411–20.
4. Mehta RS, Smith RE. Hemophagocytic lymphohistiocytosis (HLH): a review of literature. *Med Oncol* 2013;30:740.
5. Ishii E, Ohga S, Imashuku S, et al. Nationwide survey of hemophagocytic lymphohistiocytosis in Japan. *Int J Hematol* 2007;86:58–65.
6. Suzuki N, Morimoto A, Ohga S, et al. Characteristics of hemophagocytic lymphohistiocytosis in neonates: a nationwide survey in Japan. *J Pediatr* 2009;155:235–238231.
7. Meeths M, Horne A, Sabel M, Bryceson YT, Henter JJ. Incidence and clinical presentation of primary hemophagocytic lymphohistiocytosis in Sweden. *Pediatr Blood Cancer* 2015;62:346–52.
8. Nikiforov S, Berliner N. To “lump” or to “split” in macrophage activation syndrome and hemophagocytic lymphohistiocytosis. *Arthritis Rheumatol* 2020;72:206–9.
9. Brisse E, Matthys P, Wouters CH. Understanding the spectrum of haemophagocytic lymphohistiocytosis: update on diagnostic challenges and therapeutic options. *Br J Haematol* 2016;174:175–87.
10. Birndt S, Schenk T, Heinevetter B, et al. Hemophagocytic lymphohistiocytosis in adults: collaborative analysis of 137 cases of a nationwide German registry. *J Cancer Res Clin Oncol* 2020;146:1065–77.
11. Al-Ahmari A. Is secondary hemophagocytic lymphohistiocytosis behind the high fatality rate in Middle East respiratory syndrome corona virus? *J Appl Hematol* 2015;6:1–5.

12. Soy M, Atagündüz P, Atagündüz I, Sucak GT. Hemophagocytic lymphohistiocytosis: a review inspired by the COVID-19 pandemic. *Rheumatol Int* 2021;41:7–18.
13. Ehl S, Astigarraga I, von Bahr Greenwood T, et al. Recommendations for the use of etoposide-based therapy and bone marrow transplantation for the treatment of HLH: consensus statements by the HLH Steering Committee of the Histiocyte Society. *J Allergy Clin Immunol Pract* 2018;6:1508–17.
14. Henter JI, Horne A, Arico M, et al. HLH-2004: diagnostic and therapeutic guidelines for hemophagocytic lymphohistiocytosis. *Pediatr Blood Cancer* 2007;48:124–31.
15. Henter JI, Samuelsson-Horne A, Arico M, et al. Treatment of hemophagocytic lymphohistiocytosis with HLH-94 immunochemotherapy and bone marrow transplantation. *Blood* 2002;100:2367–73.
16. Wohlfarth P, Agis H, Gualdoni GA, et al. Interleukin 1 receptor antagonist anakinra, intravenous immunoglobulin, and corticosteroids in the management of critically ill adult patients with hemophagocytic lymphohistiocytosis. *J Intensive Care Med* 2019;34:723–31.
17. Apodaca E, Rodriguez-Rodriguez S, Tuna-Aguilar EJ, Demichelis-Gomez R. Prognostic factors and outcomes in adults with secondary hemophagocytic lymphohistiocytosis: a single-center experience. *Clin Lymphoma Myeloma Leuk* 2018;18:e373–80.
18. Parikh SA, Kapoor P, Letendre L, Kumar S, Wolanskyj AP. Prognostic factors and outcomes of adults with hemophagocytic lymphohistiocytosis. *Mayo Clin Proc* 2014;89:484–92.
19. Riviere S, Galicier L, Coppo P, et al. Reactive hemophagocytic syndrome in adults: a retrospective analysis of 162 patients. *Am J Med* 2014;127:1118–25.
20. Jordan MB, Allen CE, Greenberg J, et al. Challenges in the diagnosis of hemophagocytic lymphohistiocytosis: recommendations from the North American Consortium for Histiocytosis (NACHO). *Pediatr Blood Cancer* 2019;66:e27929.
21. Akenroye AT, Madan N, Mohammadi F, Leider J. Hemophagocytic lymphohistiocytosis mimics many common conditions: case series and review of literature. *Eur Ann Allergy Clin Immunol* 2017;49:31–41.
22. Janka GE. Familial and acquired hemophagocytic lymphohistiocytosis. *Eur J Pediatr* 2007;166:95–109.
23. Feig JA, Cina SJ. Evaluation of characteristics associated with acute splenitis (septic spleen) as markers of systemic infection. *Arch Pathol Lab Med* 2001;125:888–91.
24. Griffin G, Shenoi S, Hughes GC. Hemophagocytic lymphohistiocytosis: an update on pathogenesis, diagnosis, and therapy. *Best Pract Res Clin Rheumatol* 2020;34:101515.
25. Moore C Jr, Ormseth M, Fuchs H. Causes and significance of markedly elevated serum ferritin levels in an academic medical center. *J Clin Rheumatol* 2013;19:324–8.
26. Sackett K, Cunderlik M, Sahni N, Killeen AA, Olson AP. Extreme hyperferritinemia: causes and impact on diagnostic reasoning. *Am J Clin Pathol* 2016;145:646–50.
27. Wormsbecker AJ, Sweet DD, Mann SL, Wang SY, Pudek MR, Chen LY. Conditions associated with extreme hyperferritinaemia (>3000 mug/L) in adults. *Intern Med J* 2015;45:828–33.
28. Otrrock ZK, Hock KG, Riley SB, de Witte T, Eby CS, Scott MG. Elevated serum ferritin is not specific for hemophagocytic lymphohistiocytosis. *Ann Hematol* 2017;96:1667–72.
29. Naymagon L, Tremblay D, Mascarenhas J. Reevaluating the role of ferritin in the diagnosis of adult secondary hemophagocytic lymphohistiocytosis. *Eur J Haematol* 2020;104:344–51.
30. Belfeki N, Strazzulla A, Picque M, Diamantis S. Extreme hyperferritinemia: etiological spectrum and impact on prognosis. *Reumatismo* 2020;71:199–202.
31. Filipovich AH. Hemophagocytic lymphohistiocytosis (HLH) and related disorders. *Hematology Am Soc Hematol Educ Program* 2009;127–31.
32. Debaugnies F, Mahadeb B, Ferster A, et al. Performances of the H-Score for diagnosis of hemophagocytic lymphohistiocytosis in adult and pediatric patients. *Am J Clin Pathol* 2016;145:862–70.
33. Machowicz R, Janka G, Wiktor-Jedrzejczak W. Similar but not the same: differential diagnosis of HLH and sepsis. *Crit Rev Oncol Hematol* 2017;114:1–12.
34. Shakoory B, Carcillo JA, Chatham WW, et al. Interleukin-1 receptor blockade is associated with reduced mortality in sepsis patients with features of macrophage activation syndrome: reanalysis of a prior phase III trial. *Crit Care Med* 2016;44:275–81.
35. Ahmed A, Merrill SA, Alsawah F, et al. Ruxolitinib in adult patients with secondary haemophagocytic lymphohistiocytosis: an open-label, single-centre, pilot trial. *Lancet Haematol* 2019;6:e630–7.
36. Wang J, Wang Y, Wu L, et al. Ruxolitinib for refractory/relapsed hemophagocytic lymphohistiocytosis. *Haematologica* 2020;105:e210–2.
37. Beutel G, Wiesner O, Eder M, et al. Virus-associated hemophagocytic syndrome as a major contributor to death in patients with 2009 influenza A (H1N1) infection. *Crit Care* 2011;15:R80.
38. Carcillo JA, Simon DW, Podd BS. How we manage hyperferritinemic sepsis-related multiple organ dysfunction syndrome/macrophage activation syndrome/secondary hemophagocytic lymphohistiocytosis histiocytosis. *Pediatr Crit Care Med* 2015;16:598–600.
39. McGonagle D, Sharif K, O'Regan A, Bridgewood C. The role of cytokines including interleukin-6 in COVID-19 induced pneumonia and macrophage activation syndrome-like disease. *Autoimmun Rev* 2020;19:102537.
40. Ruscitti P, Berardicurti O, Iagnocco A, Giacomelli R. Cytokine storm syndrome in severe COVID-19. *Autoimmun Rev* 2020;19:102562.
41. Misra DP, Agarwal V, Gasparyan AY, Zimba O. Rheumatologists' perspective on coronavirus disease 19 (COVID-19) and potential therapeutic targets. *Clin Rheumatol* 2020;39:2055–62.
42. Calabrese LH. Cytokine storm and the prospects for immunotherapy with COVID-19. *Cleve Clin J Med* 2020;87:389–93.
43. Mehta P, McAuley DF, Brown M, et al. COVID-19: consider cytokine storm syndromes and immunosuppression. *Lancet* 2020;395:1033–4.
44. Henderson LA, Canna SW, Schulert GS, et al. On the alert for cytokine storm: immunopathology in COVID-19. *Arthritis Rheumatol* 2020;72:1059–63.
45. Chhetri S, Khamis F, Pandak N, Al Khalili H, Said E, Petersen E. A fatal case of COVID-19 due to metabolic acidosis following dysregulate inflammatory response (cytokine storm). *IDCases* 2020;21:e00829.
46. Leverenz DL, Tarrant TK. Is the HScore useful in COVID-19? *Lancet* 2020;395:e83.
47. Meftahi GH, Jangravi Z, Sahraei H, Bahari Z. The possible pathophysiology mechanism of cytokine storm in elderly adults with COVID-19 infection: the contribution of “inflamm-aging” *Inflamm Res* 2020;69:825–39.
48. Felsenstein S, Herbert JA, McNamara PS, Hedrich CM. COVID-19: immunology and treatment options. *Clin Immunol* 2020;215:108448.
49. Schulert GS, Zhang M, Fall N, et al. Whole-exome sequencing reveals mutations in genes linked to hemophagocytic lymphohistiocytosis and macrophage activation syndrome in fatal cases of H1N1 influenza. *J Infect Dis* 2016;213:1180–8.

### ARTICLE SUMMARY

#### **1. Why is this topic important?**

Hemophagocytic lymphohistiocytosis (HLH) is a condition associated with high mortality that increases with a delay in diagnosis, and the clinical presentation overlaps with several common syndromes seen in the emergency department (ED). However, ED evaluation for this disease has not previously been addressed in the emergency medicine literature.

#### **2. What does this review attempt to show?**

This review provides a summary of HLH and an approach to the recognition of HLH in the ED.

#### **3. What are the key findings?**

Several factors from the history, examination, and laboratory studies can suggest the disease. Common features include a history of infection or malignancy, fever, splenomegaly or hepatomegaly, hyperferritinemia, cytopenias, coagulopathies, abnormal liver enzymes, and hypertriglyceridemia. Once diagnosed, disease-specific treatment can be considered, along with hematology consultation.

#### **4. How is patient care impacted?**

Consideration of HLH with appropriate evaluation in the ED and specialist consultation can assist with ED diagnosis of this dangerous condition.