

UC Davis

Dermatology Online Journal

Title

Morbilliform rash after administration of Pfizer-BioNTech COVID-19 mRNA vaccine

Permalink

<https://escholarship.org/uc/item/4xs486zg>

Journal

Dermatology Online Journal, 27(1)

Authors

Jedlowski, Patrick M
Jedlowski, Mahdiah F

Publication Date

2021

DOI

10.5070/D3271052044

Copyright Information

Copyright 2021 by the author(s). This work is made available under the terms of a Creative Commons Attribution-NonCommercial-NoDerivatives License, available at <https://creativecommons.org/licenses/by-nc-nd/4.0/>

Peer reviewed

Morbilliform rash after administration of Pfizer-BioNTech COVID-19 mRNA vaccine

Patrick M Jedlowski MD, Mahdieh F Jedlowski MD PharmD

Affiliations: Division of Dermatology, University of Arizona College of Medicine, Tucson, Arizona, USA, Tucson Hospitals Medical Education Program, Tucson Medical Center, Tucson, Arizona, USA

Corresponding Author: Patrick Jedlowski MD, 1501 North Campbell Avenue, Tucson, AZ 85724-5035, Tel: 480-239-8459, Email: pjedlowski@email.arizona.edu

Keywords: coronavirus, COVID-19, mRNA vaccine, morbilliform rash, cutaneous, adverse event

To the Editor:

The severe acute respiratory syndrome coronavirus 2 (SARS-CoV-2) causes the coronavirus disease 2019 (COVID-19) systemic viral syndrome responsible for an ongoing global pandemic. COVID-19 has been diagnosed in over 25,300,000 cases and caused over 420,000 deaths in the United States alone as of January 2021 [1].

Recently, the FDA has granted emergency approval to two vaccines against SARS-CoV2: the Pfizer-BioNTech COVID-19 vaccine on 12/11/2020 and the Moderna COVID-19 vaccine on 12/18/2020 [2,3]. Both vaccines utilize a novel technology of administering vaccination, namely mRNA encoding the SARS-CoV-2 spike protein enveloped in lipid nanoparticles, thereby penetrating the cell membrane into the cell and producing spike protein for subsequent antigen presentation and immune system activation [2-4]. Although this novel vaccine technology is purported to be generally safe, the adverse effects of mRNA vaccines are not yet fully characterized. Herein, we report the development of a morbilliform rash on the trunk of a patient two days following vaccination, a hitherto unreported event.

A 30-year-old male healthcare worker with no past medical history presented for vaccination with the SARS-CoV2, the Pfizer-BioNTech COVID-19 vaccine. The day after vaccination the patient experienced mild subjective fevers, headache, and injection site soreness in the deltoid region without overlying skin changes. Forty-eight hours after administration of

the vaccine, the patient developed a mildly pruritic erythematous macular morbilliform eruption on the lower back (**Figure 1**). Over the course of the following 24 hours, the patient's rash resolved without intervention.

Twenty-one days following the initial vaccine, the patient received the second dose of the Pfizer-BioNTech COVID-19 vaccine, after which he experienced chills, fatigue and myalgias. Forty-eight hours after administration of the second dose, the patient developed a recurrent morbilliform eruption most prominent on the bilateral flanks and flesh-colored papules on the right flank with significantly increased pruritus and body surface area involvement. Notably, areas which were previously spared by the first rash including the flanks, proximal extremities and upper back were involved (**Figure 2**). Of note, regions affected in the first rash (lower back) were similarly affected in the recurrent rash. This rash similarly resolved over the following 24 hours without treatment.

Morbilliform eruptions occurring secondary to systemic viral infections, or viral exanthems, are a well-described phenomenon occurring most notably in response to picornaviruses such as enteroviruses, echovirus and coxsackie. However, they may also occur in a variety of viral infections including adenovirus, influenza and *Herpesviridae* including cytomegalovirus, Epstein-Barr virus, and human herpes virus 6 and 7 [5]. Morbilliform rashes have also been reported in COVID-19 infections; it may serve as the presenting symptom aiding in subsequent diagnosis [6]. In a case series of patients with morbilliform eruption secondary to SARS-CoV-2

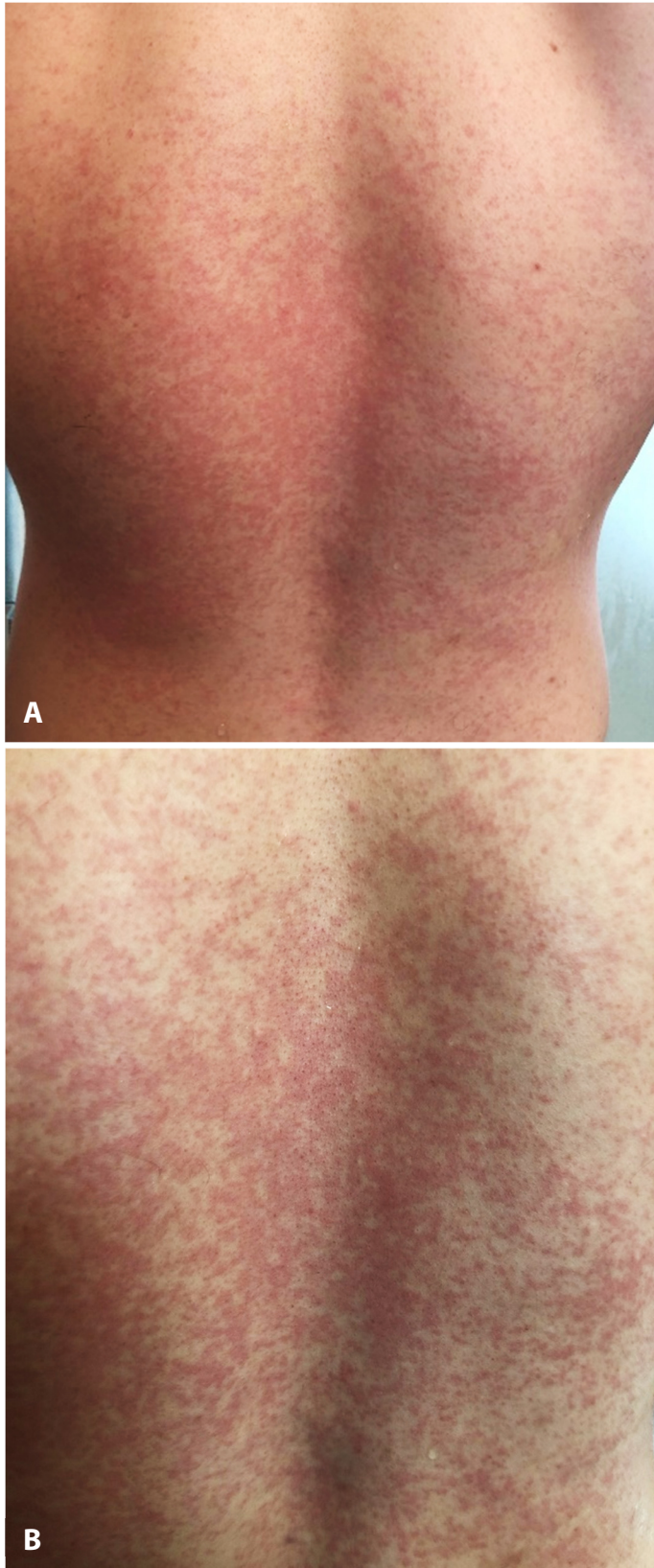


Figure 1. A) Morbilliform, erythematous macular patches on the lower back of the patient. **B)** Closer view of morbilliform eruption, revealing erythematous macules with confluence and intervening areas of unaffected skin.

infection, all skin biopsies were negative for viral RNA and proteins. However, these biopsies were notable for spongiosis and mild dermal perivascular lymphocytic infiltrates suggesting that the cutaneous eruption is not directly caused by the virus but may instead manifest secondary to immune activation [7]. Accordingly, it is possible that the morbilliform rash observed in our patient was similarly caused by immune activation, as the timing of rash onset closely coincided with vaccine administration.

Herein, we report a case of morbilliform rash secondary to the Pfizer-BioNTech COVID-19 vaccine, like that seen in COVID-19 infection. The presence of similar eruptions in SARS-CoV-2 positive patients and in this patient following vaccination with a mRNA vaccine suggests a similar underlying etiology of immune activation leading to the development of a morbilliform rash [7]. An immune-mediated etiology is plausible in our patient's vaccine-related rash, as it was recurrent and notably more extensive following the second dose of the vaccine suggesting a more robust immune response. Thus far, rash has not been

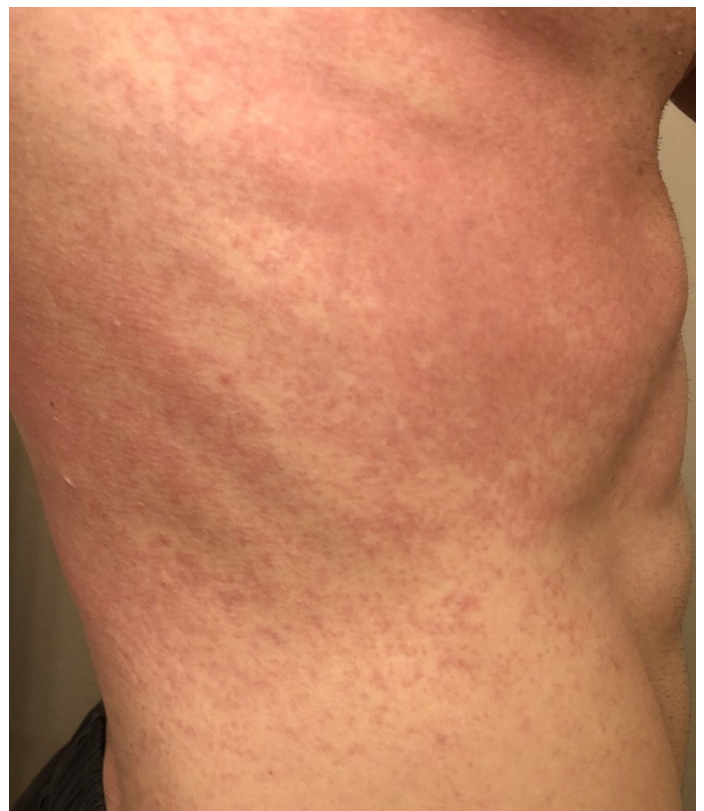

Figure 2. Recurrent morbilliform eruption on the right flank with flesh-colored papules on the posterior right flank.

reported as an adverse effect in the Pfizer-BioNTech briefing document. However, injection site rash, injection site urticaria, and maculopapular rash were described in 0.24%, 0.1%, and 0.07% of patient receiving the Moderna vaccine [8,9].

To date, over ten million individuals in the United States have received COVID-19 vaccinations [1]. As more individuals receive the Moderna and Pfizer-BioNTech mRNA vaccines, it is likely that more patients will subsequently develop cutaneous

adverse effects. Although the significance of such a cutaneous eruption is yet unclear, post-marketing surveillance will be necessary and further studies may be required to determine if development of a morbilliform rash represents a positive prognostic factor regarding immune protection from SARS-CoV-2.

Potential conflicts of interest

The authors declare no conflicts of interest.

References

1. CDC. United States COVID-19 Cases and Deaths by State. Centers for Disease Control and Prevention; 2020. https://covid.cdc.gov/covid-data-tracker/#cases_casesper100klast7days. Accessed on January 13, 2021.
2. FDA. Fact sheet for healthcare providers administering vaccine (vaccination providers) emergency use authorization (EUA) of the pfizer-biontech COVID-19 vaccine to prevent coronavirus disease 2019 (COVID-19). U.S. Food and Drug Administration; 2020. p. 29. <https://www.fda.gov/emergency-preparedness-and-response/coronavirus-disease-2019-covid-19/pfizer-biontech-covid-19-vaccine#additional>. Accessed on December 23, 2021.
3. FDA. Fact sheet for healthcare providers administering vaccine (vaccination providers) emergency use authorization (EUA) of the Moderna COVID-19 vaccine to prevent coronavirus disease 2019 (COVID-19) U.S. Food and Drug Administration; 2020. p. 22. <https://www.fda.gov/emergency-preparedness-and-response/coronavirus-disease-2019-covid-19/moderna-covid-19-vaccine>. Accessed on December 23, 2021.
4. Park KS, Sun X, Aikins ME, Moon JJ. Non-viral COVID-19 vaccine delivery systems. *Adv Drug Deliv Rev.* 2020;169:137-151. [PMID: 33340620].
5. Korman AM, Alikhan A, Kaffenberger BH. Viral exanthems: An update on laboratory testing of the adult patient. *J Am Acad Dermatol.* 2017;76:538-50. [PMID: 28413059].
6. Kulkarni RB, Lederman Y, Afiari A, et al. Morbilliform Rash: An Uncommon Herald of SARS-CoV-2. *Cureus.* 2020;12:e9321. [PMID: 32850199].
7. Fattori A, Cribier B, Chenard MP, et al. Cutaneous manifestations in patients with coronavirus disease 2019: clinical and histological findings. *Hum Pathol.* 2020;107:39-45. [PMID: 33161030].
8. FDA. FDA Briefing Document, Pfizer-BioNTech COVID-19 Vaccine. U.S. Food and Drug Administration; 2020. p. 53. <https://www.fda.gov/media/144245/download>. Accessed on December 23, 2021.
9. FDA. FDA Briefing Document, Moderna COVID-19 Vaccine. U.S. Food and Drug Administration; 2020, p. 54. <https://www.fda.gov/media/144434/download>. Accessed on December 23, 2021.