

# UC Davis

## Dermatology Online Journal

### Title

Palbociclib-induced IgA vasculitis

### Permalink

<https://escholarship.org/uc/item/4wm8004g>

### Journal

Dermatology Online Journal, 27(12)

### Authors

Patel, Payal M  
Kelm, Ryan C  
Amber, Kyle T

### Publication Date

2021

### DOI

10.5070/D3271256719

### Copyright Information

Copyright 2021 by the author(s). This work is made available under the terms of a Creative Commons Attribution-NonCommercial-NoDerivatives License, available at <https://creativecommons.org/licenses/by-nc-nd/4.0/>

Peer reviewed

## Palbociclib-induced IgA vasculitis

Payal M Patel MD, Ryan C Kelm MD, Kyle T Amber MD

Affiliation: Division of Dermatology, Department of Otorhinolaryngology, Rush University Medical Center, Chicago, Illinois, USA

Corresponding Author: Kyle T Amber MD, 707 South Wood Street, Suite 220, Chicago, IL 60612, Tel: 312-563-5990, Email: [kyleambermd@gmail.com](mailto:kyleambermd@gmail.com)

*Keywords: cutaneous toxicity, immunology, metastatic breast cancer, palbociclib, vasculitis*

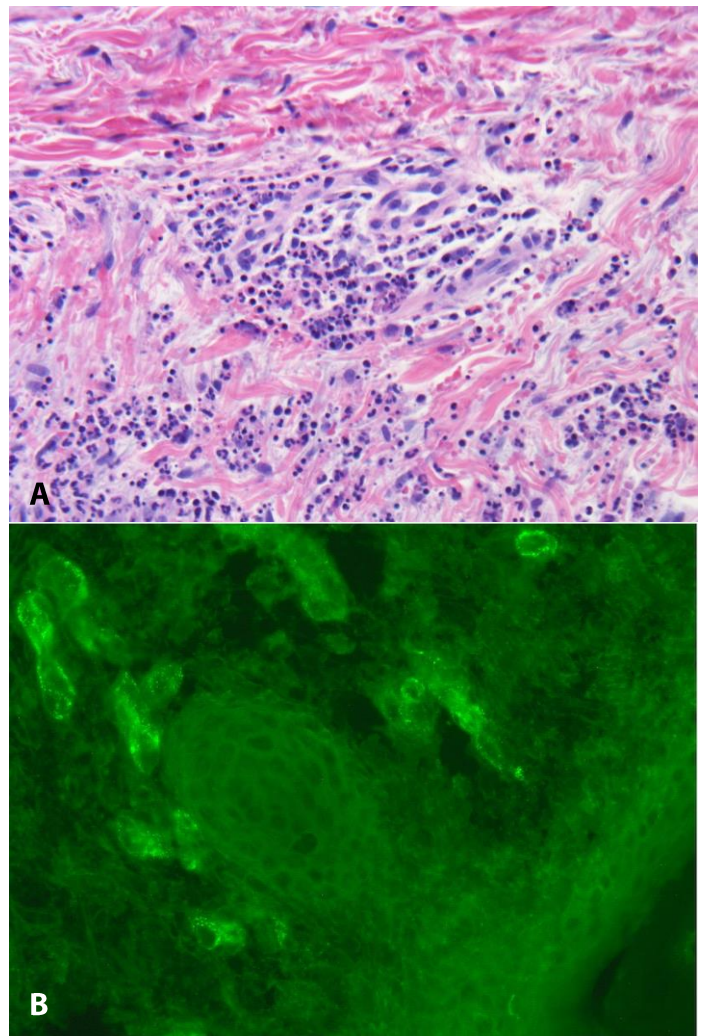
To the Editor:

A 64-year-old woman presented to the dermatology clinic with a one-week history of a worsening bilateral lower extremity rash. Medical history was significant for metastatic cystosarcoma phyllodes tumor of the right breast that recurred and progressed despite surgical intervention, chemotherapy with doxorubicin and dacarbazine, and radiotherapy. Surgical resection of tumor was not advised due to metastatic progression. The tumor was characterized as CDKN2A+ and treatment was initiated with cycled palbociclib 125mg daily for three weeks on, one week off. After two weeks of treatment with palbociclib, a cutaneous eruption started on the lower legs and progressed to involve the bilateral thighs. The rash was asymptomatic with no associated fever, chills, nausea, vomiting, joint pain, cough, and hematuria. The patient discontinued palbociclib after the onset of the eruption and denied using any medications to treat the lesions.

Physical examination revealed several scattered pink-to-erythematous-to-violaceous palpable purpuric papules and plaques extending from the bilateral lower legs to the upper thighs. No lesions were present superior to the waistline. Mucosal membranes were spared.

The clinical history and morphology of the eruption suggests a differential diagnosis of drug-induced vasculitis. Further investigations included two 4mm punch biopsies of lesional skin, one for hematoxylin and eosin (H&E) and one for direct

immunofluorescence. Histologic examination of H&E specimen revealed leukocytoclastic vasculitis. Direct immunofluorescence of the specimen was positive



**Figure 1. A).** Biopsy of lesional skin reveals small vessels with plump endothelial cells, fibrinoid necrosis and associated neutrophilic infiltrate with nuclear debris and extravasated red blood cells. H&E, 40 $\times$ . **B).** Direct immunofluorescence reveals IgA deposits within walls of small vessels in the dermis can be seen, 40 $\times$ .

with strong perivascular staining for fibrinogen and IgA within the superficial dermal blood vessels, also consistent with vasculitis (**Figure 1**). Staining for C1q, C3, IgM, and IgG were negative.

At two-week follow-up, palpable purpura self-resolved and no new lesions appeared in the interim period. Fecal occult and urine analysis were negative for blood in the stool and microscopic hematuria, respectively. Given the temporal relationship between the onset of leukocytoclastic vasculitis following palbociclib coupled with rash resolution with discontinuation, the patient was diagnosed with palbociclib-induced IgA vasculitis.

Chawla et al. [1] note that the rate of adverse effects is greatest when palbociclib is combined with fulvestrant and overall incidence may be understated due to self-resolving pathology. The pathologic mechanism behind this association has not been elucidated. CDK4/6 inhibitors may act as haptens themselves or generate an abnormal immune response by interfering with cell cycle progression, resulting in apoptosis of tumor cells or other rapidly replicating cells [2]. Additionally, certain *human leukocyte antigen (HLA)* genes,

particularly *HLA-B\*41:02*, have been identified as susceptibility markers for the development of IgA vasculitis. Since HLA genes code for molecules that present antigens to T cells, resulting in T cell activation, these processes may be involved in autoimmune disease pathogenesis [3]. In support of this theory, short-term pharmacologic use of CDK4/6 inhibitors has been shown to favor T cell proliferation and T cell recruitment [4]. Thus, the role of genetics and T cell activation in promoting IgA vasculitis may require further investigation.

With increasing reports of cutaneous toxicities with targeted therapies such as palbociclib, clinicians must maintain a high index of suspicion and obtain histopathology to establish a diagnosis. Herein, we highlight a unique example of IgA vasculitis associated with palbociclib and suggest that the pathologic mechanism may involve a complex interplay between T cell activation and the histocompatibility complex factors.

## Potential conflicts of interest

The authors declare no conflicts of interest.

## References

1. Chawla S, Hill A, Fearfield L, et al. Cutaneous toxicities occurring during palbociclib (CDK4/6 inhibitor) and endocrine therapy in patients with advanced breast cancer: a single-centre experience. *Breast Cancer Res Treat.* 2021;188:535–45. [PMID: 33683521].
2. Musgrove EA, Caldon CE, Barraclough J, Stone A, Sutherland RL. Cyclin D as a therapeutic target in cancer. *Nat Rev Cancer.* 2011;11:558–72. [PMID: 21734724].
3. Heineke MH, Ballering AV, Jamin A, et al. New insights in the pathogenesis of immunoglobulin A vasculitis (Henoch-Schönlein purpura). *Autoimmun Rev.* 2017;16:1246–53. [PMID: 29037908].
4. Deng J, Wang ES, Jenkins RW, et al. CDK4/6 Inhibition Augments Antitumor Immunity by Enhancing T-cell Activation. *Cancer Discov.* 2018;8:216–33. [doi: 10.1158/2159-8290.cd-17-0915].