

UC Davis

Dermatology Online Journal

Title

Localized cutaneous argyria: Report of two patients and literature review

Permalink

<https://escholarship.org/uc/item/4wm1j7pt>

Journal

Dermatology Online Journal, 22(11)

Authors

Beutler, Bryce David
Lee, Robert A
Cohen, Philip R

Publication Date

2016

DOI

10.5070/D32211033151

Copyright Information

Copyright 2016 by the author(s). This work is made available under the terms of a Creative Commons Attribution-NonCommercial-NoDerivatives License, available at <https://creativecommons.org/licenses/by-nc-nd/4.0/>

Peer reviewed

Case presentation

Localized cutaneous argyria: Report of two patients and literature review

Bryce David Beutler¹, Robert A. Lee², Philip R. Cohen²

Dermatology Online Journal 22 (11): 11

¹ **University of Nevada, Reno School of Medicine, Reno, NV 89557**

² **University of California San Diego, La Jolla, CA 92093**

Correspondence:

Bryce David Beutler
1060 Wiegand Street
Encinitas, CA 92024
Phone: (509) 352-9699
Email: brycebeutler@hotmail.com

Philip R. Cohen
University of California San Diego
9500 Gilman Drive #0975
La Jolla, CA 92093
Email: mitehead@gmail.com

Abstract

Background

Localized cutaneous argyria is a rare skin condition caused by direct contact with silver or silver particles. It presents as asymptomatic gray or blue-gray macules that appear similar to blue nevi. Histologic features include brown-colored or black-colored silver granules in the basement membrane and dermis, most commonly surrounding eccrine glands, elastic fibers, and collagen fibrils. The condition is most frequently observed in individuals who are regularly exposed to small silver particles, such as silversmiths and welders. However, localized cutaneous argyria has also been associated with acupuncture needles, silver earrings, and topical medications containing silver nitrate. Although the condition is benign, patients who are concerned about the cosmetic features of localized cutaneous argyria may benefit from laser therapy.

Purpose

We describe the clinical and pathologic findings of two women who developed localized cutaneous argyria. We also review the characteristics of other patients with localized cutaneous argyria and summarize the differential diagnosis and treatment options for this condition.

Materials and methods

The features of two women with localized cutaneous argyria are presented. Using PubMed, the following terms were searched and relevant citations assessed: acquired localized argyria, acupuncture, argyria, argyrosis, colloidal silver, cutaneous argyria, and localized cutaneous argyria. In addition, the literature on localized cutaneous argyria is reviewed.

Results

Two women presented with small, asymptomatic blue-gray macules appearing at sites directly adjacent to ear piercings. A punch biopsy was performed on one woman. Microscopic examination revealed a yellowish-brown colored granular material found adjacent to elastic fibers. Based on correlation of the clinical presentation and histopathologic findings, a diagnosis of localized cutaneous argyria was established. The second woman did not undergo a biopsy. However, the clinical presentation was highly suggestive of localized cutaneous argyria. Both women were reassured of the benign nature of the condition and agreed to return for clinical follow-up if they observed any changes in the appearance of the lesions.

Keywords: acquired localized argyria, acupuncture, argyria, argyrosis, colloidal silver, cutaneous argyria, localized cutaneous argyria

Introduction

Localized cutaneous argyria is a benign condition characterized by the development of blue-gray macules that appear on the skin following direct contact with silver. The condition is most commonly caused by occupational exposure to silver particles, but has also been associated with silver jewelry [1], acupuncture needles [2], and topical antibiotics [3]. Microscopic examination of localized cutaneous argyria lesions typically reveals brown-colored or black-colored silver granules within histiocytes and surrounding eccrine glands, elastic fibers, and collagen fibrils. Notably, the epidermis is spared; the silver accumulates primarily in the basement membrane and dermis.

Localized cutaneous argyria can affect both men and women. There is no known ethnic predilection. The mechanism of pathogenesis is not fully understood, but it has been postulated that skin discoloration results from a reaction between light and dermal protein-bound silver [4]. Treatment options for localized cutaneous argyria are limited. However, laser therapy may improve the cosmetic features of the condition [5].

We describe the clinical and pathologic findings of two women who developed localized cutaneous argyria. We also review the characteristics of other patients with localized cutaneous argyria and summarize the differential diagnosis and treatment options for this condition.

Case reports

Patient 1 is a 68-year-old woman who presented with blue-gray discoloration of her anterior and posterior distal helical rims and ear lobes surrounding the sites of ear piercings. Both the left and right ear lobes were similarly affected (Figure 1).

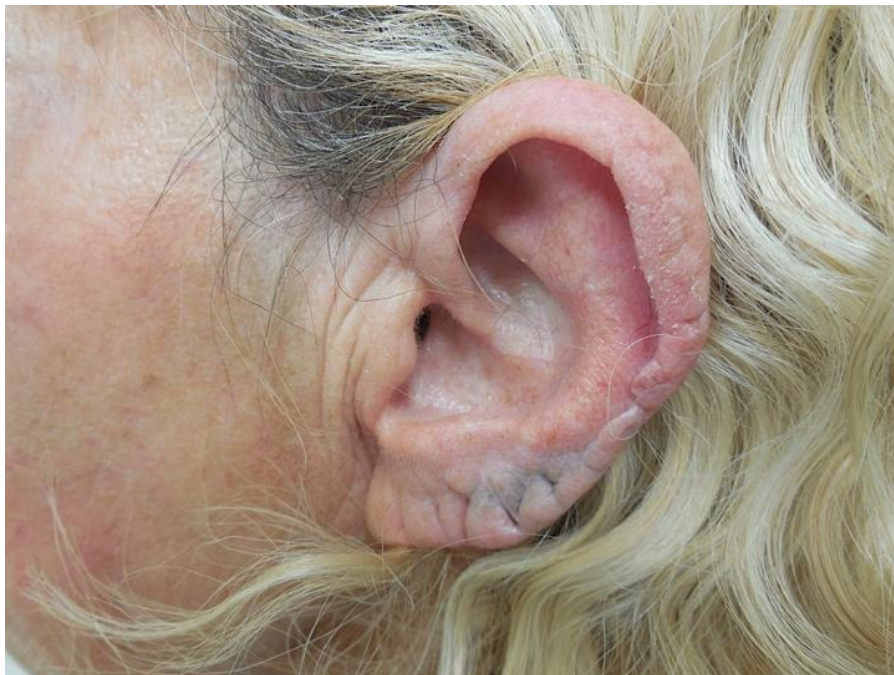

Figure 1. The left ear lobe of Patient 1 shows blue-gray discoloration on the anterior surface of the ear lobe.

A punch biopsy was performed. Microscopic examination revealed a yellowish-brown colored granular material found adjacent to elastic fibers (Figure 2).

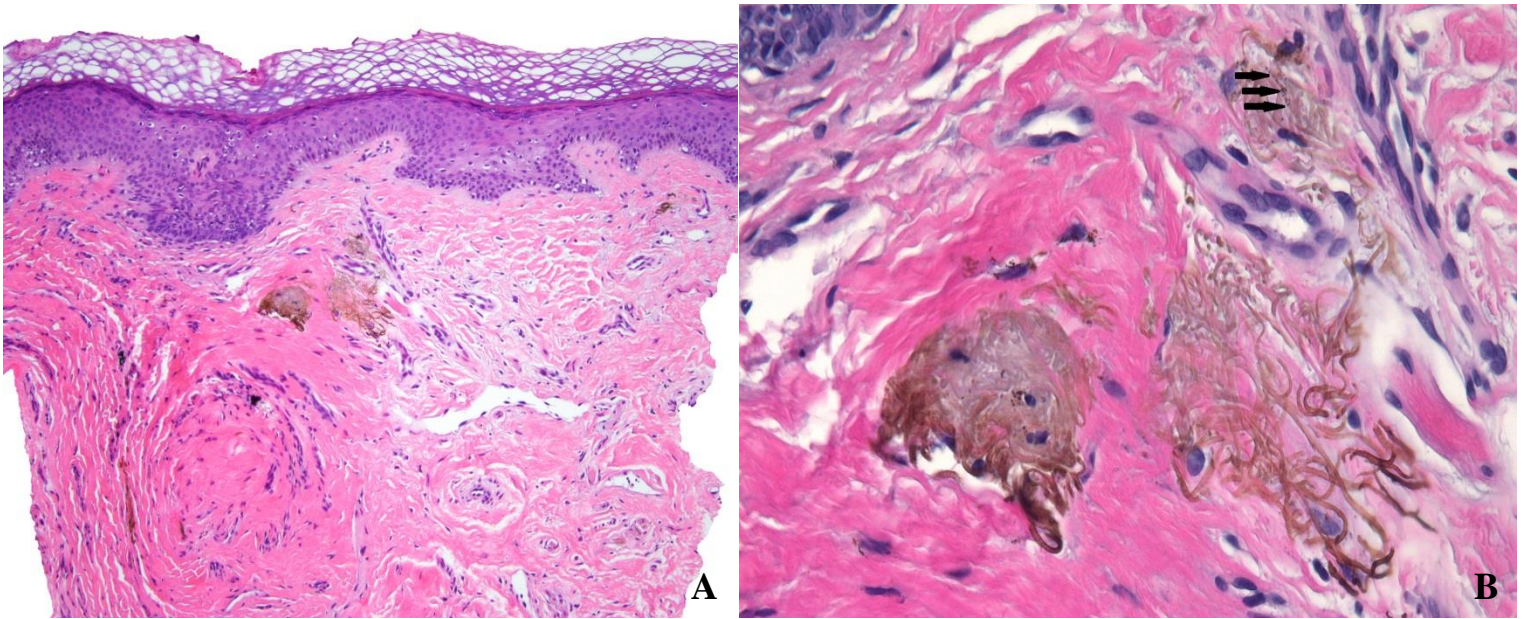


Figure 2. Low (A) and high (B) magnification views of a localized cutaneous argyria macule taken from a tissue biopsy of Patient 1 shows a yellowish-brown colored granular material (indicated by arrows) along the elastic fibers. [Hematoxylin and eosin; A = 10x, B = 60x].

The elastic fibers were highlighted by Verhoeff-Van Gieson staining (Figure 3) and stained negatively with Fontana Masson and Perls iron staining. Based on correlation of the clinical presentation and histopathologic findings, a diagnosis of localized cutaneous argyria was established. The patient declined treatment but agreed to return for clinical follow up if she observed any changes in the appearance of the lesions.

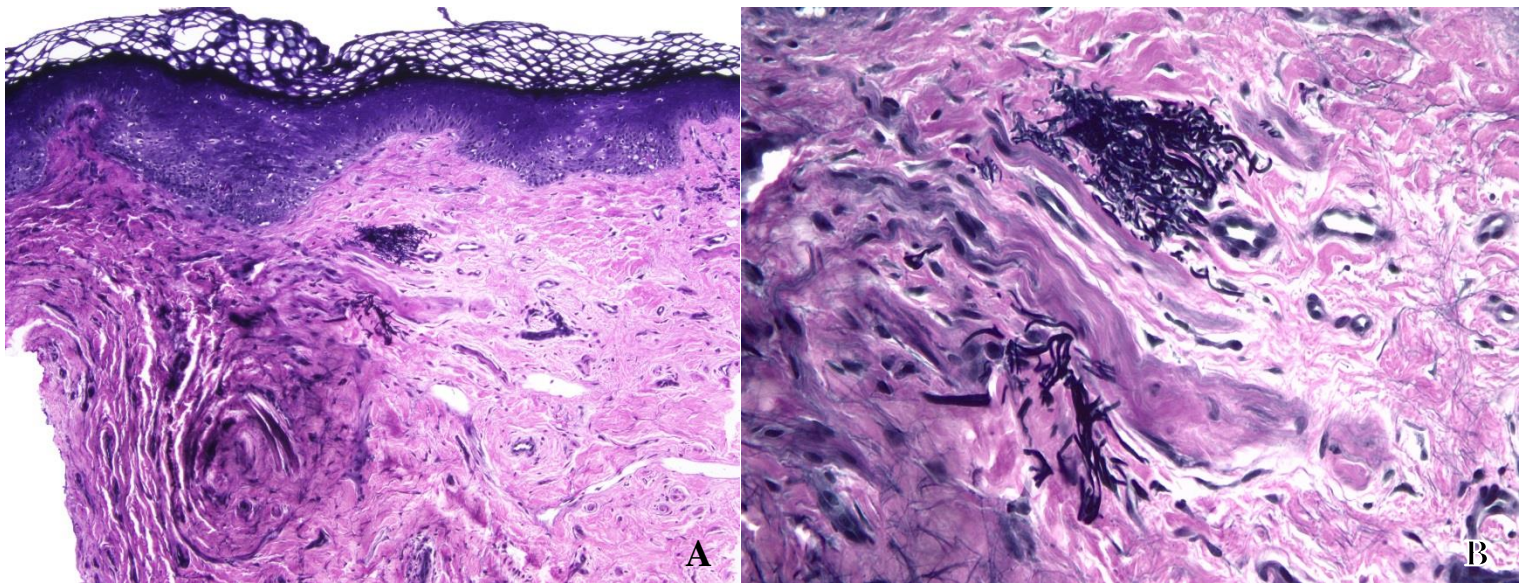


Figure 3. Low (A) and high (B) magnification views of a Verhoeff-Van Gieson stained localized cutaneous argyria macule taken from a tissue biopsy of Patient 1. The silver granules are adjacent to the black staining of elastic fibers in the dermis. [Verhoeff-Van Gieson; A = 10x, B = 40x].

Patient 2 is a 32-year-old woman who presented for evaluation of a small area of skin discoloration on her right ear. Cutaneous examination revealed a 3 x 3 millimeter blue-black colored patch on her anterior and posterior right external ear near the site of a piercing on her helix (Figure 4). The patient reported that she regularly wore silver earrings. The history and clinical presentation were highly consistent with a diagnosis of localized cutaneous argyria. She agreed to have periodic clinical follow up and her condition will be monitored for any changes.

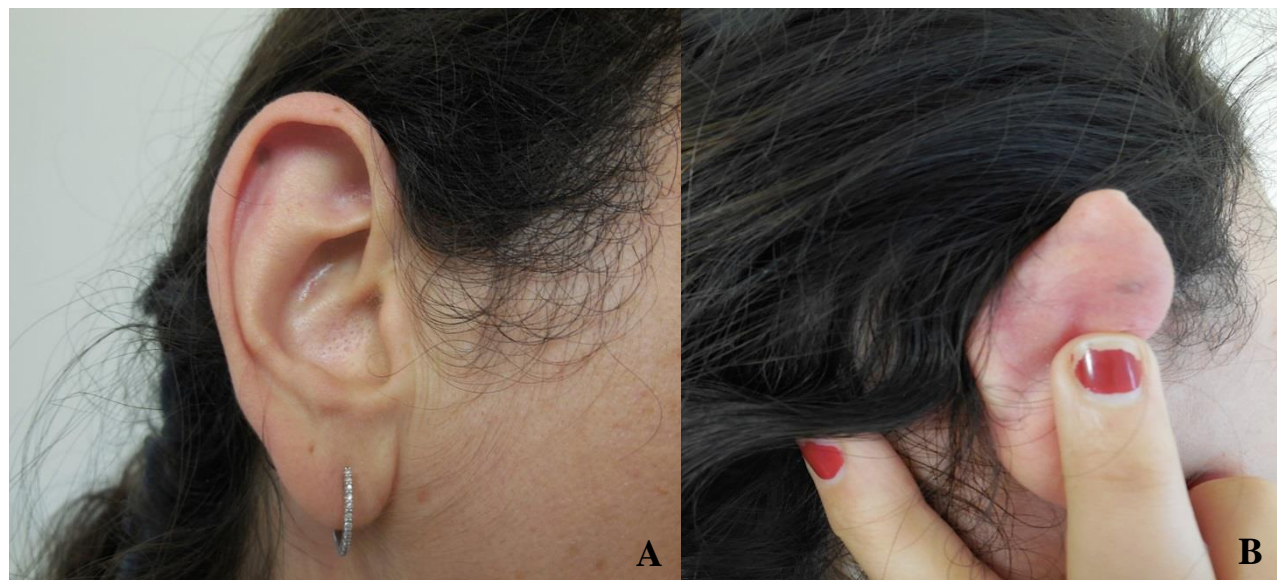

Figure 4. Anterior (A) and posterior (B) views of a 3 x 3 millimeter blue-black colored macule affecting the anterior and posterior right external ear near the site of a piercing on the helix of Patient 2.

Discussion

Argyria -- the silver-induced discoloration of skin and other body tissues -- has been recognized for hundreds of years. Indeed, the first case of argyria appeared in the medical literature in 1791 [6]. The prevalence of argyria subsequently increased throughout the 19th century, after silver nitrate was introduced as a treatment for epilepsy and wasting diseases. However, the medical use of silver salts began to decline during the late-1800s; by the turn of the century, argyria had become a rare condition that was observed almost exclusively among silversmiths and individuals who used topical silver nitrate preparations [6].

Three forms of argyria have been described in the literature: generalized argyria (formerly referred to as "argyria universalis"), argyria localis disseminata, and localized cutaneous argyria (formerly referred to as "argyria localis circumscripta").

Generalized argyria is a systemic condition characterized by extensive blue-gray discoloration of the skin and mucous membranes. It is most commonly caused by long-term ingestion of silver salts, such as colloidal silver solutions [7] and silver nitrate [8]. However, generalized argyria can also occur following exposure to aerosolized silver [9]. In addition, generalized argyria has been reported in patients using silver-containing eye drops [10] and nasal drops [11]. The blue-gray discoloration is typically most prominent in sun-exposed areas of the skin. Although skin discoloration is benign, generalized argyria has also been associated with renal impairment, thrombocytopenia, and neurological symptoms [12].

Argyria localis disseminata is an antiquated term that referred specifically to argyria caused by inhalation of aerosolized silver. It affected silversmiths and other silver workers during the 19th and early-20th centuries. Argyria localis disseminata would initially present as blue-gray discoloration on exposed areas of skin -- most commonly the hands and face -- and, in some individuals, gradually progress to generalized argyria. Aerosolized silver-related localized cutaneous argyria [13] and generalized argyria [9] still occur today. However, the term "argyria localis disseminata" is no longer used.

Localized cutaneous argyria is a local condition characterized by the development of blue-gray macules that appear on the skin following direct contact with silver. Occupational exposure is common; the condition has been reported in jewelers [5], welders [5], and silversmiths [14]. However, in similarity to our patients (Table 1), localized cutaneous argyria has also been described in individuals receiving acupuncture treatment [2] and those who routinely wear silver jewelry [1]. Although most patients report prolonged contact with silver prior to the development of localized cutaneous argyria, blue-gray discoloration may also occur after relatively brief exposure to silver metal [2]. There are no systemic symptoms associated with localized cutaneous argyria and thus treatment is rarely required.

Table 1. Characteristics of two patients with localized cutaneous argyria

Case	Age	Silver source	Site of lesion	Histology findings	Treatment
1	68	Earrings	Left and right distal helical rims and ear lobes	Yellowish-brown colored granules in dermis adjacent to elastic fibers	None
2	32	Earrings	Right ear helix	No biopsy performed	None

Localized cutaneous argyria can occur in both men and women. Individuals who have frequent contact with silver -- such as jewelers and welders -- have an increased risk of developing the condition [5]. In addition, localized cutaneous argyria has been described in patients who routinely wear silver jewelry [1]. Although there is no known ethnic predilection, blue-gray discoloration may be less apparent in dark-skinned individuals.

The distinguishing clinical feature of localized cutaneous argyria is a distinctive blue-gray or gray-colored macule or papule. The lesions are usually small. However, albeit rarely, blue-gray skin discoloration can be extensive; indeed, localized cutaneous argyria affecting the entire face and neck has been described [13]. The clinical differential diagnosis of localized cutaneous argyria is listed in Box 1 [15-18]. It includes not only local conditions, but also systemic disorders with skin lesions that may mimic localized cutaneous argyria.

Box 1. Clinical differential diagnosis of localized cutaneous argyria

Drug-related adverse effects

- Amiodarone
- Antimalarial drugs
- Chlorpromazine

Heavy-metal exposures

- Arsenic
- Bismuth
- Gold (chrysiasis)
- Mercury

Local conditions

- Blue nevus
- Melanoma *in situ*

Systemic conditions

- Cyanosis
- Hemochromatosis
- Hydrayrosis
- Malignant melanoma
- Methemoglobinemia
- Ochronosis
- Wilson disease

Localized cutaneous argyria is unique in that it occurs only after direct contact with silver or silver-containing solutions. Therefore, the diagnosis can often be established based on clinical presentation and patient history. However, a confirmatory biopsy is sometimes required, as blue-gray skin discoloration occasionally appears many months or years after exposure to silver [19]. Microscopic examination of localized cutaneous argyria lesions reveals brown-colored or black-colored silver granules in the basement membrane and dermis, most commonly surrounding eccrine glands, elastic fibers, and collagen fibrils. In addition, granular material may be present within histiocytes. The epidermis is not affected.

The mechanism of pathogenesis for localized cutaneous argyria is not fully understood. Interestingly, however, the blue-gray skin discoloration observed in both generalized and localized cutaneous argyria is most prominent in sun-exposed areas of the skin. It has therefore been postulated that a reaction between silver and light contributes to the development of argyria. Indeed, Shelley et al. observed that protein-bound silver is reduced to elemental silver upon exposure to light: "...colorless silver salts and compounds present in an inert matrix (collagen versus gelatin) are reduced by incident light to black metallic silver. This passive photosensitivity reaction leads to silver tattooing of the light-exposed skin and to photographic imaging in the film [4]." It is therefore conceivable that a reaction between dermal protein-bound silver and ambient light results in blue-gray skin discoloration. In addition, silver is known to stimulate melanocyte tyrosinase activity, which could conceivably contribute to the observed hyperpigmentation [20].

Localized cutaneous argyria is difficult to treat. Silver accumulates in the dermis and thus neither hydroquinone [21] nor dermabrasion [22] are effective in improving the cosmetic appearance of lesions. However, excellent results have recently been achieved with a low-fluence Q-switched 1064-nm Nd:YAG laser [5, 23].

Conclusion

Localized cutaneous argyria is a benign condition characterized by the development of blue-gray macules or papules that develop on the skin after direct contact with silver. It occurs primarily among individuals who are frequently exposed to silver, such as

jewelers, welders, and silversmiths. However, the condition may also affect men and women who routinely wear silver jewelry. In addition, patients being treated with silver-containing topical medications are at risk of developing localized cutaneous argyria.

Localized cutaneous argyria has a distinct clinical presentation: blue-gray or gray colored macules or papules that develop on body sites corresponding to previous silver contact. The discoloration is typically most prominent in sun-exposed areas of the skin. Histologically, localized cutaneous argyria is characterized by brown-colored or black-colored silver granules in the basement membrane and dermis, most commonly surrounding eccrine glands, elastic fibers, and collagen fibrils.

The mechanism of pathogenesis for localized cutaneous argyria is not fully understood. However, a reaction between light and dermal protein-bound silver may contribute to gray or blue-gray skin discoloration. In addition, it has been postulated that silver-induced upregulation of melanocyte tyrosinase activity contributes to the hyperpigmentation observed in argyria.

Localized cutaneous argyria is benign. Therefore, treatment is rarely necessary. However, patients who are concerned about the cosmetic features of the condition may benefit from treatment with a low-fluence Q-switched 1064-nm Nd:YAG laser.

References

1. Morton CA, Fallowfield M, Kemmett D: Localized argyria caused by silver earrings. *Br J Dermatol.* 1996;135(3):484-485. [PMID: 8949452]
2. Alés-Fernández M, Ríos-Martín JJ, Camacho-Martínez FM: Localized argyria secondary to acupuncture mimicking blue nevus. *J Drugs Dermatol.* 2010;9(8):1019-1020. [PMID: 20684156]
3. Schwieger-Briel A, Kiritsi D, Schumann H, Meiss F, Technau K, Bruckner-Tuderman L: Grey spots in a patient with dystrophic epidermolysis bullosa. *Br J Dermatol.* 2010;163(5):1124-1126. [PMID: 20545677]
4. Shelley WB, Shelley ED, Burmeister V: Argyria: the intradermal "photograph," a manifestation of passive photosensitivity. *J Am Acad Dermatol.* 1987;16(1):211-217. [PMID: 3819055]
5. Robinson-Bostom L, Pomerantz D, Wilkel C, Mader R, Lerner L, Dufresne R, Flotte T: Localized argyria with pseudo-ochronosis. *J Am Acad Dermatol.* 2002;46(2):222-227. [PMID: 11807434]
6. Buck AH, Stedman TL: Argyria. In: *A reference handbook of the medical sciences: embracing the entire range of scientific and practical medicine and allied sciences.* New York: William Wood; 1900:446-448.
7. Kim Y, Suh HS, Cha HJ, Kim SH, Jeong KS, Kim DH: A case of generalized argyria after ingestion of colloidal silver solution. *Am J Ind Med.* 2009;52(3):246-250. [PMID: 19097083]
8. Lee SM, Lee SH: Generalized argyria after habitual use of AgNO₃. *J Dermatol.* 1994;21(1):50-53. [PMID: 8157823]
9. Cho EA, Lee WS, Kim KM, Kim SY: Occupational generalized argyria after exposure to aerosolized silver. *J Dermatol.* 2008;35(11):759-760. [PMID: 19120775]
10. Nielsen IO, Kjaerbo E: Generalized argyria due to the use of eyedrops containing silver nitrate. *Ugeskr Laeger.* 1989;151(1):33-34. [PMID: 2911887]
11. Van de Voorde K, Nijsten T, Schelfhout K, Moorkens G, Lambert J: Long-term use of silver-containing nose-drops resulting in systemic argyria. *Acta Clin Belg.* 2005;60(1):33-35. [PMID: 15981703]
12. Flohr C, Heague J, Leach I, English J: Topical silver sulfadiazine-induced systemic argyria in a patient with severe generalized dystrophic epidermolysis bullosa. *Br J Dermatol.* 2008;159(3):740-741. [PMID: 18565180]
13. Tajirian AL, Campbell RM, Robinson-Bostom L: Localized argyria after exposure to aerosolized solder. *Cutis.* 2006;78(5):305-308. [PMID: 17186787]
14. Kamiya K, Yamasaki O, Tachikawa S, Iwatsuki K: Localized cutaneous argyria in a silversmith. *Eur J Dermatol.* 2013;23(1):112-113. [PMID: 23400255]
15. Enei ML, Paschoal FM, Valdés R: Argyria mimicking a blue nevus: dermoscopy features. *An Bras Dermatol.* 2013;88(3):452-455. [PMID: 23793194]
16. Utikal J, Thoeleke A, Becker JC, Figl R, Goerdts S, Schadendorf D, Ugurel S: Local cutaneous argyria mimicking melanoma metastases in a patient with disseminated melanoma. *J Am Acad Dermatol.* 2006;55(5 Suppl):S92-94. [PMID: 17052544]
17. Plewig G, Lincke H, Wolff HH: Silver-blue nails. *Acta Derm Venereol.* 1977;57(5):413-419. [PMID: 73308]
18. Kwon HB, Lee JH, Lee SH, Lee AY, Choi JS, Ahn YS: A case of argyria following colloidal silver ingestion. *Ann Dermatol.* 2009;21(3):308-310. [PMID: 20523812]
19. Takeishi E, Hirose R, Hamasaki Y, Katayama I: Localized argyria 20-years after embedding of acupuncture needles. *Eur J Dermatol.* 2002;12(6):609-611. [PMID: 12459543]
20. Buckley WR, Terhaar CJ: The skin as an excretory organ in argyria. *Trans St Johns Hosp Dermatol Soc.* 1973;59(1):39-44. [PMID: 4754563]
21. Marshall JP 2nd, Schneider RP: Systemic argyria secondary to topical silver nitrate. *Arch Dermatol.* 1977;113(8):1077-1079. [PMID: 889335]
22. Bouts BA: Images in clinical medicine. Argyria. *N Engl J Med.* 1999;340(20):1554. [PMID: 10332018]

23. Han TY, Chang HS, Lee HK, Son SJ: Successful treatment of argyria using a low-fluence Q-switched 1064-nm Nd:YAG laser. *Int J Dermatol.* 2011;50(6):751-753. [PMID: 21595676]