

UCSF

UC San Francisco Previously Published Works

Title

Bevacizumab for glioblastoma: current indications, surgical implications, and future directions.

Permalink

<https://escholarship.org/uc/item/4vv1z1nm>

Journal

Neurosurgical FOCUS, 37(6)

ISSN

1092-0684

Authors

Castro, Brandyn A
Aghi, Manish K

Publication Date

2014-12-01

DOI

10.3171/2014.9.focus14516

Peer reviewed



Published in final edited form as:

Neurosurg Focus. 2014 December ; 37(6): E9.

Bevacizumab for glioblastoma: current indications, surgical implications, and future directions

Brandyn A. Castro, B.A. and Manish K. Aghi, M.D., Ph.D.

Department of Neurological Surgery, University of California, San Francisco, California

Abstract

Initial enthusiasm after promising Phase II trials for treating recurrent glioblastomas with the antiangiogenic drug bevacizumab—a neutralizing antibody targeting vascular endothelial growth factor—was tempered by recent Phase III trials showing no efficacy for treating newly diagnosed glioblastomas. As a result, there is uncertainty about the appropriate indications for the use of bevacizumab in glioblastoma treatment. There are also concerns about the effects of bevacizumab on wound healing that neurosurgeons must be aware of. In addition, biochemical evidence suggests a percentage of tumors treated with bevacizumab for an extended period of time will undergo transformation into a more biologically aggressive and invasive phenotype with a particularly poor prognosis. Despite these concerns, there remain numerous examples of radiological and clinical improvement after bevacizumab treatment, particularly in patients with recurrent glioblastoma with limited therapeutic options. In this paper, the authors review clinical results with bevacizumab for glioblastoma treatment to date, ongoing trials designed to address unanswered questions, current clinical indications based on existing data, neurosurgical implications of bevacizumab use in patients with glioblastoma, the current scientific understanding of the tumor response to short- and long-term bevacizumab treatment, and future studies that will need to be undertaken to enable this treatment to fulfill its therapeutic promise for glioblastoma.

Keywords

bevacizumab; Avastin; anti-angiogenic; glioblastoma

Despite aggressive management with surgery, chemotherapy, and radiation at the time of diagnosis, and continued aggressive treatment with surgery and novel chemotherapy regimens at recurrence, the prognosis for glioblastoma, although improved compared with less than a decade earlier,⁷⁷ remains poor at just shy of 2 years.²¹ Conventional DNA-damaging chemotherapies may exhibit limited duration of efficacy due to the emergence of mutations promoting drug resistance.⁵⁷ The highly vascular nature of glioblastomas makes

Address correspondence to: Manish K. Aghi, M.D., Ph.D., Department of Neurological Surgery, University of California, San Francisco, 505 Parnassus Ave., Rm. M779, San Francisco, CA 94143. aghim@neurosurg.ucsf.edu.

Disclosure

Some of the research described in this report was funded by an NIH R01 grant to Dr. Aghi (no. 5R01NS079697). Brandyn A. Castro is a Howard Hughes Medical Institute Medical Research Fellow.

Author contributions to the study and manuscript preparation include the following. Conception and design: Castro. Acquisition of data: Castro. Drafting the article: Castro. Critically revising the article: both authors. Reviewed submitted version of manuscript: both authors. Approved the final version of the manuscript on behalf of both authors: Aghi.

them a prime target for treatment with antiangiogenic agents such as the humanized anti-vascular endothelial growth factor (VEGF) antibody bevacizumab (Avastin), which inhibits angiogenesis by neutralizing VEGF-A and prevents its interaction with VEGF receptors VEGFR1 and VEGFR2.⁵⁸ In this paper we review the preclinical evidence that led to the use of bevacizumab in glioblastoma, clinical trial results with bevacizumab and other antiangiogenic therapies for glioblastoma, the current scientific understanding of the tumor response to bevacizumab treatment, current clinical indications of bevacizumab for glioblastoma based on existing data, and future studies that will need to be undertaken to enable this drug to fulfill its therapeutic promise for glioblastoma.

Methods

An initial broad search on bevacizumab therapy in glioblastoma was performed. In this search, the phrase “bevacizumab and glioblastoma” was used as a search term in PubMed and Web of Science for all years up to 2014, and articles containing these terms were sorted based on relevance, most cited, and newest publication date. This search returned multiple articles, providing a general overview of the most current and pivotal studies in the literature to date on bevacizumab treatment in glioblastoma. Subsequently, a systematic search was performed. The phrases “(phase I–III) and bevacizumab and glioblastoma,” “recurrent and bevacizumab and glioblastoma,” “newly diagnosed and bevacizumab and glioblastoma,” and “safety and bevacizumab and glioblastoma” were used as search terms in PubMed and Web of Science for all years up to 2014 to identify all prospective trials of bevacizumab monotherapy and combination therapy in glioblastoma to date. References of systematic reviews were assessed for additional key information including ongoing bevacizumab trials and unpublished preliminary studies presented at recent conferences around the world. The inclusion criteria used for this review were prospective Phase I–III trials using bevacizumab as therapy at the time of diagnosis or at recurrence in patients with glioblastoma. Trials examining the use of bevacizumab in unresectable tumors were also included. Articles excluded from this study were case series and articles written in languages other than English. A total of 90 articles were included in this review.

Bevacizumab for Glioblastoma: Preclinical Evidence

With tumoral VEGF-A levels approximately 30-fold higher in patients with glioblastoma compared with lower-grade astrocytomas, VEGF is recognized as a particularly important factor in the vascularity of glioblastomas.⁶¹ Tumor cells serve as the major source of VEGF while tumor-associated stroma has also been determined to be a notable site of VEGF production.²⁹ The expression of VEGF in glioblastomas is associated with a poor prognosis and has been shown to contribute to their treatment refractoriness.^{29,47,80}

It was first shown as far back as 1993 that a monoclonal antibody specific to VEGF suppressed the growth of many human tumor lines including glioblastoma in athymic mice, emphasizing that VEGF is an important mediator of tumor angiogenesis in glioblastoma.^{47,69} Similarly, VEGF-A specific inactivation through the introduction of inhibitory RNA into tumor cells was shown in 1996 to inhibit glioblastoma angiogenicity and tumorigenicity.¹⁸ This study provided additional valuable evidence that VEGF plays a

critical role in the pathogenesis of glioblastomas in vivo and targeting it may provide therapeutic benefit in patients by suppressing tumor angiogenesis.¹⁸ The murine antibody to VEGF used in the initial in vivo studies, A.4.6.1, was “humanized” by Presta and colleagues in 1997, resulting in the drug bevacizumab.⁶⁶ Phase I safety and pharmacokinetic testing in 2001 determined that bevacizumab had a low toxicity profile, did not induce antibodies to itself, and had a terminal elimination half-life of approximately 21 days.⁴⁰

Bevacizumab for Recurrent Glioblastoma: Results to Date

In 1997, 8 years after their scientists discovered VEGF, Genentech began testing bevacizumab in patients with cancer. Bevacizumab was shown to provide therapeutic and survival benefit in rectal cell cancer and metastatic renal cancer,^{85,86,89} but safety concerns about the risk of stroke and intracerebral hemorrhage had led investigators to delay studying bevacizumab for glioblastoma. In 2004, at a time when bevacizumab was only approved for the treatment of colon cancer, the spouse of a patient with glioblastoma in Texas conducted some research and uncovered much of the preclinical evidence described above suggesting increased VEGF production by glioblastoma. This spouse asked his wife’s oncologist, Dr. Virginia Stark-Vance, a private practitioner, to prescribe the drug for his wife.⁴⁸ Dr. Stark-Vance agreed to do so in combination with the topoisomerase inhibitor irinotecan, as long as the patient received the drug as an inpatient so that she could be closely monitored for intracranial hemorrhage. A successful radiological response led Dr. Stark-Vance to later treat 21 patients with high-grade glioma using bevacizumab in addition to irinotecan in a Phase I trial, the first study to confirm the safety of bevacizumab treatment for recurrent glioblastoma. Results of this trial were presented at the 2005 meeting of the European Association of Neuro-Oncology.⁷⁵ In addition to fulfilling its primary goal of demonstrating the safety of bevacizumab treatment for glioblastoma, this study also showed a promising response rate of 43% in the small series of 21 patients (including 11 glioblastomas and 10 anaplastic astrocytomas) treated in this trial.⁷⁵ This study paved the way for the first Phase II trials examining the efficacy of this bevacizumab-irinotecan combination in recurrent glioblastoma treatment. Results published in 2007 showed improved 6-month progression-free survival (PFS) of 30%–46%,^{79,80} compared with rates in historic controls of 9%–21% (Table 1).^{4,42,53,84,90}

Studies that soon followed, whose results were published in 2009 (Table 1), examined the use of bevacizumab as monotherapy for tumor recurrence, yielding promising results in Phase II trials, with 6-month PFS of 29%–43% and overall response rate of 28%,^{33,49,60} values far exceeding the rates using historical glioblastoma treatments such as radiation therapy and other chemotherapeutic regimens of 9%–21% and 4%–9% ($p = 0.017$), respectively.^{4,42,53,84,90} Patients exhibited a radiological response rate of 71% based on Levin criteria and 35% based on Macdonald criteria.⁴⁹ On May 6, 2009, based on the results of these Phase II clinical trials showing efficacy of bevacizumab as monotherapy for recurrent glioblastomas,^{33,49} it was granted accelerated FDA approval for recurrent glioblastoma, making bevacizumab the third FDA-approved treatment for glioblastoma in nearly 4 decades after implantable carmustine wafers and temozolomide. Unlike those 2 agents, the approval of bevacizumab was designated as accelerated because it was approved without the completion of a randomized Phase III trial.²⁴

Bevacizumab in Combination With Other Agents for Recurrent Glioblastoma

Many believe that while the multiple targets of VEGFR inhibitors render them effective as monotherapy, VEGF-targeted treatments such as bevacizumab will be most effective in combination with other agents.

The topoisomerase I inhibitor irinotecan does not exert a strong antitumoral effect as monotherapy in patients with glioblastoma, with response rates of 0%–17%,^{16,23,32,65} similar to rates of other glioblastoma-targeting chemotherapeutic agents at the time the study was published. Concurrent use of irinotecan with bevacizumab in the above Phase II trials has shown increased 6-month PFS (38%–50.3%) and 6-month overall survival (72%–77%).^{33,79,80} Theories of explanation for this synergistic effect involve increased uptake of irinotecan into the CNS secondary to bevacizumab and/or the ability of irinotecan to target differentiated tumor cells while bevacizumab targets glioma stem cells.⁵ Progression-free survival was 29% with bevacizumab monotherapy at recurrence compared with 46% with bevacizumab plus irinotecan combination therapy.^{49,80} The Macdonald criteria yielded response rates of 35% for bevacizumab monotherapy and 57% for dual therapy,^{49,80} suggesting a benefit to the addition of irinotecan. The addition of temozolomide to bevacizumab treatment at recurrence in 32 patients yielded less promising results than bevacizumab monotherapy and bevacizumab plus irinotecan: 6-month PFS of 18.8%, median PFS of 15.8 weeks, 6-month overall survival of 62.5%, and median overall survival of 37 weeks.²⁸

Sorafenib, an inhibitor of tyrosine protein kinases VEGFR, platelet-derived growth factor receptor (PDGFR), and Raf kinase, was shown to exhibit antitumoral effects in gliomas in preclinical studies.⁷³ As a single agent, however, it has only modest activity, so it was used in combination with bevacizumab to generate a stronger mechanism of inhibition of the VEGF/VEGFR axis.⁵⁹ The addition of sorafenib did not significantly improve outcomes such as 6-month PFS (17%–26% compared with 18% with bevacizumab monotherapy or historic controls), potentially because of its limited ability to penetrate the blood-brain barrier.^{31,34} Sorafenib is not currently recommended as an option for combination therapy with bevacizumab.

The addition of carboplatin, carmustine, lomustine, fotemustine, erlotinib, and etoposide to bevacizumab in recurrent glioblastoma treatment has provided minimal added benefit while contributing to potential side effects.^{14,34,78}

Bevacizumab for Newly Diagnosed Glioblastoma: Results to Date

The logical next step in determining the full therapeutic spectrum of bevacizumab in patients with glioblastoma, once it was determined that there was a benefit at tumor recurrence, was to test the drug earlier in the course of the disease. Phase II trials using the drug at the time of diagnosis, in addition to the standard Stupp protocol, resulted in minimal to no additional benefit to median overall survival: 19.6–23 months^{51,61} with bevacizumab plus the Stupp protocol compared to 14.6–21.1 months^{51,76} using the Stupp protocol alone (Table 1). These

studies did, however, show a benefit of bevacizumab at diagnosis when observing median PFS of 13–13.6 months,^{51,61} compared with 6.9 months with the standard Stupp protocol alone.⁷⁶ This benefit is further supported with the observed 6-month PFS rate of 85%–88%,^{51,61} a value far exceeding the 53.9% noted with the standard Stupp protocol.⁷⁷ These Phase II trials using bevacizumab at diagnosis were initially promising, with beneficial results in 6-month PFS and median PFS, but there was no significant improvement in overall survival in these patients.

These findings were further corroborated in two Phase III trials, the Avastin in Glioblastoma (AVAglio) trial and the Radiation Therapy Oncology Group (RTOG) 0825 trial (Table 1). The AVAglio Phase III trial resulted in improved median PFS with bevacizumab, i.e., 10.6 months compared with 6.2 months with placebo ($p < 0.001$).¹⁹ Overall survival was higher in the bevacizumab group 1 year after initiation of treatment (72.4% vs 66.3%, respectively; $p < 0.049$), but this difference faded at 2 years (33.9% vs 30.1%, respectively; $p = 0.24$). Median overall survival was 16.8 months in the bevacizumab group compared with 16.7 months in the placebo group ($p = 0.10$).¹⁹

The RTOG 0825 Phase III trial noted a similar trend. The addition of bevacizumab resulted in an increase in median PFS to 10.7 months compared with 7.3 months in the placebo group ($p = 0.007$).³⁶ There was no significant difference in median overall survival observed with the addition of bevacizumab, i.e., 15.7 months compared with 16.1 months with placebo ($p = 0.21$).³⁶ These Phase III trials confirmed the trend noted in Phase II trials that using bevacizumab at the time of diagnosis has a favorable PFS outcome but fails to show benefits in overall survival.

The addition of bevacizumab to the Stupp protocol at diagnosis improved baseline quality of life and performance measures. Karnofsky Performance Scale scores remained above 70 for 9 months in the bevacizumab group and 6 months in the placebo group.¹⁹ Performance status was maintained in the bevacizumab group for a median of 9 months compared with 5.5 months in the placebo group ($p < 0.001$). Time to clinical deterioration was 14.2 months in the bevacizumab group, significantly longer than 11.8 months with placebo ($p = 0.02$). Patients receiving bevacizumab did have a lower glucocorticoid requirement.¹⁹ In summary, although the addition of bevacizumab to the standard treatment protocol at the time of glioblastoma diagnosis showed promising results in PFS and some clinical outcome measures, overall survival remained unchanged, verifying the limited additional benefit to bevacizumab use earlier in the course of the disease.

Beyond Bevacizumab: Other Antiangiogenic Therapies for Glioblastoma

Antiangiogenic agents other than bevacizumab have also been studied in the treatment of recurrent glioblastoma. Bevacizumab targets VEGF-A, without any neutralizing effects on other members of the VEGF gene family including VEGF-B, -C, or -D.⁶² Aflibercept, or VEGF Trap, is a recombinantly produced fusion protein that contains regions from the extracellular domains of VEGF receptors, which will bind to and neutralize isomers of VEGF-A, VEGF-B, and placental growth factor, another angiogenic factor. Aflibercept prevents VEGF from initiating proliferation and migration of vascular endothelial cells.²⁶ A

Phase II study indicated minimal evidence of single-agent activity with moderate toxicity in recurrent glioblastoma, with median PFS of 2.8 months and median overall survival of 9 months.²⁶

Numerous receptor tyrosine kinase inhibitors (RTKIs) can exert antiangiogenic agents by targeting the VEGF receptors. These agents are believed to be more effective than bevacizumab as monotherapy due to their ability to target other receptor tyrosine kinases outside of the VEGF pathway. The most frequently studied antiangiogenic RTKI in glioblastoma is cediranib, an oral agent targeting all 3 VEGF receptors (1, 2, and 3) as well as PDGFR and c-kit.^{8,81} Phase II trials of cediranib in recurrent glioblastoma resulted in a median PFS of 3.8 months and median overall survival of 7.5 months,⁶ values that exceed the values in historical controls of 1.8–2.1 months and 5–5.8 months, respectively.^{4,88} Advantages of cediranib over bevacizumab include oral bioavailability and a shorter half-life of 22 hours compared with 21 days with bevacizumab, which allow for rapid clearance of the drug should toxicities arise.⁶ Unfortunately, in a randomized Phase III trial, there were no differences in PFS between patients with recurrent glioblastoma receiving lomustine, cediranib, or the combination of lomustine plus cediranib.⁷

Additional RTKIs with antiangiogenic effects that have been studied for glioblastoma include sorafenib, sunitinib, pazopanib, vandetanib, axitinib, and XL184.⁷² Bevacizumab is sometimes used as salvage therapy for patients who progress on these RTKIs.^{39,72} While the overall efficacy of bevacizumab to treat glioblastoma is believed to be superior to these agents, side by side comparisons have not been made in clinical trials.

Management of Recurrent Glioblastoma: Surgery, Bevacizumab, or Both?

A common decision that patients and providers have to make in the setting of recurrent glioblastoma is the choice between surgery, bevacizumab treatment, or surgery followed by bevacizumab treatment. Several studies have attempted to define the role of surgery in the management of recurrent glioblastoma. One study suggests no additional benefit of surgery at recurrence, indicating that PFS at 6 months and overall survival were comparable between groups with and without resection at the time of tumor progression.²² Others argue that there is a survival benefit with surgery at progression, assuming a minimum extent of resection (EOR) is achieved. The first study to rigorously quantify EOR retrospectively analyzed 416 patients with glioblastoma, 183 recurrent and 233 newly diagnosed, to find a significant survival advantage in patients who received greater than 98% tumor volume resection versus less than 98%, with median survival of 13 months and 8.8 months, respectively ($p = 0.0001$), and no significant difference between the new versus recurrent or residual disease.⁵⁰ A more recent 2011 study defined the EOR threshold as being slightly lower, determining that significantly prolonged survival was noted in newly diagnosed patients with as little as 78% EOR, with an increase in survival benefit as EOR increases.⁷⁰ A year later, Bloch et al. opted for a more stratified approach to EOR because of the subjective nature of volumetric calculations. In that study, when 107 patients with recurrent glioblastoma were stratified into gross-total resection ($> 95\%$ tumor volume removal) versus subtotal resection ($< 95\%$ tumor volume removal), patients who received gross-total resection had a longer duration of

survival (20 months vs 16.6 months, respectively; $p = 0.01$).⁹ Obtaining gross-total resection at recurrence maximizes survival, regardless of initial EOR.^{9,22}

To date, no study has investigated the cytoreductive interaction between surgery and postoperative bevacizumab. It remains unclear if the small amount of residual enhancing tumor after a successful surgery is the ideal candidate for bevacizumab treatment, or if the drug is better used to treat robustly enhancing solid masses that have not undergone surgery. We do know that the side effects of bevacizumab treatment can interact with the postsurgical state, particularly hypertension, thromboembolic events, impaired wound healing, and intracranial hemorrhage. To minimize adverse outcomes, patients with intracranial hemorrhage on imaging are not candidates for bevacizumab therapy. In one study of bevacizumab and irinotecan in recurrent glioblastomas, after patients with intracranial hemorrhage were excluded, no patient developed this complication after treatment was initiated.⁷⁹ Ensuring tight blood pressure control in all patients taking bevacizumab, by conservative or pharmacological means, is also important to decrease the risks of bevacizumab-induced hypertension and associated intracranial hemorrhage. Despite these risks, the numerous examples of bevacizumab responsiveness observed when the drug is used to treat postoperative residual glioblastoma justify the role of combining surgery with postoperative bevacizumab in recurrent glioblastoma treatment (Fig. 1), as long as the providers closely monitor the patient for signs of recurrence during treatment using modern criteria for recurrence such as the Response Assessment in Neuro-Oncology (RANO) criteria.⁸³

Bevacizumab for Unresectable Glioblastoma

All patients in the studies mentioned to this point underwent tumor resection as a prerequisite for inclusion in the studies. Patients with unresectable glioblastomas have a poor prognosis, with an average survival of 6–10 months,⁵⁴ and several studies have examined the role for bevacizumab treatment of unresectable glioblastoma. Neoadjuvant therapy with bevacizumab plus temozolomide in patients with unresectable glioblastomas is believed to provide a significant amount of disease stabilization and may yield an improved responsiveness to ionizing radiation due to improved tumor oxygenation, but there is some debate on the benefit to this additional therapy.^{54,56} Results of a Phase II trial by Lou et al.⁵⁴ in 41 patients with unresectable glioblastomas treated with temozolomide plus bevacizumab at the time of diagnosis supports the theory that bevacizumab provides added benefit to this patient population (Table 1). Results of PFS appear promising, indicating a median PFS of 5.6 months in this study in which all of the cases were unresectable glioblastomas,⁵⁴ an improvement from 4.6 months and 3.7 months in studies with 54% and 91.4% unresectable glioblastomas, respectively.^{35,52} Median survival was 11.7 months in this study, which initially appears beneficial compared with median survival in previous studies of 7.9 months with radiation therapy alone,⁷⁷ 5.7 months for temozolomide alone,³⁵ and 9.4 months for temozolomide plus radiation therapy.⁷⁷ However, the subsequent Phase II trial TEMAVIR (TEMozolomideAVastinIRinotecan) yielded contradictory results, indicating no additional benefit of bevacizumab plus irinotecan for unresectable glioblastoma compared with standard therapy with temozolomide plus radiation. Results showed improved 6-month PFS and median PFS, but overall survival was comparable between the 2 groups (Table 1),

leading the authors to suggest that further evaluation of bevacizumab plus irinotecan as neoadjuvant and adjuvant therapy to traditional temozolomide and radiation therapy is not warranted in the population with unresectable glioblastoma. The median overall survival of 11.1 months in both arms of the TEMAVIR study are comparable to the seemingly beneficial 11.7 months in the study of Lou et al.,⁵⁴ suggesting that additional studies are warranted to determine the benefit of the addition of bevacizumab in the population with unresectable glioblastoma.

Adverse Effects of Bevacizumab in Glioblastoma and Their Neurosurgical Implications

Treatment with bevacizumab has been associated with a number of side effects. For example, in the 2009 monotherapy trial of Kreisl et al., these side effects included fatigue (45%), headache (37%), hypertension (30%), nose bleeds (19%), proteinuria (5%), arterial thromboembolism (5%), venous thromboembolism (4%), impaired craniotomy wound healing (2%), and intracranial hemorrhage (2%).⁴⁹ Given these side effects, patients should be risk profiled by screening for hypertension and hyperlipidemia prior to initiating therapy with bevacizumab.¹⁸ VEGF normally lowers blood pressure by phosphorylating endothelial nitric oxide synthase, thereby reducing plasminogen activator inhibitor-1 expression. Inhibition of this pathway during bevacizumab-induced VEGF blockade leads to the hypertension associated with the drug.⁴⁵ Because of this mechanism, angiotensin converting enzyme (ACE) inhibitors are often effective in treating bevacizumab-induced hypertension.⁴⁵ Patients currently undergoing bevacizumab treatment should be monitored for intracranial hemorrhage, bowel perforation, cardiac failure, wound dehiscence, and stroke, as all of these are indications for discontinuing bevacizumab therapy.¹⁴

The wound healing complications reported by Kreisl et al. and others were further investigated by Clark et al. in a retrospective study in which preoperative treatment with bevacizumab in 23 patients led to higher rates of wound healing complications when compared with a group of 168 patients who did not receive bevacizumab (35% vs 10%, respectively; $p = 0.004$).²⁰ Wound healing complications included infection, dehiscence, CSF leakage, pseudomeningocele formation, or osteomyelitis. This study, however, observed no significant difference in wound healing in patients treated with bevacizumab postoperatively.²⁰ Interestingly, this study also reported higher rates of perioperative seizure in patients who were receiving bevacizumab preoperatively compared with those who were bevacizumab-naïve at the time of surgery.²⁰ The combination of increased perioperative seizures and wound healing complications made the overall morbidity higher in patients receiving preoperative bevacizumab than patients who never received bevacizumab or patients who received bevacizumab postoperatively.²⁰ Clark et al. concluded by recommending cessation of bevacizumab therapy for at least 4 weeks prior to surgery and accepting the risk of complications for patients in whom surgery cannot wait, but ideally waiting 6 weeks if possible, and not starting or restarting bevacizumab until 4 weeks postoperatively or longer for slower-healing craniotomy wounds.²⁰

Several studies have suggested that bevacizumab may exert different side effects when used in combination with other agents compared with monotherapy. In one of the Phase III trials in newly diagnosed glioblastoma, the addition of bevacizumab to the Stupp protocol (radiation plus temozolomide) at diagnosis increased the incidences of thrombocytopenia and neutropenia during the chemoradiation therapy phase (10.2% and 7.3%, respectively) relative to patients receiving the Stupp protocol alone (7.7% and 3.7%, respectively).³⁶ During the maintenance phase, the following side effects occurred at a higher rate with bevacizumab combined with radiation and temozolomide at diagnosis, compared with the Stupp protocol alone: fatigue (13.1% vs 9.0%), neutropenia (10.0% vs 5.1%), thromboembolic disease (7.7% vs 4.7%), hypertension (4.2% vs 0.9%), wound dehiscence (1.5% vs 0.9%), serious hemorrhage (1.5% vs 0.9%), and visceral perforation (1.2% vs 0.4%).³⁶ Hypertension appears more commonly with monotherapy than with studies using combination therapy, while thromboembolic events occur more commonly with combination therapy than with monotherapy.¹⁵

There have been concerns of rebound recurrence upon the discontinuation of bevacizumab therapy, such as when side effects occur. Through a retrospective analysis of 82 patients with glioblastoma who received bevacizumab therapy for at least 6 months, it was determined that if the drug was stopped for reasons other than tumor progression, they were not at increased risk of rebound recurrence or worse PFS.³ In fact, patients whose bevacizumab was stopped for reasons other than progression had improved median PFS and 6-month PFS after salvage therapy (23 weeks and 47%, respectively), compared with patients who discontinued bevacizumab for tumor progression and underwent salvage therapy (9 weeks and 5%, respectively).³ Rebound recurrence is thus not a considerable risk in patients who discontinue bevacizumab therapy for reasons other than tumor progression.

Scientific Studies of Bevacizumab Delivery and Resistance in Glioblastoma

To improve the efficacy of bevacizumab in glioblastoma, several researchers have looked into how the drug is delivered. First, the way in which the drug is dosed emerged from the notion that the maximum tolerable dose may also be the most effective dose. But this notion, which was developed with the use of DNA-damaging chemotherapy, may not be applicable to antiangiogenic therapy, as suggested by a meta-analysis of recurrent glioblastoma studies that could not detect a difference in efficacy between 5 mg/kg versus 10 mg/kg of bevacizumab dosed every 2 weeks.⁸⁷ Second, some investigators have looked into intraarterial delivery of bevacizumab as a way of improving intratumoral uptake of the drug and reducing systemic side effects.¹² Third, others have investigated the creation of liposomal-encapsulated bevacizumab as a way of prolonging the residency of bevacizumab in target tissue, although this approach has yet to be tried in glioblastoma.¹

Unfortunately the response of patients with glioblastoma to bevacizumab may be short-lived, and these patients may experience disease progression while receiving bevacizumab, at rates approaching 40%.⁷⁹ In some studies, as many as half of the glioblastomas progressing during bevacizumab treatment have exhibited significant FLAIR bright nonenhancing imaging changes, and these glioblastomas have been proven to contain infiltrating tumor cells (Fig. 1).²⁷ This pattern of progression has led to an effort to revise definitions of

progression in clinical trials and practice, as put forth by the RANO working group.⁸³ Genes associated with this nonenhancing tumor progression after bevacizumab therapy are known to promote migration through the extracellular matrix and include integrin $\alpha 5$ (*ITGA5*), fibronectin 1 (*FNI*), neurotrophin 3 (*NTF3*), *PDGFR β* , and *CXCL12*.²⁷

The ability of glioblastoma to progress during bevacizumab treatment suggests that the tumor may have the ability to adapt and fuel its blood supply without using VEGF-A, the member of the VEGF family that bevacizumab directly targets. Proposed mechanisms for this adaptive resistance include upregulation of alternative proangiogenic pathways mediated by factors such as basic fibroblast growth factor, recruitment of bone marrow-derived cells, increased invasion of surrounding brain, and alteration of vascular architecture.^{13,27,45,46} While the specificity of bevacizumab for VEGF-A has been the basis for the suggestion that upregulation of other VEGF isoforms (such as VEGF-B, VEGF-C, or VEGF-D) could compensate for VEGF-A blockade induced by bevacizumab, no data have suggested upregulation of these factors and they are not as potent at mediating angiogenesis as VEGF-A. Reported changes in bevacizumab-resistant glioblastomas that have shed light on specific mediators of bevacizumab resistance include increased expression and/or activation of invasion-mediating $\beta 1$ -integrin,¹³ invasion-mediating receptor tyrosine kinase c-Met,⁴⁶ mediators of hypoxia-induced autophagy such as *BNIP3*,⁴⁴ and signal transducer and activator of transcription 3 (*STAT3*), a downstream mediator of signaling from many of these factors.²⁵

Bevacizumab-resistant glioblastomas have a particularly poor prognosis.²¹ Given the aggressive nature of glioblastomas, once they become resistant to bevacizumab, identifying radiological or serum biomarkers predicting resistance before it becomes entrenched will be particularly important.⁴⁵ Along those lines, biomarkers predicting strong responders to bevacizumab will also be important to identify, as there are numerous examples of dramatic response of recurrent glioblastoma to bevacizumab treatment (Fig. 1). Examples of biomarkers that have been investigated in clinical studies of patients with glioblastoma include VEGF, CA9, Ktrans, and microvessel density, all of which have been shown to predict response to bevacizumab, while diffusion-weighted MR imaging has been studied as a biomarker of bevacizumab resistance.⁴⁵ Identification of these biomarkers is particularly important because of the high cost of bevacizumab treatment (which can approach \$100,000 a year).⁷¹ This provides an added level of importance to avoiding an expensive treatment that may never be effective for a particular tumor or being able to stop treatment in a timely fashion once efficacy is unlikely to continue and increased tumor aggressiveness may be about to occur in the face of continued treatment. The National Institute for Health and Clinical Excellence in the United Kingdom no longer pays for several antiangiogenic agents approved in the US because of the high cost to benefit ratio.⁷⁴

Identifying and Treating Bevacizumab Progression in Glioblastoma

In addition to the need to use RANO criteria to evaluate radiological progression during bevacizumab treatment, it is important to be aware of the multiple patterns of progression that can occur during bevacizumab treatment, which have been described by Pope and colleagues as local, distant, diffuse, or multifocal.⁶⁴

The median overall survival of patients with glioblastomas after progression during bevacizumab therapy is 3.8 months.⁵⁵ These patients can undergo additional surgical debulking therapy, but given that progression after bevacizumab therapy is often nonenhancing and/or disseminated, this may not always be a feasible option.^{10,27}

Some investigators have looked at repeat radiation therapy as a treatment option for patients with glioblastoma who experience tumor progression while receiving bevacizumab. Repeat fractionated radiation therapy is a well-tolerated, feasible option for large volume recurrences not amenable to stereotactic radiosurgery. In one study, large-volume repeat fractionated radiation therapy was performed on 23 patients, initiated within 7–14 days of bevacizumab failure, and given with 2 cycles of concurrent bevacizumab therapy. Results from this study indicated an improved median overall survival and 6-month overall survival of 6.9 months and 65%, respectively.⁵⁵

NovoTTF-100A is a noninvasive mechanism using surface electrodes to deliver dynamic electric wavelike fields, called tumor treating fields (TTFs), to the tumor to slow or stop recurrent tumor cells from dividing.⁴¹ In a cohort of 43 patients, use of NovoTTF-100A after bevacizumab failure led to improved outcomes, with a median overall survival of 3.1 months in the chemotherapy arm, compared with 6.3 months in the NovoTTF-100A arm.⁶⁷

Despite strong preclinical evidence supporting a role for c-Met in bevacizumab resistance, the c-Met inhibitor XL184 proved particularly ineffective against glioblastomas that previously progressed during bevacizumab treatment in a Phase II clinical trial.⁸²

In a retrospective analysis of 5 Phase II trials, 55 patients who received continuous bevacizumab after initial failure of the drug had improved median overall survival of 5.9 months and 6-month PFS of 49.2% compared with patients who received treatment with other salvage chemotherapies (median overall survival 4 months and 6-month PFS of 29.5%, $p = 0.014$), and those who received palliative care only (median survival 1.5 months).⁶⁸ This study indicated that bevacizumab continuation was an independent prognostic factor of improved overall survival and supported the counterintuitive notion that continued treatment with the agent after signs of radiological progression might be a viable option for these patients. The authors of this study suggested that cessation of bevacizumab secondary to tumor progression is more likely to lead to diffuse, distant, or multifocal patterns of tumor progression, as opposed to the local trends observed in patients whose therapy is discontinued for other reasons such as side effects.³ Further study will be needed to determine the validity of this approach.

Relative to the median overall survival of 3.8 months after progression during bevacizumab therapy, deduced from a large cohort of patients participating in 16 Phase II trials ($n = 995$),⁵⁵ large-volume repeat radiation therapy for bevacizumab-resistant glioblastoma improved this median overall survival by 3.1 months,⁵⁵ NovoTTF-100A by 2.5 months,⁶⁷ and bevacizumab continuation by 2.1 months,⁶⁸ while no benefit was observed with the c-Met inhibitor XL184 or other salvage chemotherapeutic agents.^{55,82} In addition, repeat radiation may have considerable cost-benefit when compared with NovoTTF-100A, which is anticipated to cost \$10,000–\$15,000 per month.⁵⁵ Additional studies are warranted to

determine the optimal treatment for patients exhibiting progression of glioblastoma during bevacizumab treatment.

Bevacizumab Treatment in Glioblastoma: Current Clinical Indications

At present, the results of the recent Phase III trials in newly diagnosed glioblastoma have called into question the clinical indications for bevacizumab in glioblastoma treatment. For now, the accelerated FDA approval for bevacizumab in the treatment of recurrent glioblastoma remains, with ongoing randomized trials for recurrent glioblastoma in Europe likely to shed light on this indication in the near future. In the recurrent setting, bevacizumab can be used as monotherapy or in combination with other chemotherapy, irinotecan in particular (Table 2). We also know that deferred use of bevacizumab does not diminish efficacy in patients with glioblastoma, indicating that the drug can be considered at any point in the course of disease progression.⁶³ In a recent study, overall survival and PFS after bevacizumab initiation was similar whether treatment was begun after the first, second, or third recurrence.⁶³ These findings are supported by previous studies, which collectively have reported median overall survival ranges after bevacizumab initiation to be 8.4–9.1 months when used after first recurrence and 7–9.3 months when used after second recurrence.^{33,49,63}

Patients with glioblastoma receiving bevacizumab treatment have been successfully managed on reduced doses of dexamethasone, possibly due to the reduction in cerebral edema noted in these patients.⁴⁹ Lower dosages of concurrent corticosteroid usage are also recommended, given that response rates to bevacizumab are lowered by the drug.^{33,60} Younger patients tend to have more favorable outcomes (PFS and overall survival) and lower potential for suffering adverse consequences from side effects and may therefore be more optimal candidates for bevacizumab treatment.⁶⁰

The Future of Bevacizumab for Glioblastoma Treatment

The recently completed Phase III trials suggest that bevacizumab should not be incorporated into the Stupp protocol at the time of diagnosis. Definitive evidence for the role of the drug in treating recurrent glioblastoma will emerge upon completion of a large randomized clinical trial currently underway in Europe (clinicaltrials.gov no. NCT01290939). Verification of efficacy in the recurrent setting would likely lead to increasing use of the drug for recurrent glioblastoma, while lack of efficacy in a randomized trial for recurrent glioblastomas will increase the importance of identifying biomarkers for response and resistance so that appropriate candidates for treatment can continue to be identified. For now, patients with glioblastoma who are receiving bevacizumab treatment should continue to be monitored closely for treatment-related morbidity and radiological changes, with a low threshold for changing treatments early when imaging changes emerge. Neurosurgeons operating on patients who develop bevacizumab resistance should be cautious of the risk of wound healing complications, including possible consideration of obtaining assistance from a plastic surgeon with closing these wounds.³⁸

Abbreviations used in this paper

AVAglio	Avastin in Glioblastoma
EOR	extent of resection
PDGFR	platelet-derived growth factor receptor
PFS	progression-free survival
RANO	Response Assessment in Neuro-Oncology
RTKI	receptor tyrosine kinase inhibitor
RTOG	Radiation Therapy Oncology Group
TEMAVIR	TEMozolomideAVastinIRinotecan
TTF	tumor treating field
VEGF	vascular endothelial growth factor
VEGFR	VEGF receptor

References

1. Abrishami M, Zarei-Ghanavati S, Soroush D, Rouhbakhsh M, Jaafari MR, Malaek-Nikouei B. Preparation, characterization, and in vivo evaluation of nanoliposomes-encapsulated bevacizumab (avastin) for intravitreal administration. *Retina*. 2009; 31:699–703. [PubMed: 19430280]
2. Ali SA, McHayleh WM, Ahmad A, Sehgal R, Braffet M, Rahman M, et al. Bevacizumab and irinotecan therapy in glioblastoma multiforme: a series of 13 cases. *J Neurosurg*. 2008; 109:268–272. [PubMed: 18671639]
3. Anderson MD, Hamza MA, Hess KR, Puduvalli VK. Implications of bevacizumab discontinuation in adults with recurrent glioblastoma. *Neuro Oncol*. 2014; 16:823–828. [PubMed: 24596117]
4. Ballman KV, Buckner JC, Brown PD, Giannini C, Flynn PJ, LaPlant BR, et al. The relationship between six-month progression-free survival and 12-month overall survival end points for phase II trials in patients with glioblastoma multiforme. *Neuro Oncol*. 2007; 9:29–38. [PubMed: 17108063]
5. Bao S, Wu Q, Sathornsumetee S, Hao Y, Li Z, Hjelmeland AB, et al. Stem cell-like glioma cells promote tumor angiogenesis through vascular endothelial growth factor. *Cancer Res*. 2006; 66:7843–7848. [PubMed: 16912155]
6. Batchelor TT, Duda DG, di Tomaso E, Ancukiewicz M, Plotkin SR, Gerstner E, et al. Phase II study of cediranib, an oral pan-vascular endothelial growth factor receptor tyrosine kinase inhibitor, in patients with recurrent glioblastoma. *J Clin Oncol*. 2010; 28:2817–2823. [PubMed: 20458050]
7. Batchelor TT, Mulholland P, Neyns B, Nabors LB, Campone M, Wick A, et al. Phase III randomized trial comparing the efficacy of cediranib as monotherapy, and in combination with lomustine, versus lomustine alone in patients with recurrent glioblastoma. *J Clin Oncol*. 2013; 31:3212–3218. [PubMed: 23940216]
8. Batchelor TT, Sorensen AG, di Tomaso E, Zhang WT, Duda DG, Cohen KS, et al. AZD2171, a pan-VEGF receptor tyrosine kinase inhibitor, normalizes tumor vasculature and alleviates edema in glioblastoma patients. *Cancer Cell*. 2007; 11:83–95. [PubMed: 17222792]
9. Bloch O, Han SJ, Cha S, Sun MZ, Aghi MK, McDermott MW, et al. Impact of extent of resection for recurrent glioblastoma on overall survival. *Clinical article. J Neurosurg*. 2012; 117:1032–1038. [PubMed: 23039151]
10. Bloch O, Safaee M, Sun MZ, Butowski NA, McDermott MW, Berger MS, et al. Disseminated progression of glioblastoma after treatment with bevacizumab. *Clin Neurol Neurosurg*. 2013; 115:1795–1801. [PubMed: 23706614]

11. Bokstein F, Shpigel S, Blumenthal DT. Treatment with bevacizumab and irinotecan for recurrent high-grade glial tumors. *Cancer*. 2008; 112:2267–2273. [PubMed: 18327820]
12. Burkhardt JK, Riina H, Shin BJ, Christos P, Kesavabhotla K, Hofstetter CP, et al. Intra-arterial delivery of bevacizumab after blood-brain barrier disruption for the treatment of recurrent glioblastoma: progression-free survival and overall survival. *World Neurosurg*. 2012; 77:130–134. [PubMed: 22405392]
13. Carbonell WS, DeLay M, Jahangiri A, Park CC, Aghi MK. β 1 integrin targeting potentiates antiangiogenic therapy and inhibits the growth of bevacizumab-resistant glioblastoma. *Cancer Res*. 2013; 73:3145–3154. [PubMed: 23644530]
14. Chamberlain MC. Bevacizumab for the treatment of recurrent glioblastoma. *Clin Med Insights Oncol*. 2011; 5:117–129. [PubMed: 21603247]
15. Chamberlain MC. Emerging clinical principles on the use of bevacizumab for the treatment of malignant gliomas. *Cancer*. 2010; 116:3988–3999. [PubMed: 20564141]
16. Chamberlain MC. Salvage chemotherapy with CPT-11 for recurrent glioblastoma multiforme. *J Neurooncol*. 2002; 56:183–188. [PubMed: 11995820]
17. Chauftet B, Feuvret L, Bonnetain F, Taillandier L, Frappaz D, Taillia H, et al. Randomized phase II trial of irinotecan and bevacizumab as neo-adjuvant and adjuvant to temozolomide-based chemoradiation compared with temozolomide-chemoradiation for unresectable glioblastoma. Final results of the TEMAVIR study from ANOCEF. *Ann Oncol*. 2014; 25:1442–1447. [PubMed: 24723487]
18. Cheng SY, Huang HJ, Nagane M, Ji XD, Wang D, Shih CC, et al. Suppression of glioblastoma angiogenicity and tumorigenicity by inhibition of endogenous expression of vascular endothelial growth factor. *Proc Natl Acad Sci U S A*. 1996; 93:8502–8507. [PubMed: 8710899]
19. Chinot OL, Wick W, Mason W, Henriksson R, Saran F, Nishikawa R, et al. Bevacizumab plus radiotherapy-temozolomide for newly diagnosed glioblastoma. *N Engl J Med*. 2014; 370:709–722. [PubMed: 24552318]
20. Clark AJ, Butowski NA, Chang SM, Prados MD, Clarke J, Polley MYC, et al. Impact of bevacizumab chemotherapy on craniotomy wound healing. *Clinical article. J Neurosurg*. 2011; 114:1609–1616. [PubMed: 21142749]
21. Clark AJ, Lamborn KR, Butowski NA, Chang SM, Prados MD, Clarke JL, et al. Neurosurgical management and prognosis of patients with glioblastoma that progresses during bevacizumab treatment. *Neurosurgery*. 2012; 70:361–370. [PubMed: 21841523]
22. Clarke JL, Ennis MM, Yung WKA, Chang SM, Wen PY, Cloughesy TF, et al. Is surgery at progression a prognostic marker for improved 6-month progression-free survival or overall survival for patients with recurrent glioblastoma? *Neuro Oncol*. 2011; 13:1118–1124. [PubMed: 21813511]
23. Cloughesy TF, Filka E, Nelson G, Kabbinavar F, Friedman H, Miller LL, et al. Irinotecan treatment for recurrent malignant glioma using an every-3-week regimen. *Am J Clin Oncol*. 2002; 25:204–208. [PubMed: 11943904]
24. Cohen MH, Shen YL, Keegan P, Pazdur R. FDA drug approval summary: bevacizumab (Avastin) as treatment of recurrent glioblastoma multiforme. *Oncologist*. 2009; 14:1131–1138. [PubMed: 19897538]
25. de Groot J, Liang J, Kong LY, Wei J, Piao Y, Fuller G, et al. Modulating antiangiogenic resistance by inhibiting the signal transducer and activator of transcription 3 pathway in glioblastoma. *Oncotarget*. 2012; 3:1036–1048. [PubMed: 23013619]
26. de Groot JF, Lamborn KR, Chang SM, Gilbert MR, Cloughesy TF, Aldape K, et al. Phase II study of aflibercept in recurrent malignant glioma: a North American Brain Tumor Consortium study. *J Clin Oncol*. 2011; 29:2689–2695. [PubMed: 21606416]
27. DeLay M, Jahangiri A, Carbonell WS, Hu YL, Tsao S, Tom MW, et al. Microarray analysis verifies two distinct phenotypes of glioblastomas resistant to antiangiogenic therapy. *Clin Cancer Res*. 2012; 18:2930–2942. [PubMed: 22472177]
28. Desjardins A, Reardon DA, Coan A, Marcello J, Herndon JE II, Bailey L, et al. Bevacizumab and daily temozolomide for recurrent glioblastoma. *Cancer*. 2012; 118:1302–1312. [PubMed: 21792866]

29. Ferrara N, Gerber HP, LeCouter J. The biology of VEGF and its receptors. *Nat Med.* 2003; 9:669–676. [PubMed: 12778165]
30. Field KM, Simes J, Wheeler H, Hovary EJ, Nowak AK, Cher L, et al. A randomized phase II study of carboplatin and bevacizumab in recurrent glioblastoma multiforme (CABARET). *J Clin Oncol.* 2013; 31:2017.
31. Fischer I, Gagner JP, Law M, Newcomb EW, Zagzag D. Angiogenesis in gliomas: biology and molecular pathophysiology. *Brain Pathol.* 2005; 15:297–310. [PubMed: 16389942]
32. Friedman HS, Petros WP, Friedman AH, Schaaf LJ, Kerby T, Lawyer J, et al. Irinotecan therapy in adults with recurrent or progressive malignant glioma. *J Clin Oncol.* 1999; 17:1516–1525. [PubMed: 10334539]
33. Friedman HS, Prados MD, Wen PY, Mikkelsen T, Schiff D, Abrey LE, et al. Bevacizumab alone and in combination with irinotecan in recurrent glioblastoma. *J Clin Oncol.* 2009; 27:4733–4740. [PubMed: 19720927]
34. Galanis E, Anderson SK, Lafky JM, Uhm JH, Giannini C, Kumar SK, et al. Phase II study of bevacizumab in combination with sorafenib in recurrent glioblastoma (N0776): a north central cancer treatment group trial. *Clin Cancer Res.* 2013; 19:4816–4823. [PubMed: 23833308]
35. Gállego Pérez-Larraya J, Ducray F, Chinot O, Catry-Thomas I, Taillandier L, Guillamo JS, et al. Temozolomide in elderly patients with newly diagnosed glioblastoma and poor performance status: an ANOCEF phase II trial. *J Clin Oncol.* 2011; 29:3050–3055. [PubMed: 21709196]
36. Gilbert MR, Dignam JJ, Armstrong TS, Wefel JS, Blumenthal DT, Vogelbaum MA, et al. A randomized trial of bevacizumab for newly diagnosed glioblastoma. *N Engl J Med.* 2014; 370:699–708. [PubMed: 24552317]
37. Gilbert MR, Wang M, Aldape K, Lassman A, Sorenson AG, Mikkelsen M, et al. RTOG 0625: a phase II study of bevacizumab with irinotecan in recurrent glioblastoma (GBM). *J Clin Oncol.* 2009; 27(Suppl):15s. Abstract.
38. Golas AR, Boyko T, Schwartz TH, Stieg PE, Boockvar JA, Spector JA. Prophylactic plastic surgery closure of neurosurgical scalp incisions reduces the incidence of wound complications in previously-operated patients treated with bevacizumab (Avastin®) and radiation. *J Neurooncol.* 2014; 119:327–331. [PubMed: 24872117]
39. Goldlust SA, Cavaliere R, Newton HB, Hsu M, Deangelis LM, Batchelor TT, et al. Bevacizumab for glioblastoma refractory to vascular endothelial growth factor receptor inhibitors. *J Neurooncol.* 2012; 107:407–411. [PubMed: 22203237]
40. Gordon MS, Margolin K, Talpaz M, Sledge GW Jr, Holmgren E, Benjamin R, et al. Phase I safety and pharmacokinetic study of recombinant human anti-vascular endothelial growth factor in patients with advanced cancer. *J Clin Oncol.* 2001; 19:843–850. [PubMed: 11157038]
41. Gutin PH, Wong ET. Noninvasive application of alternating electric fields in glioblastoma: a fourth cancer treatment modality. *Am Soc Clin Oncol Educ Book.* 2012; 2012:126–131. [PubMed: 24451721]
42. Huppold C, Roth P, Wick W, Steinbach JP, Linnebank M, Weller M, et al. ACNU-based chemotherapy for recurrent glioma in the temozolomide era. *J Neurooncol.* 2009; 92:45–48. [PubMed: 18987781]
43. Herrlinger U, Schaefer N, Steinbach JP, Weyerbrock A, Hau P, Goldbrunner R, et al. Bevacizumab, irinotecan, and radiotherapy versus standard temozolomide and radiotherapy in newly diagnosed MGMT non-methylated glioblastoma patients: first results from the randomized multicenter GLARIUS trial. *J Clin Oncol.* 2013; 31(Suppl):LBA2000. Abstract.
44. Hu YL, DeLay M, Jahangiri A, Molinaro AM, Rose SD, Carbonell WS, et al. Hypoxia-induced autophagy promotes tumor cell survival and adaptation to antiangiogenic treatment in glioblastoma. *Cancer Res.* 2012; 72:1773–1783. [PubMed: 22447568]
45. Jahangiri A, Aghi MK. Biomarkers predicting tumor response and evasion to anti-angiogenic therapy. *Biochim Biophys Acta.* 2012; 1825:86–100. [PubMed: 22067555]
46. Jahangiri A, De Lay M, Miller LM, Carbonell WS, Hu YL, Lu K, et al. Gene expression profile identifies tyrosine kinase c-Met as a targetable mediator of antiangiogenic therapy resistance. *Clin Cancer Res.* 2013; 19:1773–1783. [PubMed: 23307858]

47. Kim KJ, Li B, Winer J, Armanini M, Gillett N, Phillips HS, et al. Inhibition of vascular endothelial growth factor-induced angiogenesis suppresses tumour growth in vivo. *Nature*. 1993; 362:841–844. [PubMed: 7683111]
48. Kolata, G.; Pollack, A. [Accessed October 2, 2014] Costly cancer drug offers hope, but also a dilemma. *New York Times*. Jul 6. 2008 <http://www.nytimes.com/2008/07/06/health/06avastin.html>
49. Kreisl TN, Kim L, Moore K, Duic P, Royce C, Stroud I, et al. Phase II trial of single-agent bevacizumab followed by bevacizumab plus irinotecan at tumor progression in recurrent glioblastoma. *J Clin Oncol*. 2009; 27:740–745. [PubMed: 19114704]
50. Lacroix M, Abi-Said D, Fourney DR, Gokaslan ZL, Shi W, DeMonte F, et al. A multivariate analysis of 416 patients with glioblastoma multiforme: prognosis, extent of resection, and survival. *J Neurosurg*. 2001; 95:190–198. [PubMed: 11780887]
51. Lai A, Tran A, Nghiemphu PL, Pope WB, Solis OE, Selch M, et al. Phase II study of bevacizumab plus temozolomide during and after radiation therapy for patients with newly diagnosed glioblastoma multiforme. *J Clin Oncol*. 2011; 29:142–148. [PubMed: 21135282]
52. Laigle-Donadey F, Figarella-Branger D, Chinot O, Taillandier L, Cartalat-Carel S, Honnorat J, et al. Up-front temozolomide in elderly patients with glioblastoma. *J Neurooncol*. 2010; 99:89–94. [PubMed: 20058048]
53. Lamborn KR, Yung WKA, Chang SM, Wen PY, Cloughesy TF, DeAngelis LM, et al. Progression-free survival: an important end point in evaluating therapy for recurrent high-grade gliomas. *Neuro Oncol*. 2008; 10:162–170. [PubMed: 18356283]
54. Lou E, Peters KB, Sumrall AL, Desjardins A, Reardon DA, Lipp ES, et al. Phase II trial of upfront bevacizumab and temozolomide for unresectable or multifocal glioblastoma. *Cancer Med*. 2013; 2:185–195. [PubMed: 23634286]
55. Magnuson W, Robins HI, Mohindra P, Howard S. Large volume reirradiation as salvage therapy for glioblastoma after progression on bevacizumab. *J Neurooncol*. 2014; 117:133–139. [PubMed: 24469853]
56. McGee MC, Hamner JB, Williams RF, Rosati SF, Sims TL, Ng CY, et al. Improved intratumoral oxygenation through vascular normalization increases glioma sensitivity to ionizing radiation. *Int J Radiat Oncol Biol Phys*. 2010; 76:1537–1545. [PubMed: 20338480]
57. Michor F, Iwasa Y, Nowak MA. Dynamics of cancer progression. *Nat Rev Cancer*. 2004; 4:197–205. [PubMed: 14993901]
58. Muhsin M, Graham J, Kirkpatrick P. Bevacizumab. *Nat Rev Drug Discov*. 2004; 3:995–996. [PubMed: 15645606]
59. Nabors LB, Supko JG, Rosenfeld M, Chamberlain M, Phuphanich S, Batchelor T, et al. Phase I trial of sorafenib in patients with recurrent or progressive malignant glioma. *Neuro Oncol*. 2011; 13:1324–1330. [PubMed: 21954442]
60. Nagane M, Nishikawa R, Narita Y, Kobayashi H, Takano S, Shinoura N, et al. Phase II study of single-agent bevacizumab in Japanese patients with recurrent malignant glioma. *Jpn J Clin Oncol*. 2012; 42:887–895. [PubMed: 22844129]
61. Narayana A, Gruber D, Kunnakkat S, Golfinos JG, Parker E, Raza S, et al. A clinical trial of bevacizumab, temozolomide, and radiation for newly diagnosed glioblastoma. *Clinical article. J Neurosurg*. 2012; 116:341–345. [PubMed: 22035272]
62. Parikh SS, Mehta HH, Desai BI. Advances in development of bevacizumab, a humanized antiangiogenic therapeutic monoclonal antibody targeting VEGF in cancer cells. *Int J Pharm Biomed Sci*. 2012; 3:156–163.
63. Piccioni DE, Selfridge J, Mody RR, Chowdhury R, Li S, Lalezari S, et al. Deferred use of bevacizumab for recurrent glioblastoma is not associated with diminished efficacy. *Neuro Oncol*. 2014; 16:815–822. [PubMed: 24627236]
64. Pope WB, Xia Q, Paton VE, Das A, Hambleton J, Kim HJ, et al. Patterns of progression in patients with recurrent glioblastoma treated with bevacizumab. *Neurology*. 2011; 76:432–437. [PubMed: 21282590]
65. Prados MD, Lamborn K, Yung WKA, Jaeckle K, Robins HI, Mehta M, et al. A phase 2 trial of irinotecan (CPT-11) in patients with recurrent malignant glioma: a North American Brain Tumor Consortium study. *Neuro Oncol*. 2006; 8:189–193. [PubMed: 16533878]

66. Presta LG, Chen H, O'Connor SJ, Chisholm V, Meng YG, Krummen L, et al. Humanization of an anti-vascular endothelial growth factor monoclonal antibody for the therapy of solid tumors and other disorders. *Cancer Res.* 1997; 57:4593–4599. [PubMed: 9377574]
67. Ram Z, Gutin PH, Stupp R. Subgroup and quality of life analyses of the phase III clinical trial of NovoTTF-100A versus best standard chemotherapy for recurrent glioblastoma. *Neuro Oncol.* 2010; 12:48–49. Abstract.
68. Reardon DA, Herndon JE II, Peters KB, Desjardins A, Coan A, Lou E, et al. Bevacizumab continuation beyond initial bevacizumab progression among recurrent glioblastoma patients. *Br J Cancer.* 2012; 107:1481–1487. [PubMed: 23037712]
69. Rubenstein JL, Kim J, Ozawa T, Zhang M, Westphal M, Deen DF, et al. Anti-VEGF antibody treatment of glioblastoma prolongs survival but results in increased vascular cooption. *Neoplasia.* 2000; 2:306–314. [PubMed: 11005565]
70. Sanai N, Polley MY, McDermott MW, Parsa AT, Berger MS. An extent of resection threshold for newly diagnosed glioblastomas. *Clinical article. J Neurosurg.* 2011; 115:3–8. [PubMed: 21417701]
71. Schmidt C. Costly cancer drugs trigger proposals to modify clinical trial design. *J Natl Cancer Inst.* 2009; 101:1662–1664. [PubMed: 19933943]
72. Scott BJ, Quant EC, McNamara MB, Ryg PA, Batchelor TT, Wen PY. Bevacizumab salvage therapy following progression in high-grade glioma patients treated with VEGF receptor tyrosine kinase inhibitors. *Neuro Oncol.* 2010; 12:603–607. [PubMed: 20156808]
73. Siegelin MD, Raskett CM, Gilbert CA, Ross AH, Altieri DC. Sorafenib exerts anti-glioma activity in vitro and in vivo. *Neurosci Lett.* 2010; 478:165–170. [PubMed: 20470863]
74. Sinha G. Expensive cancer drugs with modest benefit ignite debate over solutions. *J Natl Cancer Inst.* 2008; 100:1347–1349. [PubMed: 18812543]
75. Stark-Vance V. Bevacizumab and CPT-11 in the treatment of relapsed malignant glioma. *Neuro Oncol.* 2005; 7:369. Abstract.
76. Stupp R, Hegi ME, Mason WP, van den Bent MJ, Taphoorn MJB, Janzer RC, et al. Effects of radiotherapy with concomitant and adjuvant temozolomide versus radiotherapy alone on survival in glioblastoma in a randomised phase III study: 5-year analysis of the EORTC-NCIC trial. *Lancet Oncol.* 2009; 10:459–466. [PubMed: 19269895]
77. Stupp R, Mason WP, van den Bent MJ, Weller M, Fisher B, Taphoorn MJB, et al. Radiotherapy plus concomitant and adjuvant temozolomide for glioblastoma. *N Engl J Med.* 2005; 352:987–996. [PubMed: 15758009]
78. Taal W, Oosterkamp HM, Walenkamp AME, Dubbink HJ, Beerepoot LV, Hanse MJC, et al. Single-agent bevacizumab or lomustine versus a combination of bevacizumab plus lomustine in patients with recurrent glioblastoma (BELOB trial): a randomised controlled phase 2 trial. *Lancet Oncol.* 2014; 15:943–953. [PubMed: 25035291]
79. Vredenburgh JJ, Desjardins A, Herndon JE II, Dowell JM, Reardon DA, Quinn JA, et al. Phase II trial of bevacizumab and irinotecan in recurrent malignant glioma. *Clin Cancer Res.* 2007; 13:1253–1259. [PubMed: 17317837]
80. Vredenburgh JJ, Desjardins A, Herndon JE II, Marcello J, Reardon DA, Quinn JA, et al. Bevacizumab plus irinotecan in recurrent glioblastoma multiforme. *J Clin Oncol.* 2007; 25:4722–4729. [PubMed: 17947719]
81. Wedge SR, Kendrew J, Hennequin LF, Valentine PJ, Barry ST, Brave SR, et al. AZD2171: a highly potent, orally bioavailable, vascular endothelial growth factor receptor-2 tyrosine kinase inhibitor for the treatment of cancer. *Cancer Res.* 2005; 65:4389–4400. [PubMed: 15899831]
82. Wen PY. American Society of Clinical Oncology 2010: report of selected studies from the CNS tumors section. *Expert Rev Anticancer Ther.* 2010; 10:1367–1369. [PubMed: 20836670]
83. Wen PY, Macdonald DR, Reardon DA, Cloughesy TF, Sorensen AG, Galanis E, et al. Updated response assessment criteria for high-grade gliomas: response assessment in neuro-oncology working group. *J Clin Oncol.* 2010; 28:1963–1972. [PubMed: 20231676]
84. Wick W, Puduvalli VK, Chamberlain MC, van den Bent MJ, Carpentier AF, Cher LM, et al. Phase III study of enzastaurin compared with lomustine in the treatment of recurrent intracranial glioblastoma. *J Clin Oncol.* 2010; 28:1168–1174. [PubMed: 20124186]

85. Willett CG, Boucher Y, di Tomaso E, Duda DG, Munn LL, Tong RT, et al. Direct evidence that the VEGF-specific antibody bevacizumab has antivascular effects in human rectal cancer. *Nat Med*. 2004; 10:145–147. [PubMed: 14745444]
86. Willett CG, Duda DG, di Tomaso E, Boucher Y, Ancukiewicz M, Sahani DV, et al. Efficacy, safety, and biomarkers of neo-adjuvant bevacizumab, radiation therapy, and fluorouracil in rectal cancer: a multidisciplinary phase II study. *J Clin Oncol*. 2009; 27:3020–3026. [PubMed: 19470921]
87. Wong ET, Gautam S, Malchow C, Lun M, Pan E, Brem S. Bevacizumab for recurrent glioblastoma multiforme: a metaanalysis. *J Natl Compr Canc Netw*. 2011; 9:403–407. [PubMed: 21464145]
88. Wong ET, Hess KR, Gleason MJ, Jaeckle KA, Kyritsis AP, Prados MD, et al. Outcomes and prognostic factors in recurrent glioma patients enrolled onto phase II clinical trials. *J Clin Oncol*. 1999; 17:2572–2578. [PubMed: 10561324]
89. Yang JC, Haworth L, Sherry RM, Hwu P, Schwartzentruber DJ, Topalian SL, et al. A randomized trial of bevacizumab, an anti-vascular endothelial growth factor antibody, for metastatic renal cancer. *N Engl J Med*. 2003; 349:427–434. [PubMed: 12890841]
90. Yung WK, Albright RE, Olson J, Fredericks R, Fink K, Prados MD, et al. A phase II study of temozolomide vs. procarbazine in patients with glioblastoma multiforme at first relapse. *Br J Cancer*. 2000; 83:588–593. [PubMed: 10944597]

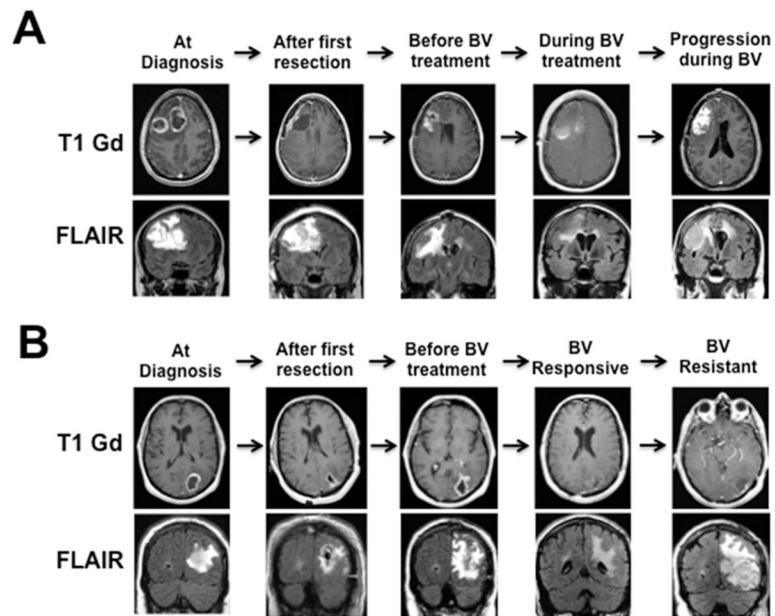


Fig. 1. Axial (*upper row*) and coronal (*lower row*) MRI findings associated with progression during bevacizumab (BV) treatment. Shown are examples of **(A)** enhancing and **(B)** nonenhancing progression occurring during bevacizumab treatment. T1 = T1-weighted.

TABLE 1

Reported results in use of bevacizumab for glioblastoma treatment*

Study	Phase of Trial	Centers Involved	Regimen	No. w/Glioblastoma	PFS			Overall Survival		
					6 Mos (%)	Median (mos)	1 Yr (%)	2 Yrs (%)	Median (mos)	
recurrent glioblastoma trials										
Stark-Vance, 2005	I	1	BV + irinotecan	11	NR	NR	NR	NR	NR	NR
Vredenburgh et al., 2007 ⁷⁹	II	1	BV + irinotecan	23	30	4.6	NR	NR	NR	9.2
Vredenburgh et al., 2007 ⁸⁰	II	1	BV + irinotecan	35	46	5.5	77	NR	NR	9.7
Bokstein et al., 2008	II	1	BV + irinotecan	17	25	4.2	55	NR	NR	7
Ali et al., 2008	I/II	2	BV + irinotecan	13	NR	5.5	NR	NR	NR	6.2
RTOG 0625, Gilbert et al., 2009	II	8	BV + irinotecan	57	37	NR	NR	NR	NR	NR
Kreisl et al., 2009	II	1	BV	48	29	3.7	57	NR	NR	7.2
BRAIN, Friedman et al., 2009	II	12	BV + irinotecan	82	50.3	5.6	69.5	9.8	0	8.7
Nagane et al., 2012	II	12	BV	85	42.6	4.2	74.1	2.4	0	9.2
Desjardins et al., 2012	II	11	BV	29	33.9	3.3	NR	34.5	NR	10.5
CABARET, Field et al., 2013	II	1	BV + TMZ	32	18.8	3.6	62.5	31.3	NR	8.5
N0776, Galanis et al., 2013	II	18	BV + carboplatin	58	26	NR	NR	NR	NR	6.9
BELOB, Taal et al., 2014	II	18	BV	62	24	NR	NR	NR	NR	6.4
	II	1	BV + sorafenib (400 mg/day)	19	26	3.61	NR	NR	NR	5.58
	II	1	BV + sorafenib (200 mg/day)	35	17	2.66	NR	NR	NR	5.62
	II	14	BV	50	18	3	NR	26	NR	8
	II	14	BV + CCNU	52	42	4	NR	48	NR	12
	II	14	CCNU	46	11	1	NR	30	NR	8
newly diagnosed glioblastoma trials										
Narayana et al., 2012	II	2	BV + TMZ/RT	51	85.1	13	85.1	42.5	NR	23

Study	Phase of Trial	Centers Involved	Regimen	No. w/Glioblastoma	PFS			Overall Survival		
					6 Mos (%)	Median (mos)	6 Mos (%)	1 Yr (%)	2 Yrs (%)	Median (mos)
GLARIUS, Herringer et al., 2013	II	15	BV + irinotecan + TMZ/RT	116	71.1	9.7	NR	NR	NR	16.6
AVAgllo, Chinot et al., 2014	III	10	BV + TMZ/RT	458	79.9	10.6	91.9	72.4	33.9	16.8
RTOG 0825, Gilbert et al., 2014	III	14	BV + TMZ/RT	312	77.5	10.7	84.3	64.1	15.1	15.7
unresectable glioblastoma trials	III	14	TMS/RT	309	52.8	7.3	82.5	62.1	16.2	16.1
Lou et al., 2013	II	2	BV + TMZ	41	NR	5.6	70.7 [†]	48.8 [†]	7.3 [†]	11.7 [†]
TEMAVIR, Chauffert et al., 2014	II	17	BV + irinotecan + TMZ/RT	61.7	50	7.1	70	43.3	15	11.1
	II	17	TMZ/RT	41.7	30	5.2	70	46.7	5	11.1

* Median PFS and median overall survival that were reported in weeks were standardized to months using the following formula: weeks/52 × 12. BV = bevacizumab; CCNU = lomustine; NR = not reported; RT = radiation therapy; TMZ = temozolomide.

[†] Enrollment and treatment in this study were limited to 4 months, limiting the ability to generate statistically accurate assessment of overall survival. Median survival from treatment initiation to death is listed.

TABLE 2

Summary of current clinical indications for bevacizumab therapy in glioblastoma

Clinical Variable	Specific Information
Treatment at diagnosis vs recurrence	Bevacizumab is currently approved in the setting of recurrent disease in glioblastoma patients. ²⁴ Bevacizumab is not currently indicated as adjuvant therapy to standard temozolomide plus radiation therapy at the time of diagnosis. ^{19,36} Bevacizumab therapy can be initiated early or late in tumor recurrence, with similar efficacy. ⁶³
Administration	The recommended dose and schedule of single-agent bevacizumab in patients with recurrent glioblastoma is currently under review with 10 mg/kg intravenously every 2 weeks until disease progression or unacceptable toxicity being the historically used regimen, but recent studies showing comparable efficacy with 5 mg/kg. ⁸⁷
Concomitant treatment	Bevacizumab can be used as monotherapy or in combination, with irinotecan as the agent producing the best results when combined with bevacizumab. ^{14,34,78} Lower doses of concurrent corticosteroids are recommended to improve response rates of bevacizumab. ^{33,60}
Safety considerations	Patients with intracranial hemorrhage on imaging are not candidates for bevacizumab therapy. ⁷⁹ Prior to initiating therapy, patient risk for hypertension and hyperlipidemia should be assessed. ⁴⁹ Bevacizumab-based therapy should be suspended for at least 4 weeks prior to surgery and not restarted until the wound has completely healed (typically 4 weeks). ²⁰ Bevacizumab treatment should be discontinued for specific severe adverse events, including intracranial hemorrhage, bowel perforation, cardiac failure, wound dehiscence, and stroke. ¹⁴ Blood pressure should be monitored and controlled, by conservative or pharmacological means, in all patients taking bevacizumab. This is important to decrease risks of bevacizumab-induced hypertension and associated intracranial hemorrhage. ^{14,79}

Author Manuscript

Author Manuscript

Author Manuscript

Author Manuscript