

UC Irvine

UC Irvine Previously Published Works

Title

Autologous rectus fascia sling for treatment of stress urinary incontinence in women: A review of the literature

Permalink

<https://escholarship.org/uc/item/4vf079w3>

Journal

Neurourology and Urodynamics, 38(S4)

ISSN

0733-2467

Authors

Mahdy, Ayman
Ghoniem, Gamal M

Publication Date

2019-08-01

DOI

10.1002/nau.23878

Peer reviewed

Autologous rectus fascia sling for treatment of stress urinary incontinence in women: A review of the literature

Ayman Mahdy MD, PhD¹  | Gamal M. Ghoniem MD, FPMRS, FACS²

¹ Department of Urology, University of Cincinnati, Cincinnati, Ohio

² Chief Division of Female Urology, Pelvic Reconstructive Surgery & Voiding Dysfunction, Department of Urology | UC Irvine Health, Orange, California

Correspondence

Gamal M. Ghoniem, MD, FPMRS, FACS, Chief Division of Female Urology, Pelvic Reconstructive Surgery & Voiding Dysfunction, Department of Urology | UC Irvine Health, 333 City Blvd. West, Suite 2100, Orange, CA 92868.
Email: gghoniem@uci.edu

Aims: Stress urinary incontinence (SUI) is common in the adult females. Surgical treatment options include synthetic mid-urethral sling (MUS), autologous sling, bulking agents, and Burch colposuspension. The autologous pubovaginal sling (PVS) has re-emerged in response to complications of synthetic MUSs and FDA communications regarding the use of vaginal mesh. This resulted in patients' fear related to vaginal mesh and drop in number of patients seeking surgical treatment of SUI. PVS has re-emerged as an option for treatment of primary SUI. The aim of this review is to familiarize, disseminate information, and share tips for the practicing female pelvic surgeons related to the practice of the autologous fascia sling.

Methods: We reviewed the literature related to the autologous sling. We used the following data bases and search engines: GoPubMed (Transinsight), Cochrane reviews (Wiley Interscience), google scholar (google), and Scopus (Elsevier). Because it is the most commonly investigated and utilized, we focused on the autologous rectus fascia sling. We also focused on the retropubic sling approach because the literature on transobturator rectus fascia sling is sparse.

Results: Out of 307 articles related to the subject found, 22 articles were included and the rest were excluded.

Conclusion: ARFS is a valid primary method of treatment for female SUI. Also, it is used in particular indications such as patients with intrinsic sphincter deficiency (ISD), prior pelvic irradiation, failed and/or complicated synthetic MUS, and violated urethral lumen.

KEYWORDS

autologous sling, rectus fascia sling, stress urinary incontinence

1 | INTRODUCTION

The use of the autologous sling in treatment of female SUI is known since the beginning of the last century. Synthetic

MUS emerged in the early 1990s and now is the most commonly used procedure for female SUI.¹⁻³ This procedure, however, has increasingly been associated with sling-related complications, malpractice litigations, and associated

Abbreviations: ARFS, autologous rectus fascia sling; CIC, clean intermittent catheterization; ISD, intrinsic sphincter deficiency; MUI, mixed urinary incontinence; MUS, mid-urethral sling; PVS, traditional autologous pubovaginal sling; SUI, stress urinary incontinence; UVF, urethrovaginal fistula.

David Ginsberg led the peer-review process as the Associate Editor responsible for the paper.

patients' concerns. This forced many synthetic sling manufacturers to withdraw their products off the market. Simultaneously many pelvic surgeons have reduced the utilization of synthetic and increased the utilization of autologous slings.⁴

The first use of a fascial suburethral sling was described by Price in 1933 using fascia lata.⁵ Aldridge popularized the use of the rectus fascia sling in 1942.⁶ In 1978, McGuire and Lyton popularized the rectus fascia sling procedure for type III-SUI (a severe form of SUI secondary to ISD).⁷ In 1986, McGuire and his group reported on the use of free rectus fascial strip in the treatment of SUI in patients with myelodysplasia.⁸ This was further modified by Ghoneim in 1989.⁹ In 1991, Blaivas and Jacobs reported on the use of ARFS in patients with complicated SUI.¹⁰

The purpose of this review article is to shed the light on the autologous slings with special emphasis on procedure technique, outcome, indications, and complications.

The term autologous sling refers to the use of patient-own-tissue as a sling. In this article, we will discuss the ARFS using the retropubic approach.

2 | METHODS

We reviewed the literature related to the autologous sling. We used the keywords "autologous sling," "rectus fascia sling," "autologous rectus fascia sling," and "autologous female sling." We used the following data bases and search engines: GoPubMed (Transinsight), Cochrane reviews (Wiley Inter-science), google scholar (google), and Scopus (Elsevier). We excluded meeting abstracts, case reports, case series, articles related to autologous sling in male and autologous sling materials other than rectus fascia. We also focused only on the retropubic sling approach being the most popular and the more investigated.

3 | RESULTS

We found 307 articles related to the subject, 22 articles were included. We found that even with the wide availability of the synthetic MUS, the autologous sling is still a valid primary option for treatment of SUI. Although the number of studies is limited, the outcome of autologous sling in specific type of SUI patients who failed or have complicated synthetic MUS seems favorable.

4 | DISCUSSION

4.1 | Mechanism of continence using the ARFS

The primary mechanism of PVS is creation of increased outlet resistance. Clearly this is the case in obstructive PVS sling

where urinary retention is sought as in patients with neurogenic bladder. But this action is not clear where both self-voiding and continence are desired as in most cases. One of the proposed mechanisms of action of ARFS is to restore the normal urethrovesical junction support and mechanical compression or kinking at the proximal urethra during stress. This increases bladder outlet resistance during increased intra-abdominal pressure and hence, prevents SUI.¹¹ Videourodynamics in the standing position in patients who received ARFS showed that during the resting position, the sling does not have much compression role. During increased intra-abdominal pressure, however, the rectus muscle contracts pulling the sling anteriorly. This forward sling move leads to rotation of the bladder base posteroinferiorly causing kinking at the posterior urethra and increasing the bladder outlet pressure which prevents SUI. This means applying overly tension on the sling during sling positioning is unnecessary and should be discouraged.^{11,12}

4.2 | Indications

Although ARFS was reserved for complicated cases of SUI, there is enough body of the literature to support the use of ARFS as a primary treatment option for women with uncomplicated SUI.¹³ Also, ARFS should be considered in situations when the synthetic MUS is less preferred and/or contraindicated. Those situations include violation of the urethral mucosa either incidental during periurethral dissection or intentional during excision of urethral diverticulum, closure of urethra-vaginal fistula, and/or excision of an eroded synthetic sub-urethral sling.^{14,15} We also favor ARFS for treatment of SUI in women with prior pelvic irradiation, women on chronic steroid therapy, extensive tissue fibrosis and scarring, and women with chronic pelvic pain and/or dyspareunia.

4.3 | Surgical technique

The technique has been previously described by McGuire.⁷ While the patient in the modified dorsal lithotomy position under general anesthesia, Foley catheter is inserted. A Pfannenstiel suprapubic incision is made and the rectus fascia is reached. The fascia is freed from the covering subcutaneous fat. The sling outline is made by a marking pen, methylene blue or the electrocautery (Figure 1). The sling dimensions are of 8-10 cm long and 1.5-2 cm wide. The marked fascial strip is then freed off circumferentially from the rectus fascia. The ends of the sling are suspended with 0 polypropylene (Prolene) or polydioxanone (PDS) sutures, one on each side (Figure 2). A linear midline or inverted U-vaginal incision is made at the level of the mid urethra and up to the bladder neck level. The vaginal epithelium is then dissected from the periurethral and

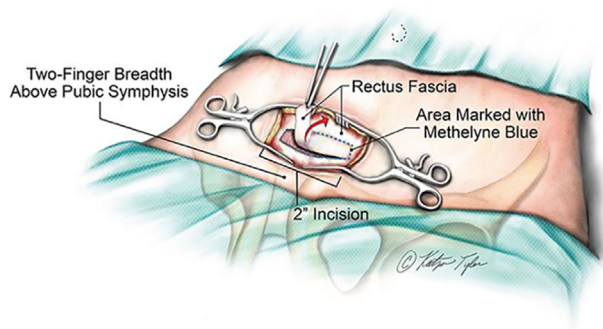


FIGURE 1 Suprapubic incision and exposure of the rectus fascia and the harvest of ARFS

pubocervical fascia till the inferior border of the pubic rami are clearly palpated on each side. At this point, enough space is created to reach the retropubic space. The bladder is then evacuated. Proper needle passers are used and passed from the suprapubic space down into the vaginal incision (Figure 3). Different types of passers have been reported including Stamey needle and McGuire ligature passer.^{11,16} We use the reusable MUS metal passers that have a gutter at the tip, which allows for suture insertion. After the passers are inserted on both sides, we remove the Foley catheter and cystoscopy is performed to rule out bladder and/or urethral perforation. The sling sutures are then inserted into the tip of the passers on each side and the sutures are delivered in an inside-out fashion delivering the sutures to the suprapubic region. The rectus fascial defect is closed with continuous 00_PDS suture. Sling tension is adjusted in a way that the assistant ties the Prolene sutures to each other in the midline over two fingers. During the suture ligature the surgeon observes for the sling tension and location making sure the sling sits loose underneath the mid-urethra. The sling is then secured to the periurethral fascia using 3/0 absorbable sutures (Figure 4). It is only in situations when we encounter severe ISD and when we use the ARFS for creating a bladder outlet obstruction that we allow tight sling positioning. In this later group of patients, we make sure that the patient is comfortable with CIC or has a suitable urinary diversion. We then close the vaginal and abdominal incisions. A vaginal packing and the Foley catheter are left in place. Patient is kept for overnight observation. Both the vaginal packing and the Foley catheter are removed in postoperative Day 1 and a trial of void is performed same day. Patient then discharged home.

4.4 | Effect of ARFS on urodynamic parameters

In one multicenter study that included patients from the SISTEr trial, 655 women who had previously had either

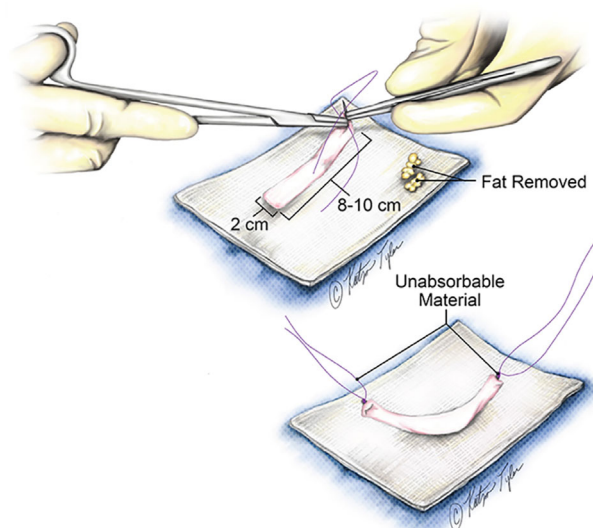


FIGURE 2 Suspension of the sling ends with no absorbable sutures; one on each side

Burch colposuspension or ARFS, had urodynamic studies performed 2 years following their incontinence procedure. Of the 655 patients included, 326 patients received ARFS as their incontinence treatment. There was found significant reduction of the uroflowmetry in both the ARFS and the Burch groups with more reduction in the uroflowmetry in the sling group. The volume at first sensation was significantly increased in both groups, the pressure flow studies showed significant reduction of the Q max with significant increase in the Pdet at Q max in the sling group. There was an increased bladder outlet index in both groups.¹⁷ Similar data were also reported by others.^{18–21}

4.5 | General outcome of ARFS

The overall success rate of the ARFS ranged between 31% and 100%.^{11,22–24} In a recent meta-analysis of 15 855 patients, synthetic MUSs and ARFS, were found to have similar objective cure rates which were superior to Burch colposuspension.²⁵

In a systematic review and meta-analysis comparing different procedures for SUI, the authors found that compared to Burch colposuspension, ARFS results in lower rates of wound infection, bladder or vaginal perforation, and bowel injury. On the other hand, Burch colposuspension tends to have less chance for mesh erosion, urinary retention that indicates intervention, and overactive bladder symptoms.²⁶

Athanasopoulos et al¹⁶ retrospectively reviewed the charts of 264 female patients with SUI and who received ARFS as the primary treatment. The mean follow-up time was 27.8 (12–78) months. Two hundred patients (75.6%) had complete resolution of their SUI, 24 patients (9.1%) had marked improvement but still required one pad daily, and 40

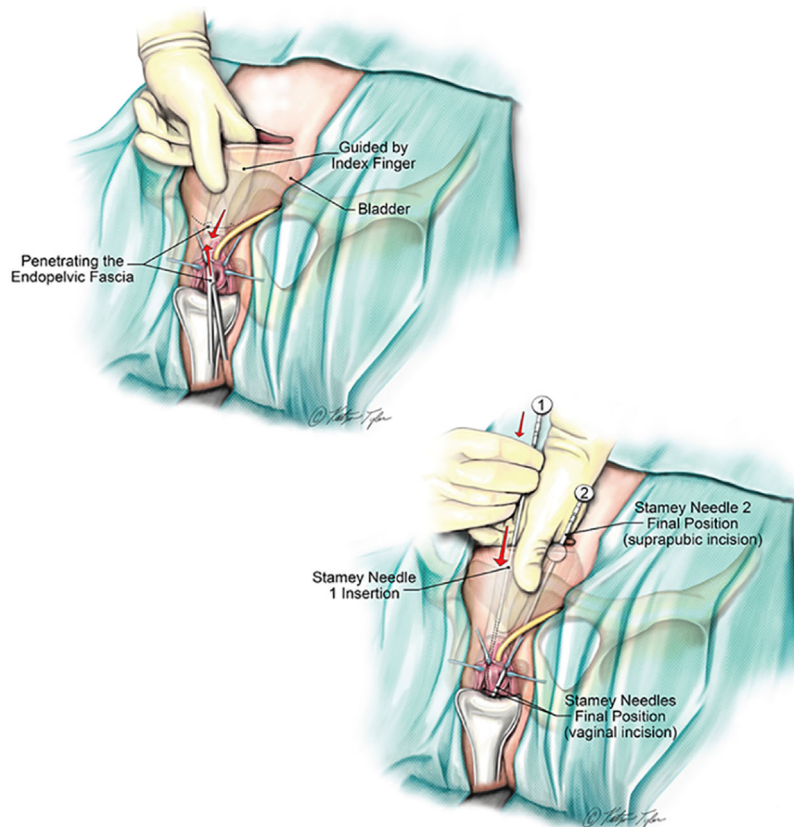


FIGURE 3 Use of Stamey needle for sling delivery

patients (15.2%) failed their procedure. Two hundred and twenty-four patients (84.7%) were satisfied with the procedure outcome. None of the preoperative factors of age, prior anti-incontinence surgery, obesity, menopause, and severity of incontinence, preoperative Valsalva leak point pressure, presence of obstruction during urodynamics, prolapse grade and/or the presence or absence of detrusor overactivity was found to affect the outcome.

In the landmark SISTEr study by Albo et al, 655 patients were randomized for either Burch colposuspension (329 patients) or ARFS (326 patients). The authors found a higher success rate in the ARFS group in any incontinence and in the stress specific incontinence.²⁷ This success was found to be maintained up to 5 years of follow-up (E-SISTEr).²⁸

The outcome of the ARFS compared to the synthetic MUS was also. In a large cohort study that compared ARFS (performed by a urologist) with the synthetic MUS (performed by a gynecologist at the same institute), 242 women were investigated. Seventy-nine women obtained ARFS and 163 women had MUS. At 3-year follow-up, the mid urethral sling showed relatively higher success than the ARFS in any incontinence, severe incontinence, and stress specific incontinence. There was no difference in the complications between the two groups; however, the ARFS group tends to have more incidence of urine retention

requiring CIC, urethrolisis, or prolonged suprapubic tube use.²⁹

Wadie et al³⁰ did a randomized clinical trial of 53 women who had either autologous sling or tension-free vaginal tape. The authors found no significant difference in the cure rates between both groups after 6 months of follow-up.

4.6 | The outcome of ARFS after previous synthetic sling excision

Recurrent SUI after complicated mesh sling release or excision was reported in up to 39% of patients, with 14% of patients need surgery for recurrent SUI after sling excision.³¹ Although another synthetic MUS can be used in those patients, ARFS can be a reasonable alternative. This is with the exception of associated urethral sling erosion; urethro-vaginal fistula or sling related pelvic pain where only ARFS should be used.^{32,33}

The decision to insert an ARFS sling as one stage during the mesh excision procedure or to postpone the ARFS to a later stage has been a matter of debate. In our practice, we advocate concomitant insertion of ARFS during complicated mesh removal when there is an evidence of SUI before the mesh excision procedure. We also favor concomitant insertion of ARFS if extensive periurethral dissection is

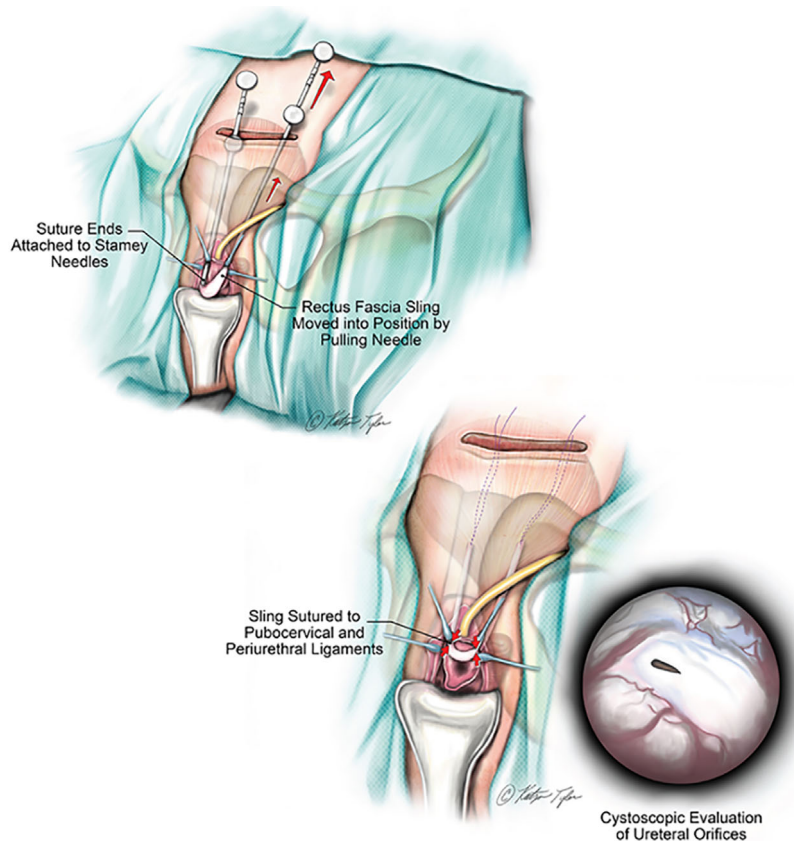


FIGURE 4 ARFS sling positioning

performed during mesh excision, or if the tissue quality is poor. In case when tissue quality is questionable, we use Martius flap. It is imperative to have a detailed discussion with the patient on the pros and cons of one- and two-stage approaches.

In one stage approach, Shah et al reviewed their experience in 21 patients who had removed synthetic MUS. Nineteen out of those 21 patients received ARFS at the same time after excision of complicated synthetic MUS. In this study, 14 patients had their mesh removed for urethral perforation and seven patients had their mesh removed for bladder perforation. Ten out of 14 (71%) urethral perforation and 7 out of 7 (100%) bladder perforation patients were continent after their secondary ARFS. Also in the latter group, there was no further intervention needed. In the other four patients with residual urinary incontinence, one patient had SUI and three patients had urge incontinence after ARFS. Five out of the 14-urethral perforation patients needed additional procedures after the ARFS; one for treatment of urethrovaginal fistula, one for severe SUI (which required a second ARFS), and the other three patients developed urinary retention that subsequently required ARFS sling lysis. Overall, four out of the 21 patients had dyspareunia (Table 1).³⁴

McCoy et al³⁵ reported on patients who underwent ARFS following previous synthetic MUS procedure. The

authors' decision to concomitantly implant the ARFS during mesh excision versus a two-stage procedure was based on the surgeon's preference and patient's choice. Furthermore, patients who had severe SUI or were significantly bothered by it received concomitant ARFS. Forty-six patients were included. Median follow-up was 9.3 months. Objective success was reported in 42 patients (91%). There was 84.6% relative reduction in pad use. Thirty-five (76%) patients perceived subjective success. Six patients developed complications including three accidental intraoperative urethrotomies or cystotomies. Ten patients out of the 46 (22%), needed an average of 1.8 additional procedures after the ARFS. Relative pad reduction was reported in 93% of patients who had concomitant ARFS and 69% in patients who had staged ARFS. There was no significant difference in the subjective success between the two groups, with 93% success in the concomitant ARFS group and 88% success in the staged ARFS group. It has to be noted that patients who had staged ARFS in this study, tend to have associated urethral erosion more likely than those who had concomitant ARFS. This may contribute to the discrepancy in the success between the two groups since there is more tendency for aggressive dissection and hence violation of the continence mechanism in the setting of urethral erosion.

TABLE 1 ARFS after prior sling procedures

Authors	N	Indication for synthetic sling removal	Follow-up in months (median)	Success n/n (%)	Complications n/n (%)	Comments
Shah et al ³⁴	21	Urethral/bladder perforation	6-39 (16)	17/21 (89)	5/21 (24): UVF, urine retention, and recurrent SUI	7/7 (100%) success in bladder perforation group
McCoy et al ³⁵	46	Dyspareunia, refractory MUI or SUI, sling erosion, extrusion, and obstruction	(9.3)	-Objective 42/46 (91) -Subjective 35/46 (76)	6/46 (13)	
Parker et al ³⁶	59	Recurrent SUI, sling extrusion, and sling obstruction	1-124 (14.7)	-Objective cure 32/59 (54.2) -Subjective cure 31/59 (52.5) -Combined objective and subjective: 27/59 (45.8)	-Any 21/59 (35.6) Major: 2/59 (3.4)	Prospective two-center cohort.
Aberger et al ³⁷	71	Failure, extrusion, erosion	12-93 (29)	44/71 (62)	12/71 (17)	-Only 13/71 (18%) patients had previous sling excised -This cohort included patients with failed both prior biological and synthetic slings.

In a prospective two-center study, Parker et al³⁶ compared the outcome of the ARFS in 229 patients who had the ARFS as a primary treatment for their SUI with 59 patients who have previously had MUS. Of the 59 patients who had prior MUS, 34 (57.4%) patients had failed sling with recurrent SUI, 20 (33.9%) patients had sling extrusion and five (8.5%) patients developed sling related obstruction that required sling excision or release. Median follow-up in the study was 14.7 months (1-124). There was found significant improvement in the number of pads used and in the patients' scoring of the validated questionnaires in both groups. There was also similar complication rate between the two groups. Urine retention was more common in patients who had prior MUS (8.5%) compared to the primary ARFS group (3.1%). Patients who had prior MUS in the study tend to obtain more additional incontinence procedures after ARFS (13.6%) than those who had the ARFS as a primary treatment (3.5%).

The outcome of ARFS compared to the synthetic mid urethral sling in the use of patients with recurrent or persistent SUI after previous sling was also looked at. Aberger et al retrospectively investigated the outcome of 224 patients who failed prior MUS and subsequently received either synthetic retropubic MUS (153 patients or 68.3%) or ARFS (71 patients or 31.6%).³⁷ The selection of the incontinence procedure was based on patient's preference with the exception of patients who had sling erosion and who were only offered ARFS. The median follow-up in the study was 29 (minimum of 12) months. There was no difference in the baseline abdominal

leak point pressure between both groups. The overall cure rate was 61.4% in the synthetic sling group and 66.1% in the ARFS group with no significant difference.

4.7 | Complications

The most common two important complications related to the ARFS are de novo urgency and bladder outlet obstruction.

De novo urgency after AFRS is reported in 15-20% of patients.^{16,38} In a study by Athanasopoulos et al,¹⁶ de novo urgency was found in 49 patients (18.5%). Nineteen of those patients (7.2%) had associated urgency incontinence.

De novo urgency after AFRS could be secondary to increased bladder outlet pressure³⁹⁻⁴¹ and disruption of the bladder autonomic nerve supply during dissection.²⁰

Voiding dysfunction and urinary retention after ARFS is relatively higher than MUS with reported urine retention rate between 5% and 20% and voiding difficulty rate between 1.5% and 7.8%.^{16,23,42} Preoperative voiding dysfunction and urodynamic evidence of hypocontractile or acontractile detrusor muscle are reported risk factors.⁴³

The risk for long-term urinary retention is particularly high in patients who tend to strain to void. During straining, angulation of the vesicourethral angle creates bladder outlet obstruction that can worsen voiding dysfunction in those patients.³⁹

Pelvic examination and post-void residual urine volume assessment may help with the diagnosis. Pressure flow studies are of low yield in detection of bladder outlet obstruction after

ARFS. This was supported by others.^{44,45} If pressure flow study is planned, we favor videourodynamics over regular urodynamics in those situations to help detect the level of the obstruction. We found no role for urodynamics in cases of urinary retention after sling procedure. This observation is supported by a study published by Aponte et al.⁴⁶

Different from our early intervention approach to urinary retention after synthetic MUS, we favor observation in case of urinary retention after ARFS for up to 3 months while patient is kept on regular CIC. The sling tension tends to be spontaneously relieved over time probably secondary to gradual loosening of the sling. If urinary retention persists, sling incision with or without urethrolisis can be performed.^{11,47–49}

5 | CONCLUSIONS

ARFS is a reasonable primary treatment option for uncomplicated female SUI. This procedure can also be used after removal of synthetic MUS. We advocate concomitant ARFS at the time of synthetic sling excision in patients who have preoperative SUI, poor tissue quality, and patients who choose to have prophylactic ARFS. ARFS should be considered as a primary option of treatment for female SUI in cases of urethral perforation, following repair of urethrovaginal fistula, in irradiated urethra, and following excision of urethral diverticulum. We also favor ARFS over synthetic MUSs in female SUI associated with chronic pelvic pain. ARFS procedure needs specific level of surgical skills and surgeons who pursue this procedure should obtain sufficient training before performing this surgery.

ORCID

Ayman Mahdy  <http://orcid.org/0000-0002-5069-9345>

REFERENCES

- Deng DY. Urinary incontinence in women. *Med Clin North Am.* 2011;95:101–109.
- Albo ME, Litman HJ, Richter HE, et al. Treatment success of retropubic and transobturator mid urethral slings at 24 months. *J Urol.* 2012;188:2281–2287.
- Wu JM, Gandhi MP, Shah AD, et al. Trends in inpatient urinary incontinence surgery in the USA, 1998–2007. *Int Urogynecol J.* 2011;22:1437–1443.
- Rac G, Younger A, Clemens JQ, et al. Stress urinary incontinence surgery trends in academic female pelvic medicine and reconstructive surgery urology practice in the setting of the food and drug administration public health notifications. *Neurourol Urodyn.* 2017;36:1155–1160.
- Price P. Plastic operation for incontinence of urine and of faeces. *Arch Surg.* 1933;41:11–19.
- Aldridge A. Transplantation of fascia for the relief of urinary stress incontinence. *Am J Obstet Gynecol.* 1942;44:398–411.
- McGuire EJ, Lytton B. Pubovaginal sling procedure for stress incontinence. *J Urol.* 1978;119:82–84.
- McGuire EJ, Wang CC, Usitalo H, Savastano J. Modified pubovaginal sling in girls with myelodysplasia. *J Urol.* 1986;135:94–96.
- Ghoniem G. Modified pubovaginal sling for treatment of complicated stress urinary incontinence in females. *AUA Today.* 1991;4:5–5.
- Blaivas JG, Jacobs BZ. Pubovaginal fascial sling for the treatment of complicated stress urinary incontinence. *J Urol.* 1991;145:1214–1218.
- Ghoniem GaS A. Sub-urethral slings for treatment of stress urinary incontinence. *Int Urogynecol J.* 1994;5:228–239.
- Ghoniem GM, Rizk DEE. Renaissance of the autologous pubovaginal sling. *Int Urogynecol J.* 2018;29:177–178.
- Sarver R, Govier FE. Pubovaginal slings: past, present and future. *Int Urogynecol J Pelvic Floor Dysfunct.* 1997;8:358–368.
- Kobashi KC, Albo ME, Dmochowski RR, et al. Surgical treatment of female stress urinary incontinence: AUA/SUFU guideline. *J Urol.* 2017;198:875–883.
- Enemchukwu E, Lai C, Reynolds WS, Kaufman M, Dmochowski R. Autologous pubovaginal sling for the treatment of concomitant female urethral diverticula and stress urinary incontinence. *Urology.* 2015;85:1300–1303.
- Athanasopoulos A, Gyftopoulos K, McGuire EJ. Efficacy and preoperative prognostic factors of autologous fascia rectus sling for treatment of female stress urinary incontinence. *Urology.* 2011;78:1034–1038.
- Kraus SR, Lemack GE, Richter HE, et al. Changes in urodynamic measures two years after Burch colposuspension or autologous sling surgery. *Urology.* 2011;78:1263–1268.
- Klutke JJ, Klutke CG, Bergman J, Elia G. Urodynamics changes in voiding after anti-incontinence surgery: an insight into the mechanism of cure. *Urology.* 1999;54:1003–1007.
- Bergman A, Elia G. Three surgical procedures for genuine stress incontinence: five-year follow-up of a prospective randomized study. *Am J Obstet Gynecol.* 1995;173:66–71.
- Mitsui T, Tanaka H, Moriya K, Kakizaki H, Nonomura K. Clinical and urodynamic outcomes of pubovaginal sling procedure with autologous rectus fascia for stress urinary incontinence. *Int J Urol.* 2007;14:1076–1079.
- Fulford SC, Flynn R, Barrington J, Appanna T, Stephenson TP. An assessment of the surgical outcome and urodynamic effects of the pubovaginal sling for stress incontinence and the associated urge syndrome. *J Urol.* 1999;162:135–137.
- McGuire EJ, O'Connell HE. Surgical treatment of intrinsic urethral dysfunction. Slings. *Urol Clin North Am.* 1995;22:657–664.
- Chaikin DC, Rosenthal J, Blaivas JG. Pubovaginal fascial sling for all types of stress urinary incontinence: long-term analysis. *J Urol.* 1998;160:1312–1316.
- Morgan TO, Jr., Westney OL, McGuire EJ. Pubovaginal sling: 4-YEAR outcome analysis and quality of life assessment. *J Urol.* 2000;163:1845–1848.
- Fusco F, Abdel-Fattah M, Chapple CR, et al. Updated systematic review and meta-analysis of the comparative data on

- colposuspensions, pubovaginal slings, and midurethral tapes in the surgical treatment of female stress urinary incontinence. *Eur Urol.* 2017;72:567–591.
26. Schimpf MO, Rahn DD, Wheeler TL, et al. Sling surgery for stress urinary incontinence in women: a systematic review and metaanalysis. *Am J Obstet Gynecol.* 2014;211:71 e1–71 e27.
 27. Albo ME, Richter HE, Brubaker L, et al. Burch colposuspension versus fascial sling to reduce urinary stress incontinence. *N Engl J Med.* 2007;356:2143–2155.
 28. Brubaker L, Richter HE, Norton PA, et al. 5-year continence rates, satisfaction and adverse events of burch urethropexy and fascial sling surgery for urinary incontinence. *J Urol.* 2012;187:1324–1330.
 29. Trabuco EC, Klingele CJ, Weaver AL, et al. Medium-term comparison of continence rates after rectus fascia or midurethral sling placement. *Am J Obstet Gynecol.* 2009;200:300 e1–300 e6.
 30. Wadie BS, Edwan A, Nabeeh AM. Autologous fascial sling vs polypropylene tape at short-term followup: a prospective randomized study. *J Urol.* 2005;174:990–993.
 31. Clifton MM, Linder BJ, Lightner DJ, Elliott DS. Risk of repeat anti-incontinence surgery following sling release: a review of 93 cases. *J Urol.* 2014;191:710–714.
 32. Blaivas JG, Purohit RS, Weinberger JM, et al. Salvage surgery after failed treatment of synthetic mesh sling complications. *J Urol.* 2013;190:1281–1286.
 33. Karram M. Biologic bladder neck sling for stress urinary incontinence. In: Walters MD, Karram MM, editors. *Urogynecology and Reconstructive Pelvic Surgery* (4th ed.). Philadelphia: Elsevier Saunders; 2014: Chapter 19: 262–271.
 34. Shah K, Nikolavsky D, Gilsdorf D, Flynn BJ. Surgical management of lower urinary mesh perforation after mid-urethral polypropylene mesh sling: mesh excision, urinary tract reconstruction and concomitant pubovaginal sling with autologous rectus fascia. *Int Urogynecol J.* 2013;24:2111–2117.
 35. McCoy O, Vaughan T, Nickles SW, et al. Outcomes of autologous fascia pubovaginal sling for patients with transvaginal mesh related complications requiring mesh removal. *J Urol.* 2016;196:484–489.
 36. Parker WP, Gomelsky A, Padmanabhan P. Autologous fascia pubovaginal slings after prior synthetic anti-incontinence procedures for recurrent incontinence: a multi-institutional prospective comparative analysis to de novo autologous slings assessing objective and subjective cure. *Neurourol Urodyn.* 2016;35:604–608.
 37. Aberger M, Gomelsky A, Padmanabhan P. Comparison of retropubic synthetic mid-urethral slings to fascia pubovaginal slings following failed sling surgery. *Neurourol Urodyn.* 2016;35:851–854.
 38. Richter HE, Varner RE, Sanders E, et al. Effects of pubovaginal sling procedure on patients with urethral hypermobility and intrinsic sphincteric deficiency: would they do it again? *Am J Obstet Gynecol.* 2001;184:14–19.
 39. Beck RP, Grove D, Arnusch D, Harvey J. Recurrent urinary stress incontinence treated by the fascia lata sling procedure. *Am J Obstet Gynecol.* 1974;120:613–621.
 40. Summitt RL, Jr BA, Ostergard DR, et al. Suburethral sling procedure for genuine stress incontinence and low urethral closure pressure: a continued experience. *Int Urogynecol J Pelvic Floor Dysfunct.* 1992;3:18–21.
 41. Speakman MJ, Sethia KK, Fellows GJ, Smith JC. A study of the pathogenesis, urodynamic assessment and outcome of detrusor instability associated with bladder outflow obstruction. *Br J Urol.* 1987;59:40–44.
 42. Poon C, Zimmern P. When the sling is too proximal: a specific mechanism of persistent stress incontinence after pubovaginal sling placement. *Urology.* 2004;64:287–291.
 43. Webster GD, Kreder KJ. Voiding dysfunction following cystourthropexy: its evaluation and management. *J Urol.* 1990;144:670–673.
 44. Gammie A, Kirschner-Hermanns R, Rademakers K. Evaluation of obstructed voiding in the female: how close are we to a definition? *Curr Opin Urol.* 2015;25:292–295.
 45. Wein AJ. Re: evaluation of obstructed voiding in the female: how close are we to a definition? *J Urol.* 2016;195:1041.
 46. Aponte MM, Shah SR, Hickling D, et al. Urodynamics for clinically suspected obstruction after anti-incontinence surgery in women. *J Urol.* 2013;190:598–602.
 47. Foster HE, McGuire EJ. Management of urethral obstruction with transvaginal urethrolysis. *J Urol.* 1993;150:1448–1451.
 48. McGuire EJ, Letson W, Wang S. Transvaginal urethrolysis after obstructive urethral suspension procedures. *J Urol.* 1989;142:1037–1038; discussion 38–39.
 49. Nitti VW, Raz S. Obstruction following anti-incontinence procedures: diagnosis and treatment with transvaginal urethrolysis. *J Urol.* 1994;152:93–98.

How to cite this article: Mahdy A, Ghoniem GM. Autologous rectus fascia sling for treatment of stress urinary incontinence in women: A review of the literature. *Neurourology and Urodynamics.* 2018;1–8. <https://doi.org/10.1002/nau.23878>