

UC San Diego

UC San Diego Previously Published Works

Title

Prevalence of trochlear dysplasia in infants evaluated for developmental dysplasia of the hip

Permalink

<https://escholarship.org/uc/item/4tq590qt>

Journal

Journal of Children's Orthopaedics, 15(3)

ISSN

1863-2521

Authors

DeVries, Clarabelle A

Hahn, Peter

Bomar, James D

et al.

Publication Date

2021-06-01

DOI

10.1302/1863-2548.15.210018

Peer reviewed

Prevalence of trochlear dysplasia in infants evaluated for developmental dysplasia of the hip

Clarabelle A. DeVries¹

Peter Hahn²

James D. Bomar³

Vidyadhar V. Upasani³

Andrew T. Pennock³

Level of Evidence III

Cite this article: DeVries CA, Hahn P, Bomar JD, Upasani VV, Pennock AT. Prevalence of trochlear dysplasia in infants evaluated for developmental dysplasia of the hip. *J Child Orthop* 2021;15:298-303. DOI: 10.1302/1863-2548.15.210018

Keywords: trochlear dysplasia; developmental dysplasia of the hip

Abstract

Purpose The purpose of this study was to define the incidence of trochlear dysplasia in an infant cohort being screened for developmental dysplasia of the hip (DDH).

Methods Newborns screened for DDH that were evaluated with ultrasound for the presence of trochlear dysplasia were retrospectively reviewed. The sulcus angle and trochlear depth were measured. Based on previous work, trochlear dysplasia was defined as a sulcus angle of $> 159^\circ$. Our newborn cohort was then analyzed to identify potential risk factors for trochlear dysplasia.

Results A total of 383 knees in 196 infants were studied. In total, 52% were referred for breech intrauterine positioning and 21% were ultimately diagnosed with DDH and had treatment initiated with a Pavlik harness. Of the entire cohort, 8% of knees were deemed to have trochlear dysplasia. Breech patients were found to have a flatter sulcus angle than those that were not breech (149.5° (SD 7.2°) versus 147.9° (SD 7.5°); $p = 0.028$). Similarly, a shallower trochlear depth was identified in breech patients versus non-breech patients (1.6 mm (SD 0.4) versus 1.8 mm (SD 0.4); $p = 0.019$). Those with trochlear dysplasia (as defined by sulcus angle $> 159^\circ$) did show a smaller alpha angle (i.e. more dysplastic hip) as compared with those without trochlear dysplasia (59.2° (SD 10.2°) versus 65.9° (SD 7.5°); $p < 0.001$). Hips with DDH were 2.4-times more likely to have knees with trochlear dysplasia (95% confidence interval 1.1 to 5.3).

Conclusion Ultrasound screening of newborn knees reveals that trochlear dysplasia is relatively common in breech babies with DDH.

¹ The University of Chicago Medical Center Chicago, Illinois, USA

² Memorial Care Miller Children's & Women's Hospital, Long Beach, California, USA

³ Rady Children's Hospital, San Diego, California, USA

Correspondence should be sent to Dr. Andrew Pennock, 3020 Children's Way, MC5062, San Diego, California 92123, USA.
Email: apennock@rchsd.org

Introduction

Trochlear dysplasia is characterized by a shallow, flattened trochlear groove in which the patella must articulate. It has a well-established association with recurrent patellar instability with up to 85% of patients with recurrent patellar instability having trochlear dysplasia.¹ Acute patellar dislocations are of relevance to the paediatric orthopaedist in that they are the most common knee disorder in children and adolescents with an incidence of 29 to 43 per 100 000.^{2,3} Beyond patellar instability, trochlear dysplasia may predispose the patellofemoral joint to osteoarthritis as biomechanical studies of trochlear dysplasia have shown that the abnormal anatomy leads to increased contact pressure and abnormal patellofemoral kinematics.⁴

The aetiology of trochlear dysplasia is not well understood. The patellofemoral articulation develops early on in gestation, between nine and 16 weeks. It has been postulated that in a manner similar to the abnormal development of the acetabulum in developmental dysplasia of the hip (DDH), a laterally tracking patella may limit the development of normal trochlear depth and morphology.⁵ Notably, breech presentation and in particular frank breech presentation has been associated with trochlear dysplasia in newborns⁶ further suggesting a potential developmental aetiology to trochlear dysplasia with morphological changes present at birth that remain unchanged over the first six years of life. As such, the purpose of this study was to further define the incidence of trochlear dysplasia in an infant cohort being screened for DDH. We hypothesized that newborn ultrasonography could not only be utilized to screen for trochlear dysplasia, but that trochlear dysplasia would be associated with hip dysplasia and breech positioning.

Materials and methods

Following institutional review board approval, data were retrospectively collected on newborns presenting to our paediatric orthopaedic clinic for screening for DDH over a period of six months (June 12, 2018 to December 13, 2018). Patients were included if they were under the age of seven months at the time of their ultrasound. Patients who did not have the ability to flex their knees to 90° so that an adequate ultrasound could be obtained were excluded. Demographic data were collected including age and sex as well as reason for referral, foetal presentation (vertex *versus* breech) and treatment plan for the hip. During the ultrasonographic examination of the infant's hips, our institution routinely performs a concurrent ultrasonographic examination of the knees to assess for anomalous morphology of the patellofemoral joint. The knee ultrasound was performed with a Fujifilm Sonosite 15 MHz multi-frequency, broadband, linear transducer (Bothell, WA, USA) oriented with the probe transverse to the axis of the leg. The image was centered on the ossific nucleus of the distal femur and oriented such that both unossified femoral condyles were visible (Fig. 1). The hip ultrasound was performed using the Graf technique.^{7,8} All ultrasounds were performed by a single ultrasound technologist with over 25 years of experience in paediatric orthopaedic ultrasound.

The sulcus angle of the trochlea was measured from the nadir of the trochlea along best fit lines of the medial and lateral walls of the trochlea. Trochlear depth was assessed as the perpendicular distance from a line that passed tangentially through the apices of the medial and lateral trochlea to the nadir of the trochlear sulcus (Fig. 2). Trochlear dysplasia was considered present if the sulcus angle was $\geq 159^\circ$ based on the work of Øye et al.⁶ Sulcus angle, trochlear depth, femoral head coverage and alpha angle were measured on ultrasound. All measurements were performed by a single orthopaedic surgeon (PH) during his paediatric orthopaedic fellowship year. A subset of 20 hips and knees were remeasured by the senior author (ATP), a fellowship-trained paediatric orthopaedic surgeon with over ten years in practice. The intraclass correlation coefficient (ICC) was used to evaluate the reproducibility of the ultrasound measurements between the fellow and the senior author. ICC values were graded from poor to excellent using the parameters set forth by Koo and Li.⁹ As seen in Table 1, the alpha angle proved to be the least reproducible measurement, sulcus angle was found to have moderate reproducibility and trochlear depth and femoral head coverage was found to have good reproducibility.

Statistical analysis

Basic descriptive statistics are presented. Mean values are presented with sd, unless stated otherwise. The unit

of analysis was the knee. Continuous data was evaluated with the Shapiro-Wilk test of normality. Data found to be normally distributed with the Shapiro-Wilk test was evaluated with Levene's test of homogeneity of variances. Continuous data found to be normal with both tests was analyzed with analysis of variance, non-normally distributed data was analyzed with the Mann-Whitney U test. Categorical data was evaluated with Pearson's chi-squared or Fisher's exact test. No *a priori* power analysis was performed. All analysis was performed using IBM SPSS Statistics (version 25, IBM Corp, Armonk, New York). An alpha of 0.008 was the threshold to declare significance due to the number of hypotheses tested in order to maintain an overall study alpha of 0.05.

Results

A total of 383 knees in 196 infants were studied. Mean age of our cohort at the time of their ultrasound was 1.9 months (sd 1.1; 0.2 to 6.9). In all, 60% of the patients were female. A total of 52% were referred for breech intrauterine positioning, whilst 21% of patients were diagnosed with acetabular dysplasia and had treatment initiated with a Pavlik harness. In total, 30 knees (8%) were found to have trochlear dysplasia and three patients had bilateral trochlear dysplasia.

Patients that were breech position were found to have a larger sulcus angle than those that were not breech (149.5° (sd 7.2°) *versus* 147.9° (sd 7.5°); $p = 0.03$). Similarly, a smaller trochlear depth was also identified in breech patients *versus* non breech patients (1.6 mm (sd 0.4) *versus* 1.8 mm (sd 0.4); $p = 0.022$). However, these differences failed to reach statistical significance. While there was no significant difference in sulcus angle or trochlear depth with the presence or absence of DDH, those with trochlear dysplasia (as defined by sulcus angle $> 159^\circ$) did show a smaller alpha angle (i.e. more dysplastic hip) as compared with those without trochlear dysplasia (59.2° (sd 10.2°) *versus* 65.9° (sd 7.5°); $p < 0.001$) and a trend towards smaller percentage femoral head coverage (Table 2). In total, 11 of 79 hips with DDH (14%) were found to have trochlear dysplasia. Hips with DDH were noted to be 2.4-times (95% confidence interval 1.1 to 5.3) more likely to have knees with trochlear dysplasia than hips without DDH ($p = 0.024$).

As expected, we observed that sulcus angle was inversely correlated with trochlear depth ($r_s = -0.803$; $p < 0.001$) such that patients with elevated sulcus angles (flatter grooves) also had shallower trochlear depths. Additionally, we found a weak inverse relationship between sulcus angle and alpha angle ($r_s = -0.156$; $p = 0.002$) with patients having more severe trochlear dysplasia also having increased acetabular dysplasia.

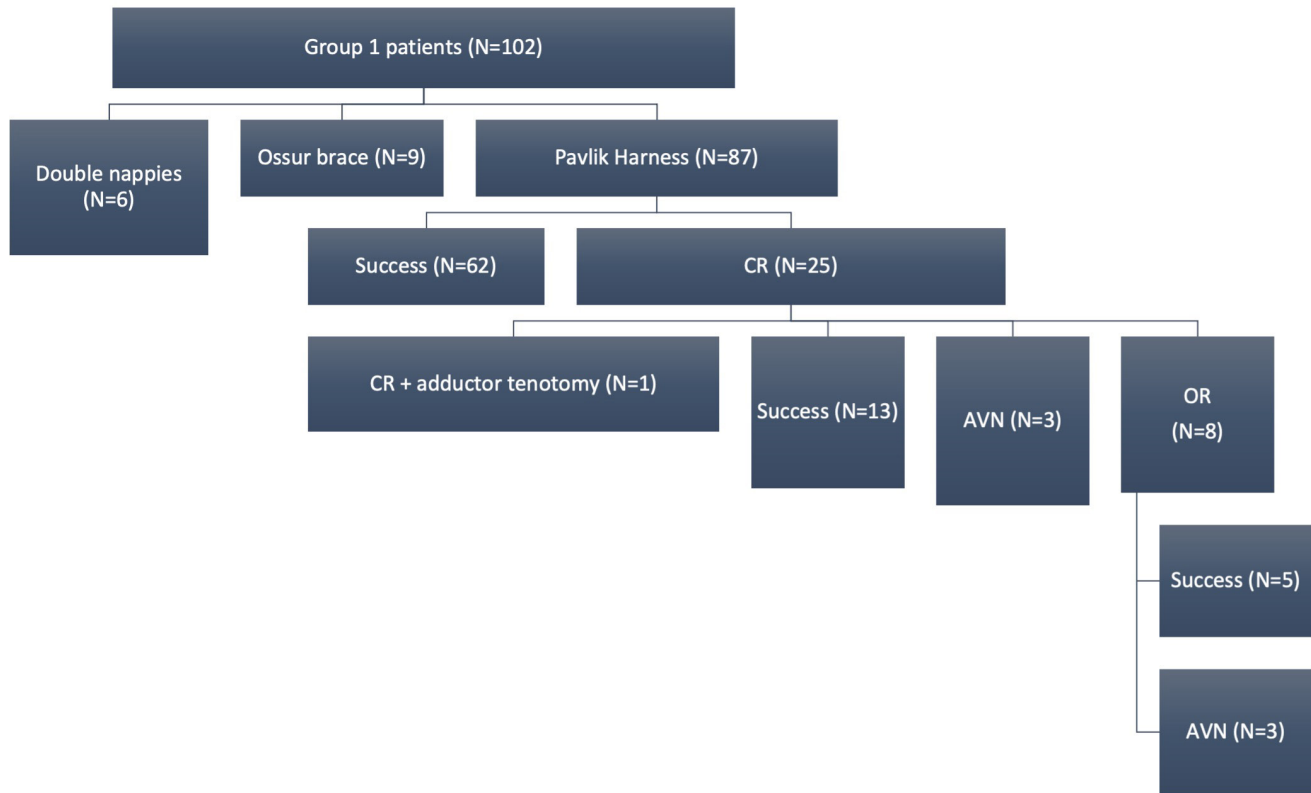


Fig. 1 Line drawing indicating the position of the ultrasound probe when performing the evaluation of the trochlea.

Discussion

The results of the current study demonstrate that ultrasonography can be employed to assess trochlear morphology in newborns that are being screened for acetabular dysplasia. Furthermore, our data would suggest a weak relationship between trochlear dysplasia and breech positioning as well as acetabular dysplasia (assessed by the alpha angle). However, the magnitude of these relationships and their clinical implications may require further, prospective, studies.

Regarding trochlear development, Gray and Gardner^{10,12} demonstrated via dissections of 45 embryos and fetuses that the patella and patellofemoral articulation are formed by eight to ten weeks. Subsequent biometric data of both adult and foetal patellofemoral joints showed that the morphology does not change significantly through development and maturity.^{11,12,13,14} Given that trochlear morphology appears well established in the prenatal period, it is conceivable that an intrauterine

developmental process may lend itself to the aetiology of trochlear dysplasia.

Breech positioning has been demonstrated to correlate with the presence of trochlear dysplasia⁶ and was re-demonstrated in our findings with 60% of patients with trochlear dysplasia having been breech presentation. Additionally, breech presentation was found to be more generally associated with a greater sulcus angle. While not elucidated in our medical records, footling and frank breech presentation may play a role in the development of trochlear dysplasia. In these foetal presentations, one or both knees are extended and together account for 85% to 90% of breech presentations.^{13,15} It is well known that the patella does not engage the trochlear groove until 30° of knee flexion and as such, these presentations would result in the patella lying proximal to the trochlea during foetal development. It is conceivable that without the consistent engagement of the patella in the trochlea, a shallower trochlear morphology could develop, similar to the pathological process noted in DDH where a subluxated

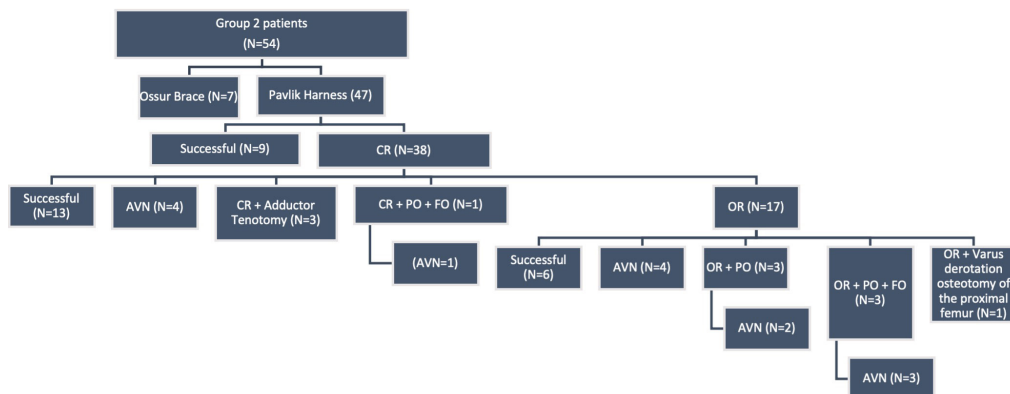


Fig. 2 Top) illustration of the sulcus angle measurement; bottom) illustration of the trochlear depth measurement.

Table 1 Measurement reproducibility

	ICC	95%CI: lower	95%CI: upper	p-value
Sulcus angle	0.673	0.351	0.855	p < 0.001
Trochlear depth	0.805	0.57	0.918	p < 0.001
Femoral head coverage	0.886	0.736	0.953	p < 0.001
Alpha angle	0.469	-0.083	0.783	p < 0.001

ICC, intraclass correlation coefficient; CI, confidence interval

or dislocated femoral head precipitates the development of a shallow and abnormal acetabulum. Interestingly, we identified a weak relationship between hip dysplasia (alpha angle) and trochlear dysplasia (sulcus angle) showing that these entities may develop concomitantly. Fu et al^{14,16} described an improvement in trochlear morphology in skeletally immature patients that underwent soft-tissue procedures for recurrent patellar dislocations in the setting of trochlear dysplasia with comparison with the contralateral knee that was treated conservatively. These results further lend themselves to the concept of trochlear dysplasia being a developmental versus congenital process.

The diagnosis of DDH as well as a smaller alpha angle of the acetabulum as measured on ultrasound were cor-

related with the presence of trochlear dysplasia. While evaluated in a skeletally mature population, Li et al^{15,17} showed a similar relationship between the presence of DDH and morphological changes in the knee joint, including a larger groove angle as compared with a control group. Breech positioning may have played a role in the aetiology of both these conditions, but other factors potentially influence their correlation. Abnormal soft-tissue laxity has been established in the DDH population and its role described in the aetiology of hip instability. By the same token, soft-tissue laxity can influence the stability of the patella in the trochlea and potentiate abnormal development of the trochlea if the patella does not track normally.

Given that trochlear dysplasia may be a developmental process, it is plausible that early diagnosis in the neonatal period would allow for intervention in a fashion similar to DDH. A theoretical treatment option would be to initiate use of a Pavlik harness that would maintain the knees in a position of flexion and use the patella to help mold the trochlea in a fashion similar to how Pavlik treatment uses the femoral head to mold the acetabulum. Further research is necessary to determine if this a true effect of the Pavlik harness use.

Table 2 Age and imaging findings by breech, trochlear dysplasia, and developmental dysplasia of the hip (DDH)

	*Mean age, mths (sd)	**Mean sulcus angle, ° (sd)	*Mean trochlear depth, mm (sd)	*Mean femoral head coverage, % (sd)	*Mean alpha angle, ° (sd)
Breech (n = 196)	1.9 (0.9)	149.5 (7.2)	1.6 (0.4)	0.59 (0.09)	65.4 (6.7)
Non-breech (n = 187)	2.0 (1.3)	147.9 (7.5)	1.8 (0.4)	0.58 (0.11)	65.4 (9.1)
p-value	0.441	0.028	0.019	0.893	0.19
Trochlear dysplasia	1.7 (1.0)	161.8 (2.3)	1.0 (0.2)	0.53 (0.18)	59.2 (10.2)
No trochlear dysplasia	2.0 (1.2)	147.6 (6.5)	1.8 (0.4)	0.59 (0.09)	65.9 (7.5)
p-value	0.183	< 0.001	< 0.001	0.056	< 0.001
DDH	1.9 (1.2)	150.0 (7.6)	1.6 (0.4)	0.51 (0.17)	58.0 (11.1)
No DDH	1.9 (1.1)	148.4 (7.3)	1.7 (0.4)	0.61 (0.06)	67.3 (5.5)
p-value	0.452	0.07	0.096	< 0.001	< 0.001

*Mann-Whitney U, **ANOVA

There are limitations to this study. The definition of trochlear dysplasia in newborns has not been widely validated in large studies. Compounding this is the operator-dependent nature of ultrasound image acquisition that potentially obfuscates accurate and precise diagnosis of trochlear dysplasia. We have observed that small alterations in the probe angle, or location, can alter the measurements used in this study. In addition to the variability that can exist between ultrasonographers during the acquisition of the ultrasound, there is also measurement error as noted in our ICC results. To decrease variability in acquisition and measurement all ultrasounds were performed by the same person. Similarly, all measurements were made by the same person. There was also some variability in the criteria to diagnose DDH, dependent on the treating physician. Finally, there is inherent recall bias on the part of the parents regarding foetal presentation and due to the retrospective nature of this study, we were unable to record data pertaining to family history of knee pain/instability or other useful data such as femoral version and ligamentous laxity. Future studies are needed to examine older subject populations to determine the rates of trochlear dysplasia in early adolescence and adulthood.

In summary, both breech positioning and the diagnosis of DDH were independently associated with markers of trochlear dysplasia, i.e. elevated sulcus angle and decreased trochlear depth. This relationship suggests a potential development aetiology of trochlear dysplasia.

Received 29 January 2021, accepted after revision 23 April 2021.

COMPLIANCE WITH ETHICAL STANDARDS

FUNDING STATEMENT

No benefits in any form have been received or will be received from a commercial party related directly or indirectly to the subject of this article.

OA LICENCE TEXT

This article is distributed under the terms of the Creative Commons Attribution-Non Commercial 4.0 International (CC BY-NC 4.0) licence (<https://creativecommons.org/licenses/by-nc/4.0/>) which permits non-commercial use, reproduction and distribution of the work without further permission provided the original work is attributed.

ETHICAL STATEMENT

Ethical approval: All procedures performed in studies involving human participants were in accordance with the ethical standards of the institutional and/or national research committee and with the 1964 Helsinki declaration and its later amendments or comparable ethical standards.

Informed consent: This study was reviewed and approved by our institutional review board and determined that written consent was not required for this study.

ICMJE CONFLICT OF INTEREST STATEMENT

Each author certifies that he or she has no commercial associations (e.g. consultancies, stock ownership, equity interest, patent/licensing arrangements, etc) that might pose a conflict of interest in connection with the submitted article.

Authors CAD, PH, and JDB have nothing to disclose.

VVU has the following disclosures: BroadWater (paid presenter or speaker); DePuy, A Johnson & Johnson Company (paid presenter or speaker); EOS Imaging (research support); Globus Medical (paid consultant); Imagen (stock or stock options); Indius (paid consultant); Nuvasive: (paid presenter or speaker); nView (research support); OrthoPediatics (IP royalties, paid consultant, paid presenter or speaker and research support); Wolters Kluwer Health – Lippincott Williams & Wilkins (publishing royalties, financial or material support).

ATP has the following disclosures: Paid consultant for Orthopediatrics Wolters Kluwer Health – Lippincott Williams & Wilkins (publishing royalties, financial or material support).

AUTHOR CONTRIBUTIONS

PH: Study design, Data acquisition, Interpretation of data.

VVU: Interpretation of data.

ATP: Interpretation of data.

JDB: Data acquisition, Analysis.

CAD: Interpretation of data.

ACKNOWLEDGMENTS

The authors would like to thank single ultrasound technologist, Natalie McNeil, BS, RMSKS, RT, for performing all the ultrasounds conducted in this study.

REFERENCES

1. **Dejour H, Walch G, Nove-Josserand L, Guier C.** Factors of patellar instability: an anatomic radiographic study. *Knee Surg Sports Traumatol Arthrosc* 1994;2: 19-26.
2. **Nietosvaara Y, Aalto K, Kallio PE.** Acute patellar dislocation in children: incidence and associated osteochondral fractures. *J Pediatr Orthop* 1994;14:513-515.
3. **Fithian DC, Paxton EW, Stone ML, et al.** Epidemiology and natural history of acute patellar dislocation. *Am J Sports Med* 2004;32:1114-1121.

4. **Van Haver A, De Roo K, De Beule M, et al.** The effect of trochlear dysplasia on patellofemoral biomechanics: a cadaveric study with simulated trochlear deformities. *Am J Sports Med* 2015;43:1354-1361.
5. **Bollier M, Fulkerson JP.** The role of trochlear dysplasia in patellofemoral instability. *J Am Acad Orthop Surg* 2011;19:8-16.
6. **Øye CR, Foss OA, Holen KJ.** Breech presentation is a risk factor for dysplasia of the femoral trochlea. *Acta Orthop* 2016;87:17-21.
7. **Graf R.** *Hip sonography: diagnosis and management of infant hip dysplasia*. 2nd ed. Cham, Springer-Verlag, 2006.
8. **Edmonds EW, Hughes JL, Bomar JD, Brooks JT, Upasani VV.** Ultrasonography in the Diagnosis and Management of Developmental Dysplasia of the Hip. *JBSJ Rev* 2019;7:e5.
9. **Koo TK, Li MY.** A guideline of selecting and reporting intraclass correlation coefficients for reliability research. *J Chiropr Med* 2016;15:155-163.
10. **Gray DJ, Gardner E.** Prenatal development of the human knee and superior tibiofibular joints. *Am J Anat* 1950;86:235-287.
11. **Glard Y, Jouve J-L, Garron E, et al.** Anatomic study of femoral patellar groove in fetus. *J Pediatr Orthop* 2005;25:305-308.
12. **Wanner JA.** Variations in the anterior patellar groove of the human femur. *Am J Phys Anthropol* 1977;47:99-102.
13. **Gibbs RS, Danforth DN, eds.** *Danforth's obstetrics and gynecology*. 10th ed. Philadelphia, Wolters Kluwer Lippincott Williams & Wilkins, 2008.
14. **Fu K, Duan G, Liu C, Niu J, Wang F.** Changes in femoral trochlear morphology following surgical correction of recurrent patellar dislocation associated with trochlear dysplasia in children. *Bone Joint J* 2018;100-B:811-821.
15. **Li H, Qu X, Wang Y, Dai K, Zhu Z.** Morphological analysis of the knee joint in patients with hip dysplasia. *Knee Surg Sports Traumatol Arthrosc* 2013;21:2081-2088.