

UCLA

Proceedings of UCLA Health

Title

Thyrototoxicosis Induced Non-Cardiogenic Pulmonary Edema Requiring Extracorporeal Membrane Oxygenation

Permalink

<https://escholarship.org/uc/item/4td5z4rf>

Journal

Proceedings of UCLA Health, 24(1)

Authors

Custer, Adam

Chirra, Annapoorna

Sah, Birenda

Publication Date

2020-04-14

CLINICAL VIGNETTE

Thyrotoxicosis Induced Non-Cardiogenic Pulmonary Edema Requiring Extracorporeal Membrane Oxygenation

Adam Custer, MD¹, Annapoorna Chirra, MD¹ and Birenda Sah, MD²

¹UCLA Department of Medicine

²SUNY Upstate Medical University

Case

A 44-year-old female with DM2, Graves' disease and Asthma presented to the emergency department with 2-3 days of flu-like symptoms. She was in respiratory distress and initial Vital signs included BP 175/99, HR 130/min, RR 36/min, with 60-70% O₂ sat on room air. Initial labs included leukocytosis of 29k/uL and lactic acid of 6.6 mmol/L. Chest X-ray showed diffuse bilateral infiltrates (Figure 1). She was thought to have acute pulmonary edema and treated with high dose furosemide and BiPAP support. Her initial arterial blood gas (ABG) showed a pH 7.3, PCO₂ 42 mmHg, PO₂ 82 mmHg, and SaO₂ 95% while on BiPAP. Over the next two hours she remained persistently tachypneic with a respiratory rate between 36 and 45. Because of concerns of respiratory fatigue, she was intubated and started on mechanical ventilation. Serial ABGs revealed persistent hypoxia, hypercapnia, and respiratory acidosis despite mechanical ventilation (Table I), so thoracic surgery was consulted and started veno-venous ECMO. Because of her rapid worsening despite diuresis, worsening bilateral infiltrates on CXR, and a PaO₂/FiO₂ ratio of 201 she was thought to have concomitant ARDS and started on Airway Pressure Release Ventilation (APRV) mode. Return of additional tests raised concern for thyroid storm with Thyroid Stimulating Hormone (TSH) < 0.03 mU/L and elevated free T₃ >20 ng/dL and free T₄ >4.5 ng/dL. Her Burch-Wartofsky score for thyrotoxicosis was 40. Respiratory viral and vasculitis panels were negative and Bronchoalveolar Lavage (BAL) was negative for viral, bacterial, or fungal organisms. Transesophageal echocardiogram showed mild left ventricular hypertrophy and Pro B-type Natriuretic Peptide (Pro-BNP) was elevated at 1288 pg/mL. She was treated with diuresis, Propylthiouracil (PTU), IV steroids, iodine drops, propranolol, and cholestyramine as well as empiric antibiotics for community acquired pneumonia. Her respiratory failure rapidly improved while on ECMO, with improving lactic acid and she was successfully decannulated and extubated on hospital day 7. However, her thyroiditis persisted despite medical management and she ultimately required two rounds of therapeutic plasmapheresis and a thyroidectomy (Figure 2). After a month long hospitalization, plasmapheresis, and thyroidectomy, the patient was successfully discharged to a rehabilitation facility.

Discussion

Graves' disease is the most common etiology of thyrotoxicosis and thyroid storm is an uncommon, life-threatening complication. Signs and symptoms include fever, tachycardia, tremor, diarrhea, altered mental status, and heart failure. However, it can also cause multiple organ failure.⁵ Diagnosis is based on signs and symptoms in the setting of elevated free T₄/T₃ with suppressed TSH. The Burch and Wartofsky scoring system has been proposed to assist with the diagnosis. A score of >45 is highly suggestive of thyroid storm and a score of <25 makes the diagnosis unlikely.⁶ Treatment typically occurs in the ICU and includes beta blockers, thionamide, iodine, and glucocorticoids which decrease new hormone synthesis, inhibit the release of existing hormone, and block the peripheral effects of thyroid hormone.^{1,7} A bile acid sequestrant may also be added in severe cases to reduce enterohepatic recycling of thyroid hormones.⁸ In severe cases, studies have shown clinical utility of ECMO for cardiopulmonary support.⁹ This disease is associated with significant mortality, with risk factors including: age >60, CNS dysfunction, mechanical ventilation, and non-use of anti-thyroid drugs or beta blockers.³

This case has several aspects for discussion. The etiology of the patient's pulmonary edema, the concern for concomitant ARDS, and the decision to employ ECMO. The patient was initially thought to have acute cardiogenic pulmonary edema from thyrotoxicosis induced cardiac decompensation. However, the echocardiogram, Pro-BNP, and evolution of the case support a diagnosis of non-cardiogenic pulmonary edema due to thyrotoxicosis. ARDS features include diffuse bilateral opacities on imaging, PaO₂/FiO₂ ratio of 201, and rapid decline in spite of diuresis. The relatively rapid resolution was not consistent with the typical ARDS course with alveolar destruction, and her improvement may have been due to resolution of her overlying non-cardiogenic pulmonary edema.¹⁰ Regarding the use of ECMO, the patient had persistent hypoxia, hypercapnia, and acidosis despite mechanical ventilation. This prompted consultation with cardiothoracic surgery and initiation of veno-venous ECMO.

While there are other plausible etiologies for the patient's ARDS, the role of thyrotoxicosis merits further discussion. Thyrotoxicosis may contribute to ARDS directly through the

pulmonary vasculature. Thyroglobulin aggregation in the pulmonary microcirculation was proposed as cause of ARDS in a patient with metastatic papillary cell carcinoma.¹¹ Thyrotoxicosis may also affect surfactant production through hormonal effects. Several studies have demonstrated the role of thyroid transcription factor-1 in surfactant protein production.^{12,13} Another possible mechanism is an antibody mediated immune response in the setting of Graves' Disease. TSH receptors are located in a variety of cells throughout the body including fibroblasts in the lungs.^{14,15} Furthermore, thyroid hormone levels have been shown to be predictive of mortality rates in patients with ARDS.¹⁶

In summary, this patient presented with flu-like symptoms, was found to have thyrotoxicosis with non-cardiogenic pulmonary edema and concomitant ARDS requiring intubation and seven days of veno-venous ECMO support. This was an atypical presentation with a wide differential including CHF exacerbation, pulmonary edema due to thyrotoxicosis, community acquired pneumonia, and ARDS. Thyroid storm in this setting presents a diagnostic challenge. It also highlights how thyroid storm is a true endocrine emergency with life-threatening complications, which may include ARDS.

Data Table I: Serial ABGs

Clinical Setting	pH	PCO2 (mmHg)	PO2 (mmHg)	HCO3- (mEq/L)	SaO2 (%)	FiO2 (%)
Pre-Intubation on BiPAP	7.3	42	82	21	95	0.21
Post-Intubation	7.04	93	201	27	99	1.0
2 Hours Post-Intubation	7.02	96	221	27	98	1.0
Post-Cannulation for ECMO	7.14	74	79	27	94	0.7
3 Hours After Placement on ECMO	7.38	40	60	24	93	0.4

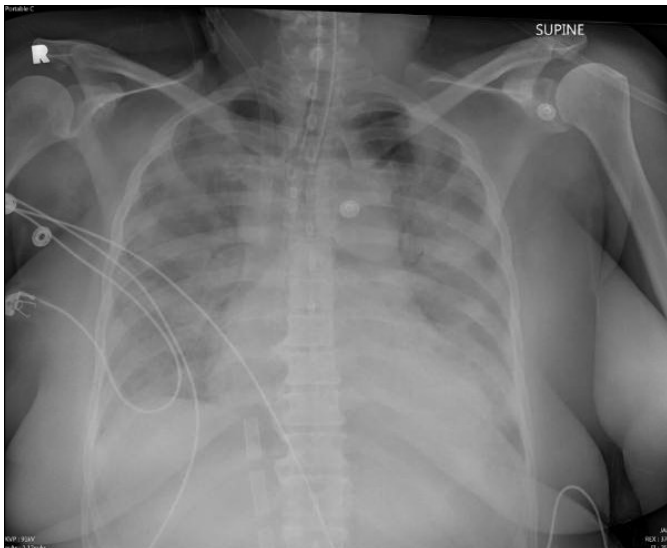

Figure 1: Chest X-ray on day of admission showing extensive diffuse airspace opacification with left retrocardiac opacification consistent with pulmonary edema, pulmonary hemorrhage, pneumonia, or ARDS.

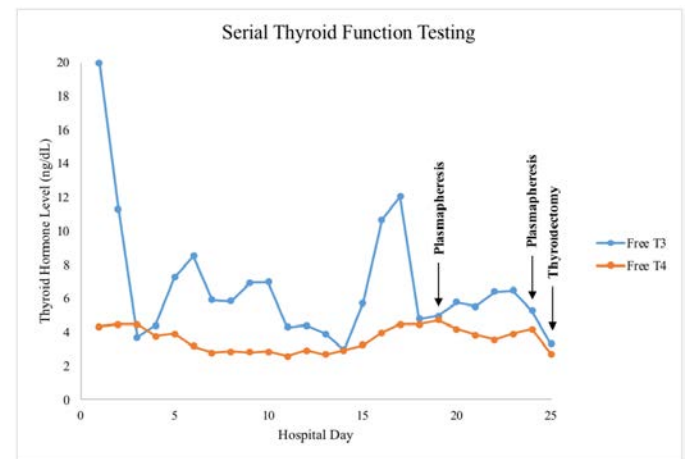


Figure 2: Graph showing the trend of thyroid hormone levels throughout the hospitalization. Arrows indicate plasmapheresis on hospital days 19 and 24 and thyroidectomy was on hospital day 25.

REFERENCES

- Akamizu T, Satoh T, Isozaki O, Suzuki A, Wakino S, Iburi T, Tsuboi K, Monden T, Kouki T, Otani H, Teramukai S, Uehara R, Nakamura Y, Nagai M, Mori M; Japan Thyroid Association.** Diagnostic criteria, clinical features, and incidence of thyroid storm based on nationwide surveys. *Thyroid*. 2012 Jul;22(7):661-79. doi: 10.1089/thy.2011.0334. Epub 2012 Jun 12. Erratum in: *Thyroid*. 2012 Sep;22(9):979. PubMed PMID: 22690898; PubMed Central PMCID: PMC3387770.
- Akamizu T.** Thyroid Storm: A Japanese Perspective. *Thyroid*. 2018 Jan;28(1):32-40. doi: 10.1089/thy.2017.

243. Epub 2017 Oct 5. Review. PubMed PMID: 28899229; PubMed Central PMCID: PMC5770119.
3. **Ono Y, Ono S, Yasunaga H, Matsui H, Fushimi K, Tanaka Y.** Factors Associated With Mortality of Thyroid Storm: Analysis Using a National Inpatient Database in Japan. *Medicine (Baltimore)*. 2016 Feb;95(7):e2848. doi: 10.1097/MD.0000000000002848. PubMed PMID: 26886648; PubMed Central PMCID: PMC4998648.
 4. **Swee du S, Chng CL, Lim A.** Clinical characteristics and outcome of thyroid storm: a case series and review of neuropsychiatric derangements in thyrotoxicosis. *Endocr Pract*. 2015 Feb;21(2):182-9. doi: 10.4158/EP14023.OR. Review. PubMed PMID: 25370315.
 5. **Kiriyama H, Amiya E, Hatano M, Hosoya Y, Maki H, Nitta D, Saito A, Shiraishi Y, Minatsuki S, Sato T, Murakami H, Uehara M, Manaka K, Makita N, Watanabe M, Komuro I.** Rapid Improvement of thyroid storm-related hemodynamic collapse by aggressive anti-thyroid therapy including steroid pulse: A case report. *Medicine (Baltimore)*. 2017 Jun;96(22):e7053. doi: 10.1097/MD.0000000000007053. PubMed PMID: 28562568; PubMed Central PMCID: PMC5459733.
 6. **Burch HB, Wartofsky L.** Life-threatening thyrotoxicosis. Thyroid storm. *Endocrinol Metab Clin North Am*. 1993 Jun;22(2):263-77. Review. PubMed PMID: 8325286.
 7. **Nayak B, Burman K.** Thyrotoxicosis and thyroid storm. *Endocrinol Metab Clin North Am*. 2006 Dec;35(4):663-86, vii. Review. PubMed PMID: 17127140.
 8. **Solomon BL, Wartofsky L, Burman KD.** Adjunctive cholestyramine therapy for thyrotoxicosis. *Clin Endocrinol (Oxf)*. 1993 Jan;38(1):39-43. PubMed PMID: 8435884.
 9. **Chao A, Wang CH, You HC, Chou NK, Yu HY, Chi NH, Huang SC, Wu IH, Tseng LJ, Lin MH, Chen YS.** Highlighting Indication of extracorporeal membrane oxygenation in endocrine emergencies. *Sci Rep*. 2015 Aug 24;5:13361. doi: 10.1038/srep13361. PubMed PMID: 26299943; PubMed Central PMCID: PMC4547135.
 10. **Matthay MA.** Resolution of pulmonary edema. Thirty years of progress. *Am J Respir Crit Care Med*. 2014 Jun 1;189(11):1301-8. doi: 10.1164/rccm.201403-0535OE. PubMed PMID: 24881936; PubMed Central PMCID: PMC4098087.
 11. **Elshafie O, Hussein S, Jeans WD, Woodhouse NJ.** Massive rise in thyroglobulin with adult respiratory distress syndrome after embolisation of thyroid cancer metastasis. *Br J Radiol*. 2000 May;73(869):547-9. PubMed PMID: 10884754.
 12. **Das A, Acharya S, Gottipati KR, McKnight JB, Chandru H, Alcorn JL, Boggaram V.** Thyroid transcription factor-1 (TTF-1) gene: identification of ZBP-89, Sp1, and TTF-1 sites in the promoter and regulation by TNF- α in lung epithelial cells. *Am J Physiol Lung Cell Mol Physiol*. 2011 Oct;301(4):L427-40. doi: 10.1152/ajplung.00090.2011. Epub 2011 Jul 22. Erratum in: *Am J Physiol Lung Cell Mol Physiol*. 2011 Dec;301(6):L1003. PubMed PMID: 21784970; PubMed Central PMCID: PMC3191750.
 13. **Hamvas A, Deterding RR, Wert SE, White FV, Dishop MK, Alfano DN, Halbower AC, Planer B, Stephan MJ, Uchida DA, Williams LD, Rosenfeld JA, Lebel RR, Young LR, Cole FS, Noguee LM.** Heterogeneous pulmonary phenotypes associated with mutations in the thyroid transcription factor gene NKX2-1. *Chest*. 2013 Sep;144(3):794-804. doi: 10.1378/chest.12-2502. PubMed PMID: 23430038; PubMed Central PMCID: PMC3760742.
 14. **Davies TF, Ando T, Lin RY, Tomer Y, Latif R.** Thyrotropin receptor-associated diseases: from adenomata to Graves disease. *J Clin Invest*. 2005 Aug;115(8):1972-83. Review. PubMed PMID: 16075037; PubMed Central PMCID: PMC1180562.
 15. **Latif R, Morshed SA, Zaidi M, Davies TF.** The thyroid-stimulating hormone receptor: impact of thyroid-stimulating hormone and thyroid-stimulating hormone receptor antibodies on multimerization, cleavage, and signaling. *Endocrinol Metab Clin North Am*. 2009 Jun;38(2):319-41, viii. doi: 10.1016/j.ecl.2009.01.006. Review. PubMed PMID: 19328414.
 16. **Türe M, Memiş D, Kurt I, Pamukçu Z.** Predictive value of thyroid hormones on the first day in adult respiratory distress syndrome patients admitted to ICU: comparison with SOFA and APACHE II scores. *Ann Saudi Med*. 2005 Nov-Dec;25(6):466-72. PubMed PMID: 16438455; PubMed Central PMCID: PMC6089744.