

UCSF

UC San Francisco Previously Published Works

Title

Cervicothoracic Versus Proximal Thoracic Lower Instrumented Vertebra Have Comparable Radiographic and Clinical Outcomes in Adult Cervical Deformity.

Permalink

<https://escholarship.org/uc/item/4sx763g2>

Journal

Global spine journal, 13(4)

ISSN

2192-5682

Authors

Kim, Han Jo
Yao, Yu-Cheng
Bannwarth, Mathieu
[et al.](#)

Publication Date

2023-05-01

DOI



10.1177/21925682211017478

Copyright Information

This work is made available under the terms of a Creative Commons Attribution-NonCommercial-NoDerivatives License, available at <https://creativecommons.org/licenses/by-nc-nd/4.0/>

Peer reviewed

Cervicothoracic Versus Proximal Thoracic Lower Instrumented Vertebra Have Comparable Radiographic and Clinical Outcomes in Adult Cervical Deformity

Han Jo Kim, MD¹ , Yu-Cheng Yao, MD^{1,2} , Mathieu Bannwarth, MD^{1,3}, Justin S. Smith, MD, PhD⁴ , Eric O. Klineberg, MD⁵, Gregory M. Mundis, MD⁶, Themistocles S. Protopsaltis, MD⁷, Jonathan Charles-Elysee, MS¹, Shay Bess, MD⁸, Christopher I. Shaffrey, MD⁹, Peter G. Passias, MD⁷, Frank J. Schwab, MD¹, Christopher P. Ames, MD¹⁰, Virginie Lafage, PhD¹; and International Spine Study Group (ISSG)

Abstract

Study Design: Comparative cohort study.

Objective: Factors that influence the lower instrumented vertebra (LIV) selection in adult cervical deformity (ACD) are less reported, and outcomes in the cervicothoracic junction (CTJ) and proximal thoracic (PT) spine are unclear.

Methods: A prospective ACD database was analyzed using the following inclusion criteria: LIV between C7 and T5, upper instrumented vertebra at C2, and at least a 1-year follow-up. Patients were divided into CTJ (LIV C7-T2) and PT groups (LIV T3-T5) based on LIV levels. Demographics, operative details, radiographic parameters, and the health-related quality of life (HRQOL) scores were compared.

Results: Forty-six patients were included (mean age, 62 years), with 22 and 24 patients in the CTJ and PT groups, respectively. Demographics and surgical parameters were comparable between the groups. The PT group had a significantly higher preoperative C2-C7 sagittal vertical axis (cSVA) (46.9 mm vs 32.6 mm, $P = 0.002$) and T1 slope minus cervical lordosis (45.9° vs 36.0°, $P = 0.042$) than the CTJ group and was more likely treated with pedicle-subtraction osteotomy (33.3% vs 0%, $P = 0.004$). The PT group had a larger correction of cSVA (−7.7 vs 0.7 mm, $P = 0.037$) and reciprocal change of increased T4-T12 kyphosis (8.6° vs 0.0°, $P = 0.001$). Complications and reoperations were comparable. The HRQOL scores were not different preoperatively and at 1-year follow-up.

Conclusions: The selection of PT LIV in cervical deformities was more common in patients with larger baseline deformities, who were more likely to undergo pedicle-subtraction osteotomy. Despite this, the complications and HRQOL outcomes were comparable at 1-year follow-up.

¹ Spine Service, Hospital for Special Surgery, New York, NY, USA

² Department of Orthopaedic, Taipei Veterans General Hospital, Taipei, Taiwan

³ Neurosurgery, University Hospital Reims, Reims, France

⁴ Department of Neurosurgery, University of Virginia Health Sciences Center, Charlottesville, VA, USA

⁵ Department of Orthopaedic Surgery, University of California, Davis, Sacramento, CA, USA

⁶ San Diego Center for Spinal Disorders, La Jolla, CA, USA

⁷ Division of Spine Surgery, Hospital for Joint Diseases, NYU Langone Medical Center, New York, NY, USA

⁸ Department of Orthopaedic Surgery, Denver International Spine Center, Denver, CO, USA

⁹ Department of Orthopaedic Surgery, Duke University, Raleigh, NC, USA

¹⁰ Department of Neurological Surgery, University of California, San Francisco, CA, USA

Corresponding Author:

Han Jo Kim, Spine Service, Hospital for Special Surgery, 535 E 70th St, New York, NY 10021, USA.

Email: hanjokimmd@gmail.com



Creative Commons Non Commercial No Derivs CC BY-NC-ND: This article is distributed under the terms of the Creative Commons Attribution-NonCommercial-NoDerivs 4.0 License (<https://creativecommons.org/licenses/by-nc-nd/4.0/>) which permits non-commercial use, reproduction and distribution of the work as published without adaptation or alteration, without further permission provided the original work is attributed as specified on the SAGE and Open Access pages (<https://us.sagepub.com/en-us/nam/open-access-at-sage>).

Keywords

adult cervical deformity, corrective surgery, lowest instrumented level, distal junctional kyphosis, reoperation, complication, health-related quality of life scores, outcomes

List of Abbreviations

ACD, adult cervical deformity; UIV, upper instrumented vertebra; LIV, lower instrumented vertebra; CTJ, cervicothoracic junction; PT, proximal thoracic; cSVA, C2-C7 sagittal vertical axis; TS, T1 slope; CL, C2-C7 lordosis; TPA, T1 pelvic angle; TK, T4-T12 kyphosis; PI, pelvic incidence; LL, lumbar lordosis; SVA, C7-S1 sagittal vertical axis; PSO, pedicle-subtraction osteotomy; DJK, distal junctional kyphosis; HRQOL, health-related quality of life; NRS, numerical rating scale; NDI, Neck Disability Index; mJOA, modified Japanese Orthopaedic Association

Introduction

Adult cervical deformity (ACD) is caused by heterogeneous etiologies, can lead to severe symptoms, and may require surgical treatment.^{1,2} Multiple studies had addressed the association between sagittal malalignment of the cervical spine and the health effects on symptomatic ACD patients.³⁻⁷ Over the last few decades, advances in surgical techniques, anesthesia, and patient care have improved the surgical outcome in patients with spinal deformity.⁸ Surgical treatment can restore the sagittal alignment, relieve symptoms, and improve the health-related quality of life (HRQOL) outcomes, and is an effective treatment method for most symptomatic patients.⁹⁻¹²

The complexity of ACD makes surgical decision-making challenging and controversial. Prior reports have shown marked variation in surgical treatment strategies and classifications for cervical deformity.¹³⁻¹⁷ Ames et al¹³ and Kim et al¹⁴ have provided the framework for the classification of cervical deformities by radiographic alignments and morphologies and demonstrated a correlation to HRQOL outcomes. Hann et al¹⁵ attempted to delineate an algorithm for the selection of surgical approach based on fixed versus passively-correctable deformities. Smith et al¹⁸ highlighted the remarkable variability in the selection of surgical approach, osteotomies, number of fusion levels, and upper (UIV) and lower (LIV) instrumented vertebral levels. A strong consensus on surgical planning is still lacking, and the use of different surgical techniques can significantly affect HRQOL outcomes and the occurrence of complications.¹⁸⁻²³

Patients with ACD often required extensive fusions that extend the LIV into the thoracic spine.^{15,22,24,25} However, factors that influence LIV selection have been scarcely reported in the literature. Thus, this study aimed to examine whether there are significant differences between patients with ACD who have an LIV to the cervicothoracic junction (CTJ) versus an LIV to the proximal thoracic (PT) spine.

Materials and Methods

This study was conducted as a comparative cohort study based on a prospectively collected multicenter database of patients with ACD, from January 2013 to October 2016. Institutional review board approval was obtained from each of the participating sites across the country. Informed consent was obtained from the patients.

The inclusion criteria of the database were patients aged >18 years and meeting at least 1 of the following radiographic criteria: cervical scoliosis with Cobb angle >10°, C2-C7 sagittal vertical axis (cSVA) >4 cm, cervical kyphosis >25°, and/or chin-brow vertical angle >25°. Additional inclusion criteria in this study were UIV of C2, LIV between C7 and T5, and a minimum of 1-year follow-up. Patients with active tumor or infection were excluded. Patients were divided into 2 groups based on the LIV levels: CTJ group (LIV between C7 and T2) and PT group (LIV between T3 and T5). Parameters of the 2 groups were then analyzed.

Patients' demographics and operative details were collected and included age, sex, prior cervical fusion surgery, prior thoracolumbar fusion surgery, estimated blood loss, operative time, surgical approach, level of instrumentation, and presence of pedicle-subtraction osteotomy (PSO). Radiographic parameters were measured on full-length, free-standing spine radiographs at baseline preoperatively and at 1-year postoperative follow-up; parameters measured were C2-C7 lordosis (CL), cSVA, T1 slope (TS), T1 pelvic angle (TPA), T4-T12 kyphosis (TK), pelvic tilt (PT), pelvic incidence (PI), lumbar lordosis (LL), C7-S1 sagittal vertical axis (SVA), and the distal junctional kyphosis (DJK) angle (the angle between the superior endplate of the LIV and the inferior endplate of the second distal vertebra below) (Figure 1). Abnormal radiographic DJK angles were defined as a junctional kyphosis angle of $\geq 10^\circ$ and a postoperative increase of $\geq 10^\circ$.²⁶ All radiographic parameters were obtained using SpineView® (ENSAM, Laboratory of Biomechanics, Paris, France).

The primary outcomes were clinical, radiographic, and HRQOL score outcomes. The secondary outcomes were complications and reoperations due to complication during the follow-up. The HRQOL scores, including the numerical rating scale (NRS) for neck and back pain, Neck Disability Index (NDI), and modified Japanese Orthopaedic Association (mJOA) scores, were obtained preoperatively and at the 1-year postoperative follow-up. Complications were tallied, and major complications were defined as previously published: those requiring additional intervention or return to the operating room, those resulting in increased length of hospital stay, or those that are not resolved during follow-up.²⁷ The number of major complications and complications requiring reoperation were determined.

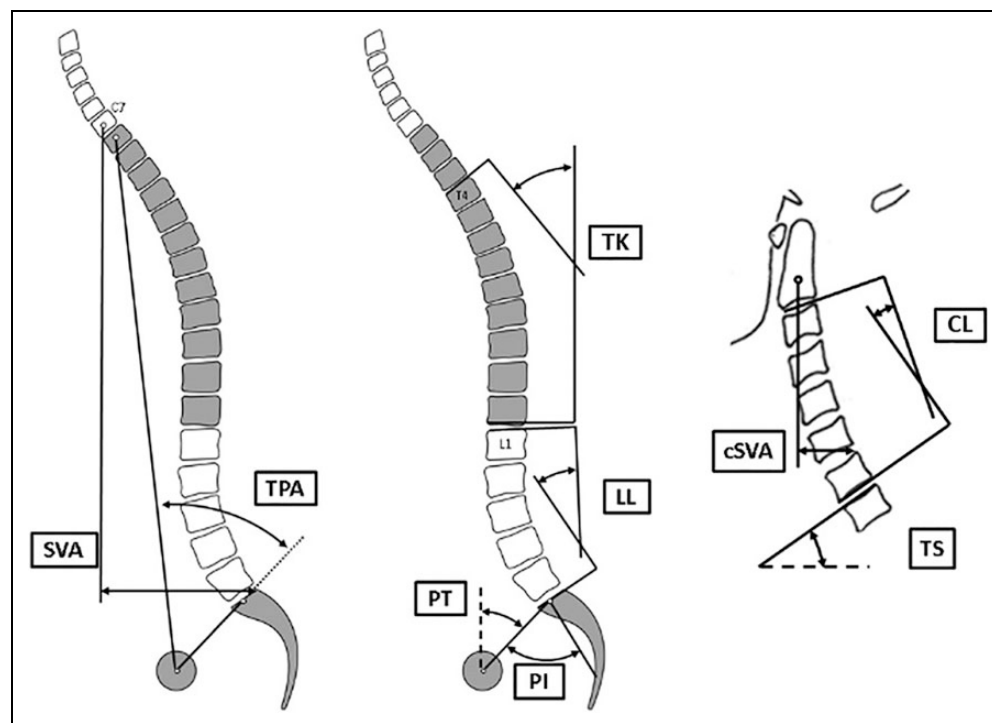


Figure 1. Measurement of radiographic parameters. TPA, T1 pelvic angle; SVA, C7-S1 sagittal vertical axis; TK, T4-T12 kyphosis; PT, pelvic tilt; PI, pelvic incidence; LL, lumbar lordosis; CL, C2-C7 lordosis; cSVA, C2-C7 sagittal vertical axis; TS, T1 slope.

Table 1. Patient Demographics and Operative Details of the Overall Cohort and the 2 Groups.

Parameters	Total cohort (n = 46)	CTJ group (n = 22)	PT group (n = 24)	P
Demographics				
Age (years)	61.6 ± 9.2	61.8 ± 7.7	61.4 ± 10.5	0.873
Female sex	25 (54.3%)	13 (59.1%)	12 (50%)	0.568
Prior cervical surgery	46 (100%)	22 (100%)	24 (100%)	1
Prior thoracolumbar surgery	6 (13%)	3 (13.6%)	3 (12.5%)	1
Surgical parameters				
Surgical approach				0.198
Posterior only	23 (50%)	8 (36.4%)	15 (62.5%)	
Combined approach	23 (50%)	14 (63.6%)	9 (37.5%)	
% PSO	8 (17.4%)	0 (0%)	8 (33.3%)	0.004
Operative time (min)	315.4 ± 141.9	346.0 ± 148.8	287.3 ± 132.2	0.417
EBL (ml)	667.1 ± 499	603.9 ± 600.2	725.0 ± 388.4	0.164

Abbreviations: PSO, pedicle-subtraction osteotomy; EBL, estimated blood loss; CTJ, cervicothoracic junction; PT, proximal thoracic.

Statistical analysis was performed using SPSS version 22.0 (IBM Corp., Armonk, NY, USA). Categorical data was compared using the chi-squared or Fisher's exact tests, and continuous data was compared using the independent T-test or Wilcoxon rank-sum test, as appropriate. A 2-tailed significance level was set at $P < 0.05$.

Results

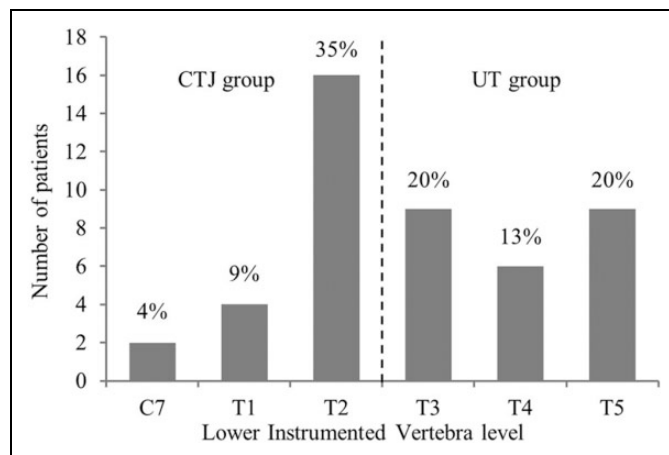
A total of 64 patients met the inclusion criteria, and 46 patients who had completed the follow-up and data collection were included in the analysis. The average age was 61.6 ± 9.2 years,

with a mean follow-up of 12 months. Of the patients, 25 were women (54.3%). All patients had undergone cervical surgery, and 13% had undergone thoracolumbar surgery (Table 1). Of the entire cohort, the average preoperative cervical alignments were cervical lordosis of $-13.7^\circ \pm 17.8^\circ$, a high TS-CL mismatch of $41.2^\circ \pm 16.4^\circ$, and a high cSVA of 40.1 ± 16.3 mm. No patients had preoperative thoracolumbar sagittal malalignment, whereas the PT was $19.7^\circ \pm 8.6^\circ$, the PI-LL was $1.6^\circ \pm 12.6^\circ$, and the SVA was -2.8 ± 67.6 mm (Table 2). The cervical alignments improved significantly after corrective surgery. Cervical lordosis increased by 5.7 ± 13.3 ($P < 0.001$), TS-CL by 31.3 ± 13.6 ($P < .001$), and cSVA by

Table 2. Pre- and Postoperative Radiographic Parameters of the Entire Cohort.

Parameters	Pre	Post	P
Cervical alignments			
CL (°)	-13.7 ± 17.8	5.7 ± 13.3	<0.001
TS (°)	27.4 ± 14.2	37.2 ± 12.4	<0.001
TS-CL (°)	41.2 ± 16.4	31.3 ± 13.6	<0.001
cSVA (mm)	40.1 ± 16.3	36.4 ± 11.8	0.078
Thoracolumbar alignments			
TPA (°)	13.4 ± 9.2	15.2 ± 10.2	0.057
TK (°)	-38.5 ± 12.3	-43.9 ± 13.5	0.002
PT (°)	19.7 ± 8.6	19.0 ± 9.5	0.325
PI (°)	53.9 ± 10.9	54.1 ± 10.6	0.536
LL (°)	52.3 ± 14.6	51.2 ± 15.1	0.355
PI-LL (°)	1.6 ± 12.6	2.9 ± 13.9	0.277
SVA (mm)	-2.8 ± 67.6	26.7 ± 66.6	<0.001

Abbreviations: CL, C2-C7 lordosis; TS, T1 slope; cSVA, C2-C7 sagittal vertical axis; TPA, T1 pelvic angle; TK, T4-T12 kyphosis; PI, pelvic incidence; LL, lumbar lordosis; SVA, C7-S1 sagittal vertical axis.

**Figure 2.** Distribution of the location of the lowest instrumented vertebra.

36.4 ± 11.8 mm ($P = 0.078$), whereas the TK and SVA reciprocal increased significantly and caused more forward global alignment (Table 2).

There were 22 patients in the CTJ group and 24 in the PT group (Figure 2). Age, sex, prior spinal surgery, surgical approach, estimated blood loss, and operative time were all comparable between the 2 groups. Patients in the PT group received more PSO than those in the CTJ group (33.3% vs 0%, $P = 0.004$) (Table 1). The PT group had a significantly higher preoperative cSVA (46.9 ± 13.6 mm vs 32.6 ± 16.0 mm, $P = 0.002$) and TS-CL mismatch (45.9° ± 17.1° vs 36.0° ± 14.1°, $P = 0.042$) than the CTJ group. The preoperative thoracolumbar alignments were not significantly different between the 2 groups. After surgery, the radiographic parameters were comparable, except the TK, which was higher in the PT group than in the CTJ group (49.0° ± 11.6° vs 36.3° ± 12.5°, $P = 0.001$) at 1-year follow-up. A larger correction of

cSVA (-7.7 ± 12.2 mm vs 0.7 ± 14.3 mm, $P = 0.037$) and increased TK (8.6° ± 8.7° vs 0.0° ± 7.2°, $P = 0.001$) was found in the PT group (Table 3). Case examples of the 2 groups were shown in Figure 3.

The incidence of DJK was 20.8% in the PT group and 9.1% in the CTJ group ($P = 0.418$) at the 1-year follow-up. The DJK angle in the PT group was significantly higher than that in the CTJ group at 1 year (21.9° ± 9.3° vs 10.9° ± 5.9°, $P < 0.001$). Moreover, 71.1% of the patients developed at least one complication, and 21.5% of the complications were major. The incidence and type of major complications were not different between the groups (Table 4). Six patients (13%) needed reoperation due to complications. The PT group had a higher reoperation rate (20.8% vs 4.5%, $P = 0.19$), but the difference did not reach statistical significance. The causes of reoperations were neurologic deficit ($n = 1$) in the CTJ group, and DJKs ($n = 2$), neurologic deficit ($n = 2$), and prominent implant ($n = 1$) in the PT group (Table 4). The HRQOL scores of the NRS back/neck, NDI, and mJOA scores were not significantly different between the 2 groups at preoperative baseline and at the final follow-up. Improvements in all HRQOL scores were comparable between the 2 groups (Table 5).

Discussion

Our result suggests that the preoperative radiographic parameters affect the selection of the LIV level in cervical deformities. The entire cohort had preoperative moderate cSVA malalignment, severe TS-CL mismatch, and moderate myelopathy, and had no thoracolumbar malalignment according to the Ames Cervical Deformity classification.¹³ Patients who had longer fusions extending into the PT spine had a larger preoperative cSVA malalignment, a greater TS-CL mismatch, and had more PSOs performed than those with fusions at the CTJ spine. Radiographic and clinical outcomes were comparable between the 2 groups at the 1-year follow-up. The PT group had a higher rate of DJK and reoperation, but the difference did not reach statistical significance. No difference was found in the incidence of major or minor complications and the HRQOL scores between the 2 groups.

A few studies have addressed the importance of LIV selection by preoperative alignments. Virk et al¹⁷ defined an algorithm for deciding LIV for patients with ACD based on consensus recommendations among spine surgeons. They suggested that if previously placed instrumentation is higher than T6, the LIV should bypass the old LIV, which likely reflects the need to properly treat a cervicothoracic or thoracic driver for deformity. Passia et al^{24,25} had described the primary driver of ACD and found the importance of including the primary driver of the deformity in the construct; otherwise, it would lead to residual malalignment and inferior HRQOL scores, which stresses the importance of preoperative alignment to postoperative outcomes. Neither of those studies had specifically discussed the selection of LIV over the CTJ versus PT spine. To the best of our knowledge, our study is the first to describe the association of preoperative radiographic

Table 3. Radiographic Parameters Analysis Between the CTJ and PT Groups at Preoperative Baseline and at the Postoperative 1-Year Follow-Up.

Parameters	Preoperative			Postoperative 1 year			Difference		
	CTJ group	PT group	P	CTJ group	PT group	P	CTJ group	PT group	P
Cervical alignments									
CL (°)	-12.4 ± 13.0	-14.9 ± 21.6	0.645	4.5 ± 11.1	6.8 ± 15.3	0.566	17.0 ± 16.0	21.7 ± 19.7	0.376
TS (°)	23.4 ± 10.7	30.9 ± 16.0	0.074	33.9 ± 9.9	40.1 ± 13.6	0.084	10.5 ± 9.2	9.2 ± 12.1	0.685
TS-CL (°)	36.0 ± 14.1	45.9 ± 17.1	0.042	29.3 ± 12.9	33.3 ± 14.0	0.326	-6.9 ± 16.7	-12.6 ± 17.2	0.271
cSVA (mm)	32.6 ± 16.0	46.9 ± 13.6	0.002	33.3 ± 12.9	39.2 ± 10.2	0.095	0.7 ± 14.3	-7.7 ± 12.2	0.037
Thoracolumbar alignments									
TPA (°)	12.8 ± 10.7	13.6 ± 7.7	0.768	13.7 ± 12.1	16.7 ± 7.6	0.322	0.9 ± 7.5	2.7 ± 4.2	0.346
TK (°)	-36.4 ± 10.8	-40.4 ± 13.5	0.271	-36.3 ± 12.5	-49.0 ± 11.6	0.001	0.0 ± 7.2	-8.6 ± 8.7	0.001
PT (°)	17.7 ± 9.7	21.5 ± 7.3	0.145	16.6 ± 10.5	21.1 ± 8.2	0.111	-1.1 ± 6.0	-0.4 ± 4.2	0.643
PI (°)	51.5 ± 11.2	56.2 ± 10.2	0.145	51.8 ± 11.0	56.3 ± 10.1	0.155	0.3 ± 1.9	0.1 ± 1.9	0.715
LL (°)	50.1 ± 16.7	54.5 ± 12.3	0.324	48.8 ± 17.4	53 ± 12.6	0.318	-1.2 ± 10.3	1.0 ± 6.0	0.936
PI-LL (°)	1.4 ± 14.7	1.8 ± 10.6	0.916	2.9 ± 17.2	2.9 ± 10.4	0.999	1.5 ± 10.3	1.1 ± 5.4	0.871
SVA (mm)	7.1 ± 54.4	-15.4 ± 77.8	0.768	29.6 ± 66.0	22.0 ± 67.6	0.703	22.5 ± 58.6	36.6 ± 41.6	0.363

Abbreviations: CL, C2-C7 lordosis; TS, T1 slope; cSVA, C2-C7 sagittal vertical axis; TPA, T1 pelvic angle; TK, T4-T12 kyphosis; LL, lumbar lordosis; PI-LL, pelvic incidence minus lumbar lordosis; SVA, C7-S1 sagittal vertical axis; CTJ, cervicothoracic junction; PT, proximal thoracic.

Table 4. Complications and Reoperations in Patients of the 2 Groups.

Variables	CTJ group (n = 22)	PT group (n = 24)	P
Total number of complications	34	31	
Major complications	8 (23.5%)	6 (19.4%)	0.683
Total patient affected	15 (68.2%)	17 (70.8%)	0.845
Types of major complications			
Dysphagia	1 (4.5%)	0 (0%)	0.478
Instrumentation	1 (4.5%)	1 (4.2%)	1
Organ failure	1 (4.5%)	0 (0%)	0.478
Neurological	1 (4.5%)	2 (8.3%)	1
Vascular	1 (4.5%)	1 (4.2%)	1
Total number of reoperations	1	6	
Total patient affected	1 (4.5%)	5 (20.8%)	0.190
Reoperation types			
Instrumentation	0 (0%)	1 (4.2%)	1
Operative	0 (0%)	1 (4.2%)	1
Radiographic—DJK	0 (0%)	2 (8.3%)	0.490
Neurological	1 (4.5%)	2 (8.3%)	1

Abbreviations: DJK, distal junctional kyphosis; CTJ, cervicothoracic junction; PT, proximal spine.

parameters and the selection of LIV in the CTJ versus PT spine in cervical deformities.

The greater PSOs performed in the PT group are thought to be associated with the larger correction of cSVA. Previous studies have shown that PSOs are a powerful osteotomy that can provide superior angular corrections and substantial sagittal deformity correction in cervical or cervicothoracic deformities.²¹⁻²³ The decision on osteotomy type and level was impacted by the primary driver or apex of cervical deformity. Smith et al²³ reported 23 ACD patients treated with 3-column osteotomy and found that most of them had the apex over the

Table 5. Health-Related Quality of Life Scores in the CTJ and PT Groups at Different Time Points.

Variables	Time point	CTJ group	PT group	P
NRS neck	Preop	7.0 ± 2.8	6.7 ± 2.2	0.738
	1Y	3.7 ± 2.6	5.0 ± 3.4	0.168
	Change	-3.2 ± 3.2	-1.8 ± 3.0	0.135
NRS back	Preop	5.2 ± 3.1	4.7 ± 2.8	0.562
	1Y	4.6 ± 2.5	4.3 ± 3.5	0.730
	Change	-0.6 ± 2.5	-0.2 ± 2.8	0.648
NDI	Preop	49.9 ± 13.5	52.9 ± 17.1	0.516
	1Y	39.7 ± 18.1	44.6 ± 18.8	0.390
	Change	-10.2 ± 13.9	-9.9 ± 14.7	0.957
mJOA	Preop	13.0 ± 3.3	13.5 ± 2.8	0.628
	1Y	13.3 ± 3.2	13.4 ± 3.3	0.923
	Change	0.1 ± 2.9	-0.1 ± 2.7	0.861

Abbreviations: NRS, numerical rating scale; mJOA, modified Japanese Orthopedic Association; NDI, neck disability index; Preop, preoperative; CTJ, cervicothoracic junction; PT, proximal thoracic.

cervicothoracic junction or thoracic region. Passias et al²⁵ summarized the different types of primary driver of ACD and noticed that the 3-column osteotomy was performed more in those that had the primary driver over the cervicothoracic junction than in the cervical spine. For the selection of level for PSO, Smith et al²³ also found that the level of PSO was mainly in the T2 and T3 than C7 and T1. The consideration of a more caudal level of PSO is a potential safety enhancement to avoid the risk of vertebral artery compromise with C7 PSO and C7, C8, T1 nerve injury with PSO at the C7 and T1 levels. It is reasonable to extend the LIV to the PT spine in ACD patients requiring PSO at the CTJ. One should know that the LIV should not include the apex of the thoracic kyphosis (usually T7-T9) to avoid junction problems.

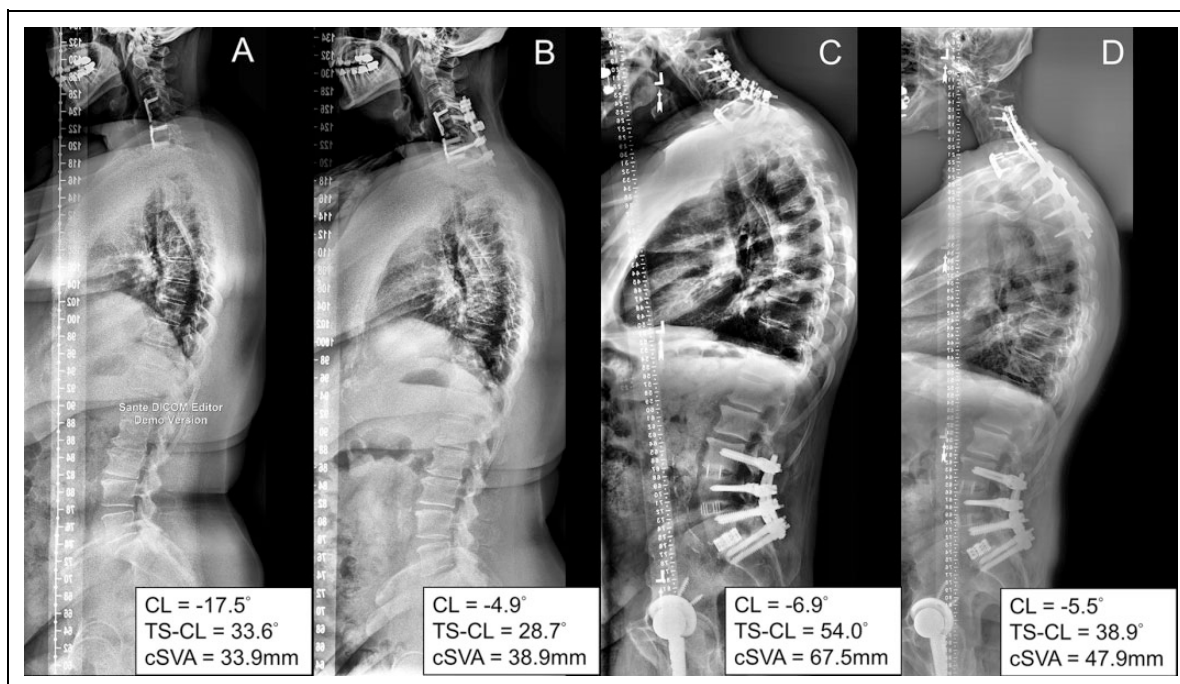


Figure 3. Representative examples of patients in CTJ and PT groups. (A) Preoperative and (B) postoperative 1-year images of a 64-year-old female with T1 LIV (CTJ group). (C) Preoperative and (D) postoperative images of a 64-year-old male with T5 LIV (PT group). The cases represent the different baseline deformities in the 2 groups. The PT group (C and D) had higher baseline cSVA, higher baseline TS-CL, and more correction of cSVA. CL, C2-C7 lordosis; TS, T1 slope; cSVA, C2-C7 sagittal vertical axis.

The development of DJK is one of the concerns in planning corrective surgery for ACD. The selection of UIV or LIV is typically viewed as a decision a surgeon can make to prevent junctional kyphosis.²⁸ Passias et al^{29,30} reported multiple factors that predict the occurrence of DJK, including baseline radiographic parameters, preoperative neurological deficit, combined surgical approach, use of a transitional rod, selection of UIV, and performance of 3-column osteotomy. Our PT group demonstrated a more severe baseline cervical malalignment, included higher TS-CL and cSVA, and more PSOs performed. The incidence of DJK, although higher in the PT group, was not significantly different. This may be due to the smaller cohort of patients in each group.

Interestingly, we noticed a significantly higher reciprocal change of TK and a higher final TK in the PT group. A previous study had raised the concept of the chain of correlation between the cervical, thoracic, and lumbar spines and emphasized how differing regional drivers might influence global sagittal spinal harmony.^{31,32} Lafage et al³³ found that the favorable reciprocal change in the thoracic spine in patients with thoracolumbar deformity who underwent lumbar PSO may help in obtaining ideal global alignment, while unfavorable reciprocal change is attributed to junctional failure. Two recent studies confirmed that the reciprocal thoracolumbar alignment changes that occur after cervical correction surgery for ACD help maintain the horizontal gaze and global standing alignment.^{34,35} Our results showed increased reciprocal change of TK in the PT group and no change of TK in the CTJ group. While a higher DJK angle

was found in the PT group, the reciprocal change of TK in the PT group could be explained by the higher DJK angle and should be considered in preoperative planning while choosing the LIV.

For ACD patients who underwent long fusion, we found that surgeons more often extend the LIV to the PT spine when PSOs were performed and when patients had worse baseline cSVA malalignment and TS-CL mismatch. Although patients with fusion to the PT spine had a larger cSVA correction, more reciprocal change of TK, and higher final TK and DJK angles, the reoperations, complications, and HRQOL outcomes were comparable. However, we could not make a firm recommendation regarding the optimal LIV in individual patients. We believe our finding would provide a reference for surgeons in preoperative planning of the LIV in ACD patients.

This study has some limitations. First, the study used a retrospective design and included a relatively small number of patients. However, the use of a prospectively collected multicenter database with standardized collection of detailed clinical and surgical data enhances the generalizability of our findings. Second, the strategy for LIV selection among different surgeons could not be determined. The decision varied widely based on the characteristics of patients and surgeons' experience. Finally, there was a lack of information regarding patients' comorbidities, osteoporosis management, and the use of different bone grafts due to the retrospective design.

Conclusion

In conclusion, the selection of the LIV in cervical deformities was affected by the preoperative deformity; those undergoing fusion to the PT spine had larger cSVA malalignment and greater TS-CL mismatch and were more likely to undergo a PSO for correction. The PT group had larger cSVA correction, more reciprocal change of TK, higher final TK and DJK angle, as well as higher rate of DJK and reoperation that did not reach statistical significance. Despite this, the numbers of major or minor complications and the HRQOL outcomes were comparable at the 1-year follow-up.

Authors' Note

Institutional Review Board approval for all participating institutes:

1. Baylor All Saints Medical Center at Fort Worth, TX, US, BRI IRB No. 096 259
2. Rocky Mountain Hospital for Children, Presbyterian St Luke's Medical Center, Denver, CO, USA. HCA-HealthONE IRB No. 325 368-10
3. Hospital for Special Surgery, NY, NY, US, IRB No. 2014-373-CR2
4. Johns Hopkins Medicine, Baltimore, Maryland, US, IRB00084730 / CR00012716
5. The University of Kansas Medical Center, KS, US, KUMC IRB No. 13 226
6. Scripps Green Hospital and Scripps Memorial Hospital La Jolla, CA, US, IRB-14-6468
7. University of California, Davis, CA, US, IRB No. 463 372-6
8. University of California, San Francisco, CA, US, IRB No. 12-08 855
9. NYU School of Medicine, NYU Langone medical center, NY, US, IRB No. i12-02 939
10. University of Virginia Health Sciences Center, Charlottesville, VA, US, HSR IRB No. 16 273
11. Washington University in St. Louis, St. Louis, MO, US, IRB No. 201 204 137.

Declaration of Conflicting Interests


The author(s) declared no potential conflicts of interest with respect to the research, authorship, and/or publication of this article.


Funding

The author(s) disclosed receipt of the following financial support for the research, authorship, and/or publication of this article: This study was supported by the International Spine Study Group foundation; Yu-Cheng Yao was supported by Taipei Veterans General Hospital-National Yang-Ming University Excellent Physician Scientists Cultivation Program, No. 108-V-A-010.

ORCID iDs

Han Jo Kim, MD  <https://orcid.org/0000-0003-2170-3592>

Yu-Cheng Yao, MD  <https://orcid.org/0000-0001-7555-4321>

Justin S. Smith, MD, PhD  <https://orcid.org/0000-0003-0467-5534>

References

1. Cho SK, Safir S, Lombardi JM, Kim JS. Cervical spine deformity: indications, considerations, and surgical outcomes. *J Am Acad Orthop Surg.* 2019;27(12):e555-e567.
2. Smith JS, Lafage V, Schwab FJ, et al. Prevalence and type of cervical deformity among 470 adults with thoracolumbar deformity. *Spine (Phila Pa 1976).* 2014;39(17):E1001-E1009.
3. Smith JS, Line B, Bess S, et al. The health impact of adult cervical deformity in patients presenting for surgical treatment: comparison to United States population norms and chronic disease states based on the EuroQuol-5 dimensions questionnaire. *Neurosurgery.* 2017;80(5):716-725.
4. Tang JA, Scheer JK, Smith JS, et al. The impact of standing regional cervical sagittal alignment on outcomes in posterior cervical fusion surgery. *Neurosurgery.* 2012;76(Suppl 1):662-669.
5. Iyer S, Nemani VM, Nguyen J, et al. Impact of cervical sagittal alignment parameters on neck disability. *Spine (Phila Pa 1976).* 2016;41(5):371-377.
6. Horn SR, Passias PG, Oh C, et al. Predicting the combined occurrence of poor clinical and radiographic outcomes following cervical deformity corrective surgery. *J Neurosurg Spine.* 2020;32(2):182-190.
7. Protopsaltis TS, Ramchandran S, Hamilton DK, et al. Analysis of successful versus failed radiographic outcomes after cervical deformity surgery. *Spine (Phila Pa 1976).* 2018;43(13):E733-E781.
8. Smith JS, Shaffrey CI, Bess S, et al. Recent and emerging advances in spinal deformity. *Neurosurgery.* 2017;80(3S):S70-S85.
9. Etame AB, Wang AC, Than KD, La Marca F, Park P. Outcomes after surgery for cervical spine deformity: review of the literature. *Neurosurg Focus.* 2010;28(3):E14.
10. Tan LA, Riew KD, Traynelis VC. Cervical spine deformity-part 3: posterior techniques, clinical outcome, and complications. *Neurosurgery.* 2017;81(6):893-898.
11. Ailon T, Smith JS, Shaffrey CI, et al. Outcomes of operative treatment for adult cervical deformity: a prospective multicenter assessment with 1-year follow-up. *Neurosurgery.* 2018;83(5):1031-1039.
12. Passias PG, Oh C, Horn SR, et al. Predicting the occurrence of complications following corrective cervical deformity surgery: analysis of a prospective multicenter database using predictive analytics. *J Clin Neurosci.* 2019;59:155-161.
13. Ames CP, Smith JS, Eastlack R, et al. Reliability assessment of a novel cervical spine deformity classification system. *J Neurosurg Spine.* 2015;23(6):673-683.
14. Kim HJ, Virk S, Elysee J, et al. The morphology of cervical deformities: a two-step cluster analysis to identify cervical deformity patterns. *J Neurosurg Spine.* 2019;1-7.
15. Hann S, Chalouhi N, Madineni R, et al. An algorithmic strategy for selecting a surgical approach in cervical deformity correction. *Neurosurg Focus.* 2014;36(5):E5.
16. Bortz CA, Passias PG, Segreto FA, et al. Grading of complications after cervical deformity-corrective surgery: are existing

- classification systems applicable? *Clin Spine Surg.* 2019;32(6):263-268.
17. Virk S, Elysee J, Gupta M, et al. Defining an algorithm of treatment for severe cervical deformity using surgeon survey and treatment patterns. *World Neurosurg.* 2020;139:e541-e547.
18. Smith JS, Klineberg E, Shaffrey CI, et al. Assessment of surgical treatment strategies for moderate to severe cervical spinal deformity reveals marked variation in approaches, osteotomies, and fusion levels. *World Neurosurg.* 2016;91:228-237.
19. Cheung JPY, Luk KDK. Complications of anterior and posterior cervical spine surgery. *Asian Spine J.* 2016;10(2):385-400.
20. Kim HJ, Nemani VM, Daniel Riew K. Cervical osteotomies for neurological deformities. *Eur Spine J.* 2014;24(Suppl 1):S16-S22.
21. Kim HJ, Piyaskulkaew C, Riew KD. Comparison of Smith-Petersen osteotomy versus pedicle subtraction osteotomy versus anterior-posterior osteotomy types for the correction of cervical spine deformities. *Spine (Phila Pa 1976).* 2015;40(3):143-146.
22. Theologis AA, Tabaraee E, Funao H, et al. Three-column osteotomies of the lower cervical and upper thoracic spine: comparison of early outcomes, radiographic parameters, and peri-operative complications in 48 patients. *Eur Spine J.* 2015;24(Suppl 1):S23-S30.
23. Smith JS, Shaffrey CI, Lafage R, et al. Three-column osteotomy for correction of cervical and cervicothoracic deformities: alignment changes and early complications in a multicenter prospective series of 23 patients. *Eur Spine J.* 2017;26(8):2128-2137.
24. Passias PG, Bortz C, Horn S, et al. Drivers of cervical deformity have a strong influence on achieving optimal radiographic and clinical outcomes at 1 year after cervical deformity surgery. *World Neurosurg.* 2018;112:e61-e68.
25. Passias PG, Jalai CM, Lafage V, et al. Primary drivers of adult cervical deformity: prevalence, variations in presentation, and effect of surgical treatment strategies on early postoperative alignment. *Neurosurgery.* 2018;83(4):651-659.
26. Lowe TG, Lenke L, Betz R, et al. Distal junctional kyphosis of adolescent idiopathic thoracic curves following anterior or posterior instrumented fusion: incidence, risk factors, and prevention. *Spine (Phila Pa 1976).* 2006;31(3):299-302.
27. Kim HJ, Iyer S, Zebala LP, et al. Perioperative neurologic complications in adult spinal deformity surgery. *Spine (Phila Pa 1976).* 2017;42(6):420-427.
28. Scheer JK, Fakurnejad S, Lau D, et al. Results of the 2014 SRS survey on PJK/PJF: a report on variation of select SRS member practice patterns, treatment indications, and opinions on classification development. *Spine (Phila Pa 1976).* 2015;40(11):829-840.
29. Passias PG, Horn SR, Oh C, et al. Predicting the occurrence of postoperative distal junctional kyphosis in cervical deformity patients. *Neurosurgery.* 2020;86(1):E38-E46.
30. Passias PG, Vasquez-Montes D, Poorman GW, et al. Predictive model for distal junctional kyphosis after cervical deformity surgery. *Spine J.* 2018;18(12):2187-2194.
31. Ames CP, Blondel B, Scheer JK, et al. Cervical radiographical alignment: comprehensive assessment techniques and potential importance in cervical myelopathy. *Spine (Phila Pa 1976).* 2013;38(22 Suppl 1):S149-S160.
32. Oh T, Scheer JK, Eastlack R, et al. Cervical compensatory alignment changes following correction of adult thoracic deformity: a multicenter experience in 57 patients with a 2-year follow-up. *J Neurosurg Spine.* 2015;22(6):658-665.
33. Lafage V, Ames C, Schwab F, et al. Changes in thoracic kyphosis negatively impact sagittal alignment after lumbar pedicle subtraction osteotomy: a comprehensive radiographic analysis. *Spine (Phila Pa 1976).* 2012;37(3):E180-E187.
34. Mizutani J, Strom R, Abumi K, et al. How cervical reconstruction surgery affects global spinal alignment. *Neurosurgery.* 2019;84(4):898-907.
35. Ramchandran S, Protosaltis TS, Sciubba D, et al. Prospective multi-centric evaluation of upper cervical and infra-cervical sagittal compensatory alignment in patients with adult cervical deformity. *Eur Spine J.* 2018;27(2):416-425.