

UCLA

Proceedings of UCLA Health

Title

Disseminated Mycobacterium Avium Complex Presenting as Bullous Sweet's Syndrome in a Patient with Anti-Interferon- γ Autoantibody Associated Immunodeficiency Syndrome

Permalink

<https://escholarship.org/uc/item/4sq5w2dn>

Journal

Proceedings of UCLA Health, 25(1)

Authors

Le, Phuong

Glaeser, Alexandra Milin

Publication Date

2021-03-04

CLINICAL VIGNETTE

Disseminated Mycobacterium Avium Complex Presenting as Bullous Sweet's Syndrome in a Patient with Anti-Interferon- γ Autoantibody Associated Immunodeficiency Syndrome

Phuong Le, MD and Alexandra Milin Glaeser, MD

Case Description

A 57-year-old woman with a past medical history of pulmonary coccidioidomycosis, pulmonary and cutaneous Mycobacterium avium complex (MAC), and salmonella presented for progressive rash.

Four months prior she developed recurrent episodes of rash on varying areas of her body. She was treated with antihistamines, topical and oral steroids, antibiotics, and antivirals with subsequent resolution of her rash. Two weeks prior to the current presentation, she developed recurrent rash on her forearm with significant progression to her face despite treatments prompting transfer to our tertiary care hospital.

She presented with facial and periorbital edema and erythema with multiple scattered areas of confluent, painful, non-pruritic papules, pustules, plaques, and bullae predominantly over the face, arms, and trunk. Her exam was also notable for left phalanx and left wrist tenderness and swelling.

Multiple punch biopsies of the lesions were obtained, revealing dermal neutrophil-rich inflammation consistent with Sweet's syndrome (Figure 1). On hospital day 3, she started colchicine for Sweet's syndrome. The patient declined first-line therapy with dapsone due to a history of sulfa allergy and concern for sulfa cross-reactivity with dapsone. In addition, her skin swabs obtained on initial presentation at the outside hospital returned positive for MAC, so she was initiated on MAC therapy with rifampin, ethambutol, and azithromycin. Her rash improved significantly with these treatments. Despite this, she continued to have significant left phalanx and wrist pain. On day 6, an x-ray of the left hand showed a lytic lesion of the left fifth phalanx. A phalanx biopsy was obtained, however with insufficient sample (Figure 2A). On day 8, an MRI of the left wrist showed severe synovitis with lunate bone lesion (Figure 2B). On day 16, she underwent left wrist synovectomy and lunate bone debridement with biopsy. On day 18, she was discharged home with colchicine and MAC therapy with plans for close outpatient follow-up.

Her initial labs included indeterminate quantiferon gold. Further analysis of the test showed absent T-cell response to the negative control, TB antigen, and most concerning, mitogen, which suggested an abnormality in the interferon- γ pathway.

This prompted further genetic testing for underlying immunodeficiency. After discharge, her tissue and bone biopsy cultures grew MAC, and her genetic testing was positive for anti-interferon- γ autoantibody associated immunodeficiency syndrome. Despite adherence to MAC therapy, the patient continued to develop recurrent infections including persistent and recurrent MAC. She was subsequently initiated on immunosuppressive treatment with rituximab to treat her anti-interferon- γ autoantibody. This eventually led to a reduced incidence of infections.

Discussion

Anti-interferon- γ autoantibody associated immunodeficiency syndrome, also known as adult-onset immunodeficiency, is a rare immunodeficiency disorder found mainly in Southeast Asia, specifically Thailand. Notably, our patient is Filipino. Interferon- γ is one of the most important modulators of the human immune system, especially macrophage activation, host defense of intracellular pathogens, and modulation of helper T cells. It primarily stimulates Janus kinase receptors and activates the STAT intracellular pathway leading to downstream pleiotropic immune effects.¹ With disruption of interferon- γ pathways with autoantibodies, patients have increased susceptibility to infections including non-tuberculous mycobacterial and opportunistic infections, such as disseminated Salmonella, Histoplasma, and Cryptococcus. Patients tend to present with nonspecific symptoms, which makes early diagnosis challenging. Our patient presented with different infections and various rashes for years prior to diagnosis.

In the United States, patients with this condition are more likely to present with MAC infection, whereas in Thailand, they are more likely to present with Mycobacterium abscessus. Bone was the most common site of infection in the United States while lymph node infection was more common in Thailand. A recent cohort study of hospitalized patients in Thailand with this immunodeficiency, reported one third with concomitant Sweet's syndrome.² Sweet's syndrome, also known as acute febrile dermatosis, is an inflammatory disorder characterized by acute rash that contains an intensely neutrophilic infiltrate on biopsy. The pathophysiology is not completely understood but is likely triggered by an immune reaction to a bacteria, virus,

tumor, or other antigen.³ Cytokine dysregulation and genetic factors also likely play a role in the body's exaggerated response. Similarly, it is hypothesized that the immune dysregulation in anti-interferon- γ autoantibody associated immunodeficiency syndrome predisposes these patients to developing Sweet's syndrome.

In the Thai cohort study, 17 out of 18 patients who died from this immunodeficiency were only treated with antibiotics. Anti-interferon- γ autoantibodies levels followed over time showed no differences in levels with antibiotic use but significantly decreased with immunosuppression such as rituximab. This supports the assertion that the optimal therapy involves not only treatment of comorbid nontuberculous mycobacterial and opportunistic infections but also therapies targeted towards reduction of circulating anti-interferon- γ autoantibodies. Rituximab, an anti-CD20 monoclonal antibody directed at B cells, has shown to have efficacy both at the clinical and molecular levels in several case reports.^{4,5} One case report demonstrated a restoration of interferon- γ -STAT1 function 6 weeks after rituximab infusion. This manifested as clinical improvement in a patient with disseminated MAC and spinal lesions who had previously had a minimal response to treatments targeted solely towards her disseminated MAC. Along with targeted immunosuppression, prevention and early recognition of opportunistic infections are important in managing patients with anti-interferon- γ autoantibody associated immunodeficiency syndrome.

Conclusions

Anti-interferon- γ autoantibody associated immunodeficiency syndrome is a rare cause of immunodeficiency and indeterminate quantiferon gold test but should be considered on the differential diagnosis. When a quantiferon gold test yield indeterminate results, further analysis of the test should be considered. Determining the etiology of indeterminate results may help identify rare but often devastating diagnoses. Sweet's syndrome and disseminated opportunistic infections are often present concurrently raising increased suspicion for an underlying immunodeficiency syndrome. Initial management should target treatment of acquired infections as well as immunosuppression directed at B cells to decrease autoantibody production. Close monitoring of these patients is needed to reduce severe, recurrent infections as well as complications while on long-term antibiotics and immunosuppression.

Figures

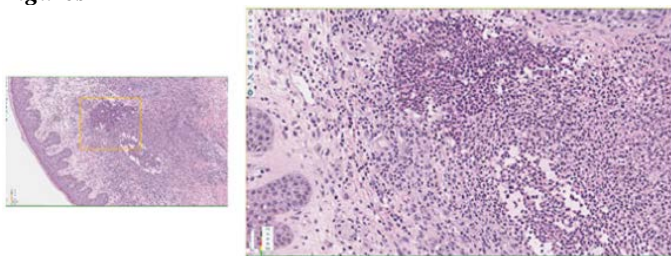


Figure 1. Pathology demonstrating dermal neutrophilic infiltrates.

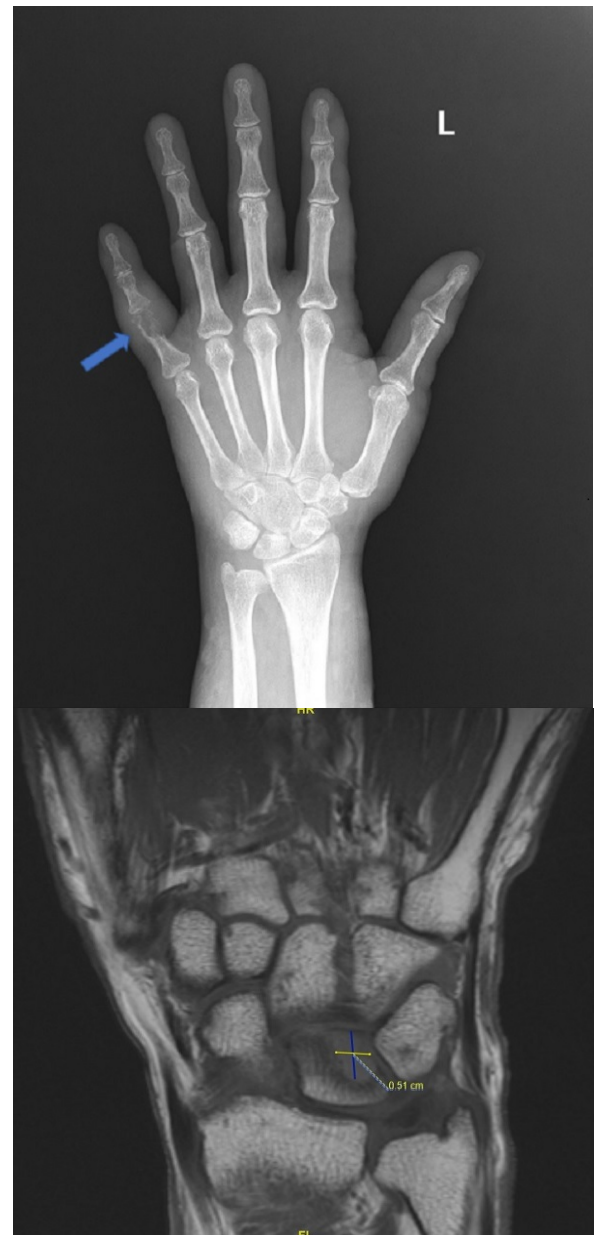


Figure 2. Radiologic imaging of the left upper extremity. A: Left hand X-ray with a lytic lesion of the 5th phalanx presumed to be another site of bony involvement. B: Left wrist MRI showing disseminated MAC involving the lunate bone.

REFERENCES

1. **Hu X, Ivashkiv LB.** Cross-regulation of signaling pathways by interferon-gamma: implications for immune responses and autoimmune diseases. *Immunity*. 2009 Oct 16;31(4):539-50. doi: 10.1016/j.immuni.2009.09.002. PMID: 19833085; PMCID: PMC2774226.
2. **Hong GH, Ortega-Villa AM, Hunsberger S, Chetchotisakd P, Anunnatsiri S, Mootsikapun P, Rosen LB, Zerbe CS, Holland SM.** Natural History and Evolution of Anti-Interferon- γ Autoantibody-Associated Immunodeficiency Syndrome in Thailand and the United

States. *Clin Infect Dis*. 2020 Jun 24;71(1):53-62. doi: 10.1093/cid/ciz786. PMID: 31429907; PMCID: PMC7312243.

3. **Heath MS, Ortega-Loayza AG.** Insights Into the Pathogenesis of Sweet's Syndrome. *Front Immunol*. 2019 Mar 12;10:414. doi: 10.3389/fimmu.2019.00414. PMID: 30930894; PMCID: PMC6424218.
4. **Czaja CA, Merkel PA, Chan ED, Lenz LL, Wolf ML, Alam R, Frankel SK, Fischer A, Gogate S, Perez-Velez CM, Knight V.** Rituximab as successful adjunct treatment in a patient with disseminated nontuberculous mycobacterial infection due to acquired anti-interferon- γ autoantibody. *Clin Infect Dis*. 2014 Mar;58(6):e115-8. doi: 10.1093/cid/cit809. Epub 2013 Dec 11. PMID: 24336756; PMCID: PMC3935498.
5. **Koizumi Y, Sakagami T, Nishiyama N, Hirai J, Hayashi Y, Asai N, Yamagishi Y, Kato H, Hagihara M, Sakanashi D, Suematsu H, Ogawa K, Mikamo H.** Rituximab Restores IFN- γ -STAT1 Function and Ameliorates Disseminated Mycobacterium avium Infection in a Patient with Anti-Interferon- γ Autoantibody. *J Clin Immunol*. 2017 Oct;37(7):644-649. doi: 10.1007/s10875-017-0425-3. Epub 2017 Aug 5. PMID: 28779413.