

UC Davis

Dermatology Online Journal

Title

Coexistence of keloids and pilomatricoma in a patient with Rubinstein-Taybi syndrome

Permalink

<https://escholarship.org/uc/item/4rq2k5fr>

Journal

Dermatology Online Journal, 24(1)

Authors

Yagi, Yosuke
Kuwatsuka, Yutaka
Asai, Misachi
et al.

Publication Date

2018

DOI

10.5070/D3241037970

Copyright Information

Copyright 2018 by the author(s). This work is made available under the terms of a Creative Commons Attribution-NonCommercial-NoDerivatives License, available at <https://creativecommons.org/licenses/by-nc-nd/4.0/>

Peer reviewed

Coexistence of keloids and pilomatricoma in a patient with Rubinstein-Taybi syndrome

Yosuke Yagi^{1,2}, Yutaka Kuwatsuka¹, Misachi Asai¹, Mai Honda¹, Atsushi Utani¹

Affiliations: ¹Department of Dermatology, Graduate School of Medicine, Nagasaki University, Nagasaki, Japan,, ²Osaka Red Cross Hospital, Osaka, Japan

Corresponding Author: Osaka red cross hospital, 5-30 Fudegasaki, Ten-nohji Ward, Osaka 543-8555, Japan, E-mail: yskysk@kuhp.kyoto-u.ac.jp

Abstract

Rubinstein-Taybi syndrome (RTS) is an autosomal-dominant hereditary disease, which contains many skeletal and organ anomalies as well as mental retardation. Although high incidence of keloids in RTS is known, it is difficult to find a detailed report on the clinical features of keloids. In the following letter, we report an RTS patient fulfilling diagnostic criteria who suffered from both keloids and pilomatricoma. We also performed a literature search, which identified the possible involvement of the Wnt/ β -catenin signaling pathway in the pathogenesis of these two skin lesions.

Keywords: Rubinstein-Taybi syndrome, keloids, pilomatricoma, Wnt/ β -catenin

Introduction

Rubinstein-Taybi syndrome (RTS) is an autosomal-dominant hereditary disease, first described in 1963 by Rubinstein and Taybi, which contains many skeletal and organ anomalies as well as mental retardation. Diagnosis is made on the clinical criteria consisting of the presence of mental retardation associated with three major symptoms such as broad thumbs or first toes, columella show, and thick eyebrows or long eyelash (Japan Intractable Disease Information Center). DNA sequence or FISH reveals mutation of *cAMP response element-binding protein (CREB) binding protein (CBP)* [1], in 50-70% of patients, which can be used as supporting data for diagnosis. Although a high incidence of keloids in RTS is known, detailed reports on the clinical features of keloids are rare. Herein, we report an RTS patient fulfilling diagnostic criteria who suffered from both keloids

and pilomatricoma [2].

Case Synopsis

A 35-year-old man exhibited mental retardation, short stature, down slant of the palpebral fissures, strabismus, thick eyebrows and long eyelash, beaked nose (**Figure 1A**), and broad thumbs (**Figure 1B**). He was referred to our hospital with an ulcerative nodule (~15 mm in diameter) on his right shin (**Figure 1C**). He also had multiple, flat-topped, reddish, elastic hard nodules on the sternal and deltoid areas, for which the diagnosis of keloids was made clinically (**Figure 1D**). Histopathological examination of the totally excised nodule revealed ghost cells, calcifications, and multinucleated giant cells (**Figures 1 E, F**), indicative of pilomatricoma.

Discussion

The majority of RTS is caused by gene mutations in *CBP* in RTS [1] and less often by those in *p300*, also a regulator of CREB activity. CBP functions as a transcriptional cofactor or regulates transcription through histone acetyltransferase activity for various target molecules involving cell proliferation, differentiation, and apoptosis. In the present RTS case, the patient had both pilomatricoma and keloids, which are the most often associated cutaneous symptoms. As for pilomatricoma, activating mutation of *catenin- β 1* in the Wnt/ β -catenin signaling pathway has been found in humans [3]. In keloids, augmentation of Wnt-3a [4] and Wnt-5a signaling pathways have been reported.

CBP is known to regulate multiple target gene expression. The development of keloids is triggered by one or some of the CBP target molecules. Alternatively, since it was reported that Wnt-3a activation resulted in suppression of CBP function

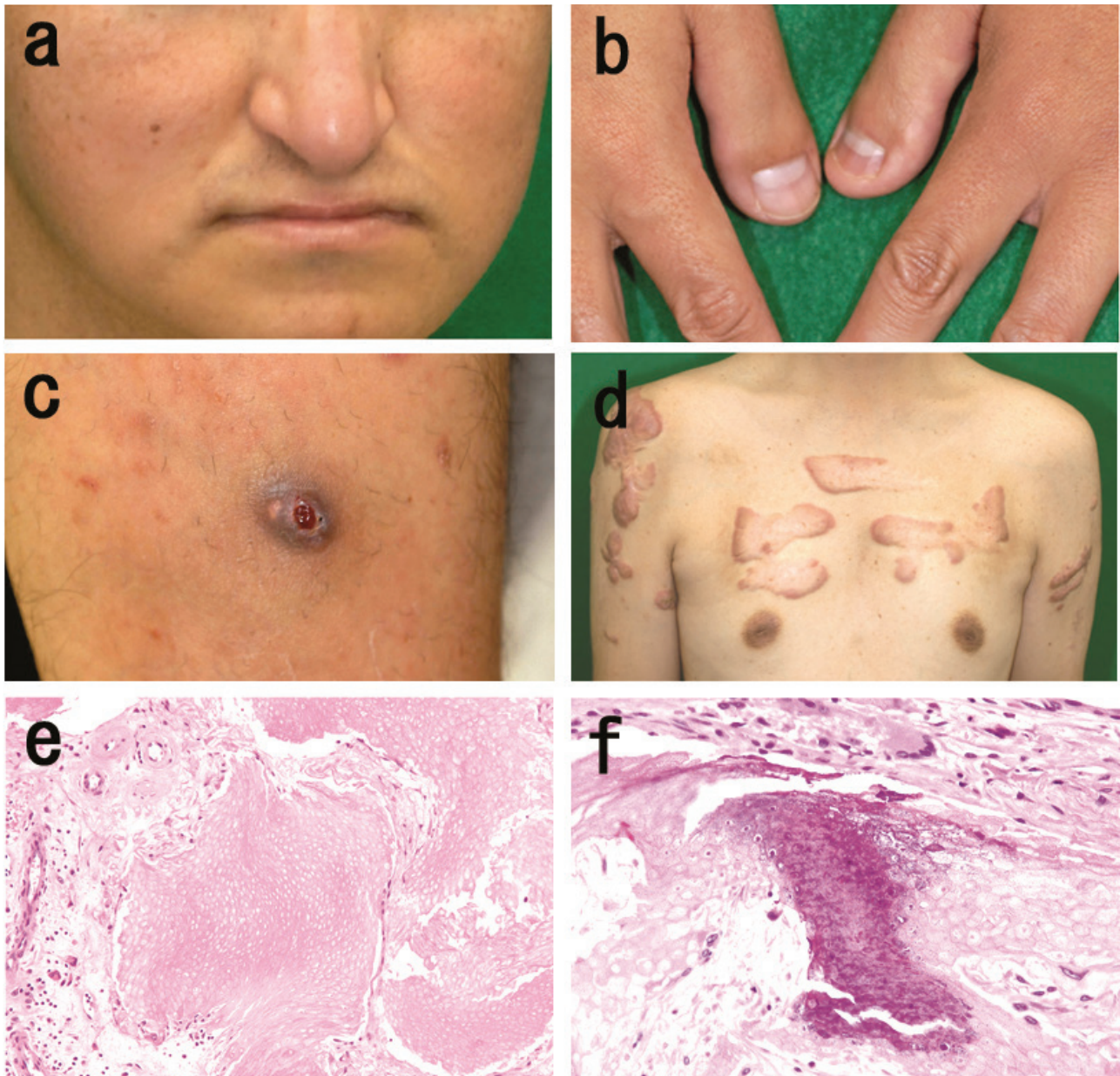


Figure 1. A) Beaked nose, B) broad thumbs, C) nodule on right shin, D) multiple keloids on the upper chest and upper arms. H&E histopathological examination. E) Ghost cells, 200 \times , and F) giant cells and calcification, 400 \times .

[5], it may be possible to explain the development of pilomatricoma and keloids in RTS by considering an interaction between Wnt/ β -catenin and CBP.

Conclusion

Genetic predisposition of keloids is strongly suspected by the presence of familial cases. However, until now, gene mutations in keloids have not been clarified, including any association with CBP/p300 and Wnt/ β -catenin. Therefore, it seems to be very intriguing to explore a possibility that CBP/p300 function and the Wnt/ β -catenin pathway may be involved in keloid development, as RTS is the only human disorder with keloids as a characteristic feature.

References

1. Petrij F, Giles RH, Dauwerse HG, Saris JJ, Hennekam RC, Masuno M, Tommerup N, van Ommen GJ, Goodman RH, Peters DJ. Rubinstein-Taybi syndrome caused by mutations in the transcriptional co-activator CBP. *Nature*. 1995;376(6538):348-51. [PMID: 7630403].
2. Masuno M, Imaizumi K, Ishii T, Kuroki Y, Baba N, Tanaka Y. Pilomatricomas in Rubinstein-Taybi syndrome. *Am J Med Genet*. 1998;77(1):81-2. Epub 1998/04/29. [PMID: 9557902].
3. Chan EF, Gat U, McNiff JM, Fuchs E. A common human skin tumour is caused by activating mutations in beta-catenin. *Nat Genet*. 1999;21(4):410-3. Epub 1999/04/07. [PMID: 10192393].
4. Lee WJ, Park JH, Shin JU, Noh H, Lew DH, Yang WI, Yun CO, Lee KH, Lee JH. Endothelial-to-mesenchymal transition induced by Wnt 3a in keloid pathogenesis. *Wound Repair Regen*. 2015;23(3):435-42. [PMID: 25845828].
5. Ma B, Fey M, Hottiger MO. WNT/ β -catenin signaling inhibits CBP-mediated RelA acetylation and expression of proinflammatory NF- κ B target genes. *J Cell Sci*. 2015;128(14):2430-6. [PMID: 26021349].