

UCLA

UCLA Previously Published Works

Title

The Clinical Significance of Anterior Horn Meniscal Tears Diagnosed on Magnetic Resonance Images*

Permalink

<https://escholarship.org/uc/item/4rd2498p>

Journal

The American Journal of Sports Medicine, 30(2)

ISSN

0363-5465

Authors

Shepard, Michael F
Hunter, David M
Davies, Mark R
et al.

Publication Date

2002-03-01

DOI

10.1177/03635465020300020701

Peer reviewed

The Clinical Significance of Anterior Horn Meniscal Tears Diagnosed on Magnetic Resonance Images*

Michael F. Shepard, †‡ MD, David M. Hunter, † MD, Mark R. Davies, † MD,
Matthew S. Shapiro, † MD, and Leanne L. Seeger, || MD

From the †Department of Orthopaedic Surgery and the ||Department of Radiological Sciences, University of California, Los Angeles, Center for the Health Sciences, Los Angeles, California

ABSTRACT

We assessed the accuracy of magnetic resonance imaging in detecting clinically significant lesions of the anterior horn of the meniscus by reviewing 947 consecutive knee magnetic resonance imaging reports. Of these, 76 (8%) indicated a tear of the anterior horn of the medial or lateral meniscus. Thirty-one of these 76 patients underwent a subsequent arthroscopic examination, and their operative reports were reviewed. The 45 patients who were not examined arthroscopically were contacted and interviewed for clinical follow-up. Among the 31 patients who underwent arthroscopic examination, 8 anterior horn tears were noted in the predicted area (26% true-positive results), 23 patients had intact anterior horns (74% false-positive results), and 18 had normal intact menisci in all zones. Of the 45 patients who did not undergo arthroscopic surgery, 6 had isolated anterior horn tears reported on magnetic resonance imaging, and 5 of the 6 were asymptomatic at follow-up. The other 39 patients had multiple pathologic conditions noted on the magnetic resonance imaging report and continued to report knee pain at the follow-up interview. Increased signal intensity at the anterior horn of the meniscus seen on magnetic resonance imaging commonly does not represent a clinically significant lesion. We recommend correlation with the physical examination when interpreting this "positive" finding on knee magnetic resonance imaging examinations.

Meniscal injury is one of the most common indications for knee surgery. The menisci function as shock absorbers and aid in the complex transmission of loads from the femur to the tibia.^{1,2,17} The medial meniscus is anchored to the deep fibers of the medial collateral ligament and is more prone to injury than is the lateral meniscus, which is more mobile.^{3,7} The menisci are divided into three zones or thirds: the anterior horn, the middle zone, and the posterior horn. The middle zone and the posterior horn have been shown to play the largest role in load transmission, transmitting up to 70% of the applied axial load in knee flexion.^{2,20,21} Isolated injury to the anterior horn, a supposedly less biomechanically active portion of the meniscus, has not been well described in the literature.

For both orthopaedic surgeons and primary care physicians, MRI has become the most widely used noninvasive test for assessing meniscal injuries.^{8,9,14,16} Accuracy in diagnosing meniscal tears on MRI has been reported to be as high as 98%.^{8,9,14,16} However, published reports have predominantly described evaluation of tears of the middle zone and posterior horn. Without clinical correlation, reliance on MRI to diagnose meniscal injuries could lead to unnecessary operations and risks for the patient. In addition, meniscal tears may be asymptomatic, and the presence of a tear does not necessarily account for a patient's symptoms.^{8,9,14,16,18} The purpose of this study was to determine the clinical significance of anterior horn meniscal tears diagnosed by routine MRI.

MATERIALS AND METHODS

We retrospectively reviewed the reports of 947 consecutive MRI examinations of the knee completed at one institution from January 1, 1996, to December 31, 1997. Anterior horn tears of either the medial or lateral meniscus were diagnosed 79 times in 76 patients (8%). Of the 947 reports, 937 (99%) were read by fellowship-trained musculoskeletal

*Presented at the interim meeting of the AOSSM, Orlando, Florida, March 2000.

‡ Address correspondence and reprint requests to Michael F. Shepard, MD, Department of Orthopaedic Surgery; UCLA Center for the Health Sciences, 10833 LeConte Avenue, Los Angeles, CA 90095.

No author or related institution has received any financial benefit from research in this study.

tal radiologists. General radiologists completed only 10 of the MRI reports (1% of total) and diagnosed only 2 of the 79 anterior horn tears (2% of all diagnosed anterior horn tears).

The medical records of the 76 patients who had a diagnosis of an anterior horn tear were reviewed. The chart and the operative notes of any patient undergoing arthroscopic surgery after having an MRI of the knee were reviewed to correlate operative findings with MRI findings. The patients who did not undergo surgery were interviewed by telephone a minimum of 1 year after the MRI examination to determine their residual symptoms and disability, if any. The patient interview consisted of eight questions designed to determine the presence of pain, disability, or mechanical symptoms, and whether the patient had sought and received further medical treatment (Table 1).

RESULTS

Of the 947 MRI reports, 79 (8%) indicated a diagnosis of anterior horn tear; 67 (85%) of these tears involved the lateral meniscus and 12 (15%), the medial meniscus. Thirty-eight (48%) of the 79 tears were diagnosed as also involving the middle zone or the posterior horn of the same meniscus. Other diagnoses noted on the MRI reports included meniscal tears of the midzone or posterior horn, ligament injuries, chondral lesions, loose bodies, patellar dislocations, cysts, and tumors.

Thirty-one patients with a diagnosis of anterior horn tear of either the medial or lateral meniscus underwent arthroscopic surgery. Indications for an arthroscopic procedure included a symptomatic meniscal tear (usually either mid- or posterior-third), ACL or PCL reconstruction, persistent pain, symptomatic plicae, a loose body, a significant osteochondral lesion, or a combination of these indications. The patients who underwent arthroscopic surgery had a mean age of 48.8 years and a mean number of 3.1 diagnoses made from their MRI reports. Of the 31 patients with anterior horn meniscal tears diagnosed by MRI, 8 (25.8%) had anterior horn tears documented in the operative report as correctly predicted by MRI (true-posi-

TABLE 1
Patient Interview Questions

1. Does your affected knee still bother you?
2. Has your knee pain or symptoms improved over the last year?
3. On a scale of 1 to 10, with 1 representing essentially a pain-free knee and 10 representing the worst pain you have ever experienced, please rate the pain in your knee that you currently are experiencing.
4. Does your knee ever lock, that is to say, does your knee get stuck in certain flexed positions that requires you to wait or to get help to straighten it?
5. After activity or at any time, does your knee ever get swollen or enlarged?
6. Does your knee restrict your activities in any way?
7. Have you seen another physician, other than the physician who ordered the MRI, for your knee problem?
8. Have you had any surgery on this knee since the MRI, either arthroscopic or open?

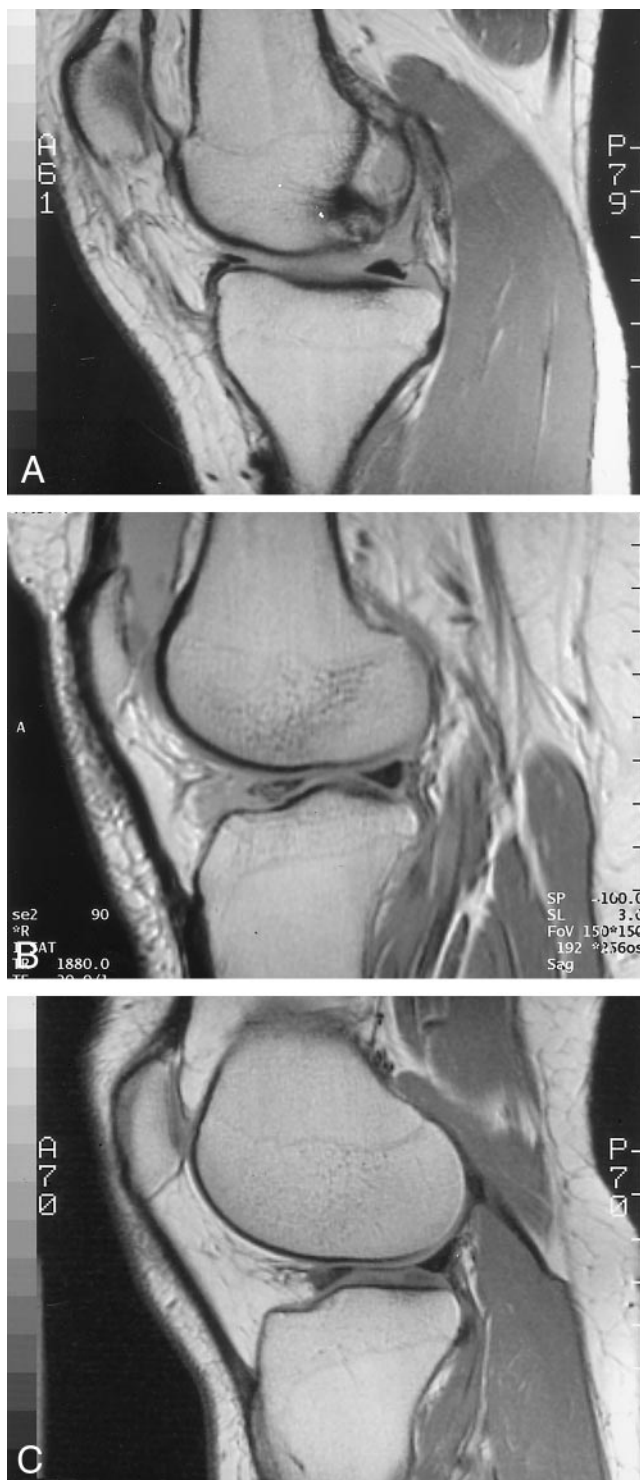


Figure 1. Magnetic resonance imaging scans of knees in which an anterior horn meniscal tear was diagnosed. A, a large anterior horn bucket-handle tear was found during arthroscopic examination (true-positive MRI result). B, an intact meniscus in all zones was found during arthroscopic examination (false-positive MRI result). C, patient was not examined arthroscopically and was completely asymptomatic at the time of the follow-up interview.

TABLE 2
Interview Results of Patients with Anterior Horn Tears on MRI
Who Did Not Undergo Arthroscopic Evaluation

Questions	Single diagnosis anterior horn tear	Multiple diagnosis anterior horn tear
Number of patients	6	39
Number contacted	6	32
Average age (years)	39.7	55.5
Average number of diagnoses	1	3.74
Knee bothersome (<i>N</i>)	1	17
Knee improved (<i>N</i>)	6	15
Mean pain scale score (1–10)	0.5	4.1
Locking (<i>N</i>)	0	2
Effusion (<i>N</i>)	0	12
Restricted movement (<i>N</i>)	1	19
Consulted another physician (<i>N</i>)	0	13
Another operation (<i>N</i>)	0	4 (total knee)

tive result) (Fig. 1A). No tear of the anterior horn was documented in the arthroscopic procedure of 23 patients (74.1%) (false-positive result) (Fig. 1B). In five patients (16.1%), the anterior horn was found to be intact, but tears were found in the posterior horn or middle zone. In 18 patients (58%), the arthroscopic examination revealed no meniscal pathologic condition.

Forty-five of the 76 patients (59.2%) who had MRI evidence of an anterior horn tear were treated nonoperatively. The mean age of this group was 53.4 years. The MRI reports of these patients contained a mean number of 3.5 diagnoses. Thirty-eight of these patients (84.8%) were available for clinical follow-up and were interviewed (Table 2).

Of the 45 patients treated nonoperatively, 6 had a diagnosis of an isolated anterior horn tear of either meniscus made from the MRI results (Fig. 1C). All six of these patients were interviewed, and five were asymptomatic at a minimum 1-year follow-up after the MRI scan. The sixth patient reported minimal pain (3 on a scale of 1 to 10) but denied mechanical symptoms and did not desire any further intervention.

Thirty-nine of the 45 patients treated nonoperatively had an average of 3.74 additional pathologic conditions noted on MRI scan. Thirty-two of the 39 patients (82%) were interviewed and reported an average pain score of 4.1 on a scale of 1 to 10. Although many of these patients reported improvement in the level of knee pain, a high percentage were still bothered by the affected knee or had consulted at least one additional physician with regard to their knee pain. Four of the 32 patients had undergone total knee arthroplasty before our interview.

DISCUSSION

Magnetic resonance imaging examination has become a valuable tool in assessing injury to the knee and, in general, has been reported to be highly sensitive and specific for tears of the meniscus.^{8,9,14,16} The sensitivity of MRI in

detecting meniscal tears has been reported in both the radiologic and orthopaedic literature as ranging from 70% to 98%, and specificity has been reported to range from 74% to 98%.^{8,9,14,16,18} Fischer et al.⁸ reported on 1014 patients in whom MRI performed before an arthroscopic examination had an accuracy of 89% for pathologic conditions of the medial meniscus and of 88% for the lateral meniscus. In a metaanalysis by Mackenzie et al.¹⁶ of 2000 patients who underwent MRI and arthroscopic examination, MRI was found to have an 88% sensitivity rate and a 94% accuracy rate for meniscal tears. However, most meniscal tears occur in the middle zone or posterior horn of the meniscus; therefore, information is lacking regarding the reliability of MRI in the diagnosis of the relatively uncommon anterior horn tear.

Many researchers have reported discrepancies between MRI diagnoses and diagnoses made during arthroscopic examination.^{5,6,12,13,15,18,23} Mackenzie et al.¹⁵ reviewed the records of 92 patients who underwent arthroscopic examination subsequent to MRI and found discrepancies between the MRI diagnosis and the arthroscopic findings in just 6% of, or 22 of the 349, diagnoses (including 10 medial meniscal tears and 6 lateral meniscal tears). Justice and Quinn¹² reported on patients undergoing both MRI and arthroscopic examination of the knee and found discrepancies in the diagnoses of 66 of the 561 patients (12%). Miller¹⁸ prospectively compared the results of clinical examinations and MRI in 57 consecutive knee examinations. By using arthroscopic examination as his standard, he found no significant difference in sensitivity between the results of clinical examination and of MRI (clinical examination, 80.7%; MRI, 73.7%).

The results of our arthroscopic findings demonstrate a higher percentage of false-positive results for anterior horn meniscal tears (74%) than previously described in the literature. Furthermore, our study showed more MRI-diagnosed anterior tears of the lateral meniscus (67) than of the medial meniscus (12). The reasons for the discrepancy between MRI and arthroscopic diagnosis in our study may be multiple. Shankman et al.²² recently reported on 22 patients who had increased signal of the anterior insertion of the meniscus but were found to have intact lateral menisci on arthroscopic examination. Furthermore, several authors have described variant insertions of the anterior horn of the medial meniscus that may be associated with hypermobility, mechanical symptoms, and abnormalities on MRI.^{4,11,19} Jerosch et al.¹⁰ showed that asymptomatic athletes, particularly those over the age of 50, had increased anterior horn signal without mechanical symptoms.

The patients undergoing arthroscopic procedures in our study were of a wide age range (18 to 96 years; mean, 48.8) and most of them certainly had degenerative changes of the knee as well as an acute tear of the meniscus. It is probable that many of the MRI discrepancies resulted from interpretation of degeneration of the meniscus as a tear. Finally, it can be difficult to visualize the anterior horn of the meniscus through standard arthroscopic portals. It is possible that some of these tears either did not

extend to the surface or could not be visualized using the standard arthroscopic portals.

Thirty-eight of the 76 patients with anterior horn tears who did not undergo arthroscopic examination were interviewed by phone. Six had isolated anterior horn meniscal tears, whereas the other 32 had multiple pathologic conditions noted on MRI that could also cause pain. These 32 patients continued to have knee pain, felt restricted by their knee condition, and had sought further medical attention for their knee pain. Attributing any symptoms to the pathologic condition of the anterior horn in this group of patients is problematic. Furthermore, these 32 patients had a mean age of 55.5 years, and a number of them would be expected to experience knee pain or symptoms from degenerative changes.

Six of the 947 patients (<1%) in the study had an isolated anterior horn meniscal tear on MRI and were treated nonoperatively. The interviews of these patients revealed significant differences in comparison with the group of patients who had additional pathologic conditions of the knee. Five of these patients had asymptomatic knees, and the sixth had only minor symptoms. A possible explanation for the lack of symptoms in this group could be that these tears represented false-positive results, similar to those demonstrated in the group undergoing arthroscopic examination. An alternative explanation is that the anterior horn of the medial meniscus is less important in the load-bearing function and, therefore, produces fewer clinically significant symptoms as compared with tears of the middle zone or posterior horns. Ahmed² and others^{20,21} have shown in vitro that meniscal contact pressures are greatest at the middle zone in extension and at the posterior horns in flexion. Furthermore, cadaveric studies have shown that, as long as the periphery of the torn meniscus remains intact, the highest contact pressures remain in the area from the middle zone to the posterior horn.^{2,20,21} Isolated anterior horn meniscal tears diagnosed on MRI are probably unimportant and may be well tolerated and amenable to nonoperative treatment. Rigorous clinical correlation must be required before the surgeon decides to operate on the basis of this diagnosis.

We recognize that there are limitations to this retrospective study. Specifically, multiple surgeons and radiologists were involved, which introduces an element of inconsistency. There was no attempt to correlate clinical findings before the MRI with the diagnosis; often, because primary care physicians referred many of these patients for MRI, this information was unavailable.

Although arthroscopy remains the standard procedure for diagnosing pathologic meniscal conditions, MRI has become a powerful diagnostic tool for the orthopaedic surgeon in evaluating knee pain and injury. Data from the Short Form-36 outcome instrument has demonstrated the positive effects of MRI as a diagnostic tool in the management of knee pain.¹⁴ However, the orthopaedic surgeon must correlate patient symptoms and physical findings to best treat patients with meniscal injuries, regardless of the location of the pathologic finding.

In conclusion, anterior horn tears were noted on 8% of all knee MRI reports at this institution over a 2-year period. Using arthroscopic findings as the standard, we found a 74% false-positive rate (23 of 31) for anterior horn meniscal tears. Increased MRI signal in the anterior horn commonly does not represent a clinically significant lesion. We recommend nonoperative treatment of anterior horn tears noted on MRI among patients without mechanical symptoms and whose clinical examination is inconsistent with the presence of a pathologic meniscal condition.

REFERENCES

1. Aagaard H, Verdonk R: Function of the normal meniscus and consequences of meniscal resection. *Scand J Med Sci Sports* 9: 134–140, 1999
2. Ahmed AM: The load bearing role of the knee menisci, in Mow VC, Arnoczky SP, Jackson DW (eds): *Knee Meniscus—Basic and Clinical Foundations*. New York, Raven Press, 1992, pp 59–72
3. Bellabarba C, Bush-Joseph CA, Bach BR Jr: Patterns of meniscal injury in the anterior-cruciate deficient knee: A review of the literature. *Am J Orthop* 26: 18–23, 1997
4. Berlet GC, Fowler PJ: The anterior horn of the medial meniscus. An anatomic study of its insertion. *Am J Sports Med* 26: 540–543, 1998
5. De Smet AA, Graf BK: Meniscal tears missed on MR imaging: Relationship to meniscal tear patterns and anterior cruciate ligament tears. *AJR Am J Roentgenol* 162: 905–911, 1994
6. De Smet AA, Norris MA, Yandow DR, et al: MR diagnosis of meniscal tears of the knee: Importance of high signal in the meniscus that extends to the surface. *AJR Am J Roentgenol* 161: 101–107, 1993
7. DiCarlo EF: Pathology of the meniscus, in Mow VC, Arnoczky SP, Jackson DW (eds) *Knee Meniscus—Basic and Clinical Foundations*. New York, Raven Press, 1992, pp 117–130
8. Fischer SP, Fox JM, Del Pizzo W, et al: Accuracy of diagnoses from magnetic resonance imaging of the knee. A multi-center analyses of one thousand and fourteen patients. *J Bone Joint Surg* 73A: 2–10, 1991
9. Gray SD, Kaplan PA, Dussault RG: Imaging of the knee—Current status. *Orthop Clin North Am* 28: 643–658, 1997
10. Jerosch J, Hoffstetter I, Reer R, et al: Strain-related long-term changes in the menisci in asymptomatic athletes. *Knee Surg Sports Traumatol Arthrosc* 2: 8–13, 1994
11. Jung YB, Yum JK, Bae YJ, et al: Anomalous insertion of the medial menisci [case report]. *Arthroscopy* 14: 505–507, 1998
12. Justice WW, Quinn SF: Error patterns in the MR imaging evaluation of menisci of the knee. *Radiology* 196: 617–621, 1995
13. LaPrade RF, Burnett QM II, Veenstra MA, et al: The prevalence of abnormal magnetic resonance imaging findings in asymptomatic knees. With correlation of magnetic resonance imaging to arthroscopic findings in symptomatic knees. *Am J Sports Med* 22: 739–745, 1994
14. Mackenzie R, Dixon AK, Keene GS, et al: Magnetic resonance imaging of the knee: Assessment of effectiveness. *Clin Radiol* 51: 245–250, 1996
15. Mackenzie R, Keene GS, Lomas DJ, et al: Errors at knee magnetic resonance imaging: True or false? *Br J Radiol* 68(814): 1045–1051, 1995
16. Mackenzie R, Palmer CR, Lomas DJ, et al: Magnetic resonance imaging of the knee: Diagnostic performance studies. *Clin Radiol* 51: 251–257, 1996
17. Messner K, Gao J: The menisci of the knee joint. Anatomical and functional characteristics, and a rationale for clinical treatment. *J Anat* 193: 161–178, 1998
18. Miller GK: A prospective study comparing the accuracy of the clinical diagnosis of meniscus tear with magnetic resonance imaging and its effect on clinical outcome. *Arthroscopy* 12: 406–413, 1996
19. Ohkoshi Y, Takeuchi T, Inoue C, et al: Arthroscopic studies of variants of the anterior horn of the medial meniscus. *Arthroscopy* 13: 725–730, 1997
20. Seedhom BB: Transmission of the load in the knee joint with special reference to the role of the menisci. Part I. Anatomy, analysis and apparatus. *Eng Med* 8: 207–219, 1979
21. Seedhom BB, Hargreaves DJ: Transmission of the load in the knee joint with special reference to the role of the menisci. Part II. Experimental results, discussion and conclusion. *Eng Med* 8: 220–228, 1979
22. Shankman S, Beltran J, Melamed E, et al: Anterior horn of the lateral meniscus: Another potential pitfall in MR imaging of the knee. *Radiology* 204: 181–184, 1997
23. Watanabe AT, Carter BC, Teitelbaum GP, et al: Common pitfalls in magnetic resonance imaging of the knee. *J Bone Joint Surg* 71A: 857–862, 1989