

# UC Davis

## UC Davis Previously Published Works

### Title

Second Extensor Compartment Entrapment in an Adult Following Distal Radius Fracture.

### Permalink

<https://escholarship.org/uc/item/4rb11990>

### Journal

Journal of Hand Surgery Global Online, 6(1)

### Authors

Beenfeldt, Davison

Delman, Connor

Bayne, Christopher

### Publication Date

2024

### DOI

10.1016/j.jhsg.2023.10.002

### Copyright Information

This work is made available under the terms of a Creative Commons Attribution-NonCommercial-NoDerivatives License, available at

<https://creativecommons.org/licenses/by-nc-nd/4.0/>

Peer reviewed



Contents lists available at ScienceDirect

Journal of Hand Surgery Global Online

journal homepage: [www.JHSGO.org](http://www.JHSGO.org)

## Case Report

## Second Extensor Compartment Entrapment in an Adult Following Distal Radius Fracture

Davison M. Beenfeldt, MD,\* Connor M. Delman, MD,\* Christopher O. Bayne, MD\*

\* University of California, Davis Medical Center, Sacramento, CA



## ARTICLE INFO

## Article history:

Received for publication October 11, 2023

Accepted in revised form October 14, 2023

## Key words:

Distal

Extensor

Interposition

Radius

Tendon

Extensor tendon entrapment in the presence of distal radius fracture is a known but relatively uncommon complication. Single tendon or entire compartment entrapment has been described through the literature in youths and adults. However these findings generally are limited to a certain age demographic or are found on advanced imaging but are unable to be confirmed intraoperatively. We describe to our knowledge the first known description of second extensor compartment entrapment in an adult seen on computerized tomography scan and confirmed intraoperatively.

Copyright © 2023, THE AUTHORS. Published by Elsevier Inc. on behalf of The American Society for Surgery of the Hand. This is an open access article under the CC BY-NC-ND license (<http://creativecommons.org/licenses/by-nc-nd/4.0/>).

Extensor tendon entrapment is a known, but uncommon, complication of distal radius fracture, generally Smith-type fractures, in youths and adults.<sup>1</sup> Most cases report entrapment of the extensor pollicis longus tendon (EPL).<sup>2–5</sup> However, entrapment of the extensor indicis proprius (EIP), extensor digitorum (ED), and extensor carpi ulnaris (ECU) also have been described.<sup>1,6–8</sup> Less commonly described is the entrapment or interposition of the second extensor compartment containing extensor carpi radialis longus (ECRL) and extensor carpi radialis brevis (ECRB) tendons. Entrapment of the ECRL tendon has been reported on computed tomography (CT) imaging in an adult although it was unable to be confirmed intraoperatively.<sup>1</sup> Only two prior cases have confirmed entrapment of the ECRL and ECRB tendons intraoperatively, found in two pediatric patients.<sup>9</sup> Here we report a case of second extensor compartment interposition in an adult following fracture of the distal radius confirmed intraoperatively. To our knowledge, this is the first time that such a case has been described. Written informed consent was obtained from the patient for publication of this case report and accompanying images.

**Declaration of interests:** No benefits in any form have been received or will be received related directly to this article. Publication fee paid for by University of California, Davis Medicine. No other benefits have been received or will be received in relation to this article

**Corresponding author:** Davison M. Beenfeldt, MD, Resident, PGY-1, University Hospitals/Case Western Reserve, 11100 Euclid Ave, Cleveland, OH 44106.

E-mail address: [dbeenfeldt@gmail.com](mailto:dbeenfeldt@gmail.com) (D.M. Beenfeldt).

## Case Report

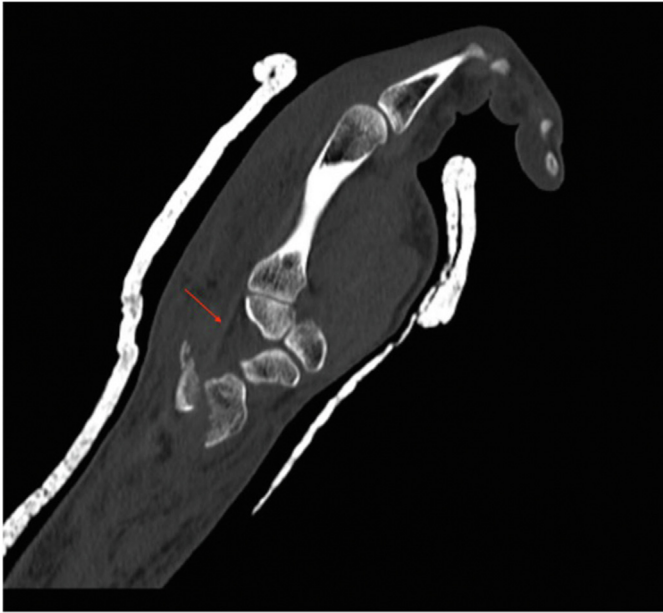
A 45-year-old man presented via ambulance following an electric scooter crash with a chief complain of right upper extremity pain. Physical examination was notable for significant right wrist pain and swelling with limited wrist range of motion. He was neurovascularly intact. Radiographs obtained in the emergency department showed a right, displaced, intra-articular shear fracture of the volar lip of the distal radius with complete associated radiocarpal dissociation. The patient did not have any other notable or pertinent comorbidities and had no known drug allergies.

Computed tomography imaging of the right upper extremity later indicated entrapment of the second compartment extensor tendons within the fracture fragments (Fig. 1). Attempts at closed reduction of the fracture were unsuccessful. After consent was obtained for operative fixation, a volar (flexor carpi radialis) approach to the distal radius was chosen for open reduction and exploration of the radius fracture. Following elevation and retraction of overlying musculature, the distal radial fracture was prepared carefully using curette and rongeur. Within the fracture fragment was interposed a second dorsal compartment including the ECRL and ECRB tendons (Fig. 2). These were freed successfully from the fracture with gentle manipulation.

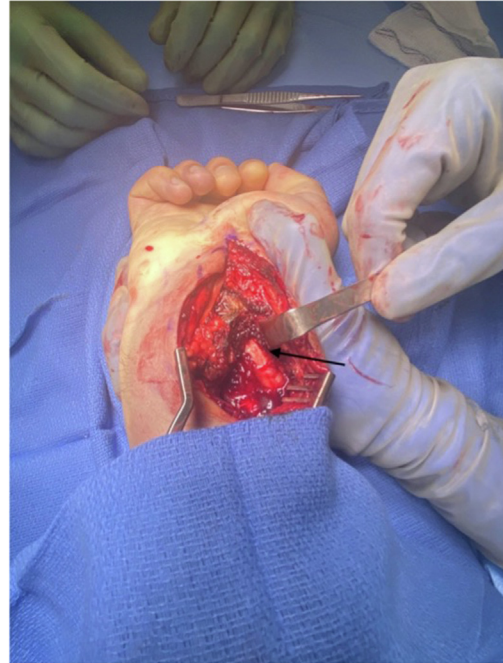
Following relocation of the interposed tendons, manual reduction was obtained under fluoroscopy and a volar locking plate was fixed internally to the distal radius. The patient was admitted to the orthopedic hand service for 24-hour antibiotics and pain control and was discharged the following day. The patient was seen in

<https://doi.org/10.1016/j.jhsg.2023.10.002>

2589-5141/Copyright © 2023, THE AUTHORS. Published by Elsevier Inc. on behalf of The American Society for Surgery of the Hand. This is an open access article under the CC BY-NC-ND license (<http://creativecommons.org/licenses/by-nc-nd/4.0/>).



**Figure 1.** Computed tomography imaging of the right wrist displaying the second extensor compartment entrapment, denoted by a red arrow.



**Figure 2.** Intraoperative image of the second dorsal compartment entrapped within the fracture, denoted by a black arrow.

**Table**  
Prior Cases of Extensor Tendon Entrapment, with the Only Other Case of Second Dorsal Compartment Entrapment Occurring in a 13-Year-Old Female

Case	Age	Sex	Side	Involved Tendons	Fracture Pattern
1	12	M	R	EPL	Type IV Smith's fracture
2	12	M	L	ECU	Comminuted distal radius fracture with DRUJ widening
3	12	M	L	ECRB	Type II Salter-Harris fracture
4	13	M	L	ECRL, ECRB	Type II Salter-Harris fracture
5	13	F	L	Extensor tendons	Salter-Harris Type II Smith's fracture
6	17	M	R	EIP	Extensor tendon rupture with subsequent entrapment
7	18	M	L	EPL	Sheer-type metaphyseal distal radial fracture
8	24	M	L	EPL	Displaced Smith's fracture with a comminuted fracture of the distal ulna
9	37	M	L	EPL, EIP, EDC, EDM	Volarly displaced distal radial fracture with dorsal dislocation of the ulna

DRUJ, distal radial ulnar joint; ERCL, extensor carpi radialis longus; ECRB, extensor carpi radialis brevis; EPL, extensor pollicis longus; ECU, extensor carpi ulnaris; EIP, extensor indicis pollicis; EDC, extensor digitorum communis; EDM, extensor digiti minimi.

clinic 2 weeks following discharge and reported minimal pain with full flexion and extension of his digits. Radiographs at this visit shows a healing and well-reduced distal radius fracture with good anatomical alignment.

## Discussion

Extensor tendon entrapment is a previously described but uncommon complication of distal radius fracture in children and adults (Table). Based on previous reports, extensor tendon entrapment is more common in children,<sup>4,6,7,9,10</sup> with interposition of the EPL tendon occurring most commonly among all age groups.<sup>5,8,10</sup> A case of isolated ECU entrapment has been reported by Hanel and Scheid<sup>7</sup> and EIP tendon entrapment by Piotuch et al.<sup>6</sup> In the case of extensor tendon entrapment, it also is possible for multiple extensor compartments to be involved as reported by Okazaki et al.<sup>3</sup> as well as Thomas and Kershaw.<sup>10</sup> However, entrapment of the second extensor compartment has been described only one time previously by Amemiva et al.<sup>9</sup> which occurred in a child. We describe to our knowledge the first known

case of entrapment of the second extensor compartment in an adult confirmed intraoperatively.

This patient suffered a high-velocity injury leading to a distal radius fracture as described previously. It is assumed that the mechanism of this injury and volar shear fracture pattern led to rupture of the extensor retinaculum. Disruption of this structure consequently allowed for free movement and ultimately, interposition of the ECRB and ECRL tendons into the fracture site.

Computed tomography imaging before surgical fixation was consistent with a second extensor compartment entrapment, which can aid in diagnosis. However, advanced imaging diagnoses do not always correlate with intraoperative findings.<sup>1</sup> This case also was complicated by two unsuccessful attempts at closed reduction further suggesting interposition of a bony fragment or soft tissue. It also is important to note that there was no noticeable reduction in the patient's ability to extend or abduct his hand at the wrist. However, it can be difficult to assess individual tendon function in the acute setting due to pain limitations or the actions of unaffected wrist extensors or abductors, such as ECU or flexor carpi radialis, respectively.

Our patient demonstrated a good clinical outcome post-operatively with full wrist abduction and extension at a 1-year

follow up visit. The *QuickDASH* (The Disability of Arm, Shoulder, and Hand) score at this time was 2.27, reporting only mild tingling of the right hand.

Extensor compartment interposition is an uncommon but possible complication of distal radius fractures in the adult population. Therefore, entrapment of an extensor tendon or compartment should be considered in an adult with an irreducible distal radius fracture and correlated CT findings even without a supporting physical exam.

## References

1. Nigh ED, Emerson CP, To D, et al. Extensor tendon entrapment on computed tomography imaging of distal radius fractures. *J Wrist Surg.* 2020;9(2):129–135.
2. Mohanlal P, Jain S. Irreducible distal radial fracture due to extensor pollicis longus tendon interposition: a case report. *Cases J.* 2009;2:6822.
3. Okazaki M, Tazaki K, Nakamura T. Extensor tendon entrapment in volarly displaced distal radial fracture. *J Hand Surg Eur Vol.* 2007;32(2):230–230.
4. El-Kazzi W, Schuind F. Extensor Pollicis longus entrapment in a paediatric distal radius fracture. *J Hand Surg.* 2005;30(6):648–649.
5. Kumar A, Kelly CP. Extensor pollicis longus entrapment after Smith's fracture. *Injury.* 2003;34(1):75–78.
6. Piotuch B, Puchalski P, Żyluk A. Entrapment of the extensor indicis proprius tendon in the callus after a distal radial fracture. *J Hand Surg Eur Vol.* 2015;40(5):541–542.
7. Hanel D, Scheid D. Irreducible fracture-dislocation of the distal radioulnar joint secondary to entrapment of the extensor carpi ulnaris tendon. *Clin Orthop.* 1988;234:56–60.
8. Okazaki M, Tazaki K, Nakamura T, Toyama Y, Sato K. Tendon entrapment in distal radius fractures. *J Hand Surg Eur Vol.* 2009;34(4):479–482.
9. Amemiya T, Okazaki M, Kato T, Tazaki K. Radial wrist extensor tendon entrapment in volarly displaced distal radius fracture. *JBJS Case Connector.* 2022;12(1).
10. Thomas, Kershaw C. Entrapment of extensor tendons in a Smith's fracture: brief report. *J Bone Joint Surg.* 1988;70(3):491–491.