

UC Davis

Dermatology Online Journal

Title

Recalcitrant Nicolau syndrome following repeated intramuscular diclofenac injections

Permalink

<https://escholarship.org/uc/item/4mw0f778>

Journal

Dermatology Online Journal, 31(1)

Authors

Unal, Ismail H.

Akoglu, Gulsen

Simsek, Gulcin

Publication Date

2025

DOI

10.5070/D331164973

Copyright Information

Copyright 2025 by the author(s). This work is made available under the terms of a Creative Commons Attribution-NonCommercial-NoDerivatives License, available at

<https://creativecommons.org/licenses/by-nc-nd/4.0/>

Peer reviewed

Recalcitrant Nicolau syndrome following repeated intramuscular diclofenac injections

İsmail H. Ünal¹, Gülşen Akoğlu¹, Gülçin Şimşek²

Affiliations: ¹ University of Health Sciences, Gulhane Training and Research Hospital, Dermatovenereology, Ankara, Türkiye,

² University of Health Sciences, Gulhane Training and Research Hospital, Pathology, Ankara, Türkiye

Corresponding Author: Prof. Dr. Gülşen Akoğlu, University of Health Sciences, Gülhane Training and Research Hospital, General Dr. Tevfik Sağlam Cd. No:1 Etlik, Ankara, Türkiye, Tel: 90-312-304-4457, Email: gusemd@yahoo.com

Keywords: adverse reaction, Nicolau syndrome, ulcer

To the Editor:

Nicolau syndrome is a severe complication that occurs rarely but notably after intramuscular injections. It is characterized by intense pain at the injection site, skin discoloration, and tissue necrosis. Although the exact pathogenesis of the disease remains unclear, a vascular occlusion etiology is considered to play a significant role [1].

A 42-year-old woman presented to our clinic with a painful and itchy wound that emerged following repeated intramuscular diclofenac injections for pain control in her right buttock that had persisted for about a year after uterine artery embolization. Dermatological examination revealed a well-defined, firm, erythematous plaque with crusted edges, measuring approximately 17x9cm in the right gluteal region (**Figure 1**). Otherwise, other body skin regions were normal. The patient's medical history was unremarkable. She had used numerous topical corticosteroids and topical and systemic antibiotics, which did not provide healing.

Histopathological examination of a skin biopsy showed mixed-type dermal inflammation and fibrosis (**Figure 2**). Considering the clinical and histopathological findings, the patient was diagnosed with Nicolau syndrome. The patient was put on antibiotic treatment owing to secondary

pseudomonal infection and colchicine therapy with a dose of 1.2mg/d to provide the anti-fibrotic effect.

Mechanical wound debridement was performed with a fractional erbium-doped yttrium aluminum garnet laser and alginate wound dressings were applied. Over a follow-up period of approximately four months of colchicine therapy, epithelialization in the former crusted area progressed, resulting in almost total healing (**Figure 3**). The patient's complaints of pain and itching significantly decreased.

Also known as embolia cutis medicamentosa, Nicolau syndrome was first reported in 1924 following the intramuscular injection of bismuth salts for the treatment of syphilis [1,2]. Subsequently, cases have been reported with various other drugs, including corticosteroids and nonsteroidal anti-inflammatory drugs [2]. Although it is frequently associated with intramuscular injections, Nicolau syndrome can also develop after intra-articular, subcutaneous, and intravenous injections [1,3,4]. Although it commonly manifests in the gluteal region, as seen in our patient, it can also occur in other parts of the body.

The pathogenesis of Nicolau syndrome is an area of ongoing research, inviting the active engagement of medical professionals. Although the exact mechanisms are yet to be fully understood, several hypotheses have been proposed. These include

vasospasm related to needle entry, disruption of tissue nutrition owing to vascular occlusion caused by the injected material, and impaired blood flow in the tissue resulting from a tissue reaction to the injected drug. Patient-related factors such as vascular anomalies and comorbid conditions are likely important factors [1,2,3,4]. As seen in our patient, the resulting vasospasm or vascular damage leads to ischemia and necrosis of the skin and subcutaneous tissues. Recent evidence suggests that diclofenac may increase the risk of arterial thrombosis, similar to selective cyclooxygenase-2 inhibitors [5]. In our case, we may speculate that diclofenac caused a local thrombotic-induced necrosis and subsequent ulceration.

The diagnosis of Nicolau syndrome is generally clinical, with skin biopsy primarily revealing skin necrosis related to ischemia [6]. The ulcer resulting from necrosis heals with a prominent scar. The treatment of Nicolau syndrome is conservative. Modalities used in treatment include covering the lesion with wound dressings, pain management, antibiotic therapy for secondary infections, pentoxifylline, hyperbaric oxygen therapy, and debridement [2,7]. Surgical intervention is rarely required. Colchicine is a medication used in dermatology practice for many diseases because of its antimetabolic and anti-inflammatory effects. It also exhibits antifibrotic effects by inhibiting fibroblast proliferation and collagen synthesis [8]. Because of its antifibrotic effect, colchicine has been suggested by clinicians for liver cirrhosis and scleroderma [9]. In our patient, colchicine was used to treat the fibrotic plaque. Partial softening of the tissue was observed during follow-up; ongoing patient monitoring continues.

In conclusion, repeated intramuscular diclofenac injections can lead to treatment-resistant fibrotic ulcers of Nicolau syndrome. Colchicine, because of its antifibrotic effects, may help in the management of the disorder.

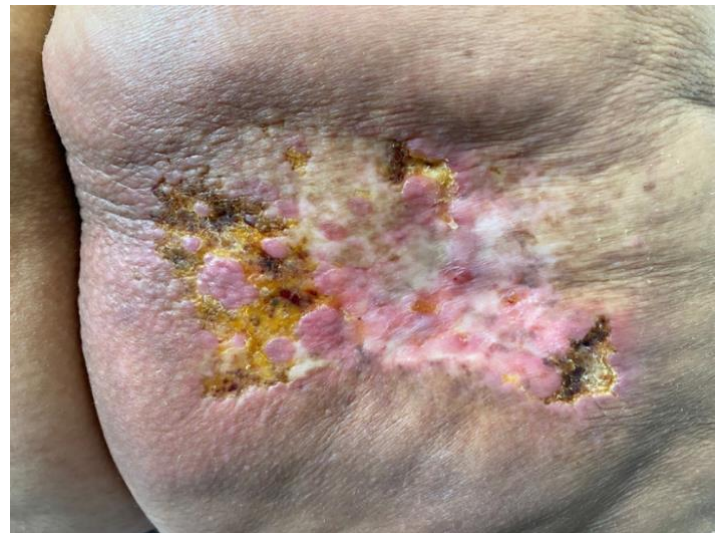

Figure 1. A large fibrotic plaque on the patient's right gluteal region with areas of ulceration covered by crusts.

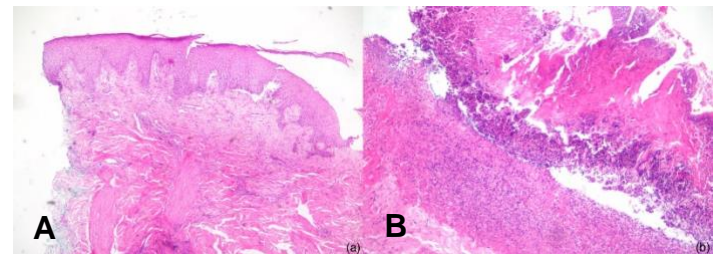


Figure 2. A) Fibrosis in the dermis (hematoxylin and eosin staining x40). **B)** Erosion and focal ulceration of the surface epithelium with active chronic inflammation (hematoxylin and eosin staining x100).

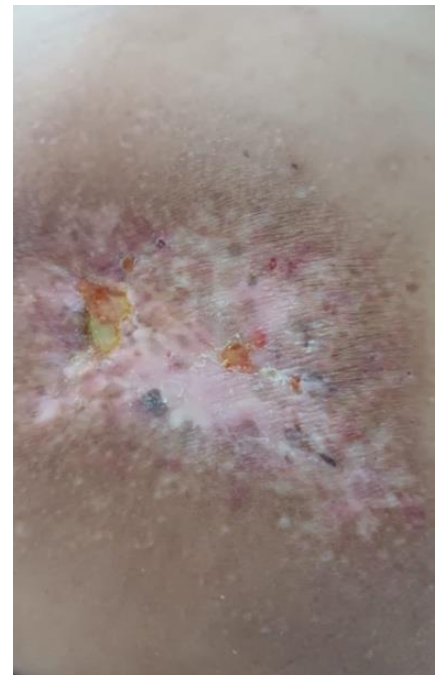


Figure 3. Significant improvement with softening and healing of ulcerations after 5 months of treatment.

Potential conflicts of interest

The authors declare no conflicts of interest.

References

1. De Sousa R, Dang A, Rataboli P. Nicolau syndrome following intramuscular benzathine penicillin. *J Postgrad Med.* 2008;4:332-4. [PMID: 18953160].
2. Nayci S, Gurel MS. Nicolau syndrome following intramuscular diclofenac injection. *Indian Dermatol Online J.* 2013;4:152-3. [PMID: 23741679].
3. Cherasse A, Kahn MF, Mistrih R, et al. Nicolau's syndrome after local glucocorticoid injection. *Joint Bone Spine.* 2003;70:390-2. [PMID: 14563471].
4. van Linthoudt D, Kurmann PT. Livedoid dermatitis of the shoulder after a repeated subacromial corticosteroid injection. *Praxis (Bern).* 2006;95:1499-503. [PMID: 17061464].
5. Struthmann L, Hellwig N, Pircher J, et al. Prothrombotic effects of diclofenac on arteriolar platelet activation and thrombosis in vivo. *J Thromb Haemost.* 2009;7:1727-35. [PMID: 19691487].
6. Yebenes M, Gilaberte M, Toll A, Barranco C, Pujol RM. Localized retiform purpura after accidental intra-arterial injection of polidocanol. *Acta Dermatol Venereol.* 2005;85:372-3. [PMID: 16191871].
7. Geukens J, Rabe E, Bieber T. Embolia cutis medicamentosa of the foot after sclerotherapy. *Eur J Dermatol.* 1999;9:132-3. [PMID: 10066964].
8. Entzian P, Schlaak M, Seitzer U, et al. Antiinflammatory and antifibrotic properties of colchicine: Implications for idiopathic pulmonary fibrosis. *Lung.* 1997;175:41-51. [PMID: 8959672].
9. Ozdemir BH, Ozdemir FN, Sezer S, Sar A, Haberal M. Does colchicine have an antifibrotic effect on development of interstitial fibrosis in renal allografts of recipients with familial Mediterranean fever? *Transplant Proc.* 2006;38:473-6. [PMID: 16549151].