

UC Irvine

UC Irvine Previously Published Works

Title

Caudal Septal Extension Grafts

Permalink

<https://escholarship.org/uc/item/4kz52834>

ISBN

9783642280528

Authors

Chiu-Collins, Lynn L
Furze, Alexis D
Wong, Brian JF

Publication Date

2013

DOI

10.1007/978-3-642-28053-5_42

Copyright Information

This work is made available under the terms of a Creative Commons Attribution License, available at <https://creativecommons.org/licenses/by/4.0/>

Peer reviewed

Lynn L. Chiu-Collins, Alexis D. Furze,
and Brian J.F. Wong

42.1 Introduction

The caudal septal extension graft (CSEG) was popularized by Toriumi and others for use in aesthetic rhinoplasty as a secure means to independently control tip projection, rotation, and nasal length. CSEGs are cartilage grafts placed at the caudal margin of the nasal septum (Fig. 42.1). They function to improve nasal tip position or columella shape through modification of either the anterior septal and/or posterior septal angle position. These grafts are differentiated from traditional free-floating columellar strut grafts in that they are securely fixed to the caudal margin of the septum. Using this septal attachment as a

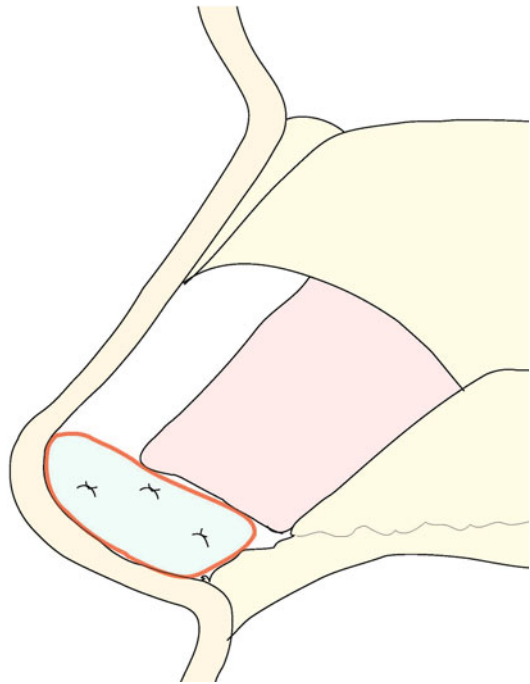


Fig. 42.1 Caudal septal extension graft (CSEG) is placed at the caudal margin of the septum either in overlapping or end-to-end configuration

L.L. Chiu-Collins, M.D.

Division of Facial Plastic Surgery, The Department of Otolaryngology – Head and Neck Surgery-5386, The University of California Irvine, 19182 Jamboree Road, Irvine, CA 92617, USA
e-mail: lynnchiu.md@gmail.com

A.D. Furze, M.D.

2552 Walnut Ave. #130, Tustin, CA 92780, USA
e-mail: alexis.furze@gmail.com

B.J.F. Wong, M.D., Ph.D. (✉)

Facial Plastic Surgery, The Beckman Laser Institute and Medical Clinic, The University of California Irvine, 1002 Health Sciences Road East, Irvine, CA 92617, USA

Division of Facial Plastic Surgery,

The Department of Otolaryngology – Head and Neck Surgery -5386, The University of California Irvine, 19182 Jamboree Road, Irvine, CA 92617, USA
e-mail: bjwong@uci.edu

defining element for these grafts, it appears that the first caudal septal extension graft description was actually termed a columellar strut and was described as a maneuver in cleft rhinoplasty that consisted of an end-to-end augmentation of the caudal septum [1]. Later, this technique included overlapping the graft with the caudal margin of the nasal septum and was described as a columellar control strut [2].

The term “caudal septal extension” was initially used to describe a maneuver performed in subtotal septectomy and reconstruction. In the description of this procedure, the reconstructed L-strut was designed with additional dorsal length, which allowed the strut to sit further caudally than the position of the native caudal septal margin. The medial crura were then sutured to the new caudal margin, influencing nasal tip position and stability, as well as the shape of the columella via a tongue-in-groove approach [3]. Later, it was described that patients with a retracted columella could also benefit from caudal septal lengthening. Similar to the earlier descriptions of caudal septal extension grafting, the medial crura were also secured to the extension graft for improved stability of the tip and columella [4]. These methods recapitulate the “tongue-in-groove” method while offering additional structural advantages. Pure “tongue-in-groove” approaches that simply secure medial crura to the caudal septum are powerful methods to stabilize the nasal tip, but must be exercised with caution as overrotation is a common outcome if the patient has inadequate native caudal septum; therein lies the utility of the CSEG.

42.2 Advantages and Disadvantages

In open structure rhinoplasty, CSEGs are being more widely used, replacing traditional columellar strut graft techniques. CSEGs have several advantages over this classic approach. Traditional columellar struts are free floating and limited in the degree of projection that can be achieved. Columellar struts rely upon the use of shield- and cap-type grafts to increase projection or require a lengthy graft that is either resting on or sutured to the nasal spine. In contrast, CSEG’s allow the surgeon to use the native domes to define the tip by securing the tip complex to an extended portion of the septum.

CSEGs can be used to alter nasal length, projection, supratip break, tip rotation, columella shape, infratip lobule position, and nasolabial angle, all independent of each other [5, 6]. The surgeon has the freedom to adjust a structural feature as an isolated element. The graft size and

shape are then customized to achieve the specific goals of the surgeon and patient.

A limitation of the CSEG method is nasal tip stiffness and decreased compliance in comparison to traditional floating columellar strut methods. The patient must be informed of this prior to surgery. There is a technical learning curve when using this method, as all of the aforementioned features of the nasal tip on lateral view change and surgery requires intraoperative analysis and reanalysis to ensure an appropriate outcome. This approach may require the repeated placement and replacement of the CSEG along with attachment and reattachment of the medial crura to assess outcomes. Intraoperative analysis is imperative—if the CSEG is not carefully planned, there is risk of excessive columellar show or blunting of the columella with absence of the “double break” curvature. Depending upon the specific application and need for projection and counterrotation, inadequate cartilage may necessitate the use of conchal or costal cartilage.

42.3 Indications and Contraindications

In open structure rhinoplasty, a CSEG should be considered in cases where significant changes in nasal tip projection are needed, particularly where length must be increased while rotation is preserved. This is a particularly powerful technique in patients with severe nasal tip ptosis or in platyrrhine noses such those encountered in Latin or Asian patients. In cases of significant caudal septal cartilage excess, the more straightforward tongue-in-groove approach can be used. CSEGs are also valuable in circumstances where postoperative loss of projection may occur due to contraction and wound healing such as in revision rhinoplasty operations.

The role of the CSEG in a patient with cephalically oriented lower lateral cartilage should be discussed here. In these patients, if the CSEG is used to lengthen the dorsum or counterrotate the nose, there is a risk of creating weakness in the soft triangle region and a potential “parenthesis sign” deformity. Alternatively, if rotation or reduction of

nasal length is required, then CSEGs or the tongue-in-groove technique will result in improvement of the lower lateral cartilage cephalic orientation. Finally, the external valve must be evaluated as part of the rhinoplasty process if a CSEG is anticipated for use. CSEGs, when overlapping the native septum, may significantly reduce the area of the nasal aperture at the external nasal valve, and this would also be a contraindication to use.

42.4 General Surgical Technique

The basic surgical technique of CSEG placement remains the same regardless of the effect desired. The cartilage can be harvested from the nasal septum (ideal), the conchal bowl, or costal margin. Use of conchal cartilage must be exercised with caution as these grafts may be curved or lack adequate mechanical stability in many cases. The graft will typically be shaped and sized prior to implantation, but then precisely

modified in situ. Classically, caudal septal extension grafting is performed during open rhinoplasty after separating the nasal domes from one another, dividing intervening soft tissue and exposing the septal cartilage by elevating the mucoperichondrial flaps on either side down to the posterior septal angle. If necessary, wider exposure of the nasal septum can be achieved by separating the upper lateral cartilages from the dorsal septum.

The graft is most often partially overlapped with the caudal margin of the nasal septum and sutured into place with multiple mattress sutures in a manner that allows the caudal margin of the graft to lie in the midline (Fig. 42.2) [4, 6]. In most applications, the graft is overlapped with the native caudal septum and held in position using 25- or 27-gauge hypodermic needles before suturing into place (Fig. 42.3). Suture selection remains controversial, though the senior author uses either absorbable or permanent sutures depending on the degree of load

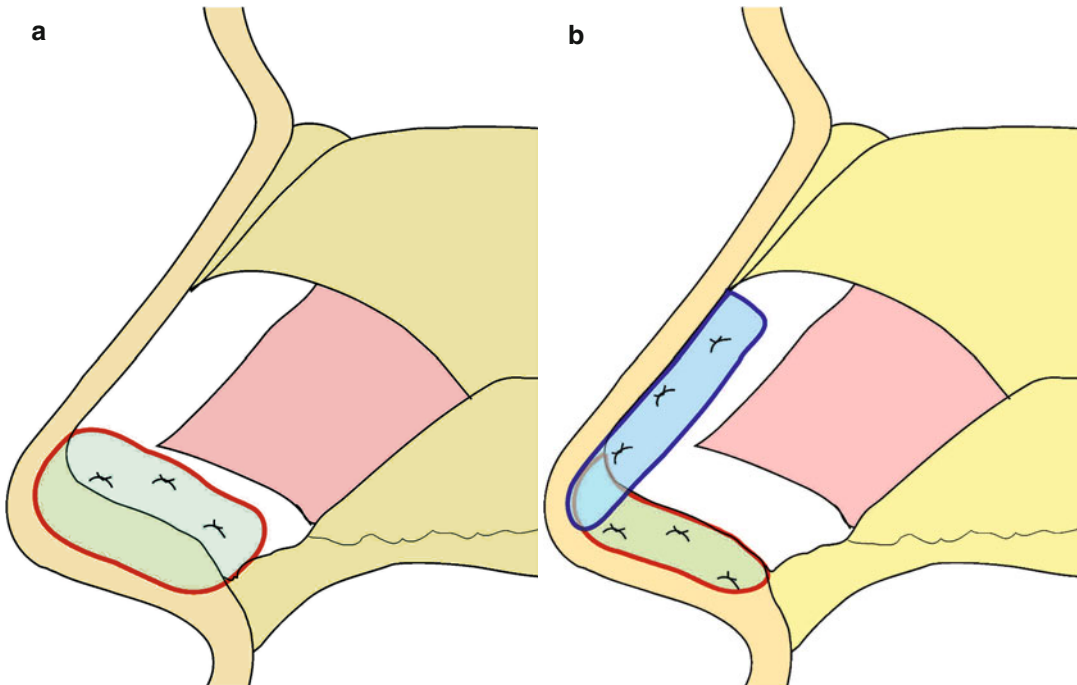


Fig. 42.2 Grafts are secured in (a) an overlapping fashion with multiple sutures to counter gravity and flexure or (b) an end-to-end fashion secured either with small

buttress grafts or extended spreaders. Suture material can be absorbable or permanent depending upon long-term forces acting on the graft

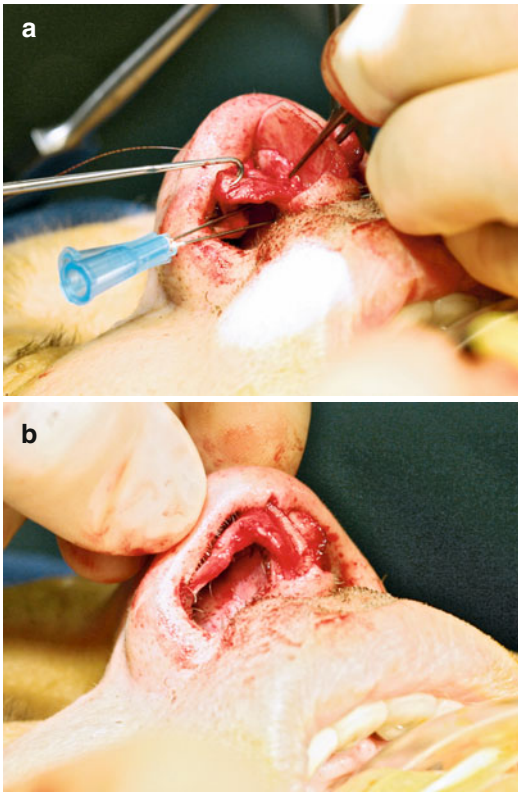


Fig. 42.3 (a) CSEG stabilized with 25-g hypodermic needles. Use of a large graft creates significant projection as well as control of the columella shape. (b) The medial crura are secured to the CSEG, and dome sutures reconstruct the tip

bearing anticipated. In either case, at least three sutures are used to secure the graft in position. The CSEG is particularly valuable in cases where the native caudal septum is deviated off the midline; in this situation, the graft is positioned to correct this deformity. In cases where this overlap creates a caudal deviation at the tip or columella, the cephalic portion of the graft can be trimmed or the graft itself can be placed in an end-to-end configuration with the caudal septum with thin splinting grafts or extended spreader grafts placed to reinforce the extension graft on its lateral aspects (Fig. 42.2) [6]. PDS plates can be used as well, but these are discussed elsewhere in this volume. Of note, when securing the CSEG to the septum in an overlapping manner, attention must be paid to the external valve, as graft

placement may potentially narrow the nasal aperture in this area. Likewise, when the graft significantly projects the nose, the downward forces on the tip generated after closure of the skin soft tissue envelope may lead to buckling or torsional deformation of the graft and caudal septum. In these circumstances, one should consider securing both the graft and the posterior septal angle to the nasal spine and using a CSEG that extends to the spine as well.

Once the CSEG is in place, the medial crura are sutured to the caudal margin of the graft in a tongue-in-groove fashion in order to stabilize the tip and control its position along with the degree of columellar show and infratip lobule shape (Fig. 42.3) [7, 8]. Alternatively, the medial crura may be suspended from the caudal end of the graft, in an end-to-end manner, using figure-of-eight sutures as well, though this is less commonly performed and the fixation less secure and may be prone to “cheese wiring” if the tip is excessively mechanically loaded. Once the medial crura are secured to the CSEG, domal geometry is reestablished using conventional suture techniques. When executed properly, tip and shields grafts are not required as the native domal cartilages are sutured to create an aesthetically contoured tip. Modification of lower lateral cartilage shape is performed as in conventional rhinoplasty.

The size and shape of the CSEG, as well as the position in which the medial crura are attached to the graft will determine the desired effect on nasal shape. This grafting technique can be used to increase nasal tip projection, rotation, or counterrotation. It can also be used to lengthen the nose, increase or decrease columellar show, and control the shape and curvature of the columella and infratip lobule, or simply to add stability to the nasal tip. Figure 42.4 is a montage that illustrates four common CSEG designs that (a) project and lengthen the nose without rotation, (b) rotate and lengthen with counter rotation, (c) purely rotate the nose and stabilize the tip, and (d) create a stable shape for the infratip lobule while lengthening and rotating the nose. These graft designs will be discussed in detail below.

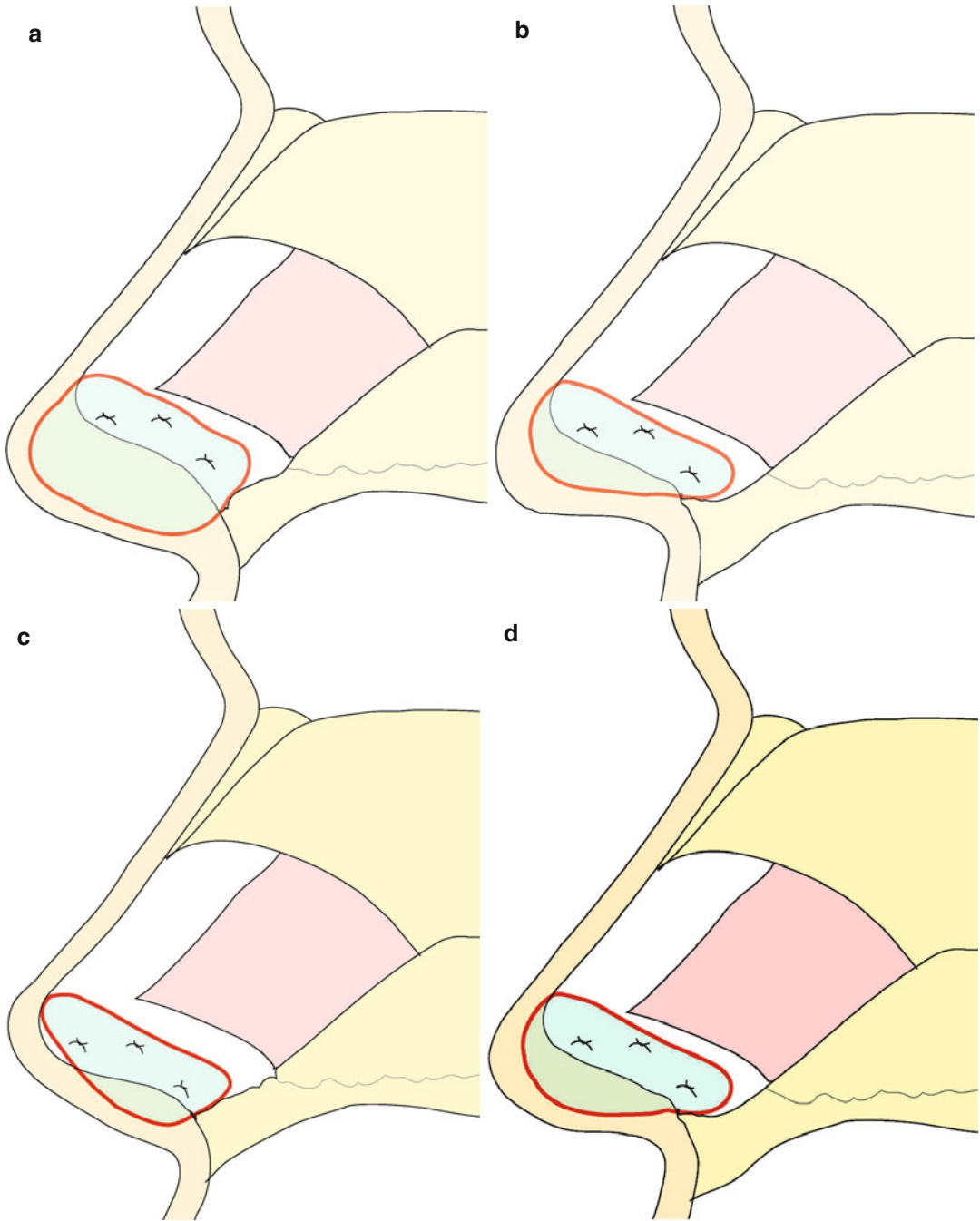


Fig. 42.4 CSEG designs that (a) Project and lengthen the nose without rotation. (b) Project and lengthen with counterrotation. (c) Purely rotate the nose and stabilize

the tip. (d) Create a stable shape for the infratip lobule while lengthening, projecting, and counterrotating the nose

42.5 Applications

42.5.1 Changing Nasal Tip Projection

In patients with a deprojected nasal tip, the medial crura can be sutured along the nasal septum in a more anterior position in order to further project the tip, provided excess caudal septum exists (simple tongue-in-groove technique). However, this anatomy is relatively uncommon, particularly in the revision rhinoplasty patient. If there is a paucity of septal cartilage in either the anterior or caudal dimensions, the septum can be extended with a CSEG so that the medial crura can be secured in a position that adequately projects the nasal tip without causing columella retraction or unwanted rotation of the tip (Fig. 42.4). Figure 42.5 illustrates the use of a CSEG to largely correct projection with little or no change to tip rotation. This patient had three previous rhinoplasty operations, and in addition to CSEG placement, a gently morselized thin auricular cartilage graft was along the dorsum. Septal perforation repair was performed, and spreader grafts were placed at the same time. Based on the shape of the caudal septal extension graft and the position of the medial crura attachment, nasal tip projection can be increased independently or in conjunction with rotation or counterrotation of the tip, lengthening or shortening the nose, or increasing or decreasing columellar show. Sutures are placed at discrete points of the overlap between the medial crura and CSEG in order to further control the appearance of the columella on lateral view. The ability to place these multiple sutures allows precise control over the extent of columellar show and appearance of the infratip lobule on lateral view. The CSEG can be modified to increase fullness of the infratip lobule as well (Fig. 42.4) and facilitate the creation of a soft double break, rather than a straight line from subnasale to tip.

In order to increase tip projection without altering other aspects of the nasal tip (e.g., rotation), a CSEG should be designed with its caudal margin roughly parallel to that of the caudal septum and its cephalocaudal distance just wide enough to extend past the cephalic margin of the

paired medial crura without passing their caudal margin. One uses this graft to create a tongue-in-groove approximation. The caudal margin of the graft is fashioned to shape the columella on lateral view. This graft is somewhat rectangular in shape [6]. The amount of anterior extension of the graft and the amount of anterior advancement of the medial crura on to the graft will determine the degree of the additional projection achieved. The “new” anterior septal angle created by the CSEG is the key surgical landmark, and it is important to design the graft such that this point is at or near the point where the desired nasal tip will reside. Inadequate extension (position of the “new” anterior septal angle) is common when first using this technique and is readily evident upon attachment of the medial crura and dome suturing. In this circumstance, the sutures need to be removed and graft repositioned.

If deprojection alone is desired (without nasal lengthening), CSEGs are seldom used. However, if the caudal margin of the native septum does not approximate the medial crura and the medial crura need to be positioned further posterior to achieve deprojection, then a CSEG may be necessary. The graft design would be rectangular in shape, similar to those used to increase projection, without significant anterior extension of the graft.

42.5.2 Changing Nasal Tip Rotation

The caudal septal extension graft can be a powerful tool to control rotation of the nasal tip, while independently controlling projection. Reliable independent control of rotation and projection is lacking in conventional columellar strut techniques when combined with lateral crural steals even with the use of shield and cap grafting. Nasal tip rotation is largely assessed by the nasolabial angle, and as such, changing this angle is achieved by changing (1) the cephalocaudal dimension of either the posterior columella—moving the pedestal of the columella more toward or away from the posterior septal angle—or (2) the position of the nasal tip at the area of the intermediate crura.

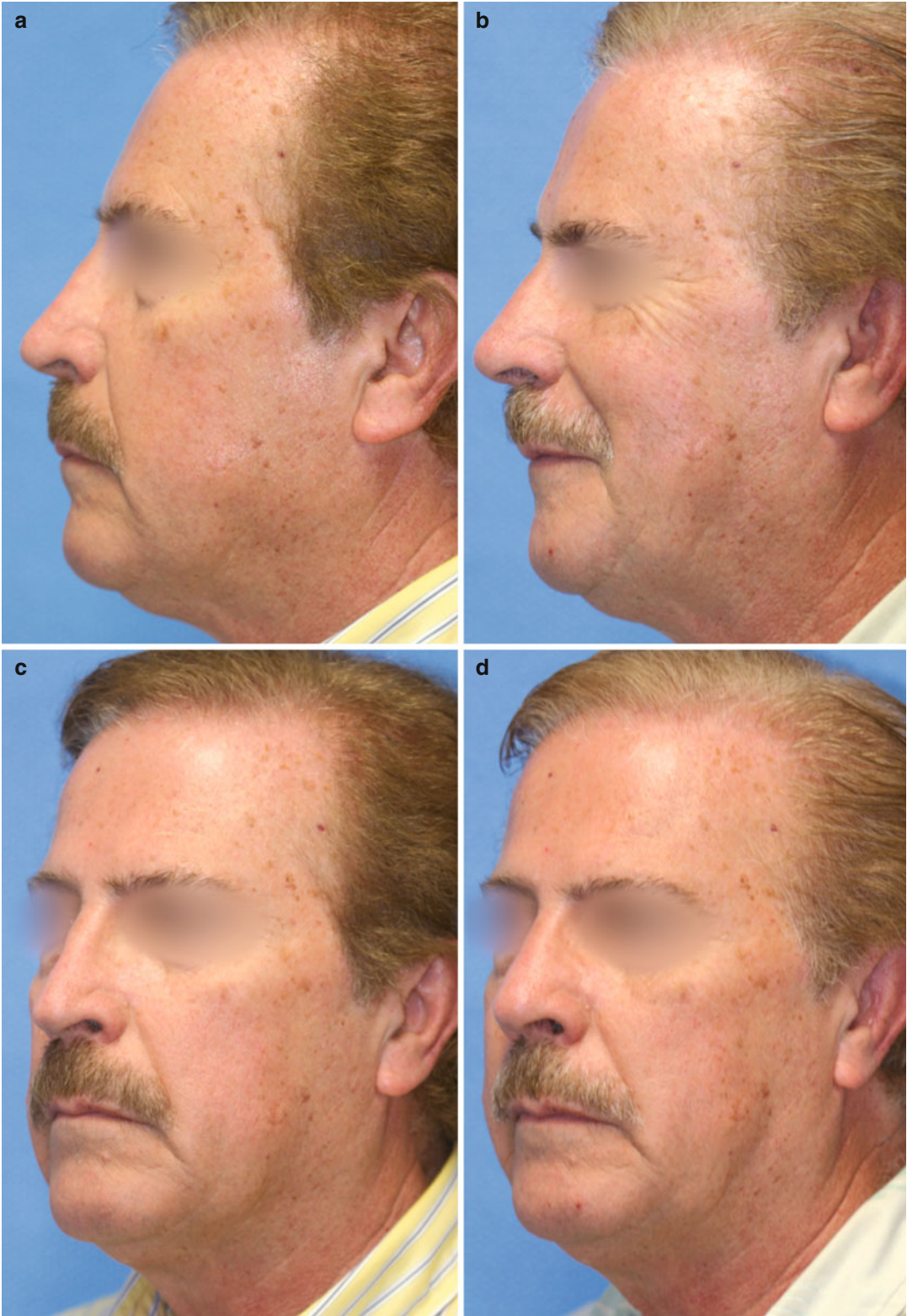

Fig. 42.5 (a) Preoperative patient with three previous rhinoplasty operations. (b) Postoperative after CSEG to correct projection with little or no change to tip rotation

Simply rotating the tip more cephalically will shorten nasal length. Conversely, if the tip area is counterrotated into a more caudal position, then overall nasal length will be increased. The relative position of the subnasale can be controlled with this technique as well (Fig. 42.4), as it may be positioned more anteriorly or posteriorly, depending upon the shape of the CSEG. It is important to remember that if subnasale position—the dimension at the columellar pedestal—is changed, this will have an inverse effect on the apparent length of the upper lip. Caudal septal extension grafts can be designed to address these specific areas in the columella-tip complex that will achieve the desired effect on tip rotation.

In order to increase tip rotation with a CSEG, the graft must be fashioned in a manner in which the graft tapers to become more cephalad at its anterior aspect—in other words more triangular with the apex pointing skyward (Fig. 42.4). This can be achieved either by (1) designing the graft to be wider in a cephalocaudal dimension at its posterior aspect (near posterior septal angle) and narrower as it approaches the nasal tip or (2) simply controlling the degree of overlap between the graft on the caudal septum so that its anterior aspect is positioned more cephalically than its posterior aspect (preferred by senior author) [2]. The key point again is determining the locus of the new anterior septal angle which is almost always more anterior and caudal than one initially anticipates. It is more prudent to create excess cartilage in the CSEG which can be precisely trimmed when the medial crura are attached and domal sutures applied. In cases where the posterior columella is positioned too far cephalically causing an acute nasolabial angle, the extension graft can be designed with excess posterior caudal extension in order to position the posterior columella more inferior and increase the nasolabial angle and tip rotation. Figure 42.6 illustrates the use of a large CSEG that creates a much more projected and rotated nasal tip; no hump reduction surgery was performed in this primary rhinoplasty patient. The images of the CSEG for this patient are in Fig. 42.3 [6]. When cartilage tissue availability is inadequate for the creation of

a CSEG along the entire border of the native caudal septum, plumping grafts can be placed along the spine.

Counterrotation of the nasal tip is accomplished by designing grafts in a manner opposite of those used to rotate the tip (Fig. 42.4); obviously, such grafts also lengthen and project the nose at the tip area. As such, this calls for grafts that are wider at their anterior aspect (i.e., near new anterior septal angle) so that the medial crura can be repositioned more caudally. If the nasolabial angle is overly obtuse, the medial crura may need to be repositioned so their footplates lie more cephalically. Typically, this can be done with a tongue-in-groove maneuver by suturing the medial crura to the caudal septum. If there is a deficiency of caudal septum, however, an extension graft may be needed to allow fixation of the medial crura without causing columella retraction. In many cases, where the nasolabial angle is obtuse, however, there is excess cartilage in the area of the posterior septal angle, making a septal extension graft unnecessary.

42.6 Lengthening the Nose

Lengthening the nose usually requires repositioning the nasal tip in a more anterior and caudal position. CSEGs are a powerful means to achieve this. By moving the nasal tip in this manner, either rotation or columella show will be affected. As previously described, a CSEG with an anterior aspect that is widened in a cephalocaudal dimension will lengthen the nose as the tip is counterrotated. This graft is useful in the short, overrotated nose. If the degree of rotation is adequate and to be preserved during nasal lengthening, then the caudal extension graft will need to be rectangular in shape to allow the entire medial crura to be advanced antero-caudally and maintain the nasolabial angle (Fig. 42.2), and sometimes must be of considerable size (Fig. 42.4). Nasal lengthening will entail stretching of the skin-soft tissue envelope, and the cartilaginous nasal tip-CSEG-septal complex will have to resist the forces of wound healing, contraction, and native tissue elasticity. This is particularly common and challenging in

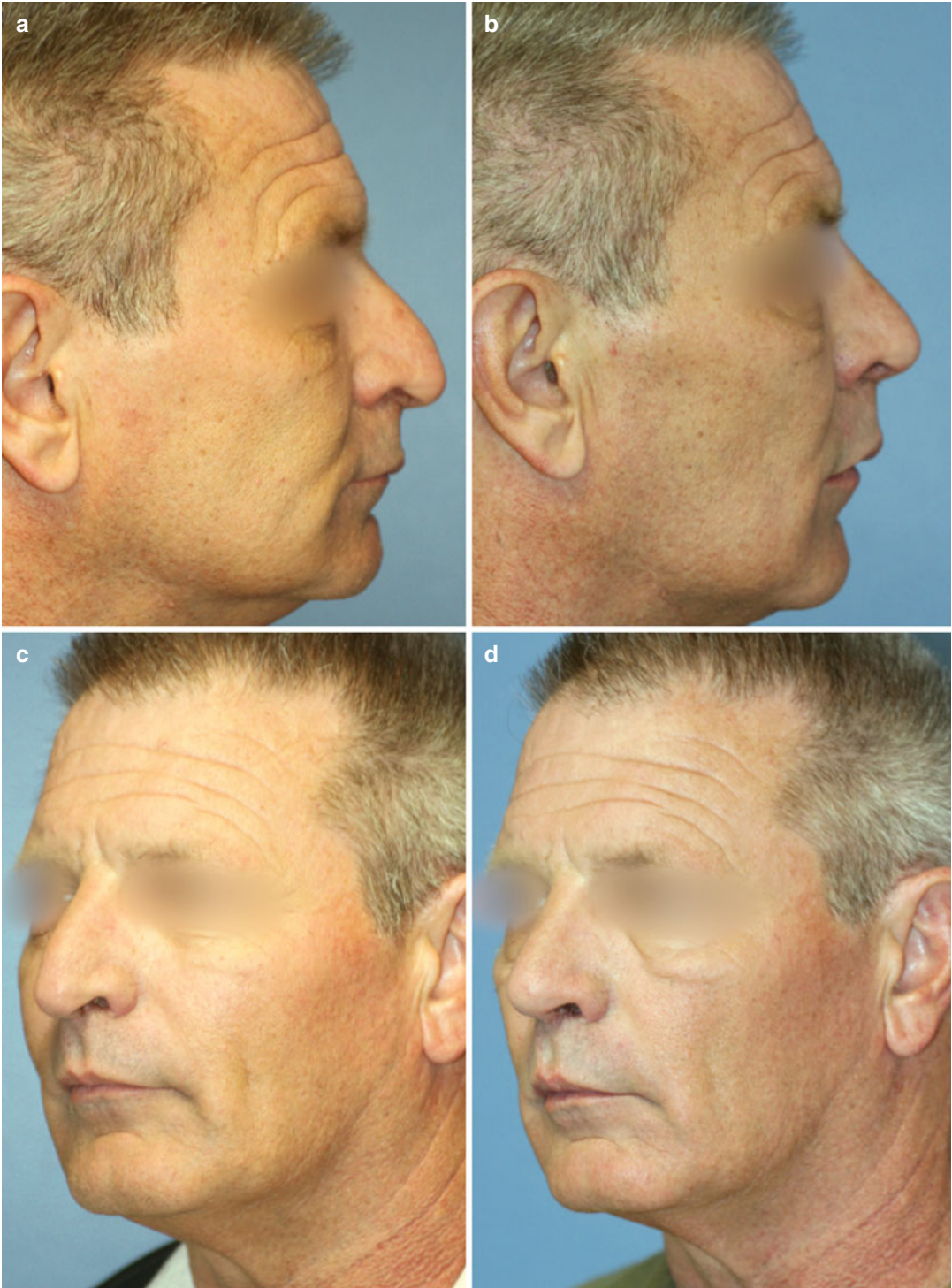

Fig. 42.6 Aggressive use of CSEG. Primary rhinoplasty patient in whom a large CSEG was used to project and rotate nasal tip; no hump reduction surgery was performed. (a) Preoperative. (b) Postoperative

revision rhinoplasty cases. In these circumstances, the senior author advocates using (1) as large a CSEG as possible, maximizing overlap with the native septum; (2) a CSEG that extends to the nasal spine; and (3) nonabsorbable sutures. A caveat is that once the skin-soft tissue envelope has been replaced, the downward forces acting upon graft may lead to flexure and buckling. Hence, it is important to consider the three measures noted above as well as considering stouter tissue such as costal cartilage.

The soft tissue envelope may ultimately limit the extent of grafting that can be performed. If the nose is to be lengthened or projected dramatically, the skin and subcutaneous tissue may not stretch enough to accommodate a large caudal septal extension graft. In these cases, the surgeon may be forced to settle for less length and projection than what is ideal. In cases of chronically infected or severely retracted skin and soft tissue, the patient may even require soft tissue reconstruction to achieve the desired outcome. Because of this, patients should be counseled with respect to these potential limitations prior to surgery. Figure 42.7 illustrates a secondary rhinoplasty patient who had resection of the anterior septal angle. The objective of surgery was to lengthen the dorsum without altering significantly nasal tip rotation. In this case, a columella strut would not have achieved this objective and, potentially, its placement would increase columellar show. A CSEG was placed to position the nasal tip defining point as well as create a softer contour along the infratip lobule. An extremely conservative carti-

laginous hump reduction was performed along with spreader graft placement. The nasal tip was created using dome suture techniques alone.

As with all CSEG applications, columellar show and infratip lobule structure will change in noses requiring this maneuver, so care must be taken when attaching sutures between the medial crura and the CSEG. It is extremely important to perform rigorous intraoperative analyses of the columellar profile in these instances.

42.7 Summary of Advantages

CSEGs provide the rhinoplasty surgeon with independent control of nasal tip projection and rotation with very stable long-term results due to the fixation of the lower alar cartilage to the nasal septum. These grafts resist the downward pull created by contraction of the skin-soft tissue envelope over time. Unlike classic columellar strut methods or lateral crural steal techniques, projection and rotation can be controlled independent of one another. Likewise, judicious selection of suture points and graft design allows for establishment of the ideal contour for the infratip lobule and nasal labial angle. One powerful application is that a retrused or deficient columella can easily be corrected. Tip position is determined by where the medial crura are attached to the CSEG using a tongue-in-groove-type technique. Conventional domal sutures are used to reestablish tip shape and reduce the need for shield or cap grafts.

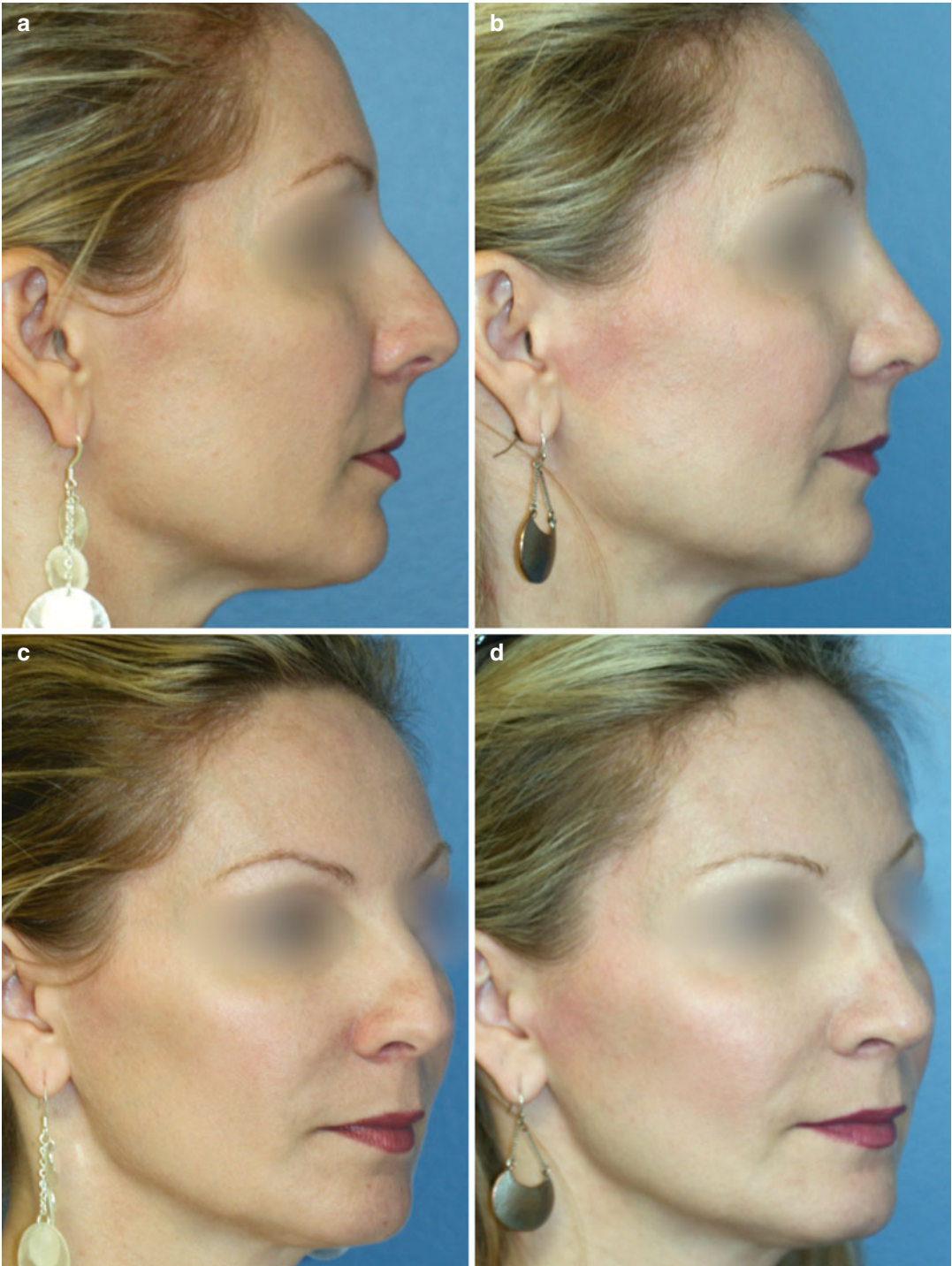

Fig. 42.7 Subtle use of CSEG in secondary rhinoplasty patient who had previous resection of the anterior septal angle (performed elsewhere). The objective of surgery

was to lengthen the dorsum without altering significantly nasal tip rotation. (a) Preoperative. (b) Postoperative

References

1. Dibbell DG (1976) A cartilaginous columellar strut in cleft lip rhinoplasties. *Br J Plast Surg* 29(3):247–250
2. Tebbetts JB (1994) Shaping and positioning the nasal tip without structural disruption: a new, systematic approach. *Plast Reconstr Surg* 94(1):61–77
3. Toriumi DM (1994) Subtotal reconstruction of the nasal septum: a preliminary report. *Laryngoscope* 104(7):906–913
4. Toriumi DM (1995) Caudal septal extension graft for correction of the retracted columella. *Oper Tech Otolaryngol Head Neck Surg* 6(4):311–318
5. Byrd HS, Andochick S, Copit S, Walton KG (1997) Septal extension grafts: a method of controlling tip projection shape. *Plast Reconstr Surg* 100(4):999–1010
6. Toriumi DM (2006) New concepts in nasal tip contouring. *Arch Facial Plast Surg* 8(3):156–185
7. Kridel RW, Scott BA, Foda HM (1999) The tongue-in-groove technique in septorhinoplasty. A 10-year experience. *Arch Facial Plast Surg* 1(4):246–256; discussion 257–258
8. Toriumi DM (2005) Structure approach in rhinoplasty. *Facial Plast Surg Clin North Am* 13(1):93–113