

# UC Davis

## Dermatology Online Journal

### Title

Incidental angiofibromas prompt a diagnosis of multiple endocrine neoplasia type-1 (MEN-1)

### Permalink

<https://escholarship.org/uc/item/4kq2z97b>

### Journal

Dermatology Online Journal, 20(9)

### Authors

Roman, John W  
Logemann, Nicholas F  
Adams, Erin

### Publication Date

2014

### DOI

10.5070/D3209023911

### Copyright Information

Copyright 2014 by the author(s). This work is made available under the terms of a Creative Commons Attribution-NonCommercial-NoDerivatives License, available at <https://creativecommons.org/licenses/by-nc-nd/4.0/>

Peer reviewed

## Case Presentation

### **Incidental angiofibromas prompt a diagnosis of multiple endocrine neoplasia type-1 (MEN-1)**

**John W. Roman MD<sup>1</sup>, Nicholas F. Logemann DO<sup>2</sup>, Erin Adams MD<sup>2</sup>**

**Dermatology Online Journal 20 (9): 5**

**<sup>1</sup>Medical Officer for the Combat Assault Battalion, 3d Marine Division, at Camp Schwab, Okinawa, Japan.**

**<sup>2</sup>Dermatology Department at Walter Reed National Military Medical Center.**

## Correspondence:

Dr. John W. Roman

PSC 482 box 2426

FPO AP 96362

Email: john.w.roman@gmail.com; john.roman@usmc.mil; john.roman@med.navy.mil

Phone: 080 3445 2553 (Japanese Number)

## Abstract

**Importance:** We believe this to be the first documented report of multiple endocrine neoplasia type-1 (MEN-1) in which the diagnosis was suspected based purely on cutaneous findings. The patient was initially referred to the dermatology department for cosmetic concerns and had no overt symptoms, laboratory abnormalities, or known family history of MEN-1.

**Observations:** The patient is a 28-year-old man who was referred to the dermatology department for evaluation and removal of skin lesions, later confirmed by biopsy to be facial angiofibromas and a truncal collagenoma. This combination of cutaneous findings was suspicious for a genodermatosis and genetic testing subsequently confirmed the diagnosis of MEN-1. The patient was referred for appropriate follow up and surveillance.

**Conclusions and Relevance:** This case highlights the importance of vigilance on the part of dermatologists to be aware of subtle skin findings that may be characteristic of rare disorders and may have gone unrecognized by other providers and the patients themselves. In this respect, dermatologists are in a unique position given their specialized training in the recognition of inherited skin disorders. An early diagnosis of an inherited disorder, especially one with increased risk of malignancy, can allow for appropriate surveillance and potentially alter the course of the disease.

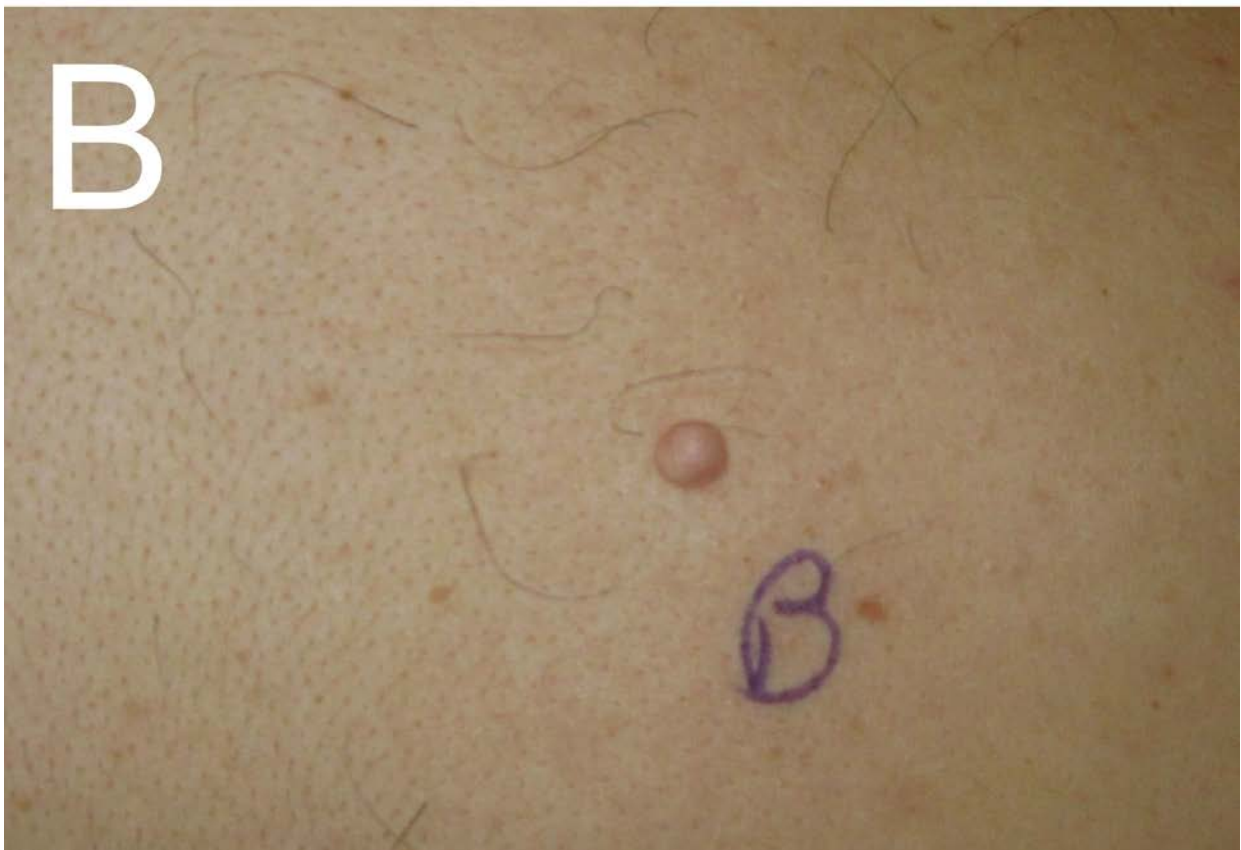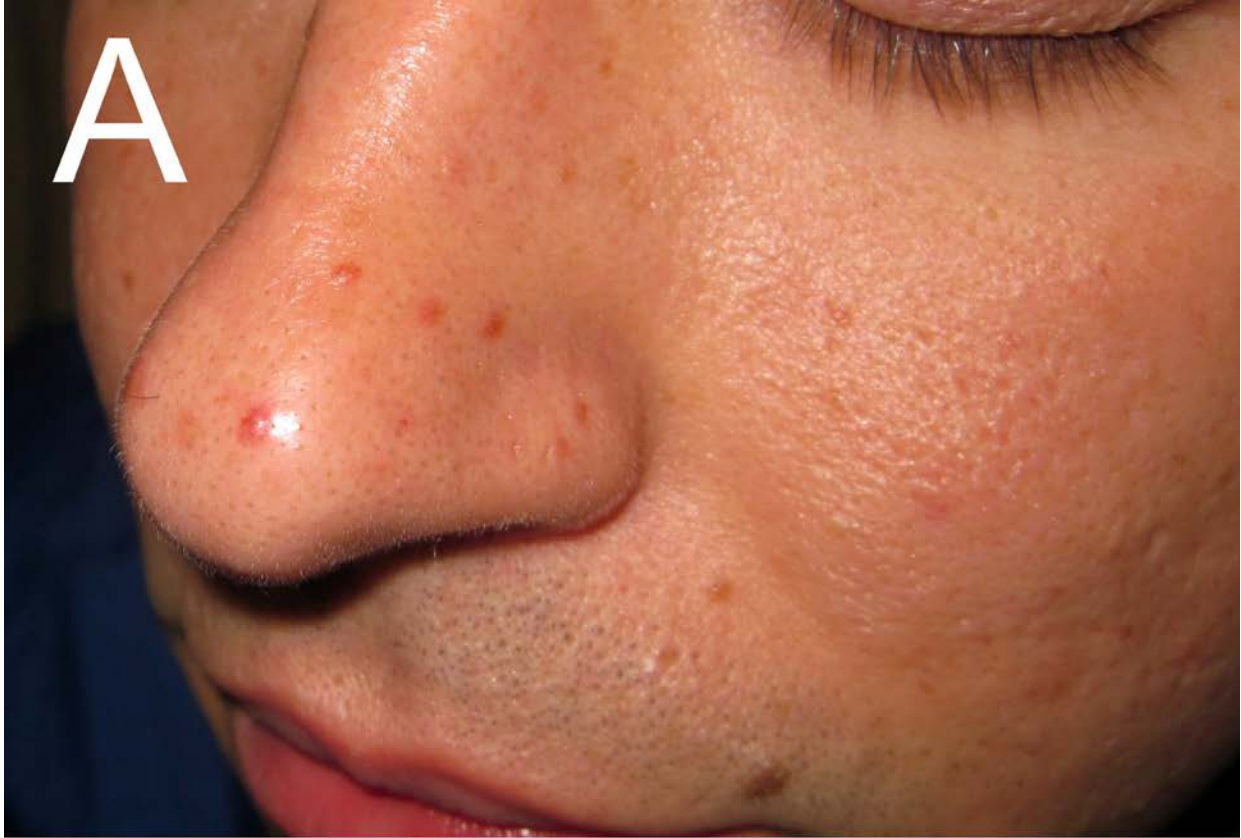**Keywords:** angiofibromas; collagenomas; multiple endocrine neoplasia type-1; cutaneous findings of systemic disease

## Introduction

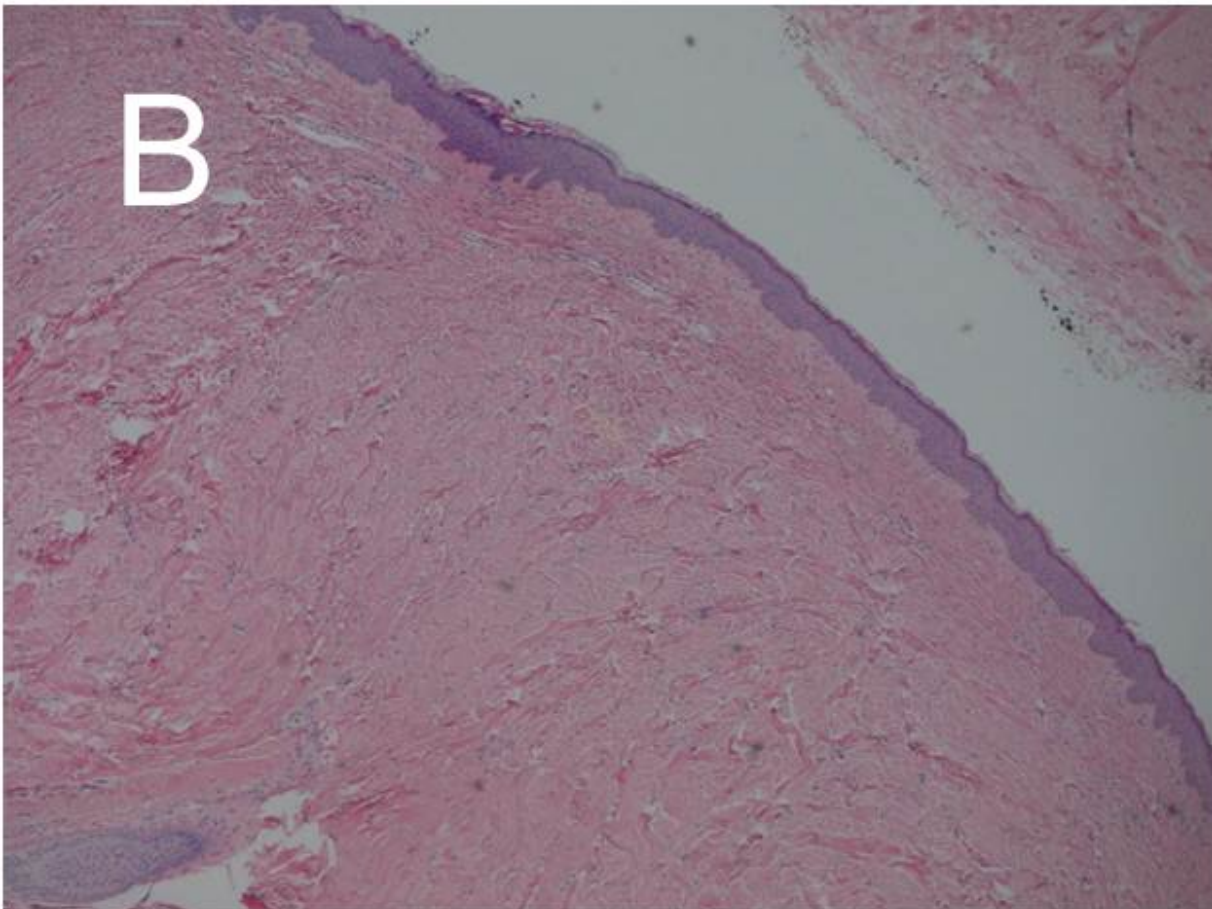
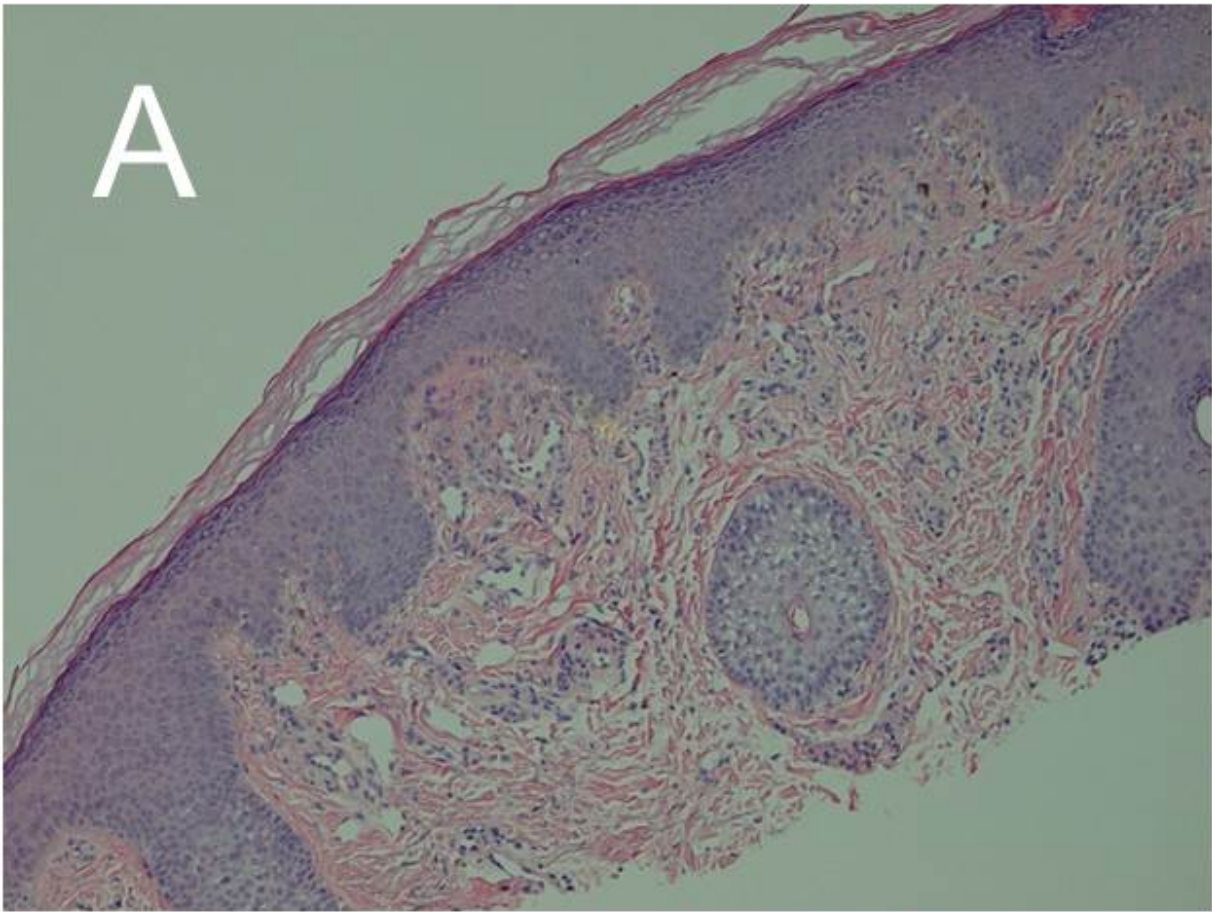
Dermatology practice is unique in medicine because the identification of a systemic disease can be based purely on cutaneous manifestations. This recognition of a disease process can occur before the symptoms of systemic disease have provided any clues to the clinician or to the patient. As a result, interventions can be made that may have an impact on overall disease progression. The case below provides a rare example of multiple endocrine neoplasia type-1 (MEN-1) that was suspected based solely on cutaneous findings prior to any overt symptoms or the presence of endocrine tumors. Genetic testing subsequently confirmed the diagnosis of MEN-1. To the best of our knowledge, there are no reports of a diagnosis of MEN-1 prompted by cutaneous findings in an otherwise healthy patient with no known family history of the disease.

## Case synopsis

A 28-year-old man was referred to the dermatology department by his primary care provider for evaluation of multiple “hemangiomas” on his nose that were cosmetically bothersome to him; the patient requested removal. Additionally, he had several “moles” on his back that were irritated by his clothing. On physical exam, the patient had numerous, 1-3mm, shiny, red papules located only on his nose and a flesh colored, sessile, 8mm papule on his right upper back (Figure 1A and B). Given the clinical findings of multiple facial papules, there was concern for a genodermatosis and transverse shave biopsies were performed. Histopathology confirmed the nasal and back lesions to be an angiofibroma and a collagenoma, respectively (Figure 2A and B).



**Figure 1.** **A.** Multiple, 1-3mm, red, shiny papules located on the patient's nose, biopsy proven angiofibromas **B.** A single, 8mm, flesh colored, sessile papule, on the patient's upper right back, a biopsy proven collagenoma



**Figure 2.** **A.** Angiofibroma of the nose is demonstrated on H&E histology at magnification x10. There are numerous dilated blood vessels as well as prominent irregular fibrosis. **B.** Collagenoma biopsied from the back of our patient is demonstrated on H&E histology at magnification



x10. There are dense collagen bundles arranged haphazardly. An elastic stain demonstrates an absence of elastic fibers thus helping to establish the diagnosis of a collagenoma.

With the combination of angiofibromas and a collagenoma, a diagnosis of tuberous sclerosis or MEN-1 was considered. Initially, the patient denied any significant family history of endocrine disease, cancer, or inherited skin disorder. However, the patient later queried his mother who then revealed a personal history of two parathyroid adenomas as well as a pituitary adenoma. Both had been surgically removed in the remote past. Despite these endocrine tumors, there was no confirmed family history of a diagnosis of MEN-1 or any other inherited skin diseases. Given the mother's history of endocrine tumors in combination with the clinical and histopathologic findings of the patient's skin lesions, genetic testing for MEN-1 was offered and revealed a single gene deletion in the MEN-1 gene. The patient was then referred to the endocrinology department where a complete systemic evaluation was ordered to include: complete metabolic panel, insulin, glucagon, pancreatic polypeptide, insulin-like growth factor, prolactin, thyroid stimulating hormone, thyroxine, adrenocorticotrophic hormone, cortisol, luteinizing hormone, follicular stimulating hormone, and magnetic resonance imaging (MRI) of the sella turcica. Unfortunately, owing to the patient's life circumstances including a change of insurance, employment and geographic location, the patient was unable to follow up with much of the indicated testing. However, his initial complete metabolic panel and thyroid and parathyroid testing were normal. In addition, the patient received genetic and disease management counseling as well as family planning advice regarding his genetic diagnosis. Furthermore, during a recent phone conversation with the patient after he transferred care from our facility, he reported having received appropriate, follow-up care from another institution.

## Discussion

This case is unique in that the diagnosis of MEN-1 was made on cutaneous findings before the patient had any symptomatic endocrine abnormalities. Awareness of his diagnosis affords him the ability for early disease recognition through periodic screening. According to current guidelines for high risk patients (i.e. those that are genetically confirmed to have MEN-1), annual laboratory studies to include calcium, parathyroid stimulating hormone, prolactin, gastrin, insulin like growth factor-1, chromogranin-A, glucose, and insulin are recommended [1]. Additionally, baseline imaging followed by periodic imaging every 1-3 years to include magnetic resonance imaging (MRI) of the pituitary, computed tomography(CT) or MRI of the chest, and CT/MRI/ultrasound of the abdomen should be performed [1]. The potential for early detection allows coordination of care with an appropriate multi-disciplinary team to include all or part of the recommended specialists in Endocrinology, Genetics, Gastroenterology, Oncology, Surgical Oncology, and Radiology [1]. This initiation of surveillance in the asymptomatic phase potentially decreases the patient's disease burden and mortality, [2, 3]. More specifically, it affords the opportunity for the disease to be identified at early stages, with milder symptoms, and fewer tumors, possibly before malignant transformation has begun [3]. Finally, early detection allows for genetic screening for all first degree relatives and future offspring. This provides the patient and their family members the opportunity to have an educated and personalized discussion about the social, psychological, ethical, and financial implications of the disease in addition to appropriate clinical surveillance [4, 5].

MEN-1 is an autosomal dominant disease process that is characterized by tumor growth in at least two endocrine organs. The most common locations (by approximate percentages) are the parathyroid gland (95%), anterior pituitary gland (40%), and gastroenteropancreatic tract (30%) [1, 5]. Presenting symptoms are usually either cutaneous or secondary to consequences from endocrine products of secretion such as nephrolithiasis, hypercalcemia, hypoglycemia, or sequelae from increased gastric acid secretion [1, 5]. The clinical syndrome has a high degree of genetic penetrance, with estimates as high as ninety percent by the fifth decade of life [6]. The leading cause of morbidity and mortality are secondary to gastroenteropancreatic tumors and carcinoid tumors [2, 3]. If left untreated, the endocrine tumors are associated with an earlier mortality in patients with MEN-1 as compared to the normal population, with a 50% chance of death by the age of fifty [2, 3].

The percentages of cutaneous manifestations in MEN-1 include: angiofibromas (88%) collagenomas (72%), café-au-lait macules (38%), lipomas (34%), confetti-like hypopigmented macules (6%), and multiple gingival papules (6%) [7]. Specifically, one study demonstrated that in 110 patients with gastrinomas and confirmed MEN-1, the presence of one or more collagenomas or three or more angiofibromas had a 75% sensitivity and 95% specificity for a diagnosis of MEN-1 [8]. This close association with MEN-1 is tied to the disease's underlying pathophysiology. In a 1998 publication, *Darling et al* demonstrated through retrospective analysis of patients already diagnosed with MEN-1 that the angiofibromas, collagenomas, and lipomas demonstrated allelic deletions of the MEN-1 gene. These deletions likely led to cellular proliferation and development of the skin lesions [9]. More specifically, bi-allelic mutations in the MEN-1 gene (11q13) and subsequent inactivation of the menin protein, a tumor suppressor protein, are implicated in the proposed pathogenesis of the disease. It is this inherited gene deletion and subsequent somatic inactivation that ultimately leads to hyperplasia and tumorigenesis in cutaneous and endocrine tissues [5, 9].

Characteristically, angiofibromas in MEN-1 are multiple, a few millimeters in size, skin-colored to erythematous papules located mainly on the central face. Collagenomas are skin-colored papules and nodules, varying in number that usually present on the trunk [10]. Although the combination of angiofibromas and collagenomas are suggestive of MEN-1, by themselves they are not

diagnostic of the disease; other conditions may also have these skin findings (i.e. tuberous sclerosis). Although clinically indistinguishable, the angiofibromas in MEN-1 tend to be fewer in number and involve the upper vermilion border, an area commonly spared by the angiofibromas of tuberous sclerosis [11].

Similarly, collagenomas are also found in a number of other conditions besides MEN-1. For example, patients with Cowden syndrome can demonstrate multiple storiform collagenomas [12], whereas patients with familial cutaneous collagenomas have papules that occur symmetrically on the trunk typically in their teenage years [13]. Additionally, patients with Birt-Hogg-Dube syndrome can have associated collagenomas and angiofibromas [14]. Likewise, two non-familial conditions, eruptive collagenomas or isolated collagenomas, can have either numerous rapidly appearing collagenomas or slowly growing solitary lesions, respectively [15]. All of these entities should be considered in the differential diagnosis of patients presenting with angiofibromas and collagenomas. This wide differential demonstrates the importance of correlation of cutaneous findings with other clinical symptoms, family history, laboratory, imaging studies, histopathology, and genetic testing.

In the appropriate clinical setting, early diagnosis of MEN-1 may be accomplished through the recognition of cutaneous manifestations prior to the patient's exhibition of overt symptoms. Future areas of research could consider investigating the utility of thorough dermatologic exams in patients who have family members with multiple endocrine tumors to facilitate early recognition of this inherited disease. In our patient, the presence of multiple facial papules prompted additional questioning and evaluation leading to the ultimate diagnosis.

## References

1. Thakker RV, Newey PJ, Walls GV, et al. Endocrine Society. Clinical practice guidelines for multiple endocrine neoplasia type 1 (MEN1). *J Clin Endocrinol Metab.* 2012; 97(9):2990–3011. [PMID: 22723327]
2. Geerdink EA, Van der Luijt RB, Lips CJ. Do patients with multiple endocrine neoplasia syndrome type 1 benefit from periodical screening? *Eur J Endocrinol.* 2003; 149(6):577–582. [PMID: 14641000]
3. Dean PG, Van Heerden JA, Farley DR, et al. Are patients with multiple endocrine neoplasia type I prone to premature death? *World J Surg.* 2000; 24(11):1437–1441. [PMID: 11038219]
4. Lourenço DM Jr, Toledo RA, Coutinho FL, et al. The impact of clinical and genetic screenings on the management of the multiple endocrine neoplasia type 1. *Clinics (Sao Paulo).* 2007; Aug; 62(4):465-76. [PMID: 17823710]
5. Thakker RV. Multiple endocrine neoplasia type 1. *Indian J Endocrinol Metab.* 2012 Dec; 16 (Suppl 2):S272-4. [PMID:23565397]
6. Machens A, Schaaf L, Karges W, et al. Age-related penetrance of endocrine tumors in multiple endocrine neoplasia type 1 (MEN1): a multicentre study of 258 gene carriers. *Clin Endocrinol (Oxf).* Oct; 67(4):613– 622. [PMID: 17590169]
7. Darling TN, Skarulis MC, Steinberg SM, Marx SJ, Spiegel AM, Turner M. Multiple facial angiofibromas and collagenomas in patients with multiple endocrine neoplasia type 1. *Arch Dermatol.* 1997 Jul;133(7):853-7. [PMID:9236523]
8. Asgharian B, Tuner ML, Gibril F, Entusuah LK, Serrano J, Jensen RT. Cutaneous tumors in patients with multiple endocrine neoplasm type 1 (MEN1) and gastrinomas: prospective study of frequency and development of criteria with high sensitivity and specificity for MEN1. *J Clin Endocrinol Metab.* 2004;89(11):5328-36. [PMID: 15531478]
9. Pack S, Turner ML, Zhuang Z, et al. Cutaneous tumors in patients with multiple endocrine neoplasia type 1 show allelic deletion of the MEN-1 gene. *J Invest Dermatol.* 1998; 110(4):438 –440. [PMID: 9540988]
10. Xia Y, Darling TN. Rapidly growing collagenomas in multiple endocrine neoplasia type I. *J Am Acad Dermatol.* 2007 May;56(5):877-80. Epub 2006 Dec 22. [PMID: 17188781]
11. Darling TN, Moss J, Mausner M. Dermatologic Manifestations of Tuberous Sclerosis Complex (TSC). In: DJ Kwiatkowski, VH Whittemore, E Thiele. *Tuberous Sclerosis Complex: Genes, Clinical Features and Therapeutics.* Boston, MA: Wiley-Blackwell; 2010: 285-309.
12. L. Requena, J. Gutierrez, E. Sanchez Yus. Multiple sclerotic fibromas of the skin: a cutaneous marker of Cowden's disease. *J Cutan Pathol.* 1992 Aug; 19(4): 346–35. [PMID: 1430474]
13. Park MY, Choi YJ, Lee JY, Shin MS, Ahn JY. A case of familial cutaneous collagenoma. *Ann Dermatol.* 2011 Sep;23 (Suppl 1):S119-22. [PMID: 22028557]
14. Schaffer JV, Gohara MA, McNiff JM, Aasi SZ, Dvoretzky I. Multiple facial angiofibromas: a cutaneous manifestation of Birt-Hogg-Dubé syndrome. *J Am Acad Dermatol.* 2005 Aug; 53(2 Suppl 1):S108-11. [PMID: 16021156]
15. Batra P, Loyd A, Patel R, Walters R, Stein JA. Eruptive collagenomas. *Dermatol Online J.* 2010 Nov 15;16(11):3. [PMID: 21163154]