

UC Davis

Dermatology Online Journal

Title

A case report of crusted scabies in an adult patient with Down syndrome

Permalink

<https://escholarship.org/uc/item/4kc74256>

Journal

Dermatology Online Journal, 21(8)

Authors

Nagsuk, Phillips
Moore, Rachel
Lopez, Lisa

Publication Date

2015

DOI

10.5070/D3218028438

Copyright Information

Copyright 2015 by the author(s). This work is made available under the terms of a Creative Commons Attribution-NonCommercial-NoDerivatives License, available at <https://creativecommons.org/licenses/by-nc-nd/4.0/>

Letter

A case report of crusted scabies in an adult patient with Down syndrome

Phillips Nagsuk, MSIV¹, Rachel Moore MD¹, Lisa Lopez MD²

Dermatology Online Journal 21 (8): 13

¹Baylor Scott & White Health/Texas A&M College of Medicine, College Station, TX. – Department of Dermatology

²Department of Pathology, Baylor Scott & White Health/Texas A&M College of Medicine, Temple, TX. – Department of Pathology

Correspondence:

Phillips Nagsuk, MSIV
Attn: Rachel Moore MD
Baylor Scott and White
Department of Dermatology
1700 University Dr.
College Station, TX. 77840
Email: nagsuk@medicine.tamhsc.edu
Phone: (979) 691-3300
Fax: (979) 691-3453

Abstract

Importance: Crusted (Norwegian) scabies is a severe manifestation of the contagious skin infection caused by *Sarcoptes scabiei*. Crusted scabies has been well described in patients with known immunocompromised states. Treatment may be complicated by delayed diagnosis and/or inadequate treatment. This infection may not rank highly on one's differential diagnosis in the absence of an immunocompromised state, highlighting the uniqueness of the case being presented. Several papers describe immunocompromised children with Down syndrome who are infected with crusted scabies. We present a case of infection in an adult with Down syndrome without evidence of an immunocompromised state.

Observations: Our patient came to us with a 13-month history of progressively worsening symptoms, the last 4-6 weeks of that time period being most dramatic, despite various treatments. We performed tissue biopsy, culture, and laboratory evaluations, which revealed numerous mites and bacterial superinfection.

Conclusions and Relevance: Crusted scabies infection may occur in adult age individuals with Down syndrome regardless of immune status, leading us to encourage practitioners to consider this condition when presented with patients of this population. We also highlight the need for further exploration of disease prevalence in this patient population.

Key Words: Norwegian scabies, crusted scabies, immunosuppression, infestation, Down syndrome, eczema, Ppalmoplantar psoriasis, parasites, palmoplantar keratoderma

Abbreviation List:

AIDS: Adult Immune Deficiency Syndrome

CBC: Complete Blood Count

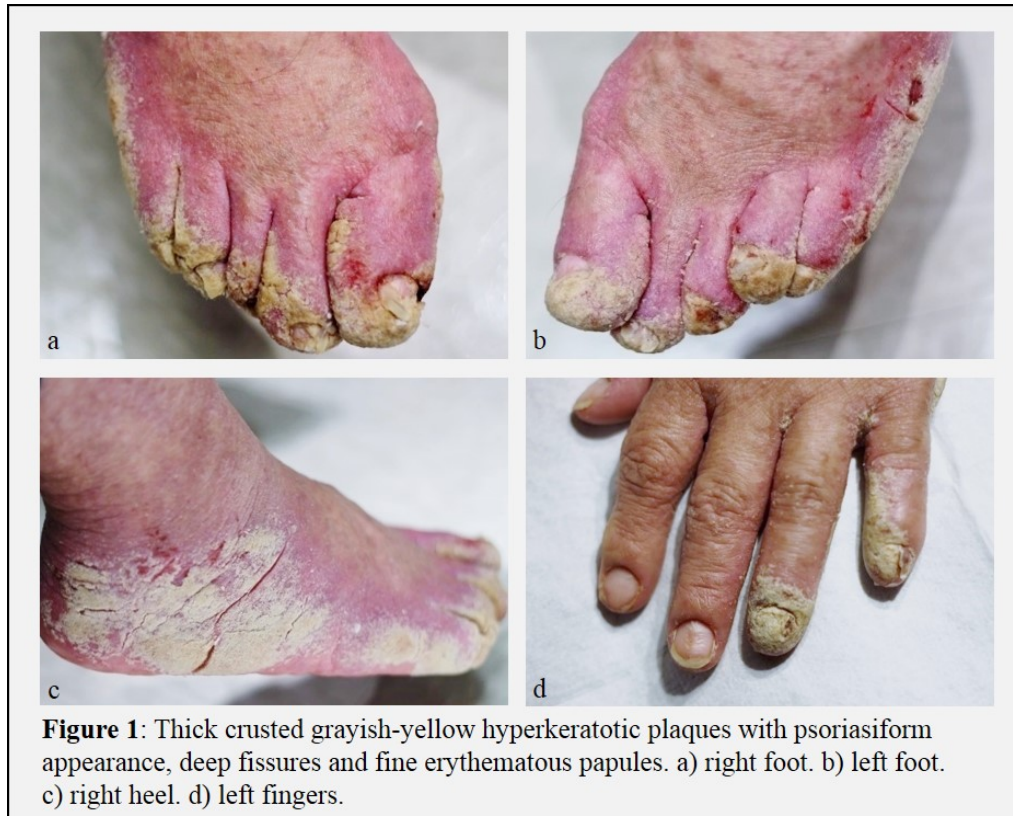CMP: Complete Metabolic Profile

TSH: Thyroid Stimulating Hormone

Introduction

Cases of crusted (Norwegian) scabies have been well described in patients with known immunocompromised states such as AIDS, lymphoma, organ transplant, chronic high-dose corticosteroid therapy, and leprosy [1,2,3]. We report the case of an adult patient with Down syndrome who developed severe crusted scabies.

Case synopsis



A 46-year-old woman with a history of Down syndrome, eczema, bilateral cataracts, and seizure disorder presented as a new patient with a 13-month history of palmoplantar pruritus, erythema, and body rash that had originated at the hands and feet and had rapidly worsened in the last 4-6 weeks, becoming increasingly malodorous. During this 4-6 week period, family members also witnessed the patient scratching several regions of her body to the point of bleeding. Physical examination revealed thick crusted grayish-yellow hyperkeratotic plaques over the bilateral distal hands and feet with a psoriasiform appearance. There was full involvement of the nail plates, deep fissures on hands and feet, and fine erythematous papules disseminated over the arms, legs, neck, and face accompanied by excoriations in various stages of healing. The patient denied complaints of diaphoresis, tinnitus, syncope, diarrhea, dysuria, abdominal pain, headache, chills, anorexia, or insomnia. She was afebrile, with stable vital signs.

Over this 13-month period, the patient had been diagnosed and treated by multiple physicians for eczema and tinea corporis with worsening symptoms. Topical treatments of triamcinolone, clobetasol, ciclopirox, and nystatin and oral treatments of terbinafine and fluconazole were used without relief of symptoms. It is noteworthy that neither of the two family members who reside with the patient nor other family members who regularly visit the patient complained of pruritus or other symptoms. Additionally, the patient had no documented history or current evidence of an immunocompromised state.

A 4mm punch biopsy of the right volar thenar region was performed, and the specimen was sent for analysis. Multiple superficial fissures and hyperkeratotic plaques of the distal extremities were also swabbed and cultured. Blood was drawn for laboratory testing which included CBC, CMP, TSH, and anti-convulsant drug levels.

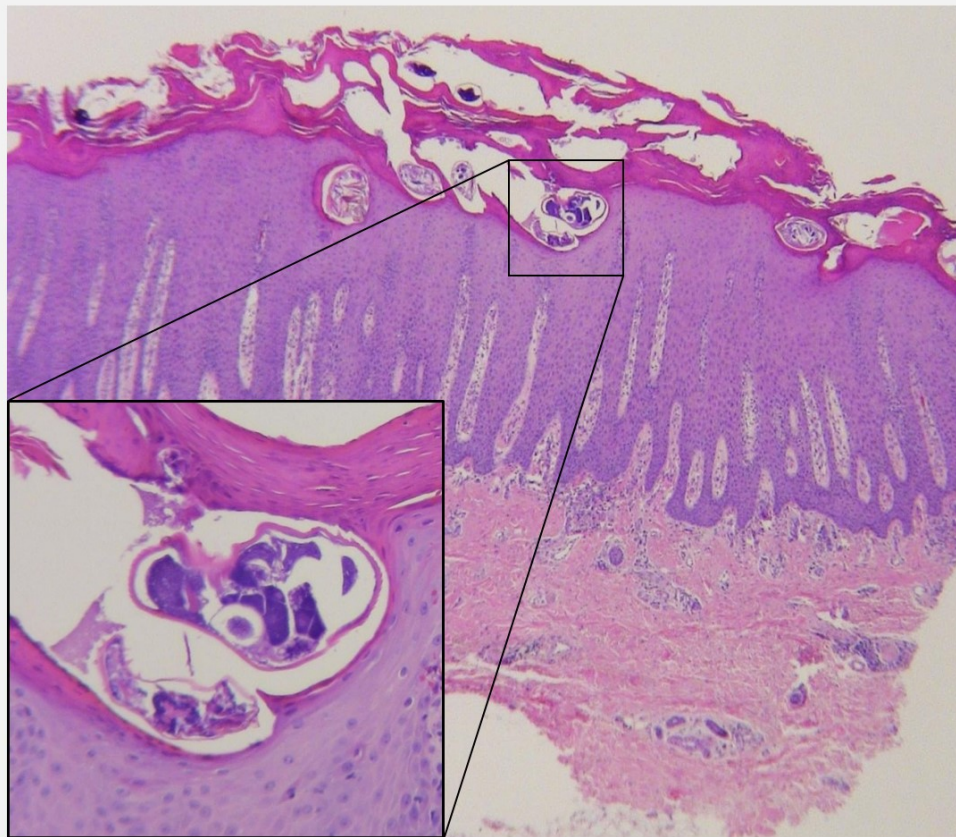


Figure 2: Tissue Biopsy - Marked psoriasiform hyperplasia with prominent hyperkeratosis and numerous mites.

Histological analysis of the tissue biopsy revealed marked psoriasiform hyperplasia with mild spongiosis, prominent parakeratosis, mild dermal fibrosis, and mixed inflammation with scattered eosinophils and extravasated red blood cells. Numerous mites were present both within the keratin and within furrows in the upper epidermis. Cultures of the fissures of bilateral hands and feet revealed bacterial superinfection with *Escherichia coli*, *Staphylococcus aureus*, and *Streptococcus agalactiae*. Labs revealed no marked abnormalities.

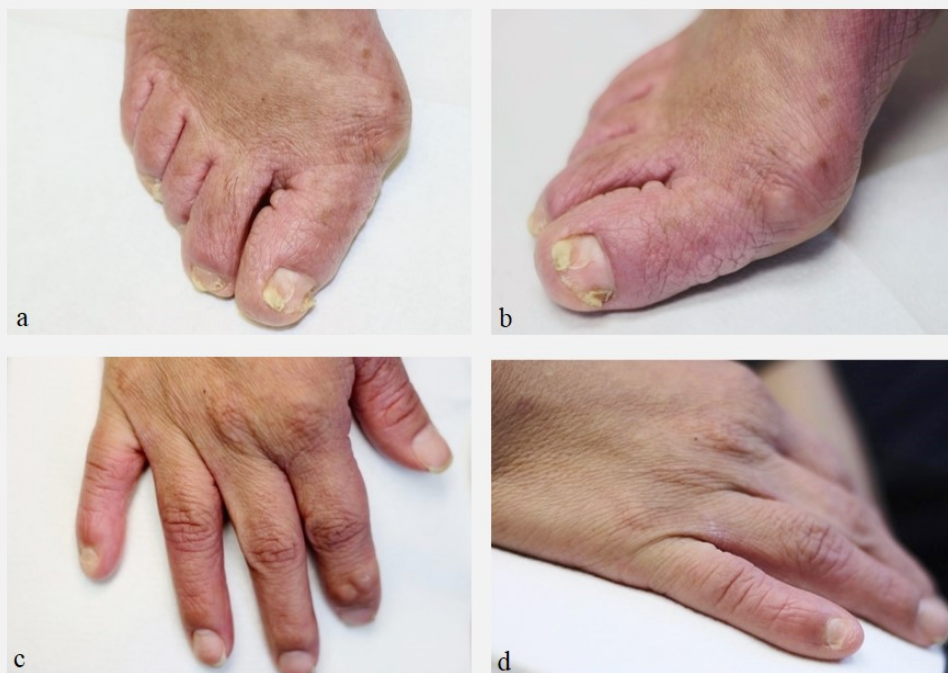

Figure 3: Two month follow-up after completion of treatment. a) right dorsal foot. b) right medial foot. c) right dorsal hand. d) right medial hand.

The patient was treated with the recommended two doses of topical 5% permethrin and two doses of oral ivermectin 200 µg/kg for the crusted scabies separated by 10 to 14 days [4,5,6]. Doxycycline and sulfamethoxazole-trimethoprim were given for

concurrent bacterial infection of hands and feet. Antibiotics were selected based on culture sensitivity results. Family members received topical treatment with 5% permethrin once the diagnosis was established and were strongly encouraged to thoroughly wash exposed clothing and bedding with hot water and dry with a hot dryer [6]. The patient returned to our clinic for follow-up at two months after initial visit having completed her treatment regimen, with satisfactory resolution of all symptoms and infection.

Discussion

Crusted scabies is a rare and severe manifestation of the common disease, scabies, caused by the mite, *Sarcoptes scabiei* [2]. It is well established that the diagnosis of crusted scabies may be delayed owing to a lack of specialized care and a variable presentation. The differential diagnosis also includes palmoplantar psoriasis, eczema, tinea, palmoplantar keratoderma, and Langerhan's cell histiocytosis [4,5]. Owing to the extremely contagious nature of this disease, physicians should keep scabies in mind when examining patients who present with hyperkeratosis and severe pruritus of the distal extremities particularly when an erythematous papular eruption is also present. Additionally, the associated fissures may provide optimal conditions for bacterial superinfection to arise [2,7]. The patient and/or individuals living in close proximity to the patient may not actually present with pruritus given the variability of pruritic symptoms [2]. In instances in which the history may not lead to clear diagnosis, skin scrapings and dermoscopy are excellent first line diagnostic measures, although biopsy can provide needed confirmation [3].

It is well documented that immunocompromised patients are at increased risk of developing crusted scabies infestation. Several pediatric reports of crusted scabies in patients with Down syndrome have been published [8,9]. However, our patient is in an adult with no definitive evidence of immunosuppression, which has been documented in previous cases [10]. It is not well understood why Down syndrome may increase a patient's susceptibility to crusted scabies in absence of lymphoma or other immunosuppressive states. We encourage the further study of individuals in this patient population.

References:

1. Sampathkumar K, Mahaldar A, Ramakrishnan M, et al. Norwegian scabies in a renal transplant patient. *Indian J Nephrol* 2010; 20(2):89-91 [PMID: 20835323]
2. Chosidow O. Scabies and pediculosis. *The Lancet* 2000; 355(9206):819-826 [PMID: 10711939]
3. Wong S, Woo P, Yuen K. Unusual Laboratory Findings in a Case of Norwegian Scabies Provided a Clue to Diagnosis. *J. Clin. Microbiol* 2005; 43(5):2542-2544 [PMID: 15872307]
4. Heukelback J, Feldmeier H. Scabies. *Lancet* 2006; 367:1767-1774 [PMID: 16731272]
5. Chosidow O. Scabies. *N Engl J Med* 2006; 354:1718-1727 [PMID: 16625010]
6. Gunning K, Pippitt K, Kiraly B, et al. Pediculosis and Scabies: A Treatment Update. *Am Fam Physician* 2012; 86(6):535-541 [PMID: 23062045]
7. Lin S, Farber J, Lado L. A CASE REPORT OF CRUSTED SCABIES WITH METHICILLIN-RESISTANT STAPHYLOCOCCUS AUREUS BACTEREMIA. *J Am Geriatr Soc* 2009; 57(9):1713-1714 [PMID: 19895437]
8. Fonseca V, Price H, Jeffries M, et al. Crusted Scabies Misdiagnosed as Erythrodermic Psoriasis in a 3-Year-Old Girl with Down Syndrome. *Pediatr Dermatol* 2013; 31(6):753-754 [PMID: 24138478]
9. Nijamin T, Laffargue J, Mantero N, et al. Norwegian scabies in a pediatric patient with Down syndrome. *Arch Argent pediatr* 2013; 111(6):141-143 PMID: 24196772
10. Aubin F, Humbert P. Ivermectin for Crusted (Norwegian) Scabies. *N Engl J Med* 1995; 332:612 [PMID: 7838209]